AGENCY FOR INTERNATIONAL DEVELOPMENT
WASHINGTON, D. C. 20523

BIBLIOGRAPHIC INPUT SHEET

FOR AID USE ONLY
0179

1. SUBJECT CLASSIFICATION

A. PRIMARY: Agriculture — AL72-0000-0000

B. SECONDARY: Pests of animals

2. TITLE AND SUBTITLE

Blood parasites in Texas deer

3. AUTHOR(S)

Robinson,R.M.; Kuttler,K.L.; Emerson,H.R.; Jones,L.P.; Marburger,R.G.

4. DOCUMENT DATE: 1968

5. NUMBER OF PAGES: 6p.

6. ARC NUMBER: ARC

7. REFERENCE ORGANIZATION NAME AND ADDRESS

Tex.A&M

8. SUPPLEMENTARY NOTES *(Sponsoring Organization, Publishers, Availability)*

(In Trans.of 33d North Am.Wildlife and Natural Resources Conf.,p.359-364)

9. ABSTRACT

10. CONTROL NUMBER

PN-RAA-128

11. PRICE OF DOCUMENT

12. DESCRIPTORS

Anaplasmosis
Babesiasis
Eperythrozoon
Serodiagnosis
Deer

13. PROJECT NUMBER

14. CONTRACT NUMBER

CSD-1947 Res.

15. TYPE OF DOCUMENT

AID 590-1 (4-74)

Reprinted from Transactions of the Thirty-Third North American Wildlife and Natural Resources Conference, March 11, 12, 13, 1968. Published by the Wildlife Management Institute, Wire Building, Washington, D. C. 20005

CSd 3675 2114

BLOOD PARASITES IN TEXAS DEER[1]

R. M. ROBINSON,[2] K. L. KUTTLER,[3] H. R. EMERSON,[2] L. P. JONES[3]
Texas A & M University, College Station, and

R. G. MARBURGER
Texas Parks and Wildlife Department, Kerrville

The Texas white-tailed deer harbors several hemoprotozoa. These organisms are of concern no only to those who aspire to properly manage the white-tailed deer for recreation or protein production, but also to those who produce protein in the form of domestic livestock for profit. Due to the free ranging habits of deer, any disease of these animals should be of concern to those who graze other ruminants concomitantly with them.

A representative of most of the major forms of hemoprotozoa may

[1]A contribution of a cooperative project between the Texas Parks and Wildlife Department and the Department of Veterinary Pathology, College of Veterinary Medicine, and the Texas Agriculture Experiment Station, Texas A&M University supported by Texas Pittmann-Robertson Project W-93-R. Dr. Emerson is partially supported by a grant from the Welder Wildlife Foundation, Sinton, Texas.
[2]Department of Veterinary Pathology.
[3]Institute of Tropical Veterinary Medicine.

be found in the Texas white-tailed deer. Deer are excellent hosts for hemoprotozoa, constituting an ideal environment for the parasite. Deer have good resistance to these infections and usually survive for some time with the disease unless subjected to undue physiological stress. Should any of the diseases to which we refer be transmissible to other ruminants, the problem of control becomes difficult and very costly.

With these concepts in mind, then, let us review those hemoprotozoan infections which are known in Texas white-tailed deer.

EPERYTHROZOONOSIS

Following splenectomy of Texas deer derived from wild populations, exacerbations of eperythrozoonosis may occur (Kuttler *et al.*, 1968). Eperythrozoon parasitemia reaches a peak about 14 days following splenectomy. High parasitemias result in these infections, and a drop in packed cell volume and mild icterus is generally seen. Deaths resulting from this infection are rare in deer.

Infections of eperythrozoon are not believed to cause many deaths in wild deer populations, and clinical illness has not been observed in unsplenectomized deer. This organism is commonly carried by wild deer however, and the latter must be regarded as a good host for it.

ANAPLASMOSIS

Mule deer (*Odocoileus hemonius*) have been demonstrated to be a reservoir host for *Anaplasma* in the Northwestern U. S. (Christensen *et al.*, 1960; Howe *et al.* 1964, Osebold *et al*, 1959). In contrast, white-tailed deer in the Southeastern U. S. seemed to be of less importance as a carrier of the organism (Bedell, 1966); infection of splenectomized calves having failed following their inoculation with pooled blood samples from 270 white-tailed deer.

Spontaneous clinical disease caused by *Anaplasma* has not been demonstrated in wild Texas deer. Satisfactory serological tests have been developed utilizing experimental *Anaplasma* infections in deer by Kuttler at Texas A&M University. The capillary agglutination (CA) test in particular has proven quite reliable in the detection of antibody titers in experimentally infected deer (Kuttler 1968).

During the summer of 1967 a single positive reaction to the CA test was found using serum from a deer from Wharton County, Texas. This is an enzootic area for anaplasmosis in cattle. Following this observation, 11 of 21 samples from deer in Anderson County, and 2 of 8 samples taken in from deer in Colorado County, gave positive reactions, both being enzootic areas.

Experimental unsplenectomized deer have maintained *Anaplasma*

infections for long periods without clinical signs. Serial passage of *Anaplasma* of bovine origin in splenectomized deer has resulted in anemia and high parasitemia, suggesting that this agent can adapt and increase in virulence to white-tailed deer.

It is not known to date how *Anaplasma* behave in wild deer herds in Texas. Natural infections are not as uncommon as has been previously indicated. Arthropod vectors, such as tabanids and ticks are found in abundance in enzootic areas.

Basically then, *Anaplasma* may be maintained in carrier deer for long periods. CA testing is effective in experimental cases, and reactor deer are present in the wild deer in Texas Anaplasma enzootic areas.

THEILERIASIS

Theileriasis is the most common hemoprotozoan disease of deer in Texas (Robinson *et al.*, 1967). This disease is of some importance to the wild deer herds. Deaths due to this disease may occur, particularly in times of physiological stress. Clinically the disease is characterized by anemia manifested by a decrease in packed cell volume, debility, dyspnea and pale mucous membranes and skin. Marked icterus is not seen in field or experimental cases. The majority of deer in the eastern half of Texas are infected by this organism, thus it is obvious that many more deer are infected than die of the disease. Theileria are not highly pathogenic by themselves, but when the disease occurs along with other debilitating factors such as drouth or a concomitant disease, it may become a major cause of deer losses. This disease is transmitted by at least one species of tick, *Amblyomma americanum* (Kuttler *et al.*, 1967) and control, if required, must necessarily be directed to the control of the arthropod vector.

Complement fixation and capillary agglutination tests which have been developed are adequate for the detection of this infection (Kuttler *et al.*, 1967, Kuttler and Robinson, 1967).

Domestic livestock are refractory to experimental infection with this organism (Smith, 1967). It has not been established if the exotic game species now present on Texas ranges are susceptible to this disease.

HABESIASIS

A species of *Babesia* was found in a deer in New Mexico by Spindler in 1958. Emerson isolated a species of *Babesia* from deer in Tyler County, Texas in 1966. Since then, this organism has been re-isolated from deer from Tyler and Polk counties. This hemoprotozoan produces an acute disease in white-tailed deer characterized by hemoglobinuria, marked icterus and death in a few days after inoculation.

Experimentally infected splenectomized deer die in 4-21 days. Unsplenectomized deer under controlled conditions have developed into carriers which have been infective for as long as eight months.

This disease may figure prominently in deer mortality in enzootic areas. Isolations have been made where deer losses occurred. The deer in these herds were in poor condition. Tick infestations of deer in these areas were extremely heavy, and it would appear that ticks were probably the vector.

Investigations are presently underway to determine the importance of this disease to domestic livestock.

A nonpathogenic *Babesia* which is morphologically different from the pathogenic one mentioned above also has been found in splenectomized deer. This organism is larger and does not produce clinical illness even in splenectomized animals. It is difficult to maintain by serial passage in splenectomized deer and is viewed as an academic curiosity. It has been found in three splenectomized deer.

DISCUSSION

Two of the diseases mentioned are of particular concern because of their possible importance to the livestock industry. It has been shown that deer are hosts for *Anaplasma*, their capability for carrying this organism for long periods having been demonstrated. The parasite-host relation is an excellent one, the deer showing little or no clinical effects. Ranchers who are in the practice of introducing livestock for stocking purposes from non-enzootic areas should expect losses from this disease, particularly in areas with high vector populations, due to the presence of both bovine and cervine carriers.

Texans have long had considerable respect for *Babesia bigemina* infections in cattle, and quarantine and dipping regulations intended to control their spread are still in force, particularly in the southern part of the state. We therefore approach this disease in deer with extreme caution. Fortunately, pilot studies indicate that this disease of deer is not readily transmitted to domestic livestock.

Babesiosis and Theileriasis alike are important contributors to deer mortality in the state. It appears that the pathogenic *Babesia* is less widely distributed, but must be recognized as being of greater importance where it does occur as it is more pathogenic to deer.

Diagnostic problems may arise from attempts to differentiate *Anaplasma*, *Theileria*, and *Babesia* by morphological characteristics alone. Variant forms of each organism may be found which resemble the other organisms morphologically (Fig. 1). The diagnostic problem is complicated also by the fact that two or more infections may exist simultaneously in the same host. These infections must be differenti-

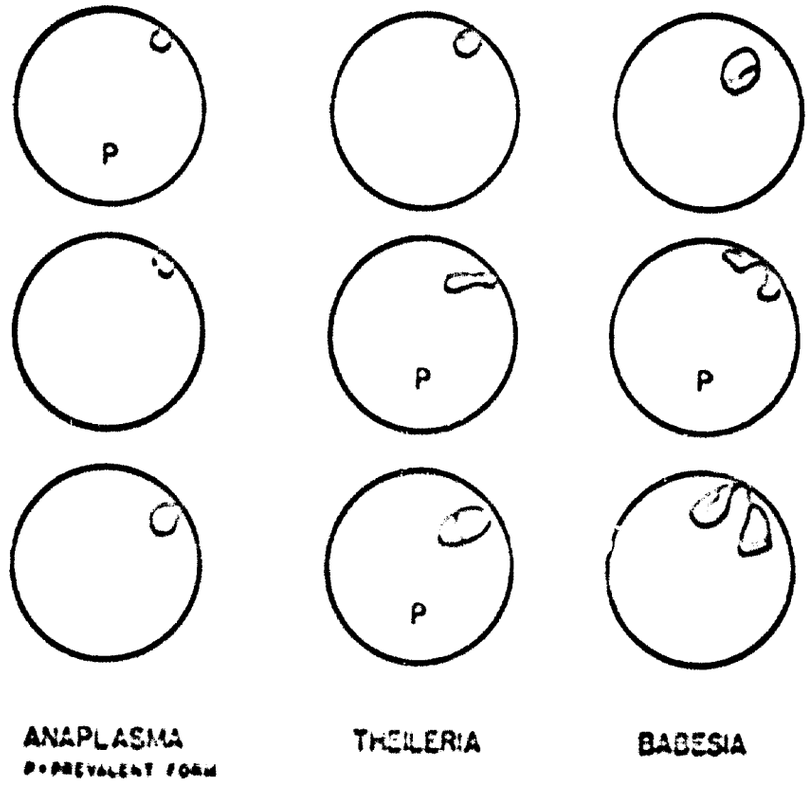

Figure 1 — Some morphological variants of Anaplasma, Theileria and Babesia

ated by the recognition of the prevalent morphological form of the organism which is present, the clinical disease manifested, and if possible, by experimental reproduction of the disease and serological response to known antigens.

LITERATURE CITED

Boldt, P. M. and J. J. Howe
1966 A report of the examination of [illegible] whitetailed deer (Odocoileus virginianus) from [illegible] areas of the Southeastern United States for evidence of anaplasmosis. Animal Disease Department, University of Georgia College of Agriculture, Georgia Coastal Plain Exp. Sta., Tifton, Georgia. 150 pp.

Christensen, J. F., J. W. Gorham, J. D. Herrmann and M. S. Rosen
1966 Prevalence of latent Anaplasma marginale infection in deer. JAVMA 150: [illegible]

Howe, G. L., W. G. Hepworth, F. M. Dietz and G. M. Thomas
1964 Anaplasmosis in the white-tailed deer: experimental infection and evaluation of serological tests. Am. J. Vet. Res. 25: 1511-1515.

Kettler, K. L. and R. M. Robinson
1967 A capillary-tube agglutination test for the detection of Fasciola infections in white-tailed deer (Odocoileus virginianus). Southwestern Vet. 21(1): 61-65.

Kettler, K. L., R. M. Robinson, and W. P. Rogers
1968 The detection of specific anaplasma-fixing antibodies in serum of white-tailed

deer (*Odocoileus virginianus*) with *Fasciola* infection. Canad. J. Comp. Med. Vet. Sci. (In Press.)

Kettler, M. L., Robinson, H. M. and Rogers, W. P.
1966. Distribution of intestinal ophthiotyle infections in deer following spinantomy. Canad. J. Comp. Med. Vet. Sci. (In Press.)

Kettler, M. L., H. M. Robinson and T. E. Franklin
1966. Histological lesions in dorsocaudal marginale infection in splenectomized deer (*Odocoileus virginianus*) as revealed by the complement fixation and capillary tube agglutination tests. Presented at the Anaplasmosis Research Workers Meeting, Oklahoma City, Oklahoma (Mimeo.) 20 p.

Kettler, M. L. and H. M. Robinson
1967. Tick transmission of Theileriosis in a white-tailed deer. Bull. Wildl. Dis. Assoc. Vol. 3.

Ossebold, H. J. H. Schroeder, W. M. Lewis and M. R. Beers
1959. Latent dorsocaudal marginale infection in wild deer demonstrated by calf inoculation tests. Vet. Med. 54:113.

Ossebold, J. W.
1959. Wild deer as carriers of anaplasmosis in California. Calif. Vet. 13(4): 14-19.

Robinson, H. M., R. L. Kettler, J. W. Thomas and R. G. Mathegat
1967. Theileriosis in Texas white-tailed deer. J. Wildl. Mgmt. 31(3): 455-459.

Smith, J. P.
1967. Studies on Theileriosis of a deer hemoprotozoan to domestic animals. M.S. Thesis. Texas A&M University. 31 pp.

Spindler, L. A., R. W. Ahrens, L. D. Diamond and J. C. Lutz
1966. Babesia in white-tailed deer. J. Wildl. Dis. 2(3): Supp. pp. 9 to 6.

DISCUSSION

DISCUSSION LEADER: THAINES. This paper is interesting and illustrates nicely a typical pattern in wildlife disease.

One starts out looking for the unknown, and before you are in it long, in this case three years, you come up with at least four problem agents. Some of these we learn to live with, such as anaplasmosis, probably not important to the deer itself, but potentially important in cattle, and other diseases that are very important as far as the deer population is concerned.

I again really appreciate this type of paper.