The highest incidence of metacercarial infestation among both examined and infested Tilapia species was found in the muscles of the posterior third (77 57% and 95 60%) followed by middle third (69 14% and 85 21%), anterior third (62 7% and 77 28%), gills (62% and 76 4%), liver (29 57 and 36 44%), kidneys (23 29% and 36 44%), spleen (16% and 19 72%) eye (16 20 and 13 14%), skin (12 26% and 15 14%) and fins (9 00 and 11 09%)

In *Clarias lazera* the maximum incidence of metacercarial infestation in both examined and infested fish was found in the muscles of middl third (85 00% and 100%) followed by anterior third (71 36% and 83 95%), posterior third (62 27% and 79 14%), liver (49 55% and 58 28%) gills (40 91% and 48 12%), kidneys (31 36% and 36 90%) and spleen (19 55 and 22 99%)

The highest incidence of metacercarial infestation in Tilapia species was found in fish of 100-150 gm and that measured 20-25 cm in length, while in *Clarias lazera* it was found in fish less than 200 gm weight and of length less than 30 cm

The highest incidence of infestation among Tilapia was found in July (96 22%) and March (94 44%) and the lowest in November (65 21%) In *Clarias lazera* the highest incidence was found in June (100%) and November (100%) while the lowest recorded in January (68 42%)

The maximum incidence of infestation in Tilapia was recorded during summer (90 30%) followed by spring (87 58%) and winter (85 96%) while the lowest was reported during autumn (65 57%) In

This report is dedicated to spirit of

Prof. Dr Mohy El-Said Easa
Prof of Fish Pathology
Faculty of Veterinary Medicine
Cairo University, Egypt

CONTENTS

	Page
1 INTRODUCTION	1
2 REVIEW OF LITERATURE	5
I Parasites	5
Human , Animal and birds as a host of fish Incysted Metacercaria	5
1 Incidence of encysted metacercariae in fish	6
2 Number of encysted metacercariae per gram of muscle and organs in fish	10
3 Distribution of the encysted metacercariae in fish tissue and organs	14
4 Types of encysted metacercariae recovered from fish tissues and organs	16
5 Histopathological alteration among fish and experimentally infested animals and birds	25
6 Parasites transmitted to man through fish flesh	33
7 Parasites transmitted to birds through fish flesh	39
8 Pathological reaction due to metacercarial infestation	42
9 Elemination of encysted metacercariae	47
a Effect of chilling and freezing on the viability of the encysted metacercariae	47
b Effect of heat on the viability of encysted metacercariae	50
Boiling	50

	Page
Frying	51
Grilling	51
II Bacteria	52
Bacteria transmitted to man from fish	52
1- *Aeromonas hydrophila*	52
1 1 Aeromoniasis in human	52
1 2 Aeromoniasis in cultured fish , animals and birds	53
1 3 Taxonomy of *Aeromonas hydrophila*	54
1 4 Morphological and biochemical characteristics of *Aeromonas hydrophila*	56
1 5 The clinical forms and pathological lesions of *Aeromonas hydrophila* infection in fish	58
1 6 Pathogenicity of *Aeromonas hydrophila*	61
1 7 Motile *Aeromonas* , septicaemia in Egypt	63
2 *Salmonellae*	66
2 1 The enteric fever (*Salmonella typhi* (typhoid) , *Salmonella paratyphi* , *Salmonella schottmullessi* etc (paratyphoid)	66
2 2 Septicemias (*Salmonella choleara suis*)	66
2 3 Gastroenteritis (*Salmonella typhimurium* , *Salmonella enteritidis* and *Salmonella derby*)	67
2 4 Identification of *Salmonellae*	67
2 4 1 Morphological identification	67
2 4 2 Detection of motility	67
2 4 3 Biochemical activities	68

	Page
2 4 4 Serotyping of *Salmonellae*	69
3 *Shigellae*	70
4 *Stphylococcus aureus*	70
5 *Streptococcus faecalis*	71
6 *Klebsiella*	72
7 *Yersinia enterocolitica*	72
III Viruses	74
3 MATERIAL AND METHODS	75
I Parasitological examination (Encysted metacercaria)	75
1 Samples	75
2 Examination of fish for Encysted Metacercariae	75
2 1 Macroscopic examination	75
2 2. Microscopic examination	76
3 Distribution and number of encysted metacercariae per gram muscles	78
3 1 Excystation of the recovered encysted metacercariae	78
3.2 Tissue digestion method	78
4 Experimental infection of birds and animals	79
4.1 Procedure of experimental infection	80
4 1 1 Infection of birds	80
4 1 2 Infection of animals	81
4 2 Detection of trematodes from infected birds and animals	82
5 Detection of trematodes from human	82
6 Preparation of permenant mounting trematodes and Excysted Metacercariae for identification	85

	Page
6 1 Relaxation	85
6 2 Fixation	85
a- Fixation of encysted metacercariae	85
b- Fixation of collected trematodes and excysted metacercariae	85
6 3 Staining	85
6 4 Differentiation	86
6.5 Dehydration	86
6 6 Clearing	86
6 7 Mounting	86
6 8 Drawing and measurements	86
7 Histopathology	87
7 1 Histopathological examination of the infested fish	87
7 2 Histopathological sections from experimental animals and birds	87
8 Effect of temperature on the viability of encysted metacercariae	87
8 1 Effect of heat on the viability of encysted metacercariae	88
Boiling	88
Frying	88
Grilling	89
8 2 Effect of chilling and freezing on the viability of encysted metacercariae of Tilapia species and Nile-catfish (*Clarias lazera*)	89
a- Effect of chilling at 4°C	89
b- Effect of freezing	90

	Page
II- Bacteriological examination	90
1 Collection of samples	91
2 Determination of Aerobic plate count (APC) in fish samples	92
3 *Staphylococcus aureus* count in fish	92
4 Determination of Enterobacteriaceae	93
5 Determination of Coliform count (MPN)	93
6 Isolation of *Aeromonas hydrophila*	94
7 Isolation of *Salmonella* and *Shigella*	97
8 Isolation of enteropathogenic *E. coli*	97
9 Isolation of *Campylobacter*	98
10 Isolation of *Yersinia enterocolitica*	99
III- Virological examination	99
4 RESULTS	101
I- Parasitological results	101
1 Clinical and post mortem lesions	101
1 1 Clinical findings	101
1 2 Post mortem findings	102
2 Prevalence of the encysted metacercariae	117
Prohemistomatidae metacercariae	121
Heterophyide metacercariae	131
Haplorchide metacercariae	131
3 Incidence of human infection with encysted metacercariae at Manzala Lake	133

	Page
4 Histopathological findings in different organ and tissues fish infested with metacercariae	135
5 Experimental infection of birds with encysted metacercariae (EMC)	146
6 Morphologic characters of the investigated trematodes	164
Family Prohemistomatidae	164
Prohemistomum vivax	164
Mesostephanus appendiculatus	165
Mesostephanus fajardensis	166
Family Heterophyidae	170
1- *Heterophyes aequalis*	170
2- *Heterophyes dispar*	172
Genus Pygidiopsinae	174
1- *Pygidiopsis genata*	174
2- *Pygidiopsis summa*	175
Subfamily Centrocestinae	176
1- *Centrocestus armatu*	176
Subfamily Ascocotylinae	178
Ascocotyle mcintoshi	178
Subfamily Metagonimnae	179
Metagonimus yokogawai	179
Genus Haplorchis	181
Haplorchis pumilio	181
2- Haplorchis yokogawi	184
3- Haplorchis disca	184

	Page
7 Results of parasitological examination in Cairo area	187
8 Results of parasitological examination of Tilapia spp in Aswan area	190
9 Results of parasitological examination of muscle of Tilapia for encysted metacercariae in Manzala Lake	193
10 Results of parasitological examination in Alexandria area	196
11 Pathological changes in the experimental birds	189
12 Pathological changes in laboratory animals	189
13 Effect of heat on the viability of EMC	207
II- Bacteriological results	219
1 Results of bacteriological examination in Cairo area	219
2 Results of bacteriological examination of fish from Aswan , source of water Nile (High-Dam) lake at March , 1994	222
3 Results of bacteriological examination of fish from Aswan , (High-Dam) at June , 1994 (following Rowanda war , pollution resulting from thousands of dead bodies thrown into the Lake)	224
4 Results of bacteriological examination of fish from Manzala Lake	226
5 Results of bacteriological examination of fish from Alexandria area	232
III- Virological results (in aquaculture)	240
5 DISCUSSION	241
6 SUMMARY	276
7 REFERENCES	283

LIST OF TABLES

		Page
Table (1)	Biochemical reactions of *Aeromonas hydrophila*	60
Table (2)	Toxins produced by *Aeromonas hydrophila* and their possible effect	62
Table (3)	Interpretation of the reactions on TSI medium	68
Table (4)	Identification of *Salmonella* isolates using biochemical criteria	69
Table (5)	Species of animals for experimental infection with Encysted Metacercaria	83
Table (6)	Species of birds for experimental infection with Encysted Metacercaria collected from infested Tilapia species and Mugil spp	84
Table (7)	Clinical symptoms of the examined Tilapia species in releation to months	108
Table (8)	Clinical symptoms of the examined *Clarias lazera* in relation to month	110
Table (9)	Post mortem findings of the examined Tilapia species in relation to month	111
Table (10)	Post mortem findings of the examined *Clarias lazera*	113
Table (11)	Incidence and distribution of metacercarial infestation in affected Tilapia species and *Clarias lazera*	114
Table (12)	Average number of encysted metacercariae in the infested Tilapia species in releation to season	115
Table (13)	Average number of encysted metacercariae in the infested *Clarias lazera* in releation to season	116
Table (14)	Prevalence of encysted metacercariae infection in relation to weight of the examined Tilapia sp and *Clarias lazera*	117
Table (15)	Prevalence of encysted metacercariae infection in releation to length of the examind Tilapia species and *Clarias lazera*	118
Table (16)	Monthly prevalence of the encysted metacercariae in the examined Tilapia species and *Clarias lazera*	119

		Page
Table (17)	Prevalence of the encysted metacercariae in the examined Tilapia species and *Clarias lazera* in releation to season	120
Table (18)	Identification of the recovered EMC from the examined Tilapia species and *Clarias lazera*	124
Table (19)	Difference between the detected metcercariae from Tilapia species and *Clarias lazera*	125
Table (20)	Age/sex relationship in case of heterophyesiasis in human at Manzala Lake " Egypt "	133
Table (21)	Clinical finding in patients parasitized with heterophyids at Manzala Lake (El-Mattariayah and Manzala Cities)	134
Table (22)	Experimental infection of week-old- chicks with EMC from Tilapia species and *Clarias lazera*	150
Table (23)	Experimental infection of baby chicks with metacercariae of Tilapia species	151
Table (24)	Experimental infection of day-old-ducklings with EMC from Tilapia speceis and *Clarias lazera*	152
Table (25)	Experimental infection of squabs with EMC from Tilapia species and *Clarias lazera*	153
Table (26)	Experimental infection of quails with EMC from Tilapia species and *Clarias lazera*	154
Table (27)	Experimental infection of herons *(Egretta ibis ibis)* with metacercariae from Tilapia species and *Clarias lazera*	155
Table (28)	Experimental infection of moorhens *(Gallinula ch chloropus)* with metacercariae from Tilapia species and *Clarias lazera*	156
Table (29)	The encountered encysted metacercaria in Tilapia spp	187
Table (30)	The prevalence of the encysted metacercaria in the Tilapia spp	188
Table (31)	The prevalence of infection with the encysted metacercaria in Tilapia spp	188
Table (32)	The prevalence of the encysted metacercariae in different regions of Tilapia spp	189
Table (33)	The prevalence of infection with encysted metacercaria of Tilapia spp at Aswan area (High-Dam and Upper Egypt)	190

		Page
Table (34)	The prevalence of the encysted metacercariae of Tilapia spp at Aswan (Naser Lake and Upper Egypt)	190
Table (35)	The prevalence of different species of encysted metacercariae in Tilapia spp at Aswan	191
Table (36)	The prevalence of encysted metacercariae in different regions of Tilapia spp at Aswan area (High-Dam and Upper Egypt)	191
Table (37)	The prevalence of encysted metacercariae infection in relation to Tilapia spp and weight of examined fish at Aswan area (High-Dam and Upper Egypt)	192
Table (38)	The prevalence of infection with encysted metacercaria of Tilapia spp at Aswan area (High-Dam and Upper Egypt)	193
Table (39)	The prevalence of Heterophids encysted metacercariae in different regions of body in three species of Tilapia in Manzala Lake	193
Table (40)	The prevalence of heterophid encysted metacercariae	194
Table (41)	The average of the weight (W) in grams and length (L) in cm of infected Tilapia spp	194
Table (42)	The weight in gm and the length in cm of examined fish	195
Table (43)	Prevalence of fish infection with Heterophyid (*Pygidiopsis genata* and *Haplorchis pumilio*) metacercariae in Abokir region in Alexandria	196
Table (44)	Prevalence of fish infection with Heterophyid (*Pygidiopsis genata* and *Haplorchis pumilio*) metacercariae in El-Max region in Alexandria	197
Table (45)	Effect of heat (broiling, frying and grilling) on the viability of EMC found on infested Tilapia species and *Clarias lazera*	208
Table (46)	Effect of chilling on the viability of encysted metacercariae found in Tilapia species and *Clarias lazera*	210
Table (47)	Effect of freezing on the viability of encysted metacercariae found in Tilapia species and *Clarias lazera*	214
Table (48)	Results of Aerobic plate count in the examined fishes	219

		Page
Table (49)	Results of Coliform count in the examined fishes	219
Table (50)	Enterobacteriacae isolated from fish surface	220
Table (51)	Enterobacteriacae isolated from intestine of fish	220
Table (52)	Enterobacteriacae isolated from fish muscles	221
Table (53)	Enterobacteriacae isolated from fish species	221
Table (54)	Results of Aerobic plate count in the examined fish from Aswan	222
Table (55)	Results of Coliform count in the examined fish from Aswan	222
Table (56)	Enterobacteriacae isolated from fish surface from Aswan	223
Table (57)	Bacteria other than Enterobacteriacae isolated from fish surface from Aswan	223
Table (58)	Bacterial loads of water samples from Aswan Lake	224
Table (59)	Bacterial loads of live fish samples from Aswan Lake / cm^2 surface	225
Table (60)	Incidence of pathogenic bacteria in water and fish samples	225
Table (61)	Results of Aerobic plate count (A P C) in the examined fishes from Lake Manzala	226
Table (62)	Results of Coliform count in the examined fishes from Lake Manzala	226
Table (63)	Enterobacteriacae isolated from examined fishes of Manzala Lake	227
Table (64)	Enterobacteriacae isolated from surface of examined fishes	227
Table (65)	Enterobacteriacae isolated from surface of examined fishes	228
Table (66)	Enterobacteriacae isolated from intestine of examined fishes	228
Table (67)	Enterobacteriaceae isolated from different parts of the examined fishes	229
Table (68)	Staphylococci isolated examined fishes	229
Table (69)	Staphylococci isolated from different parts of the examined fishes	230
Table (70)	Microorganisms isolated from fish species	230
Table (71)	Microorganisms isolated from different parts of the examined fishes	231

		Page
Table (72)	Results of Aerobic plate count in examined fishes from El-Max region	232
Table (73)	Results of Coliform count in examined fishes from El-Max region	232
Table (74)	Results of Aerobic plate count in the examined fishes from Abokir region	233
Table (75)	Results of Coliform count in the examined fishes from Abokir region	233
Table (76)	Staphylococci isolated from examined fishes from El-Max region	234
Table (77)	Staphylococci isolated from different parts of the examined fishes from El-Max region	234
Table (78)	Staphylococci isolated from examined fishes from Abokir region	235
Table (79)	Staphylococci isolated from different parts of the examined fishes from Abokir region	235
Table (80)	Staphylococci isolated from examined fishes from Alexandria	236
Table (81)	Staphylococci isolated from different parts of the examined fishes from Alexandria	236
Table (82)	Enterobacteriaceae isolated from fishes from El-Max region	237
Table (83)	Enterobacteriaceae isolated from fishes from El-Max region	237
Table (84)	Enterobacteriaceae isolated from fishes from Abokir region	238
Table (85)	Enterobacteriaceae isolated from fishes from Abokir region	238
Table (86)	Other bacteria isolated from the examined fishes in Alexandria area	239
Table (87)	Incidence of detectable viral pathogen	240
Table (88)	Types and number of viral antigen detection in stabilization pond system	240

LIST OF FIGURES

Fig (1) Showing black spots on the skin with eroded fins (a) , Darkness of the skin and cloudness of the eyelense (b) and white spoted eye with exophthalmia and wide spread of minute haemorrhag's on the skin (c) 109

Fig (2) Showing heavely infested Tilapia's muscles with medium size encysted metacercariae (Prohemistomatide sp) (X 4) 112

Fig (3) Showing heavely infected Tilapia's muscles with small size encysted metacercariae (Haplorchide sp) (X 4) 112

Fig (4) Showing Diplostomatide metacercariae 122
A- Diplostomum ibis or Diplostomum niloticus encysted metacercaria
B- Diplostomum ibis or Diplostomum niloticus excysted metacercaria
C- Bulbophorus sp encysted metacercaria
D- Bulbophorus sp excysted metacercaria
E- Diplostomatid sp metacercaria
F- Dilpostomatid sp excysted metacercaria
G-Diplostomum paracaudum metacercaria with evagenated pseudosuckers
H- Diplostomum paracaudum metacercaria with invagenated pseudosuckers
(Scale bar in A B E, F & H = 0 2 mm and in C & D = 0 5 mm)

Fig (5) Diplostomatide metacercariae 123
A- Diplostomum ibis or Diplostomum niloticus encysted metacercaria
B- Diplostomum ibis or Diplostomum niloticus excysted metacercaria

Fig (6) Showing 126
A- Clarias lazera muscles infested with Diplostomum sp metacercaria
B- Diplostomum sp metacercaria *(Clarias lazera)*
C - Diplostomum sp excysted metacercaria *(Clarias lazera)*
D- Cyanodiplostomum sp encysted metacercaria
E- Cyanodiplostomum sp excysted metacercaria
F Gills infested with Echinostomatide sp metacercaria
G- Echinochasmus sp excysted metacercaria
H- Nephrostomum sp excysted metacercaria (Ventral veiw)
I- Nephrostomum sp excysted metacercaria (Lateral view)
J- Apharyngostrigia sp excysted metacercaria
(Scale bar of B &C = 0 35,of G = 0 2, & of D E,H & J = 0 5)

Fig (7) Excysted metacercariae 127
E- Echinochasmus sp
F- Nephrostomum sp
G- Apharyngostrigia sp

Fig (8) Clinostomum Tilapiae excysted metacercaria 128

Fig (9) Clinostomum Tilapiae excyested metacercaria 129

		Page
Fig (10)	*Euchmostomum heterostomum* metacercaria	130
Fig (11)	*Euchmostomum heterostomum* metacercaria	130
Fig (12)	Showing A B C-Prohemistomatide species encysted metacercariae (X 4) &(12A) D- Prohemistomatide species excysted metacercaria, (X 4) & (12B) E- Heterophyid encysted metacercaria, (X 10) & (12C) F- Heterophyid excysted metacercaria, (X 10)& (12D) G- Haplorchid encysted metacercaria, (X 10) & (12E) H- Haplorchide excysted metacercaria, (X 10) & (12F)	132
Fig (13)	Skin of fish contain larg parastic cyst showing mild tissue reaction with aggregation of marcophages and other inflammatory cells Edema is also seen in deep dermal layer stain (H & E) X 250	136
Fig (14)	Infested superficial muscle bundles appear replaced with Fibrocellular reaction Stain (H & E) X 125	137
Fig (15)	Dorsal muscle showing Cysts deeply invaded muscle bundles with few leucocytic and melanin carrying cell infiltration (arrow) Stain (H & E) X 125	139
Fig (16)	Muscle bundles infested with large cyst revealed Sarcoplasmic granulation, vacuolation and dissolution (arrows) Stain (H & E) x 250	139
Fig (17)	Muscle bundles of fish showing infestation with great number of cysts with tunnels of inflammatory cells infiltration between muscle faciculi (arrow) Stain (H & E) x 125	140
Fig (18)	Histological section in msucle showing large parasitic elements filled the cystic capsule with mild tissue reaction Stain (H & E) x 125	141
Fig (19)	Section in muscle display degenerated calcified large parasitic cyst with marked host connective tissue proliferation Degeneration and necrosis of neighbouring muscles also noticed Satin (H & E) x 125	141
Fig (20)	Liver infested with multiple small size parasitic cysts showing Dissociation of pancreatic acini (arrow) and coagulative necrosis of hepatocytes Stain (H & E) x 125	142
Fig (21)	Liver infested with parasitic cysts (arrow) showing Degenerative changes of hepatocytes with dissociation of pancreatic acini and leucocytic infiltration Stain (H & E) x 250	142
Fig (22)	Histological section in parasitized liver displayed large parasitic cyst with mild tissue reaction Stain (H & E) x 125	143
Fig (23)	Liver showing Large parasitic cysts with mild tissue reaction form mainly of connective tissue with few number of leucocytic infilteration Stain (H & E) x 125	143
Fig (24)	Anterior kidney showing Parasitic cyst form of two layer inner collagenous and auter cellular form of leucocytes and melanin carying cells Stain (H & E) x 125	144
Fig (25)	Anterior kidney infested with parasitic cyst displayed degenerative changes of kideny tubules with depletion of intertubular hematopoietic elements Stain (H & E) X 125	144

		Page
Fig (26)	Kidney infested with large number of parasitic nodular cysts (arrows) showing Degenerative changes and coagulative necrosis in kidney tubules Atrophy of capillary tuft with edema in Bawman's capsule also notice Stain (H & E) X	145
Fig (27)	Kidney infested with Euclinostomum (arrows) showing Large parasitic elements surround with well developed connective tissue capsule infiltrated with leucocytes and melanin-carrying cells Stain (H & E) x 125	145
Fig (28)	Showing (A) *Diplostomum ibis sp nov* (X 100) (B) *Diplostomum niloticus sp nov* , (X 10)	157
Fig (29)	*Diplostomum ibis sp nov*	157
Fig (30)	*Diplostomum niloticus sp nov*	158
Fig (31)	Showing (A) *Ornithodiplostomum* sp (X 100) (B) *Echinochasmus japonicus* (X 100) (C) *Echinochasmus beleocephalus* , (X 100)	159
Fig (32)	Showing (A) *Ornithodiplostomum* sp , (X 100) (B) *Echinochasmus japonicus* , (X 100) (C) *Echinochasmus beleocephalus* , (X 100)	160
Fig (33)	*Nephrostomum ramosum*	161
Fig (34)	*Nephrostomum ramosum*	162
Fig (35)	*Aphyaryngistrigia ibis* , (X 40)	163
Fig (36)	*Aphyaryngistrigia ibis* , (X 40)	163
Fig (37)	Showing A- *Prohemistomum vivax* (X 40) B- *Mesoste appendiculatus* (X 4) C- *Mesostephanus fajardensis* , (X 40) D- *Mesostephanus flapi* , (X 10) E- *Paracenogonimous ovatus*, (X 40) F- *Holosteph volgensis*, (X 100)	167
Fig (38)	Showing A- *Prohemistomum vivax* B- *Mesoste appendiculatus*	168
Fig (39)	Showing A- *Mesostephanus fajardensis* B- *Mesostephanus flapi*	169
Fig (40)	Showing A- *Heterophyis aequals*, (X 100) B- *Heterophyis dispar* , (X 100) C- *Pygidiopsis genata* (X 100)	171

		Page
	D- *Pygidiopsis summa* (X 100)	
	E- *Centrocestus armatus*, (X 100)	
	F- *Ascocotyl mcintochi*, (X 100)	
	G- *Metagonimus yokojawai* (X 100)	
Fig (41)	Showing	173
	A- *Heterophyis* equalis	
	B- *Heterophyis dispar*	
Fig (42)	Showing	177
	A- *Pygidiopsis genata*	
	B- *Pygidiopsis summa*	
	C- *Centrocestus armatus*	
Fig (43)	Showing	180
	A- *Ascocotyl mcintochi*	
	B- *Metagonimas yokajawai*	
Fig (44)	Showing	182
	A- *Haplorchis pumilio* (X 100)	
	B- *Haplorchis yokojawai*,, (X 100)	
	C- *Haplorchis disca* (X 100)	
Fig (45)	*Haplorchis pumilio*	183
Fig (46)	*Haplorchis yokojawai*	185
Fig (47)	*Haplorchis disca*	186
Fig (48)	Small intestine of bird infected with Tilapia'smuscles (lower portion) showing Two mature parasites causing pressure atrophy necrosis and inflammatory changes in the intestinal crypts assoliated with decrease of number of mucus glands Stain (H & E) &x 125	200
Fig (49)	Lower intestine of pigeon containing mature parasite phagocytosed necrotized tissue fnd tissue debris Notice the cutinized mouth opening (arrow) passing tissue debris Stain (H& E) x 250	201
Fig (50)	Histological section in intestine of heron infested with parasitized Tilapia's muscle display Presence of parasites within intestinal lumen, some are invade the submucosa between the intestinal glands resulting in mild host reaction (arrows) Stain (H & E) x 75	203
Fig (51)	Intestine of herons showing hyperplastic proliferation of mucus glands in the intestinal crypts while at the site the parasitic attachement there was lake of mucus glands (arrow) Stain (H & E) X125	204
Fig (52)	Histological section in heron's intestine showing Hyperplasia of mucus glands at intestinal crypts while parasites invade themucosa (arrows) with fibroblastic proliferation and few leucocytic infiltrations Stain (H & E) x 125	205

		Page
Fig (53)	Intestine of heron showing Hyperplasia of mucus glands in neighbouring villi, while villi around parasitic elements arrows showing lake of mucus glands Stain (H & E) x 125	206
Fig (54)	Effect of chilling on the viability (%) of encysted metacercariae found in Tilapia species	211
Fig (55)	Effect of chilling on the viability (%) of encysted metacercariae found in Nile-catfish (*Clarias lazera*)	212
Fig (56)	Effect of freezing at -4 or -5°C on the viability (%) of encysted metacercariae found in Tilapia species	215
Fig (57)	Effect of freezing at -10°C on the viability (%) of encysted metacercariae found in Tilapia species	215
Fig (58)	Effect of freezing at -15°C on the viability (%) of encysted metacercariae found in Tilapia species	216
Fig (59)	Effect of freezing at -20°C on the viability (%) of encysted metacercariae found in Tilapia species	216
Fig (60)	Effect of freezing at -4 or -5°C on the viability (%) of encysted metacercariae found in Nile-catfish (*Clarias lazera*)	217
Fig (61)	Effect of freezing at -10°C on the viability (%) of encysted metacercariae found in Nile-catfish (*Clarias lazera*)	217
Fig (62)	Effect of freezing at -15°C on the viability (%) of encysted metacercariae found in Nile-catfish (*Clarias lazera*)	218
Fig (63)	Effect of freezing at -20°C on the viability (%) of encysted metacercariae found in Nile-catfish (*Clarias lazera*)	218

Morozov (1952) mentioned that *Metagonimus yokogawai* infection of man and carnivores causing catarrhal inflammation of the alimentary canal

Watson (1960) found that heterophyid flukes infection in man had been associated with diarrhoea and some visceral complication

Gomaa (1962) found two Egyptian patients suffering from pulmonary complication due to heterophyes infection

Hamed and Elias (1970) found that when man eat not well cooked fish containing living metacercariae, till reach his small intestine they hatched and attached themselves to mucosa and matured These worms may cause superficial necrosis of the mucosa In heavy infestation, they cause sever visceral pain, discomfert in the abdomen and diarrhoea sometimes the eggs of heterophyes go to the lymphatics via the mucosa and migrate to brain, myocardium, heart valve, lungs and mesentery and may lead to serious damage e g myocarditis, heart failure or even brain haemorrhage

Dippon and Widmer (1976) collected *Opisthorchis felineus* flukes from ductus choledochus from a woman suffereing from biliary colic at operation They also added that the patient had been infected from eating fish

Boulos *et al* (1981) examined the small intestine of experimentally infected hamster with *Pygidiopsis genata* The intestine

showed brownish dots (representing the adult worms), edema and hyperaemia of its proximal part Histopathological studies revealed that, most of the worms were deeply lodged between the villi and only few were seen in the lumen of the intestine, the villi at the site of infection were stunted thinned cut with widening of the intervillous spaces, occasionally the mucosa was flattened with loss of the villous processes, foci of cellular reaction (histocytes, lymphocytes and few plasma cells) observed in the connective tissue in the lamina propria, the underlying submucosa thickened by edema, a mild diffuse cellular infilteration (histocytes, lymphocytes and plasma cells) and dilated lymphatic vessels, and hyperplastic peyer's patches at the site of parasitic infection

Bindseil and Christensen (1984) found that experimental infection of mouse with *Echinostoma caproni,* associated with gut dilation The tissue reaction revealed villous atrophy, heightened villi, increased crypt number, decrease in brush borders and goblet cells and atrophy of the circular musculature

Hyung Lee *et al* (1984) collected the eggs of Heterophyids (*Metagonimus yokagawai Heterophyes heterophyes nocens, Heterophyes continua, Stellantchasmus falcatus* and *Pygidiopsis summa*) from the feces of patients suffered from gastrointestinal symptoms with history of eating raw flesh of brakishwater fish in Korea

Jong *et al* (1985) reported cases of humen infection with *Heterophyes heterophyes* nocens All were mullet eaters and had clinical manifistation of general malaise , gastrointestinal trouble and / or heart

palpation The present cases are all males between the age of 36-55 years In Korea

Hyung Lee *et al* (1988) described the gross finding of the guinea pig liver infected experimentally with *Clonorcus sinensis* were remarkably enlarged in size, with cystic elevation, swelling and yellowish discoloration at the surface areas and rough fibrotic texture, Moreover, the pathological finding revealed sectioned worms were demonstrated in the bile ducts, tortuous and irregulerly ditated bile ducts with cystic changes and widened portal space, egg granulomas around the bile ductules In addition the epithlia of bile ducts showed partial compression atrophy, edematous proliferation, thickeness and periductual fibrosis accompanied by periductual inflammatory cell infilteration

Stuart and Bernard (1989) reported that experimental infection of domestic chicks with *Echinostoma caproni* accompanied by unkempt feathers, watery diarrhoea and wight loss In addition the infected ileum showed atrophic villi, hypertrophied circular musculature with collagen-like fibers and haemorrhagic zones, the brush border of epithelial cells and goblet cells were absent in the mucosa, and abraded mucosa due to cephalic spines of the worms which showed tissue plugs in their suckers

Mondal and Baki (1989) described that catarrhal and haemorrhagic enteritis were associated with natural infection of *Echinostoma revolutum* in domestic ducks Histopathological examination revealed sloughing off villi epithelium and increased

numbers of goblet cells in the villi as well as in the glands, and marked cellular reaction in the lamina propria associated with cross section of the parasites

Shalaby (1992) obtained *Aliptrema tilapiae* n sp from the small intestine of dogs fed on tilapia muscles contained encysted metacercariae The lesions induced by these flukes represented by inlfammatory picture of the intestinal wall Microscopical studies of the duodenum showed detatchment and sloughing of the superficial epithelial cells of villi lymphocytic infilteration of mucosa, hyperplasia and necrosis of burner's gland, mononuclear cellular infiltration and edema of submucosa In addition the ileum showed over destruction of villi, the epithelial cells were hyperplastic and pyknotic in somf cells, lymphocytic infilteration and congested blood vessels of submucosa and mononuclear cellular infilteration of subserosa

Sung *et al* (1993) studied the experimental infection of rates with *Clonorchis sinensis* metacercariae The adult fluke were located in the intrahepatic bile duct of the liver and associated with proliferation of epithelial cells of the billary mucosa

Pedro *et al* (1992) reported human infection by phagicola sp during stool examination All infected patient who ate raw mullet sp Six of the nine patient suffered from flatulence and four had diarrhoeal episodes In addition the authors also found that six patient showed slight eosinophilia

Mahdy *et al* (1995) studied the histopathological examination of puppies and kittens experimentally infected with metacercariae from tilapia species The adult fluke were seen in the intestinal lumen, the intestinal reaction at early stages was characterized by vascular dilation, hyperplasia and hypertrophy of the mucus cells and excessive accumulation of tissue debris over the mucosa of the lower intestine Seven days post infection, moderate tissue reaction were noticed, characterized by atrophy and decrease in the number of mucus glands in the area of parasitic elements, fibroblastic proliferation which replaced the intestinal mucosa, numerous inflommatory cells mainly macrophages, lymphocytes and small size eosinophilic cells The intestinal crypts showed distruction of mucosa and edema at the point of interance of the infested parasite

9- Elemination of Encysted metacercaiae

a Effect of chilling and freezing on the viability of the encysted metacercariae

Kawai and Yumoto (1936) found that cats, dogs and rabbites could be infected with trematodes by experimental feeding on infested fish preserved in ice for 5-10 days

Callot (1939) mentioned that the encysted metacercariae were killed by freezing for 24 hour

Hamed and Elias (1970) recorded that *Heterophyes heterophyes* metacercariae in the infected mullet were survived for 30 hours when the fish stored at -10°C or -20°C and were killed after 33 hours at both degree

Ghittino (1972) and Roberts (1978) suggested that deep freezing of fish muscles at -10°C for 24 hours was sufficient to destroy the encysted metacercariae

Fahmy *et al* (1980) reported that freezing at -4°C was found to be lethal to metacercariae of *Prohemistomum vivax* in 36 hours and for *Haplorchis pumilio* metacercariae in 48 hours

Magda *et al* (1981) found that 33% of metacercariae of *pygidiopsis genata* of Tilapia species developed to adult worms in white mice The recovery rate decreased from 33% to 20% and 3% when metacercariae obtained from fish frozen at -4°C for 4 and 7 days, respectively while freezing for 10 days killed all metacercariae

Brown and Neva (1983) suggested freezing of fish muscles at 10°C for 24 hours to kill the encysted metacercariae *Heterophyes heterophyes Metagenimus yokogawai* and *Clonorchis sinensis*

Mahmoud (1983) studied the effect of freezing on the encysted metacercariae of *Heterophyes heterophyes* He recomended simple freezing at 2°C for a period not less than 9 days and deep freezing of fish muscles at 20°C for 48 hours to ensure killing of metacercariae

Shalaby (1985) recorded that freezing at 18°C for 24 hours inhibited the motility of *Clarias lazera* metacercariae (Mesostephanus sp) while cooling at 10°C inhibit the motility of the infested metacercariae on the 5th day

El-Bouhy *et al* (1988) suggested freezing as a method of treatment of fish *(Clarias Lazera)* infected with encysted metacercariae of *Cyanodiplostomum azimi, Mesostephanus appendiculatus* and *Prohemistomum vivax* They found that adult worms were obtained from chicks fed on infected muscles frozed at 20°C for 7 days would kill the parasite and show negative result

El-Sherbiny (1988) studied the effect of freezing on the infectivity of metacercaria obtained from *Tilapia nilotica* (stephanopora spp , *Pygidiopsis genata, Echinochasmus perfoleatus, Heterophyes heterophyes, Haplorchis pumilio* and Haplorchoides species) He found that freezing at 5°C for 24 hours lethal to stephanopora sp and *Echino chasmus perfoleatus*, for 48 hour, was lethal for *Heterophyes heterophyes* and for 72 hours was lethal for all the remaining types Moreover 22 4% of these metacercariae were developed to adult worms in dogs, the recovery rate decreased from 22 4% to 12 65% and 3 66% when infested fish freezed at 5°C for 24 and 48 hours Freezing for 72 hours kill all type of metacercariae and gave negative result

Freezing at -15°C kill *Echinochasmus perfoliatus* and *Pygidiopsis genata* after 24 hours and after 48 hours all the previous types, in addation to *phagicola longa* were killed The recovery rate decreased

from 20 10% to 5 99% when dog feed on muscles frozed at -15°C for 24 hours while those recieveing fish freezed at - 15 for 48 hours showed negative result

Youssef *et al* (1993b) studied the effect of chilling and freezing on the viability of encysted metacercariae of *Clarias Lazera* and *Tilapia nilotica* They found that metacercariae still viable at 4°C for 24 hours and 48 hours in both *Tilapia nilotica* and *Clarias lazera* infected muscles, while, metacercariae of both fish type were killed when freezed at - 10°C after 24 hours

b Effect of heat on the viability of encysted metacercariae

Boiling

Faust (1955) suggested thorough cooking of fish before consumption to kill fish parasites of public health importance

Hamed and Elias (1970) found that the encysted metacercariae in muscles of mullet kept viable at 100°C for 10 minutes and at 50°C for 180 minutes

Reichenbach-Klinke (1973) concluded that all fish parasites which are dangerous to man were killed by boiling of fish

Brown and Neva (1983) found that thorough cooking of fish for at least 10 minutes at 50°C was sufficient to kill fish parasities

Mahmoud (1983) showed that heating of fish to a temperature 45°C for 30 minutes may safe guard against *Heterophyes hetrophyes* infection but preferal higher temperature according to muscle thickness

El-Sherbiny (1988) illustrated that boiling of fish muscles at 100°C for 5 minutes was sufficient to kill the encysted metacercariae which lodged in fish muscles

Frying .

El-Sherbiny (1988) found that fried of each side of infected fish for 4 minutes was sufficient to kill the encysted metacercariae lodged in its muscle

Grilling

Hamed and Elias (1970) recorded the viability of encysted metacercariae in the muscles of 2 forms 10,3 from 10 & 3 from 10 grilled grilled mullet in three respective trials were not effected

El-Sherbiny (1988) found that grilling of infected Tilapia species for 4 minutes in each side was not sufficient to kill the encysted metacercariae of *Haplorchis pumilio* and Haplorchoides species, while it was adequate to kill the encysted metacercariae of Echinochasmus, Heterophyes, Mesostephanus and Phagicola species

Youssef *et al* (1993b) recorded that grilling of pieces of muscles of *Tilapia nilotica* for 15 minutes was enough to kill the encysted metacercariae lodged in its muscles

II- Bacteria

Bacteria transmitted to man from fish

Fish is an important vector in the transmission of many microorganisms to man These microorganisms or pathogens may do not cause diseases diseases in fish and considered as accidental passengers in and on fish These pathogens survive and multiply in the gut, mucosa and tissue of fish Among these bacteria are motile *Aeromonas* , *Salmonellae* , *Shigella* , *Staphylococcus aureus* , *Streptococcus faecalis* , *Klebsiella* spp and *Yersinia enterocolitica*

1- *Aeromonas hydrophila* :

1 1 Aeromoniasis in human

Strains of *Aeromonas hydrophila* have been found to be responsible for septic infections , diarrhoea , corneal ulcers , skin infections , wound infections (**George *et al* , 1985**) , meningitis and fatal infections in compromised cancer patients (**Heckerling *et al* , 1983**) or as a result of AIDS or other chronic diseases (**Flynn and Knepp , 1987**)

Furthermore , *Aeromonas hydrophila* is abundant in sewage and water contaminated with sewage (**Geldreich , 1973 , Snieszko , 1974**) Thus it was suggested that *Aeromonas hydrophila* might serve as a water pollution indicator organism (**Schubert , 1976**)

Although *Aeromonas hydrophila* is not considered a normal inhabitant of the human gastrointestinal tract and although less than 1 % of healthy adults carry aeromonads in their guts (**Von Graeventiz and Mansch , 1986**) , yet the role of *Aeromonas hydrophila* in human is receiving a great deal of attention Strains of *Aeromonas hydrophila* have been found to be responsible for septic infections , diarrhoea , corneal ulcers , skin and wound infections , meningitis and fatal infections in compromised cancer patients (**Dean and Tost , 1967 , Davis *et al* , 1978 and Joseph *et al* 1991**)

1 2 Aeromoniasis in cultured fish , animals and birds

The first published report of diseases in aquatic animals due to strains of what was presumed to be *Aeromonas hydrophila* were reported in late 1800's (**Sanarelli , 1891**) though the disease was probably common in Europe throughout the middle ages **(Amlacher , 1970)**

The role of a bacterium as the primary aetiological agent of hemorragic septicemia seemed well established Since the first reports of disease conditions due to *Aeromonas hydrophila* were documented , the disease has been recorded with increasing frequency in fish , reptiles , amphibian , invertebrates and mammals including humans

Motile mesophilic aeromonads have long been associated with disease conditions in freshwater fish known by different synonyms depending in the species of fish affected The infection has been called Bauchwassersucht in reference to its clinical signs , ascitis , infectious dropsy (carp) , myoenteroheptic syndrome (carp) , red-mouth (trout) ,

red pest or red sore (pike) , motile aeromonas septicaemia (MAS) and ulcerative disease syndrome (U D S) (**Wolke , 1975**) , **Wakabayashi** *et al* , **1981** , **Rahim** *et al* **1985** , **Toranzo** *et al* , **1986 Llobrera and Gacutan , 1987 , James** *et al* , **1977 , Easa and Hatem , 1986**)

Lallier and Higgins (1988) reported *Aeromonas hydrophila* was the predominant species from clinical specimens and was isolated from pneumonia , wound infections , septicaemia and abortion in horses , cattle and pigs So it was suggested that *Aeromonas hydrophila* could be a potential pathogen for domestic animals and fish and may represent a potential reservoir of infection

Glunder and Siegmann (1989) isolated *Aeromonas hydrophila* from out of 1226 wild birds The rate of isolation from aquatic birds was higher than from birds of terrestrial habitates The same authors stated that infection may also depend on dietary habitates and *Aeromonas hydrophila* was isolated more frequently during summer than winter

1 3 Taxonomy of *Aeromonas hydrophila*

Aeromonas species have been described under many synonyms over the years primarily because the taxon is very heterogenous biochemically , antigenically and genetically

Kluyver and van Neil (1936) proposed that genus *Aeromonas* be used to encompass those microorganisms that are phenotypically similar to the enteric group but motile by means of a polar flagellum **Miles and Miles (1951)** noted that many organisms previously described as

members of the genera *Pseudomonas* , *Proteus* , *Bacillus* and *Aerobacter* were really members of the genus *Aeromonas*

Snieszko (1975) in the 7 th edition of Bergey's manual , differentiated three species of motile aeromonads based upon pathogenicity and biochemical tests , namely *Aeromonas hydrophila* *Aeromonas punctata* and *Aeromonas liquefaciens* , Studies by **Ewing** ***et al*** **(1961) , Eddy (1962) , Page (1962)** and **Schubert (1976)** , reiterated the existence of sufficient biochemical similarities to warrant the genus name but they did not concur as to low the motile aeromonads should be divided into species In the 9 th edition of Bergey's Manual , five subspecies are described under the family *Vibrionaceae* *Aeromonas hydrophila* , *Aeromonas hydrophila anaerogenes* , *Aeromonas hydrophila preoteolytica* , *Aeromonas puctata punctata* and *Aeromonas punctat caviae* Both *Aeromonas hydrophila hydrophila* and *Aeromonas hydrophila anarogenes* were further subdivided into two biotypes **(Schbert , 1974)**

Popoff and Veron (1976) , in a computerized numerical taxononmy study , examined 68 strains of *Aeromonas* for 203 morphological , biochemical and genetic properties They concluded that *Aeromonas punctata* is an illegitmate synonym for *Aeromonas hydrophila* and suggested that the group of organisms belonging to the *Aeromonas hydrophila-Aeromonas punctata* taxons be classified as *Aeromonas hydrophila* and a new species *Aeromonas sorbia* Through their taxonomic analysis failed to differentiate two clear biotypes in the *Aeromonas hydrophila* taxon , they nontheless , propossed that the

species could be divided into two subspecies, *Aeromonas hydrophila* sub *hydrophila* and *Aeromonas hydrophila* subs *anaerogenes* They also suggested that *Aeromonas hydrophila* subs proteolytica be removed from the genus

Recently with the advent of molecular genetics *Aeromonas* spp have been recalssified into a distinct family called *Aeromonadaceae* (**Cowell *et al* , 1986**) In fact the genus is much more complex than previously believed and several new phenotypic species have been identified which include *Aeromonas media* , *Aeromonas veronii* , *Aeromonas jandaei* , *Aeromonas eucrenophila* and *Aeromonas schubertii* , representing twelve hybridizing groups as described by **Carnhan and Joseph (1990)**

1 4 Morphological and biochemical characteristics of *Aeromonas hydrophila*

Zimmerman (1980) cited by **Shotts and Rimler (1973)** reported the first isolation of microorganisms with characteristics typical for *Aeromonas*

Ferguson and Handerson (1974) stated that within the previous 50 years additional bacteria types were isolated and they were tentatively placed into the genus *Aeromonas*

Chen and Levin (1975) studied the effect of temperature on the growth rate of *Aeromona* spp , American types collection center 29063 ,

and they noted that the optimum growth temperature was 30°C with no growth being observed at 45°C

In **Bergey's Manual of Determinative Bacteriology (1974)**, the original definition of *Aeromonas hydrophila* was emended to include the following salient properties gram-negative staight rods , polar flagellation (generally monotrichous) , facultative anaerobe , fermentation of carbohydrates with formation of acid or acid and gas , oxidase positive , reducing nitrates to nitrites , insensitive to the vibriostatic compound 2 , 4 diamiono-6-7-diisopropylpteridine (O / 129), and a guanine-cytosine content of 57 to 63 mol %

Poppf and Veron (1976) found that *Aeromonas hydrophila* is a gram-negative , straight rod measuring approximately 0 5 x 1 0 micron , usually has a single polar flagellum , facultative anaerobe , ferments carbohydrates with formation of acid and / or gas , cytochrome positive , reduces nitrates , insensitive to the O / 129 vibriostatic compound , and DNA with G + C content of 57 to 63 %

Shotts and Rimler (1973) reported that a characteristic yellow colony was obtained when *Aeromonas hydrophila* was inoculated into Rimler-Shotts (R-S) medium indicating maltose fermentation Ninteen of the 20 strains tested produced yellow colonies

Boulanger *et al* (1985) found that an isolate of *Aeromonas hydrophila* was oxidase and arginine dehydrolase positive , produced acid from mannitol , grew in 0 % to 3 % but not in 8 % Nacl , was

negative for lysine decarboxylase and ornithine dehydrolase , did not produce acid from inositol , and was insensitive to the vibriostatic compound O / 129

Hus *et al* (1985) found that *Aeromonas hydrophila* can ferment a variety of carbohydrates several polysaccharides (Table 1)

Toranzo *et al* (1986) found that *Aeromonas hydrophila* isolates from fish and water tanks were positive for B-galactosidase , fermented glucose and mannitol and produce indole They were negative for ornithine decarboxylase , inositol fermentation , urease and produced hydrogen sulphide from thiosulfate or tryptone deaminase

1 5 The clinical forms and pathological lesions of *Aeromonas hydrophila* infection in fish

Aeromonas hydrophila infections in fish may be manifested by one of the following forms

1 An acute rapidly fatal septicemia , with few or no gross symptoms Internal congestion of organs , haemorrhagic lower intestine and musculature may be present
2 An acute form with dropsy and scale protrusion
3 A chronic ulcerous form
4 A latent form with no symptoms (carriers)

Ventura and Grazzle (1988) described two types of *Aeromonas hydrophila* infection One caused systemic infection in which *Aeromonas hydrophila* was isolated from the skin and subjacent muscles

only The other type caused cutaneous lesions They added that biochemical characteristics of the bacteria isolates and source of the fish were not consistently different in cutaneous and systemic infections Skin lesions in fish with systemic and cutaneous infections were similar

Soliman *et al* (**1989**) reported that infection of striped mullet (*Mugil cephalus*) with *Aeromonas hydrophila* resulted in an acute septicaemia The disease was experimentally induced by intramuscular injection , skin or gills scarification , or by the oral route using pellets purposely seeded with the bacteria The organism was reisolated from the blood 1 - 2 days after infection The disease was characterized by early inflammatory and proliferative changes and later by necrotic changes in different organs They added that enteritis and hepatic necrosis were consistently found but surface lesions were not pathognomic for these infections in mullet Death of infected fish was attributed to bacterial toxins which caused necrosis of parenchymal organs and soft tissue structures

Lawhavinit *et al* (**1991**) stated that atherosclerosis lesions were present in blood vessels of the lateral musculature of gold fish injected I / m with *Aeromonas hydrophila* The organism was reisolated from lesions and from the kidneys of the injected fish

Table (1) Biochemical reactions of *Aeromonas hydrophila*

Substrate	Type of reaction
Monosaccharides	
Arabinose	A - G
Fructose	A - G
Galactose	A - G
Glucose	A - G
Mannose	A - G
Disaccharides	
Cellobiose	A - G
Lactose	A - G
Maltose	A - G
Sucrose	A - G
Trehalose	A - G
Polysaccharides	
Algine	H
Cellulose	H
Chitin	H
Dextrin	A - G
Glycogen	A - G
Pectin	H
Starch	H
Sugar alcohol	
Glaycerol	A - G
Mannitol	A - G
Glucosides	
Esculin	H
Salicin	A - G
Galactoside	
ONPG	H

Complied by **Hus *et al* (1985)**
A acid production , G gas production , H hydrolysis
ONPG O-nitrophenyl-B-D-galactopyranoside

1 6 Pathogenicity of *Aeromonas hydrophila*

Pathogenicity of *Aeromonas hydrophila* may be attributed to its toxigenic properties The production of these toxins varies among *Aeromonas hydrophila* isolates A number of potential factors may influences the virulence of the organism These includes enterotoxins, cytotoxin hemolysins proteases, lipases and leucocidins (**Gloriase, 1974 , Trust *et al*, 1979 , Allan *et al*, 1981 and Thune *et al*, 1982a and 1982 b**)

However , **Janda *et al*** (**1985**) studied the virulence markers of *Aeromonas* species and found that there is no correlation between highly virulent *Aeromonas* isolates and phenotypes associated with enterotoxigenicity , haemolytic activity and cytotoxin production

Leung and Stevenson (1988) reported the major extracellular proteases of *Aeromonas hydrophila* strains NRC 505 and ATCC 7966 were thermostable metallo-protease (Tsmp) and thermolabile serine protease (Tlsp) Most *Aeromonas hydrophila* strains produced both kinds

Santos *et al* (1989) studied haemolytic and agglutinating activities of motile aeromonads isolated from fish and the results suggested that haemolysin could be an important factor to the pathogenisis of a particular strain , but it was not virulence determinant in all motile *Aeromonas* spp

Paniagua *et al* (1990) found that when rainbow trout were infected intramuscularly with different motile aeromonads , 72 % of

Aeromonas hydrophila isolates and 63 % of *Aeromonas sorbia* isolates were virulent On the other hand , lower virulence was reported when the intraperitoneal route of inoculation was used

Viola Zaki (1991) found that *Aeromonas jandaei* almost all of *Aeromonas hydrophila* isolates were able to produce elastase , where as the other numbers of *Aeromonas* spp failed to elaborate this enzyme

Sioutas *et al* (1991) reported that *Aeromonas hydrophila* was isolated from lesions of diseased fish (common carp) Transmission experiment with isolates using mirror carp showed that *Aeromonas hydrophila* strains induced identical clinical and pathological pictures after intra-and / or subcutaneous injection Extracts of the *Aeromonas hydrophila* isolates as well as supernatent of culture bouillon were toxic for carp and mice indicating the presence of endo and exotoxins Th results proved that carp erythrodermatitis (CE) may be caused by different bacteria mainly *Aeromonas hydrophila*

Table (2) Toxins produced by *Aeromonas hydrophila* and their possible effect (after Soliman , 1988)

Toxin	Effect
Haemolysin	Lysis of red cells of rabbit , guinea pig , sheep and fish
Necrotizing toxin	Necrosis of the skin of carp and white mice
Leucocidin	Lethal effect on white mice
Cytotoxin	Lysis and vacuolization of fish cell cultures
Enterotoxin	Possible gastroenteritis in humans

1 7 Motile *Aeromonas* , septicaemia in Egypt

Motile *Aeromonas* septicaemia (MAS) caused by *Aeromonas hydrophila* was reported for the first time in Egypt among catfish (*Clarias lazzra*) by **Amin and Eisa (1982)** The disease caused considerable losses in both private and governmental fish farms as well as hatcheries in upper and lower Egypt (**Ahmed , 1983 , Enany , 1983 , Amin *et al* , 1985**)

Natural outbreaks of MAS were described in the common carp (*Cyprinus carpio*) , cat fish (*Clarias lazera*) and *Tilapia nilotica* and the main clinical signs and gross pathological lesions were recorded

The clinical signs reported by **Ahmed (1983)** from observations on *Tilapia nilotica* naturally infected with *Aeromonas hydrophila* included redness of the skin , especially at the ventral part of the abdomen that extended to the caudal part including the anal orifice The skin was dark in colour with roughness of the scales and ulcers formation All visceral organs were congested with slight abdominal distension and there was an accumulation of small amount of sanguinous fluid in peritoneal cavity In fish that survived for one week post-inoculation the intestines were congested and filled with pink yellowish mucous The liver was enlarged with minute hemorrhages and multiple necrotic foci The kidney appeared hypermic and the spleen was enlarged Most of these symptoms and post-mortum lesions were noticed in naturally infected carp by **Enany (1983)** and in *Tilapia nilotica* inoculated with *Aeromonas hydrophila* (**Soliman , 1984**)

Fasial *et al* (**1984**) studied the distribution of *Aeromonas hydrophila* in organs and blood of naturally and experimentally infected *Oreochromis niloticus* Isolation trials of *Aeromonas hydrophila* from experimentally infected *Oreochromis niloticus* revealed the presence of the organism in the kidney (80 7 %), spleen (77 2 %), heart blood (68 4 %) , liver (59 7 %), brain (45 6 %) and eye (43 8 %) of fish examined At early stages of infection *Aeromonas hydrophila* was detected from the heart blood and spleen in large numbers than from any other organs examined By the progress of infection , the number of *Aeromonas hydrophila* increased progressively in the kidney Most of the symptoms were observed between the 3 rd and 7 th day post-infection where the titre of *Aeromonas hydrophila* in the kidney was at its peak

From observations on *Tilapia nilotica* raised in ponds in Upper Egypt and naturally infected with *Aeromonas hydrophila* **Amin** *et al* (**1985**) reported two main forms of MAS (acute and chronic) The acute form was characterized by redness and inflammation of the skin and membranous portion of the fins , marked abdominal distension and bilateral exopthamia The chronic form was marked by various haemorrhagic patches all over the body , dark discoloration of the skin , together with roughness of the scales and their detachment from some parts of the body Not uncommonly , ulceration of the epidermis and slight abdominal distension were observed

Faisal *et al* (**1989**) reported that in Egypt the bacterium was responsible for losses between 10 and 70 % among farmed Tilapia The LD_{50} of 17 isolates ranged from 10^3 to 10^4 bacteria

Soliman *et al* (**1989**) reported that the simultaneous infestation with *Lernaea* sp and infection with *Aeromonas hydrophila* can be attributed to injured skin barrier by *Lernaea* sp allowing the opportunistic *Aeromonas hydrophila* to invade the fish body and to induce infection

Soliman *et al* (**1989**) induced experimental infection with *Aeromonas hydrophila* in common carp by intramuscular inoculation of 24 x 10^7 viable cells / fish and found that the organism colonized the liver , kidney and spleen , and it could be detected up to one week after injection

Soliman and Hassieb (**1990**) reported that after intramuscular inoculation of common carp with different gram-negative organisms , *Aeromonas hydrophila* induced the most severe changes , followed by *Aeromonas sobria* and *Salmonella enteritidis* whereas *Salmonella tshwinge* was the least virulent to this type of fish

Soliman *et al* (**1991**) reported that an isolate of *Aeromonas hydrophila* was pathogenic to common and fall under the category of high virulence , with LD_{50} value of $10^{4.3}$ The overcrowding in the pond , high temperature , together with stress associated with the presence of *Trichodina* sp could be contributing factors to the proliferation of *Aeromonas hydrophila* inducing an epizootic

Viola Zaki (**1991**) isolated *Aeromonas hydrophila* , *Aeromonas sobria* , *Aeromonas veronii* , *Aeromonas jandaei* and *Aeromonas*

schubertii from naturally infected catfish *Aeromonas hydrophila* and *Aeromonas veronii* were able to produce a disease condition when inoculated into Tilapia which was characterized by liquifaction and haemorrhages arround the site of inoculation *Aeromonas sorbia* and *Aeromonas caviae* failed to produce any external lesions even after a 7-day observation period

2. *Salmonellae* :

In man all forms of *Salmonella* infection enter via the oral route and may produce either or subclinical infection *Salmonellae* may produce 3 main types of diseases , but mixed forms are frequent

2 1 The enteric fever (*Salmonella typhi* (typhoid) , *Salmonella paratyphi* , *Salmonella schottmullessi* , etc (paratyphoid)

Organisms ingested with contaminated food or drink reach the small intestine from which they enter the intestinal lymphatics They then travel via the thoracic duct into the blood stream and are disseminated into many organs including the intestines where organisms mutiply in lymphoid tissue and are excreted in the stool

The outstanding lesions are hyperplasia and necrosis of lymphoid tissue , focal necrosis in the liver and inflammatory of the gall bladder

2 2 Septicemias (*Salmonella choleara suis*)

Early investion of the blood stream follows infection by oral route , although intestinal involvment is often absent The organisms are

widely disseminated and tend to cause focal suppuration , absesses , meningitis osteomylitis , pneumonia and endocarditis especially in debilitated hosts

2 3 Gastroenteritis (*Salmonella typhimurium* , *Salmonella enteritidis* and *Salmonella derby*)

Symptoms appear after only 1 - 3 days incubation which suggests that ingestion of large number of organisms results in a violent irritation of mucous membranes Usually invasion of the blood stream and dissemination of infection to other organs does not occur

In fish *Salmonella* is excreted in faeces of infected animals and water is contaminated by it from which fish contract this microorganism and transmit it to man without gaining any diseases

2 4 Identification of *Salmonellae*

2 4 1- Morphological identification (Cruickshank *et al* , 1975)

Smears were prepared from the suspected colonies and stained with Gram's method , then examined microscopically for morphological appearance

2 4 2 Detection of motility (Kreig and Holt , 1984)

Motility was tested by stabbing the *Salmonella* strains into 0 5 % soft agar

2 4 3 Biochemical activities

The tested *Salmonella* strains were cultured and purified on MacConkey bile salt lactose agar plates and incubated at 37°C for 24 hours Further identification was carried out within 2 steps in addition to the serological identification

2 4 3 1 Preliminary screening of cultures by using TSI slants Interpretation of the results were carried out as shown in Table (3)

Table (3) Interpretation of the reactions on TSI medium

Reaction *				**Possible Micro-organisms**
Slant	Butt	Gas	H_2S	
K	A	+	+	*Salmonella Proteus* , *Citrobacter freundii*
A	A	+	-	*Escherichia* , *Klebsiella* , *Enterobacter* , *Citrobacter* and *Serratia*
K	A	-	-	*Shigella Providencia* , *Serratia* and *Enterobacter agglomerans*
A	A	+	+	*Citrobacter freundii* and *Proteus vulgaris*

K = Alkaline (red) A = Acid (yellow) H_2S = Black colour

2- Further identification was achieved by group of biochemical tests that were recommended by **Edwards and Ewing (1972)** , **Cruickshank et al** , **(1975)** , **Fingold and Martin (1982)** and **Koneman *et al*** , **(1992)** as illustrated in Table (4)

Table (4) Identification of *Salmonella* isolates using biochemical criteria

Test	Reaction *
Indole	-
Methyl red	+
Voges Proskauer	-
Simmon's citrate	+
Urease	-
Gelatin liquefaction at 22°C	-
Malonate	-
Glucose	AG
Lactose	-
Sucrose	-
Mannitol	AG
Dulcitol	AG
Salicin	-
Adonitol	-
Inositol	AG
Sorbitol	-
Arabinose	AG
Raffinose	-
Rhaminose	-
Lysine decarboxylase	-

+ = positive - = Negative AG = Acid and gas

2 4 4 Serotyping of *Salmonellae*

Cultures that yield reactions similar to that given by *Salmonella* on TSI , urea media and other biochemical tests should be screened serologically This was accomplished rather easily with the slide plate agglutination test with " O " omnivalent *Salmonella* test sera If agglutination occurred , they should be tested with polyvalent antisera representing No (I , II & III) If agglutination occurred , they should be tested for their individual factor for O and H to determine their groups and species according to Kauffman-White scheme (**Cruickshank *et al* , 1975**)

3. *Shigellae* :

In man after a short incubation period (1 - 4 days) there is a sudden onset of abdominal pain cramps , diarrhoea and fever The stools are liquid and contain mucous and blood after the first few movement Their passage is accompanied by much straining and tenesmus Spontaneous recovery generally occurs in a few days but small children sometimes succumb to dehydration and acidosis The disease caused by *Shigella dysenteriae* is particularly severe

In fish *Shigella* is obtained by fish from water which is contaminated with the faeces of infected animals and then acts as a passive vector in the transmission of this microorganism to man

Flody and Jones (1954) isolated *Proteus* sp besides *Shigella* and *Salmonella* sp from the intestinal tract of fish collected from polluted water

Shigellae is not affect fish However , fish cultivated in water contaminated with sewage may carrying the organism and transport it to consumer or fishermen

4 *Stphylococcus aureus*

In man *Stphylococcus aureus* causes , a) abscess formation (localized and painful) undergoes suppuration from the center b) food poisoning caused by *Stphylococcus aureus* has short incubation period (1 - 8 hours) with the symptoms of gastrointestinal disturbance nousia , vomiting and diarrhoea with no fever

In fish the causative pathogen grow and produces high potent endotoxins in the improperty processed fish meat and after ingestion it cause human disease due to poisoning rather than infection

Member of the genus *Stphylococcus* occasionally produce disease in fish (**Shotts and Teska , 1989**) **Oghondeminu and Okaeme (1986)** isolated *Stphylococcus* sp from Africa aquaculture pond water In Egypt, **Akealah (1987) , Laila *et al* (1986) and Nabilah (1975)** isolated and identified *Stphylococcus aureus* and *Escherichia coli* from intestinal tract of Tilapia sp

5 *Streptococcus faecalis*

It cause food poisoning in man which is characterized by gastrointestinal disturbances , such as nausia , vomiting , abdominl pain and diarrhoea

Although no transmission of *Streptococcus* sp from fish to man has been documented , the potential for human infection does exist among individuals who handle diseased fish Many fish isolates are Lancifield group B and D seiotypes (**Shotts and Teska , 1989**) Outbraks produced by members of the genus *Streptococcus* among fresh water and salt water fish in USA and Japan was reported by **Frerichs and Roberts (1989)** In Egypt , **Laila *et al* (1986)** and **Hefnawy *et al* (1989)** isolated *Streptococcus faecalis* from intestinal tract of tilapia sp lesions are not specific appear as raised inflammed areas behind the dorsal fin extending ventrally , haemorrhage arround the anus , congestion in the intestine , swollen kidnies and congestion of the liver

6 *Klebsiella* :

Klebsiella spp were found to be opportunistic pathogens *Klebsiella* is widely distributed in nature , as it has been isolated from lakes rivers , sea water , sewage and various waste water , drinking water , soil and animals including humans (**Siedler *et al* , 1975 , Campbell *et al* , 1976 , Kinttel *et al* , Brynhildsen *et al* , 1988**)

Nabilah Mohamed (1975) examined 265 fish , especially *Tilapia* spp , and isolated 231 bacterial strains including *Klebsiella* spp from the intestine

Knittel *et al* (1977) concluded that water polluted with botancial material served as a potential reservoir for mutiplication of the opportunistic *Klebsiella* pathogens

Morphological and biochemical characters

Klebsiella colonies appear pink to red on the agar surface within 24 hours of incubation at 37°C On Rimler-Schotts medium colonies are greenish yellow to green They show the following biochemical reactions they are indole negative (**Krieg and Holt , 1984**) , do not utilize citrate or produce H_2S and are urease negative

7 *Yersinia enterocolitica* :

Yersinia enterocolitica infections are now seen with some concern in both human and veterinary medicine ***(Morris and Feeley, 1976)*** The infections due to *Y enterocolitica,* affecting animals first and then man,

have been spreading dramatically since 1961 ***(WHO Chronicle, 1976)*** *Yersinia enterocolitica* is capable of causing a variety of diseases both in animals and man Theses include gastroenteritis , septicaemia , acute polyarthritis erythema nodosum , acute mesentric lymphadenitis and terminal ileitis closely resembling appendicitis (**Mittal and Tizard , 1981**)

Most human pathogenic strains belong to serovars O 3 , O 8 and O 9 and biovars 2 , 3 and 4 (**WHO Scientific Working Group , 1980)** The pathogenicity of other serovars of *Yersinia enterocolitica* isolated from animals , birds , food , water and environment was a contraversial issue (**Swaminathan et al , 1982**)

Schiemann and Davenish (**1982**) found that the invasiveness of *Yersinia enterocolitica* was restricted to certain serovars or biovars *Yersinia enterocolitica* virulence is a complex phenomenon **Cornels *et al*, (1987**) recorded a number of distinct chromosomal and plasmid gene sequences result in the overall elaboration of the pathogenic or virulent phenotypes **Delor and Cornelis (1992**) observed that the enterotoxin (Yst) was a major factor involved in the *Yersinia enterocolitica* associated diarrhoea in the young rabbits

2.3 Viruses

The enteric viruses constitute the largest group among the viruses They mutiply in the intestine and one excreted in numbers up to 10^{10} or more organisms per gram of faeces (**Bitton , 1980**) The diseases they cause range from insignificant to serious , and are sometimes fatal

Excreted viruses cannot multiply outside living cells However , they may survive for weeks in the environment and may infect new human hosts

It is only recently that viruses have been discovered to be a major cause of diarrhoea Rotaviruses are known to a major cause of childhood gastroenteritis and are perhaps the major viral cause of diarrheal disease

3- MATERIAL AND METHODS

I - Parasitological examination (Encysted metacercaria)

1- Samples

A total of 920 freshwater fish were collected from Cairo and Kalıobıa ıncludıng 700 fish from dıfferent specıes of Tılapıa and 220 *Clarias lazera* Also, Tılapıa specıes were collected from dıfferent localıtıes (Lake Nasei, Aswan, Caıro area, El-Manzala) and from Alexandıa Other specıes (Mugıl, Sıganus and Sharegesh) were collectes from Alexandrıa (El-Max and Abo-Kerr) The fish were transported ın polyethelene bags containing about 30% of ıts volume water and fish and the ıemaınıng volume was filled wıth aır While the freshly dead fish were labelled and packed ın a clean plastıc bags and put ın an ıce boxer at 4°C and carıed to the laboıatory foı ımmedıate examınatıon

For hıstopathologıcal examınatıon, samples were taken from skın and muscles, lıver, spleen, kıdneys and gılls of heavely ınfested fish

Clınıcal and postomortem examınatıon of the collected fish were summarızed and presented ın the results

2- Examination of fish for Encysted Metacercariae

2 1 Macroscopic examination ·

Macroscopıc examınatıon of the fish was carrıed out to exclude stale fish and to detect any changes ın the dıfferent parts of fish body and ıts physıcal characters (**Syme, 1966**)

Clinically the collected fish were examined as follows

1-Skin and fins were examined for discoloration , black patches, spots, elevated greyish white spots, nodules, reddish spots or streaks, roughness or desquamation of the scales and erosion or ulceration of the skin and or fins

2-Abdominal cavity was examined for ascitis fluid , parasites and other abdominal contents

3-Eyes were examined for exophthalmia, sunken eyes, opacity of the cornea, clear white or red spotted eyes or inflammed ones

The autopsied fish were examined as follows

1-Fish were skinned and checked for dermal or subcutes cysts

2-Muscles were examined for the presence of different cysts, nodules or for being flabby, spotted or emaciated

3-Liver, spleen and kidneys were examined for mottling, spotting or nodulations

4-Abdomen of fish were checked for the presence of ascietic fluid (colour and consistancy)

5-Gills and branchial cavities were checked for the presence of large cysts or greyish white small nodules on gill filaments, rackers and arches

2 2 Microscopic examination

The microscopic examination was carried out to detect Encysted Metacercaria that were lodged in/or attached to the different organs and tissues of the examined fish The microscopic examination of fish was recomended bu *Morishita et al (1965)* using compression technique

Examination of skin

Parts of skin were removed from the examined fish and wetted with few drops of saline solution then compressed between two slides of comparessorium and examined under the dissecting microscope for the presence of attached metacercariae

Examination of the eyes

The eye balls were removed from the orbit and cut opened on a slide to examine its fluid contents, then the eyelenses were macerated by the help of two mounted needles Finally, the preparation was covered with a clean cover slide which pressed gently with the mounted needle and examined microscopically and also the fat around the eye ball was examined for the presence of encysted metacercariae

Examination of the branchial cavity and gills

The branchial cavity was dessected and examined grossly, then under the dessecting microscope The gills were dissected and each gill arch was put on a slide,wetted with few drops of saline solution then compressed between two glass slides and examined microscopically

Examination of muscles

Very small pieces of muscles were taken from different regions and depth and also from right and left sides of the fish body The muscle pieces were mixed with few drops of saline solution, then compressed between two glass slides and examined under the microscope

3- Distribution and number of encysted metacercariae per gram muscles

The fish body was divided into three parts, anterior third, middle third and posterior third One gram of muscle was taken from each part and compressed between the two slides of comparesorium and examined under the dissecting microscope in search for encysted metacercariae lodged in the tissue Encysted metacercariae were counted and recorded

3 1 Excystation of the recovered encysted metacercariae

The recovered macroscopic encysted metacercariae were excysted using dissecting fine needles under dissecting microscope, while the microscopic encysted metacercariae were excysted using tissue digestion method

3 2 Tissue digestion method (Oshima *et al* , 1966 and Yokogawa & Sano, 1968)

A- Solutions used

1- Pepsin digestive solution (PDS) formed from

Pepsin	5 gram
Hydrochloric acid (0 1N)	100 ml
Ringer's saline solution	900 ml

2- Hatching solution formed from

Trypsin	10 gm
Sodium taurocholate	5 gm
Sodium bicarbonae (1%)	1000 ml

b- Technique

Fifty grams of the minced infected fish muscles were added to 250 ml of pepsin digestive solution The content were homogenised, then another 250 ml of pepsin digestive solution were added to the homogenate poured in flasks and incubated at 37°C for about 3-4 hours, the flasks were shaken for 30 seconds every half an hour during the incubation, after that the homogenate was poured in a large conical flask and left to settle down for 5-10 minutes at room temperature the supperinatant fluid was discarded and the sediment was washed several times with saline solution until the supernatant become clear, the sediment was then partially poured in a watch glass and the metacercariae were collected by means of pasteur pipettes under the dissecting microscope If the encysted metacercariae did not excyst in pepsin digestive solution, they were collected and transferred into another flask containing hatching solution, on which hatching occured within 30-40 minutes These excysted metacercariae were collected and put into saline solution for identification of its cyst Excysted metacercariae and the freely separated encysted one were used for experimental infections of baby chicks, herons *(Egretta ibis ibis)* and moorhens *(Gallinulla ch chloropus)*

4- Experimental infection of birds and animals

The following birds were used for experimental infections Number of birds, age and type of food management were summarized as follows

a- 45, chicks aged one week

b- 17, baby chicks (1-3 days old)

c- 45 pickini duckling (one day old)

d- 18 balady duckling (one day old)

e- 32 quials aged two weeks

f- 24 squabs afed three weeks

g- 24, herons (*Egretta* ibis *ibis*)

h- 8, mooihfns (*Gallinula* ch *chloi opus*)

The following animals were used for experimental infection

a- 44 Buppied

b- 38 Kittens

c- 38 Mice

4 1 Procedure of experimental infection

4 1 1 Infection of birds

As summarized in Table (5), the birds were subdivided into 4 - 6 groups First group "A" feeding on 2 gram (each contain 150-200 Encysted Metacercariae) of muscle of Tilapia spp & Mugil spp While the second group received cystes (2 - 6 cysts) collected from branchial cavity, the 3rd group received viable cysts (8 - 20 cysts) collected from fishs eyes In case of 4th group received Encysted Metacercariae collected from gills 5th and 6th groups were kept as positive and negative control

On days 3,7 and 15 post-infection, three birds per infected group and 2 birds per control group were clinically examined, then killed and autopsied Post-mortem examination of all slaughtered birds was done The autopsied birds were subjected to parasitological and histopathological examination

4 1 2 Infection of animals

120 animals (44 , Buppies , 38 Kettens and 38 mice) were equally devided into four groups (A B C D) Animlas were orally feeding with viable Encysted Metacercaria collected from the muscles of Tilapia spp and Mugil spp (Group A) , other from cysts of bronchial cavity , (Group B) , the 3rd group (Group C) from eye cysts Source of infective Metacercaria and the dose per animal found in Table (6) Control animals (Group D) were left and kept in separate cages Infected and non infected animals were put under observation for 15 days

In each group fears were examined daily for mature worm and parasitic eggs Two animals were randomly slaughtered on day 3 , 7 , 10 and 15 post-infection Animals were clinically examined before being slaughtered , then outopsid Parasitological examination was done on all slaughtered animals Samples for histological examination were taken from infected tissue or organs Swaps from the intestine were performed for parasitological examination

Domestic birds (chicks, baby chifks, ducklings and quials) and animals were fed strater commertial rations Vquabs were supplied by grains (corn and beens) Wild birds were given young sized fish (which were metacercarial free and freezing at -4°C for 4 days prior to be feeding) Each type of birds were reared either in separate cages (domestic birds) or kept free in a separate room (wild birds) All birds and animals were supplied with water Birds and animals were treated with yomesan (Bayer) at a dose rate of 0 25 gm/kg daily for 3 days prior to experimental infection Birds and animals were checked for trematode

infection through fecal examination and were found trematode free prior to experimental infection The previous experimental animals and birds were divided into groups presented in Table (5 & 6)

4 2 Detection of trematodes from infected birds and animals :

The sacrificied experimentally infected birds that shedded trematode eggs or mature worms where autopsied and their small intestine (were subdivided into three parts anterior, middle and posterior third) and large intestine were examined In baby chicks, herons and ducklings all the alimentary canal was examined Each part was put into a clean peteri-dish and separately opend Contents and scraped mucosa of each part were collected in suitable jars containing normal saline Contents were washed several times with normal saline to remove the coarse particles and mucous The sediments were examined with a binocular microscope The trematode were collected in normal saline and counted

5- Detection of trematodes from infected human .

Seven hundred and nighty five human in clinic were devided in to 6 groups according to their age and sex (♂ or ♀)

Those peoples were subjected to clinical examination (diarrhoea , bloody diarrhoea , mucoid diarrhoea , abdominal pain bawel sound , some of examined people showed no symptoms)

Faeces of each were put in clean jars containing normal saline Contents were washed several times with normal saline to remove the coarse particles and mucous The sedements were examined microscopically for egg morphology and adult trematodes Trematodes were fixed and stained for identification of parasites

Table (5) Species of animals for experimental infection with Encysted Metacercaria

	Type of examined animals								
	Buppies			Kittens			Mice		
	No of inf	No of count	Total No	No of inf	No of count	Total No	No of inf	No of count	Total No
Muscle	10	5	15	10	5	15	10	5	15
Branchial cavity	10	3	13	6	3	9	10	2	12
Muscle of Mugil	10	6	16	10	3	14	10	1	11
Total	30	14	44	26	11	38	30	8	38

Table (6) Species of birds for experimental infection with Encysted Metacercaria collected from infested Tilapia species and Mugil spp

Donor fish	Sources of infecting metacercaria	Type and number of recipient experimental bird																							
		Week old chickens			Baby chicks			Ducklings						Squabs			Quails			Herons *Egretta ibis*			Moorhen *Gallinula chloropus*		
		No of	No of	Total No	No of	No of cont.	Total No	No of infected		No of control		Total number		No of	No of cont.	Total No	No of infect	No of cont	Total No	No of infect.	No of cont	Total No	No of infect.	No of cont	Total No
								P	B	P	B	P	B												
	Muscles	9	6	15				9	6	6	3	15	9	6	3	9	8	8	16	6	3	9	3	1	4
Tilapia species	Gills or branchial cavity cyst	9	6	15	6	2	8	9		6		15		3	3	6				3	3	6			
	Eye and suronding tissue				6	3	9																		
Mugil spp	muscles	9	6	15				9	6	6	3	15	9	6	3	9	8	8	16	6	3	9	3	1	4
Total		27	18	45	12	5	17	27	12	18	6	45	18	15	9	24	16	16	32	15	9	24	6	2	8

No of infect = The number of infected birds
No of cont = The number of control birds

P = Pickini duckling
B = balady duckling

6- Preparation of permenant mounting trematodes and Excysted Metacercariae for identification :

6 1 Relaxation

Detected trematode parasites were individually put between a clean slide and a thin glass slide By gentle pressure, the specimen was flattened to the desired degree careing not to destroy the delicate parasite

6 2 Fixation

a- Fixation of encysted metacercariae

The encysted metacercariae were fixed with a small part of sourrounding tissues,compressed between two glass slides and ligated by a thread and dipped in 5% formalin, then the encysted metacercariae were collected in a small vial containing 5% formalin

b- Fixation of collected trematodes and excysted metacercariae

The relaxed trematodes and excysted metacercariae were collected and put in small vials containing 10% formalin It is preferable to fixed the metacercariae in 5% formalin if it is small in size

6 3 Staining

Immediately before staining the fixed specimens were washed several times by distilled water, then stained by acetic acid alum carmine **(Weesner, 1968)** The acetic acid alum carmine stain was fromed from

Carmine	2gm
Aluminium ammonium alum	5gm
Distilled water	70 ml
Glacial acetic acid	30 ml

It was prepared by dissolving the carmine in water then the alum was added This mixture was boiled then cooled Galcial acetic acid was then added and the mixture boiled again, then cooled and filtered A crystal of thymol was added to the filterate

6.4 Differentiation

It was done by using a dilute solution of acid alcohol (1 ml conc hydrochloric acid in 100 ml of 70% alcohol) The end point of differentiation was determined under dissecting microscope

6 5 Dehydration

This processe was carried out in an ascending grade of ethyl alcohol (30%, 50%, 70% 80%, 90%, 95% and absolute alcohol), time of dehydration varied according to the size of the specimen

6 6 Clearing

Clearing of adult trematodes and excysted metacercariae was performed using clove oil for long period up to 12 hours or more according to the size of specimen

6 7 Mounting

By using canada balsam as a mounting material

6 8 Drawing and measurements

The recovered trematodes were measured using a calibrated ocular micrometer lens All measurments are in millimeters unless other wise stated All drawings were made by using a drawing microscopal tube

Lastly all the parasites collected throughout the present study were identified according to **Yamaguti (1958) , Skrjabin , (1964), McDonald (1981) and Soulsby (1982)**

7- Histopathology

7 1 Histopathological examination of the infested fish

From sacrificied heavely infected fish, specimens of muscles, liver, spleen, kidneys and gills containing metacercariae were fixed in 10%phosphate buffer formalin (PBF) Paraffin sections of 5-7 microns thickness were prepared and stained with hematoxylin and eosin(H & E), brussion blue stain and periodic acid Schief reaction (PAS) **Carleton *et al* (1967)**

7 2 Histopathological sections from experimental animals and birds

From intestine of sacrificied animals and birds , specimens of upper, middle and lower parts of intestine were fixed in 10% buffer formatin Paraffin sections of 5-7 microns thickness were prepared and stained with hemotoxylin and eosin (H & E) and periodic acid schief reaction (PAS) **Carleton *et al* (1967)** Results were illustrated

8- Effect of temperature on the viability of encysted metacercariae

For this study , two species of fishes were choosen , one species was with feably muscle and less fatty (Tilapia spp), other was soft muscle and more fatty (Nile catfish) , four hundred and twenty two Tilapia species and 120 Nile-catfish (*Clarias lazera*) fish were choosen

from different localities The obtained fish were of variable weight and size, then subjected to internal and external examinations and the encysted metacercariae were counted according to the technique recommended by **Morishita *et al* (1965)** Heavely infested fish including different types of metacercariae were taken and subjected for the following experiment

8 1 Effect of heat on the viability of encysted metacercariae

Fishes belonging to Tilapia species and Nile-catfish (*Clarias lazera*) were cleaned and evasciated except those used in grilling and examined for the presence of encysted metacercariae according to the technique recomended by **Morishita *et al* (1965)** The infested Tilapia species and Nile-catfish *(Clarias lazera)* were devided into three categories of different size (small, medium and large) and the large sized fish were cutting into three parts The prepared fish were subjected to the following

Boiling

A sufficient number of small, medium and large sized infected Tilapia species and Nile-catfish *(Clarias lazera)* were boiled at 100°C for 5 and 10 minutes then examined to determine the viability of the encysted metacercariae

Frying

Adequate number of small, medium and large sized fish (Tilapia sp & *Clarias lazera*) were fried on each side for 5 and10 minutes, then

the fried fish examined to detect the viability of the encysted metacercariae

Grilling

A suiTable number of small, medium and large sized infected Tilapia species were grilled on each side of the whole fish for 5 minutes and 10 minutes after that examined to determine the viability of the infested metacercariae

8 2 Effect of chilling and freezing on the viability of encysted metacercariae of Tilapia species and Nile-catfish (*Clarria lazera*)

a- Effect of chilling at 4°C

A sufficient number of nearly equal sized Tilapia species and Nile-catfish *(Clarias lazera)* were collected then send to the laboratory where they killed, autopsied and examined for the detection and count of the encysted metacercariae per gram of fish muscles according to technique recomended by **Morishita *et al* (1965)**

The infected fish were evascerated and kept in clean tightly closed plastic bags and put in refrigerator at 4°C Daily examination of refrigerated fish to record the viability percent by determined the ratio between the life and dead encysted metacercariae The viable metacercariae were recognized by their movement inside the cyst and or their reaction to the light as well as experimental inoculation to laboratory animals (Buppies , Kittens and rats) For the obtained percentage of encysted metacercariae from both Tilapia species and Nile-

catfish *(Clarias lazera)* the effect of chilling per days on their viability were recorded

b- Effect of freezing

A required number of fish (Tilapia species and *Clarias lazera*) were collected and send to laboratory where they sacrificeid and examined for the detection the number of the encysted metacercariae per gram of the fish muscles according to technique recomended by **Syme (1966)** The evaserated fish were divided into 5 groups from A to E Such fish were labelled and put in clean plastic bags and freezed at -4°C or -5°C , -10°C , -15°C and -20°C , for group A , B , C , D and E respectively Three fish per each group were taken every 8 hours and left to thawing at the room temperature then examined microscopically to show the viable metacercariae and count the viability percent on each of the recomended temperature

II- Bacteriological examination :

In order to investigate the influence of the hygienic status of treated of treated wast water on the initial bacterial load on fish surface and muscle , determination of the total bacterial count (APC) , Enterobacteriaceae count , Coliforms count and *Staphylococcus aureus* count

Also , isolation and identification of *Salmonella* , *Shigella* organisms, Enteropathogenic *E coli* , *Campylobacter* spp , *Aeromonas hydrophila* and *Yersinia enterocolitica*

1- Collection of samples

● Surface swabs

Surface samples consisted of swabs taken over a prescribed area (20 cm^2) and collected from fishes directly after being caught Each swab sample shaken in 20 ml 0 1 % peptone water to have a dilution of 10 % sterile dilutions were then prepared in peptone up to 10^7

● Muscle samples

Directly after fish capture 10 grams muscle samples were taken under aseptic condition from the dorsal muscle above the lateral line Muscle homogenate was then prepared according to technique recommended by **ICMSF (1978)**

● Liver and intestinal samples

After collection of surface swabs and muscle samples , the abdominal wall opened from the ventral side under complete aseptic condition , the liver as well as intestins were cut into small pieces and each transferred to a test tube containing 10 ml peptone water as an enrichment

Collected samples were transfered in ace box to the laboratory with minimum of delay where subjected to bacteriological examination

● Preparation of muscle samples

The homogenate was prepared as followes , 10 gm of the sampel under examination were transferred into sterile blender jar to which 90 ml of peptone water (0 1 %) were added to provide a dilution of 10^1

The blendei was operated to give 2000 revolution per minute for 2 5 minutes and the mixtuie was then allowed to stand for 2 minutes at room tempeiatuie The contents were then shaken and 1 ml of the original suspension was tiansfeiied to a sterile test tube containing 9 ml of 0 1 % peptone water to have a dilution of 10^2 Serial dilution were prepared in peptone up to 10^7

2- Determination of Aerobic plate count (APC) in fish samples :

In suiface spiead plate technique recommended by the International Commission of Miciobiology Specifications for Food (**ICMSF , 1978**) was applied , plte count agar , plates were inoculated in duplicates with 0 1 ml quantities fiom the original suspension and its piepaied decimal dilutions Each inoculum was evenly spread by a sterile glass spieader The inoculated plates were incubated at 30°C for 48 houis

The average number of colonies per counTable plates were determined and the total colony count per gram muscle and cm^2 surface weie calculated and iecorded

3- *Staphylococcus aureus* count in fish

The same technique of the surface spread plate method was applied using Baiid and Parker agai medium (**ICMSF , 1978**) Incubated plates with control were incubated in a thermostatically controlled incubatoi at 37 °C for 24 - 48 hours Suspected colonies (black and shiny with narrow white maigins, surrounded by a clear zone)

were then counted The average number of colonies on countable plates was determined and *Staphylococcus aureus* count per cm^2 surface and gram of muscle was calculated and recorded

4- Determination of Enterobacteriaceae

The same technique of the surface spread plate method was applied using Violet red bile glucose agar (**ICMSF , 1978**) The inoculated plates were incubated at 37°C for 24 hours All purple colonies were counted The average number of colonies on counTable plates were determined and Enterobacteriaceae count per cm^2 surface and gram muscle was calculated

5- Determination of Coliform count (MPN)

The mutiple tube method recommended by **ICMSF (1978)** and (**APHA , 1989**) was adapted as follows

Presumptive Coliform test

From the previously prepared dilutions one ml each dilution was incubated separetly into each of 3 lauryl sulphate tryptose broth tubes supplemented with inverted Durham's tubes The inoculated tubes and control were incubated at 37°C for 48 hours Tubes showing acid and gas were considered positive and recorded

Confirmatory test

A loopful from each positive lauryl sulphate tryptose broth tube transferred to a fermentation tube containing brillient green lactose broth

2 % Inoculated and control tubes were incubated at 37°C for 48 hours and positive tubes showing gas production were recorded

The coliforms count was estimated and reported as the Most Probable Number (MPN) per cm^2 or gram of the original samples and recorded

Determination of coliforms organisms of fecal origin

E coli broth tubes were inoculated with a loopful from each positive lauryl sulphate broth tube The inoculated tubes were incubated at 45 5°C for 48 hours in a thermostaticaly controlled water bath *E coli* broth tubes displaying gas production were presumed positive for fecal coliforms

6- Isolation of *Aeromonas hydrophila* :

Clinically healthy fishes as well as fishes showing different pathological alterations were examined

The skin , muscles , liver and intestine of each of fish were examined for the presence of *Aeromonas hydrophila* The R-S (Rimler and Shotts) selective media , nutrient broth and nutrient agar media were used Plates of R-S and nutrient agar media were streaked for isolation After incubation for 18 - 24 hours at 37°C , the plates were examined to determine the colony types and other growth characteristics

Suspected yellow colonies on R-S were picked and transferred to each nutrient agar sloop , nutrient broth tubes and semisolid agar

Stained smear as well as cytochrome oxidase test were prepared from nutrient agar slant after 18 - 24 hours of incubation at 37°C

The nutrient broth tubes was used to inoculate the various test media used for identification which include citrate utilization , urea hydrolysis nitrate reduction , Voges ProsKauer , gelatin liquifaction , gas from glucose fermentation of galactose , lactose , sucrose , mannitol and the semi solid agar was used to detect the motility The isolates which suspected to be *Aeromonas* according to the above mentioned biochemical tests inoculated into API 20E which includes the following biochemical reactions

ONPG	Ortho-nitrophenyl-galactose
ADN	Arginine dihydrolase
LDC	Lysine decarboxylase
ODC	Ornithine decarboxylase
CIT	Citrate utilization
H_2S	H_2S production
URE	Urease
TDA	Tryptophane deaminase
IND	Indole production
VP	Voges ProsKauer ,
GEL	Gelatin liquifaction
GLU	Glucose
MAN	Mannitol
INO	Inositol
SOR	Sorbitol
RHA	Rhamnose
SAC	Sucrose
MEL	Melibiose
AMY	Amygdalin
ARA	Arabinose
OX	Cytochrome oxidase

Procedure

Preparation of the bacterial suspension

Agar plates were streaked by a well isolated colony to verify the purity of the strain A well isolated colony was made a homogenous suspension in 5 ml of distilled water

Preparation of galleries

An incubation tray and lid were set up-specimen number was recorded on the elongated flap of the tray , 5 ml of tap water were dispensed into the incubation tray to provided humid atmosphere during incubation API galleries were removed from sealed envelope and one gallery was placed in each incubation tray

Inoculation of the galleries

The API 20E gallery contains 20 microtubes , each consists of a tube and cuple with a Pasteur pipette , the API 20E gallery was inoculated The tube section of the side of the capule was filled by placing the pipette tip against the side of capule Both the tube and cupule of citrate , Vp and gelatin tubes were filled After the inoculation, the cupule sections of ADH , LDC , ODC and URE tubed were completly filled with sterile mineral oil

Incubation of the galleries

After inoculation , the lid was lid on tray and the galleries were incubated for 18 - 24 hours at 35 - 37 °C

Reading the galleries

The biochemical reactions of API 20E were recorded after 18 24 hours using interpretation Table

Identification of organisms

The API 20E analytical profile index (API # 2019) for rapid identification at species and biotype level The API coder transferes all the 21 biochemical results into a seven-digit numbers by specific numerical value for each of the positive results The number was then looked up in the index and the identification determined

7- Isolation of *Salmonella* and *Shigella*

The technique adapted was that recommended by **ICMSF (1978)** as follows

Samples of muscles , surface , intestines and livers of examined fishes collected into peptone water were incubated at 37°C for 24 hours Then 10 ml from each samples was transfered an Erlenmyer's flask containing 90 ml selenite broth and incubated at 43°C for 24 hours Loppfuls of enriched culture were streaked on plates of MacConkey broth , S S agar and brillient green phenol red lactose agar Suspected colonies were isolated in pure culture and subjected to different biochemical tests for identification (**Cruickshank *et al* , 1975**)

8- Isolation of enteropathogenic *E coli*

Tubes of brillient green lactose bile broth showing gas production and *E coli* broth used in detection of faecal coliforms were used to

inoculate eosin methylene blue agar , inoculated plates were incubated at 35 - 37°C for 24 hours

Colonies 2 - 3 mm in diameter with little tendency to confluent grwoth exhibiting a green metalic seen by reflected light and dark purple centeis by transmitted light were picked up and streaked on nutrient agar sloopes The isolates after being Gram stained were subjected to IMVIC reactions Suspected strains were then inoculated into API 20E , then subjected to serological examination

9- Isolation of *Campylobacter*

Samples under examination were inoculated on Priston campylobactei selective media (Oxoid) which were incubated at 37°C under micio-aerophills condition obtained by using anaerobic jar (Macintosh anf field's jar) and carbon dioxide kits (Campylobacter gas generating kits) Incubated plates were examined after 24 , 48 and 72 hours for suspected colonies

Identification of isolates

Suspected round , small gray , buffy or brownish colonies were picked up inoculated into thioglycolate broth media and incubated at 37°C for 48 hours to obtain pure cultures *Campylobacter* isolates were identified according **Holt *et al* (1994)** as follows

Morphology and staining reaction

Films weie prepared fiom suspected colonies , fixed and stained by Giam stain Giam negative bacilli , seagull wings shaped could be observed

Biochemical reactions

Thioglycolate broth medium was used as a basal medium for biochemical tests The following biochemical tests were applied for identification of isolates after being inoculated into thioglycolate broth The tests applied were that recommended by **Hall (1984)** which included catalase oxidase , hydrogen sulphide production , glucose fermentation , glycine and sodium selenite reduction tests besides sensitivity

10- Isolation of *Yersinia enterocolitica*

Isolation of *Yersinia enterocolitica* was done following the methods described by **Schiemann (1979) and Head *et al* (1982)** 1 ml of sample inoculated to modified Rappaports broth and incubated at -22°C for 18 hours A loopful of enrichment broth was streaked onto Yersinia selective agar medium (C I N) (Oxoid) and incubated at 25°C for 48 hours

Typical colonies of *Yersinia enterocolitica* will develop as a dark red (bull's eye) surrounded by a transparent border were tested biochemically **(Holt *et al* , 1994)**

III- Virological examination :

After preparation and concentration of water samples (**Gerba and Goyal , 1982**) , commercially marketed kits were used for detection of rota virus (BioMerieux) by using slide agglutination test , hepatitis surface B antigen by using two methods hepalatex test (CHEMTEX ,

USA) and HepaLisa (CHEMTEX , USA) , hepatitis A virus antigen by using an enzyme immunoassay HAT-EIA (DENKA SEIKEN Co LTD Japan) , poliovirus (DENKA SEIKEN Co LTD , Japan) by using complement fixation test , Adeno virus (DENKA SEIKEN Co LTD , Japan) by using complement fixation test , Measeles (DENKA SEIKEN Co LTD , Japan) by using passive haemagglutination and Rubella (ORION DIAGNOSTICA , ESPOO , Finland) by using haemagglutination inhibition test

4- RESULTS

I- Parasitological results :

Nine hundred and twenty wild and cultured fish, including 700 Tilapia fish and 220 *Clarias lazera* were collected from Cairo and Kalioblia , examined clinically , from which about 57 78% of Tilapia species and 51 87% of *Clarias lazera* showing obvious clinical signs

1- Clinical and post mortem lesions :

1 1 Clinical findings :

Clinical examination of naturally diseased Tilapia as shown in Table (7) and Fig (1) revealed that the skin of all these fish were covered with excess mucus, had detatched scales and appeared emaciated with sunken eyes (100% for each) In addition other signs were also recorded as haemorrhages on the skin either in patches (32 01%) or diffuse (7 32%) , grey discoloration of body surface either in patches (32 93%) or diffuse (42 07%), darkness of the skin either in patches (15 89%) or diffuse (16 83%),abdominal distention was found in about 32 01% exophthalmia in 21 34%, well demarcated black spots were found in the body surface especially at the area of caudal peduncle and fins of clinically diseased fish in a rate of 26 22% and 19 2% respectively, fins suffered from distruction either on their spines, rayes or membrans in a rate of 10 67%, 3 96% and 21 64% respectively, white spoted eyes and opacity in about 28 05% and errected scales in 14 94% of the clinically diseased fish

Clinical examination of naturally diseased *Clarias lazera* as shown in Table (8) revealed that the fish skin covered with excess mucus in about 96 91% Also other signs were found as haemorrhage on the skin (either patches (19 88%) or diffuse (5 15%), dark grey discoloration of body surface in some fish (either patches (28 87%) or diffuse (8 25%), black patches on the skin in about 8 25%, emaciation with low body gain and poor growth in about 96 91%, buffy skin as a result of the presence of large cyst in superfecial subcutaneous layer especially at the peduncle region and ventral side of the body of about 14 43%, enlarged abdomen in 17 53% and erroded fins in about 14 43% of the clinically diseased fish

1-2 Post mortem findings

Autopsies of all the examined Tilapia species as shown in Table (9) and Fig 2 and Fig 3 revealed the presence of muscle nodules in 77 57% of the fish, these nodules were of variable size which ranged from small to large macroscopic nodules and were of different colours, (greyish white, yellowish white, yellow yellowish brown, brown or black) Gill filaments had small greyish foci in 59 14%, presence of nodules under skin in 46 86%, emaciated and flabby spotted muscles in 46 86%, liver nodules showed in 35 86%, while mottled livers recorded in 29 57% Large greyish to yellowish white cysts found in the excretory portion of kidneys embeded within the tissue or attached to the renal capsule, sometimes it were attached to the peritenium, kidneys mottled in 23 29% and had nodules of variable size in 22 71% and nodulated spleen were detected in 16 00%, skin of the examined fish had black cysts in 10 71% or appeared erroded in 10 29% or ulcerated in 3 43%, fins contained black cysts in 7 57%, bianchial cavity had large yellowish

white cysts in about 3 57% In addition, fluid had been detected in the abdominal cavities and eye pouch in about 7 00% fiom the examined fish

Autopsies of the examined *Clarias lazera* as shown in Table (10) the most prominant finding was the muscle nodules (in about 85%) which weie of vaiiable size and coloui (gieyish white, yellowsh brown, brown and black pigmented) followed by cysts in superfecial epidermanl layer in about 63 18%, liver appeared mottled or nodulated in about 49 55%, muscles appeaied thin (42 73%) or soft flabby (42 73%), gills had grey white foci in their filaments in about 40 91%, kidneys mottled or nodulated in about 31 36%, spleen appeared mottled or had nodules in about 19 55% skin erosion and ulceration were found in about 10 91% and 7 27% iespectively and ascietic fluid showed only in about 3 74% fiom the examined fish

Internal findings of the examined fish revealed presence of encysted metacercariae in clinically healthy Tilapia species and cat fish in a rate of 64 52% and 73 17% respectively

Macro-and miciioscopic examination of fish for the presence of encysted metacercaiiae ievealed about 81 14% and 85% of Tilapia species and *Clarias lazera* respectively were infested with encysted metaceicariae

Regarding to the incidence and distribution of metacercarial infestation in muscles and other oigans of infested Tilapia species and *Clarias lazera* (Table 11) there were the maximum incidence in the

muscles of the posterior third of Tilapia species (95 60%) and in the muscles of the middle third of *Clarias lazera* (100%) which non significantly increase than that recorded in the muscles of the middle third of Tilapia species (85 21%) and in the muscles of the anterior third of *Clarias lazera* (83 95%) and significantly increased than that observed in the muscles of the anterior third (77 28%) and gills (76 40%) of Tilapia species and in the muscles of the posterior third of *Clarias lazera* (79 14%) A more significant reduction in the incidence of metacercarial infestation was detected in the liver (58 28%) and in the gills (48 12%) of *Clarias lazera* followed by a significant decrease in their distribution in liver (36 44%) and kidneys (28 68%) of Tilapia species and kidneys (36 90%) of *Clarias lazera* A more continuous significant reduction in the distribution of metacercarial infestation was recorded in spleen of Tilapia species (19 72%) and *Clarias lazera* (22 99%) and in eye (16 20%) and skin (15 14%) of Tilapia species then in tilapia fins (11 09%) which significantly increased than that observed in branchial cavity of Tilapia species (4 4%) The minimum incidence of metacercarial infestation (0 00%) were reported in branchial cavity, skin, fins and eyes of *Clarias lazera*

With respect to the incidence and distribution of metacercarial infestation in muscles and organs of the total examined Tilapia species and *Clarias lazera*, Table (11) shows that the maximum incidence of metacercarial infestation were detected in muscles of the middle third (85 00%) of *Clarias lazera* which was non significantly increased than that recorded in the posterior third of Tilapia species (77 57%) and that of anterior third of *Clarias lazera* (71 36%) and significantly increased than that mentioned in the middle third of Tilapia species (69 14%) and

muscles of posterior third of *Clarias lazera* (67 27%) A significant decrease in the distribution of metacercarial infestation was observed in muscles of the anterior third (62 71%) and gills (62 00%) of Tilapia species followed by a more significant reduction in their distribution in liver (49 55%) and in gills (40 91%) of *Clarias lazera* which significantly increased than that reported in kidneys (31 36%) of *Clarias lazera* and in liver (29 57%) and kidneys (23 29%) of Tilapia species A more continuous reduction was investigated in the spleen of *Clarias lazera* (19 55%) and in spleen (16 00%), eye (13 14%), skin (12 26%) and fins (9 00%) of Tilapia species which significantly increased than that showed in the branchial cavity of Tilapia species (3 57%) The lowest incidence of metacercarial infestation (0 00%) was recorded in branchial cavity, skin, fins and eyes of *Clarias lazera*

As shown in Table (12) , the maximum number of encysed metacercariae in Tilapia species, was observed in muscles of the posterior third (34 93/gm) followed by a continuous significant reduction in their number in muscles of the middle (23 21/gm) and anterior (13 24/gm) third of the body which significantly higher than that mentioned in liver (4 05), fins (3 38), skin (3 44) and kidneys (2 84) A more significant reduction in the average number of encysted metacercariae was observed in spleen (1 92) and eye lenses (1 24) The minimum number was recorded in the branchial cavity (0 16)

With respect to the effect of season on the number of encysted metacercariae in Tilapia species Table (12) shows that the maximum number was detected in muscles of the the posterior third during spring (62 87/gm) followed by a significant decrease in their number in the

posterior third during summer (33 34/gm) and in muscles of the middle third during spring (38 36/gm) and summer (28 02/gm) A more reduction in the number of encysted metacercariae recorded in muscles of the posterior third during winter (24 48/gm) and autumn (13 22/gm) and in muscles of the anterior third during spring (21 35/gm) followed by a continuous significant decrease in their number in muscles of the middle third during winter (15 02/gm) and autumn (13 22/gm) and in muscles of the anterior third during summer (12 84/gm), winter (10 37/gm) and autumn (9 42/gm), fins during spring (11 19) and skin during spring (12 46) A more significant drop in the number of encysted metacercariae observed in liver during winter (3 52), spring (5 42), summer (4 28) and autumn (3 63),fins during summer(3 36) and kidneys during spring (4 86) followed by a continuous significant decrease in their number in eye lenes during winter (2 88), kidney during summer (2 87) and winter (2 05), spleen during winter (2 94) and summer (2 09), skin during summer (2 44), spleen during winter (1 68), eye lenses during spring (1 28), kidneys during autumn (1 28), spleen during autumn (1 05) and eye lenses during summer (0 47) and autumn (0 18) The minimum number of encysted metacercariae (0 00) observed in fins and skin during winter and autumn and in the branchial cavity during spring, summer and autumn

For Euclinostomum infection the number of metacercariae per fish ranged from 1-3 and detected only during winter in Tilapia species The average number per fish was 0 92 ± 0 24

Gill affection in Tilapia species was recorded and the highest number of metacercariae was detected in the spring season (up to 6 per gill filament) followed by winter, summer and Autumn

Table (13) shows the maximum number of encysted metacercariae in *Clarias lazera* was recorded in muscles of the middle third (51 89/mg) which significantly higher than that observed in muscles of the anterior third (33 29/gm) and posterior third (24 74/gm) A more continuous significant reduction in the number of encysted metacercariae were detected in liver (5 86), kidneys (3 66) and spleen (1 52)

Regarding the effect of season on the number of encysted metacercariae in *Clarias lazera* Table 15 explains that the maximum number was detected in the muscles of middle third during winter (67 33/gm) summer (61 12/gm) and spring (56 93/gm) which non significantly varied from that mentioned during winter (67 33/gm), non significantly higher than that detected in the muscles of anterior third during winter (40 67/gm) and summer (40 80/gm) and significantly increase than that found in the muscles of antrior third during spring (38 60/gm) and of posterior third during winter (27 25/gm) and summer (33 97/gm) A more significant reduction appeared in the muscles of middle third during autumn (28 62/gm) and of posterior third during spring (23 83/gm) followed by that mentioned in autumn for the anterior third (17 36/gm) and posterior third (15 65/gm) Moreover, there was a continuous significant decrease in the number of encysted metacercariae in liver during winter (6 67), spring (7 04) and summer (7 33) and kidney during winter (4 08) and spring (5 72) followed by that detected in liver during autumn (3 02) and kidneys during summer (3 55) which significantly increased than that recorded in kidney during autumn (1 72) and in spleen during winter (1 67), spring (2 09) and summer (1 59) The minimum number of encysted metacercariae observed in spleen during autumn(0 89)

Table (7) Clinical symptoms of the examined Tilapia species in releation to months

Months	No of exam fish	No of infes fish	Clin normal fish	Clinical symptoms																		
				Em & L G	Abd dist	Haemorrhagels on skin		Grey discolorntion		Darkness of skin		Black S on fins	Distruction of fin			Exo	Wse & opacity	Er Scal	Det Scale	Ex M on Skin	Black S on Body	Sunken eyes
						patch	diff	patch	diff	patch	diff		rays	spins	Mem							
January	61	56	23	33	18	10	5	5	8	5	5	0	0	0	3	5	22	5	33	35	0	33
February	32	25	12	13	6	3	0	6	4	0	3	0	0	0	2	1	13	1	13	15	0	13
March	36	34	17	17	8	3	4	8	2	7	0	0	2	0	4	2	10	2	17	17	7	17
April	76	65	20	45	25	20	8	12	10	6	16	30	15	0	20	10	18	10	45	45	35	45
May	33	28	16	12	4	8	0	4	8	5	0	15	7	0	7	2	0	2	12	12	20	12
June	42	39	14	25	6	18	0	13	7	0	5	18	2	0	5	6	5	6	25	2	18	25
July	53	51	28	23	10	6	2	5	10	10	8	0	0	0	2	2	6	2	23	23	6	23
August	70	59	26	33	3	0	0	8	20	5	3	0	0	0	0	2	0	2	33	33	0	33
September	62	45	10	35	13	10		10	22	0	0	0	1	0	4	5	5	5	35	5	0	35
October	32	24	13	11	0	0	0	5	6	0	3	0	5	0	8	0	0	0	11	11	0	11
November	118	70	31	39	8	0	0	19	20	5	8	0	1	0	5	8	0	8	39	39	0	39
December	85	72	30	42	5	0	0	12	21	9	7	0	2	0	10	5	18	5	42	42	0	42
Total	700	568	240	328	105	77	24	107	138	52	48	63	35	0	70	49	92	49	328	328	86	328
%			42 22	57 75	18 66	13 56	4 23	18 83	24 29	9 15	8 45	10 97	6 19	0	12 32	8 60	16 19	8 60	57 74	5 4	15 14	57 74
			328	100 0	37 01	23 48	7 32	32 93	42 07	15 85	16 63	19 71	10 67	0	21 34	14 94	28 05	14 94	100 0	100 0	26 22	100 0

Clin = clinically Em = emaciation Abd= abdominal diff = diffuse LG = low body gain Mam = membrans
S = Spots Er = errected Det = detatched Ex = Excess Exo = Exophthalmia M= mucus
Wse = white spotted eyes exam = examend Infes= infested



Fig (1) Showing black spots on the skin with erroded fins (a) , Darkness of the skin and cloudness of the eyelense (b) and white spoted eye with exophthalmia and wide spread of minute haemorrhag's on the skin (c)

Table (8) Clinical symptoms of the examined *Clarias lazera* in relation to month

Months	No of the exam fish	No of inf fish	Clinic normal fish	Clinical symptoms												
				Haemorrhage on skin		Dark grey discoloration		Black patchs on skin		Skin cover with excess mucus	Emaciation with L G	Buffy skin	Distructed fins	Abdominal distention	Exoptalmia	Eye catract
				patch	diffuse	patch	diffuse	patch	diffuse							
January	19	13	6	0	0	0	5	2	0	7	7	5	0	2	0	0
February	15	12	5	2	0	2	3	0	0	7	7	4	0	0	0	0
March	14	13	4	0	2	0	1	3	0	9	9	8	2	4	0	0
April	18	15	5	3	2	5	0	0	0	10	10	7	1	3	0	0
May	22	19	8	2	0	2	7	0	0	11	11	5	0	0	0	0
June	20	20	12	0	0	5	5	0	0	8	8	2	0	0	0	0
July	17	15	4	2	1	0	6	2	0	9	9	10	4	0	0	0
August	15	12	6	0	0	4	2	0	0	6	6	0	0	0	0	0
September	21	15	12	3	0	3	0	0	0	0	0	0	0	2	0	0
October	14	10	6	3	0	1	0	0	0	1	1	0	0	1	0	0
November	30	30	17	4	0	2	10	1	0	13	13	13	7	5	0	0
December	15	11	5	0	0	4	2	0	0	6	6	2	0	0	0	0
Total	220	187	90	19	5	28	40	8	0	94	94	56	14	17	0	0
%			48 13	10 16	2 67	14 97	21 14	4 28	0	50 27	50 27	29 95	7 49	9 09	0	0
%				19 88	5 15	28 87	41 24	8 25	0	96 91	96 91	57 72	14 43	17 53	0	0

Table (9) Post mortem findings of the examined Tilapia species in relation to month

Months	No of exam fish	No of infes fish	Clin normal fish	Postmortem findings																
				Skin erso	Skin ulcer	Cyst on skin	Cyst on Br c	Grey tocı o ı gills	fluid in abd	fluid in eye pch	Cyst in Skin	Muscles			Mottling of			nodules on			Cyst on fins
												nod	flabby	ema	L	S	K	L	S	K	
January	61	56	23	0	0	0	20	30	5	5	33	36	33	33	18	16	18	14	16	18	0
February	32	25	12	2	0	0	5	20	1	1	13	20	13	13	8	5	6	13	5	6	0
March	56	34	17	5	3	7	0	34	2	2	17	34	17	17	8	5	5	8	5	5	0
April	76	65	20	17	3	35	0	45	10	10	45	65	45	45	33	17	31	33	17	25	30
May	35	28	16	12	5	15	0	20	2	2	12	28	12	12	11	5	6	11	5	6	15
June	42	39	14	10	7	18	0	30	6	6	25	39	25	25	17	8	15	17	8	15	18
July	55	51	28	7	0	5	0	25	2	2	23	51	23	23	18	11	15	18	11	15	0
August	70	59	26	6	2	0	0	40	2	2	33	59	33	33	21	5	13	21	5	15	0
September	62	45	10	8	2	0	0	35	5	5	35	45	35	35	31	20	28	31	20	28	0
October	32	24	13	5	2	0	0	8	0	0	11	18	11	11	5	0	0	18	0	0	0
November	118	70	31	0	0	0	0	55	8	8	59	70	39	39	21	11	16	33	11	16	0
December	85	72	30	0	0	0	0	72	7	5	42	72	42	42	16	9	10	38	9	14	0
Total	700	568	240	72	24	75	25	414	49	49	328	543	328	328	207	112	163	251	112	195	53
%			42 22	12 68	4 23	13 20	4 40	72 89	8 63	8 63	57 75	95 59	57 74	57 74	36 44	19 72	28 69	44 19	19 72	27 99	9 33
%			34 29	10 29	3 43	10 71	3 57	59 14	7 00	7 00	46 86	77 57	46 86	46 86	29 57	16 00	23 29	35 86	16 00	27 71	7 57

er = erosion Br C = branchial cavity Clinic = clinically

L = liver S = spleen K = kidneys ema = emaciation

Fig (2) Showing heavely infested Tilapia's muscles with medium size encysted metacercariae (Prohemistomatide sp) (X 4)



Fig (3) Showing heavely infected Tilapia's muscles with small size encysted metacercariae (Haplorchide sp) (X 4)

Table (10) Post mortem findings of the examined *Clarias lazera*

Months	No of the exam fish	No of inf fish	No of clinic normal fish	Post mortem findings															
				Skin erosion	Skin ulceration	Grey foci on gills	Cyst in branchial cavity	fluid in abdomen	Fluid in eye pouch	Cyst in skin	Muscles		Mottling of			Nodules			Emaciated muscles
											Soft & flabby	nodules	liver	kidney	spleen	liver	y	n	
January	19	13	6	0	0	5	0	1	0	13	7	13	10	8	7	10	8	7	7
February	15	12	5	2	2	5	0	0	0	12	7	12	8	5	3	8	5	3	7
March	14	13	4	2	2	10	0	2	0	13	9	13	6	3	4	6	3	4	9
April	18	15	5	5	4	8	0	0	0	12	10	15	9	4	4	9	4	4	10
May	22	19	8	2	1	13	0	0	0	19	11	19	13	5	2	13	3	2	11
June	20	20	12	0	0	8	0	0	0	15	8	20	15	9	6	15	9	6	8
July	17	15	4	3	2	11	0	1	0	13	9	15	10	7	3	10	7	3	9
August	15	12	6	0	0	4	0	0	0	12	6	12	6	4	1	6	4	1	6
September	21	15	12	3	2	3	0	0	0	8	0	15	3	1	0	3	1	0	0
October	14	10	6	3	1	3	0	0	0	3	1	10	0	0	0	0	0	0	1
November	30	30	17	4	2	14	0	3	0	23	13	30	18	13	8	18	13	8	13
December	15	11	5	0	0	6	0	0	0	6	6	11	11	10	5	11	10	5	6
Total	220	187	90	24	16	90	0	7	0	139	94	187	109	69	43	109	69	45	94
%			48 13	12 83	8 56	48 13	0	74	0	74 33	50 27	100 0	9	36 90	22 99	58 29	36 90	22 99	50 27
%				10 91	7 27	40 91	0	3 18	0	63 18	42 73	85 00	5	31 36	19 55	49 55	31 36	19 55	42 73

A = Bahr Moies

B = Drainage canals

exam = examined

Clinic = Clinically

D = El-Raih El-Tawfiki

Inf = infested

Table (11) Incidence and distribution of metacercarial infestation in affected Tilapia species and *Clarias lazera*

Fish Species	No of exam fish	No of infest fish	Incidence %	Muscles						Gills		Branchial cavity		Skin		Fins		Eye		Liver		Kidneys		Spleen	
				Anterior third		Middle third		Posterior third																	
				No of infest fish	/	No of infest fish		No of infest fish		No of infest fish	/	No of infest fish	/	No of infest fish	/	No of infest fish	/	No of infest fish	/	No of infest fish	/	No of infes fish		No of infes fish	
Tilapia	700	568	81 14[i]	439	77 28[b]	484	85 21[b]	543	95 60	43[a]	76 40[b]	25	4 4	86	[illegible]	63	11 09	92	16 20[fg]	207	36 44	163	28 68[de]	11[illegible]	19 72[fg]
Species	700	–		439	62 71	484	69 14[bc]	543	7 57[ab]	434	62 00[e]	25	3 57[i]	86	12 26	63	9 00	92	13 14[gh]	207	29 57[c]	16[illegible]	23 9[f]	11[illegible]	16 00[gh]
Clarias	270	187	85 00[i]	157	83 95[b]	187	100	148	79 14[b]	90	48 1[illegible]	0	0[j]	0	0[j]	0	0[j]	0	0[j]	109	58 [illegible]8	69	36 90[d]	43	22 99[cd]
lazera	270			157	71 36[ab]	187	85 00	148	67 [illegible][bc,e]	90	40 91[d]	0	0[k]	0	0[k,e]	0	0[k,e]	0	0[k]	109	49 55	69	31 36[e]	43	19 55[de]
Total	970	755	82 07	596	78 94[B]	671	88 87[A]	716	94 83[A]	574	69 40[C]	25	3 [illegible][i]	86	11 39[ab]	63	8 34[H]	92	12 19[G]	316	41 84[D]	232	30 72[E]	155	20 53[F]
	970			596	64 78[B]	671	72 93[A]	716	77 83[A]	574	56 56[C,e]	25	2 7[illegible][i]	86	9 35[ab]	63	6 85[H]	92	[illegible]	316	34 35[D]	[illegible]	25 2[illegible][F]	155	16 85[F]

Table (12) Average number of encysted metacercariae in the infested Tilapia species in releation to season

Season of the year	No of the exam fish	No of the infes fish	No of EMC per gram muscles from						No of Met in eye lenses		NO of EMC in fin		No of EMC in skin		No of EMC In branchial cavity		No of EMC in Liver		No of EMC in Kidney		No of EMC in spleen	
			Anterior third		Middle third		Posterior third															
			Range	M±SE	Range	M±SE	Range	M±SE	Rnage		Rnage	M±SE	Rnage	M±SE	Rnage	M±SE	Rnage	M±SE	Rnage	M±SE	Rnage	E
Winter (Dec Feb)	178	153	0-88	10 37^{g} ± 1 43	0 134	15 02^{cf} ± 1 96	2 200	24 48^{cd} ± 2 64	0 19	2 88^{ijk} ± 0 38	0	0	0	0^{f}	0 5	0 58° ± 0 11	0 25	3 52^{hi} ± 0 35	0 17	2 05^{ik} ± 0 27	0 12	1 68^{lm} ± 0 20
Spring March May)	145	127	0-_10	21 35^{de} ± 3 36	0 320	38 36^{b} ± 5 66	2-450	62 87 ± 8 28	0 15	1 28^{mn} ± 0 30	0 114	11 19^{fg} ± 1 94	0 68	12 46^{fg} ± 1 52	0	0	0 34	5 42^{h} ± 0 56	0 20	4 86^{h} ± 0 49	0 18	2 94^{ik} ± 0 20
Summer June August)	165	149	0 100	12 84^{fg} ± 1 56	0 135	28 02^{bc} ± 7 90	2 190	33 34^{bc} ± 2 84	0 10	0 47^{oq} ± 0 15	0 86	3 36^{h} ± 1 03	0 46	2 44^{ik} ± 0 55	0	0	0 18	4 28^{h} ± 0 57	0 15	2 87^{j} ± 0 43	0 9	2 09^{kl} ± 0 20
Autumn Sept Nov)	212	139	0-68	9 42^{g} ± 1 17	0 88	13 22^{fg} ± 1 54	1 130	22 12^{d} ± 2 03	0 8	0 18^{q} ± 0 085	0	0	0	0^{f}	0	0	0 13	3 63^{hj} ± 0 49	0 10	1 28^{mn} ± 0 18	0 8	1 05° ± 0 17
Over all	700	568	0 ?10	13 239^{C} ± 0 996	0 320	23 210^{B} ± 1 513	1-450	34 936^{A} ± 2 303	0 19	1 238^{I} ± 0 1d38	0 114	3 384^{DJ} ± 0 259	0 68	3 435^{DE} ± 0 422	0 5	0 157^{G} ± 0 032	0 34	4 046^{D} ± 0 249	0 20	2 843^{E} ± 0 206	0 18	^{F} ± 0 121

EMC = Encysted metacercariae Exam = Examined M = Mean SE= stander error

Met = Metacercariae infes = infested

Means with different small or Capital alphabetica superscripts are significantly different from each other at level (P < 0 05)

Table (13) Average number of encysted metacercariae in the infested *Clarias lazera* in releation to season

Season of the year	No of the exam fish	No of the infested fish	No of EMC in gram muscle from						No of the EMC in liver		No of EMC in kidney		No of EMC in spleen	
			Anterior third		Middle third		Posterior third							
			Range	M ± SE	Range	M ± SE	Range	M ± SE	Range	M ±SE	Range	M ±SE	Range	M ±SE
Winter (Dec-Feb)	49	36	2-408	40 67^{abc} ± 11 899	2 660	67 33^{ab} ± 18 71	0 - 368	27 25^{bcd} ± 10 37	0 - 60	6 67^{ef} ± 2 01	0 - 30	4 08^{efgh} ± 1 14	0 - 10	1 67^{hmn} ± 0 46
Spring (March-May)	54	47	0-188	38 60^{b} ± 4 24	4 - 250	56 93^{a} ± 6 74	0 - 108	23 83^{cd} ± 3 76	0 - 40	7 33^{e} ± 1 36	0- 20	5 72^{ef} ± 1 85	0 - 13	2 09^{ghm} ± 0 44
Summer (June-Augast)	52	49	0 -218	40 80^{abc} ± 7 60	2- 320	61 12^{a} ± 10 30	0 - 150	33 97^{bc} ± 5 49	0 - 35	7 04^{e} ± 1 05	0 - 20	3 55^{fg} ± 0 70	0 - 10	1 59^{mn} ± 0 32
Autumn (Sept-Nov)	65	55	0 - 90	17 36^{d} ± 3 03	3 - 130	28 62^{c} ± 4 39	0 - 70	15 65^{d} ± 3 25	0 - 13	3 02^{fg} ± 0 48	0 - 8	1 72^{m} ± 0 32	0 - 5	0 89^{n} ± 0 21
Over all	220	187	0 - 408	33 294^{B} ± 3 512	2 - 660	51 893^{A} ± 5 061	0- 368	24 738^{B} ± 2 824	0 - 60	5 86^{C} ± 0 599	0 - 30	3 663^{D} ± 0 561	0 - 13	1 524^{E} ± 0 178

EMC -Encysted metacercariae exam = examined
M = Mean SE = Stander error
Means with different small or Capital alphabetica superscripts are significantly different from each other at level (P < 0 05)
EMC = Encysted metacercariae

2- Prevalence of the encysted metacercariae :

Table (14) illustrates the prevalence of encysted metacercariae in relation to weight of both Tilapia species and *Clarias lazera* The maximum prevalence of encysted metacercariae was recorded in Tilapia species weighted from less than 100 gm up to 250 gm (62 75-93 94%) and in *Clarias lazera* that weighted from less than 200gm up to 500gm (86 67-98 33%) The prevalence of encysted metacercariae significantly decrease with the increase of fish weight for both Tilapia species that weighted 200-300gm (39 13%) and 300-350 gm (41 38%) and *Clarias lazera* that wighted 500-600gm (63 64%) and 600-700 gm (27 78%)

Table (14) Prevalence of encysted metacercariae infection in relation to weight of the examined Tilapia sp. and *Clarias lazera*

Fish species	Weight of the examined fish	No of the examined fish	No of the infested fish	Prevalence %
Tilapia species	Less than 100gm	387	326	91 32[a]
	100-150 gm	132	124	93 94[a]
	150-200 gm	67	56	83 58[ab]
	200-250 gm	51	32	62 75[ab]
	250-300 gm	46	18	39 13[c]
	300-350 gm	29	12	41 38[c]
Total	-	700	568	81 14[A]
Clarias lazera	Less than 200gm	60	59	98 33[a]
	200-300 gm	48	45	93 75[a]
	300-400 gm	42	38	90 48[ab]
	400-500 gm	30	26	86 67[ab]
	500-600 gm	22	14	63 64[bc]
	600-700 gm	18	5	27 78[c]
Total		220	187	85 00[A]

Means with different alphabetica superscripts are significantly different from each other at level ($P < 0\ 05$)

Table (15) shows a non significant variation in the prevalence of encysted metacercariae (60 71-91 86%) among different length of both Tilapia species (from fish measured less than 15cm up to those of 25-30 cm length) and *Clarias lazera* (from fish measuring less than 30cm up to that of 50-60 cm length)

Table (15): Prevalence of encysted metacercariae infection in releation to length of the examind Tilapia species and *Clarias lazera*

Fish species	length of the examined fish	No of examined fish	No of infested fish	Prevalence %
Tilapia species	Less than 15cm	237	175	73 84[a]
	15-20 cm	279	235	84 23[a]
	20-25 cm	141	124	87 94[a]
	25-30 cm	43	34	79 07[a]
Total	-	700	568	81 14[A]
Clarias lazera	Less than 30cm	6	79	91 86[a]
	30 -40 cm	62	55	88 71[a]
	40 -50 cm	44	36	81 82[a]
	50- 60 cm	28	17	60 71[a]
Total	-	220	187	85 00[A]

Means with different alphabetica superscripts are significantly different from each other at level ($P < 0\ 05$)

Table (16) reveales a non significant difference in the prevalence rate of encysted metacercariae between both Tilapia species (81 14%) and *Clarias lazera* (85%) However, there were variations in the incidence of encysted metacercariae during the different months of the year The highest incidence of encysted metacercariae were recorded for *Clarias lazera* during June and November (100%) followed by that detected during the period from January up to October (75-96 22%) and December (84 47%) for Tilapia species and that observed during the period from January upto May (68 42-86 36%), the period from July up to October (78 57 -88 23%) and during December (77 33%) for *Clarias lazera* The lowest incidence of encysted metacercariae was mentioned for Tilapia species during November (65 21%)

Table (16) · Monthly prevalence of the encysted metacercariae in the examined Tilapia species and *Clarias lazera*

Month of the year	Tilapia Species			*Clarias lazera*		
	No of examind fish	No of infested fish	Prevalence %	No of examined fish	No of infested fish	Prevalence %
January	61	56	87 80[ab]	19	13	68 42[ab]
February	32	25	78 125[ab]	15	12	80 00[ab]
March	36	34	94 44[a]	14	13	92 85[a]
April	76	65	85 55[a]	18	15	83 33[ab]
May	33	28	84 84[a]	22	19	86 26[ab]
June	42	39	92 85[a]	20	20	100[a]
July	53	51	96 22[a]	17	15	88 23[ab]
August	70	59	84 28[a]	15	12	80 00[ab]
September	62	45	72 58[ab]	21	14	66 66[ab]
October	32	24	75 00[a]	14	11	78 57[a]
November	118	70	65 21[b]	30	30	100[a]
December	85	72	84 47[a]	15	11	73 33[ab]
Total	700	568	81 14 %[A]	220	187	85 00%[A]

Means with different small or Capital alphabetica superscripts are significantly different from each other at level ($P < 0\ 05$)

Table (17) showes the prevalence of tencysted metacercariae in the examined Tilapia species and *Clarias lazera* The total incidence of encysted metacercariae was higher during summer (91 24%) and spring (87 43%) followed by that recorded during winter (83 26%) and which was significantly higher than that mentioned during autumn (70 04%) However, for Tilapia species the highest incidence of encysted metacercariae observed during summer (90 30%), spring (87 58%) and winter (85 96%) which significantly higher than that mentioned during autumn (65 57%) On the other hand for *Clarias lazera,* the maximum incidence of encysted metacercariae was found to be (94 23%) in summer followed by that detected during spring (87 03%) and autumn (84 62%) The lowest incidence was recorded during winter (73 46%)

Table (17) · Prevalence of the encysted metacercariae in the examined Tilapia species and *Clarias lazera* in releation to season

Season of the year	Tilapia species			*Clarias lazera*			Total	Total	
	No of exam fish	No of infest fish	prevalence %	No of exam fish	No of infest fish	prevalence %	No of exam fish	No of infest fish	incidence %
Winter (Dec -Feb)	178	153	85 96^{ab}	49	36	73 46^{bc}	227	189	83 26 ^{AB}
Spring (Mar -May)	145	127	87 58^{ab}	54	47	87 03^{abc}	199	174	87 43^{A}
Summer (June-Aug)	165	149	90 30^{ab}	52	49	94 23^{ab}	217	198	91 24^{A}
Autumn (Sept -Nov)	212	139	65 57^{c}	65	55	84 62^{abc}	277	194	70 04^{B}
Total	700	568	81 14^{I}	220	187	85 00^{I}	920	755	82 07

exam = examined infest = infested

Means with different small or Capital alphabetica or latin numbers superscripts are significantly different from each other at level (P < 0 05)

Table (18) shows that the encysted metacercariae recovered from Tilapia species were identified as Prohemistomatide, Haplorchidae, Clinostomatidae, Heterophyidae, Diplostomatidae, and Echinostomatidae metacercariae, while those recorded from infested *Clarias lazera* were belonging to families, Prohemistomatide, Diplostomatide Cynodiplostomatide and Haplorchide The morphological differance among various species of encysted metacercariae were presented in Table (19)and Figs (4 - 12)

***Prohemistomatidae* metacercariae :**

The cysts were found in both Tilapia species and *Clarias lazera* and were located in muscles and internal organ (liver, kidneys, spleen, gills and eye tissues) The encysted metacercariae were of medium sized and of variable colour varied from greyish white to yellowish brown, rounded in shap with double layered cyst wall, the outer was fragile and easly rupture and the inner was difficult to remove In some encysted metacercariae the parasite was surrounded with a membranous wall containing fluid The cyst measured 0 26-0 630 mm in diameter Fig (12 A,B&C and Fig 12A)

The excysted metacercariae were elliptical to oval in shape and measured 0 3-0 43 mm long and 0 20-0 25 mm wide The oral sucker was subterminal measured 0 048 x 0 066 mm Prepharynx absent Pharynx was spherical and measured 0 03-0 035 mm in diameter Ventral sucker was smaller than the oral one and measured 0 03 - 0 045 mm in diameter Intestinal caeca extending to the posterior extremity The primitive gonads were present Fig (12-D and Fig 12B)



Fig (4) Showing Diplostomatide metacercariae
A- Diplostomum ibis or Diplostomum niloticus encysted metacercaria
B- Diplostomum ibis or Diplostomum niloticus excysted metacercaria
C- Bulbophorus sp encysted metacercaria
D- Bulbophorus sp excysted metacercaria
E- Diplostomatid sp metacercaria
F- Diplostomatid sp excysted metacercaria
G- Diplostomum paracaudum metacercaria with evagenated pseudosuckers
H- Diplostomum paracaudum metacercaria with invagenated pseudosuckers
(Scale bar in A,B,E, F & H = 0 2 mm and in C & D = 0 5 mm)

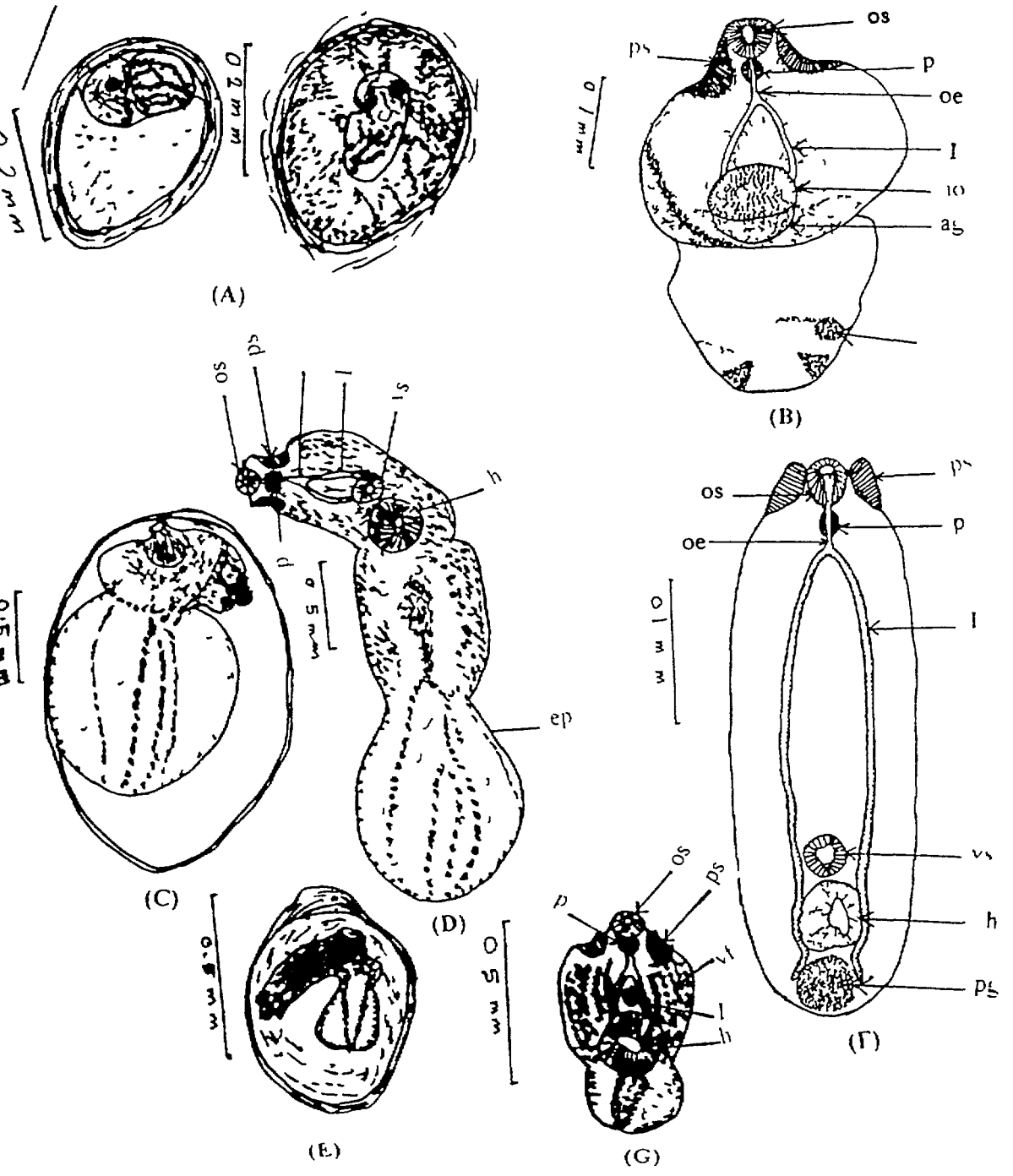

Fig (5) Diplostomatide metacercariae
A- *Diplostomum ibis* or *Diplostomum niloticus* encysted metacercaria
B- *Diplostomum ibis* or *Diplostomum niloticus* excysted metacercaria

Table (18) Identification of the recovered EMC from the examined Tilapia species and *Clarias lazera*

Fish species	Total no of examined fish	Total no of infested fish	Percentages %	Type of the recovered EMC from the examined fish
Tilapia species	700	568	81 14%	Prohemistomatide Haplorchide Heterophyide Diplostomatide Euclinostomatide Clinostomatide Echinostomatide
Clarias lazera	220	187	85%	Prohemistomatide Diplostomatide Cynodiplostomatide Haplorchide

EMC = Encysted metacercariae

Table (19) Difference between the detected metcercariae from Tilapia species and *Clarias lazera*

Type of EMC / Items	-atid	Clinostoma-tid	Cyanodiplo-stamatid	Diplostomatid		Echinostomatid	Heterophyid	Haplorchid	Prohemistomide
				metacercaria	encysted metacercariae				
Host	Tilapia sp	Tilapia sp	*Clarias lazera*	Tilapia sp	Tilapia sp and *Clarias lazera*	Tilapia sp	Tilapia sp	Tilapia sp and *Clarias lazera*	Tilapia sp and *Clarias lazera*
Location	Kidney	Branchial cavity	Muscles skin gill cover, floor of mouth	eye lense	Muscles, gills and internal organs	Gill filament and muscles	muscles, eye tissue internal organs and gill filam	muscles, gill filament eye tissue	muscles gill filament, eye tissue and internal organs
Colour	Greyish to yellowish - white	Whitish tenged with orange	Greyish white	Transparent	Grey to black	Greyish	Transparent with black spot	Light greyish	Greyish to yellowish brown
Shape	Spherical	Spherical	Rounded	Elongated worm like	Elleptical or oval	Oval	Oval to elleptical	Rounded to oval	Rounded
Size	3 2 - 6 3 mm in diameter	2 5-5 mm in diameter	0 6 -1 1 mm in diameter	0 46 x 0 23	0 3 - 1 15 x 0 22-0 78 mm	0 2 -0 25 x 0 09-0 15 mm	0 3 - 0 4 x 0 21 - 0 3	0 26 0 5 x 0 16 0 35	0 26 - 0 63 mm
Sucker	Well developed	Well developed	Well developed	Well developed	Well developed	Well developed	Difficult to seen	Difficult to seen	Well developed
Cyst wall	Very thick	Very thick	Very thick	Absent	Delecate to somewhat thicken and very thick in CL sp	Thin and transparent	Thick	Thick	Granular thick
Presence of black pigment	-	-	-	-	Present	-	Present		Present

C L Sp = *Clarias lazera* Diplostomatid cysts EMC = encysted metacercariae



Fig 6 Showing

A- Clarias lazera muscles infested with Diplostomum sp metacercaria
B- Diplostomum sp metacercaria *(Clarias lazera)*
C- Diplostomum sp excysted metacercaria *(Clarias lazera)*
D- Cyanodiplostomum sp encysted metacercaria
E- Cyanodiplostomum sp excysted metacercaria
F Gills infested with Echinostomatide sp metacercaria
G- Echinochasmus sp excysted metacercaria
H- Nephrostomum sp excysted metacercaria (Ventral veiw)
I- Nephrostomum sp excysted metacercaria (Lateral view)
J- Apharyngostrigia sp excysted metacercaria
(Scale bar of B &C = 0 35,of G = 0 2, & of D,E,H & J = 0 5)

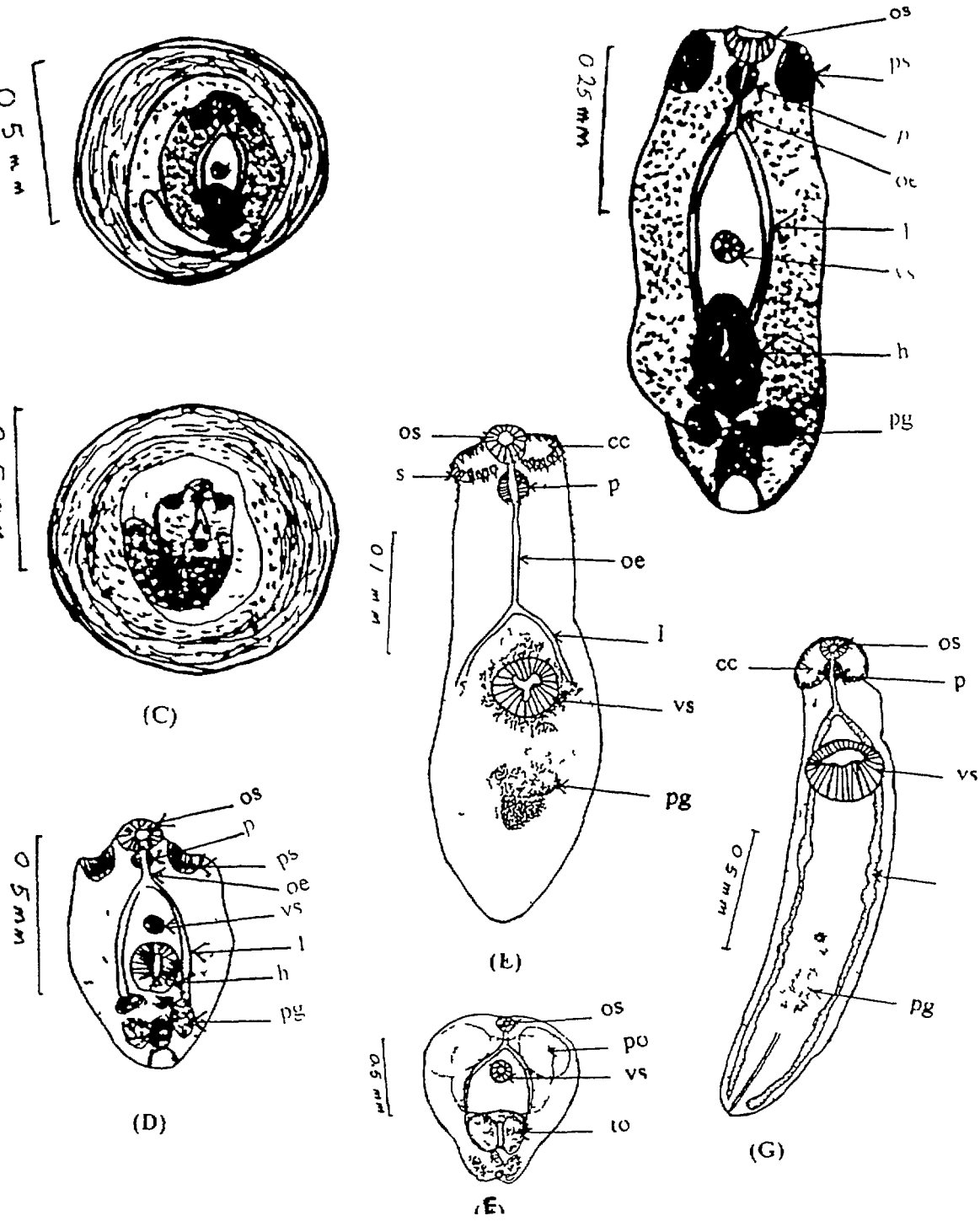

Fig (7) Excysted metacercariae
E- Echinochasmus sp
F- Nephrostomum sp
G- Apharyngostrigia sp



Fig 8 Clinostomum Tilapiae excysted metacercaria

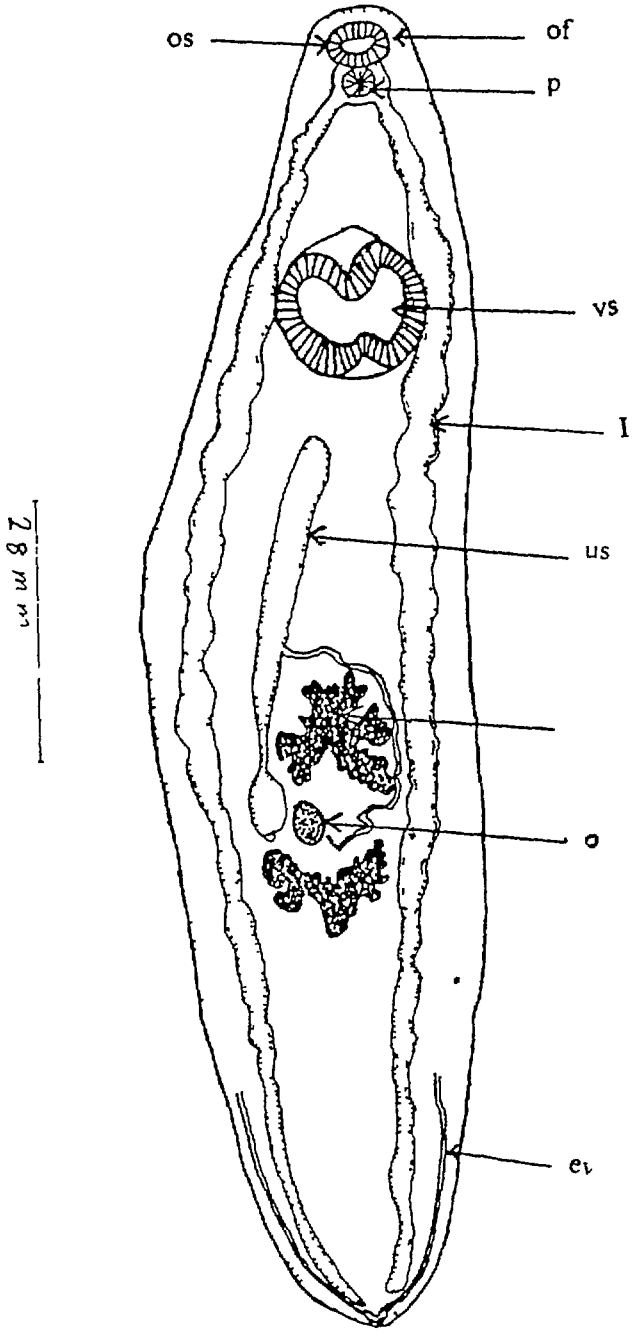

Fig 9 Clinostomum Tilapiae excyested metacercaria



Fig (10) *Euclinostomum heterostomum* metacercaria

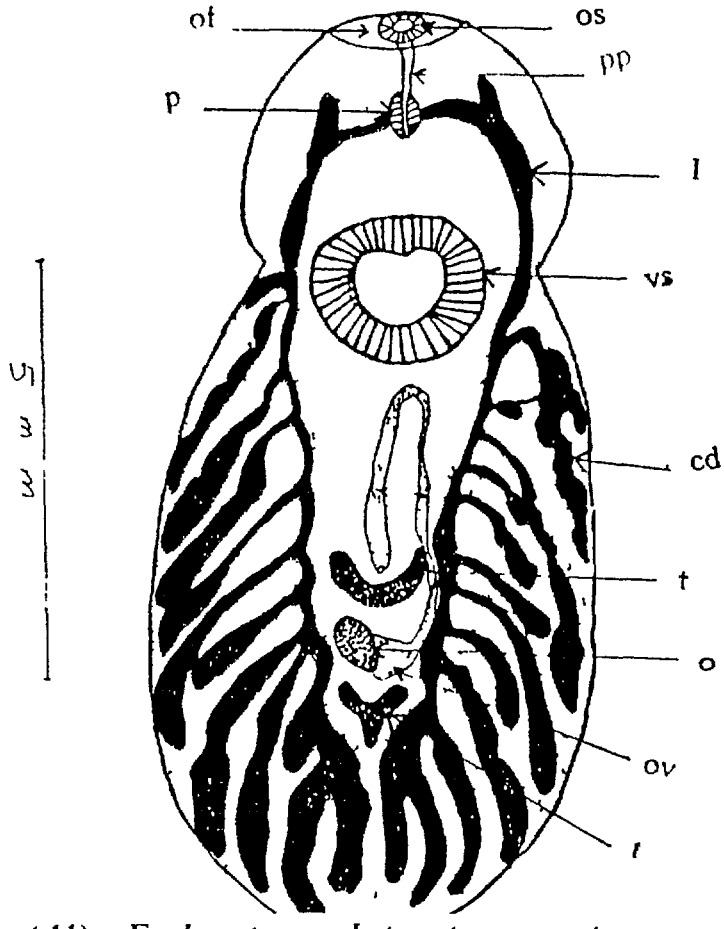

Fig (11) *Euclinostomum heterostomum* metacercaria

Heterophyide metacercariae :

The encysted metacercariae Fig (12-E) was obtained from Tilapia species and appeared as small sized pigmented cysts It was mainly located in the superfacial layer of the muscles espcially at the base of the fins In addition eye tissue, gills, liver, spleen, and kidney were found to be harbouring heterophyid metacercariae It was small oval to elliptical in shape and measured 0 30-0 40 mm in length and 0 21-0 3 mm in width The cyst wall was formed from two layers, the outr was thick while the inner was thin and the inner structure contained dark pigmented granules Fig (12-E & 12-C)

The excysted metacercaria was elongated and oval dorsoventrally and measured 0 2-0 25 mm in length and 0 1-0 12 mm in width The oral sucker was subterminal and measured 0 040 - 0 046 mm in diameter The ventral sucker was small, rounded and measured 0 032 - 0 039 mm in diameter Prepharynx, pharynx and oesophagus were found and the intesinal caeca could be detected Genital sucker located adjacent to the acetabulum Primordia of gonads and vitelline follicles (in peritesticular zone) could be detected at the posterior extremity Fig (12-F and 12-D)

Haplorchide metacercariae

The encysted metacercariae were recovered from both Tilapia species and *Clarias lazera* It were located in muscles and more abundant mainly around large blood vessels Also these metacercariae were found in liver, spleen,kidneys, eye tissue and gills The cyst was round to oval in shap and measured 0 26-0 50 x 0 16-0 35 mm The cyst wall was double layered and appeared transparent, hyaline and homogenous The cyst contained characteristically light spots Fig (12-G & 12-E)



Fig 12 Showing

A,B,C- Prohemistomatide species encysted metacercariae, (X 4) &(12A)

D- Prohemistomatide species excysted metacercaria, (X 4) & (12B)

E- Heterophyid encysted metacercaria, (X 10) & (12C)

F- Heterophyid excysted metacercaria, (X 10)& (12D)

G- Haplorchid encysted metacercaria, (X 10) & (12E)

H- Haplorchide excysted metacercaria, (X 10) & (12F)

The excysted metacercariae were elongated and measured 0 2-0 24 mm in length and 0 102- 0 112 mm in width The oral sucker measured 0 04- 0 053 mm in diameter Prepharynx, pharynx, oesophagus acetabulum, intestinal caeca and primordia of gonads can be detected in some speciemens Numerous refractile granules occupied the major part of the body Fig (12-H & 12-F)

3- Incidence of human infection with encysted metacercariae at Manzala Lake

Incidence of human infection with encysted metacercariae at Manzala Lake and clinical findings in patients was illustrated in Table (20 and 21)

Table (20) Age/sex relationship in case of heterophyesiasis in human at Manzala Lake " Egypt "

Age	Sex	No of exam cases	No of infect cases	Percent of infection
	Male	35	12	34 2
0 - 9	Female	65	25	38 5
	Subtotal	100	37	37 0
	Male	45	15	33 3
10 - 19	Female	63	18	28 6
	Subtotal	108	33	30 6
	Male	95	22	23 1
20 - 29	Female	40	6	15 0
	Subtotal	135	28	20 7
	Male	100	20	20 0
30 - 39	Female	72	11	15 3
	Subtotal	172	31	18 3
	Male	80	12	15 0
40 - 49	Female	20	4	20 0
	Subtotal	100	16	16 0
	Male	120	20	16 7
50 - 59	Female	60	12	20 0
	Subtotal	180	32	17 8
	Male	475	101	21 3
Total	Female	320	76	23 8
	Subtotal	795	177	22 3

The percentages were approximate to the nearst tenth

Table (21) Clinical finding in patients parasitized with heterophyids at Manzala Lake (El-Mattariayah and Manzala Cities)

Age	Percentage of infection	Symptoms on infected patients	Physical examination of infected patients
0 - 9	33 3	MD 16 patients showed NS	5 patient revealed BS
10 - 19	30 6	MD , One patient revealed BD , while 12 showed NS	N
20 - 29	20 7	D Three patients revealed BD 5 showed NS	N Three patient revealed AP
30 - 39	18 0	D 15 patient revealed BD while 5 appeared with NS	N
40 - 49	16 0	D , 6 patient revealed BD 7 showed NS	N
50 - 59	17 8	D , 16 patient revealed BD , 4 showed NS	N , 6 patient revealed AP

D Diarrhea BD Bloody Diarrhea AP Abdominal pain

BS Bawel sound NS No symptoms N No physcial examination

The percentages were approximate to the nearst tenth

4- Histopathological findings in different organ and tissues fish infested with metacercariae

Muscles

Muscles infested with metacercariae of Heterophyidae displayed cysts mainly concentrated in subepidermal layer, between collagen bundles of stratum compactum of the dermis or among the loose connective tissue in stratum spongeosum However, the cysts appeared small in size, great in number seen within superfacial layer of the dermis showed presence of faint basophilic parasitic elements Sometimes the cysts of other species of parasities appeared variable in size and the tissue reactions were in the form of aggregation of few number of inflammatory cells mainly macrophages and considerable number of melanin carrying cells with scattered number of eosinophilic granular cells (EGC) Sometimes inflammatory cells invade the parasitic elements or diffusely scattered under stratum compactum of the dermis Large parasitic cysts appear surrounded with serous fluid which contain a network of fibrin follow by cellular host reaction (Fig 13)

In most examined cases superficial muscle bundles appear replaced by connective tissue proliferation, fine blood capillaries with enlarged swelling endothelium usually surrounded with melanin-carrying cells Proliferated connective tissue usually infiltrated with leucocytes mainly macrophages and lymphocytes (Fig 14) Cysts invade deeply mascular layer with minimum tissue reaction in the form of slight connective tissue proliferation and few number of leucocytic cellular infilteration, together with melanin-carrying cells in surrounding tissue (Fig 15)

Fig (13) Skin of fish contain larg parastic cyst showing mild tissue reaction with aggregation of marcophages and other inflammatory cells Edema is also seen in deep dermal layer stain (H & E) X 250

Fig (14) Infested superficial muscle bundles appear replaced with Fibrocellular reaction Stain (H & E) X 125

Surround muscles revealed granulation of sarcoplasm and sometimes sarcolemmal vaculation or sarcoplasmis dissolution (Fig 16) In case of small parasitic cysts the tissue reaction comparatively appear great, form of thick layer of inflammatory cells mainly lymphocytes and macrophages Tunnels of inflammatory cells were seen between muscle bundles extended until reach the area of parasitic cysts (Fig 17)

In case of diplostomum spp infested tissue, the reactions were characterized by inflammatory cells, infletration sometimes together with great number of melanin- carrying cells which appear in the outer zone of parasitic cyst and in perivascular area Parasitic elements appear large in size and fill the parasitic cyst Oral and ventral suckers as well as pseudosucker easly detected in histological sections (Fig 18) Degenerated and necrotized parasitic cysts were noticed Sometimes it undergo calcified or replased with connective tissue proleferation In these cases the cystic wall appear thick hyalinized, refractile and parasitic elements were basophilic and calcium granules were dark bluish, as concentric lamellae at the inner wall of the parasitic cysts replacing parasetic elements Host tissue reactions were pronounced characterized by active connective tissue proliferation causing pressure atrophy and even replaced the neighbouring musclar tissue Muscle bundles arround parasitic cysts were suffered from degenerative changes and zencker's necrosis (hemogenous, refractile darkly eosinophilic in stain) (Fig 19)

Internal organs

The histopathological findings of internal organs including liver and kidney were manifested in Figs (20 - 27)



Fig (15) Dorsal muscle showing Cysts deeply invaded muscle bundles with few leucocytic and melanin carrying cell infiltration (arrow) Stain (H & E) X 125

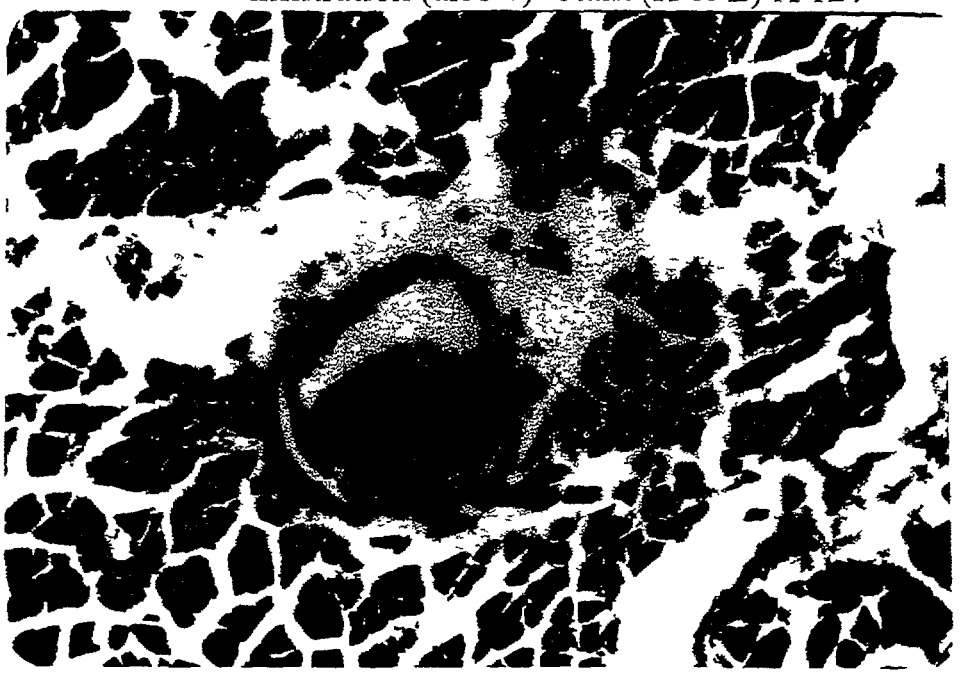

Fig. (16) Muscle bundles infested with large cyst revealed Sarcoplasmic granulation, vacuolation and dissolution (arrows) Stain (H & E) x 250

Fig. (17) · Muscle bundles of fish showing infestation with great number of cysts with tunnels of inflammatory cells infiltration between muscle faciculi (arrow) Stain (H & E) x 125

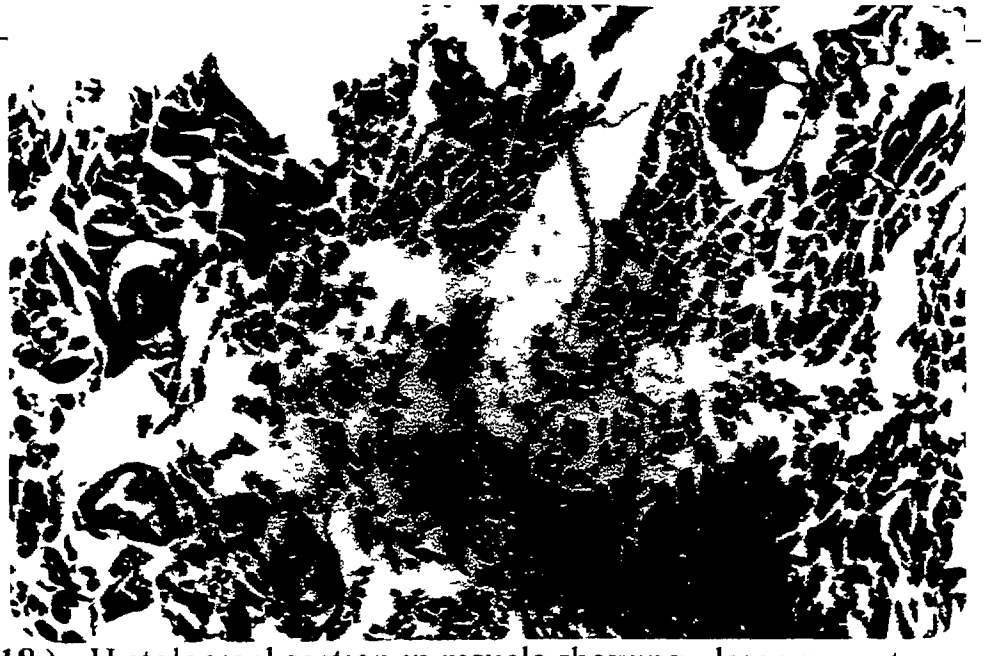

Fig (18) Histological section in msucle showing large parasitic elements filled the cystic capsule with mild tissue reaction Stain (H & E) x 125

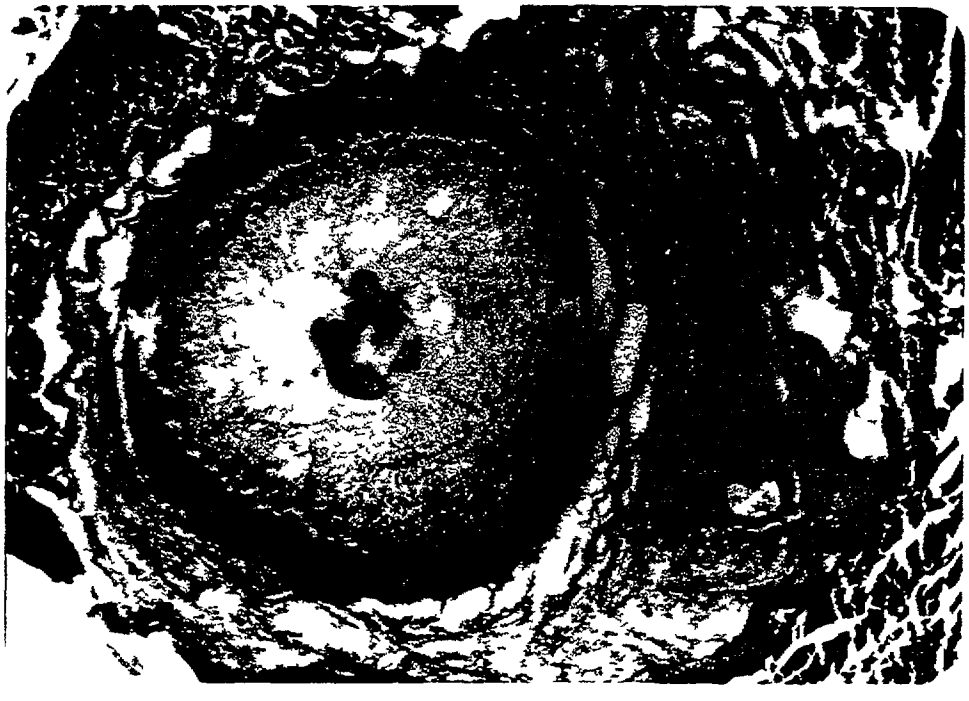

Fig (19) · Section in muscle display degenerated calcified large parasitic cyst with marked host connective tissue proliferation Degeneration and necrosis of neighbouring muscles also noticed Satin (H & E) x 125



Fig (20) Liver infested with multiple small size parasitic cysts showing Dissociation of pancreatic acini (arrow) and coagulative necrosis of hepatocytes Stain (H & E) x 125



Fig (21) Liver infested with parasitic cysts (arrow) showing Degenerative changes of hepatocytes with dissociation of pancreatic acini and leucocytic infiltration Stain (H & E) x 250



Fig (22) Histological section in parasitized liver displayed large parasitic cyst with mild tissue reaction

Stain (H & E) x 125



Fig (23) Liver showing Large parasitic cysts with mild tissue reaction form mainly of connective tissue with few number of leucocytic infilteration Stain (H & E) x 125

Fig. (24) · Anteriori kidney showing Parasitic cyst form of two layer inner collagenous and auter cellular form of leucocytes and melanin carying cells Stain (H & E) x 125

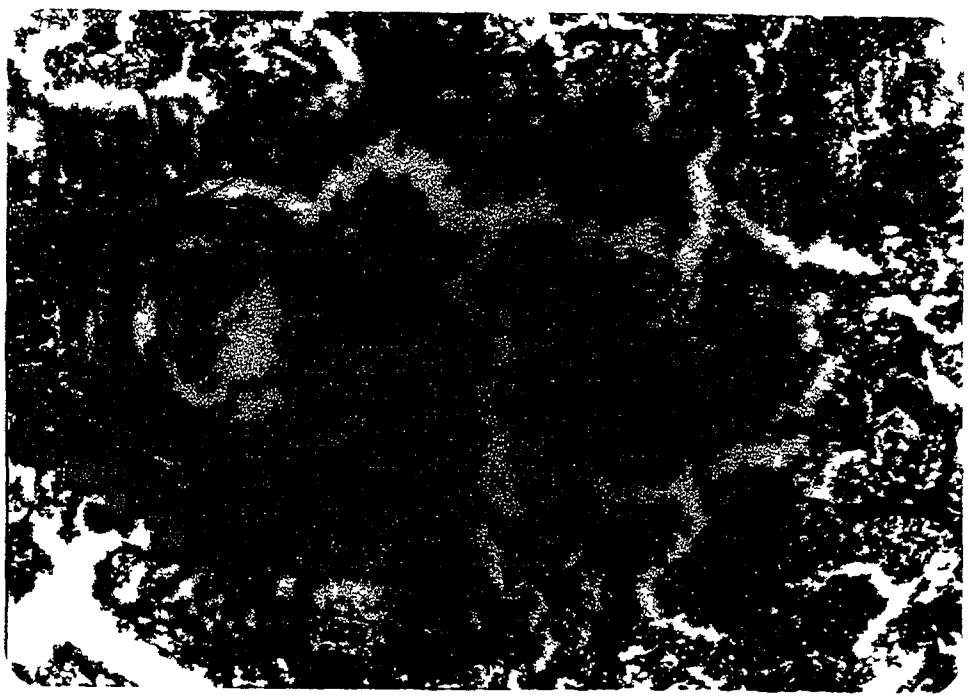

Fig (25) Anterior kidney infested with parasitic cyst displayed degenerative changes of kideny tubules with depletion of intertubular hematopoie ic elements Stain (H & E) X 125

Fig (26) Kidney infested with large number of parasitic nodular cysts (arrows) showing Degenerative changes and coagulative necrosis in kidney tubules Atrophy of capillary tuft with edema in Bawman's capsule also notice Stain (H & E) X

Fig (27) : Kidney infested with Euclinostomum (arrows) showing Large parasitic elements surround with well developed connective tissue capsule infiltrated with leucocytes and melanin-carrying cells Stain (H & E) x 125

5- Experimental infection of birds with encystedmetacercariae (EMC)

Experimeninfection of week old-chickens with EMC collected from both Tilapia fish and *Clarias lazera* as presented in Table (22) revealed that trematode species including *Prohemistomum vivax*, *Mesostephanus appendiculatus* and *Haplorchis pumilio* were obtained from the small intestine of chicks fed on infested Tilapia fish muscles while in chicks , group recieving infested Tilapia gills *Mesostephanus appendiculatus* fluke was found in their small intestine and also *Prohemistomum vivax* , *Mesostephanus appendiculatus*, *Mesostephanus fajardensis* , *Haplorchis pumilio*, *Paracenogonimus ovatus* and *Ornithodiplostomum* spp were obtained from small intestine of the group recieving infested *Clarias lazera* muscles

Experimental infection of baby chicks with metacercariae of Tilapia fish as found in Table (23) revealed that the encysted metacercariae obtained from eye ball content and the tissue around it were given orally to baby chicks and the adult fluke recovered from small intestine were *Haplorchis pumilio* , *Prohemistomum vivax* and *Pygidiopsis genata* The group of baby chicks given orally excysted metacercariae collected from branchial cavity of Tilapia failed to give adult worm but in one dead bird two immature worms were found in its oesophagus

Table (24) illustrated that experimental infection pickini duckling with encysted metacercariae from both Tilapia species and *Clarias lazera* failed to develop to mature worm in their intestine However, oral dosing

of balady duckling with infested muscles from both Tilapia sp and *Clarias lazera* was succeeded to produce mature worm in their intestine In duckling group recieving Tilapia infected muscle, their small intestine found to contain *Prohemistomum vivax* and *Mesostephanus appendiculatus*, while those recieving *Clarias lazera* infected muscles their intestine revealed presence of adult flukes including *Prohemistomum vivax*, *Mesostephanus appendiculatus*, *Mesostephanus fajardensis* and *Paracenogenimus ovatus*

Table (25) revealed that experimental infection of squabs with metacercarial infested muscles succeeded to produce adult worm in their intestine The obtianed trematodes identified as *Prohemistomum vivax* , *Mesostephanus appendiculatus* , *Mesostephanus fajardensis* , *Haplorchis pumilio* , *Pygidiopsis genata* and *Holostephanus volgensis* Birds groups recieved metacercarial infested gills failed to give mature worm, while those orally given infected *Clarias lazera* muscles, their small intestine had many species of trematodes including Prohemistomum vivax , Mesostephanus appendiculatus , Mesostephanus fajardensis , *Mesostephanus flapi* , *Paracengonimus ovatus* and *Haplorchis pumilio*

Table (26) revealed that experimental infection of quails with encysted metacercariae collected from infected Tilapia species resulting in presence of *Prohemistomum vivax* and *Mesostephanus appendiculatus* in their intestine While those recieving *Clarias lazera* metacercariae found to contain *Prohemistomum vivax* , *Mesostephanus appendiculatus* and *Mesostephanus fajardensis* in their small intestine

Experimental infection of herons as found in Table (27) showed that , herons received Tilapia species metacercariae had many species of trematodes in their intestine including *Prohemistomum vivax* , *Mesostephanus appendiculatus* , *Haplorchis pumilio* , *Haplorchis disca* , *Haplorchis yokojawai* , *Heterophyes equalis* , *Pygidiopsis genata* , *Pygidiopsis summa* , *Centrocestus armatus* , *Heterophyes dispar* , *Asococtyl mcintoshi* , *Metagonimus yokojawai* , *Diplostomum ibis sp nov*, *Diplostomum niloticus sp nov* , and *Echinochasmus japonicus* while those recivemg infected Tilapia gills revealed presence of *Echinochasmus japonicus* , *Echinochasmus beleocephalus* , *Apharyngistrigia ibis* , *Haplorchis pumilio centrocestus armatus* and *Ascocotyle micintochi* trematodes in their small intestine Moreover *Haplorchis pumilio* , *Haplorchis yokojawai* , *Haplorchis disca* , *Nephrostomum ramosum* , *Prohemistomum vivax* and *Mesostephanus appendiculatus* were obtained from small intestine of experimentally infected herons with *Clarias lazera* metacercariae

Table (28) illustrated that experimental infection moorhens with Tilapia species metacercariae resulting in the presence of mature worms in their intestine identified as *Prohemistomum vivax* , *Mesostephanus appendiculatus* and *Haplorchis pumilio* In addition *Prohemistomum vivax* , *Mesostephanus appendiculatus* and *Haplorchis pumilio* were recovered from the small intestine of experimentally infected moorhens with *Clarias lazera* metacercariae

It is clear that Tilapia species and *Clarias lazera* metacercariae were experimentally fed to diffrent species of birds where were find its way to complet their life cycle in a suitable host and the trematode parasites of different maturation stages were found in their intestine As a result of direct irritation of the parasites on muscosa of the small intestine, heavely infested birds showing clinical signs including loss of

body weight, unkempt feather , unthriftiness and watery diarrhoea Post mortem examination of some slaughtered birds revealed emaciation with promination of keel bone dilated gut with unusual amount of fluid , thickening ofthe intestinal wall, velvety appearance of mucosa with sloughing and bloody intestinal content in some cases The more sensitive birds were quails followed by squabs, herons, moorhens, balady duckling and chicks while pickini duckling resist the infection

Experimental infection of pickini duckling with all species of encysted metacercariae recovered in the present investigation failed to develop to adult worms and so there was no eggs in their droppings While experimental infection of baby chicks, week-old chicks,balady duckling, squabs, quails, herons, and moorhens revealed presence of eggs in their dropping and the prepatent period for the discovered trematodes varied according to species of trematodes and the types of experimental avian hosts Four type of eggs recorded and morphologically different, the first two groups were detected from most of the experimental birds, first typewas oval or ovoid, yellowish in colour, operculated with thin shell, medium to some-what large sized and measured 0 089 x 0 052 mm in average size and suspected to beProhemistomatidae eggs, the second type was small in size, oval, yellowish in colour operculated with thick shell and measured 0 020 x 0 015 mm and suspected to be Heterophidae or Haplorchidae While the last two groups of eggs were recovered only from the dropping of the infested herons, the first group of eggs were oval inshape, yellowish in colour, thin shell and measured 0 089x 0 056 mm suspected to be Dilpostomatidae eggs, and the second group of eggs were ovoid in shape transparent in colour and measured 0 09 x 0 07 mm in average size and suspected to be Echinostomatidae eggs

Table (22) Experimental infection of week-old- chicks with EMC from Tilapia species and *Clarias lazera*

Donor fish	Source of EMC	No of infected birds	Dose per bird	No of EMC per each unit	No of positive birds	No of the obtained trematode	Recovery rat	Species of the obtained trematodes	nt period/ day	Predilection seat for each parasite
Tilapia species	Muscles	9	2 gram	150 200 per gram	2	14	2	*Prohemistomum vivax* *Mesostephanus app* *Halporchis pumilio*	5 7 5 7 7 9	middle and lower SI middle and lower SI lower SI
	Gills	6	filament of 4 pair gill leaflets	2 6 per each gill filament	1	2	⊖	*Mesostephanus app*	5 7	middle SI
Clarias lazera	Muscles	9	2 gram	150-200 per gram	6	400	19 05	*Prehemistomum vivax* *Mesostephanus app* *Mesostephanus fajardensis* *Haplorchis pumilio* *Paracenogonimus ovatus* *Ornithodiplostonum spp* *Mesostephonus flapi*	5-7 5-7 5 7 7 9 5 7 5 7 5 7	upper, middle& lower SI upper, midle & lower SI middle & lower SI lower SI lower SI lower SI lower SI

EMC = encysted metacercariae
SI = small intestine
app = appendiculatus

⊖= difficulty of claculation of the number of encysted metacercariae in primary and secondary lamellae

Table (23) Experimental infection of baby chicks with metacercariae of Tilapia species

Donor fish	Source of metacercariae (encysted and or excysted)	No of experimental infected birds	Dose per bird	No of positive bird	No of the obtained trematode	Recovery rate	Species of the obtained trematode	Prepatent period per day	Predilection seat for each parasite
Tilapia	eye ball content and tissue around it	6	50 80	4	15	5 80	*Haplorchis pumilio* *Prohemestumum vivax* *Pygidiopsis genata*	7 9 5 7 4 5	lower SI middle SI lower SI
Species	branchial cavity	6	5	1	2	40	*Clinostomum tilapia*	1 day	oesophagus

SI = small intestine

Table (24) Experimental infection of day-old-ducklings with EMC from Tilapia speceis and *Clarias lazera*

Species of ducklings	Donor fish	Source of EMC	No of experimental infected bird	Dose per bird	No of EMC / each unit	No of positive bird	No of the recovered trematode	Recovery rat	Species of the recovered trematode	Pre patent period / days	Predilection seat for each parasite
Pickini ducklings	Tilapia species	Muscles	9	2 gram	100 120	0					
		Gills	9	filament of 4 pair gill leaflets	each gill filament had 2 6	0					
	Clarias lazera	Muscles	9	2 gram	150 170	0					
Balady ducklings	Tilapia speceis	Muscles	5	2 gram	100 120	5	300	27 27	*Prohemistomum vivax* *Meostephanus app*	5 7 day	upper & middle SI upper & middle SI
	Clarias lazera	Muscles	5	2 gram	150 170	5	500	31 25	*Prohemistamum vivax* *Mesostephanus app* *Mesostephanus Faj* *Paracenog ovatus*	3 5 day	upper middle & lower SI upper & middle SI upper SI middle SI

SI = small intestine
EMC = encysted metacercariae
app = appendiculatus
Faj = fajardensis
paracenog = paracenogonimus

Table (25) Experimental infection of squabs with EMC from Tilapia species and *Clarias lazera*

Donor fish	Source of EMC	No of infected bird	Dose per bird	No of EMC per each unit	No of positive birds	No of obtained flukes	Recovery rat	Speceis of the obtained trematod	Prepatent period / day	Predlection seat for each parasite
Tilapia species	Muscles	6	10 gm	200-250	5	1934	17 19	*Prohemistomum vivax*	5 7	upper middle & lower SI
								Mesostephanus app	5 7	upper middle & lower SI
								Mesostephanus fajardensis		
								Haplorchis pumilio	5 7	upper, middle & lower SI
								Pygidiopsis genata	4 6	lower SI
								Holostephauns volgenis	4 5	middle SI
									4 5	middle & lower SI
	gills	3	Gill filament of 4 pair gill leaflets	2 6 in each gill filament	0					
Clarias lazera	Muscles	6	10 gm	200 250	6	2600	23 11	*Prohemistomum vivax*	5 7	upper middle & lower SI
								Mesostephamus app	5 7	middle & lower SI
								Mesostephanus fajardensis	5 7	middle & lower SI
								Mesostephanus flapi	5 7	lower SI
								Paracenogonimus ovatus	5 7	middle & lower SI
								Haplorchis pumilio	4 6	lower SI

SI = small intestine
EMC = encysted metacercariae
app = appendiculatus

Table (26) Experimental infection of quails with EMC from Tilapia species and *Clarias lazera*

Donor fish	No of infected birds	Dose per bird (EMC)	No of the positive birds	No of recovered flukes	Recovery rat %	Species of the recovered trematodes	Prepatent period /day	Predilection seat for each parasite
Tilapia species	8	100	8	50	6 25	*Prohemistomum vivax*	7 9	upper & middle SI
						Mesostephanus appendiealatus	7 9	upper & middle SI
Clarias lazera	8	100	8	78	9 25	*Prohemistmomum vivax*	7-9	upper &middle SI
						Mesostephanus appendiculatus	7 9	uper & middle SI
						Mesostephanus Fajardensis	7-9	upper & middle SI

EMC = Encysted metacercariae
SI = Small intestine

Table (27) Experimental infection of herons *(Egretta ibis ibis)* with metacercariae from Tilapia species and *Clarias lazera*

Donor fish	Source of met	No of exp infected birds	Dose per bird per day	Feeding period (in day)	No of positive bird	No of the obtained trematode	Recovery rate	Species of the obtained trematodes	Prepatent period (day)	Predilection seat for each parasite
Tilapia species	Muscles	6	200 220 meta	3	6	1800	47 62	*Prohemistomum vivax*	7 9	upper SI
								Mesostephanus app	7 9	upper SI
								Haplorchis pumilio	4 6	upper middle & lower SI
								Haplorchis disca	4 6	upper & middle SI
								Haplorchis yokjawai	4 6	middle SI
								Heterophys equalis	4 5	middle SI
								Pygidiopsis genata	4 5	upper, middle & lower SI
								Centrocestus armatus	7 9	upper & middle SI
								Pygidropsis summa	5 6	upper middle & lower SI
								Heterophys dispar	4 5	upper middle & lower SI
								Metagonimus yokajawai	7 9	middle SI
								Diplostomum ibis sp nov	9 12	upper & middle SI
								Diplostomum niloticus sp nov	9 12	upper & middle SI
								Echinoschamus japonicus	9 12	upper SI
	Gills	3	gill filament of 4 pair gill leaflet	3	3	400	(-)	*Echinochasmus japonicus*	9 12	upper SI
								Echinochasmus beleocephalus	9 12	upper SI
								Haplorchis pumilio	12 15	middle small int
								Centrocestus armatus	4 6	upper middle & lower SI
								Ascocotyle micintoshi	3 5	upper middle & lower SI
								Apharyngistrigia ibis	3 5	upper & middle SI
									12 15	upper small intestine
Clarias lazera	Muscles	6	300 350 meta	3	6	720	12 31	*Haplorchis pumilio*	4 6	upper & middle lower SI
								Haplorchis yokojawai	4 6	upper & middle SI
								Haplorchis disca	4 6	upper SI
								Prohemistumum vivax	7 9	upper SI
								Mesostephanus append	7 9	upper SI
								Nephrostomum ramosum	12 18	upper SI

SI = small intestine
Met = metacercariae
(-) = difficulty of calculation of the number of encysted metacercariae in primary and secondary lamellae
app = appendiculatus

Table (28) Experimental infection of moorhens *(Gallinula ch chloropus)* with metacercariae from Tilapia species and *Clarias lazera*

Donor fish	Source of Met	No of experimal infect bird	Dose per bird	Feeding period (days)	No of positive bird	No of the obtained trematode	Recovery rate	Species of the obtained trematode	Prepatent period (in day)	Predelection seat for each porasite
Tilapia species	Muscles	3	200 220 meta	1	2	100	23 81	*Prohemistomum vivax*	7 10	middle SI
								Mesostephanus app	5 7	upper SI
								Haplorchis pumilio	6 7	middle & lower SI
Clarias lazera	Muscles	3	150 170 meta	3	1	20	4 17	*Prohemistomum vivax*	5 7	upper SI
								Mesostephanus app	5 7	upper SI
								Haplorchis pumilio	6 7	lower SI

Met = metacercariae
SI = small intestine
app = appendiculatus

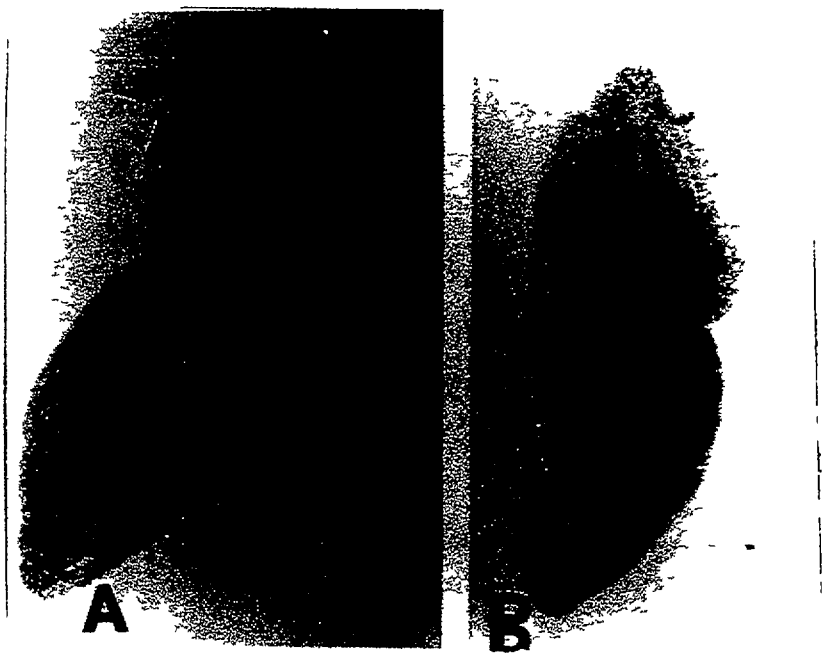

Fig 28 Showing

(A) *Diplostomum ibis sp nov* (X 100) .

(B) *Diplostomum niloticus sp. nov.* , (X 10)

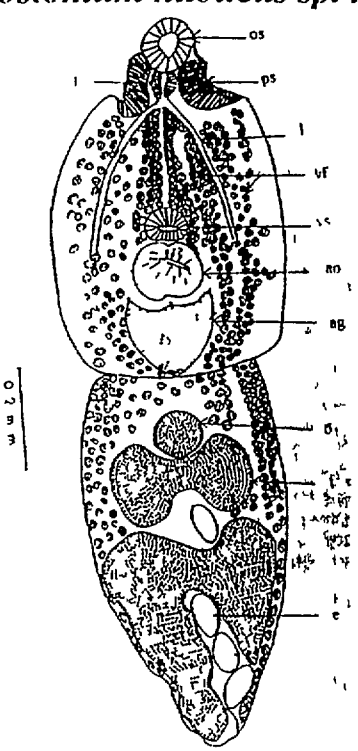

Fig (29) . *Diplostomum ibis sp nov*

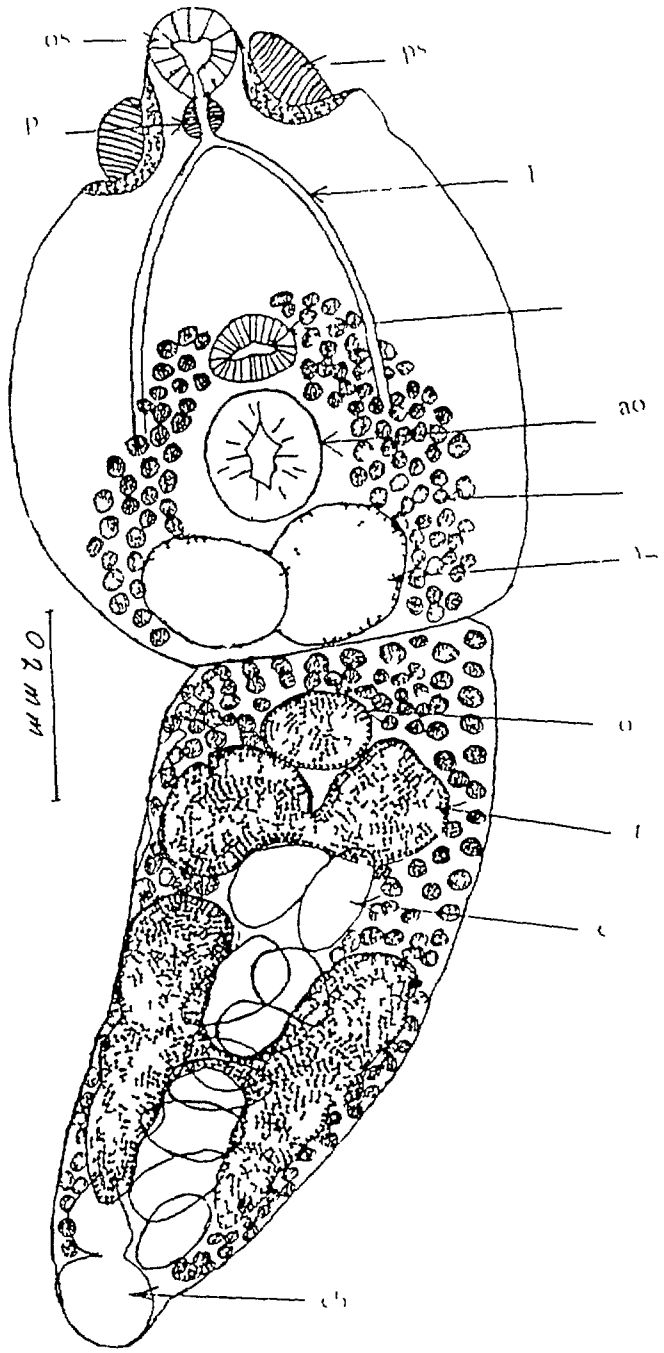

Fig (30) *Diplostomum niloticus sp nov*



Fig. (31) Showing

(A) *Ornithodiplostomum* sp , (X 100) .

(B) *Echinochasmus japonicus* , (X 100) .

(C) *Echinochasmus beleocephalus* , (X 100)

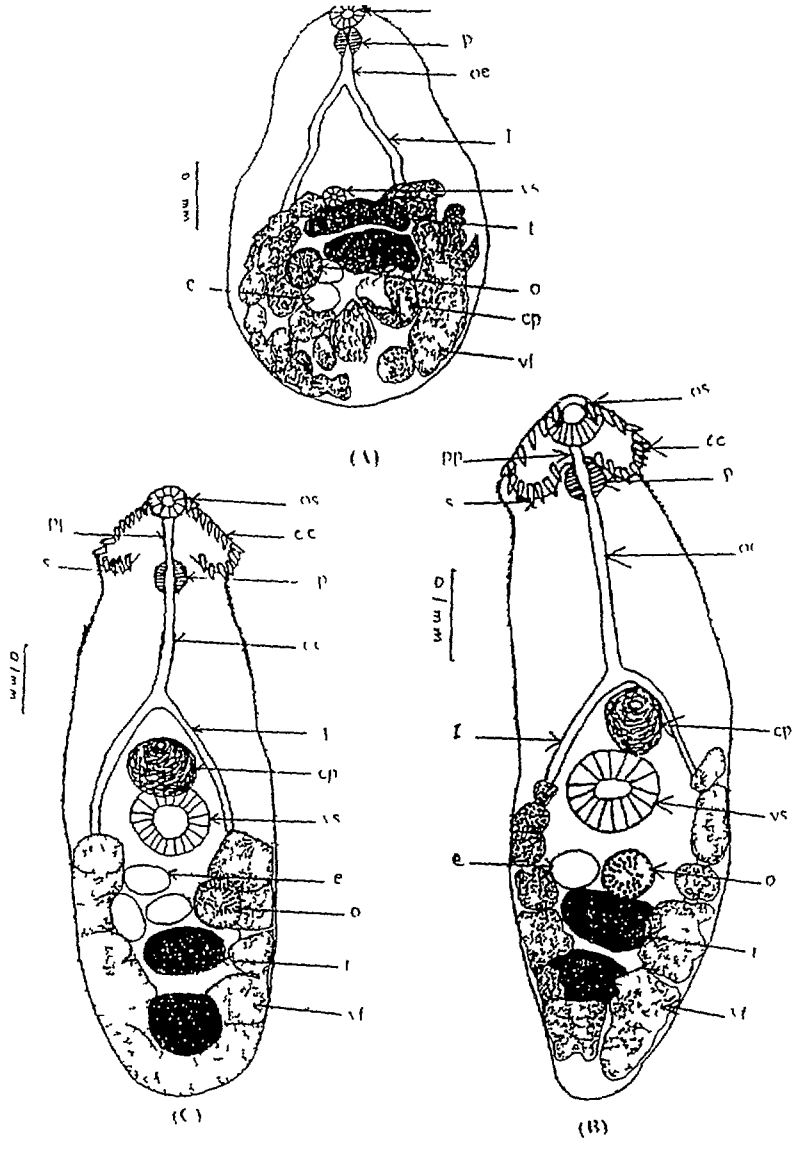

Fig (32) Showing

(A) *Ornithodiplostomum* sp , (X 100)

(B) *Echinochasmus japonicus* , (X 100)

(C) *Echinochasmus beleocephalus* , (X 100)



BEST AVAILABLE COPY

Fig (33) · *Nephrostomum ramosum* .

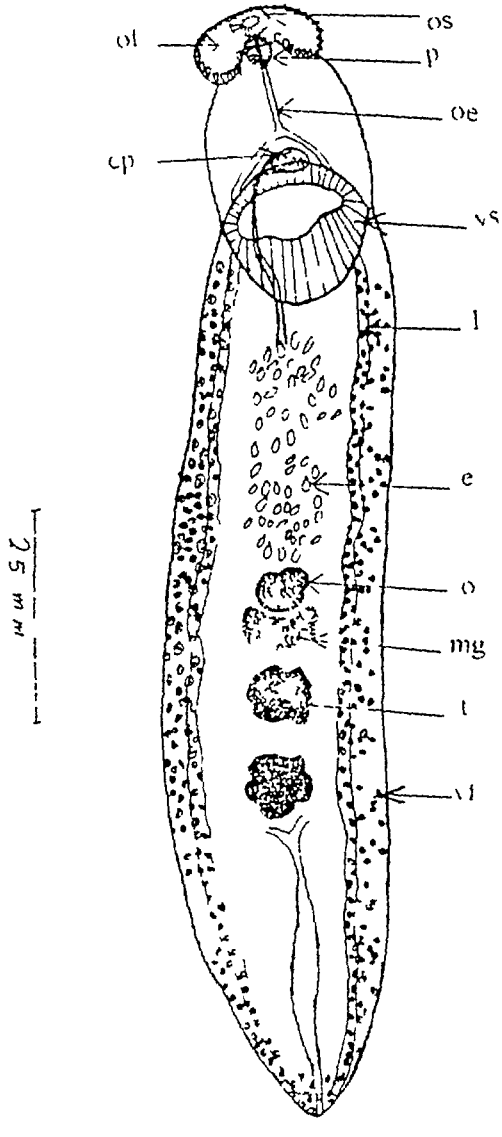

Fig (34) *Nephrostomum ramosum*



Fig (35) · *Aphyaryngistrigia ibis* , (X 40) .

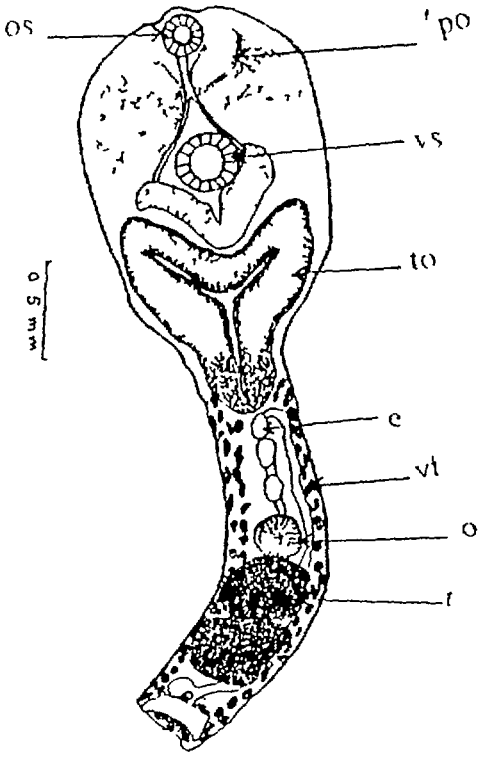

Fig. (36) *Aphyaryngistrigia ibis* , (X 40) .

6- Morphologic characters of the investigated trematodes .

Family Prohemistomatidae

Prohemistomum vivax (**Sonsin 1892**) Fig (37 - A) and Fig (38 - A)

The parasite was recovered from the small intestine of experimentally infected pupies and kittens as well as from chickens, ducklings, squabs, quails, herons and moorhens with metacercariae from Tilapia species and *Clarias lazera*

Morphology

The flukes was oval, some-what tapering at both ends The body was spinose and the spines were prominant on the ventral surface to the edges of tribocytic organ beacoming less numerous toward the posterior end It measured 1 15 - 1 4 mm in length and 0 52 - 0 625 mm in maximum width The oral sucker was ovoid in shape and measured 0 068 x 0 090 mm while the ventral sucker nearly equal the oral sucker and measured 0 058 x 0 080 mm and located just anterior to the organof brands Prepharynx absent but pharynx was nearly oval and measured 0 066 - 0 087 mm in length Oesophagus measured 0 065- 0 072 mm long The intestinal caeca were easly detected till the postacetabular part of the worm,then were completely hidden by the vitelline follicles The testes were globular, smooth nearly equal in size,tandem in location and measured 0 120 - 0 200 mm in diameter Cirrus

pouch was well developed and measured 0 52 - 0 65 mm in length Ovary was globular, submedianin postion and measured 0 088 mm (mean) in diameter Vitelline follicles were fairly large confined to postacetabular region The uterus contained few numbei of eggs which were round in shape, thin shelled and measuied 0 078 x 0 089 mm in diameter

Mesostephanus appendiculatus **(Ciurea , 1916)** Fig (37 - B) and Fig (38 - B)

The parasite was collected from the small intestine of experimentally infected pupies and kittens as well as chicken , ducklings, squabs, quails, herons and moorhens on metacercariae from Tilapia species and *Clarias lazera*

Morphology

The body was linguiforshape, slighlty concave behined the middle, posteriorly it was narrowed and protruded into small dorsoterminalappendage The body covered with spines which were numerous anteriorly The fluke measured 1 23 - 1 7 mm in length and 0 55 - 0 68 mm in width The oral sucker was subterminal and measured 0 08 - 0 093 mm in diameter Prephaiynx absent Pharynx was short and measured 0 064 - 0 09 mm in diameter followed by oesophagus which wasshort and measured 0 045 - 0 065 mm in length Ventral

sucker situated just anterior to the tribocytic organ and measured 0 052 - 0 068 mm in diameter Intestinal caeca were simple, nearly stright, thick walled (double thickenss of oesophagus), swollen and their course could not be traced postacetabular and completely hidden by thevitelline follicles Testes were tandem in location The anterior testis measured 0 153- 0 240 mm in length and 0 19 - 0 25 mm in width, while the posterior testis was0 18 - 0 24 mm in length and 0 198 - 0 26 mm in width Vaginal sphincter was prominant The ovary located posteriolateral to the anterior testis and measured 0 09- 0 105 mm in diameter Vitelline follicle were fairlylarge confined to the posterior half of the body commencing at or near the level of acetabulum and not introducing into caudal appendage The uterus extend from the middle of the fluke till the common genital porewhich opened in the caudal appendage The later contain the vaginal shpencter The eggs were ovoid, thin shelled,few in number, being up to 5 eggs per parasite andmeasured 0 11 x 0 063 mm Cirrus pouch was well developed and measured 0 39 - 0 54 mm in length

Mesostephanus fajardensis **(Price, 1934)** Fig (37 - C) and Fig (39 -A)

The parasite was collected from the small intestine of chickens ducklings, squabs and quails experimentally fed onencysted metacercariae from Clarias lazera (*Clarias lazera*) Also squabs fed on Tilapia species cyst revealed this parasite



Fig 37 Showing :

A- *Prohemistomum vivax* , (X 40)

B- *Mesoste appendiculatus* , (X 4)

C- *Mesostephanus fajardensis* , (X 40)

D- *Mesostephanus flapi* , (X 10)

E- *Paracenogonimous ovatus*, (X 40)

F- *Holosteph volgensis*, (X 100)

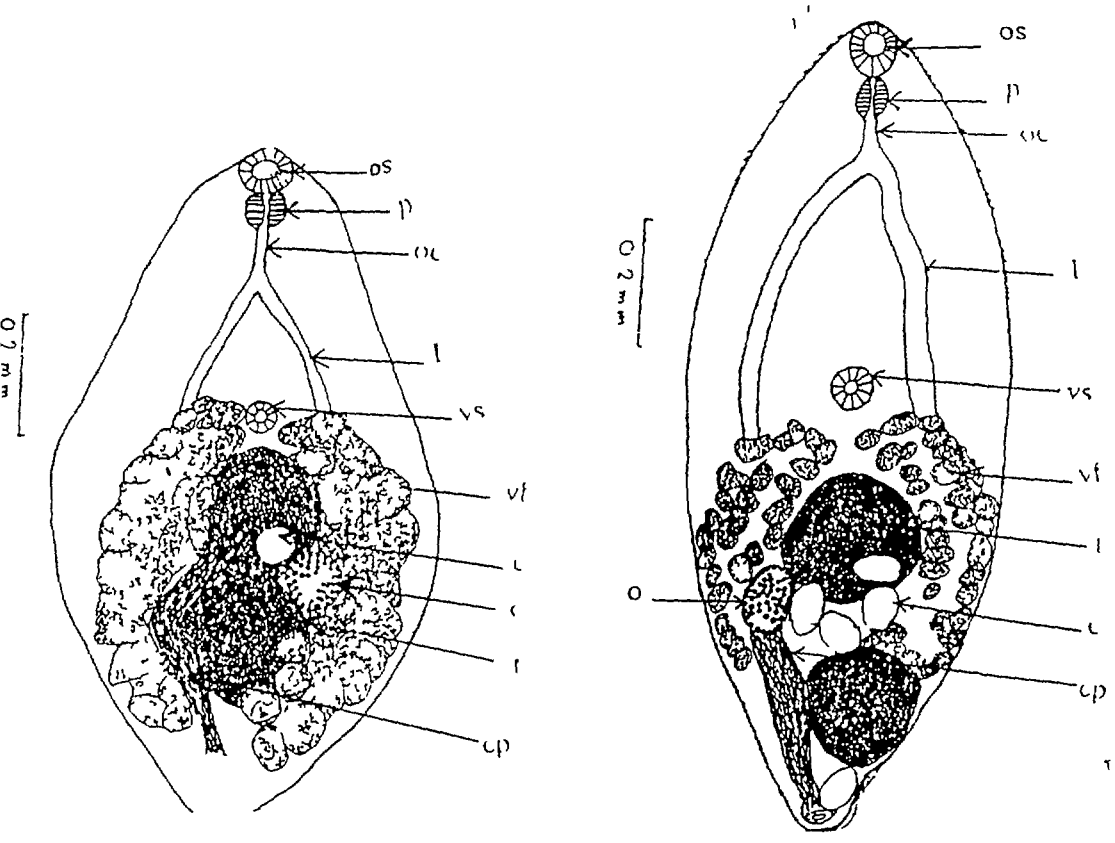

Fig 38 Showing

A- *Prohemistomum vivax*

B- *Mesoste appendiculatus*

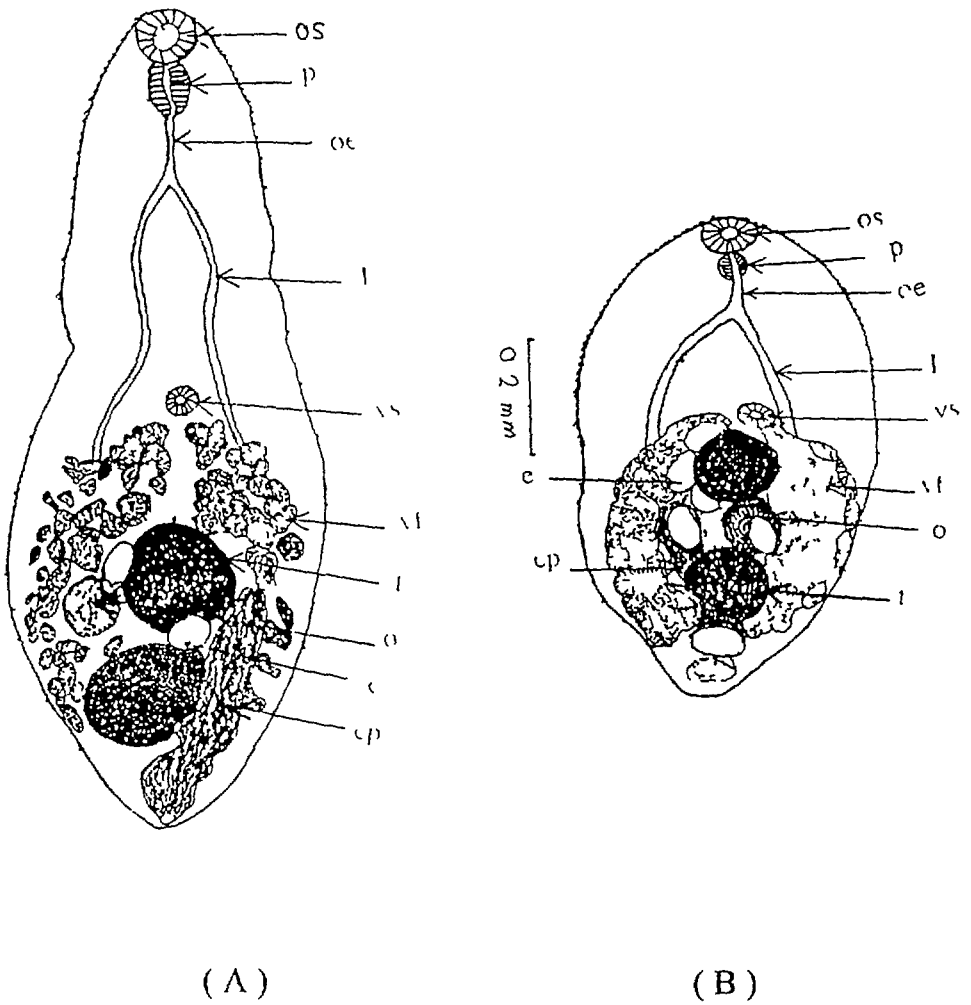

Fig 39 Showing

A- *Mesostephanus fajardensis*

B- *Mesostephanus flapi*

Family Heterophyidae

1- *Heterophyes aequalis* (Looss, 1902) Fig (40-A) and Fig (41-A)

The adult worms wobtained from the small intestine of experimentally infected puppies and kitten as well as from herons with metacercariae from Tilapia species

Morphology

A minute pear shaped distomal worm, cowith scale like spines which were numerous anteriorly and measured 0 40 - 0 6 mm in length and 0 180- 0 28 mm in maximum width Oral sucker subterminal and measured 0 038 - 0 046 mm in diameter Prepharynx measured 0 038 - 0 050 mm in length Pharynx measured 0 030 - 0 040 mm length and 0 028 - 0 033 mm in width The oesophagus measured 0 030 - 0 033 in length The intestinal caeca was short and trerminated at the level of the ovary The ventral sucker was developed and situated near the middle of the body and measured 0 040 - 0 060 mm in diameter The gonotyl was small located posterio lateral to the acetabulum and measured 0 028 - 0 035 mm indiameter Two testes were nearly globular, nearly similar and lay side by side in the caudal region The right one measured 0 050 - 0 064 in length and 0 076 - 0 081 mm in width While the left one measured 0 041 - 0 046 mm in length and 0 076 - 0 080 mm in width The ovary was large subglobular and located infront of testes and measured 0 058 - 0 068 x 0 046 - 0 056 mm The vetilline gland consisted of large follicles at ovario testicular zone The uterus was coiled in the area extended from the acetabulum to the testes Uterine eggs were very small, yellowish brown in colour with thick shell and were operculated



Fig (40) Showing

A- *Heterophyis aequals*, (X 100)

B- *Heterophyis dispar* , (X 100)

C- *Pygidiopsis genata* , (X 100)

D- *Pygidiopsis summa*, (X 100)

E- *Centrocestus armatus*, (X 100)

F- *Ascocotyl mcintochi*, (X 100)

G- *Metagonimus yokojawai*, (X 100)

2- *Heterophyes dispar* (Looss, 1902) Fig (40 - B) and Fig (41 - B)

The parasite were obtained from the smalintestine of herons experimentally infected with metacercariae from Tilapia species

Morphology

The flukes were pear in shape, their bodies covered by spines wwere numerous anteriorly, and measured 0 4 - 0 86 mm in length and 0 21 - 0 40 mm in maximum width Oral sucker was subterminal and measured 0 060 - 0 078 mm in diameter Prepharynx was short and measured 0 029 - 0 04 mm long Pharynx wassmall and measured 0 05-0 06 mm in diameter Oesophagus was somewhat long and measured 0 093 - 0 104 mm in length Intestinal caeca extended till reach the posterior end of the body The ventral sucker larger than the oral one and measured 0 013-0 156 mm in diameter The gonotyl located posteriolateral to acetabulum and measured 0 11 - 0 132 mm in diameter Testes symmetrical situated at the posterior extremity andmeasured 0 21 x0 18 mm in average size Ovary rounded, situated submedian,pretesticular and measured 0 09-0 102 mm in diameter The vitelline glands appeared as large follicles in the lateral area of the ovario-testicular zone Uterus accupied the area between acetabulum and testes It contain numerous number of minute eggswhich were embryonated yellowish brown in colour, thick shelled and operculated It measured 0 018 x 0 011 mm

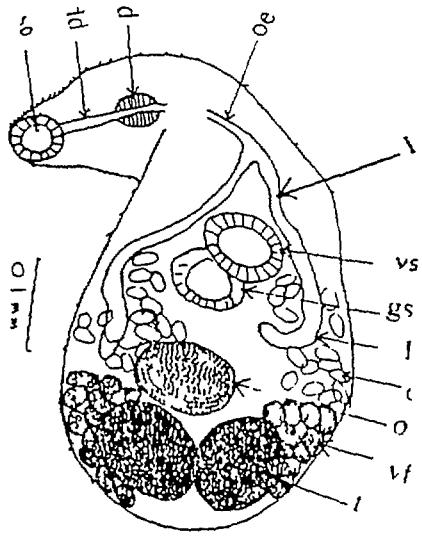

(B)

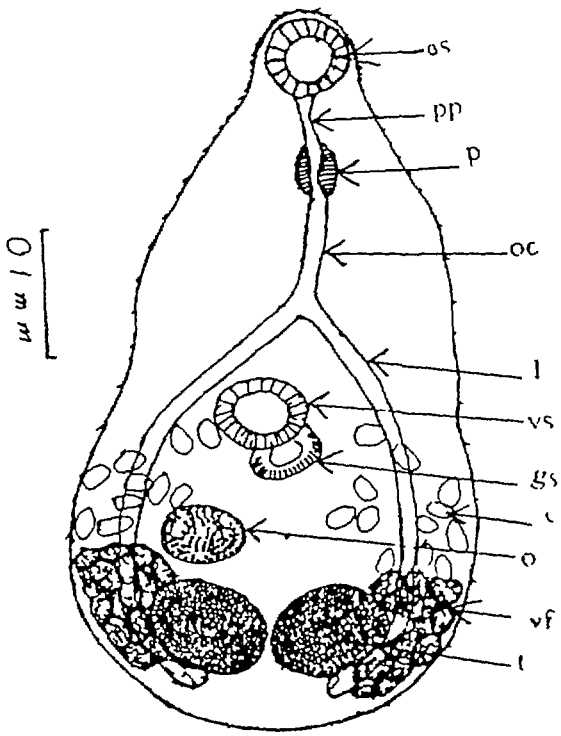

(A)

Fig 41 Showing

A- *Heterophyes equalis*

B- *Heterophyes dispar*

GenusPygidiopsinae

1- *Pygidiopsis genata* (Loose, 1907)

The parasites were obtained fthe small intestine of pupies and kitten as well as from herons, squabs and baby chicks experimentally fed on metacercariae from Tilapia species

Morphology

The body was small flattened , pyriform and measured 0 28 -0 42 mm long and 0 15- 0 21 mm wide The body covered with spines which decreased toward the posterior end Oral sucker was subterminal and measured 0 033- 0 04 mm in diameter Prepharynx was long andmeasured 0 038 - 0 043 mm in length while the oesophagus was short and measured 0 020 - 0 030 mm in length Caeca terminate at the level of the ovary Acetabulum wasround, usually post equaternal and of 0 022 - 0 028 mm in diameter and enclosed to the genital atrium Testes were ovoid, symmetrical transversely located at the posterior end of the body They measured 0 043 - 0 052 x 0 033 - 0 043 mm Ovary was ovoid in its outline submedian, pretesticular and measured 0 032 x 0 038 mm Vesicula seminalis mono or bipartite and located postacetabular Gonotyl appeared anteriolateral to the acetabulum (contained a single row of up to 7 spines) and form with it ventragenital apparatus Uterus coiled between testes and acetabulum contain small sized eggs which measured 0 015 - 0 0163 x 0 011- 0 0108 mm Vitelline follicles were formed from 5-7 large follicles massed together and located laterally in ovariotesticular zone

2-*Pygidiopsis summa* (Onji and Nishio , 1924)

The parasites was obtained from the small intestine of buppies and kitten as well as from herons fed on metacercariaefrom Tilapia

Morphology

The body tapering anteriorly and bluntly ending posteriorly and measured 0 4 - 0 53 mm in length and 0 22 0 29 mm in width (maximum width) The oral sucker subterminal and beset with a single crown of circumoral spines, only in life Itmeasured 0 03 - 0 05 mm in diameter Prepharynx present and measured 0 06 - 0 07 mm in length, pharynx well developed Oesophagusnearly equal to prepharynx and measured 0 07 - 0 081 mm Two caeca extending down to anterior margin of testes and each ended bluntly with a swollen end Ventral sucker transversely elliptical but always a little obliquely and submedially located near the middle portion ofbody It measured 0 06 - 0 078 mm x 0 049 - 0 057 mm Genial apparatus located at the left anteriolateral to the ventral sucker and a little elongated and internally bearing two groups of small spines (right and left one) Gonotyl armed with 7-9 minute spines on the left side and 5-6 on the right side Seminal vesicle bilobed with a constriction, frequently C form and located postacetabular while seminal recepticlesituated anterior to the testes Vitelline follicles fused together and extent near the level of the posterior edge of the ovary Intrauterine eggs were small (0 019 - 0 024 mm long) ovoid to pyriformy relatively thick-shelled with clear and smooth outer surface Testes symmetricaly situated at posterior extremely and measured 0 04-0 052 mm in length and 0 073 - 0 089 mm width Ovary situated medially infront of testes and measured 0 04 - 0 048 mm in diameter Figs (40 - C and 42 - A)

Subfamily Centrocestinae

1- *Centrocestus armatu* (Tanabe, 1926) .Fig (40-E) and Fig (42-C)

The flukes were recovered from small intestine of herons experimentally given metacercariae from Tilapia speceis

Morphology

Body small, flattened oval pyriform or somewhat elongated, vpined and measured 0 3-0 4 mm in length and 0 130 200 mm in&maximum width Oral sucker terminal, with two alternate raws of&42-40 circumoral spines and measured 0 056 x 0 04 mm Prepharynx present and measured 0 02 - 0 030 mm long while pharynx was oval in shape and measured 0 035 x 0 028 mm in average size The oesophagus was measured 0 058 - 0 080 mm in length The intestinal biforcation was nearly at the junction of anteior and middle third of the body and the caeca terminating infront of testes Acetabulum rather small, in middle third of body and measured 0 039 x 0 049 in average size Testes symmetrical, at posterior extremity and varied slightly in size, the left tesits measured 0 036 x 0 058 mm while the right testis measured 0 041 x 0 064 mm in their average size No cirrus pouch Ovary located infront of right testis and measured 0 034 x 0 043 mm in average size Receptaculum seminis large, median and pretesticular and measured 0 03 x 0 058 mm in average size Uterusfilled with eggs which were small, thin, yellow coloured, operculated shell and measured 0 036 x 0 019 mm Vitellaria extending along the lateral margin of the body

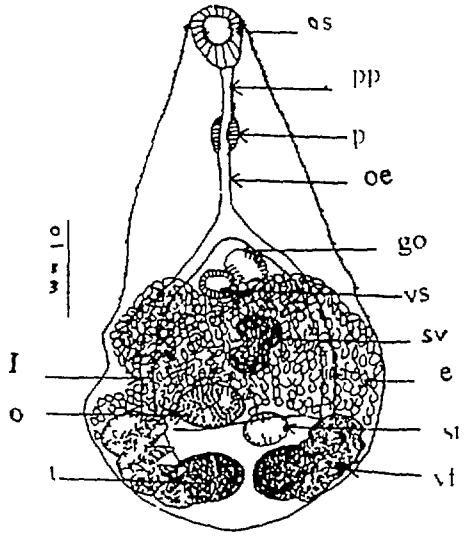

(A)

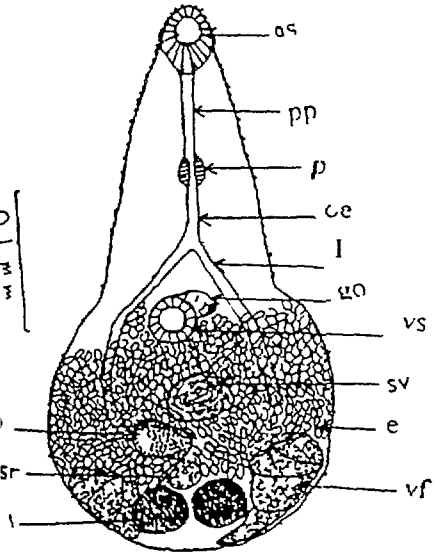

(B)

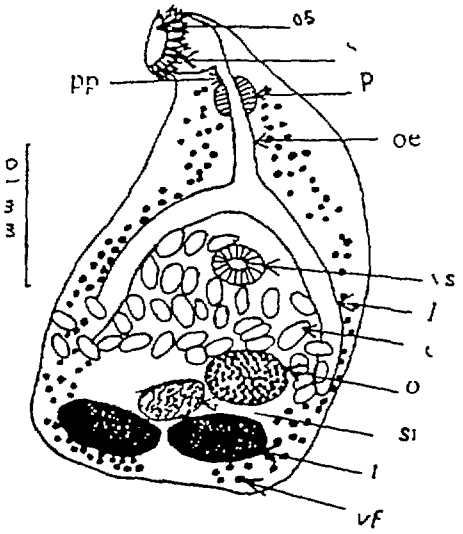

(C)

Fig 42 Showing

A- *Pigidiopsis genata*

B- *Pigidiopsis summa*

C- *Centrocestus armatus*

Subfamily Ascocotylinae

Ascocotyle mcintoshi (Price, 1936) (40-F) and Fig (43-A)

The flukes were obtained from the smallintestine of herons experimentally fed on metacercariae from Tilapia species

Morphology

Body small attenuated anteriorly, round posteriorly, spined and measured 0 25 - 0 39 mm in length and 0 062 - 0 085 mm in maximum width Oral sucker with a crown of spines surmounted by a small conical lobe or lip produced backword into a funnel-shaped blind tube and measured 0 028 mm (mean) Prepharynx measured 0 019 - 0 029 mm in length Pharynx well developed and measured 0 012 - 0 018 mm in diameter Oesophagus measured 0 030 -0 035 mm in length Ventral sucker lied at or near midbody and measured 0 023 - 0 030 mm in diameter Gonotyle located anteriorlateralto ventral sucker Testes symmetrical separated one from the other by excretory vesicle at posterior extremity and measured 0 034 x 0 020 mm in average size Ovary was elongate, oval submedian in location and measured 0 016-0 020 x 0 020 - 0 023 mm Seminalvesicle sigmoid, not divided and located just posterior to the ventral sucker No cirrus pouch Seminal recepticle was and located was large and located medial to the ovary Uterus usually coiled between testes and genital atrium contained small sized eggs Vitellaria extending in
lateral field from the level of acetabulum to near the posterior end of the body Excretory vesicle was characteristically branched

Subfamily Metagonimimae

Metagonimus yokogawai (Katsurada, 1912)

The parasites were obtained from the small intestine experimentally infected animals as well as from herons with metacercariae from *Clarias lazera*

Morphology

The body was small flattened and ellipticashape It measured 0 39 - 0 45 mm length and 0 115-0 13 mm in width and covered by minute spines The oral sucker was subterminalmeasured 0 040-0 059 mm in diameter Prepharynx was short and measured 0 010- 0 019 mm in length pharynx measured 0 055 - 0 069 mm in diameter The oesophagus was somewhat long and measured 0 1 - 0 112 mm in length Intestinal caeca extend till reach the posterior extremity of the body Ventral suckerround in shape and measured 0 083 mm (mean) in diameter Testes were ovoid in shape,nearly horizontal in location and lied at the posterior end of the body The right one was 0 15 - 0 163 x 0 13 - 0 138 mm in average size while the left testis measured 0 168 - 0 179 x 0 13-0 141 mm Seminal vesicle located transversely posterior to the ovary while seminal receptacle found anterior to the ovary Ovary was ovoid in shape, submedian in location and measured 0 055 - 0 063 x 0 078-0 089 mm Vitellaria were small follicles confined to ovariotesticular zone on the lateral side of the body Uterus occupied the space between thetestes and genital atrium containing small sized oval shaped, thick shelled eggs which measured 0 020 - 0 024 x 0 011 - 0 012 mm Figs (40 - G and 43 - B)

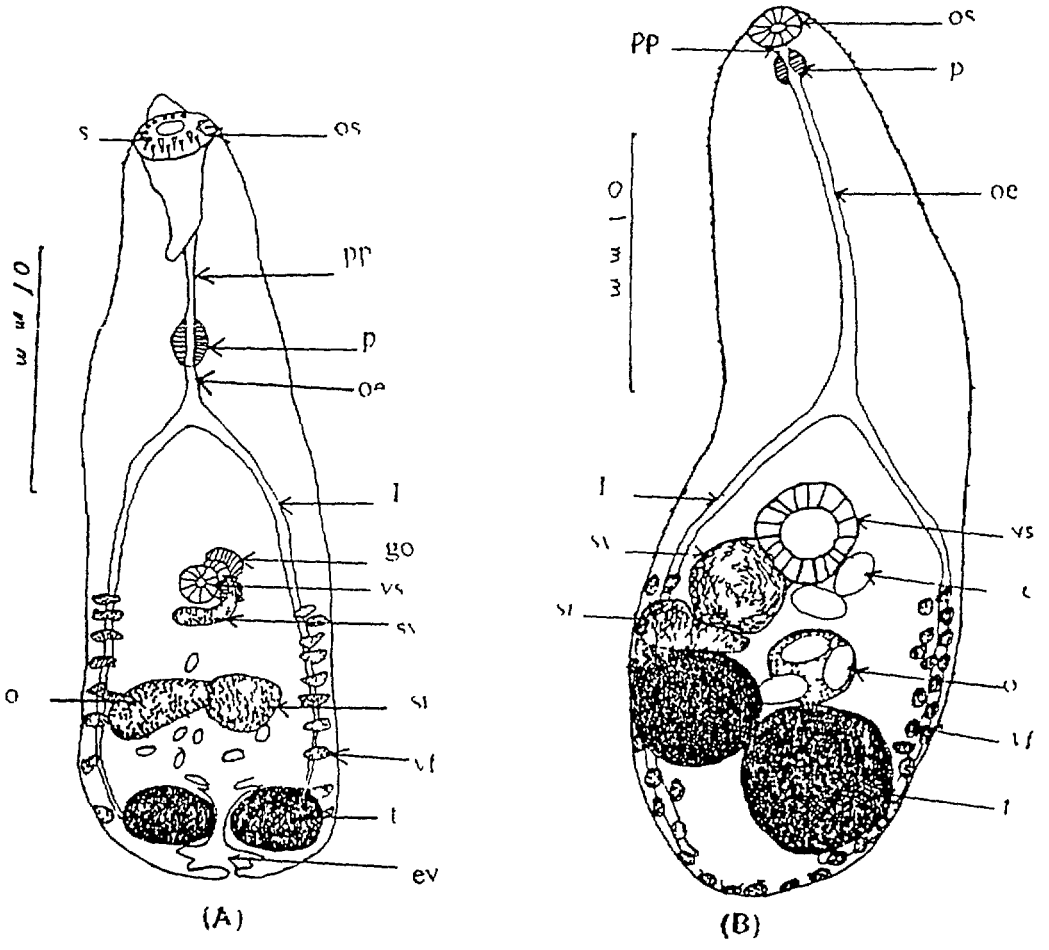

Fig 43 Showing

A- *Ascocotyl mcintochi*

B- *Metagonimas yokajawai*

Genus Haploichis

Haploichis pumilio **Looss, 1899)** Fig (44-A) and Fig (45)

The parasites found in the small intestine of experimentally infected animals heron chicks and squabs with metacercariae from Tilapia species and *Clarias lazera*

Morphology

The body was small elongwith rounded end and its surface covered with spines which decrease towards the posterior end it measured 0 4 - 0 50 mm in length and0 18 - 0 22 mm in maximum width The oral sucker was oval, subterminal and measured 0 031 - 0 04 x 0 038 - 0 048 mm Prepharynxmeasured 0 06 - 0 08 mm in length The pharynx was ovoid and measured 0 026 - 0 035 mm in diameter The oesophagus was longer than the prepharynx and measured 0 090 - 0 105 mm in length The intestinal caeca was somewhat thick and extend to a distance infront of the anterior border of the testis The testis was globular and measured 0 067 - 0 085 in length and 0 073 - 0 090 mm in wide The ovary wasnearly globular and situated just infront of the testis It measured 0 045 - 0 050 mm in diameter Seminal recepticle was large and located anterior lateral to the testis The vitelline follicels were follicular and extended in the ovariotesticular area The ventrogenital sucker appeared immediately posterior to intestinal biforcation The anterior edges of ventral sucker not armed with spines Bipartit seminalvesicle was found and lied dorsoventral to the right of the ventrogenital sucker The uterus occupied the space from posterior part of the body upto the acetabulum contained yellow ovoid eggs which measured 0 02 - 0 026 x 0 012 - 0 015 mm in average size Figs (44 - B and 45)



Fig 44 Showing

A- *Haplorchis pumilio* , (X 100) .

B- *Haplorchis yokojawai*,, (X 100) .

C- *Haplorchis disca* , (X 100)

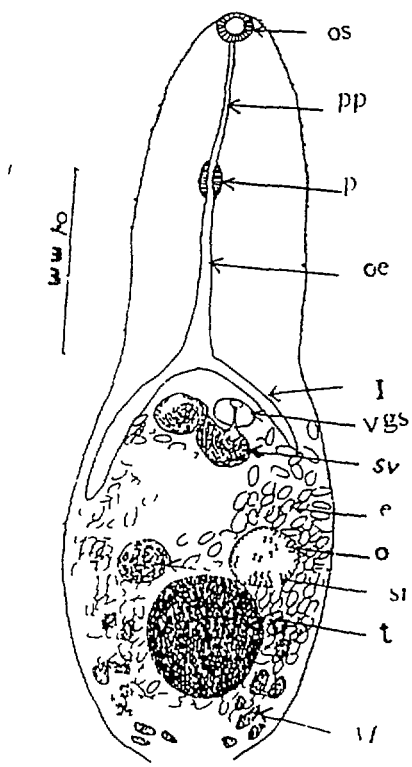

Fig (45) *Haplorchis pumilio*

Haplorchis yokogawi (**Katsuta , 1912**) Fig (44-B) and Fig (50)

The parasite were obtained from small intestine of heron experimentally fed on metacercariaefrom Tilapia species

Morphology

The fluke was small in size, ellieptical in shape and measured 0 35- 0 47 mm0 2 - 0 27 mm The body covered with minute spines The oral sucker was subterminal and measured 0 04 - 0 054 mm in diameter Prepharynx measured 0 03 - 0 038 mm in length Pharynx measured 0 02 - 0 026 x 0 026 - 0 032 mm Oesophagus measured 0 048 - 0 067 mm length Testis was shperical and located near the posterior extremity measured 0 069 - 0 081 indiameter Ovary was round and measured 0 039 - 0 048 mm in diameter Vitelline follicles lied at the posterior part of the body in the ovario testicular zone

Haplorchis disca (**Shalaby , 1982**)

The parasites were found on small intestine of heroexperimentally fed on metacercariae from Tilapia species and *Clarias lazera*

Morphology

The body was small withhind body separated from flattened forebody by a constriction the body covered with spines and measured 0 32 - 0 46 mm in length and 0 135 - 0 22 mm in maximum width Oral sucker was subterminal and measured 0 036 - 0 047 mm in diameter Prepharynx was short andmeasured 0 02 - 0 028 mm long, followed by pharynx which measured 0 02 x 0 015 mm and oesophagus was long

than prepharynx and measured 0 089 - 0 102 mm in length Intestinal bifoication occured at the junction between the fore and hind body extend till reach the ovary then masked by uterus Testis was large round and measured 0 09 - 0 109 mm in diameter Ovary locatedanterio to the testis and measured 0 040 - 0 046 mm in diameter Vitelline follicles located posteriolateral in the disc shape hind body (Figs 44-C and 47)

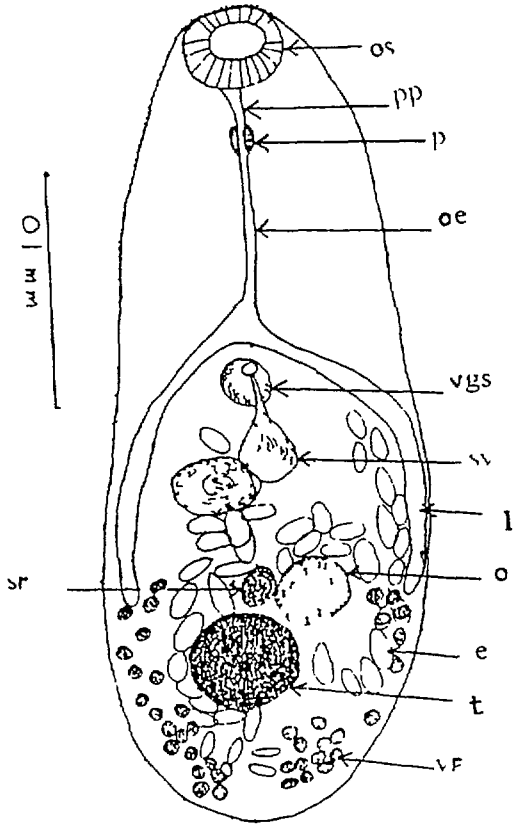

Fig (46) *Haplorchis yokojawai*

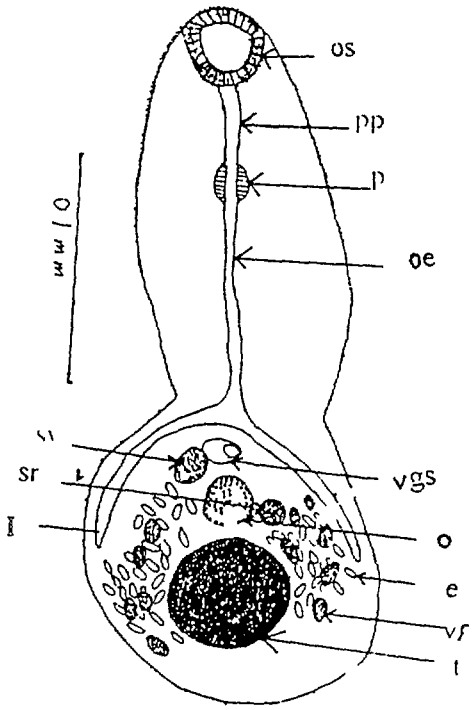

Fig 47 *Haplorchis disca*

7- Results of parasitological examination in Cairo area

Table (29) The encountered encysted metacercaria in Tilapia spp

No of fish	Metacercaria					
	Prohemistomatid	Diplostomatid	Heterophyid	Haplorchid	Clinostomatid	Euclinostomatid
1	+	-	-	-	-	+
2	+	+	+	-	-	+
3	+	-	-	-	-	-
4	+	+	-	-	-	-
5	+	-	-	-	-	-
6	+	-	-	-	-	-
7	+	+	+	+	-	-
8	+	+	+	-	-	-
9	+	-	-	-	-	-
10	+	-	-	-	-	-
11	+	+	-	-	-	+
12	+	-	-	-	-	-
13	+	+	-	-	-	-
14	+	+	+	-	-	+
15	+	+	-	-	-	-
16	+	+	-	-	-	-
17	+	-	-	-	-	-
18	+	-	-	-	-	-
19	+	-	-	-	-	-
20	+	-	-	-	-	-
21	+	-	-	-	-	-
22	+	-	-	-	-	-
23	+	-	-	+	-	-
24	+	+	+	-	-	-
25	+	+	-	-	-	-
26	+	+	-	-	-	-
27	+	+	-	-	-	-
28	+	+	-	-	-	-
29	+	-	-	-	-	-
30	+	+	-	-	-	-
31	+	+	+	+	-	-
32	+	-	+	+	-	-
33	+	+	-	-	-	-
34	+	-	-	-	-	-
35	+	+	-	-	-	-
36	+	+	-	-	-	-
37	+		-	-	-	-
38	+	+	-	-	-	-
39	+	-	-	-	-	-
40	+	+	-	-	-	-

Table (30) The prevalence of the encysted metacercaria in the Tilapia spp,

Types of encysted metacercaria	No of the examined fish	No of the infected fish	Percentage
Prohemistomatid	40	40	100 0
Diplostomatid	40	21	52 5
Heterophyid	40	7	17 5
Haplorchid	40	4	10 0
Euchinostomatid	40	4	10 0

Table (31) The prevalence of infection with the encysted metacercaria in Tilapia spp

Type of infection	Total examined fish	No of infected fish	%
Single infection	40	16	40 0
Mixed infection with two types of encysted metacercariae	40	17	42 5
Mixed infection with more than two types of encysted metacercariae	40	7	17 5

Table (32) The prevalence of the encysted metacercariae in different regions of Tilapia spp

Types of encysted metacercariae	Head region		Trunk region		Tail region	
	No of infected fish	%	No of infected fish	%	No of infected fish	%
Prohemistomatid	16	40 0	17	42 5	37	92 5
Diplostomatid	20	50 0	10	25 0	11	27 5
Heterophyid	1	2 5	2	5 0	7	17 5
Haplorchid	-	0 0	1	2 5	4	10 0

8- Results of parasitological examination of Tilapia spp in Aswan area

Table (33) The prevalence of infection with encysted metacercaria of Tilapia spp at Aswan area (High-Dam and Upper Egypt)

Type of fish	No of examined fish	No of infected fish	Prevalence
Tilapia nilotica	29	14	48 27 %
Tilapia aurea	11	4	36 36 %
Total	40	18	45 00 %

Table (34) The prevalence of the encysted metacercariae of Tilapia spp at Aswan (Naser Lake and Upper Egypt)

Type of infection	Total examined fish	No of infected fish	Prevalence
Single infection	40	16	40 00 %
Mixed infection with two types of encysted metacercariae	40	1	2 50 %
Mixed infection with more than two types of encysted metacercariae	40	1	2 50 %

Table (35) The prevalence of different species of encysted metacercariae in Tilapia spp at Aswan

Types of encysted metacercaria	No of the examined fish	No of the infected fish	Prevalence
Prohemistomatid metacercariae	40	16	40 00 %
Heterophyid metacercariae	40	1	2 50 %
Clinostomatid metacercariae	40	2	5 00 %
Euclinostomatid metacercariae	40	3	7 50 %

Table (36) The prevalence of encysted metacercariae in different regions of Tilapia spp at Aswan area (High-Dam and Upper Egypt)

Region	Types of encysted metacercariae											
	Diplostomatid			Heterophyid			Clinostomatid			Euclinostomatid		
	1	2	3	1	2	3	1	2	3	1	2	3
Head	40	13	32 5%	40	1	2 5%	40	-	00%	40	-	0 0 %
Trunk	40	4	16 0%	40	-	00 /	40	-	00%	40	-	0 0 %
Tail	40	3	7 5%	40	-	00%	40	-	00%	40	-	0 0 %
Branchial cavity	40	-	00	40	-	00	40	2	5 0	40	-	0 0 %
Kidneys	40	-	00 /	40	-	00	40	-	00%	40	3	7 5 %

1- Number of examined fish

2- Number of infected fish

3- Prevalence of infected fish

Table (37) The prevalence of encysted metacercariae infection in relation to Tilapia spp and weight of examined fish at Aswan area (High-Dam and Upper Egypt)

Weight	Species of fish					
	Tilapia nilotica			*Tilapia aurea*		
	1	2	3	1	2	3
Over than 100 gm	5	2	40 0 %	- ve	-	00 0 %
Over than 150 gm	6	3	50 0 %	1	-	00 0 %
Over than 200 gm	7	4	57 1 %	2	1	50 0 %
Over than 250 gm	5	4	80 0 %	1	1	100 0 %
Over than 300 gm	3	1	33 3 %	3	1	33 3 %
Over than 350 gm	1	1	100 0 %	3	1	33 3 %
Over than 400 gm	2	1	50 0 %	1	-	00 0 %
Total	29	16	55 17 %	11		

9- Results of parasitological examination of muscle of Tilapia for encysted metacercariae in Manzala Lake :

Table (38) The prevalence of infection with encysted metacercaria of Tilapia spp at Aswan area (High-Dam and Upper Egypt)

Type of fish	No of examined fish	No of infected fish	Prevalence
Tilapia nilotica	15	3	20 00 %
Tilapia zilli	23	10	43 47 %
Tilapia aurea	12	7	58 33 %
Total	50	20	40 00 %

Table (39) The prevalence of Heterophids encysted metacercariae in different regions of body in three species of Tilapia in Manzala Lake

Type of fish	Heterophide encysted metacercariae								
	Head			Trunk			Tail		
	N	I	%	N	I	%	N	I	%
Tilapia nilotica	3	1	33 33	3	-	00 00	3	1	33 33
Tilapia zilli	10	4	40 00	10	2	20 00	10	10	100 00
Tilapia aurea	7	1	14 28	7	1	14 28	7	6	85 70
Total	20	6	30 00	20	3	15 00	20	17	85 00

N Total Number of fishes

I Number of infected fish

% Prevalence

Table (40) The prevalence of heterophid encysted metacercariae

Weight	*Tilapia nilotica*			*Tilapia zilli*			*Tilapia aurea*		
	N	I	%	N	I	%	N	I	%
Less than 50 gm	-	-	-	4	-	-	-	-	
Over 50 gm	10	1	10	19	10	52 6	9	5	
Over 100 gm	4	1	25	-	-	-	2	1	
Over 150 gm	-	-		-	-	-	1	1	
Less 200 gm	1	1	100	-	-	-	-	-	
Total	15	3		23	10		12	7	

N Total Number of fishes

I Number of infected fish

% Prevalence

Table (41) The average of the weight (W) in grams and length (L) in cm of infected Tilapia spp

Type of fish	No of examined fish	No of infected fish	Prevalence
Tilapia nilotica	15	3	145 20 X 20 00
Tilapia zilli	23	10	67 63 X 15 50
Tilapia aurea	12	7	94 93 X 17 07

Table (42) The weight in gm and the length in cm of examined fish

Tilapia nilotica		*Tilapia zilli*		*Tilapia aurea*	
No	weight X Length	No	weight X Length	No	weight X Length
1	220 00 X 22 0	1	94 00 X 16 0	1	67 00 X 15 5
2	91 00 X 18 0	2	37 27 X 15 0	2	91 82 X 17 0
3	130 00 X 20 0	3	63 42 X 16 0	3	154 50 X 21 0
4	125 00 X 20 0	4	64 10 X 15 0	4	104 00 X 17 0
5	57 50 X 17 0	5	72 98 X 16 0	5	70 24 X 16 5
6	77 29 X 16 5	6	71 61 X 16 0	6	76 35 X 14 5
7	148 50 X 21 0	7	64 42 X 15 0	7	98 46 X 17 5
8	104 00 X 18 0	8	46 85 X 15 0	8	95 41 X 15 0
9	67 41 X 16 5	9	90 36 X 17 5	9	104 44 X 19 0
10	78 00 X 17 0	10	84 20 X 17 0	10	63 00 X 14 0
11	80 00 X 14 0	11	68 05 X 16 0	11	75 40 X 16 0
12	76 17 X 17 0	12	63 54 X 15 0	12	88 37 X 18 0
13	66 75 X 16 0	13	63 95 X 14 5		
14	93 70 X 14 5	14	69 00 X 15 0		
15	51 50 X 15 0	15	66 70 X 16 0		
		16	57 25 X 15 0		
		17	61 00 X 14 0		
		18	65 00 X 15 0		
		19	65 00 X 16 0		
		20	51 40 X 15 5		
		21	49 80 X 15 5		
		22	56 00 X 14 0		
		23	40 40 X 15 0		

10- Results of parasitological examination in Alexandria area

Table (43) Prevalence of fish infection with Heterophyid (*Pygidiopsis genata* and *Haplorchis pumilio*) metacercariae in Abokir region in Alexandria

Sample time	No of ex fish	Mugil sp		No of ex fish	Siganus sp		No of ex fish	Sharegesh sp	
		P g	H p		P g	H p		P g	H p
October 1994	274	170	27	54	10	8	3	1	0 0
November 1994	69	42	0 0	34	17	14	10	3	0 0
December 1994	99	23	0 0	10	1	0 0	6	0 0	0 0
Total	442	235	27	98	28	2 2	19	4	0 0
% infected		53 2	6 1		28 2	22 2		21 1	0 0

Table (44) Prevalence of fish infection with Heterophyid (*Pygidiopsis genata* and *Haplorchis pumilio*) metacercariae in El-Max region in Alexandria

Sample time	No of examined fish	Tilapia sp		No of examined fish	Mugil sp		No of examined fish	Siganus sp		No of examined fish	Sharegesh sp	
		P g	H p		P g	H p		P g	H p		P g	H p
October 1994	151	85	12	161	126	18	58	25	8	36	13	4
November 1994	97	2	0 0	169	47	0 0	94	94	0	47	5	0 0
December 1994	100	8	0 0	150	13	4	10	10	0 0	10	2	0 0
Total	247	95	12	490	186	22	162	162	8	93	20	4
% infected		38 5	4 9		37 9	4 5			5 0		21 5	4 3

11- Pathological changes in the experimental birds :

Histopathological examination of the intestine of experimental infected squabs with tilapia's muscles revealed that, the lower portion of small intestine showed presence of large parasitic elements which sometimes causing pressure on the epithelium of intestinal crypts Some intestinal villi revealed distruction of their free portion with sever inflammation of lamina propria associated with inflammatory cells mainly lymphocytes and macrophages Parasitic elements were found between intestinal villi causing pressure atrophy associated with decrease in number of mucus glands Fig (48) Sometimes the parasites appear engulfed the epithelium linning of intestinal crypts and other tissue debris Fig (49) The area of parasitic infestation revealed sever inflammatory reaction characterized by aggregation of inflammatory cells with proliferation of connective tissue in the lamina propria of intestinal villi Focal areas of edema and sever dilatation of the blood vessels of subepithelial layer between the intestinal glands were notice Sometimes intestine revealed excessive distruction of the intestinal crypts , filled with basophilic necrotic debris, while the reactive changes were mild characterized by aggregation of macrophages and lymphocytes

12- Pathological changes in laboratory animals .

Mature worms were developed in the intestinal tract of Lab animal (pupies , kettens and mice) Adult paraistes were seen in the intestinal lumen or attached to the wall 7 - 10 day after

inoculation of metacercariae Parasites caused distruction to the intestinal mucosa and sloughing of their epithelium Epithelial surface were replaced by necrotic debris , mucus , connective tissue and numerous inflammatory cells

In most examined case the parasite invade the intestinal wall and appeared between the intestinal glands Mild tissue reaction and excessive metaplastic proliferation of the intestinal epithelium to mucous cells were determine The reactive changes were seen mainly in the intestinal crypts characterized by distruction of covering epithelium with presence of thin layer of mucous cells , submucosal connective tissue proliferation , leucocytic aggregation mainly of lymphocytes and macrophages together with few numbers of melanin carying cells

Laboratory animals sacrified after 10 days , moderate tissue reactions were noticed characterized by atrophy and decrease of number of mucous cells in areas of parasitic elements , fibroblastic proliferation which appear replaced the intestinal mucous , numerous inflammatory cells mainly macrophages , lymphocytes and small size eosinophilic cells Point of entery of the parasite in intestinal crypts revealed distruction of mucosa and oedema Infestation of the intestinal wall with great number of the parasitic elements

At early stages of development of the parasitic reaction of the intestine was characterized by vascular dilation hyperplasia and hypertrophy of mucous cells Excessive accumulation of tissue debris especially on the mucosa of lower intestine

Fig 48 · Small intestine of bird infected with Tilapia'smuscles (lower portion) showing Two mature parasites causing pressure atrophy, necrosis and inflammatory changes in the intestinal crypts assofiated with decrease of number of mucus glands Stain (H & E) &x . 125

Fig 49 Lower intestine of pigeon containing mature parasite phagocytosed necrotized tissue fnd tissue debris Notice the cutinized mouth opening (arrow) passing tissue debris Stain : (H& E) x 250

Histopathological changes in the heron's intestine (infected with Tilapia's muscles) associated with greate number mature parasites within the intestinal lumen or invade the submucosa between mucosal glands More than one species of parasites were seen in intestinal lumen or invade the intestinal crypts to submucosa resulting in various mild pathological reaction Fig (50) In addition to the following, pathological changes which characterized by hyperplastic proliferation of mucus glands at the wall of intestinal crypts especially at the basal portion and in areas neighbouring to attachement of prasite while at the site of the parasite the intestinal villi revealed lake of mucaus glands with necrosis of its epithelial linning Figs (51 , 52) Blood vessels in lamina propria and around the intestinal glands were dilated Few number of inflammatory cells were seen in area of parasitic infestation somtimes the parasite appear small elongated, flattened anteriorly and rounded posteriorly and the uterus is filled with eggs which appeared ovoid, elongated yellowish incolour & unstainable while the other internal structure of parasite appear esinophilic, mild distructive changes also pronunced (Fig 53)

Mature worm of Ascocotyle appear deeply penetrated the intestinal epithelium and localized between the intestinal glands andsitmulate fibrogenetic activity in area of infestation together with few number of inflammatory cells Sometimes Parasitic elements were seen in intestinal lumen or between the intestinal villi revealed clear destructive changes and haemorrhages Fig (53) Sometimes intestine showing sever distruction of the epithelial linning Their crypts displayed excessive haemorrhages and leucocytic infilteration between intestinal glands

Edema in subepithelial area of the intestine Inspite of parasitic elements were not detected basophilic necrotic debris were seen between the intestinal villi and intestinal lumen Intestinal lumen appeared as a bag filled with necrotic debris, haemorrhagic blood and few number of inflammatory cells

Fig 50 Histological section in intestine of heron infested with parasitized Tilapia's muscle display Presence of parasites within intestinal lumen, some are invade the submucosa between the intestinal glands resulting in mild host reaction (arrows).

Stain . (H & E) x 75

Fig 51 Intestine of herons showing hyperplastic proliferation of mucus glands in the intestinal crypts, while at the site the parasitic attachement there was lake of mucus glands (arrow).

Stain : (H & E) X125

Fig 52 Histological section in heron's intestine showing Hyperplasia of mucus glands at intestinal crypts while parasites invade themucosa (arrows) with fibroblastic proliferation and few leucocytic infiltrations. Stain (H & E) x : 125.

Fig 53 Intestine of heron showing Hyperplasia of mucus glands in neighbouring villi, while villi around parasitic elements arrows showing lake of mucus glands Stain · (H & E) x 125.

13- Effect of heat on the viability of EMC

The infected Tilapia species and *Clarias lazera* used in this experimend were classified according to their size into three categories , small medium and as large In Tilapia species the weight ranged from 50 - 90 gm , 100 - 200 gm and 300 - 400 gm for small , medium and large size respectively , while in *Claria lazera* the weight ranged from 100 - 150 gm, 250 - 350 gm and 700 - 800 gm for small , medium and large size fish respectively

From Table (45) it is clear that boiling has a direct lethal effect on the viability of EMC which disappeared completely after 5 minutes for all types of EMC found in small, medium and large sized Tilapia fish and Clarias lazera While boiling for 10 minutes was sufficient to kill all the EMC found on Tilapia fish and *Clarias lazera*

In Tilapia species, frying the whole fish on each side for 5 minutes were sufficient to lose theviability of all types of EMC found in small and medium sized fish and also those of large size except fish weighting 350-400 gm stillhave viable EMC of Prohemistomatide and Haplorchide While frying for 10 minutes on each side were sufficient to kill all types of EMC found in small,medium and large sized fish In *Clarias lazera* frying the muscles on each side for 5 minutes were sufficien to disappear the EMC found in small and medium sized fish, while on the large sized fish the EMC of Prohemistomatide Haplorchide, Diplostomatide and Cyanodiplostomatide still viable but frying for 10 minutes on each side lose the viability of these types of EMC and kill those found in small and medium sized fish

In Tilapia species, grilling the whole fish on each side for 5 minutewere sufficient to loss the viability of EMC found on small sized fish while those lodged in the muscles of medium sized (Prohemistomatidae Haploirchide and Heterophyide cyst) was still viable and this viability were lost by grilling on each side for 10 minutes

Table (45) Effect of heat (bioling, frying and grilling) on the viability of EMC found on infested Tilapia species and *Clarias lazera*

Fish species	Type of recovered EMC	Boiling		Frying		Grilling	
		Time of exposure		Time of exposure		Time of exposure	
		5 min	10 min	5 min	10 min	5 min	10 min
Tilapia species	Prohemistomatide	non	non	V *	non	V * 0	non
	Haploirchide	non	non	V *	non	V * 0	non
	Heterophyide	non	non	non	non	V * 0	non
	Diplostomatide	non	non	non	non	non	non
	Echinostomatide	non	non	non	non	non	non
	Haploirchide	non	non	non	non	non	non
Clarias lazera	Prohemistomatide	non	non	V *	non	-	-
	Haploirchide	non	non	V *	non	-	-
	Diplostomatide	non	non	V *	non	-	-
	Cyanodiplostomatide	non	non	V *	non	-	-

non = not vaible
V = viable
* = in large sized fish
0 = medium sized fish
EMC = encysted metacercariae

Regarding effect of chilling on the viability of encysted metacercariae infested Tilapia species and *Clarias lazera* Table (46) and Figs (54 and 55) revealed that the encysted metacercariae of Tilapia species showing rapid loss of their viability on the second day chilling were belonging to families Diplostomatidae and Echinostomatidae followed by Echinostomatidae , Haplorchidae , Prohemistomatidae and Heterophyyidae metacercariae on the day 5 , 6 and 7 respectively All the recorded number of encysted metacercariae of Prohemisttomatidae , Haplorchidae , Diplostomatidae , Euchinostomatidae and Echinostomatidae were loss their viability completely at 18 17 15 14 8 and 5 day chilling respectively

On the other hand the encysted metacercariae recovered from the infected *Clarias lazera* muscles began to loss their viability on 3rd day (Diplostomatidae) , 4th day (Haplorchidae and Cyanodiplostomatidae) , and 6th day (Prohemistomatidae) of chilling All the present encysted metacercariae of Prohemistomatidae , Haplorchidae , Diplostomatidae and Cyanodiplostomatidae were completely unviable at 14 , 12 , 14 and 16 days post chilling respectively

Table (46) Effect of chilling on the viability of encysted metacercariae found in Tilapia species and *Clarias lazera*

Fish species	Type of the obtained metacercariae	Period of chilling in days																			
		0	1	2	3	4	5	6	7	8	9	10	11	12	13	14	15	16	17	18	19
		V%	V%	V%	V%	V%	V%	V%	V%	V%	V%	V%	V%	V%	V%	V%	V%	V%	V%	V%	V%
Tilapia species	Prohemistomaide	100	100	100	100	100	100	100	90	90	80	80	80	70	60	50	40	20	10	0	0
	Haplorchide	100	100	100	100	100	100	90	80	80	70	60	50	50	40	30	0	0	0	0	0
	Heterophyide	100	100	100	100	100	100	100	90	90	90	80	70	70	60	40	30	10	0	0	0
	Diplostomatide	100	100	90	80	80	80	70	70	60	50	40	40	40	30	10	0	0	0	0	0
	Echinostomatide	100	100	80	60	30	10	0	0	0	0	0	0	0	0	0	0	0	0	0	0
	Euchinostomatide	100	100	100	100	100	60	30	20	0	0	0	0	0	0	0	0	0	0	0	0
Clarias lazera	Prohemistomatide	100	100	100	100	100	100	90	90	80	70	60	40	30	10	0	0	0	0	0	0
	Haplorchide	100	100	100	100	90	80	80	70	60	50	40	10	0	0	0	0	0	0	0	0
	Diplostomatide	100	100	100	80	80	70	60	50	50	40	30	20	10	10	0	0	0	0	0	0
	iplodiplost -omatide	100	100	100	100	90	80	70	50	50	40	40	40	30	30	20	10	0	0	0	0

V% = Viability percent
EMC = encysted metacercariae

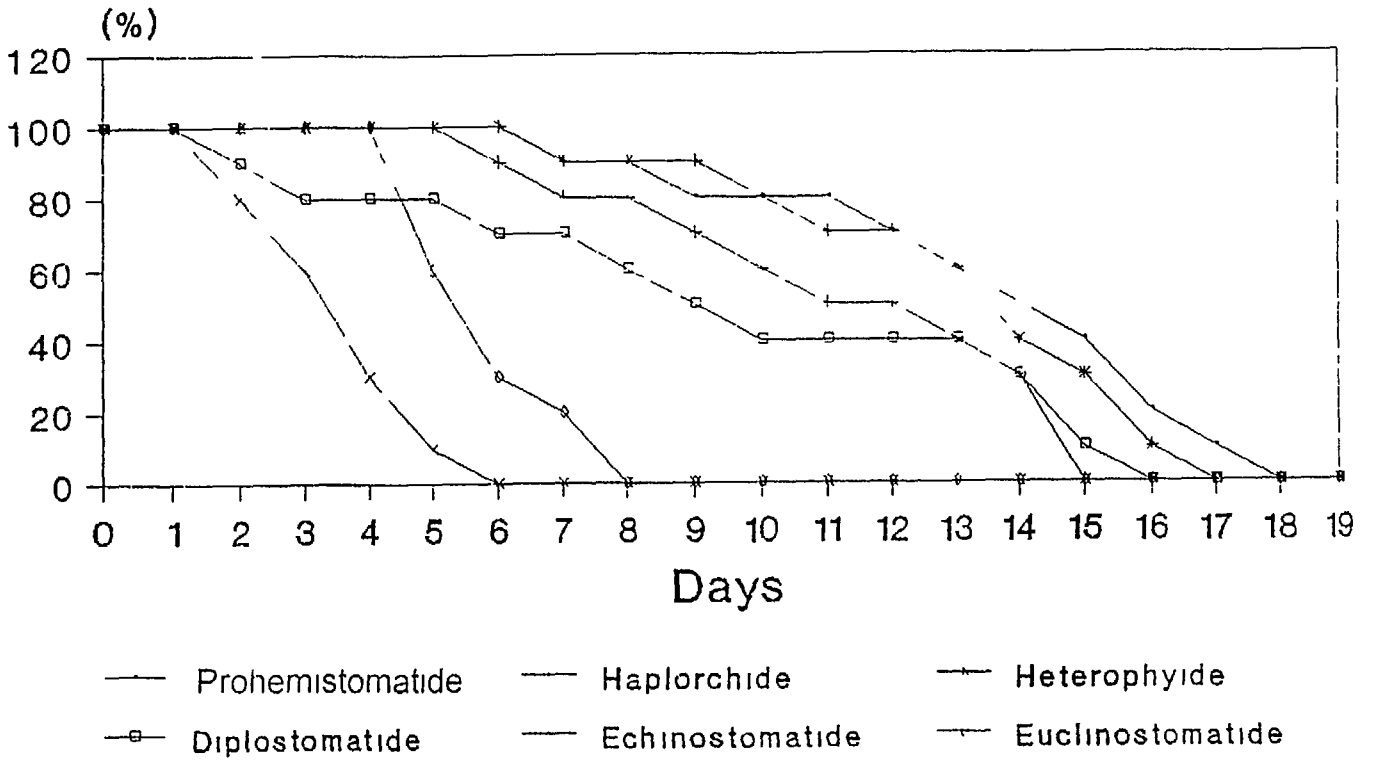

Fig (54) Effect of chilling on the viability (%) of encysted metacercariae found in Tilapia species

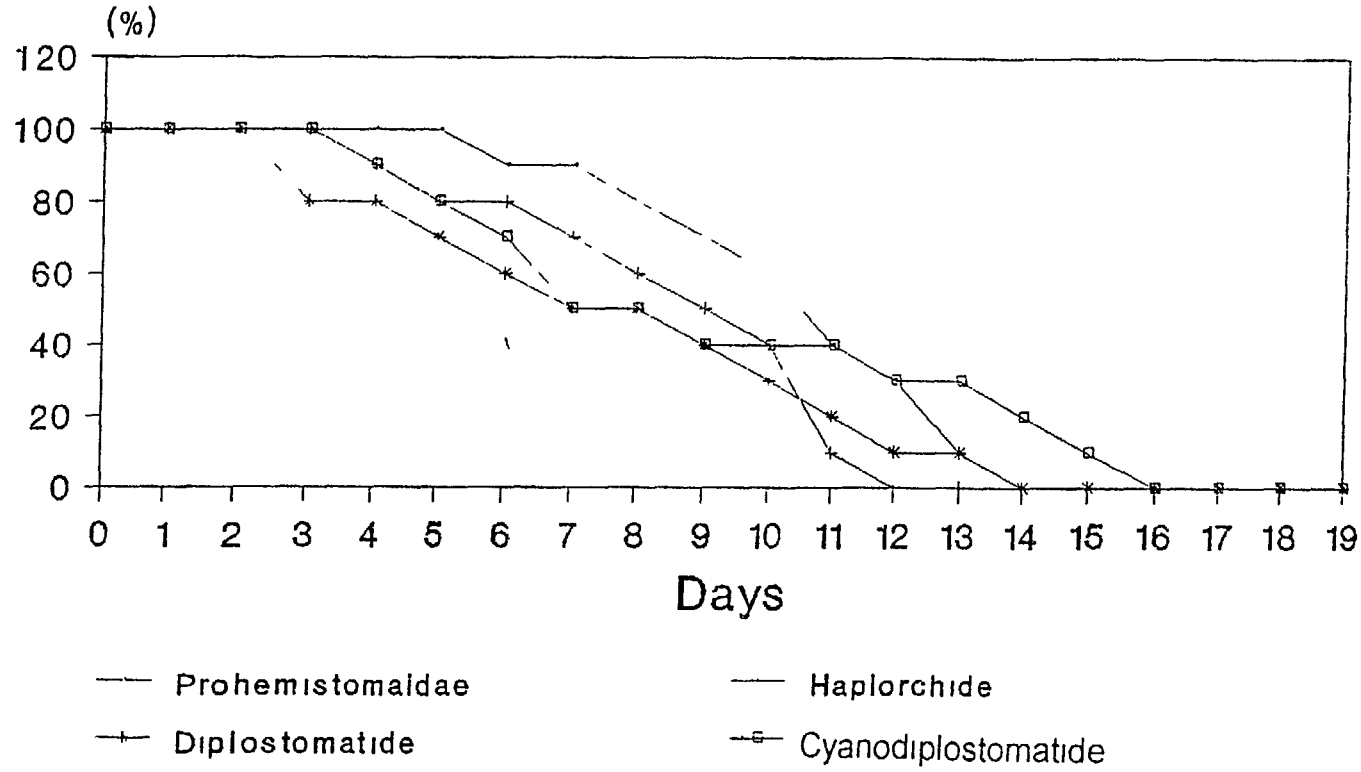

Fig (55) Effect of chilling on the viability (%) of encysted metacercariae found in Nile-catfish (*Clarias lazera*)

Regarding effect of freezing on the viability of encysted metacercariae that recorded from infested Tilapia species, (Table 47) and Figs (56 57 58 and 59) showed that the encysted metacercariae differe in their stability to the lethal effect of freezing depending on freezing degree , type of infested metacercariae and the fishspecies it self In the infected Tilapia species fish , we showed that the encysted metacercariae of Prohemistomatidae lost their viability by freezing at -4° or -5°C , -10°C, -15°C and -20°C after 48 , 32 , 24 and 16 hours respectively Haplorchid metacercariae became unviable following freezing at -4 or -5°C , -10°C , -15°C and -20°C after 40 , 24 , 16 and 16 hours respectively , Heterophyidae encysted metacercariae became unviable following freezing at -4 or -5°C , -10°C , -15°C and -20°C after 40 , 24 , 16 and 16 hour , respectively Diplostomatide metacercariae lost their motility by freezing at -4 or -5°C , -10°C, -15°C and -20°C after 32, 24 16 and 8 hours respectively , Echinostomatidae metacercariae became unviable by freezing at -4 or -5°C , -10°C , -15°C and -20°C after 24, 16, 16 and 8 hours respectively and the encysted metacercariae of Euchinostomatidae lost their viability at -4 or -5°C , -10°C , -15°C and -20°C following freezing at 32 , 24 , 16 and 8 hours respectively

In the infested *Clarias lazera* , Table (47) and Fig (60 , 61 , 62 and 63) illustrated that the encysted metacercariae of Prohemistomatidae lost their motility by freezing at -4 or -5°C, -10°C, -15°C and -20°C after 32, 24, 16 and 8 hours respectively, Haplorchid encysted mftacercariae became unviable after 32,16, 16 and 8 hours followifg freezing at -4 or -5°C -10°C, -15°C and -20°C respectively, the Diplostomatidae cysts lost their motility by freezing at -4 or -5°C, -10°C, -15°C and -20°C after 24 , 16 , 16 and 8 hours respectively and cyanodiplostomatid cysts were non motile by freezing at -4or -5°C, -10°C, -15°C and -20°C after 32, 24, 16 and 16 hours respectively

Table (47) Effect of freezing on the viability of encysted metacercariae found in Tilapia species and *Clarias lazera*

Fish species	types of the obtained metacercariae	Freezing degree at																						
		-4 or -5°C								-10°C						-15°C					-20°C			
		Freezing period in hour								Freezing period in hour						Freezing period in hour					Freezing period in hour			
		0	8	16	24	32	40	48	56	0	8	16	24	32	40	0	8	16	24	32	0	8	16	24
		V%	V%	V%	V%	V%	V%	V%	V%	V%	V%	V%	V%	V%	V%	V%	V%	V%	V%	V%	V%	V%	V%	V%
Tilapia Species	Prohemistomatide	100	100	100	100	80	10	0	0	100	100	80	20	0	0*	100	80	10	0	0*	100	50	0	0*
	Haplorchide	100	100	100	70	20	0	0*	0	100	100	50	0	0*	0	100	60	0	0*	0	100	20	0	0*
	Heterophyide	100	100	80	40	10	0	0*	0	100	100	30	0	0*	0	100	60	0	0*	0	100	30	0	0*
	Diplostomatide	100	100	90	10	0	0*	0	0	100	80	10	0	0*	0	100	20	0	0*	0	100	0	0*	0
	Echinostomatide	100	90	50	0	0*	0	0	0	100	60	0	0	0	0	100	10	0	0*	0	100	0	0*	0
	Euclinostomatide	100	100	100	50	0	0*	0	0	100	60	20	0	0*	0	100	20	0	0*	0	100	0	0*	0
Nile catfish	Prohemistomatide	100	100	90	30	0	0	0*	0	100	80	20	0	0*	0	100	20	0	0*	0	100	0	0*	0
	Haplorchide	100	100	70	10	0	0	0*	0	100	60	0	0*	0	0	100	10	0	0*	0	100	0	0*	0
	Diplostomatide	100	100	50	0	0	0*	0	0	100	40	0	0	0	0	100	10	0	0*	0	100	0	0*	0
	Cyanodiplostomatide	100	100	90	50	10	0	0	0*	100	70	20	0	0*	0	100	40	0	0*	0	100	0	0*	0

V% = viability percent
0* = the larvae within the cyst begin to be distructed after thawing
EMC = encysted metacercariae

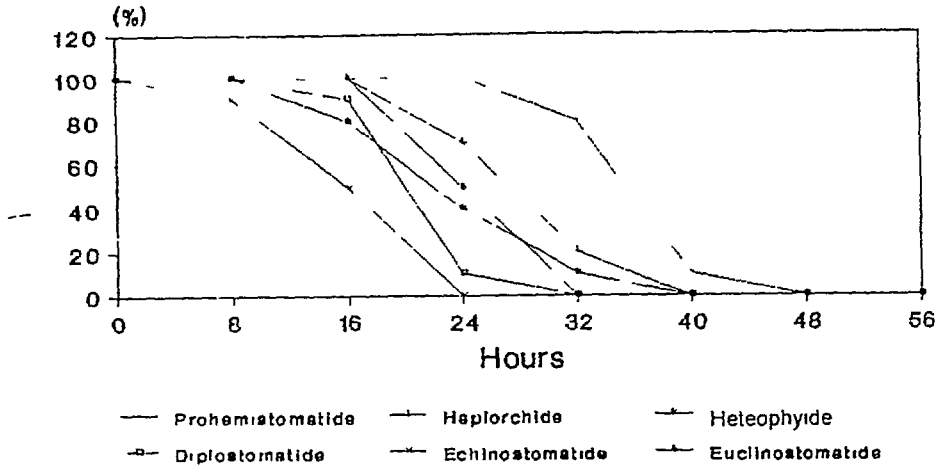

Fig (56) Effect of freezing at -4 or -5°C on the viability (%) of encysted metacercariae found in Tilapia species

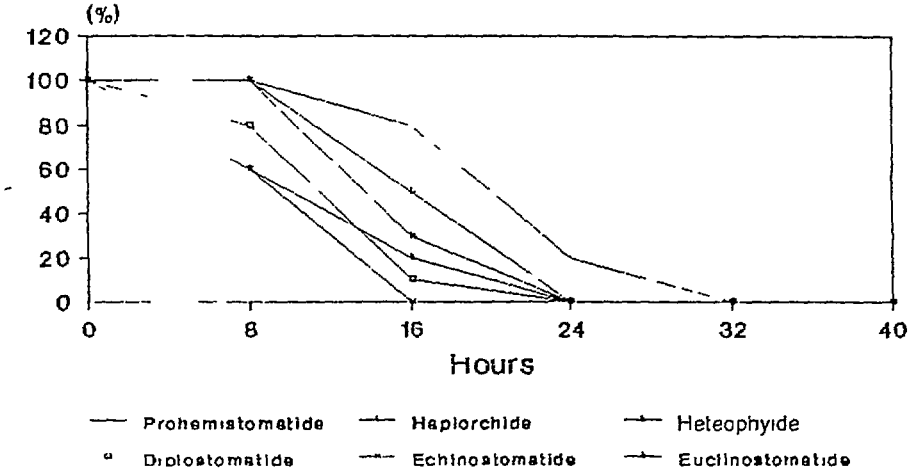

Fig (57) Effect of freezing at -10°C on the viability (%) of encysted metacercariae found in Tilapia species

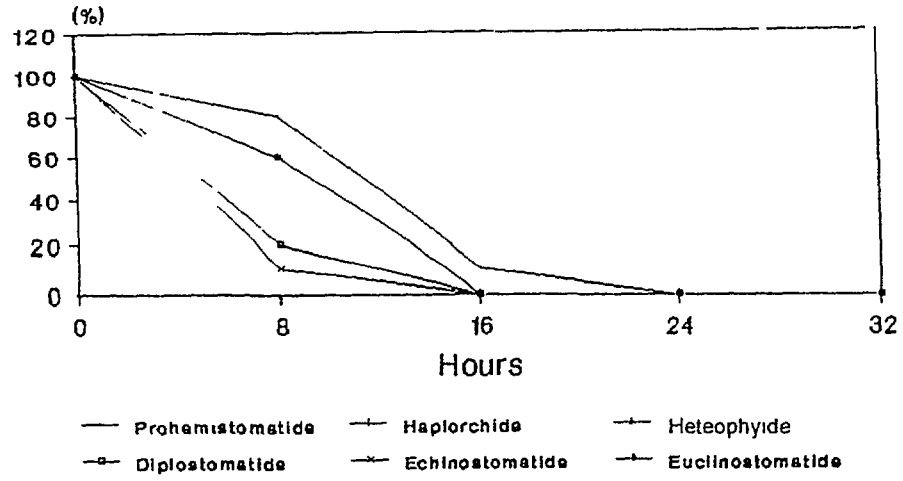

Fig (58) Effect of freezing at -15°C on the viability (%) of encysted metacercariae found in Tilapia species

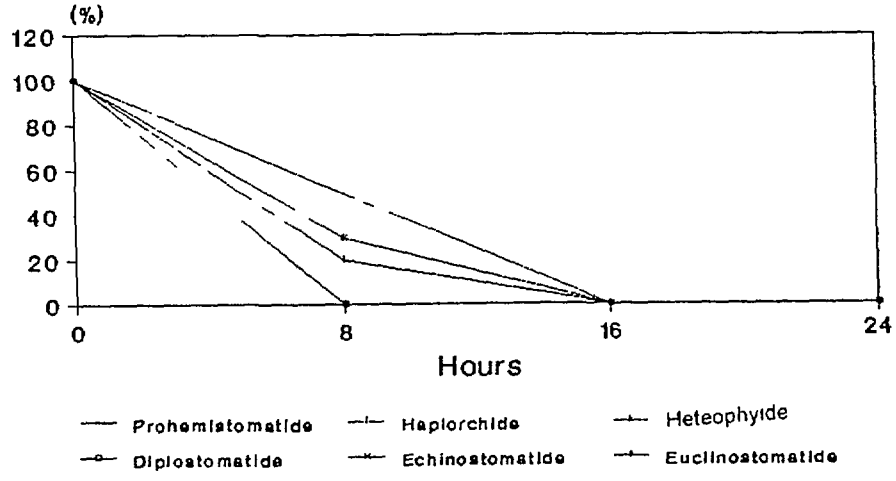

Fig (59) Effect of freezing at -20°C on the viability (%) of encysted metacercariae found in Tilapia species

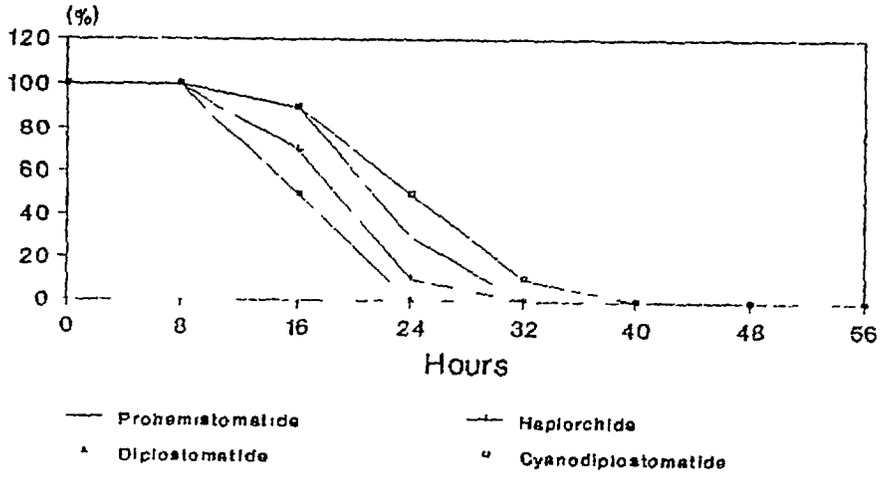

Fig (60) Effect of freezing at -4 or -5°C on the viability (%) of encysted metacercariae found in Nile-catfish (*Clarias lazera*)

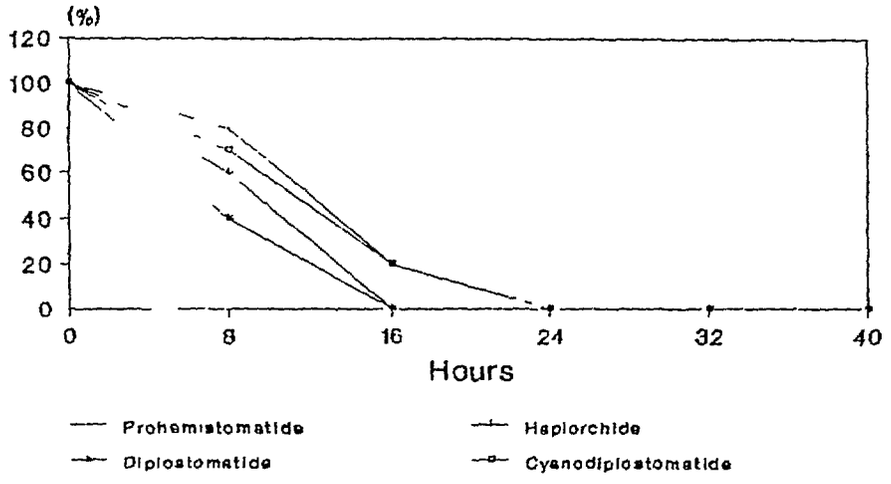

Fig (61) Effect of freezing at -10°C on the viability (%) of encysted metacercariae found in Nile-catfish (*Clarias lazera*)

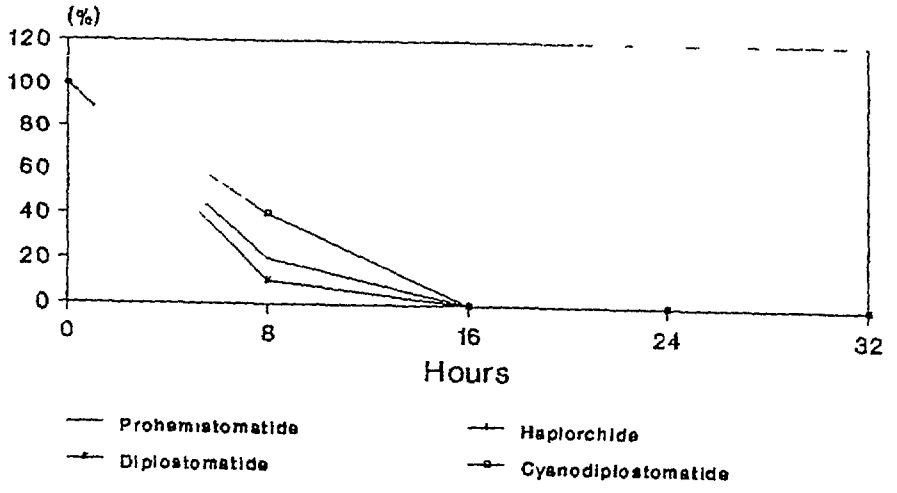

Fig (62) Effect of freezing at -15°C on the viability (%) of encysted metacercariae found in Nile-catfish (*Clarias lazera*)

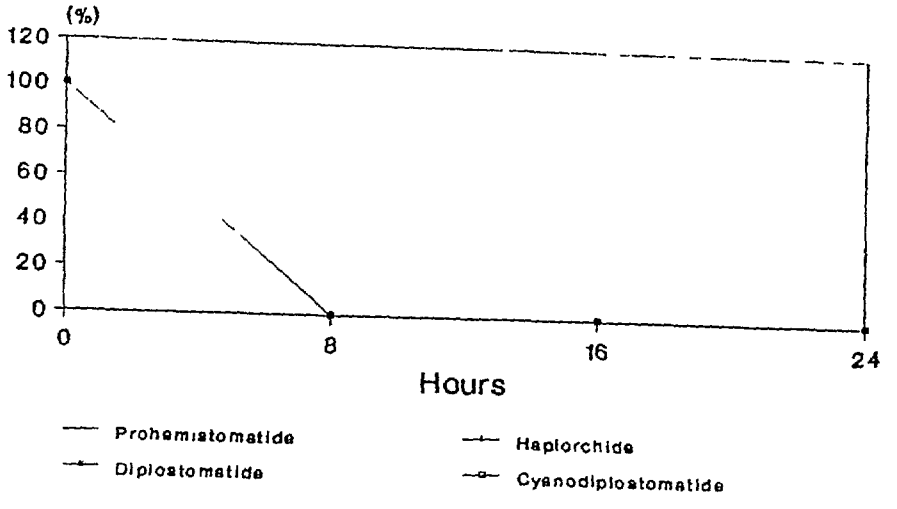

Fig (63) Effect of freezing at -20°C on the viability (%) of encysted metacercariae found in Nile-catfish (*Clarias lazera*)

II- Bacteriological results :

1-Results of bacteriological examination in Cairo area

Table (48) Results of Aerobic plate count in the examined fishes

Fish species	Surface A P C / cm^2	Muscle A P C / gm
Tilapia	1200	0

The number of examined fish was 25

Table (49) Results of Coliform count in the examined fishes

Fish species	Surface Coliform / cm^2	Muscle Coliform / gm
Tilapia	15	0

The number of examined fish was 25

Table (50) Enterobacteriacae isolated from fish surface

Microorganisms	Number of positive fish samples	Percentage
Shigella dysentrae	2	8
Provedencia alcalifaciens	7	28
Enterobacter aerogenes	8	32
Klebsiella pneumoniae	10	40
Escherichia coli	20	80

The number of examined fish was 25

Table (51) Enterobacteriacae isolated from intestine of fish

Microorganisms	Number of positive fish samples	Percentage
Shigella dysentrae	0	0
Provedencia alcalifaciens	0	0
Enterobacter aerogenes	2	8
Klebsiella pneumoniae	3	12
Escherichia coli	22	88

The number of examined fish was 25

Table (52) Enterobacteriacae isolated from fish muscles

Microorganisms	Number of positive fish samples	Percentage
Shigella dysentrae	0	0
Provedencia alcalifaciens	0	0
Enterobacter aerogenes	0	0
Klebsiella pneumoniae	0	0
Escherichia coli	0	0

The number of examined fish was 25

Table (53) Enterobacteriacae isolated from fish species

Microorganisms	Surface		Muscle		Intestine	
	No	%	No	%	No	%
Shigella dysentrae	2	4 2	0	0	0	0
Provedencia alcalifaciens	7	14 8	0	0	0	0
Enterobacter aerogenes	8	17 0	0	0	2	7 4
Klebsiella pneumoniae	10	21 2	0	0	3	11 1
Escherichia coli	20	42 5	0	0	22	81 4

Number of examined fish was 25

2- Results of bacteriological examination of fish from Aswan, source of water Nile (High-Dam) lake at March , 1994 :

Table (54) Results of Aerobic plate count in the examined fish from Aswan

Fish species	Surface A P C / cm^2	Muscle A P C / gm
Tilapia	2×10^2	0

The number of examined fish was 25

Table (55) Results of Coliform count in the examined fish from Aswan

Fish species	Surface Coliform / cm^2	Muscle Coliform / gm
Tilapia	1	0

The number of examined fish was 25

Table (56) Enterobacteriacae isolated from fish surface from Aswan

Microorganisms	Number of positive fish samples	Isolation percentage
Escherichia coli	4	16
Enterobacter aerogenes	7	28
Citrobacter freundii	6	24
Proteus vulgaris	6	24
Edwadsiella tarda	1	4

The number of examined fish was 25

Table (57) Bacteria other than Enterobacteriacae isolated from fish srface from Aswan

Microorganisms	Number of positive fish samples	Percentage
Pseudomonas aeruginosa	1	4
Micrococci	8	32

The number of examined fish was 25

3- Results of bacteriological examination of fish from Aswan, (High-Dam) at June , 1994 (following Rowanda war , pollution resulting from thousands of dead bodies thrown into the Lake)

Table (58) Bacterial loads of water samples from Aswan Lake

Bacterial load		Before	After
APC / ml	Mean	3×10^2	5×10^2
	Minimum	1×10^2	1×10^2
	Maximum	1×10^3	2×10^3
Coliforms / 100 ml	Mean	10	8
	Minimum	4	4
	Maximum	13	13
Staph aureus	Mean	-	-
	Minimum	-	-
	Maximum	-	-

Table (59) Bacterial loads of live fish samples from Aswan Lake / cm^2 surface

Bacterial load		Before conflict at Nile origin	After conflict at Nile origin
APC / ml	Mean	2×10^2	1×10^3
	Minimum	3×10^2	4×10^2
	Maximum	3×10^3	2×10^3
Coliforms / 100 ml	Mean	1	4
	Minimum	0	2
	Maximum	3	7
Staph aureus	Mean	-	-
	Minimum	-	-
	Maximum	-	-

N B Muscle samples were examined and it was free of bacteria

Table (60) Incidence of pathogenic bacteria in water and fish samples

Microorganisms	Water	Fish Surface
Salmonella species	0 %	0 %
Shigella species	0 %	0 %
Staphylococcus aureus	0 %	0 %
Vibrio cholera	0 %	0 %

4- Results of bacteriological examination of fish from Manzala Lake

Table (61) Results of Aerobic plate count (A P C) in the examined fishes from Lake Manzala

Fish species	Surface A P C / cm^2	Muscle A P C / gm
Tilapia	38×10^3	0

The number of examined fish was 25

Table (62) Results of Coliform count in the examined fishes from Lake Manzala

Fish species	Surface Coliform / cm^2	Muscle Coliform / gm
Tilapia	21×10^2	0

The number of examined fish was 25

Table (63) Enterobacteriacae isolated from examined fishes of Manzala Lake

Microorganisms	No of isolates	% in relation to T N I
Aeromonas hydrophila	2	4 2
Escherichia coli	15	31 9
Edwardsiella tarda	5	10 6
Citrobacter freundii	8	17 1
Proteus vulgaris	6	12 8
Klebsiella pneumoniae	11	23 4
Total	47	100 0

The number of examined fish was 25

T N I Total number of isolates

Table (64) Enterobacteriacae isolated from surface of examined fishes

Microorganisms	No of isolates	% in relation to T N I
Escherichia coli	9	32 1
Edwardsiella tarda	4	14 3
Citrobacter freundii	5	17 9
Proteus vulgaris	4	14 3
Klebsiella pneumoniae	6	21 4
Total	28	100 0

The number of examined fish was 25

T N I Total number of isolates

Table (65) Enterobacteriacae isolated from surface of examined fishes

Microorganisms	No of isolates	% in relation to T N I
Escherichia coli	9	32 1
Edwardsiella tarda	4	14 3
Citrobacter freundii	5	17 9
Proteus vulgaris	4	14 3
Klebsiella pneumoniae	6	21 4
Total	28	100 0

The number of examined fish was 25

T N I Total number of isolates

Table (66) Enterobacteriacae isolated from intestine of examined fishes

Microorganisms	No of isolates	% in relation to T N I
Aeromonas hydrophila	2	10 5
Escherichia coli	6	31 5
Edwardsiella tarda	1	5 3
Citrobacter freundii	3	15 8
Proteus vulgaris	2	10 5
Klebsiella pneumoniae	5	26 3
Total	19	100 0

The number of examined fish was 25

T N I Total number of isolates

Table (67) Enterobacteriaceae isolated from different parts of the examined fishes

Site of isolation	No of isolates	*Escherichia coli*	*Edwardsiella tarda*	*Citrobacter freundii*	*Proteus vulgaris*	*Klebsiella*	*Aeromonas hydrophila*
Surface	28	9	4	5	4	6	-
Intestine	17	6	1	3	2	5	2
Muscle	-	-	-	-	-	-	-
Total	47	15	5	8	6	11	2

Table (68) Staphylococci isolated examined fishes

Microorganisms	No of isolates	% in relation to T N I
Staph epidermidis	8	88 9
Staph aureus	1	11 1
Total	19	100 0

T N I Total number of isolates

Table (69) Staphylococci isolated from different parts of the examined fishes

Sute of isolation	No of isolates	*Staph epidermidis*	*Staph aureus*
Surface	4	3	1
Muscle	5	5	-
Total	9	8	1

Table (70) Microorganisms isolated from fish species

Microorganisms	Surface		Muscle		Intestine	
	No	%	No	%	No	%
Aeromonas hydrophila	0	0	0	0	2	10 5
Escherichia coli	9	32 1	0	0	6	31 5
Edwardsiella tarda	4	14 3	0	0	1	5 3
Citrobacter freundii	5	17 9	0	0	3	15 8
Proteus vulgaris	4	14 3	0	0	2	10 5
Klebsiella pneumoniae	6	21 4	0	0	5	26 3

Table (71) Microorganisms isolated from different parts of the examined fishes

Site of isolation	No of isolates	*Escherichia coli*	*Edwardsiella tarda*	*Citrobacter freundii*	*Proteus vulgaris*	*Klebsiella pneumoniae*	*Staph epidermidis*	*Staph aureus*	*Aeromonas hydrophila*
Surface	31	9	4	5	4	6	2	1	-
Gills	24	6	3	4	3	7	1	-	-
Muscle	5	-	-	-	-	-	5	-	-
Intestine	17	6	1	3	2	5	-	-	2
Total	79	21	8	12	9	18	8	1	2

5- Results of bacteriological examination of fish from Alexandria area :

Table (72) Results of Aerobic plate count in examined fishes from El-Max region

Fish species	Surface APC / cm^2	Muscle APC / gm
Mugil sp	7×10^3	2×10^2
El-Sharagesh	7×10^3	1×10^2
Siganus sp	8×10^3	5×10
Tilapia sp	1×10^4	2×10^2

No of examined fishe samples were 10 fish of each species

Table (73) Results of Coliform count in examined fishes from El-Max region

Fish species	Surface Coliform / cm^2	Muscle Coliform / gm
Mugil sp	70	9
El-Sharagesh	40	6
Siganus sp	30	5
Tilapia sp	90	20

No of examined fishe samples were 10 fish of each species

Table (74) Results of Aerobic plate count in the examined fishes from Abokir region

Fish species	Surface APC / cm^2	Muscle APC / gm
Mugil sp	4×10^3	3 x 10
El-Sharagesh	2×10^3	2 x 10
Siganus sp	1×10^3	1×10^2

No of examined fishe samples were 10 fish of each species

Table (75) Results of Coliform count in the examined fishes from Abokir region

Fish species	Surface Coliform / cm^2	Muscle Coliform / gm
Mugil sp	40	7
El-Sharagesh	30	4
Siganus sp	20	3

No of examined fishe samples were 10 fish of each species

Table (76) Staphylococci isolated from examined fishes from El-Max region

Fish species	Total No of isolates	*Staph epidermidis*	*Staph saprophyticus*
Mugil sp	3	0	3
El-Sharagesh	6	6	0
Siganus sp	9	7	2
Tilapia sp	4	4	0
Total	22	17	5

No of examined fishe samples were 10 fish of each species

Table (77) Staphylococci isolated from different parts of the examined fishes from El-Max region

Fish species	Total No of isolates	*Staph epidermidis*	*Staph saprophyticus*
Surface	11	9	2
Liver	0	0	0
Kidney	2	2	0
Intestine	9	6	3
Total	22	17	5

No of examined fishe samples were 10 fish of each species

Table (78) Staphylococci isolated from examined fishes from Abokir region

Fish species	Total No of isolates	*Staph epidermidis*	*Staph saprophyticus*
Mugil sp	8	6	2
El-Sharagesh	0	0	0
Siganus sp	5	1	4
Total	13	7	6

No of examined fishe samples were 10 fish of each species

Table (79) Staphylococci isolated from different parts of the examined fishes from Abokir region

Fish species	Total No of isolates	*Staph epidermidis*	*Staph saprophyticus*
Surface	9	5	4
Liver	0	0	0
Kidney	1	0	1
Intestine	3	2	1
Total	13	7	6

No of examined fishe samples were 10 fish of each species

Table (80) Staphylococci isolated from examined fishes from Alexandria

Fish species	El-Max region		Abokir region		Total
	Staph epidermidis	*Staph saprophyticus*	*Staph epidermidis*	*Staph saprophyticus*	
Mugil sp	0	3	6	2	11
El-Sharagesh	6	0	0	0	6
Siganus sp	7	2	1	4	14
Tilapia sp	4	0	ND	ND	4
Total	17	5	7	6	35

No of examined fishe samples were 10 fish of each species

ND Not done

Table (81) Staphylococci isolated from different parts of the examined fishes from Alexandria

Fish species	El-Max region		Abokir region		Total
	Staph epidermidis	*Staph saprophyticus*	*Staph epidermidis*	*Staph saprophyticus*	
Surface	9	2	5	4	20
Liver	0	0	0	0	0
Kidney	2	0	0	1	3
Intestine	6	3	2	1	12
Total	17	5	7	6	35

No of examined fishe samples were 10 fish of each species

ND Not done

Table (82) Enterobacteriaceae isolated from fishes from El-Max region

Fish species	Total No of isolates	*Shigella dysentrae*	*Escherichia coli*	*Proteus vulgaris*	*Klebsiella pneumoniae*	*Citrobacter freundii*
Mugil sp	12	0	7	0	4	1
El Sharig sh	15	0	9	2	1	3
Siganus sp	9	1	4	2	2	0
Tilapia sp	17	0	10	1	4	2
Total	53	1	30	5	11	6

No of examined fishes were 10 of each species

Table (83) Enterobacteriaceae isolated from fishes from El-Max region

Fish species	Total No of isolates	*Shigella dysentrae*	*Escherichia coli*	*Proteus vulgaris*	*Klebsiella pneumoniae*	*Citrobacter freundii*
Surface	23	1	14	2	4	2
Liver	3	0	3	0	0	0
Kidney	8	0	4	0	4	0
Intestine	19	0	9	3	3	4
Total	53	1	30	5	11	6

No of examined fishes were 10 of each species

Table (84) Enterobacteriaceae isolated from fishes from Abokir region

Fish species	Total No of isolates	*Escherichia coli*	*Klebsiella pneumoniae*	*Citrobacter freundii*	*Enterobacter aerogenes*
Mugil sp	7	4	0	1	2
El Sharagesh	8	3	1	4	0
Siganus sp	13	7	2	1	3
Total	28	14	3	6	5

No of examined fishes were 10 of each species

Table (85) Enterobacteriaceae isolated from fishes from Abokir region

Fish species	Total No of isolates	*Escherichia coli*	*Klebsiella pneumoniae*	*Citrobacter freundii*	*Enterobacter aerogenes*
Surface	13	7	1	3	2
Liver	2	1	0	1	0
Kidney	4	1	0	1	2
Intestine	9	5	2	1	1
Total	28	14	3	6	5

No of examined fishes were 10 of each species

Table (86) Other bacteria isolated from the examined fishes in Alexandria area

Fish species	El-Max region		Abokir region	Total No of isolates
	Aeromonas hydrophila	*Vibrio alginolyticus*	*pseudomonas aeruginosa*	
Mugil sp	0	0	1	1
El-Sharagesh	0	1	0	1
Siganus sp	1	0	0	1
Total	1	1	1	3

No of examined fishe samples were 10 fish of each species

III- Virological results : (in aquaculture)

Suez experimental system was chosen for virological examination of fish free human safety

Table (87) Incidence of detectable viral pathogen

Type	Number	Percentage
Rota	5	10 42
HB	3	6 25
HA	2	4 17
Polio	9	18 75
Adeno	8	16 67
Meseales	1	2 08
Rubella	0	0 00
Total	28	58 33

Table (88) Types and number of viral antigen detection in stabilization pond system

Stabilization ponds	Rota	HB	HA	Polio	Adeno	Meas	Rub	Total
Raw sewage	2	1	1	4	3	1	-	12
Anaerobic pond	1	1	1	1	2	-	-	6
Facultative pond	1	-	-	2	1	-	-	4
Maturation pond 1	1	1	-	1	1	-	-	4
Maturation pond 2	-	-	-	1	1	-	-	2
Fish pond	-	-	-	-	-	-	-	-
Total of positive	5	3	2	9	8	1	-	28

5- DISCUSSION

The present study tried to throw some light on the role of fish in transmitting parasitic diseases to some birds , animal and human Trematode larvae were considered as fish parasites that invade their body through skin or mucosa of the digestive tract and migrate to different tissues and organs Such invasion frequently lead to stunted growth or death of the affected fish Some of these migrating parasites were harmful to human animals or even birds when consumed as raw or unsufficient cooked infested fish

The metacercariae of different trematode families infested most tissues and organs of Tilapia species and Nile-catfish *(Clarias lazera)* inducing clinical symptoms, gross and microscopic lesions

Generally clinical symptoms observed in infested Tilapia species were emaciation with low body gain, sunken eyes, haemorrhag's on the skin, greyish discoloration of body surface, darkness of the skin, distruction of fin rays and membranes, black spotes on fins, white spotted eyes and opacity, abdominal distension, exophthalmia, errected scales, excess mucus on the skin and black spots on body surface especially at the caudal peduncle These observation agreed with those previously reported including minute skin haemorrhages and blindness of experimentally infested fish with *Diplostomum spathaceum* (**Dogiel**

et al , **1970**) , black spots on the skin, fins and gills, emaciation blindness and exopthalmia in cultured fish (**Paperna** , **1980**) , eye blindness, black spots on fins and skin of the infected *Tilapia nilotica* (**Mahdy** , **1991**) , poor growth , blindness and growth deformities in eye fluke infested freshwater fish (**Chappell** *et al* , **1994**) , and keratitis, white spoted eye , blindness , black spots on fins and body surface especially at peduncle region, enlarged abdomen and darkness of the skin in heavy infestation (**Soliman** , **1994**)

On necropsy muscle nodules of variable sizes and colours were a common finding in most of all infested Tilapia fish Other lesions including flabby spotted and emaciated muscles, cysts under the skin, mottled and nodulated liver spleen and kidney, large cysts embeded in the kidney tissue or attached to peritonium, cyst under the skin, cyst on the skin and fins, large cysts in the branchial cavity, greyish white foci on the gill filamments, fluid in the abdomen and in the eye pouch, and erosion and ulceration of the skin These observation nearly agreed with that reported by **Van Duijn** (**1967**) who found parasitic cysts surrounded with pigment cells if the cut was near the surface of the skin and with **Donges** (**1974**) who recorded the presence of large cysts dorsal to the swime bladder and in the kidneys of *Tilapia zillii* In the same respect, **Paperna** (**1980**) described black pigmented cysts in the skin, non pigmented cysts on gills resulting in thickening and deformation of the filaments and also found pigmented and non pigmented cysts on muscles of culutied fish Moreover, **Soliman** (**1994**) reported similar lesions including nodules of different sizes and colours among muscles small multiple cysts in the spleen, liver and kidneys,

ascitis and large greyish-white to yellowish cyst in the renal tissue of Tilapia species

Macroscopic lesions of the examined Nile-catfish *(Clarias lazera)* revealed muscle nodules of variable sizes and colours in almost all infested fish Other lesions included emaciated and soft flabby muscles, cysts under the skin, mottled and nodulated livers, spleens and kidneys, ascitis, skin erosions and ulcerations, and grey foci on the gill filaments These findings might be due to variartion of host tissue reactions against infested cercariae in the form of pericystual aggregation of melanin-carying cells, lymphocytes and other inflammatory cells These observations were nearly similar to those reported by **El-Mossalami and Sheriff (1964)**, who found oval whitish cysts among the muscle fiber **El-Bouhy *et al* (1988)** recorded nodular skin lesions especially in the peduncle region and ventral sides of body, as well as muscle nodules of variable size and colour **Mahmoud *et al* (1989)**, described multiple nodules of different sizes distributed allover the muscles of the back and sides of fish which were dark in colour and lead to muscle distension Moreover, **Youssef *et al* (1993 b)** detected whitish raised nodules in the muscles while **Ahmed *et al* (1994)** found black pigmented nodules in the muscles of the examined fish

In agreement with previous findings of **El-Bouhy *et al* (1988)** our investigation revealed the presence of encysted metacercaia in the clinically healthy Tilapia species and Nile-catfish (*Clraias lazera*) in a rate of 42 22 % and 48 13 % respectively This might be due to early infestaion of fish with parasitic cysts or presence of few number of

encysted metacercaria infested the fish muscle without invasion of the vital organs and become unable to produce obvious clinical signs

The incidence of encysted metacercariae in Tilapia species was found to be 81 14% A finding which came in consistent with those investigated by **Mahdy (1991)** , was higher than that recorded by **Mahmoud (1983) , El-Naffar and El-Shahawy (1986) , Fayek *et al* (1986) , Mansour *et al* (1987) , El-Dally (1988) , Shalaby *et al* (1989) , Khalifa (1993) , Tantawy (1993) and Mahdy *et al* (1995)** and was lower than that observed by **El-Mokaddem (1982)**

Moreover the incidence of metacercarial infestation in examined *Clarias lazera* was 85% This observation came in accordance with that reported by **Fahmy *et al* (1976) , Mahmoud (1983) , El-Sherbiny (1988) and Tantawy (1993)** , was nearly similar to those recorded by **El-Naffar and El-Shahawy (1986) , El-Bouhy *et al* (1988) , Al-Bassel (1990) and Youssef *et al* (1993 a)** and was higher than that mentioned by **Issa and Ibaid (1969) , El-Aroussi (1984) , Shalaby (1985) , El-Dally (1988) , Mahdy (1991) and Khalifa (1993)**

The maximum total incidence of metacercarial infestation in both infested and examined fish were significantly higher in the posterior third (94 83 and 77 83%) followed by middle third (88 87 and 72 93%) and the lowest were observed in the anterior third (78 94 and 64 78%), respectively These findings were partially inagreement with those observed by **Mahdy (1991)** , they found the higher rate of infection in the tail followed by head and trunk regions On the other hand, **Mahmoud (1983)** detected the maximum incidence in the middle

followed by the posteiior and anterior third of the examined fish, **El-Dally (1988)** recorded the higher infestation rate in head followed by tail and tunk regions while, **El-Sherbiny (1988)** observed the highest infestation rate in the middle (74 65 %) followed by anterior (68 67 %) and posteiioi (67 33 %) third of the examined fish

With respect to the type of fish examined, the present study indicated that the maximum incidence of metacercarial infection in Tilapia species was found in the muscle of the posterior third This finding came imagreement with that reported by **Mahdy (1991) and Khalifa (1993)** and disagreed with those recorded by **Mahmoud (1988), El-Dally (1988) , and El-Sherbiny (1988)** While the highest incidence of metacercarial infestation in *Clarias lazera* was observed in the muscles of the middle third This observation came in consistent with that recorded by **Mahmoud (1983) , El-Bouhy *et al* (1988) , El-Dally (1988) and El-Sherbiny (1988)** and was differ from that mentioned by **Al-Bassel (1990) and Mahdy (1991)**

In Tilapia species the maximum number of encysted metacercariae per gram of muscles was found in the posterior third (34 93/gm) followed by a continous significant decrease in the middle third (23 2/g) and anterior third (13 24/g) of the muscles This observation was nearly similar to that mentioned by **Ibrahim and Mahmoud (1988) , Shalaby *et al* (1989) and Khalifa (1993)** and was lower than that reported by **Paperna (1980) , El-Naffar and El-Shahawy (1986) , Al-Bassel (1990) and Tantawy (1993)**

Moreover, the highest number of encysted metacercariae per gram muscle of the infected *Clarias lazera* was found in the middle third (51 893 ± 2 824) This finding was nearly similar to those recorded by **Shalaby (1985) , El-Bouhy *et al* (1988) , El-Dally (1988) and Al-Bassel (1990)** was higher than those reported by **Mahmoud (1983) and El-Sherbiny (1988)** and was lower than that observed by **Paperna (1980) , El-Naffar and El-Shahaw (1986) , Mahdy (1991) , Khalifa (1993) and Tantawy (1993)** A more continous reduction in the average number of metacercariae found in livers (5 86 ± 0 599) , kidneys (3 663 ± 0 561) and spleens (1 524 ± 0 178) Such variation in the number of encysted metacercariae may be due to the degree of pollution of water, presence or abscence and or intensity of wild birds and water fowl and the technique recomended for detection and counting of the encysted metacercariae

In the present investigation the average number of encysted metacercariae in different parts of both examined Tilapia spieces and *Clarias lazera* was significantly varied in different seasons In Tilapia species the maximum number of encysted metacercaria per gram muscles from each third of the fish, as well as in fins, skins, livers, kidneys and spleens were recorded during spring followed by that recorded during summer and the lowest number were observed during autumn This may be due to that, the breeding seasons of the snail (first intermediate host of trematode metacercariae) occured during spring and autumn **(El-Aroussi, 1984)** Fish coming from winter with depleted fat reserves, low immune body defence and become more susceptible to infection However, in the late autumn the temperature become low and the movement of tilapia fish for searching about feed was supressed so the direct contact of the fish

with infected snails and the liberating free swimming cercariae become rare

The eye fluke affection occured in winter and tend to be saesonal This finding agreed by **chapell *et al* (1994)** The highest number of encysted metacercariae in eye lenses and in branchial cavity were observed during winter This finding might be due to cercaria species liberation maturation and infectivity were time and temperature dependent **(Palmieri , 1976 and Whyte *et al* , 1991)**

In the other hand , the maximum number of metacercariae per gram muscles as well as, in the livers, kidneys and spleens of *Clarias lazera* were recorded during winter, while the lowest number obtained during autumn This observation may be returned to increase the fish susceptibility to infestation because of depleted fat reserves and with low immune body defence in winter as well as increasing of the fish in age gave a chance for more metacercariae infestation to susceptable fish

The present results indicated that the incidence of metacercarial infection in both type of fish under investigation was significantly decrease with the increase of body weight and not affected with the variation in body length This may reffered to that the heavely infestation with encysted metacercariae resulting in emaciation associated with low drop in body weight without any changes in their length Moreover, the small sized fish were highly susceptable for infestation than the large sized ones as the skin was thin and delicate and easly penetrated by metacercariae **(Paperna, 1980)** These observations were nearly similar to that reported by **Shalaby (1982) , El-Aroussi (1984) and El-Bouhy**

et al (**1988**) , and are differ from that recorded by, **El-Sherbiny (1988)** found that the infection rate elevated with the increase of fish weight

In the present work, the maximum incidence of metacercarial infestation was found among fish weighting 100-150 gm and up to 200 gm for both Tilapia species and *Clarias lazera,* respectively A similar findings were observed in Tilapia species (**Shalaby , 1982**) and in *Clarias lazera* (**El-Aroussi , 1984 and El-Bouhy *et al* , 1988**)

Prohemistomatid metacercariae were obtained from muscles and organs of Tilapia species and *Clarias lazera* These metacercariae were previously discribed by several authors from the Nile fish In Egypt, **Fahmy *et al* (1986) , El-Naffar and El-Shahawy (1986) , Mahmoud *et al* (1987) , El-Dally (1988) , El-Bouhy *et al* (1988) , Al-Bassel (1990) , Mahdy (1991) , Tantawy (1993) and Raff (1994)** The present rediscription were imagreement with the description given by previous authors Moreover the rediscription for the investigated excysted metacercariae in the present study was similar to the discription reported by **Al-Bassel (1990) , Mahdy (1991) and Raff (1994)**

Heterophyid metacercariae obtained from Tilapia species The same metacercaria was previously recorded by many authers (**Khalil, (1937) , Reichenbach- Klinke (1973) , Fahmy *et al* (1976) , Boulos *et al* (1981) , Ahmed (1981) , Shalaby (1982) , Fayek *et al* (1986), Nada and Gawady (1986) , Makhlouf *et al* (1987) , Mahmoud (1990) , Mahdy (1991) , Soliman (1994) and Mahdy *et al* (1995)** The rediscription in the prestent investigation similar to description given

by **Mahdy (1991)** and the average dimension in the present study was larger than that recorded by **Raff (1994)**

In the present study haplorchid metacercariae were recovered from Tilapia species and *Clarias lazera* These finding came inagreement with that reported by **El-Naffar and El-Shahawy (1986) , Mahdy (1991) and Tantawy (1993)** In the same respect, Haplorchid cysts were obtained from Tilapia species by **Makhlouf *et al* (1987) , Mansour *et al* (1987) , Mahdy (1991) and Soliman (1994)** and from *Clarias lazera* were detected by **Shalaby (1985) and Mahmoud *et al* (1989)** The rediscription in the present study similar to the discription given by **El-Naffar and El-Shahawy (1986) and Mahdy (1991)**

Concerning the microscopical examination of skin and underlying muscles of fish infested with encysted metacercariae in the present investigation It revealed presence of great number of small sized cysts concentrated in the superfacial layer of the dermis between collagen bundles of stratum compactum or among the loose connective tissue of stratum spongeosum and appeared as faint basophilic parasitic elements Similar findings were explained by **Soliman (1994) and Mahdy *et al* (1995)**

Moreover, parasitic cysts of variable size were detected and surrounded by aggregation of few number of inflammatory cells mainly macrophages melanin-carying cells and easinophilic granular cells (EGC), which sometimes invade parasitic elements or scattered under stratum compactum of the dermis These large cysts appear surrounded with serous fluid follow by cellular reaction These results came

magreement with that reported by **El-Bouhy *et al* (1988), Mahmoud *et al* (1989) , Shalaby *et al* (1989), Soliman (1994) and Mahdy *et al* (1995)** In addition the superfacial muscle bundles of infested area appear replaced by connecive tissue proliferation usually infletrated with macrophages and lymphocytes, fine blood capillaries with enlarged endothelium usually surrounded with melanin-carrying cells This may be due to irritation of infective parasite and their toxic product These observation came in accordance with that detected by **El-Mossalami and Sherif (1964), Shalaby *et al* (1989) and Soliman (1994)**

On the other hand parasitic cysts invaded the deep muscle layer of the infested fish showed minimum tissue reaction (slight connective tissue proleferation, few number of leucocytic cells and melanin-carrying cells), granulation of sarcoplasm, sarcolemmal vaculation or sarcoplasmic dissolution, while other small cysts surrounded with thick layer of inflammatory cells (Lymphocytes and Macrophages) and tunnels of inflmmatory cells were seen between muscle bundles extended until reach the area of parasitic cysts These findings may be due to the migration of metacercariae within the muscles These observations were nearly similar to those reported by **Shalaby *et al* (1989) and Mahdy *et al* (1995)** Sometimes large parasitic cysts were surrounded by inflammatory cells with great number of melanin- carrying cells in the outer zone of parsitic cyst and in perivascular area Similar findings were described by **Van Duijin (1967), Post (1987), Shalaby *et al* (1989), Ahmed *et al* (1994) and Soliman (1994)** who recorded excessive aggregation of melanin-carrying cells around and infletrated the parasitic capsule The excessive aggregation of melanin-carrying cells around the parasitic cyst may decleared their defensive role (**Roberts, 1978**)

Degenerated and necrotized parasitic cysts detected which were undergo calcified or replaced with connective tissue proliferation containing dark, basophilic granular elements and the surrounding tissues characterized by connective tissue proleferation causing pressure atrophy and even replacing the neighbouring muscles, also the surrounding muscles suffered from degenerative changes and zenker's necrosis This finding may be due to prolonged irritation by the calcified materials, in addition to toxic effect of parasitic metabolities These results were inagreement with that reported by **El-Bouhy *et al* (1988), Mahmoud *et al* (1989), Shalaby , *et al* (1989), Youssef *et al* (1993 a), Soliman (1994) and Abd El-Hafez (1996)**

Moreover experimental infection of baby chicks, chickens , balady duckling, squab, quails, herons and moorhens with encysted metacercariae succeed to develop to adult worm producing different type of trematode eggs The prepatent period of the obtained trematodes in our experiments was varied from that recorded by the previous authors These findings may be due to the variation in the species of birds and/or fish used in these experiments This finding supported those reported by **Mahdy (1991)**

Metacercarial infection of experimental infected birds in the present study revealed appearance of clinical signs especially in susceptible heavely infested birds Clinical signs of experimental infected birds including loss of body weight , unkempt feathers , unthriftiness and watery diarrhoea and in some cases bloody diarrhoea may occure These findings were similar with those recorded by **Huffman *et al* (1986)** for *Echinostoma trivolis* in golden hamster and

with **Stuart and Brenard (1989)** for *Echinostoma caproni* in domestic chick Moreover our finding was nearly similar to that detected by **Fried and Nilson (1981)** who found decrease in body weight of domestic chicks infected with *Echinostoma revolvs*

Postmortem finding of experimental birds revealed emaciation with prominance keel bone , dilated gut with unusual amount of fluid , thickening of the intestinal wall , velvety appearance of intestinal mucosa which sometimes sloughed and bloody intestinal content in some cases The results of our study showed certain similarities to that of *Echinostoma caproni* in the mouse intestine **(Bindseil and Christensen, 1984)** , in domestic chicks **(Stuart and Bernard , 1989)** and to that of *Echinostoma revolutum* in domestic ducks **(Mondal and Baki, 1989)**

Prohmeistomum vivax flukes were recovered from the small intestine of experimentally infected herons, chicks squabs, quails, ducklings and moorhens The same parasite was obtained from chickens **(Nada and Gawady , 1986 , Abd El-Salam *et al* , 1987 a , El-Bouhy *et al* , 1988 , Mahdy , 1991 and Raff , 1994)** , Pigeons **(Abdel-Salam *et al* , 1987 a , Mahdy , 1991 and Tantawy , 1993)** , and herons **(El-Naffar and Khalifa , 1975)** Duckling, moorhens and quails were a new host record The description in the present study was similar to the description given by **Shalaby (1982) , Mahdy (1991) and Raff (1994)** However our specimen was of larger body length than those of **Shalaby , (1982)** Also the oral sucker was small in size than that reported by **Mahdy (1991)** Also the body length was smaller than that detected by **Raff (1994)**

Mesostephanus appendiculatus worms were found in the small intestine of experimentally infected chicks, herons, ducklings, squabs, quails and moorhens These findings were inagreement with that reported by **Ciurea (1916), Lutz (1935), El-Bouhy *et al* , (1988) and Mahdy (1991)** The present description nearly agreed with the description given by previous authors from animal or birds (**Yamaguti , 1958 , Shalaby , 1982 , Fahmy *et al* , 1982 , Shalaby , 1985 , Mahdy , 1991 and Raff , 1994**) However herons, moorhens and quails ae considered a new host recored for the parasite

Mesostephanus fajardensis was detected from small intestine of chicken , squabs squails and duckling The present description nearly coincided with the description given by **Yamaguti (1958) and Mahdy (1991)** except for slight dimensional differences Also chicks, quails and ducklings are considered a new host record for the parasite

Mesostephanus flapi worms were found in the small intestine of experimentally infected squabs and chicks with metacercariae from Tilapia species and *Clarias lazera* In the same respect, **Shalaby (1982)** obtained the same parasite from dog infected with metacercariae from Tilapia spp The present description came inagreement with the description recorde by **Shalaby (1982)** However the lateral sides of the broad forebody of the parasite were evaginated *Clarias lazera* fish, squabs and chicks considered a new host record

Paracenogonimous ovatus flukes were recovered from the small intestine of experimentally infected chicks, squabs and duckling with metacercariae from *Clarias lazera* In the same respect **Shalaby (1982)**

recorded the parasite from experimentally infected dog with Tilapia spp and **Mahdy (1991)** detected the same parasite from pigeon experimentally infected with *Clarias lazera* The present description was nearly conicided the description given by **Katsuarda (1914) , Yamaguti (1958) , Skrjabin (1964) , Shalaby (1982) and Mahdy (1991)** However the obtained parasite was larger in size than that reported by **Shalaby (1982)**

Holostephanus volgensis parasites were found in the small intestine of squabs experimentally fed on metacercariae from Tilapia species The description in the present was similar to the descrption given by **Vojtkova (1996) and McDonald (1981)** except for slight dimensional differences Tilapia spp fish and squabs are considered a new host record

Heterophyes aequalis, obtained from the small intestine of experimentally infected heron with Tilapia species metacercariae The redescription of this parasite in the present study conicided to the description given by **Skrjabin (1964) and Raff (1994)** However the ovary was with larger dimension also the intestinal caeca extended to the level of the ovary, the fact which was also noticed by **Raff (1994)** while in **Skrjabin (1964)** description they reach to the level of anterior portion of the testes

Heterophyes dispar recovered from small intestine of heron experimentally fed on metacercariae from Tilapia spp The present description nearly similar to the description reported by **Skrjabin (1964), Chai and Lee (1990) and Raff (1994)** However the ovary was

submedian in position instead of being median in description given by **Raff (1994)** Also the oral sucker appear with larger dimension It was differentiated from *Heterophyes heterophyes* and *Heterophyes h nocens* by the small sized genital sucker and small number of rodlets on gonotyl (22 - 33)

Pygidiopsis genata worms were detected from the small intestine of experimentally infected squabs, chicks and herons, with Tilapia species metacercariae These findings came inagreement with that reported by **Nada and Gawady (1986) and Mahdy *et al* (1995)** Also the intestinal caeca terminating at the level of the ovary while terminating in front of the testes as descriped by **Nada and Gawady (1986)**

Pygidiopsis summa were found in the small intestine of herons experimentally infected with Tilapia species metacercariae The same parasite recovered from the small intestine of experimentally infected dog with metacercariae (**Amin, *et al* 1993**) The present description agreed with keys and description given by **Skrjabin (1964) , Chai *et al* (1986) and Chai and Lee (1990)** However the vitellaria in our specimen had a more posterior location (from the level of posterior edge of the ovary to the posterior edge of the testis) Also the small posterior appandage of the oral sucker described by **Skrjabin (1964)** were not abserved in our specimen *Pygidiopsis summa* was differentiated from *P genata* in the morphology of ventral sucker, ventrolateral apparatus and the caeca (**Chai *et al* , 1986**) The parasite was recorded for the first time in Egypt and Tilapia fish and herons are a new host record

Metagonimus yokogawai were recovered from intestine of experimentally infected herons The present description nearly agreed with that detected by **Katsurada (1912), Miyata (1944) and Raff (1994)** However our specimen was small in size than that recorded by **Raff (1994)**

Ascooctyle mcintochi were detected from the small intestine of experimentally infected herons with metacercariae from Tilapia spp gills The redescription in the present study agreed with the description given by **Leigh (1974)** who studied its life cycle, in the present study the adult were recovered in the heron intestine 4-days post feeding, while **Leigh (1974)** recovered the adult in intestine of day-old-chick within 48-60 hours post feeding The variation may be due to differance in the lab bird and the infested tissue given to the bird In the same respect **Nasir *et al* (1970)** found *Ascocotyle paratenicollis* in the small intestine of chicken fed on cyst from intestine of *Lebistes reticulatus* fish The obtained parasite was described for the first time from the Egyptin locality and herons is a new host record

Haplorchis pumilio were recovered from the small intestine of experimentally infected chickes, squabs, herons and moorhens with metacercariae from Tilapia sp and *Clarias lazera* The same parasite were recovered by previous authors from pigeon and herons (**Mahdy , 1991**) , from mice (**El-Naffar , 1980 , El-Mokaddem , 1982 and Tantawy, 1993**) and from dog (**Shalaby , 1982 and El-Sherbiny , 1988**) The present description was identical with that reported by **Gohar (1935) , Velasques (1973), Shalaby (1982) and Mahdy (1991)** However slight difference in measurments were noticed which

might be related to the process of preparing the specimen for identification Also the detailed description of the ventrogenital sac particularly the abscence of spine from the anterior edge of ventral sucker were not observed by the previous author i e **Shalaby (1982)** stated that the ventral sucker was absent

Haplorchis yokojawai obtained from small intestine of experimentaly infected herons with Tilapia species metacercariae In the same respect, the obtained parasites were detected from dog or cat fed on infested *Tilapia nilotica* (**Azim , 1938 , Fahmy and Selim , 1959 , Pande and Shukla , 1972 and Fahmy *et al* , 1976)** and from rat by **Fahmy *et al* (1986)** The present description nearly agreed with the description given by **Pearson (1964) , Fahmy *et al* , (1976) and Fahmy *et al*, (1986)** However our specimen was small in size This finding may be due to the difference in the final host

Haplorchis disca recovered from small intestine of experimentally infected herons with metacercariae from Tilapia species and *Clarias lazera* The same parasites were recovered from dog infected with Tilapia spp encysted metacercariae **(Shalaby , 1982)** The present description was agreed with the description given by **Shalaby (1982)** However , our specimens were of small body length and with long flattened for body and small disc shaped hind body These differences may be due to the difference in final hosts *Clarias lazera* and herons were considered a new host record

Concerning the effect of boiling on the viability of different type of encysted metacercariae The present study revealed that boiling of

Tilapia species and *clarias lazera infested with metacercariae* fish for 5 minutes were sufficient to complete loss the viability of the metacercarial species (Prohemistomatide , Haplorchide , Heterophyide , Diplostomatide , Euclinostomatide , Echinostomatide and Cyanodiplostomatide) These observation were inagreement with that of **Reichenbach-Klinke (1973) and El-Sherbiny (1988)** The time consumed in our study was lower than that redorded by **Hamed and Elias (1970)**, this might be due to the method of heat treatment used in their experiment where they arranged fish on a tray and hold it in oven to the recommended temperature so the exposure to heat was superficial not reach the deep muscles as in boiling Other finding came in consistent with our results were reported including Through cooking of fish before its consumption suffecient to kill fish parasites (**Faust , 1955 and Roberts , 1978)** , heating of *Heterophyes heterophyes* infested fish at 45°C for 30 minute and prefered higher temperature according to muscle thickness may safe guard against it **Mahmoud (1983)** and thorough cooking by heating at 50°C for at least 10 minutes were sufficient to kill such parasites

In present investigation showed that the viability of encysted metacercaria were disappeared by Fried the Tilapia and *Clarias lazera* muscles for 10 minutes on each side These finding were higher than that reported by **El-Sherbiny (1988)** found that frying of fish for 4 minute of on each side variation could be attributed to the fish size and species where he used only Tilapia species of the same size in his experiment while in our study we used both Tilapia species and *Clarias lazera* of different size categories

Concerning the effect of grilling on the viability of metacercariae Our result showed that the viability of the infested Tilapia species cyst in some fish were not affected by grilling for 5 minute on each side Such findings came in accordance with that found by **Hamed and Elias (1970) and El-Sherbiny (1988)** These observation might be due to the temperature of the inner part of the fish ranged from 55 to 70°C So , there were some portion of the fish tissue not not affected by the fire On the other hand , fish of the same size were griled for 10 minute on each side showing loss of viability of the encysted metacercariae lodged within their muscle Similar observation were recorded by **Youssef *et al* (1993 b)** they found that grilling of pieces of muscles of *Tilapia nilotica* for 15 minute was enough to kill the encysted metacercariae lodged in this muscles

Regarding to the effect of chilling on the viability of encysted metacercariae found in Tilapia sp and *Claria lazera* Our results showed that chilling at 4°C for 18 , 15 , 17 , 15 , 14 and 5 days were sufficient to stop the viability of all the recorded number of the encysted metacercariae of Prohemistomatide , Halporchide , Heterophyid , Diplostomatide , Euchinostomatide and Echinostomatide respectively While the encysted metacercariae of *Clarias lazera* muscles were found to be loss their viability by chilling for 16 , 14 , 14 and 12 days for Cyanodiplostomatide , Prohemistomatide , Diplostomatide and Haplorchide metacercariae respectively In the same respect , **Kawi and Yumoto (1936)** found that the viability of encysted metacercariae did not affect by preservation of infested fish in ice for 5 - 10 days and **Youssef *et al* (1993 b)** reported that metacercariae still viable at 4°C

for 24 hour and 48 hour in Tilapia species and *Clarias lazera* respectively

Freezing of the infested Tilapia species with encysted metacercariae in the present study showing that the viability of Prohemistomatide metacercariae was lost by freezing at -4°C or -5°C, -10°C, -15°C and -20°C after 16 hours freezing These results was higher than that reported by **Fahmy *et al* (1980)** they found freezing at 48 for 36 hours was lethal to *Prohemistomum vivax* cyst, these variation might be due to that they studying the effect of freezing on one species of Prohemistomatidae metacercariae Haplorchide metacercariae loss their viability at 40, 32 24 and 16 hours following freezing at -4°C or -5°C, -10°C, -15°C and -20°C respectively In the same respect **Fahmy *et al* (1980)** found that 48 hours freezing at -4°C was lethal to *Haplorchis pumilio* metacercariae and **El-Sherbiny (1988)** showed that freezing at -5°C for 72 hours and -15°C for 48 hours were sufficient to kill Haplorchid metacercariae such variation might be due to that they were studying the infectivity of the cyst not their viability In addition Heterophyide metacercariae became unviable by freezing at -4°C or -5°C for 40 hour, -10°C for 24 hour and at -15°C and -20°C for 16 hours The results of freezing at -10°C were agreed with that reported by **Ghittino (1972), Roberts (1978), Brown and Neva (1983) and Youssef *et al* (1993 b)** On the other hand, **Hamed and Elias (1970)** recorded that 33 hours freezing at -10°C or -20°C were sufficient to kill *Heterophyes heterophyes* metacercariae, **Magda *et al* (1981)** found 10 days freezing at -4°C kill *Pygidiopsis genata* cyst, **Mahmoud (1983)** described freezing for a period not less than 9 day at -2°C and 48 hour at

-20°C were sufficient to kill *Heterophyes hetrophyes* metacercariae in the infected muscles and **El-Sherbiny (1988)** found that freezing at -5°C and -10°C for 48 hours were lethal for *Heterophyes heterophyes* cyst and 72 hours at -5°C and 24 hours at -15°C were lethal for *Pygidiopsis genata* metacercariae and also the Echinostomatide metacercariae lost their viability by freezing for 32,24, 16 and 8 hour at -4°C or -5°C, -10°c -15°C and -20°C respectively These finding partially agreed with that described by **El-Sherbiny (1988)** who found that *Echinochesmus perfoliatus* cyst were killed by freezing at -5°C and -15°C for 24 hours

Concerning the effected of freezing on the viability of encysted metacercariae of *Clarias lazera* muscles The present investigation showed that freezing of infested muscles at -4°C or -5°C, -10°C, -15°C and -20°C were sufficient to loss the viability of encysted metacercariae of Prohemistomatide after 32,24,16 and 8 hours respectively, Haplorchide after 32 , 16 ,16 and 8 hours respectively and Cyanodioplostomatide after 32 , 24 , 16 and 16 hours respectively These finding nearly resemble that reported by **Youssef *et al* (1993 b)** In the same respect , **Shalaby (1985)** recorded that freezing at -18°C for 24 hours and at -10°C for 5 days were inhibite the motility of *Clarias lazera* metacercariae (Mesostephanus species) and **El-Bouhy *et al* (1988)** described that freezing at -20° for 7 days sufficient to kill the encysted metacercariae of *Cyanodiplostomum azimi, Mesostephanus appendiculatus* and *Prohemistomum vivax*

The three Tilapia species were collected from Manzala lake , revealed that , *Tilapia zillii* , 25 (43 1 %) , *T nilotica* 3 (20 %) and *T ouria* 7 (58 33 %) were infected with heterophyid encysted metacercariae

The latter show site preference in the fish host depending upon the trematode species involved **(Ciurea , 1924)** In the present work , the *hetero-phyid* metacercariae were mainly found encysted in the muscle layers especially in the tail region and less frequently in the trunk region The location of heterophyid metacercariae coincide with those reported by **Mahdy (1991)** at Giza However , this results disagreement of those **Mansour *et al* (1987)** , they found that the *Pygidiopsis* encysted metacercariae especially in the head region and less frequently in the tail region The three Heterophyid metacercariae (Heterophyis , Pygidiopsis and Haplorchis metacercariae) in the muscle of *Tilapia zillii* , *T nilotica* and *T ouria* , collected in the present work , belonged to , *Heterophyes heterophyes*, *H aequalis*, *H dispar* , *Ascocotyle (Phagicola) ascolonga* , *Haplorchis pumilio* and *pygidiopsis genata* It would be preferable to include animal infection and use ault characters for specific identification of metacercariae **Fahmy and Selim (1959)** did not identify the metacercariae , due to the difficulty in morphological differentiation They identified species from adults obtained from animal infections By this method they demonstrated that the 62 % of Tilapia infection included seven heterophyid parasites viz , *Heterophyes heterophyes* , , *Diorchitrema pseudocirratum* *Haplorchtis sp* , *Phagicola sp* , *Pygidiopsis genata* and *Stictodora sawakinensis* Collected from Cairo and Giza province Their findings raise doubt concerning the results of **Gharibe and Hamdy (1969)** , whose found 67 % of

Tilapia spp from Qarun lake were infected with *H heterophyes* , since their identification was based on metacercarial morphology without animal infection In the present work , the prevalence of heterophyid metacercariae were (41 18 %) from Manzala lake , at winter , this result was considered a lower prevalence than of those previous authours This might be explained by the change in environmental conditions in the different localities of Egypt Moreover, **Makhlouf *et al* (1987)** , were recovered seasonal variations in prevalence and intensity of infection at Mansoura They recorded increased prevalence and intensity of heterophyid metacercariae in summer months , may be due to an increase in cercarial emergence from the snail during this period **(Oshima and Nishi, 1963)** Concerning, the present prevalence was considered low in winter , may be due to change in temperature and humidity

The present prevalence was coincides with **Shalaby *et al* (1989)** from *Tilapia nilotica* in Giza They recorded an incidence (41 43 %)

It is of interest that thirty-nine years ago **Wells and Randall (1956)** found only *H heterophyes* in 67 % of *T zillii* from Manzala and Burullus lakes , while during the present work were recovered six species of heterophyid parasites from the same fish species

In both studies confirmation of parasite identification was based on the recovery of adult flukes by feeding the metacercariae to experimental nimals , rats and puppies in the present work

The morphological characters of the obtained trematode in this work are identical with those of the original description **Yamaguti (1958) and Skarjabin (1964)**

In the limited studies of the snail in Manzala , Edku and Maryut lakes (**Boulos , 1979**) no *Prinella conica* , the vector of *H heterophyes* was found The same survey revealed 2460 *Melania tuberculota* 1 % of which were shedding *P genata* and another 1 5 % were shedding *H pumilio* cerearia The same result was found by **Mansour *et al* (1987)** from the same lakes , they obtained *H pumilio* and *P genata* from experimentally infected animals after feeding by *Tilapia* species infected with encysted metacercariae of these parasites In the present work these results disagreement with **Boulos (1979)** and **Mansour *et al* (1987)** due to recovered of *H heterophyes* , *H aequalis* and *H dispar* from experimentally infected animals with *Tilapia* species which harboured the cysts of Heterophyes species These results agreement with **Makhlouf *et al* (1987)** , they were recovered the same flukes from experimentally dogs fed on infected muscle of *Tilapia zillii* and *T nilotica* with encysted metacerariae at Damietta , Egypt The presence of heterophyid encysted metacercariae mainly in muscle is of importance and presents a hazard for man when improperly cooked fish is eatin (**Youssef *et al* , 1987**) especially in *Tilapia* spp which is often grilled

Histopathology, the eneysted metacerearia of Heterophyid were varies in size as they were very small undected by naked eyes such as pygidiopsis , *Haplorchis* and *heterophyes* cysts It appeared as round or ovoid greyish white nodules about 1 - 3 mm in diamter in subcutis and

between muscle bundles Similar findings were reported by **El-Attar (1988) and Mahdy (1991)**

Different type of cystes were varies in size and shape as well as tissue reaction mature or immature The cyst wall consisted of two layers inner fibrous (Fibroblasts and collagen fibers) and outer cellular (young fibrablasts , lymphocytes , macrophages and melanin carrying cells) The cystes usually found in dermis (stratum spongiosum) and between muscle bundles Such location of the cysts could indicate that the metacercariae migrated through the skin to the blood vessels to reach the various tissues This finding is coincide with that mentioned by **Gharib and Hamdy (1969)** who stated that the metacereariae of heterophyes may reach the eyes by piercin the skin

The tissue reaction in the skin and muscles of infected fish was varies according to stage of maturation and degree of infestation It was represented by excessive cellular and vascular reaction in early stages of infestation while at latter stages of infestation the reactive changes become more fibrous less cellular inassociation with atrophic and degenerative changes in the neighbouring muscles This may be due to reactive changes during migration of the parasite follow by parasitic toxic products , as well as pressure of the parasitic cysts on the neighbouring structure Similar reactive changes were mentioned by **Roberts (1978) , Ilan paperna (1980) Mansour , *et al* (1987) , Sekhar and Threlfall (1970) and El-Attar (1988)**

The reactive changes in the intestine of lab animals (Rats and Puppies) infected with metacercariae which isolated from fish flesh

revealed acute inflammatory reaction in the intestine Mature worm demonstrated free in the intestinal lumen , attached to the wall or penetrate the intestinal mucosa to submucosa and seen between the intestinal glands Severe tissue reaction was demonstrated at early stages of infection chacterised by vascular dilation , hyperplasia of mucus glands together with necrosis However , moderate tissue reaction was noticed 7 days post-infection charactrized by decrease of number of mucous glands , inflammatory cells aggregation and fibrolast cell proliferation in the wall of the intestine together with small eosinaphils This reactive changes may be due to irretation of the parasites and their toxic products also , these reactive changes may explain the clinical lesions developed in mamals and human being eat under cooked or row fish handle or gut the fish containing transrmisable parasitic cysts

From Table (20 and 21) we notice that the age/sex incidence of infection with heteropyids is not varies greatly while the high incidence of heterophyediasis in area of examination (Manzala Lake area) may be due to the high contamination of the lake with human sewage (5 provinces are drained their sewage in the lake as Damietta , Dakahlia , Port-Said , Sharkeia , and Cairo province) The number of fish harbouring metacercariae consumed (Tilapia sp) in this area being more abundant and less expensive The symptoms and lesions were related to the number of infected worms and age of worms The symptoms to be passed unnoticed when the number of the worms burden is low

Hapet of peoples living in Manzala Lake area (Manzala and Matariyah Cities) were eat small fishes as whole The natives call such

food " Bisaria " The fish may be cooked in oil or may be eaten salted and without coking or grilled after cover with a thick layer of bran Tle cooking is so brief that deeper tissues may be raw Therefore it seems likely that trematodes especially heterophyids may parasize man Accordingly heterophyldiasis appear endemic in these area Because the aim of this study is to investigate the incidence of heterophyidae in both fish and man in Manzalla Lake area through

(1) Identification of the parasite by aid of lab animal inoculation with encysted metacercariae , isolated from infected fish Our results indicate a new fish host , the Tilapia for this harmful parasite

(2) Morphology of eggs and mature worm in stool of man living in this area (Manzalla Lake area) We ourselves saw how the people in El-Mattariyah and El-Manzala villages cook their fish are found it semiraw They believe that if the red colour of the fish flesh disappears , their nutritive value is extremely dinminished It is our feeling that , the different media like newspaper , and local radio-broad casting should participate in teaching the fishermen , the healthy way to cook their fish

Several heterophids occur in mammals and birds Only 15 of them are transmitted to man (*Heterophyes heterophes* , *Haplorchis pumilio* , *Haplorchis yokogawai* , *Haplorchis taichui* , *Stellantchasmus falcatus* , *Heterophyes katsuradai* , *Heterophyes conimus* , *Centrocestus armatus* , *Haplorchis michrochis* , *Haplorchis vanissimus* , *Metgonimus yokogawai* and *Stictodora fuscata*) The first five were reported in Egypt (**Tadros**

and El-Mokaddem , 1983) In our study centrocestus was reported in the three species of Tilapia *Heterophyes heterophes* , *Haplorchid* spp as well as *pygediopses* spp were also reported in three species of Tilapia

Heterophyes heterophes was reported in man in Egypt by **Khalil (1983) Kuntz *et al* (1958)** and others The intermediate host was Tilapia and Mugil spp In **1956** in Egypt **Wells and Pandall** discovered new intermediate host for metacercariae of *Heterophyes heterophes* *Heterophyes dispar* and *Heterophyes aequalis* It was Saciaena aquilla (Loot) Solea vulgaris (Samal mousa) No previous records of *Heterophyes dispar* or *Heterophyes aequalis* in intestine of people In this study , *Heterophyes heterophes* was recorded in the three Tilapia spp (*Tilapia nilotica* *Tilapia zilli* and *Tilapia aurea*)

Boulos (1979) and El-Mokadem (1982) enlisted *Pygidiopsis genta* among heterophyid parasites which occur in man in Egypt **Lotfy and Madi (1980)** observed *Pygidiopsis genta* in faeces of human at village of Azraq oasis in Jordan In this study *Pygidiopsis* spp was demonstrated in the three examined spp

Haplorchis pumilio was isolated from intestinal tract of Egyptian people by **Khalil (1932) and Kuntz *et al* (1958)**

It was noticed that young age are more susceptible to infection with Heterophyd in Manzala area This may be due to the immune status which play an important role in the susceptibility of the infection Also , it was noticed that female are more susceptibile to infection than male , may be due to hormonal role

Generally , the infection with Heterophyd in Manzala area (22 3 %) is high this is may be due to the high pollution of the water in this area with human sewage In addition to , the habbit of preparation of fish for consumption , as fish usually covered with thick layer of bran and grill this fish will cause apparently coocked while the actually temperature not sufficient to kill the encysted metacerariae in the muscle of the fish appear so small so fishermen not will coocked these small fish Moreover , presence of low number of snails (intermediate host) *Pirinella conica* or *Melania tuberculata* in which the larvae of parasite mutiply in it In addition to keep of fish in refrigerator (less than 1 - 4 °C) not enough to destroy the parasite cyst as the parsitic cyst need 2 weeks for destruction when put in refrigerator

It is evident from the results achieved from bacteriological examination of fish from Aswan area that the average count of APC of water was 2 x 10^2 / cm^2 This indicate that the water from which fish originate has low bacterial count i e not suffering from pollution

Also it was found that the average coliform count was 1 / cm^2 of fish surface This very low count of coliform indicate that there is no fecal pollution and the presence of non significant numbers of coliform may be due to fishing activity

The failure to detect bacteria in muscles of living fish agree with the finding of some authors who stated that the flesh and body fluids of newly cought fish were sterile and it seems probable that infection in living fish is kept down by continous secreation and slaughing of slime

as protective barrier but in dead fish , the slime certainly acts as good medium for bacterial growth

In addition to , it was found that there is no isolation of primary pathogens although there is some members of Enterobacteriaceae , the presence of this bacteria may be due to water birds and fishing activity

Fish and shell-fish dono't naturally carry a wide variety of pathogens and those contaminating the marketed products are normally derived from environment such as pollution of water in which they live and improper handling after they were removed from water

The flora of fish are influenced quantitively and qualitatively by environment and season and are a reflection of water in which they cought and if the water is polluted the fish will certainly be polluted also

Moreover there was no variation in APC / ml or coliform / 100 ml before and after Rowanda conflict , no pathogenic bacteria were isolated from water or surface and muscles of examined fish

Bacteria isolated from fish surface and intestine in Cairo area were *Escherichia coli* from intestine and fish surface *Klebsiella pneumoniae* , *Enterobacter aerogenes* and *Providencia alcalifaci* from fish surface

Enterobacteriaceae isolated from fish species in Cairo area showed that *Escherichia coli* perform 42 5 % of isolated organisms from fish surface and 81 4 of isolated organisms from the intestine While *Shigella dysentrae* were isolated only from fish surface and perform 4 2 % of

isolated organisms Both two organisms cause intestinal disorders in man

Bacteria isolated from fish muscle , gills , intestine and fish surface from Manzala Lake were Aeromonas hydrophila (from intestine) , *Escherichia coli* (from fish surface , intestine and gills) , *Staphylococcus aureus* (from fish surface) , *Staphylococcus epidermidis* (from fish surface , muscle and gills) , *Edwardsiella tarda* (from fish surface , intestine and gills) , *Citobacter freundii* (from fish surface , gills and intestine) , *Proteus vulgaris* (from fish surface , gills and intestine) and *Klebsiella pneumoniae* (from fish surface , intestine and gills)

It was noticed that APC and coliform counts on fish surface (Lake Manzala) were very high (38 x 10^3 and 21 x 10^3 per cm^2 respectively) , if compared with APC and coliform counts on fish surface of Cairo areas (12 x 10^2 and 15 per cm^2 , respectively)

Also , it was noticed that *Aeromonas hydrophila* was isolated only from intestine It perform 10 5 % of identified isolates , while other isolates were isolated from both fish surface and intestine

From previous observations , it was noticed that when Nile going to northern Egypt , it will carry a heavier load of microorganisms because the human activites along Nile River

Results of bacteriological examination in Alexandria area (El-Max area and Abokir area) revealed that , high Aerobic Plate Count

(APC) and coliform count / cm^2 of fish surface and gm of muscle in El-Max area while in Abokir area the APC / cm^2 and gm of muscle and coliform count are low

The wide range variation in bacterial count between the two areas may be due to contamination of water with sewage or high salinity in Abokir area The high contamination of water with human sewage and freshness of water in El-Max may decrease the die-off of bacteria

Staphylococci isolates from El-Max region were higher than that isolated from Abokir region *Staphylococcus epidermidis* were usually greater in number than that *Staphylococcus saprophyticus* This may be related to the high degree of pollution in El-Max than that in Abokir region

Bacteria were isolated from dead fish obtained from fishermens , at El-Max and Abokir areas So isolation of bacteria were marked from the muscle and visceral organs of fish in both areas

Bacteria were isolated from surface of fish (Tilapia , Mugil, Siganus and Sharagesh sp) and from muscle , liver , kidneys and intestine in high accounts This is due to bacteria after fish deaths may invade the muscle and other organs from intestine Results achieved revealed that the total number of bacterial isolates from El-Max area were higher if copmare with that isolated from Abokir area This may be due to higher contamination of El-Max area with sewage This results coincid

with higher number of isolates of Enterobacteriaceae from fish of El-Max area (53 isolates) than that of Abokir area (28 isolates)

Moreover , one isolate of *Aeromonas hydrophila* and one isolate of *Vibrio alginolyticus* were isolated from El-Sharagesh and Siganus sp at El-Max area , while one isolate of *Pseudomonas aeruginosa* was isolated from from Mugil sp at Abokir area , all of these isolates are of human origin and usually casuing gastro-intestinal disorders

Animal and human wastes have been used in all parts of the world and for many countries to fertilise fields and ponds where fish and aquatic vegetables are grown

The microorganisms under choice of this article are most enteric microorganisms from animals or human origin , as well as others have public health importance

In this study , virological methods depend mainly on viral antigen detection , by different serological techniques which are specific and sensitive for viral antigen detection Some viruses cannot cultivate on tissue culture or assay by the conventional cell culture technique , because it needs many requirement , special equipments and laboratory facilities So , the immunochemical assay methods nave been developed to detect such viruses as antigens (**Kapikian *et al* , 1979 and Blacklow and Cukor , 1980**)

The variations of many viral antigen detection was illustrated in Table (87) The highest percentage recorded were polio , Adeno and rota viruses followed by hepatitis surface B antigens (HB) and hepatitis A (HA) viral antigens On the other hand meseals represent very low percent and no rubella antigen wasc detected The previous results may attribute to the main sources of enteric viruses which are faecal pollution (**Sobsey , 1976**) The polio and some Adeno virus are mainly excreted with faeces in large amount , both viruses are heat stable and resist to different pH and chemicals (**Biberstein and Zee , 1990**)

Regarding the rota virus is also one of enteric virus pathogen , the considerable detectable quantitiy must be in high concentration and examined in faeces and sludge itself The recorded percentage of rota virus in this study (10 42 %) act as a mirror which reflect the highest percentage of sewage pollution with rota virus **Frank *et al* (1993)** reported that rota survives in faeces for several months , some rota viruses are highly resistant to chlorination and can survive for a long period in water supply

Hepatitis surface B antigen and hepatitis A antigen mainly excreted with faeces and urine of infected persons The Hepatitis surface B antigen particles serve as the antigen for the most common diagnostic tests These particles must be present in a large number (**Robinson , 1990**) This explained the low percentage of detection of both hepatitis surface B antigen and hepatitis A antigen

Meseals was detected in very low percent and no rubella antigen was deteced These may be due to the primary site of mutiplication of

both virus is presumed to be in the respiratory tract but the virus can also demonstrat in the urine and faeces which are considered the important sources of infection in infants (**Stewart and Beswick , 1977**)

Table (88) clarfies the gradually decrease of viral antigens as a pathogenic oragnisms in different stabilization pond system (from raw sewage till maturation ponds) which may attribute to many factors related to the pond system as sewage treatment , dilution natural inactivation , time factor , precipitation with sludge and oxidation process which simeltenously reduce the viral number without any compansation of this number due to the viruses are intracellular organisms (**Visnawathan , 1957 , Melnick , 1957 and Andrew *et al* , 1995**) Also the samples and sampling times are very important factors and play an important role in viral detection

6- SUMMARY

A total of 700 Tilapia species and 220 *Clarias lazera* were collected from Bahr Moies, El-Riah El-Tawfiki and their branches, drainage canals and abbasa fish ponds

Examination of the obtained fish revealed that only 57 78% Tilapia species and 51 87% *Clarias lazera* showed obvious clinical symptoms including excess mucus on the skin, emaciation with low body weight darkness of the skin, black patches and or well demarcated black spots on the body surface especially at the area of the caudal peduncle and fins, minute haemorrhag's on the skin, blindness and white spotted eyes, enaliged abdomens and exophthalmia

Gross lesions were mainly muscle nodules of variable size and colour, grey foci on the gill filaments, nodulated and marbling liver, spleen and kidneys, presence of large macroscopic cysts in the branchial cavity and kidney tissues, ascitic fluid in the abdominal cavity and eye pouch

On microscopic examination encysted metacercariae, were found in 81 14% and 85% of the examined Tilapia species and *Clarias lazera* respectively

The highest incidence of metacercarial infestation among both examined and infested Tilapia species was found in the muscles of the posterior third (77 57% and 95 60%) followed by middle third (69 14% and 85 21%), anterior third (62 7% and 77 28%), gills (62% and 76 4%), liver (29 57 and 36 44%), kidneys (23 29% and 36 44%), spleen (16% and 19 72%) eye (16 20 and 13 14%), skin (12 26% and 15 14%) and fins (9 00 and 11 09%)

In *Clarias lazera* the maximum incidence of metacercarial infestation in both examined and infested fish was found in the muscles of middl third (85 00% and 100%) followed by anterior third (71 36% and 83 95%), posterior third (62 27% and 79 14%), liver (49 55% and 58 28%) gills (40 91% and 48 12%), kidneys (31 36% and 36 90%) and spleen (19 55 and 22 99%)

The highest incidence of metacercarial infestation in Tilapia species was found in fish of 100-150 gm and that measured 20-25 cm in length, while in *Clarias lazera* it was found in fish less than 200 gm weight and of length less than 30 cm

The highest incidence of infestation among Tilapia was found in July (96 22%) and March (94 44%) and the lowest in November (65 21%) In *Clarias lazera* the highest incidence was found in June (100%) and November (100%) while the lowest recorded in January (68 42%)

The maximum incidence of infestation in Tilapia was recorded during summer (90 30%) followed by spring (87 58%) and winter (85 96%) while the lowest was reported during autumn (65 57%) In

Clarias lazera the highest infestation rate was found in summer (91 24%) followed by spring (87 43%) and winter (83 26%) and the lowest was obtained during autumn (70 04%)

The maximum number of encysted metacercariae per gram muscles and other organs among tilpia was found in the muscles of the posterior third (34 936 /gm) followed by that detected in middle third (23 21/gm), anterior third (13 23/gm), liver (4 05), fins (3 38), skin (3 44) kidney (2 84), spleen (1 92), eye lenses (1 24) and in branchial cavity (0 16)

The highest number of metacercariae (per gram) was recorded during spring in the muscles of posterior, (62 87), middle (38 36) and anterior third (21 35) as well as in skin (12 46), fins (11 19) Liver (5 42), kidneys (4 86) and spleen (2 94) While the lowest number was detected during autumn

In *Clarias lazera* the maximum number of encysted metacercariae per gram muscle and other organs was reported in muscle of middl third (51 893) followed by anterior (33 294), posterior third (24 738), liver (5 86), kidneys (3 66) and spleen (1 52), with respect to the effect of season, the highest number was found during winter and the lowest recorded during autumn

The encysted metacercariae obtained from Tilapia species were identified as Prohemistomatide, Diplostomatide Haplorchide Heterophyide, Echinostomatide, Euchinostomatide and Clinostomatide, metacercariae, while those recovered from *Clarias lazera* were found to

be belonging the families Prohomistomatide, Diplostomatide, Haplorchide and Cyanodiplostomatide

Histopathological reactions around the encysted parasite in fish muscle and organs varied in severity according to the species of the infested metacercariae In muscle the inflammatory reaction was represented by aggregation of lymphocytes, macrophages, esinophilic granular cells and melanin-carrying cells Degenerative and necrotic muscular changes beside pressure atrophy, were also found Kidney tissues showing aggregation of lymphocytes, macrophages and excessive number of melanin-carying cells, in addition vacuolar and granular degeneration of tubular epithelium and somesort of haemorrhage between kidney tubules and around parasitic elements Some tubules suffered from necrobiotic changes with coagulative necrosis of their epithelium atrophy of capillary tuft of the glomeruli and edema in Bawman's capsule

Moreover the infested liver showed granuiomas and parasitic nodules, dissociation of pancreatic acini and coagulative necrosis of hepatocyts The infested gills showed presence of multiple small sized parasitic cyst causing pressure atrophy on cartilagenous specules of the gill filaments or ending with cartilagenous hyperplasia or metaplasia

All the previously described species of metacercariae were experimentally fed to week-old chicks, baby chicks, day-old ducklings (pickini and balady), squabs, quails, herons and moorhens

Heavely infested birds showing obvious clinical symptoms and lesions and their intestine contained different species of trematode

worms The recovered trematodes identified as *Diplostomum ibis* sp nov, *Diplostomum niloticus* sp nov, ornithodiplostomum, *Echinochasmus japonicus* *Echinochasmus beleocephalus*, *Nephrostomum ramosum* *Apharyngistrigia ibis*, *Prohemistomum vivax*, *Mesostephanus* (M) *appendiculatus*, *M fajardensis*, *M flapi*, *Paracenogonimus ovatus* *Holostephanus volgensis*, *Heterophyes equalis* *Heterophyes dispar*, *Pygidiopsis genata*, *Pygidiopsis summa*, *centrocestus armatus*, *Ascocotyl mncintochi*, *Metagonimus yokojawai*, *Haplorchis pumilio* *Haplorchis yokojawai* and *Haplorchis disca*

Histopathological changes in the intestine of infested birds with mature worms showing hyperplastic proliferation of mucus gland at the wall of intestinal crypts especially at the basal portion and in areas neighbouring to attachement of parasite while at the site of the parasite the intestinal villi revealed lake of mucus glands with necrosis of epithelial lining, dilated blood vessels in lamina propria associated with few number of inflammatory cells Sometimes the intestine showing sever destruction of the epithelial lining and their crypts displayed excessive haemorrhages and leucocytic infiltration between intestinal glands In some cases the intestinal lumen appeared as a bag filled with necrotic debris haemorrhage's and few number of inflammatory cells

For studying the effect of temperature on the viability of the EMC, a total of 422 Tilapia fish and 120 *Clarias lazera* were collected from Bahr Moies, El-Riah El-Tawfiki and their branches and drainage canals

Regarding to the effect of heat on the viability of encysted metacercariae, boiling of the infested Tilapia and *Clarias lazera*, for 5 minute were sufficient to loss the viability of the cysts, while frying of

infested Tilapia and *clarias lazera* for 5 minute were quite sufficient to loss the viability of the cysts found in small and medium sized fish while 10 minute were required for cysts laden in the muscles of large sized fish

Grilling of the infested Tilapia on each side for 5 minute were sufficient to lose the viability of encysted metacercariae found in small size while in medium sized fish the viability lost after 10 minutes

Chilling of the infested Tilapia at 4 °C revealed that the encysted metacacercariae of Diplostmatide and Echimostomatide showed rapid lose in their viability on the second day post chilling On the other hand the encysted metacercariae of Prohemistomatide, Haplorchid Heterophyid, Diplostomatide, Euchinostomatide and Echinostomatid loss their viability completely at 18,17,15,14 8 and 5 day post chilling respectivelly While the encysted metacercariae of Prohemistomatidae, Haplorhcide Diplostomatide and Cyanodiplostomatide recovered from the infested *Clarias lazera* lost their viability at 14,12,14 and 16 day post chilling respectivelly

The encysted metacercariae infested Tilapia fish lost their viability by freezing at -4°C or -5°C, -10°C, 15°C and -20°C for Prohemistomatide after 48, 32, 24 and 16 hours post freezing (PF) respectively, for Haplorchid after 40, 32, 24 and 16 hour PF, respectively, for Diplostomatide after 32, 24,16 and 8 hours PF respectively, for Echinostomatidae at 24, 16 16 and 8 hours PF respectively and for Euchinostomatidae after 32,24,16 and 8 hours PF respectively

In infested *Clarias lazera* the obtained encysted metacercariae lost their viability by freezing at -4°C or -5°C, -10°C -15°C and -20°C for Prohemistomatide after 32,24,16 and 8 hours PF respectively, for Haplorchide after 32, 16,16 and 8 hours PF respectively, for Diplostomatidae after 24, 16,16 and 8 hours PF respectively and for Cyanodiplostomatidae after 32,24, 16 and 16 hour PF respectively

The results from the bacteriological study indicated that the absence of bacterial contamination in the muscles in all fish samples from all localities On the other hand , the bacterial load on the fish surface reflected the degree of water contamination Levels of APC / cm2 and coliform / cm2 of fish surface were highest in samples from the polluted water of Lake Manzala and the lowest levels were observed in samples of fish from Aswan

In conclusion from this bacteriological study , while Nile goes to Northern Egypt , its microbial loads increase as a result of increased human activites on the river which give it no chance sufficient for self purification of water

7- REFERENCES

Abd El-Azim, M A (1938)
On the intestinal helminthes of dogs in Egypt
J Egypt Med Ass , 21 (3) 118-122

Abd El-Hafez, A A T (1996)
Clinicopathological and Morphological studies on some affection of Nile-catfish PhD Thesis, Fac of Vet Med (Moshtohor) Zagazig Univ

Abd El-Salam, F A , Mahmoud, N A M and Abd El-Gawad, A F (1987a)
Some studies on metacercarial infection in Schilbe mystis freshwater Nile-fish at Sohag Province, Egypt Experimental infection of newly hatched chicks fed with viable metacercariae of Stictodora tridactyla Martin and Kuntz, 1955 and Prohemistomum vivax Sonsino 1892 Assiut Vet Med J 19 (37) 58-65

Abd El-Salam, F A , Mahmoud, N A M and Abd El-Gawad, A F (1987b)
Some studies on metacercarial infection in Schilbe mystis freshwater fish at Sohag province, Egypt Experimental infection in squabs fed with viable metacercariae of P Vivax Assiut Vet Med J , 20(39) 74-77

Africa, C M , Deleon, W and Garica, E Y (1935)
Heterophyiasis II Ova in sclerosedmitral valves with other chronic lesions in the myocardium
J Philip Islands Med Ass , 15 583-592

Africa, C M , Deleon, W and Garcia, E Y (1936)
Heterophyiasis IV Lesions found in the myocardium of eleven infected hearts including three cases with valvular involvement Philip , J Pub Health 1(2) 1-27

Ahmed, A A S (1981)
Studies on Heterophyes heterophyes
M Sc Thesis Fac of Med Tanta Univ , Egypt

Ahmed, SH M , Hussein, S Y and Sadiek, A H (1994)
Diplostomiasis or black spot disease in Clarias lazera at Assiut
Assiut Vet Med J 31 (61) 115-123

Ahmed , S M (1983)
Natural and experimental studies on Motile *Aeromonas* septicemia in freshwater fish (*Tilapia nilotica*) M V Sc Thesis Fac , Vet Med Assiut Univ

Akealah (1987)
Some studies on the intestinal flora of the genus Tilapia in Manzalah fish farm M V Sc Thesis , Fac Vet Med , Zagazig Univ

Al-Bassel, O H M (1990)
Studies on the helminth parasites of some fishes from some inland water in Egypt Thesis for the Award of Ph D Degree of Science

Allan , B J and Stevenson , R M W (1981)
Extracellular virulence factors of *Aeromonas hydrophila* in fish infactious Can J Microbiol , 27 1114 - 1122

Amer, O H , Nada, M S and Dosoky, E A (1988)
Further study on some digenetic trematodes from fresh water fishes Bull Fac Sci Zagazig Un , 10(1) 469-483

Amer, O H and Gattas, W (1993)
Studies on the role played by freshwater fish in trasmitting of some trematodes to fish eating birds J Egypt Vet Med Ass 53 (1&2) 121-127

Amin O A (1969)
Helminth fauna of suckers (Catostomidae) of the Gilla River system Arizona II Five parasites from catostomus supp American Midland Naturalist 82 429-443

Amin , N and Easa , M S (1982)
Microbiological and pathological investigation of motile *Aeromonas* in experimentally inoculated *Clarias lazera* Proc of 3rd Pan-Africa Vet Congress Sudan Vet Assoc

Amin , N E , Abdallah , I S Elallawy , T and Ahmed , S M (1985)
Motile *Aeromonas* septicaemia among *Tilapia nilotica* (*Sarotherodon niloticus*) in Upper Egypt Fish Pathol , 20 93 - 97

Amin, A M , Omar, A H , Mahmoud, A M , Labib, E M and Shihata, A A (1993)
Occurrence of trematodes of zoonotic importances in marine fish in Egypt Zag Vet J Vol 21(2) 259-277

Amlacher , E (1970)
Textbook of fish diseases , P, 117 - 135 T F H Publication Inc Neptune , USA

Andrew , D , E , Lemore , S and Arnold , E (1995) Standard methods for examination of water and wastewater Publication office American Public Health Association 1015 15 street , NW Washington , D C 20005

Antonov, P P and Sapozhnikov, T I (1981)
Control of diplostomatid and ligulid infection by the introduction of coregonid fish UFA, USSR Ul'Yanovskii Sel'Skokhozyaistvennyi Institut 52-54

American Public Health Association " APHA " (1989) Standard methods for examination of water and wastewater 17 ed , APHA Inc , New York

Attwood H D and Dennett (1977)
Clonorchis sinesis Aust J Med Technol , 6 99 - 100

Azim, M A (1935)
Entwicklung segeschichte von Apharyngostriage ibis n sp dem Reiher Ardeola ibis ibis Z Parastitkde, 7, 608-614

Azim, M A (1938)
On the intestinal helminths of dogs in Egypt, J Egypt Med Ass 21(3) 1-5

Bassiouni, G A (1979)
Studies on heterophyiasis and its chemotherapy Ph D Thesis (Parasitology) Faculty of Medicine, Cairo University

Beaver, P C ; Jung, R C and Cupp, E W (1984) .
Clinical parasitology Lea & Febiger, Philadelphia PP 825

Belov , G F and Feiginova , F A (1969)
Clinical classification of opisthorchiasis Nauchyne Novosibirskogo Gosudarstvennogo Meditsinskogo Instituta, 46 289 - 292

Bergey's Manual (1984)
Determinative Bacteriology 9th ed Buchanan , R E and N E Gibbon (Eds) Williams and Wilkins Co , Baltimore

Berrie, A D (1960)
Two Diplostomulum larvae (strygeida, trematoda) in the eyes of stckle-backs (Gasterosteus aculeatusl) J Helminth , 34 (3/4) 211-216

Biberstein , E and Zee , Y C (1990) Review of veterinary microbiology Blackwell Scientific Publications Inc , Boston , Oxford , London

Bilgees, F M (1972)
Freshwater fish trematodes of Pakistan III Metacercarial forms of Euclinostomum Travassos 1928 from Ophiocephalus spp Acta Parasit pol (1972) Vol XX 55-62

Bindseil, E and Christensen, N (1984)
Thymus-independent crypt hyperplasia and villous atrophy in the small intestine of mice infected with the trematode Echinostoma revolutum Parasitol 88, 431-438

Black , N R and Cukor , G (1980) Viral gastroenteritis agents , chap 90 in E H Lennette , A Balows , W J Hausler , J and J P Truant , ed Manual of clinical microbiology , Washington , D C

Blair, D (1974)
The life cycles of Apatemon spp (trematoda Strigeidae) with metacercariae in fishes Parasitol Vol 96 XV

Bitton , G (1980) Introduction to environmental virology John Wiley and Sons , Chichester , New York

Boulanger , Y , Lallier , R and Cousineau , G (1977)
Isolation of enterotoxigenic *Aeromonas* from fish Cand J Microbiol 23 (9) 1161 - 1164

Boulos, L M (1979)
Parasitological studies on the Heterophyids in Tilapia fish from Edku and Maryiut lakes and the transmission to laboratory animals M D Thesis Fac Med , Alex Univ

Boulos, L M , Abdou, L A and Girgis, R S (1981)
Histopathological and Histochemical studies on experimentally infected hamsters with Pygidiopsis genata J Egyption Soc Parasit , 11 (1) 67-76

Brglez, J (1983)
Diplostomid trematodes in birds life in Yugoslavia Akademieverlag PP 149-153

Britz J , As J G Van, and Saayman, J E (1984)
Notes on the morphology of the metacercaria and adult of Clinostomum tilapiae Ukoli, 1966 (Trematoda, Clinostomatidae) South Africa J Wildlife Res 14 (3) 69-72

Brown, H W and Neva, F A (1983)
Basis clinical parasitology" 5th ed PP 175-179

Brynhildsen, L , landrgen B V , Allard B and Rosswal T (1988)
Effect of glucose concentration on Cadmium, Copper, Mercury and Zinc toxicity to *klebsiella* Spp Appl Environ Microbiol 54 1689-1693

Buchmann, K (1986)
Prevalence and intensity of infection of Cryptocotyle lingua (Creplin) and Diplostomum Spathaceum (Rudolphi) parasitic metacercariae of Baltic cod (Gadus morhua L) Nordisk Vet 38 303-307

Callot, J (1939)
Particularities biologiques de la metacercariae de Posthodiplostomum cuticola (Von Nordmann) Annales Parasit hum Comparee 17(4) 332-335

Campbell, R A (1973)
Studies on the biology of the life cycle of Cotylurus flabelliformis (trematoda Strigeidae) Transact Amer Microsc Soc 92(4) 629-640

Campbell, L M , Michael , G , Klein , R D and Roth L I (1976) .
Isolation of *klebsiella pneumoniae* from lake water Can J Microbiol 22 1762-1767

Carleton, M A , Grury, R A B , Wallington, E A and Carmeron, H (1967)
Carlton's histopathological technique Oxford University Press, New York

Carmen, C V (1973)
Observation on some Heterophyidae (Trematoda Digenea) encysted in Philippine fishes J Parasit 59 77-84

Carnahan, A M and Joseph S (1990)
Aeromonas update New species and global distribution Abstract of International Symposium on *Aeromonas* and *Plesiomonas* L-Skolen, Hesingor, Denmark Faculty of Medicine, Lund University, Sweden

Chakrabarti, K K (1974)
Studies on some metacercariae of the Indian fresh water fishes, Channa punctatus (Bloch) and C Striatus (Bloch) Rev Iber Parasit 34 (1/2) 57-81

Chai, Y , Seo, B , Lee, S and Hong, S (1986)

Growth and development of Pygidiopsis summa in rats and mice with a supplementary note on its morphological characters Korean J Parasit 24 (1) 55-62

Chai, J and Lee, S (1990)
Intestinal trematodes of humans in Korea Metagonimus, Heterophyids and Echinostomes Korean J Parasit 28, 103-122

Chainuvati, T , Paosawadhi, A , Sripranoth, M , Manasatith, S and Viranuvatti, V (1976)
Carcinoma of the cystic duct associated with opisthorchiasis Southeast Assian J Trop Med Publ Health, 7 462 - 486

Chappell, L H , Hardie, L J and Secombes, C J (1994)
Diplostomiasis the disease and host-parasite interactions PP 59-86 in Pike, AW and Lewis, J W (Eds) Parasitic diseases of fish, Dyfed, Samara Publishing Ltd

Chen, T C and levin R E (1975)
Isolation of Aeromonas Sp Atcc 29063 aphenol producing organism from fresh haddock Appl Microbiol , 120-122

Colwell, R R , MacDonell, M T and Deley J (1986)
Proposal to recognize the family Aeromonad aceae fam Nov Internation Journal of Systematic Bacteriology, 36 (3) 473 - 477

Choi, J J (1977)
Epidemilogical studies of Clonorchis serensis in vicinity of Chinju, kyungnam Province, Korea, J Bussan Med College, 17 (11) 79-87

Chopra, A K , Arun Kumar and Singh, H R (1987)
Inflammatory response of the integument to the metacercarial infection in cold water fish, Schizothorox spp Acta Parasit Pol 32 (4) 353-356

Ciurea, I (1916)
Prohemistomum appendiculatus eine neue Holostomidenart aus Hunde und Katzendarm, dessen infirtiansquelle in den

Susswasserfischen zu suchen ist Zeitschr Inf Krht Haust, 17 (5) 309-338

Cnu I (1970)
Trematode infection in Korea Official J Res Inst Med Sci, Korea, 2 33 - 40

Coolidge, B J and Haward, R M (1979)
Animal Histology procedures NIH publication No 80-275 Department of health

Cornelis, G , Laroche, Y , Balligand, G *et al* (1987)
Yersinia enterocolitica , a primary model for bacterial invasiveness Rev Inf Dis , 9 (1) 64 - 87

Cruickshank , R , Duguid, J R , Marmion, B P and Swain, R H (1975)
Medical Microbiology 12th Ed , Churchill Livingstone , Edinburgh and New York

Davis, D J (1936)
Pathological studies on the penetration of the cornea of Strigeid trematode, Diplostomum flexicaudaum J Parasit 22 329-337

Davis, W A , Kane, J G and Garagus V F (1978).
Human Aeromonas infection Medicine (Baltimore) 57 267-277

Dawes, B (1946)
The trematode with special reference to British and other European forms Cambridge Univ Press

Dean, H M and Tost R M (1967)
Fatal infection with *Aeromonas hydrophila* in a patient with acute Mylogenous leukemia Annuals of Internal Medicine, 66 1177 -1179

Delor, I and Cornelis, G R (1992)

Role of *Yersinia enterocolitica* yst toxin in experimental infection of young rabbits Infect Immun , 60 (10) 4269 - 4277

Dennis, E A and Penner, L R (1971)
Mesostephanus yedae sp n (Trematoda Cyathocotylidae), its life history and description of the developmental stages Occasional papers, University of Connecticut 2(2) 5-15

Dennis, E A and Marian Sharp (1973)
Morphology of Euclinostomum heterostomum (Rudolphi 1809) (Trematoda Clinostomatidae) from Bulbicus ibis J Helminth 47 17-25

Dietz, E (1909) ·
Die Echinostomiden der vogel Zool Anz 34 (6) 180-192

Dippon, R and Widmer, A (1976)
Trematodes in bile ducts Helvetica Chirurgica Acta, 43, 553-55

Dogiel, V A , Petrushevski, G K and Polyanskimu, I (1961)
Parasitology of fishes Oliver and Boyd, Edinburgh and London

Dogiel, V A , Petrushevski, G K and Polyanski, YU I (1970)
Problems of fish parasities T F H Publications, Inc Ltd Hong Kong

Donges, J (1967)
Parasitically induced formation of melanin in fishes Z Parasitenk 29 310-312

Donges, J (1974)
The life cycle of Euclinostomum heterostomum (Rudolfi, 1809) (Trematoda Clinostomatidae) Int J Parasit, 4 79-90

Dubois, G (1935)
Contribution a L'etude de quelques parasites de L'order des strigeatoidea Rev Suiss Zool 42 (1) 1-19

Easa , M El S and Hatem , M E (1986)
A record of Aeromonosis infection in Liza ramada in a fish farm in Port-Said , Egypt IV th International Symposium of Veterinary Laboratory Diagnosticians , Amsterdam , Holland , P 428 - 431

Edelman M H and Soingarn C L (1949)
Clonorchiasis in the United States report of four cases J Am Med Ass 140 1147 - 1150

Ebtsam, A G T (1993)
Muscular parasites in markets fishes M V Sc Thesis of Hygiene and Food control, Fac of Vet Med , Cairo, Univ

Eddy , B P (1962)
Cephalotorchous, fermentative Gram negative bacteria genus Aeromonas J Appl Bacteriol, 23 216 - 249

Edwards P R and Fwing , W H (1972)
Identification of enterobacteriaceae 3rd Ed Burgess publication Co , Atlanto , U S A 208- 337

El-Aroussi, N M (1984)
Morphological and biological studies on some trematodes of fish-eating mammals with emphasis on the role of fishes as second intermediate host M Sc Thesis (Zoology), Fac Sci , Cairo, Univ

El-Attar, El S R (1988)
Correlative experimental pathologic studies on Bilhariziasis and Cysticercus fasciolaris in mice and some related fish parasitiies Ph D , Thesis, Faculty of Vet Med , Zagazig, Univ

El-Bouhy, Z M , Saleh, G , El-Desoky, E A and Ali, A A (1988)
Studies on yellow grub infestation in Nile catfish (Clarias lazera) in Sharkia Province Zagazig Vet J Vol XVII No 2(B), P 166-186

El-Dally, K M H (1988)
The role of fish as intermediate host for transmitting some parasites of zoonotic importance in Behera Governorate

M V Sc Thesis, Fac of Vet Med , Alex Univ

El-Gindy, M S (1961)
Larval trematodes found in Planorbid snails in Egypt (A R E) J Egypt Med Ass 44, 382-393

El-Mokaddem, A (1982)
The prevalence of Heterophyids in man, animals and various fish hosts in Edku area Thesis M Sc Public Health, Sci High Ints P H P Alexandria Univ

El-Mossalami, E and Sherif, H I (1964)
Encysted metacercariae in the muscles of Clarias lazera (Armout - catfish) Ceylon Vet J , 7 50-53

El-Naffar, M K (1979)
Parasites of the Egyptian moorhens Diplostomum magnicaudium Nov with part of its life cycle J Egypt Soc Parasitol 9 (2) 349-358

El-Naffar, M K (1980)
Studies on Heterophyid cercariae from Assiut Province, Egypt II The life cycle of Haplorchis cahirinus (Loss, 1896) J Egypt Soc Parasitol 10(1) 117-125

El-Naffar, M K and El-Shahawy, G A (1986)
Studies on the metacercariae of the Nile fishes at El-Minia province, A R E Assiut Vet Med J 15 (30) 47-54

El-Naffar, M K and Khalifa, R (1975).
Parasitofauna of the Egyptian aquatic birds I Trematode parasites of the bufr-backed herum (Ardeola ibis ibis) in Assiut Governorate, Egypt J Egypt Soc Parasit 4 42-55

El-Naffar, M K and Khalifa, R (1979)
Euclinostomum ardeola sp Nov (Trematoda Clinostomatidae) with the description of its life cycle J Egypt Soc Parasit 9 42-55

El-Naffar, M K and Khalifa, R M (1981)

Euclinostomum ardeolae sp nov (Tiematoda Clinostomatidae) J Egypt Soc Parasit, 11(1) 175-181

El-Naffai, M K, Khalifa, R and Sakla, A A (1980)
Parasitofauna of the Egyptian aquatic birds II Trematode parasites of the Giant heron (Ardea goliath) in Assiut Goveinoiat J Egypt Soc Paiasit 10(1) 107-116

El-Naffai, M K, Saoud, M F and Hassan, I M (1985)
Role played by fish in tiansmitting some tremadoes of dogs and cats at Aswan Piovicne Assiut Vet Med J, 14 (27) 57-67

El-Reid, A M (1994)
Role of maiine fish in tiansmission of some parasites to animals and birds Ph D Thesis (Paiasitology) Fac of Vet Med Zagazig University

El-Sayed, N M A, (1994)
Helminth paiasites of some wild biids M V Sc Thesis, Fac of Vet Med, Zagazig Univ

El-Sherbiny, M M T (1988)
Paiasits in maiket fish and its public health importance M V Sc Thesis, Fac of Vet Med, Cairo Univ

Enany, M M (1983)
Biochemical, Serological and biological properties of *Aeiomonas* species isolated from fish Ph D Thesis Fac of Vet Med Zagazig Univeisity

Ewing, W H, Hugh, R and Johnson J G (1961)
Studies on *Aeiomonas* giouf P 37 In Public Health Service Monogr CDC, Atlanta USA

Fahmy, M A M and Selim, M K (1959)
Studies on some trematode parasites of dogs in Egypt with special refeience to the role played by fish in their tiansmission Z Paiasitenk, 19 (1) 3-13

Fahmy, M A M , Mandour, A M , Arafa, M S and Amran, L A M (1976)
Larval trematodes recorded from Melania tuberculata in Assiut Province Part I Assiut Vet Med J 3(5) 239-247

Fahmy, M A M , Khalifa, R and Youssef, H (1980)
Effect of salting and freezing on the viability and infectivity of the metacercariae of Haplorchis pumilio (Louss, 1896) and Prohemistomum vivax (Sonsino, 1983) Assiut Vet Med J 7

Fahmy, M M , Afafa, M S , Khalifa, R , Abdel-Slam, A M and Mounib, M E (1982)
Studies on Helminth parasites in some small mammals in Assiut Governorate I Trematode Parasites Assiut Vet Med 11 (22) 43-53

Fahmy, M A M , Khalifa, R and Makhlouf, L M (1986)
Studies on Heterophyid cercariae from Assiut Province II The life cycle of Haplorchis yokojawai (Katsuta, 1936) trematoda Heterophyidae Ass Vet Med J 16 (31) 120-132

Faisal, M , Popp , W and Refia , M (1989)
Bewegliche Aeromonaden septikamie bei dem Nil Tilapia orechromis motilicus Beol Munch Tierazl Wsc

Faisal, M H S , Abd El-Hamid , H A , Torky , M K Soliman and M Abou El ,Wafaa (1984)
Distribution of *Aeromonas hydrophila* in organs and blood of naturally and experimental infected or *Oreochromis niloticus* J Egypt Vet Med Ass 44 4 - 11

Faistey, V (1986)
Centrocestus sp (Heterophyidae) and other trematode infection of the snail Melanoides tuberculata (Muller 1774) and Cichlid fish in lake Kinneret unpublished M Sc Thesis, Hebrew University of Jerusalem, 1986 (Hebrew text, English Summary)

Faust, A C (1955)

Animal Agents and Vectors of Human Diseases" Lea and Febiger

Fayek, S A . Nada, M S and Ahmed, B A (1986)
Heterophyid parasites recovered from dogs with special reference to Phagicola longus (Ransom, 1920) Vet Med J , 34 (2) 201-210

Ferguson, M S (1940)
Excystation and sterilization of metacercariae of the avian strigeid trematode, Pasthodiplostomum minimum and their development into adult worms in strile cultures J Parasit 26 359-372

Ferguson W W and Henderson N P (1947)
Description of strain C27, a motile organism with the major antigen of *Shigella sonnei* phase 1 J Bacteriol , 54 179 -181

Filimonova, L V (1979)
The phenomen of "amphixeny" in the trematode Echinochasmus japonicus Zoologicheskii Zhurnal 58(8) 1103-1109

Finegold , S M and Martin , W J (1982)
Diagnostic Microbiology 6th ed , The C V Mosby Company USA

Fischthal, J H and Kuntz, R E (1963)
Trematode parasites of fishes in Egypt Part VI The metacercariae of Euclinctomum heterostomum (Rudolphi, 1809) travassos, 1928 (Clinostomatidae) with a review of the genus Trans Amer Microscop Soc 82(3) 335-342

Flynn T and Knepp I (1987)
Seafood shucking as an etiology for *Aeromonas hydrophila* infection Arch Inter Med , 147 1816 - 1617

Flody T M and Jones G B (1954)
Isolation of *Shigella* and *Salmonella* organisms from Nile fish Am J Trop Med Hyg , 13 475 - 480

Animal Agents and Vectors of Human Diseases" Lea and Febiger

Fayek, S A , Nada, M S and Ahmed, B A (1986)
Heterophyid parasites recovered from dogs with special reference to Phagicola longus (Ransom, 1920) Vet Med J , 34 (2) 201-210

Ferguson, M S (1940)
Excystation and sterilization of metacercariae of the avian strigeid trematode, Pasthodiplostomum minimum and their development into adult worms in strile cultures J Parasit 26 359-372

Ferguson W W and Henderson N P (1947)
Description of strain C27, a motile organism with the major antigen of *Shigella sonnei* phase 1 J Bacteriol , 54 179 -181

Filimonova, L V (1979)
The phenomen of "amphixeny" in the trematode Echinochasmus japonicus Zoologicheskii Zhurnal 58(8) 1103-1109

Finegold , S M and Martin , W J (1982)
Diagnostic Microbiology 6th ed , The C V Mosby Company USA

Fischthal, J H and Kuntz, R E (1963)
Trematode parasites of fishes in Egypt Part VI The metacercariae of Euclinctomum heterostomum (Rudolphi, 1809) travassos, 1928 (Clinostomatidae) with a review of the genus Trans Amer Microscop Soc 82(3) 335-342

Flynn T and Knepp I (1987)
Seafood shucking as an etiology for *Aeromonas hydrophila* infection Arch Inter Med , 147 1816 - 1617

Flody T M and Jones G B (1954)
Isolation of *Shigella* and *Salmonella* organisms from Nile fish Am J Trop Med Hyg , 13 475 - 480

Gerba , C P and Goyal , S M (1982) Methods in environmental virology Marcel Dekker , New York

Glunder, G and Siegmann , O (1989)
Occurance of *Aeromonas hydrophila* in wild birds Avian Pathology , 18 (4) 685 - 695

Ghittino, P D (1972)
Aqua-culture and associated disease of fish of public health importance J Amer Vet Med Ass , 161 1476-1485

Gohar, M (1935)
Lists des trematodes parasites et de leur hotes du Nil Deuxieme Partie Ann Parasit hum Comp 13 83-90

Gomaa, T (1962)
Pulmonary complications of Heterophyes infection J Egypt Med Ass 45 317-322

Grabda, K B (1974)
Clinostomum complanatum (Rudolphi, 1819) and Euclinostomum heterostomum (Rudolphi, 1809) (Trematoda, Clinostomatidae), their occurrence and possiblity of acclimatization in artificially heated lakes in poland Acta parasit pol 22(22/34) 285-293

Gupta, P C and Gupta, S P (1979)
On two avian trematode parasites (Family Heterophyidae odhner, 1914) from kanpur Indian J Helminth (1977, publ 1979) 29 (1), 73 - 78

Gupta, V and Jahan, A (1979)
On four new trematodes of Echinostomatidae Poche, 1926 from birds Indian J Helminth (1977, publ 1979) (1) 57-72

Hamed, M G E and Elias, A N (1970)
Effect of food processing methods upon survival of the trematode Heterophyes sp in flesh of mullet cought from brackish Egyptian water J Fodd Sci 35(4) 386-388

Hartley J P R and Douglas A F (1975)

A case of colonorchiasis in England Brit Med J , 3 575

Head , C B , Whitty , D A and Ratnam , S (1982)
Comparative study of selective media for recovery of *Yersinia enterocolitica* J Clin Microbiol , 16 (4) 615 - 621

Heckerling , P , Stine , T , Pottag , J , Levin , S and Harris A, (1983)
Aeromonas hydrophila myonecrosis and gas gangrene in a nonimmuno compromised host Arch Inter Med , 134 2005 - 2007

Hefnawy, Y , Srefai R and Sabah Moustafa (1989)
Prevalence of some potential pathogens in Nile fishes in Upper Egypt Assiut Vet Med J , 21 (42) 101 - 108

Holt , J H , Krieg , N R , Sneath , P H , Staley , J T and Williams, S T (1994) Bergey's manual of determinative bacteriology , 9th ed Williams and Wilkins , Baltimore

Hoffman, G L (1958)
Experimental studies on the cercaria and metacercaria of a strigeid trematode, Posthodiplostomum minimum Exp Parasitol , 44 416

Huffman, J E , Michos, C and Fried, B (1986)
Clinical and Pathological effects of Echinostom revoutum (Digenea Echinostomatidae) in the golden hamster Mesocricetus auratus Parasitology, 93, 505-515

Hyung lee, S , Hwang, S K , Jong, Y C and Seo Byong-Seol (1984)
Comparative Morphology of eggs of Heterophyids and Clonorchis sinensis causing human infection in Korea Korean J Parasit 22 (2) 171-180

Hus , T C , Shotts , E B and Waltman W D (1985)
Action of *Aeromonas hydrophila* complex on carbohydrate substrate Fish pathology , 20 (1) 23 - 35

Hyung Lee, S , Yilchai, J , Yang, E , Yun, K , Sung-Tae, H and Lee, J B (1988)

Observation of liver pathology after praziquantel treatment in experimental Clonorchis Sinensis infection in Guinea pigs Sooal J Med 29(3) 253-262

Ibrahim, M M and Mahmoud, N A A (1988)
Histological studies on lesions induced by Ampliceaum type larvae (Nematoda) in some predatory fish species at High Dam Lake,Egypt Egypt J Comp Pathol Clin Pathol, 1 (1)

ICMSF (1978)
Microorganisms in Food Their Significance and Methods of Enumeration 2nd Ed, Univ of Toronto Press, Toronto

Imam, F A, Hasan, A A, El-Shabrawy, M N and Tawfik, M A (1979)
On some parasites of Nile fishes in Egypt
J Egypt Vet Med Assoc, 39(1) 119-126

Issa, G I and Ibaid, N M (1969)
Trematodes of Nile fishes VI Population density of digenic trematodes in freshwater fishes J Egypt Vet Med Assoc, 29 (3/4) 183-188

Ito, J and Mochizuki, H (1968)
An epidemiologic study of human helminthes in Shizuoka prefecture VI The metacercarial funna in fresh and brackish fish Jap J Parasit, 17(2) 69 - 74

Jaiswal, G P (1957)
Studies on the trematode parasites of fishes and birds found in Hyderabad state Part I-IV Zool Jahrb, Jena, Abt Syst, (85) 1-72

James, A G, Hum D G and Brownell C L (1988)
A note on the incidence and treatment of a bacterial infection of wild pelagic fish maintained in the laboratory South African Journal of Marine Scienece, 6 13 - 15

Janda, H M, Lark R B and Branden R (1985)
Virulence of *Aeromonas* species as assessed through mouse lethality studies Current Microbiology, 12 163 - 168

Jinpei, P (1983)
Studies of the late stage of the life history of two strigeid trematodes with notes on the histological observation and histochemical properties of the cyst wall J of Fisheries of China (1983) 7(3) 235-249

John, D S (1966)
Fish and fish inspection, 2nd edition, H K lewis and Co Ltd University press London

Jong, Y C, Sung, J H, Woon, S, Hyung, Lee, S and Seo, B S (1985)
Further cases of human Heterophyes heterophyes infection in korea Seoul J Med 26(2) 197-200

Joseph, S W, Carnahan, A M, Brayton, P.R, Fanning, G R, Almazan, R, Drabick, C, TrudoJr, E W and Colwell, R R (1991)
Aeromonas Jandaei and *Aeromonas veronii*, dual infection in human wound following aquatic exposure J Clinical Microbiol, 29 (3) 245-250

Kalantan, A M W, Arfin, M and Nizami, W A (1987)
Seasonal incidence and pathogenicity of the metacercariae of Clinostomum complanatum in Amphanius dispar
Jap J Parasit 36 (1) 17-23

Kammerer, W S, Vandecker, J D, Keith, T B and Mott, K E (1977)
Clonorchiasis in New York City Chinese Trop Doc, 7 105 - 106

Kapikian, A Z, Yolken, R H, Greenberg, H B, Wyatt, R G, Kalica, A R, Chamock, R M and Kim, H W (1979)
Gastroenteritis virus In E H Lennette and N J Schmidt eds Diagnostic procedures for viral, rickettsial and chlamydial infections American Public Health Association, Washington, D C

Karmanova, E M (1974)

The life cycle of Echinochasmus Coaxatus and E bleocephalus trudy Gel minthologicheskoi laboratorii 24 45-53

Katsuata, F (1912)
On a new tiematode, Metagonimus yokogawai Tokyo Iji shinshi, (796), 3483-3489

Katsurada, F (1912)
On a new trematode, Metagonimus yokogawai, Tokyo Iji Shinshi (1796) 3488-3489

Katsurada, F (1914)
Studien uber tiematodenlarven bei susswasser fischen mit besondeiei Beiucksichtigung dei Eibe-U Alster- Fische Voilaufige Mitteilung Zbl Bakt I Oiig 73 (4-5) 304-314

Kawai, T and Yumoto, Y (1936)
On the distribution of the encysted cercariae of Clonorchis sinensis (Gobbald) in the second intermediate hos Pseudoiasboia paiva (Temminch and schleae), and the rate of their infections to the mammalian hosts
Taiwan Igakkai Zasski, 35 (4) 880-887

Khalifa, R , El-Naffai, M K and Arafa, M S (1977)
Studies on Heteiophyid metacercariae from Assiut province, Egypt I Notes on the life cycle of Haplorchis pumilio (Looss, 1896) with a discussion on previously described species Acta paiasit Pol 25 25-58

Khalifa, J F (1993)
The role of fish in transmistting some parasites to man M V Sc Thesis Fac of Vet Med Alexan Univ

Khalil, M (1932)
The life histoiy of Heterophyid parasite in Egypt Congress International De Medicine Tropicale et d'Hygiene, Le Caire, Egypt, Decembei 1928, IV 137-146

Khalil, M (1933)
The discoveiy of the life histoiy of Heterophyes heterophyes in Egypt J Egypt Med Ass XVI (7), 796-933

Khalil, M (1937)
The life history of the human trematode parasite, Heteropyes heterophyes C R Congr Intern Zool Lishon, 3 1889-1899

Khalil, M (1963)
On Diplostomum tiegenna, the diplostomum stage of Diplostomum tiegenna Nazmi, Gohar, 1932 with an experimental demonstration of part of the life cycle
J Helminth 37 (3) 199-206

Khalil , H M and Abdel-Baki, M H (1979)
Flash on Human Parasitology, Part 1 Ain Shams Univ , Fac of Med , Egypt

Khalil, M , El-Naffar, M K and Sakla, A A (1978)
On 2 Cynodiplostomatid parasites (Diplostomatidae) with description of the encysted metacercariae Assiut Med J 1 1-16

Kim, Y K , Kang, S Y and Lee, S H (1979)
The frequency distirubtion of the metacercarial density of Clonorchis sinensis in a fish host Pseudorasbora Parva Korean Parasit 17 (2) 127-131

Kluvyer, A J and C Bvan Niel (1936)
Prospects for a natural system classification of bacteria zentralbl Bakteriol Parasitenk In fektionskr Hyg Abt 2 369 - 403

Knittel , M D , Seidler, R J , Eby , C and Cabe, L M (1977)
Colonization of the botanical environment by Klebsiella isolates o f pathogenic origin Applied and Environmental Microbiology 34 (5) 557-563

Konemann , E W , Steven , D A , Dowell , V R , William , M G , Herber , M S and Washington , C W (1992)
Diagnostic Microbiology Key for biochemical identification of enterobacteriaceae 4 th Ed J B Lippincott Co Philadelphia U S A

Krieg , N R and Holt , J G (1984)

Bergey's Manual of Systemic Bacteriology Willams and Wilkins Baltimore London

Kuntz, R E , Lawles, D K , Langbehn, H R and Malaktis, G M (1958)
Intestinal protozoa and helminths in people of Egypt lining in different type localities Am J Trop Med Hyg 7(3) 262-264

Lallier, R and Higins R (1988)
Biochemical and toxigenic characteristics of *Aeromonas* spp isolates from clinical mammals, morbund and healthy fish Vet Microbiol 18 (1) 63 - 71

Laila , S Ahmed , Dosoky , M M , Kamel , Y , Abdallah T S and Ismal A A (1986)
Bacteriological studies on fresh water fish (*Tilapia nilotica*) in Upper Egypt Assuit Vet Med J , 15 (30) 102 - 106

Leung , K y and Stevenson R W (1988)
Characteristics and distribution of extracellular proteases from *Aeromonas hydrophila* Journal of General Microbiol , 134 151 - 160

Lawhavinit ,O , Hatai , K and Kubtas S (1991)
A theirosclerosis found in the muscal blood vessels of goldfish, Carassius auratus injected intramuscularly with *Aeromonas hydrophila* Bulletin of Nippon Veterinar, and Zootechnical College (1989) N 38 - 48

La Rue, G R , Bulter, E P and Berkhout, P G (1926)
Studies on the trematode family strigeidae (Holostomidae) No Iv The eye of fishes, an important habitat for larval strigeidae Trails Am Microsc Soc , 45 282-288

Lee, Y C , Liu, C C and Huang, R J (1976)
Investigation of the causes of death of growing ducks in rice fields after harvesting J Chinese soc Vet Sci 2(2) 56-58

Lei-Ching, H (1985)

Occurrence of the eye fluke Diplostomum (D) baeribucculentum Dubois et Rausch, 1948 in Salmonid fishes of northern British Columbia
Can J Zool, 63(2) 296-399

Leigh. H W (1974)
Life history of Ascocotyle mcintoshi Price, 1936 (Trematoda Heterophyidae) J Parasit (1974) Vol 60(5) 768 - 772

Librea, A T and Gacutan Q R (1987)
Aeromonas hydrophila associated with ulcerative epizootic in l'eguna debay, Philippines Aquacalture, 67 273 - 278

Lily, H M, Galila, A B and Nabil, M E (1990)
A preliminary study of Liver functions in Heterophyasis J Egypt Soc Parasit 20 (1) 83-86

Looss, A (1899)
Wiitere Beitrag Zur Kenntniss der Trematoden fauna Aegyptens Zool Labrb n Syst 12, 521-784

Looss, A (1902)
Eine Revision der Fasciolidengattung Heterophyes Notizen Zur helminth Agypt Zbl Bakt 32 886-891

Looss, A (1907)
Notizen zur Helmintologie Agyptens VII Uber einige neue Trematoden der agyptischen fauna Zbl, Bakt, 43 474-490

Lutz, A (1935)
Observacace consideracaes sobre cyatzocotylinaease Prohemistomuneas
Mem Inst Osw Cruz 30 157-168

Macgarey, D J, Foley D P, Reyes, B, Linda, J R, Frye, C and Lim D V (1990)
The role of motile aeromonads in the fish disease, ulcerative disease syndrome (UDS) Abstract of the International Symposium on *Aeromonas* and *Plesiomonas* Lo- Skolen Helsingor Denmark, Faculty of Medicine Lund University Sweden

Magda, Y , Noshy, S M , Nabil, A H , Helen, N A and Boulos, L M (1981)
Effect of freezing and grilling on Pygidiopsis genata metacercariae in Tilapia J Egypt Soc Parasit 11 (2) 425-428

Mahdy, O A (1991)
Morpho-biological studies on the role of some freshwater fishes in transmitting parasitic helminthes of some avian hosts Ph D Thesis, Fac of Vet Med Cairo Univ

Mahdy, O A , Manal, A A , Essa and M El E Easa (1995)
Parasitological and pathological studies on Heterophyid infection in Tilapia species from Manzala lake Egypt Egypt J Comp pathol and Clinic pathol 8 (2) 131-145

Mahmoud, N A (1983)
Parasitic infestations of some native species of fishes in Cairo market with special reference to parasites transmissible to man and animals Thesis, M Sc (Zoonosis), Fac Vet Med , Cairo Univ

Mahmoud, N A (1990)
Larval trematodes of medical significance found in food fish Sarotherdon spp at Fayum Province Egypt J Comp Pathol Clin Pathol , 3(1) 169-177

Mahmoud, N A , Abd El-Slan, F A and Abd El-Gawad A F (1987)
Some studies on metacercarial infection in Schilbe mystis freshwater Nile fish at Sohag province, Egypt Incidence and morphological characters for metacercarial infections Assiut Vet Med J , 19 (37) 52-56

Mahmoud, N A , Youssef, H , Khalifa, R and Nasser, A M (1989)
Infection in freshwater fish in Assiut Province Egypt Egypt J Comp Pathol Clin Pathol 11 (1) 213-225

Mahmoud, N A M , Abdel-Salam, F A and Alyan, S A (1993)
Metacercarial encystation in Bagrus bayad freshwater fish at Sohag Province, Egypt Assiut Vet Med J 29(57) 73-80

Makhlouf, L M , Zakham, A A , El-Khaly, E.I , Abou-Shady, A F Magied S A and El-Shazely, A (1987)
Heterophyids of some freshwater fish from Mansoura, Egypt J Egypt Soc Parasit , 17(2) 573-576

Mansour, S N , Youssef, M M , Awadalla, N H , Hammouda, N A and Boulos, L A (1987)
Heterophyid metacercariae in the fish Tilpaia sp (Cichlidae) from Edku, Maryut and Manzala Lakes in Egypt J Egypt Soc Parasit 17(2) 481-493

Marianne, K (1990)
The life cycle of Pygidiopsis ardeae kie, 1990 (Digenea Heterophyidae) J Parasit , 76 (4) 537-541

Martin, W E (1958)
The life histories of some Hawaiin Heterophyid trematodes J Parasit , 37 297-300

Martin, W E (1961)
Life cycle of Mesostephanus appendiculatus (Ciurea, 1916), Lutz, 1935 (Trematoda Cyathocotylidae)

Martin, W E and Kuntz, R E (1955)
Some Egyptian Heterophyid trematodes
J Parasit , 41 (4) 374-382

Mayer, D G (1960)
Studies on the life history of Mesostephanus kentuekiensis (Cable, 1935) J Parasitol 46 (6) 819-832

Melnick , J L (1957) A water-borne urban epidemic of hepatitis In Hepatitis Frontiers Little , Brown and Co Boston Mass

McDonald, M E (1981)
Key to trematodes reported in water fowl Department of the interior fish and wildlife service Washington, D C 1981

Miles, E M and Miles A A (1951)
The identity of *Proteus hydrophilus*, Kluvey and van Niel J Bacteriol , 46 213 - 214

Mitchell, L G , Ginal, J and Baily, w C (1983)
Melanotic visceral fibrosis associated with larval infections of Posthodiplostomum minimum and Proteucephalus sp in bule gill Lepomis macrochirus Rafiesque, in central Iowa, U S A J Fish Diseases, 6 135-144

Mittal , K R and Tizard , I R (1981)
Serological responses of pigs to experimental infection with *Yersinia enterocolitica* serotype O9 and *Brucella abortus* Am J Vet Res , 42 (3) 443 446

Miyata, I (1944)
Some discussion on the classification of the genus Metagonimus Dobutsugaku Zasshi, 26 (1-3) 16-19

Mohamed, I B (1996)
Oathological changes in some fish eating mammals as a result of consumption of fish infested with encysted metacercariae Ph D Thesis (Pathology) Fac of Vet Med Cairo University

Mondal, M M H and Baki, M A (1989)
Pathology of Echinostoma revolutum infection in domestic ducks Bangladesh Veterinarian,6(2) 31-33

Moravec, F (1977)
Some digenetic trematodes from Egyptian freshwater fish Vestnik Ceskoslovenski Spolechosti Zoologicke, 41(1) 52-67

Moris , G K and Feeley , J C (1976)
Yersinia enterocolitica a review of its role in food hygiene Bull World Hlth Organ , 54 79 - 85

Morishita, K , Komiya, Y and Matsubayshi, H (1965)
Progress of Medical Parasitology in Japan Vol II Meguro Parasitological Museum, Tokyo

Morozov, F N (1952)
Superfamily Heterophyidea Faust 1929, in Skrjabin (Ed) Trematode of animals and man

Nabilah , M Mohamed (1975)

A bacteriological and serological study on fresh water fish in Upper Egypt M D Thesis Faculty of Medicine Assuit University

Nada, M S and Gawady, H M (1986)
Heterophyiasis in chickens with special reference to Prohemistomum vivax (Sonsino, 1982) Assiut Vet Med J 16(31) 169-180

Nasir, P , De-Guevara, D L and Diaz, M (1970)
On the trematode larvae of fresh water XXIV Partial life cycle of Ascocotyle Paratenuicollis n sp (Trematoda Digenea) Acta Biol Venezelica 7(1) 1-4

Nasr, M (1941)
The occurrence of Prohemistomum vivax infections in man with redescription of the parasite
Lab and Med Prog , 2 135-149

Nath, D (1974a)
A note on the metacercarial fauna encountered in Indian freshwater fishes (Short communication) Indian Vet J , 51 (6) 481-483

Nath, D (1974b)
Observation on the experimental development of Echinochasums corvus Bhalerao, 1926 in domestic poultry with remarks on the validity of some other species Indian J Anim Sci 44 (3) 198-203

Nazmi, M (1932)
Diplostomum tregenna sp n , a new trematode parasite of the Egytian Kite Annals and Magazine of Natural History, ser 10 (9) 567-573

Niewiadomska, K (1987)
Diplostomum paracaudum (Iles, 1959) Shigin, 1977 (Digenea, Diplostomatide) and its larval stages a new record from Poland Acta Parasit Pol (31) 199-210

Nolf, L O (1945)

Cercarial productions in snails and metacercrial infection in fish from Carrol lake, Wisconsin J Parasit , 31 Suppl 19

Oghondeminu , F and Okacme , A (1986)
Bacterial flora associated with an organic manureaquaculture system in Kainji lake basin area Nigeria Int J Zoon , 13 54 - 56

Onji, Y and Nishio, T (1924)
A monograph of intestinal trematodes Chiba Igakkai Zasshi, 2(3) 113-161

Oshima, T andNishi, S (1963)
Any fish transplantation from Lake Biwa and epidemiology of Metagonimus yokojawai infection in Japan Bull Inst Pub Health Tokyo, 12 29 - 33

Oshima, T , Kagei, N and Kihata, M (1966)
A simple method for estimating the total number of metacercariae of Metagonimus yokagawai in Plecoglossus altivalis A new proposal of the infection index of fish Jap J Parasit , 15 161 - 167

Page , L A (1962)
Acetyl methyl carbinol prand classification of aeromonads associated with ulcerative diseases of ectothermic vertebrates J Bacteriol 34 772-777

Palmieri, J R (1976)
Life cycle and incidence of Diplostomum spathaceum, 1819 (Trematoda Diplostomatidae) in Utah, U S A Great Basin Nat , 36 86-96

Pande, B P and Shukla, R P (1972)
Metacercarial cyst of Haplorchis pumilio, its development in experimental animals and two other heterophyid infections of freshwater fishes and their Zoonotic significance Indian J Anim Sci , 42 (11) 971- 978

Pande, B P and Shukla, R P (1976)

Haplorchoides Chen 1949 (Haplorchinae Heterophyidae) in freshwater fishes J Helminth , 50 (3) 181-192

Paniagua , C ,, Rivero , O , Angiuta J and Naharro (1990)
Pathogenicity factors and virulence for Rainbow trout (Salmo gairdneri) of motile *Aeromonas* spp isolated from a river Journal of Clinical Microbiol , 28 (2) 530 - 535

Paperna, I (1980)
Parasitic infection and diseases of fish in Africa F A O CIFa Technical Paper 7 51-62

Paperna, I (1995)
Digenea (Phylum platyhelminthes) Fish diseases and disorders Vol 1 P , 329-389

Pedro, P C , MariaCecilia, O G , Domingas, M A G , RosaMaria, D S , AnaCelia, S M , Monteiro, A V and Woiciechovski, E (1992)
Human infection by Phagicola sp (Trematoda, Heterophyidae) J of Tropical Medicine and Hygiene 95, 346-348

Pearson, T C (1964)
A review on the subfamily Haplorchinae Parasit 54, 601-676

Planikov , N N and Zerchaniov L K (1932)
Contributions to biology of opisthorchis felineus Med Parasitol (Moscow) 1 3 - 4

Popoff , M and Veron M (1976)
A taxonomic study of the *Aeromonas hydrophila - Aeromonas punctata* group J Gen Microbiol , 94 11 - 22

Post, G (1987)
Textbook of fish health Revised and expanded edition T F H publications, Inc

Price, E W (1934)
New trematode parasites of birds Smith Misc Coll , 91(6) 1-6

Price, E.W (1936)
A new heterophyid trematode of the genus Ascocotyle (centrocestinae) Proc helm Soc 3 31-32

Rahim, Z K , Aziz , M S , Hua I and Saeed H (1985)
Isolation of *Aeromonas hydrophila* from the wounds of five species of brackish fish of Bangladesh Bangladesh Journal of Zool 13 (1) 37-42

Raff, M A (1994)
Role of marine fish in transmission of some parasites to animals and birds Ph D Thesis, Fac of Vet Med Zagazig Univ

Rai, P (1970)
On the Clinostomatid metacercaria in some of our edible fishes and remarks on the pathological significance, Indian J Anim Sci , 40(2) 189-198

Rai, P and Randc, B P (1969)
On morphology and pathogenic significance of the strigeoid metacercariae in some Indian freshwater fishes II Prohemistomum Arch Zool Exp , 39(4) 360-364

Ramsis, C L Y and Madi, M (1980)
Studies on Pygidiopsis genata from Tilapia zillii in the Zragosis of Jordan The Zoological society of Egypt, 65-72

Reichenbach-Klinke H H , (1973)
Reichenbach-Klinke's fish pathology A guide to recognition and treatment of diseases and injuries of fishes with emphasis on environmental and pollution prolpems pp 420-540

Richard, J (1964)
Trematodes d'oiseaux de Madagascar (note III) Espese de la famile Echinostomatidae Poche, 1926 Ann Parasit, human Comp 39 607-620

Rifaat, M A , Salam, S A , El-Kholy, S I , Hegazi, M M and Youssef, M (1980)

Studies on the incidence of Heterophyes heterophyes in man and fish in Dakahlia Governorate
J Egypt Soc Parasit 10(2) 369-373

Rim H S (1982)
Clonorchiasis in CRC Handbook Series in Zoonoses Section C, Parasitic Zoonoses Ed G V Hillyer and C E Hopla Vol III p 17 CRC Press Inc Boca Raton Fl

Roberts, R J (1978)
Fish Pathology, PP 144-182
G Britain, Univ Press Aberdeen

Robinson , W S (1990) Hepadnaviridae and their replication In Fields virology B N Field , D M Knipe , M S Hirsch , J L Melnick , T P Monath and B Roizman eds , 2nd ed p 2137 , Roven , New York

Rudolphi, C A (1809)
Entozoorum sive vermium intestinalium historia naturalis, Vol I Am stelod 527 PP

Rousset, J. J and Pasticier A (1972)
Two cases of heterophid infection Epidemiological and clinical aspects Importance of opsopathology Ann Parasitol Hum Comp , 47 465 - 474

Sadun , E H (1955)
Studies on opisthorchis viverrini in Thialand Am J Hyg , 62 81

Sanarelli, G (1891)
Ubei einen mikroorganismus des wassers fur tiere nit veraenderlich und konstanter temperature pathogen ist zentrabl Parasitenl Inflektionskr Hyg Abt 29 192 - 199 , 222 - 228

Santos, Y , Bandin , I Nieto ,T P , Nunez S and Toranzo A E (1989)
Haemolytic and agglutinating activities of motile *Aeromonas* from fish culture systems

Scheimann D A (1979)
Synthesis of a selective agar medium for *Yersinia enterocolitica* Can J Microbiol , 25 1298 - 1304

Schubert, R (1976)
The detection of aeromonads of the hydrophila punctata group within the hygienic control of drinking water Centralbaltt fur Bakteriologie und Hygiene Abteilung Originale B 161 482-497

Sekhar, S C and Threlfall, W (1970)
Infection of the Cunner Tautogolabrus adspersus (Walbaum), with metacercariae of Cryptocotyle lingua (Creplin, 1825) J Helminth , XLIV (2) 189-198

Seo, B S , Cho, S Y , Chai, J and Hong, S T (1980)
Studies on intestinal trematodes in korea II Identification of metacercariae of Heterophyes heterophyes nocens in mullets of three southern coastal area Seoul J Med 21 (1) 30-38

Seo, B S , Hong, S T and Chai, J Y (1981)
Studies on intestinal trematodes in Korea Natural human infections of Pygidiopsis summa and Heterophyes heterophyes nocens Seoul J Med , 22 (2) 228-235

Seo, B S , Rim, H J , Lee, S H , Cho, S Y , Kwack, C W , Lee W J and Yeo, T H (1971)
Two cases of metagonimiasis with special reference on the egg laying capacity in the human host Seoul J Med , 12 234 - 241

Shalaby , S I A (1976)
Studies on the role played by some Nile fishes in transmitting trematode worms to dogs M V Sc Thesis , Fac Vet Med , Cairo University

Shalaby, S I A (1982)
Studies on the role played by some Nile fishes in transmitting trematode worms to dogs,
M V Sc Thesis (Parasitology) Fac of Vet Med , Cairo Univ

Shalaby, S I A (1985)
Further studies on the role played by catfish in transmitting some trematodes to fish-eating mammals with sepcial reference to the morphological studies of Mesostephanus appendiculatus Ph D Thesis (Parasitology) Fac of Vet Med Cairo Univ

Shalaby, S I (1988)
Parasitological observation on Prohemistomum sp, encysted metacercaria (trematoda) in Nile fishes II Experimental animals Alex J Vet Sci, 4(1) 243-251

Shalaby, S I (1993a)
Communicable parasites from nile fishes I-Parasitological and pathological studies on Aliptiema Tilapi N sp Egypt J Comp Pathol Clin Pathol 6(10 189-197

Shalaby, S I (1993b)
Communicable parasites from Nile fishes II Intestinal pathology in the final host induced by Haplorchia flukes Egypt J Comp Path Clinol Pathol, 11(1) 174- 184

Shalaby, S I and Easa, M E S (1994)
Trematode parasites transmitted to man and fish eating mammals through Tilapia nilotica II- New Trematode species XXVI Congress of the Italian Association of Bulatricus volume II, 1577 - 1580

Shalaby, S I, Ibrahim, M M, Mahmoud, N A and Thoraya, N El-Assely, (1989)
Parasitological and pathological studies on encysted metacercaiae in the musculature and different organs of Tilapia nilotica Egypt J Comp Pathol Clin Pathol, Vol II No 1 186-212

Shariff, M, Richards, R H and Sommervile, C (1980)
The histopathology of acute and chronic infections of rainbow trout, Salmo gairdneri Richardson with eye flukes Diplostomum spp J Fish Diseases, 3 455-465

Shiemann, D A and Devenish, J A (1982)

Relationship of Hela cell infectivity to biochemical, serological and virulence characteristics of *Yersinia enterocolitica* Infect Immun , 35 (2) 497 - 506

Shigin, A A (1977)
Morfologijai taksonomija roda Diplostomum ot chajjkovykh ptic paleaktiki Trudy gel'mint, Lab , 27, 5-64

Shugar , R A and Ryan J J (1977)
clonorchis and pancreatitis twenty five years after endemic exposure Am J Gastroentrol , 64 400 - 403

Siedlar, R J Morrow , J E and Balgley S T (1975)
Klebsielleae in drinking water emanating from red wood tanks Appl Environ Microbiol , 35 893-900

Sinha, A K , Sinha, C and Nikhil, R (1988)
Studies on yellow grub disease of freshwater fish Chinna punctatus (Bolch) Current Sci India, 57 (4) 218-219

Sioutas S , Hoffmann , R W , Pfeilputzien C and Fischer-Schierl, T (1991)
Carp erythrodermatis (CE) due to an *Aeromonas hydrophila* infection Journal of Veterinary Medicine Series (B) 38 (3) 186-194

Skrjabin, K I (1964)
Key to the trematodes of animal and man English translation Edited by Hisao P Arai University of Alberta, Calgary and center for Zoonoses research university of Illtnois University of Illtnois press, Urbana 1964

Sobsey , M D (1976) Methods for detecting enteric viruses in water and wastewater In G Berg , H L Bodily , E H , Lennette , J L Melnick and T G Metcalf eds viruses in water APHA , Washington D C

Shotts, E B and Rimler R B (1973)
Media for isolation of *Aeromonas hydrophila* Applied Micro 26 550 - 553

Shotts, E B Jr and Feska, J J (1969)
Bacterial pathogens of aquatic vertebrates In Methods for microbiological examination of fish and shellfish Austin B, Austin D Eds) John Wiley and Sons, New York, pp 164 - 166

Snieszko, S F (1974)
The effects of environmental stress on outbreaks of infectious disease of fish J Fish Biol, 6 197-208

Snieszko, S F (1975)
History and present status of fish diseases J Wild Dis, 11 446 - 459

Soliman, M K (1984)
Some ecological factors and their relations of the development and elimination of *Aeromonas* in fish M V Sc Thesis Fac Vet Med Alexandria University

Soliman, M K (1988)
The pathogenesis of *Aeromonas hydrophila* isolates in fish with special emphasis on their control Ph D Thesis Fac Vet Med Alexandria University

Soliman, O A (1994)
Pathologic studies on some parasitic diseases of Tilpia species M V Sc Thesis (Pathology- fish pathology) Fac of Vet Med Zagazig University

Soliman, M K, Esr, M El S, Faisal, M, Abou-El-Azm I M and Hetrick, F M (1989)
Motile aeromonas infection of striped (grey) mullet Mugil cephalus Antonie van leeuwenhoek, 56 323-335

Soliman, M K, Nadia Saber, Amal Rody and Eglal Omar (1989)
Investigation on the effect of experimental infection of four strains of gram negative bacteria on the blood picture of common carp and the distribution of the different infections in the organs Third Egyptian-British Conference in Animal, Fish and Poultry Production, 3 231 - 340

Soliman, M K and Hassieb M M (1990)
Comparative histopathological studies on the effect of some gram negative bacteria in Fish Egypt J Comp Patholo Clin Pathol 3 (2) 1990

Soliman, M K Kitao, T Ruangpan L and Yoshida T (1991)
First record of association of *Aeromonas hydrophila* with mortalities of cultured Mullet, Mugil capito in Egypt Fisheries Sci Soc of Thiland, 1(1) 90- 95

Sonsino, T (1892)
Studie sui parasiti de molluschi di aqua dolce nei dintorni di Cairo in Egitto Festschrift 70 Geburtstag R Leuchart 134 - 146

Soulsby, E J L (1982)
Helminths Arthropods and Protozoa of Domesticated Animals 7th Ed The English Book Society, Beilliere Tindail, London

Spall and Summerfelt, R C (1970)
Life cycle of the white grub, Posthodiplostomum minimum (MacCullum, 1921 Trematoda, Diplostomatidae) and observation on host parasite releationships on the metacercaria in fish P 218 In Asymposium on Diseases Spec Publ No 5 Washington, D C

Srivastava, O N (1950)
A preliminary note on the life cycle of Clinostomum sp and Euclinostomum heterostomum (Rudolphi, 1809)
Proc Nat Acad Sci India, Sect B, 20 85-92

Srivastava, U S (1954)
On a new strigeid trematode of the genus Diplostomum V Nordmann 1832 from the common grey pond heron India J Helminth 6,7-12

Statistical Analysis System (SAS) (1987)
User s Guide Statistics SAS Institue, Cary, North Carolina

Stewart , F S and Beswick , T S (1977) Bacteriology , virology and immunity for students of medicine 10th ed The English Language Book Society and Balliere Tindall , London

Stuart, K and Bernard, F (1989)
Pathological effects of Echinostoma caproni (Trematoda) in the domestic chick J Helminth 63 231-238

Sudarikov, V e (1962)
Otryad Strigeidida (La Rue, 1928) Sudarikov, 1959 Chast 4 Podotryad Cyathocotylata Sudarikov, 1959 Pages 269-469 in Skrjabin, K I , ed Trematody Zhivotnykhi Cheloveka, Osnovy trematodologii, V 19 Akad Nauk SSSR, Moscow

Sung, T , Weon, G , Kim, W and Jong, Y C (1993)
Turnover the biliary epithelial cells in Clonorchis sinensis infected rats Korean J Parasit 31(2) 83 - 89

Swaminathan , B , Harmon , M C and Mehlman , I J (1982)
A review of *Yersinia enterocolitica* J Appl Bacteriol , 52 191 - 183

Sweeting, R A (1976)
An experimental demonstration of the life cycle of Diplostomulum from lampetra fluviatilis Linnaeus Z parasitenk 49(3) 233-242

Syme, J D (1966)
Fish and fish Inspection
2nd Ed , pp 95-115, London, N K Lewis and co Ltd

Szidat, L (1936)
Parasiten aus Seeschwalben I I Z Parasit 8(3), 285-316

Tantawy, E A E (1993)
Muscular parasites in market fishes
M V Sc Thesis, Fac of Vet Med Cairo Univ

Tanabe, H (1926)

Studien ubeidie tiematoden mit susswasserfischen als Zwischenwiit I Stamnosoma armatum n g, n sp Kyoto-Igaku Zasshi, 19 (3), 1- 14

Tantachamaium, T and Kliks, M (1976)
Heteiophyid infections in human ilem ieport of three cases Southcast Assian J Tiop Med Publ Health, 9 228 - 231

Thatchei, V E and Vaiella, A B (1980)
Fish Pathology of Biazilian Amazonia 2 A malignant tumor of the gill ieleated to metacercaiia of a Trematode Acta Amazonica 10 (3) 651-656

Thune, R. L, Giaham, T E, Riddle, L N and Amborsk, R L (1982a)
Extiacellulai pioducts and endotoxin from *Aeromonas hydrophila* effects in age channel catfish Transactions of the Ameiican Fisheries Society III, 404-408

Thune, R L, Giaham, T E, Riddle, L N. and Amborsk, R L (1982b)
Extiacellulai proteases fiom *Aeiomonas hydrophila* Partial puiification and effects in age channel catfish Transactions of the American Fisheries Society III, 497-754

Toranzo, A M, Baya, B S ; Roberson, J L, Barja, D Jay Grimes and Hetrick F M (1986)
Specificity of slide agglutination test for detecting bacteria fish pathogens Aquaculture, 61 81-97

Trust, T J and Spariow R A H (1973)
The bacterial flora in the alimentary tract of freshwater salmonid fishes Can J Microbiol, 19 1219-1228

Ukoli, F M A (1966a)
On the life history, giowth and development from the metacercarial stage to adulthood of Clinostomum tilapiae J Helminth Vol XL No 1/2 215-226

Ukoli, F M A (1966b)
"On Euclmostomum heteiostomum (Rudolphi 1809)"

J Helminth 40 (1/2) 227-234

Ulmer, M J (1955)
Notes on the morphology and host-parasite specificity of fibricola crateria (Barker and Noll, 1915) Dubois, 1932 (Trematode Diplostomatidae) J Parasit, 41 460-466

Van der kuyp, E (1953)
Euclinostomum heterostomum in Celebes Docum Med geogr Trop Amsterdam, 5, 329-332

Van Duijn, C J (1967)
Diseases of fishes, published by Hiffe Book Ltd, Dorsel House, Stamford Street London, S E L

Velasquez, C C (1960)
Studies on parasites of philippine edible fishes I Family Clinostomidae in Ophicephalus striatus Bloch, Clinostomum philippines sp nov with nots on the definitive hosts Doc Med Geogr et Trop, 88 263-278

Velasquez, C C (1973)
Observation on some Heterophyidae (trematoda digenea) encysted in philippine fishes J Parasit 59(1) 77-84

Ventura, M T and Grazzle J M (1988)
Lesions associated with natural and experimental infections of *Aeromonas hydrophila* in channel catfish, *Ictalurus punctatus* J of Fish Disease, 11 397- 407

Visnawathan, R (1957) Epidemiology Indian J Med Res, 45 1 (supplementary number)

Viola, Z H (1991)
Some studeis on motile Aeromonas in fresh water fish with special emphasis on their toxigenic profile M V Sc, Thesis, Alexandria University

Von Graeventiz, A and Mensch H (1968)
The genus *Aeromonas* in human bacteriology New Eng J Medicine 3 245-294

Vojtkova, L (1966)
Zur Kenntnis des Entwicklungszyklus von Holostephanus Volgensis (Sudikov, 1962) n comb (Trematoda, Digenea Cyathocotylidae) Vestn Cesk Spol Zool 30 275-286

Von Nordmann, A (1832)
Entozoa in the eyes of animals Dublin J Med and Chem Sci 1(2) 228

Wakabayashi H , Kanais, K , Hus chuan, T. and Egusa S (1981)
Pathogenic activities of *Aeromonas hydrophila* (Chester) Popoff and Veron , 1976, to fishes Fishes Pathology 15 (314) 319-325

Wang, P (1976)
Studies on the trematode family Echinostomatidae Dietz, 1909 from Fujian Acta Zoologica Sinica 22 (3) 288-293

Watson, J M (1960)
Medical Helminthology
Bailliere Tindall and Co , London

Wells, W.H and Randall, R H (1956)
New hosts for trematodes of the genus Heterophyes in Egypt J Parasit , 42 287- 292

Wessner, F M (1968)
General Zoological microtechniques Scientific Book Agency Calcutta, India

Wilde, H (1973)
Biliary calculus associated with opisthorchiasis Am J Trop Med Hyg , 22 819 - 820

Willian, H and Beverly, H (1956)
New hosts for trematodes of the genus Heterophyes in Egypt J Parasit , 14 287-292

Williams, O M (1966)

Studies on the morphology and life-cycle of Diplostomum (Diplostomum) gasterostei (Strigeida Trematoda) Parasitol 56, 693 - 706

Williams, O M (1967)
Studies on the adult and diplostomulum of Diplostomum (Dolichoichis) leonensis (Strigeida Trematoda) Parasitol 57 673-681

Whyte, C K , Secombes, C J and Chappell, L H (1991)
Studies on infectivity of Diplostomum spathaceum in rainbow trout (Oncorhynchus mykiss) J Helminth , 65 (3) 169-178

WHO Chronicle (1976)
Worldwide spread of infection with *Yersinia enterocolitica* WHO Chronicle , 30 494 - 496

WHO Scientific Working Group (1980)
Enteric infections due to *Campylobacter* , *Yersinia* , *Salmonella* , and *Shigella* Bull World Hlth Organ , 58 (4) 519 - 537

Wolke , R E (1975)
Pathology of bacterial and fungal diseases affecting fish In The pathology of fish Ed W E Ribelin and G Migaki P 33-116 The University of Wisconsin Press

Yamaguti, S (1958)
Systemic helminthes Vol I Digentic trematodes of Vertebrates Part I and II Interscl Bubl Inc New York

Yoakim, K C and El-Naffar, M K (1986)
Studies on the effect of metacercariae of the parasitic trematode Euclinostomum ardeolae on the kidney of the Nile cichild fish Tilapai nilotica
Assiut Vet Med J , 15 (30) 31-38

Yokagawa, M and Sano, M (1968)
Studies on the intestinal flukes IV On the development of worms in the experimentally infected animals with metacercariae of Metagonimus yokagawai

Jap J Parasit, 17 540 - 545

Youssef, M M, Mansour, N S, Hammouda, N A, Awadalla, H W, Khalifa, R and Boulos, L M (1987)
Studies on some developmental stages in life cycle of Pygidiopsis genata Loos, 1907 (Trematoda Heterophyidae) from Egypt J Egypt Soc Parasit Vol 17 No 2

Youssef, H, El-Khateib, T p, Afifi, S H, Fatma, G S and Riad, R M (1993a)
Histopathological changes associated with encysted metacercariae in the muscles of Clarias Assiut Vet Med J 28 (56) 164 - 170

Youssef, H, El-Khateib, T, Fatam, G S and Raid, R M (1993b)
Metacercarial infection in the muscles of Tilapia nilotica and Clarias lazera and the effect of some physical and chemical factors on the viability of encysted metacercariae Assiut Vet Med J 28 (56) 157-163

Zhang, F S, Pan, X Y and Chen, Y M (1986)
A new trematode Echinostoma hangzhouensis sp nov from domestic duck Acta Veterinaria at Zootechnica Sinica (1986) 17(3) 205-208

Zimmerman, O E R (1890)
Die Bakterien unserer Trink-und Nutzwassers Partl 36-39, Cheminitz, B cited by Shotts E B and R B Rimler, 1973 Medium for isolation of *Aeromonas hydrophila* Appl Microbiol, 26 550-553