PN-ABS-452
7.276

FinD

KIDNEY DISEASE OF SEABASS (*Lates calcarifer*)

cc: BOSTID

OCT - 7 1988

FINAL REPORT

Covering Period: April 15, 1988 to December 31, 1992

Submitted to the Office of the Science Advisor
U.S. Agency for International Development

KIDNEY DISEASE OF SEABASS (Lates calcarifer)

Principal Investigator : Dr. Sitdhi Boonyaratpalin
Grantee Institute : National Institute of Coastal Aquaculture, Kaoseng, A. Muang, Songkhla 90000 Thailand

Collaborator : Dr. John L. Fryer
Institute : Department of Microbiology, Oregon State University, Corvallis, OR, U.S.A.

Project Number : 7.276
Grant Number : 936-5542-G-00-8031-00

TABLE OF CONTENTS

	PAGE
EXECUTIVE SUMMARY	3
RESSEARCH OBJECTIVES	4
METHODS AND RESULTS	6
IMPACT, RELEVANCE AND TECHNOLOGY TRANSFER	8
PROJECT ACTIVITIES/OUTPUTS	8
PROJECT PRODUCTIVITY	10
FUTURE WORK	10
LITERATURE CITED	11
ANNEX	12

EXECUTIVE SUMMARY

Kidney Disease of Seabass (*Lates calcarifer*) Project was carried out between April 15, 1988 to December 31,1991 and the project has been extended until December 31, 1992.

The project took place at the National Institute of Coastal Aquaculture, Songkhla.

The overall aim and specific objectives were

a. Overall Aim

The overall aim of this project is to determine the causes and possible methods to control kidney disease of seabass.

b. Specific Objectives

1. Examine the time course and pathology associated with the disease.
2. Characterise the nature of the lesions by histological methods.
3. Determine if the disease is caused by an infectious agents by applying microbiological techniques (bacteriology, virology, mycology and protozoology).
4. Examine environmental and dietary contributions to development of the disease.
5. Devise possible methods to control the disease once the etiology is known.

The research project has proved successful in fulfilling most of its objectives. A total of 3 experiments were conducted under the Kidney Disease of Seabass (*Lates calcarifer*) Project. These research was executed following the technical work plan.

1. Development of kidney disease and occurrence of pathogens in seabass (*Lates calcarifer*) fed two different diets.
2. Effect of trash fish on the development of kidney disease in seabass (*Lates calcarifer*).
3. Effect of caranx fish (*Selaroides leptolepis*) flesh on the development of kidney disease in seabass (*Lates calcarifer*).

It was established from this research that the kidney disease of seabass is not caused by any pathogenic agents or environmental stress. The involvement of caranx flesh played the most important role in kidney disease development. The crystal

granuloma from seabass kidney was analysed as a tyrosine. Only seabass fry had affected from kidney disease.

However, some factors should be considered for further benefit of farmers; such as how to get the fish farmers to use pelleted feed instead of trash fish, and how to get the private sector to produce more pelleted feed for farmer's use.

Therefore, further support and effort from Department of Fisheries and any other donor agencies for the development of the pelleted diets for seabass are needed to solve problems of kidney disease of seabass.

It is concluded that a well balanced, pelleted feed can eleminate the kidney disease problem in seabass.

RESEARCH OBJECTIVES

Since 1983, a condition referred to as seabass (*Lates calcarifer*) kidney disease has occurred among cultured populations of this species in southern Thailand. The disease generally apppears about six weeks after hatching or at culturing time in the cages, and in some cases, causing mortality exceeding 90 percent. The etiology of the disease is unknown. Same work by Thai scientists indicates that bacteria is not responsible, but further research is still needed (Kasornchandra and Boonyaratpalin, 1984).

Gross signs of the disease are swelling of the kidney, abdominal distention, exophthalmia and darkening. The gills show pallor suggesting anaemia. The spleen is enlarged and the liver is grey and mottled in appearance. The lesions in the kidney are not well-characterized but observations thus far indicate a diffuse granulomatous response.

Kidney hypertrophy similar to that observed in seabass, is also seen in several other species of fish and the causes are multiple. Chronic bacterial infection such as that caused by *Renibacterium salmoninarum* in salmonid fishes induce kidney swelling as a result of the accompanying inflammation associated with the bacterial cell proliferation in the tissues (Fryer and Sanders, 1981). Fungal pathogens such as *Ichthyophonus hoferi* can also induce significant hypertrophy of the kidney (McVicar, 1982). Protozoans, most notably the myxosporidan which causes proliferative

kidney disease, can induce extreme swelling of the kidney (Clifton-Hadley et al., 1984). Nephrocalcinosis, a condition characterized by the deposition of calcium salt casts in the lumens of the kidney tubules, can also induce gross swelling of the kidney, particularly in the latter stages of the disease when tubule degeneration and rupture into the interstitium occurs (Harrison and Richards, 1979). The cause of nephrocalcinosis is not clearly understood but there are indications that both amounts of dissolved gases (particularly CO_2) and dietary contents of calcium are important factors predisposing fish to this disease. Recent observations indicate this condition is present in salmonids reared in seawater and have found fish are particularly susceptable to changing salinities with even mild cases of nephrocalcinosis. Mortality, which is rapid in onset, presumably results from the inability of the proximal tubules to regulate divalent cation excretion and adsorption (Kent and Hedrick, 1985).

As indicated above, one might expect kidney diseases to be caused by several factors, including environmental, dietary and infectious conditions.In examining the cause of the seabass kidney disease, the contribution of each will be evaluated so that more clear understanding of the etiology and possible control can be achieved.

Overall Aim and Specific Objectives

a. Overall Aim

The overall aim of this project is to determine the causes and possible methods to control kidney disease of seabass.

b. Specific Objectives

1. Examine the time course and pathology associated with the disease.
2. Characterize the nature of the lesions by histological methods.
3. Determine if the disease is caused by an infectious agent by applying microbiological techniques (bacteriology, virology, mycology and protozoology).
4. Examine environmental and dietary contributions to development of the disease.
5. Devise possible methods to control the disease once the etiology is known.

Seabass culture is an important and developing method of food production for Thailand. The onset of kidney disease among these cultured fish has severely limited

their production and a more thorough understanding of the condition and its possible remedy is required.

Since the collaborated laboratories in the U.S.A. have had extensive experience with kidney disease in salmonid fishes (due to bacterial, protozoan, environmental and dietary causes), and adequate exchange of information should be useful to both countries. Use of current techniques to compare kidney disease in the U.S.A. laboratories (with appropriate modifications to the new species and unique environmental conditions) with the situation in Thailand should improve understanding of the seabass kidney disease and methods for its control.

The causes and means to control kidney disease of seabass are currently unknown. The approach outlined in the proposal provide the most comprehensive study undertaken to determine its causes and possible control. The techniques applied will be those of most current availability to fish health specialists in the U.S.A., Thailand and other ASEAN countries.

METHODS AND RESULTS

The technical work plan was designed to achieve these following answers:

a. Time course and pathology of the disease.

b. Characterization of the kidney lesion.

c. Possible involvement of infectious agents. .

d. Role of dietary or environmental factors.

e. Possible control measures.

Three research topics (details as in the annex) were conducted at the National Institute of Coastal Aquaculture, Songkhla during April 15, 1988 to December 31, 1991.

The first research is "Development of kidney disease and occurrence of pathogens in seabass (*Lates calcarifer*) fed two different diets". In this study, seabass fed moist pelleted feed and chopped fresh trash fish for 11 weeks at three different locations were observed for the development of kidney granuloma. From the

seventh week, systemic granuloma, characterized by whitish granular material, was observed in the posterior portion of swollen kidneys in 20% of seabass from the location where the water pass through the sand-filtered water system. Gross symptom and histopathological examination demonstrated that prevalence and severity of kidney granuloma was directly attributed to chopped fresh trash fish. Occurrence of pathogens was not different among the experimental fish. There did not appear to be any correlation between pathogens and prevalence on severity of kidney granuloma. It is concluded that fish fed fresh trash fish (*Selaroides leptolepis* and *Sardinella* spp.) exhibit kidney disease within 7 weeks. There was no evidence that the occurrence of microbial pathogens influenced the development of kidney granuloma. Parasites to include the myxosporean were not linked with the cause of progress kidney granuloma.

The second research, "Effect of trash fish on the development of kidney disease in seabass (*Lates calcarifer*)" was carried out to narrow down the causative agent of kidney disease in seabass. Since trash fish in the experiment 1 was proved to be the agents, in this study, seabass fed caranx's flesh and whole body; and sardine's flesh and whole body at different qualities were observed for the development of kidney disease by gross pathology and histopathology at the end of 12 weeks. Only seabass fed minced caranx flesh developed the crystal granuloma in kidney: kidney swelling and exophthalmia of varying degree without periorbital hemorrhage, body darkening and abdomen distention. Necrosis and degeneration of kidney tubules was observed in kidney. Massive accumulation of eosinophilic materials (possible proteinatous materials) in the tubules due to the malfunction of glomeruli were observed. High dilated glomeruli capillaries and Bowman's space associated with shrunken glomeruli were also detected. The deposition of needle-like crystals in the renal tubule of the affected fish were illustrated.

The third research, "Effect of caranx fish (*Selaroides leptolepis*) flesh on the development of kidney disease in seabass (*Lates calcarifer*)" was conducted at the same laboratory to find out what kind of proteinatous materials will cause the development of kidney disease and what size of seabass will be affected to the kidney disease. Two different sizes of seabass were used for this trial, 3-5 cm and 7-9 cm in length. Six different diets were compared: caranx fish flesh, caranx fish flesh left 1, 2 and 3 nights, moist pelleted diet and moist pelleted diet with 4% tyrosine. The results

showed that seabass fed caranx fish flesh and moist pelleted diet with 4% tyrosine were developed systemic granuloma at 32 and 35 days respectively. Tyrosine accumalation was analysed from kidney of seabass fed caranx fish flesh and moist pelleted diet with 4% tyrosine. No symptom was observed in the experiment of 7-9 cm seabass. Blood parameters that differed significantly in these two groups of experimental seabass were hematocrit, hemoglobin, red blood cell and thrombocyte.

In conclusion, this kidney disease of seabass is not caused by any pathogenic agents (bacteria, fungi, parasite and virus). Environmental stress was not involved in the development of the kidney disease. The involvement of the dietary contribution played the most important role in the kidney disease development. The practical way of using trash fish especially caranx fish flesh fed to seabass fry (3-5 cm) initiated kidney disease problem. Larger fish had not developed crystal granuloma after fed caranx fish flesh for 12 weeks. Tyrosine was analysed from kidney crystal granuloma. Moist pelleted feed is recommended to use in the future seabass culture and it can be a tool to eliminate the kidney disease in seabass.

IMPACT, RELEVANCE AND TECHNOLOGY TRANSFER

This finding will be very useful in developing countries where they are culturing seabass and will culture seabass. Much of the work has been successfully transfered via extension officers to fish farmers and private sector resulting in reduced kidney disease problem and turn to increase production of seabass. These will also give benefit to farmers in other ASEAN countries. The scientific capabilities of collaborating country scientists have been improved at a better understanding level.

PROJECT ACTIVITIES/OUTPUTS

International Symposium/Meeting

1. Joint Meetings of the Fish Health Section of the American Fisheries Society and the Midwest Fish Health Workshop. Minneapolis, Minnesota, U.S.A. July 15-19, 1990.

8

2. Second International Symposium on Viruses of Lower Vertebrates. Corvallis, Oregon, U.S.A. July 29-31, 1991.
3. American Fisheries Society, Fish Health Section Meeting. Newport, Oregon, U.S.A. August 1-3, 1991.
4. Fifth International Congress for the Society of Developmental and Comparative Immunology. Portland, Oregon, U.S.A. August 5-9, 1991.

Local Workshop

1. Workshop on AID/SCI Funded Research in Agricultural Biotechnology. Bangkok. August 16-18, 1990.

Project Consultation/Implementation/Collaborated Work in U.S.A.

1. Department of Microbiology, Oregon State University, Corvallis, Oregon, U.S.A. October 14- November 15, 1988.
2. Marine Science Center, Oregon State University, Newport, Oregon, U.S.A. April 20- May 19, 1989.
3. Department of Microbiology, Oregon State University, Corvallis, Oregon and Fish Disease Laboratory, Fish and Wildlife Service, National Fisheries Research Center, Seattle U.S.A. November 9 - December 28, 1989.
4. Department of Microbiology, Oregon State University, Corvallis, Oregon, U.S.A. July 20-26, 1990.
5. Department of Microbiology, Oregon State University, Corvallis, Oregon, U.S.A. July 26-29, 1991.

Co-investigator Trip to Thailand

1. National Institute of Coastal Aquaculture, Songkhla, Thailand. February 22-March 15, 1990.

Publications

1. Boonyaratpalin, S.,J.L.Fryer, R.P. Hedrick, K. Supamattaya, S. Direkbusarakom and U. Jadesadakraisorn. 1990. Development of kidney disease and occurrence

of pathogens in seabass (*Lates calcarifer*) fed two different diets. Technical Paper No.8. National Institute of Coastal Aquaculture Songkhla, Thailand.13 p.

2. Boonyaratpalin, S., J. Kasornchandra, K. Supamattaya, and U. Ekpanithanpong. 1993. Effect of trash fish on the development of kidney disease in seabasss (*Lates calcarifer*). Technical Paper No.9.National Institute of Coastal Aquaculture Songkhla, Thailand. 11 p.
3. Boonyaratpalin, S., J. Kasornchandra, K. Supamattaya, U. Ekpanithanpong, and Y. Danayadol. 1993. Effect of caranx fish (Selaroides leptolepis) flesh on the development of kidney disease in seabass (*Lates calcarifer*). Technical Paper No. 10. National Institute of Coastal Aquaculture Songkhla, Thailand. 19 p.

PROJECT PRODUCTIVITY

Kidney disease of seabass (*Lates calcarifer*) project has proved successfully in fulfilling its objectives with slightly modified design plan. Total of 3 researches were conducted at the National Institute of Coastal Aquaculture. Also, much of the work has been transfered via the Diagnostic Service at the National Institute of Coastal Aquaculture to farmers. Presentations and publications of the research results had been done at the international and national level.

FUTURE WORK

This project will lead to future work on the development of moist pelleted diets for seabass. Feed and feeding are the most important factors affecting growth, health, size variation and survival of seabass. Immune enhancer and immune stimulator could be added in the diets for disease resistance and reducing the drug residue problem.

LITERATURE CITED

Clifton-Hadley, R.S., D. Bucke and R.H. Richards. 1984. Proliferative kidney disease of salmonid fish: A review. Journal of Fish Diseases 7: 363-377.

Fryer, J.L. and J.E. Sanders. 1981. Bacterial kidney disease of salmonid fish. Annual Reviews of Microbioloty 35: 273-298.

Harrison, J.G. and R.H. Richards. 1979. The pathology and histopathology of nephrocalcinosis in rainbow trout in *Salmo gairdneri* Richardson in fresh water. Journal of Fish Disease 2: 1-12.

Kasornchandra, J. and S. Boonyaratpalin. 1984. Disease found in seabass. Thai Fisheries Gazette 37: 426-432.

Kent, M.L. and R.P. Hedrick. 1985. PKX, the causative agent of proliferative kidney disease (PKD) of Pacific salmonid fishes and its affinities the myxozoa. Journal of Protozoology 32: 254-260.

McVicar, A. 1982. *Ichthyophonus* infections of fish. In, Microbial Diseases of Fish. Ed. R.J. Roberts, Academic Press, London, pp. 243-269.

ANNEX

DEVELOPMENT OF KIDNEY DISEASE AND OCCURRENCE OF PATHOGENS IN SEABASS (*LATES CALCARIFER*) FED TWO DIFFERENT DIETS

S. Boonyaratpalin[1], J.L. Fryer[2], R.P. Hedrick[3] K. Supamattaya[4] S. Direkbusarakom[1] and U. Jadesadakraisorn[1].

[1]National Institute of Coastal Aquaculture, Kaoseng, A. Muang, Songkhla 90000, Thailand.

[2]Department of Microbiology, Oregon State University, Corvallis, OR 97331, U.S.A.

[3]Department of Medicine, School of veterinary Medicine, University of California, Davis, California 95616, U.S.A.

[4]Department of Natural Resource, Prince of Songkhla University, Hat Yai Campus, Thailand.

ABSTRACT

In this study, seabass (*Lates calcarifer*) fed moist pelleted feed and chopped fresh trash fish for 11 weeks at three different locations were observed for the development of kidney granuloma. From the seventh week, systemic granuloma, characterized by whitish granular material, was observed in the posterior portion of swollen kidneys in 20% of samples. Gross symptom and histopathological examination demonstrated that prevalence and severity of kidney granuloma was directly attributed to the chopped fresh trash fish. Occurrence of pathogens was not different among the experimental groups. *Sphaerospora* sp. was observed from the kidney of experimental fish. There did not appear to be any correlation between pathogens and prevalence on severity of kidney granuloma.

INTRODUCTION

Since 1983 a condition referred to as seabass kidney disease has occurred among cultured populations of this species (*Lates calcarifer*) in southern Thailand. The disease generally appears about six weeks after stocking in net-cages at the size of 1.0-1.5 cm and in some cases, causes mortality may exceed 90%. Gross signs of the disease are swelling of the kidney, abdominal distention, exophthalmia and darkening. The gills are pale, suggesting anemia. The spleen is enlarged and the liver grey and mottled in appearance. The lesions in the kidney are not well-characterized but observations thus far have shown a diffuse granulomatous texture.

Kidney hypertrophy similar to that observed in seabass is also seen in several other species of fish and results from multiple cause. Chronic bacterial infection such as that caused by *Renibacterium salmoninarum* in salmonid fishes induces kidney swelling as a result of the accompanying inflammation associated with bacterial cell proliferation in the tissue (Fryer and Sanders 1981). Fungal pathogen like *Ichthyophonus hoferi* can also induce significant hypertrophy of the kidney (McVicar 1982). Protozoans, most notably the myxosporidian which causes proliferative kidney disease, induces extreme swelling of the kidney (Clifton-Hadley et al. 1984). Nephrocalcinosis, a condition characterised by the deposition of calcium salt casts in the lumens of the kidney tubules to include the ureter and ducts induces gross swelling of the kidney, particulary when the kidney tubule degenerate and rupture into the interstitium (Harrison and Richards 1979). The causes of nephrocalcinosis are not clearly understood but there are indications that both the amounts of dissolved gases (particularly CO_2) and dietary calcium are important factors predisposing fish to this disease. Recent observations indicate this condition is present in salmonids reared in seawater. Fish with mild cases of nephrocalcinosis were particularly susceptible to changing salinities. Mortality presumably results

from the inability of the proximal tubules to regulate divalent cation excretion and adsorption (Hedrick. unpublished data). As indicated kidney diseases may be caused by seveval factors, including environmental, dietary and infectious conditions.

The objective of this study was to determine possible causes of kidney disease of seabass fed two different diets in seawater cagès at three locations by means of histological, microbiological and gross external examinations.

MATERIALS AND METHODS

This experiment was conducted during the period 1988-1989 at the National Institute of Coastal Aquaculture, Songkhla Thalland. The experimental fish were obtained from the government hatchery and were divided into two groups and fed different diets. Fifty fish from each group were randomly sacrificed and subjected to macroscopic examination to insure the absence of systemic granuloma. The rest were trained to accept a moist pelleted feed (Table 1) or chopped fresh trash fish (*Selaroides leptolepis* and *Sardinella* spp.)

The experiment was carried out in six 1.5x1.0x1.0 m nylon net cages with 0.5 cm mesh size, in three different locations (Table 2). The experimental fish were graded for size 1.5-2.0 cm to reduce cannibalism before stocking at the rate of 500 fish/cage in two nylon net cages at each location. Fish in one cage were fed using a moist pelleted feed and the other were fed chopped, fresh trash fish. Fish were fed ad libitum twice a day at 08.30 and 17.00 hours. The cages were cleaned every other day.

Five fish were taken from each cage at weekly intervals for 11 weeks and the external and internal appearance of each fish was observed and recorded. External parasites from the skin and gills and any external clinical signs of disease were examined and recorded. Bacterial examination was performed from external lesions, livers and kidney of fish on blood agar or tryptic soy agar + 1.5% NaCl and

Table 1. Ingredient components of moist pelleted feed

Ingredient	g/100g
Fish meal	70
Choline chloride	0.5
Vitamin C	0.05
Vitamin premix*	1.5
Mineral premix**	4.0
Marine fish liver oil	3.0
Soy bean oil	3.0
CMC	6.0
- Cellulose	1.95
- Starch	10.0

*Vitamin premix (mg / 100g of feed) : Thiamine HCl 5, Riboflavin 20, Pyridoxin HCl 5, Niacin 75, Ca-Pantothenate 50, Inositol 200, Biotin 0.5, Folic acid 1.5, Cyanocobalamin 10 (ug), Menadione 4, Tocopherol acetate 40, Vitamin A 1,000, Vitamin D 200 (iu), B.H.T. 1.0, Dextrose as a filler

**Mineral premix (per 100g of feed) : NaCl 0.173g, $MgSO_4$ $7H_2O$ 0.545g, $NaH_2PO_4.2H_2O$ 0.347g, KH_2PO_4 0.945g, $Ca(H_2PO_4)_2H_2O$ 0.540g, Fe citrate 0.118g, Calactate 1.301g, KI 0.579mg, $AlCl_3$ 0.597mg, $CuCl_3$ 0.398mg, $MnSO_4$ 3.184g, $CoCl_2$ 3.979mg, $ZnSO_4$ 11.94mg.

Table 2 The experimental net cages at three lacations with two diets

Cage	Description
A	Cages at Yoh island inside Songkhla Lake with chopped fresh trash fish
AA	Cages at Yoh island inside Songkhla Lake with moist pellted feed
B	Cages at the mouth of Songkhla Lake with chopped fresh trash fish
BB	Cages at the mouth of Songkhla Lake with moist pelleted feed
C	Cages at the National Institute of Coastal Aquaculture, water supply passed through sub-sanded filter, with chopped fresh trash fish
CC	Cages at the National Institute of Coastal Aquaculture, water supply passed through sub-sanded filter, moist pelleted feed

incubated for 24 and 48 hr at 25 and 35 °C. The possibility of viral infection was determined before and after 7 weeks of the experiment using liver, spleen and kidney tissue on fish cell lines EPC, FHM and BF-2. The cell cultures were incubated at 25 °C and examined on a daily basis for 14 days after inoculation in order to observe any cytopathic effects (CPE).

Small fish and tissue of internal organ of fish larger than 3 cm were preserved in 10% neutral buffered formalin and they were embedded in paraffin. Mid line sagital sections were stained with haematoxylene and eosin, Giemsa or Ziehl Nielsen acid fast reagent.

RESULT AND DISCUSSION

Development of gross symptom

Results indicated seabass at the different locations and diets grew normally and were free from disease symptoms through the first four weeks. After 30 day, the fish receiving a diet of chopped trash fish at location C began to exhibit loss of appetite, poor growth, weight loss and darkening of the body. From the seventh week, systemic granuloma, characterized by whitish granular material, were observed by light microscope in the posterior portion of swollen kidneys in 20% of the fish. From the eighth to eleventh week up to 40% of fish had these granulomas in the kidney.

Occurrence of pathogens

Certain external parasites were observed including *Cryptocaryon* sp., *Trichodina* sp., *Henneguya* sp., *Scyphidia* sp., *Epistylis* sp. *Amylodinium* sp., *Dactylogyrus* sp. and *Argulus* sp. on gills were recorded in low numbers in experimental fish from three locations, as shown in Table 3. No pathogenic bacteria were isolated from any internal organs or external lesions. No CPE was detected in inoculated cell cultures after 14 days at 25 °C incubation.

Histopathological changes

Examitation of histological sections of the experimental fish, revealed *Myxosporeans* in the gills, muscle and renal tubules (Table 4). The most abundant form was a *Sphaerospora* sp. found in the lumina of the tubules of many fish from locations A and B. It was noticeably absent from location C. Certain members of this genus are associated with inflamatory diseases resulting from the host's response to developmental and sporogenic stages of the myxosporean. In these fish however, there was no noticeable effects on the renal tubules.

The myxosporeans in the gill and muscle were similar to *Henneguya* sp. when numbers of these organisms are very high in fish, this parasite can cause disease but the infections seen here were mild to moderate and are not beleived to have caused damage to the host.

The most significant changes observed in this study were to fish at location C. Fish fed chopped fresh trash fish had a severe myopathy of unknown etiolgy. The body musculature was severely affected beginning the fifth week after introduction of the seabass to the cages. These changes to the muscle may be associated with diet as it was not observed in fish from the same location fed the moist pelleted feed (CC). Degenerative changes to the proximal tubules in the kidney of fish fed the chopped fresh trash fish however, may indicate there was some protein imbalance in the feed. Additional evidence for dietary effects comes from the hepatocytes of fish on the two diets. Lipidosis was moderate to severe in the C group but much less or absent from the CC group (Table 5 and 6).

Histopathological, pathogenic and gross external examinations demonstrated that prevalence and severity of kidney granuloma increased when a chopped fresh trash fish was used, especeally at site C where environmental condition were controlled using sand-filtered water reducing natural foods available in the water. Although various factors affecting environmental conditions at sites A

Table 3 External parasitics infestration* found on gills and mucous of the experimental seabass (*Lates calcarifer*)

Time (week)	Treatment of the experimental fish											
	A		AA		E		BB		C		CC	
	Gill	Mucous	Gill	Mucous	Gill	Mucous	Gill	Mucous	Gill	Mucous	Gill	Mucous
1	Cr,Tr	Cr	Cr,Tr	Cr	Tr	-	He,Tr	Tr	-	-	-	-
2	Am,Tr	Am	Da,Tr	Tr	Da,Tr	Tr	He	-	-	-	Ep	-
3	Cr,Da,He	Tr	Da,Tr,He	Tr	Cr,Da,Sc	He,Tr	Cr,Da,Tr	He	Cr	-	Cr	-
4	Cr,He,Tr	Tr	Cr,He,Tr	He	Cr	-	-	-	-	-	-	-
5	Cr,Tr	Tr	He	He	Cr,Tr	Tr	Tr	Tr	-	-	-	-
6	Da	-	Da	He	Tr	Tr	Tr	Tr	-	-	-	-
7	Da,Cr	-	Da,He,Cr	-	Da,Tr	Tr	Ar,Da	Tr	-	-	-	-
8	Ar,Cr,He	Tr	Ar,Da,He	Tr	Tr	-	Cr,Da	Cr	-	-	-	-
9	Da,He,Tr	Tr	Da,Cr,Tr	Tr	Da,Tr	-	Da,He,Tr	-	-	-	-	-
10	Da,Cr,He	Tr	Cr	-	-	-	-	-	-	-	-	-
11	Da,Cr,He	-	Da,Cr,He	He	-	-	-	-	-	-	-	-

* in low number

Am = *Amylodinium* Sp.
Ar = *Argulus* Sp.
Cr = *Cryptocaryon* Sp.
Da = *Dactylogyrus* Sp.
Ep = *Epistylis* Sp.
He = *Henneguya* Sp.
Sc = *Scyphidia* Sp.
Tr = *Trichodina* Sp.

Table 4 *Sphaerospora* sp. and *Henneguya* sp. infection of experimental seabass (*Lates calcarifer*) from histological study (number of infected fish/number of examined fish)

Treatment	Examined time (week)										
	1	2	3	4	5	6	7	8	9	10	11
A	–	–	–	–	–	–	3/5Sp	5/5Sp	1/5Sp, 1/5He	1/5Sp	–
AA	–	–	–	–	–	–	5/5Sp	3/5Sp, 1/5He	1/5Sp	1/5Sp	1/5Sp, 1/5He
B	–	–	–	–	–	–	1/5Sp	4/5Sp	1/5Sp	–	–
BB	–	–	–	–	–	–	2/5Sp	–	1/5He	1/5Sp	–
C	–	–	–	–	–	–	–	–	–	–	–
CC	–	–	–	–	–	–	–	–	–	–	–

Sp = *Sphaerospora* sp. in the kidney

He = *Henneguya* sp. on the gills

Table 5 Assessment of severity of kidney disease following gross examination

Severity assessment	Observations
0	Kidney apparently normal
•	Small whitish crystalline deposits in kidney, body darkened
••	Numerous whitish spot in swollen kidney, body darkened
•••	Numerous whitish area in swollen kidney and eye opagues with small granule deposits in gills, body darkened

Table 6 Gross and histopathological prevalence of kidney disease.

Treatment	Time (week)	Overall gross prevalence %(1)	Histopathological changes (2)				
			0	+	++	+++	++++
A	1-4	0	5	-	-	-	-
	5	0	5	-	-	-	-
	6	0	5	-	-	-	-
	7	0	4	-	-	1	-
	8	0	4	-	-	1	-
	9	0	4	-	1	-	-
	10	0	3	-	2	-	-
	11	0	4	-	1	-	-
AA	1-4	0	5	-	-	-	-
	5	0	5	-	-	-	-
	6	0	5	-	-	-	-
	7	0	5	-	-	-	-
	8	0	3	-	2	-	-
	9	0	2	1	2	-	-
	10	0	4	-	1	-	-
	11	0	4	1	-	-	-
B	1-4	0	5	-	-	-	-
	5	0	5	-	-	-	-
	6	0	5	-	-	-	-
	7	0	4	1	-	-	-
	8	0	3	-	2	-	-
	9	0	3	-	-	2	-
	10	0	5	-	-	-	-
	11	0	5	-	-	-	-
BB	1-4	0	5	-	-	-	-
	5	0	5	-	-	-	-
	6	0	5	-	-	-	-
	7	0	4	-	-	1	-
	8	0	5	-	-	-	-
	9	0	5	-	-	-	-
	10	0	3	-	-	2	-
	11	0	5	-	-	-	-
C	1-4	0	5	-	-	-	-
	5	0	4	-	-	1	-
	6	0	4	-	-	1	-
	7	20*	4	-	-	1	-
	8	40*	-	-	3	2	-
	9	40*	2	2	1	-	-
	10	40**	1	3	-	-	1
	11	40***	2	-	-	3	-
CC	1-4	0	5	-	-	-	-
	5	0	5	-	-	-	-
	6	0	5	-	-	-	-
	7	0	5	-	-	-	-
	8	0	4	1	-	-	-
	9	0	4	-	1	-	-
	10	0	4	1	-	-	-
	11	0	3	2	-	-	-

(1) Percentage of total number of fish in each treatment showing changes varying from "to"*** (Table 5) during the course of the experiment.

(2) Extent of histopathological damage in 5 fish from each treatment sampled at weekly interval for 11 weeks.

Key to histopathological changes.

0	No abnormality detected.
+	Gill damage.
++	Enteritis in small intestine or exocrine element in pancreas.
+++	Lipidosis in liver or liver inflamatory or muscle necrosis.
++++	Kidney damage, myopathy.

and B have been suggested to have inhibited the developement of kidney granuloma among fish fed the chopped fresh trash fish. It is only possible to speculate on the true etiology. One probable cause was the availability of natural food at sites A and B to supplement the diets provided. Similar study was conducted by Paperna (1987) on "Systemic granuloma of cultured *Sparus aurata*" with dietary and metabolic etiology of tyrosinaemea and kidney tyrosinosis.

Similar conditions previously described in fish showed extensive, chronic inflamation and urolithiasis or nephrocalcinosis in rainbow trout, *Salmo gairdneri* (Richardson) and visceral granuloma of brook trout, However in each of these cases the lesions were limited in site and, deposition of calcium salts was characteristic (Besse et al. 1968; Landolt 1975; Harrison & Richards 1979). The inflammatory reaction was also more limited in extent particularly in nephrocalcinosis and was usually referable to an identifiable local irritant such as a necrotic focus or a deposit of calcium bearing material (Harrison & Richards 1979). In the present study extensive areas of inflammation occurred without apparent focus and haemorrhage, and fibrin production was more evident than in nephrocalcinosis or visceral granuloma.

There was no evidence that the occurrence of microbial pathogens influenced the development of kidney granuloma. Parasites to include the myxosporean were not linked with the cause of progress of kidney granuloma.

REFERENCES

Besse, P., P. DE Kinkelin and J.C. Levaditi. 1968. La nephrocalinose dans la truite arc-en-ciel (*salmo irsideux* Gibbons 1855). Bulletin Office International des Epizootis 69:1391-1399.

Clifton - Hadley, R.S., D. Bucke and R.H. Richards. 1984. Proliferative kidney disease of salmonid fish : A review. Journal of Fish Diseases 7: 363-377.

Fryer, J.L. and J.E. Sanders. 1981. Bacterial kidney disease of salmonid fish. Annual Reviews of Microbiology 35 : 273-298.

Harrison, J.G. and R.H. Richards. 1979. The pathology and histopathology of nephrocalcinosis in rainbow trout *Salmo gairdneri* Richardson in fresh water. Journal of Fish Disease 2 : 1-12.

Landolt, M.L. 1975. Visceral granuloma and nephrocalcinosis of trout. In : The Pathology of Fishes (ed. by W.E. Ribelin and G. Migaki). pp. 793-801. The University of Wisconsin Press. Medison. Wisconsin.

McVicar, A. 1982. *Ichthyophonus* infections of fish. In Microbial Diseases of Fish. Ed. R.J. Roberts, Academic Press, London, pp 243-269.

Paperna, I. 1987. Systemic granuloma of Sparid fish in culture. Aquaculture, 67 : 53-58.

EFFECT OF TRASH FISH ON THE DEVELOPMENT OF KIDNEY DISEASE IN SEABASS (*LATES CALCARIFER*)

S. Boonyaratpalin[1], J. Kasornchandra[1], K. Supamattaya[2] and U. Ekpanithanpong[1]

1 National Institute of Coastal Aquaculture, Kaoseng, A. Muang, Songkhla 90000, Thailand

2 Department of Aquatic Science, Faculty of Natural Resource, Prince of Songkla University, Hat Yai Campus, Songkhla 90110, Thailand

ABSTRACT

Two species of trash fish and their qualities were examined to study their effect on the development of kidney disease in seabass (*Lates calcarifer*). Caranx (*Selaroides leptolepis*) and sardine (*Sardinella* spp.) were studied. The experiment consisted of 8 treatments: 1. refrigerated minced caranx flesh; 2. refrigerated minced whole caranx; 3. minced caranx flesh refrigerated after one day; 4. minced whole caranx refrigerated after one day; 5. refrigerated minced sardine flesh; 6. refrigerated minced whole sardine; 7. mince sardine flesh refrigerated after one day; 8. mince whole sardine refrigerated after one day. However, fish fed with refrigerated minced caranx flesh showed symptoms of disease which was characterized by abdominal distention, kidney swelling, exophthalmia, darkening and needle-like crystalline deposition in kidney. The kidney disease which was characterized by the needle-like crystal deposited in kidney observed in seabass was similar to tyrosinosis kidney in spariid fish.

EFFECT OF TRASH FISH ON THE DEVELOPMENT OF KIDNEY DISEASE IN SEABASS (*LATES CALCARIFER*)

S. Boonyaratpalin[1], J. Kasornchandra[1], K. Supamattaya[2] and U. Ekpanithanpong[1]

1 National Institute of Coastal Aquaculture, Kaoseng, A. Muang, Songkhla 90000, Thailand

2 Department of Aquatic Science, Faculty of Natural Resource, Prince of Songkla University, Hat Yai Campus, Songkhla 90110, Thailand

INTRODUCTION

Kidney granuloma is chronic to subacute inflammatory disease affecting the posterior kidney of cultured seabass (*Lates calcarifer*). The incidence of the disease was found in fingerling seabass at the size of 3.0-7.0 cm. The disease is not severe, however, in some cases mortality may exceed up to 90%.

Gross signs of kidney granuloma are enlargement of the kidney and spleen, abdominal distention, exophthalmia and darkening of the body. The lesions in the kidney show a gritty texture with a nodular surface.

The experiment carried by Boonyaratpalin et al. (1990) revealed that the cause of this disease may involved with diet. They suggested that fresh trash fish (*Selaroides leptolepis* and *Sadinella* spp.) was suspected as it was observed that seabass being fed with the moist pelleted feed showed no signs of the disease. Therefore, in this experiment the effect of species and quality of the trash fish on the development of kidney disease was emphasized.

MATERIALS AND METHODS

Seabass (*Lates calcarifer*) fry, 1.5-2.0 cm, were obtained from the hatchery of the National Institute of Coastal Aquaculture, Songkhla, Thailand. Experimental fish were designed for eight treatments with three replications each, and were acclimatized for one week before starting the experiment. Ten fish from each treatment were randomly sacrified and subjected to microscopic detection to insure the absencec of the kidney granuloma.

The experiment was carried out in 30 L aquaria equipped with seawater flow through system and aeration with stocking density of 30 tail/quarium. Two kinds of fish, caranx (*Selaroides leptolepis*) and sardine (*Sardinella* spp.), were used as experimental feed. The following diets were given to each treatment twice a day at 9:30 and 14:30 h.

Formular 1: Refrigerated minced caranx flesh

Formular 2: Refrigerated minced whole caranx

Formular 3: Minced caranx flesh that has been left outside for one day and then refrigerated

Formular 4: Minced whole caranx that has been left outside for one day and then refrigerated

Formular 5: Refrigerated minced sardine flesh

Formular 6: Refrigerated minced whole sardine

Formular 7: Minced sardine flesh that has been left outside for one day and then refrigerated

Formular 8: Minced whole sardine that has been left outside for one day and then refrigerated

Whole batch of feed for each treatment was prepared before starting the experiment and used until termination. The experiment was carried out for 12 weeks. Gross and histopathological samples were taken at the end of the experiment. Kidney and liver tissues were fixed in 10% neutral buffered formalin for 24 h. After dehydration, they were embedded in Paraplast, sectioned at 4-5 um, and stained with hematoxylin and eosin.

The same tissues were also fixed for electron microscopy. Tissues were fixed in 6.25% glutaraldehyde in Sorensen phosphate buffer pH 7.4 for 3 h. The tissues were then post-fixed in 1% OsO_4 for 2 h, dehydrated in acetone series and embedded in Epon-812. Semithin sections were examined under electron microscope (Zeiss EM-109) at 80 kV.

RESULTS AND DISCUSSION

Gross pathology

Seabass fed with different formulars demonstrated slightly gross pathological changes through the experiment except fish fed with formular 1 (refrigerated minced caranx flesh) showed clinical signs of kidney granuloma. Fish fed with formular 3, 4, 7, and 8 poor growth was observed without showing disease symptoms, particularly abdominal distention, swelling of kidney, exophthalmia and body darkening. Retarded growth may have been caused by loss of appitite due to the behavior of fish which otherwise favorably consumes fresh feed. Fish fed with formular 1 exhibited loss of appitite, weight loss. darkening of the body, severe emacination and extended operculum. Abdominal distention and exophthalmia of varying degrees without periorbital hemorrhages were also characterzed. . No lesions on the skin or fin were observed. Some fish with abdominal distention also contained clear, bacteriological sterile ascitic fluid within the peritoneal cavity. Affected kidneys were enlarged containing a whitish granular material (Fig. 1) as described by Boonyaratpalin et al. (1990). The granulomatous proliferation was spread over the posterior kidneys having a gritty texture. Macroscopic examination on the squash preparations of the granulomatous kidneys exhibited a large number of needle-like crystals (Fig. 2). The needle-like crystals in the kidney from this experiment resembled the kidney tyrosinosis in spariid fish (*Sparus aurata*) studied by Paperna (1987).

Histopathology

Histological sections of the affected kidneys of fish fed with formular 1 showed necrosis and degeneration of kidney tubules. Massive accumulation of eosinophilic materials (possible proteinatous materials) in the tubules due to the malfunction of glomeruli were observed. Highly dilated glomeruli capillaries and Bowman's space associated with shrunken glomeruli were also detected (Fig. 3). Fig. 4 shows the deposition of needle-like crystals in the renal tubule of the affected fish. It was appeared that all the affected fish fed with formular 1 had needle-like crystals as the characteristics of this disease. Although in this experiment, no attempts were made to identify this crystal chemically, only two chemical substances, calcium and tyrosine, have been considered to be the cause of the crystalline deposition in kidney (Harrison

and Richards, 1979 ; Paperna, 1987). Furthermore, brush borders of the affected kidney also showed distention and fusion of microvilli. These may become the protein masses deposited in the renal tubules (Fig.5). Degenerative changes in the proximal tubules of the kidney of fish fed with formula 1 may indicate some protein imbalance in feed. Moreover, severe alterations of liver specially the increasing of lipid droplet in hepatocytes (Fig.7 and 8) may also indicate the effect dietary performance.

Electron micrographs of the same kidney showed epithelial cells of proximal tubules containing large amount of lysosomes. Nuclear degeneration (Fig. 6) and high amplitude swelling of mitochondria containing a few cristae were also detected, indicating degeneration may occurred shortly.

Seabass fed with experimental diet formula 2-8 showed slight changes in kidney tissues. Although necrosis and degeneration of hemopoietic tissues of affected kidneys as well as infiltrations of fibroblastic cells were detected, no needle-like crystals, the suspected character of kidney granuloma were seen in deposition in renal tubule as those found from fish fed with formular 1.

Gross pathological observations and histopathological changes demonstrated the prevalence and the progressive induction of kidney granuloma in seabass when fed with refrigerated minced caranx flesh. Quality of feed seem to play a major role in seabass feed intake. No signs of kidney granuloma were observed from fish fed with whole caranx and sardine which contained more calcium components. As this experiment was conducted in the aquaria, therefore calcium avialable in supplied sea water in aquaria was limitted. In this case the crystal deposited in kidney of seabass is more likely composed of tyrosine rather than calcium. The presence of needle-like crystal deposited in kidney and massive necrosis with the extensive areas of inflammation were the characteristics of this finding. Similar results were obtained from previous studies on the nephrocalcinosis in rainbow trout, *Salmo gairdneri*, and visceral granuloma in brook trout, *Salvelinus fontinalis* (Durnbar and Herman, 1971; Harrison and Richards, 1979). However in rainbow trout the inflammation was limitted in some areas and accompanied with hemorrhagic lesions (Harrison and Richards, 1979). In the present study, no hemorrhagic inflammmation was detected.

. The results presented here, using caranx flesh as fish feed may play a major role in development of kidney granuloma in cultured seabass. Therefore, tyrosinosis should be emphasized for further study.

ACKNOWLEDGMENTS

This research was supported under Grant No. 936-5542-G-00-8031-00, Program in Science and Technology Cooperation, Office of the Science Advisor, U.S. Agency for International Development. The authors wish to thank Dr. Rao Gayathri for her valuable comment.

REFERENCES

Boonyaratpalin, S., J. L. Fryer, R. P. Hedrick, K. Supamattaya, S. Direkbusarakom and U. Jadesadakrisorn. 1990. Development of kidney disease and occurrence of pathogens in seabass (*Lates calcarifer*) fed two different diets. Technical paper No. 8. National Institute of Coastal Aquaculture, Songkhla, Thailand. 13p.

Durbar, C. E. and R. L. Herman. 1971. Visceral granuloma in brook trout (*Salvelinus fontinalis*). Journal of Nutrition 101:1445-1452.

Harrison, J. G. and R. H. Richards. 1979. The pathology and histopathology of nephrocalcinosis in rainbow trout *Salmo gairdneri* Richardson in fresh water. Journal of Fish Disease 2:1-12.

Paperna, I. 1987. Systemic granuloma of spariid fish in culture. Aquaculture 67:53-58.

Fig. 1 Seabass (*Lates calcarifer*) fed with caranx flesh exhibited kidney granuloma



Fig. 2 Squash preparation of kidney granuloma revealed a numerous needle-like crystals

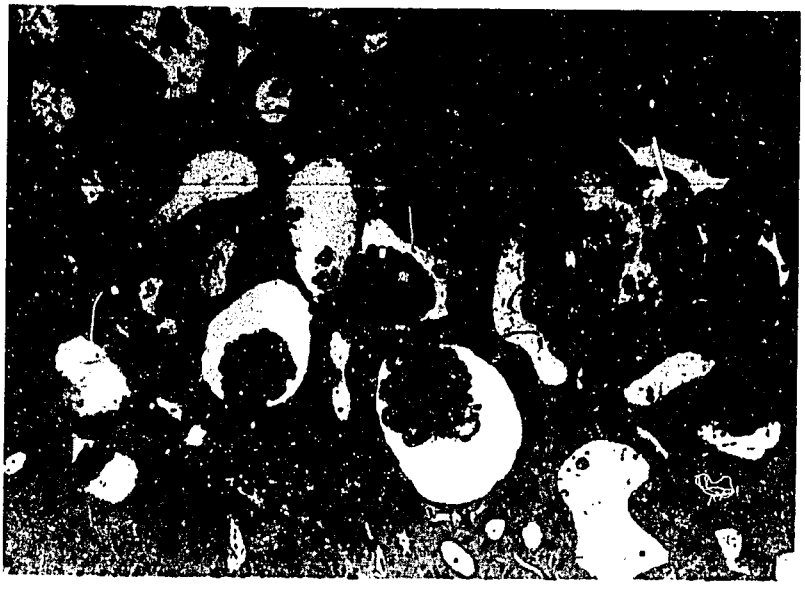

Fig. 3 Kidney of the affected seabass showed the dilation of renal tubule and shrunken of glomerulus (H&E, x230)

Fig. 4 The deposition of needle-like crystals in renal tubule of the affected seabass (H&E, x560)



Fig. 5 Affectd kidney exhibited fibrosis of interstitial tissue and renal tubule filled with nitrogenous waste (H&E, 230)

Fig. 6 Electron micrograph of affected renal tubule revealed nuclear degeneration



Fig. 7 The deposition of lipid droplet in hepatocyte of the affected seabass fed with refrigerated minced caranx flesh (H&E x230)

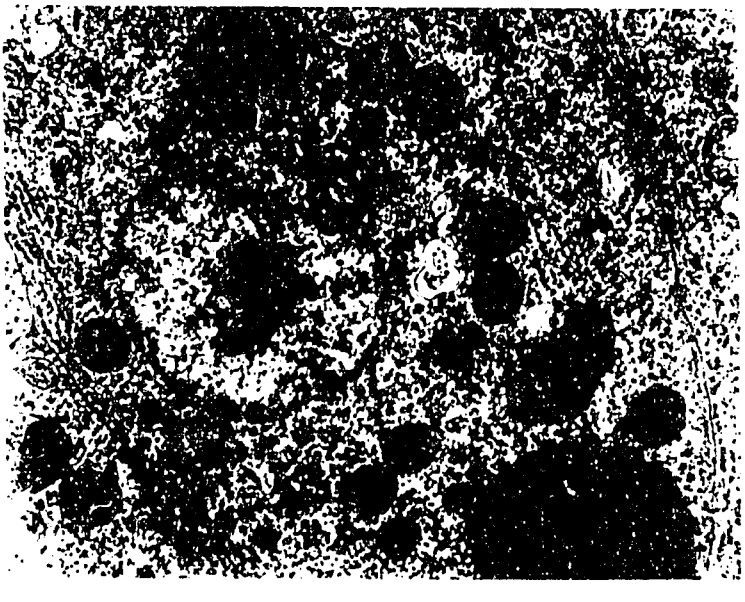

Fig. 8 Electron micrograph of the same liver showed lipid droplet and myelin figure in the cytoplasm of hepatocyte

EFFECT OF CARANX FISH (*SELAROIDES LEPTOLEPIS*) FLESH ON THE DEVELOPMENT OF KIDNEY DISEASE IN SEABASS (*LATES CALCARIFER*)

S. Boonyaratpalin [1], J. Kasornchandra [1], K. Supamattaya [2], U. Ekpanithanpong [1], and Y. Danayadol [1].

[1] National Institute of Coastal Aquaculture, Kaoseng, A. Muang Songkhla 90000, Thailand.

[2] Department of Aquatic Science, Faculty of Natural Resource. Prince of Songkla University, Hatyai Campus, Thailand.

ABSTRACT

The effect of caranx fish (*Selaroides leptolepis*) that influenced the development of kidney disease in seabass (*Lates calcarifer*) was investigated. Two size and weight (3-5 cm and 7-9 g, and 7-9 cm and 14 - 16 g) classes of seabass were compared in two experiments using the some six experimental diets which were as follows: 1. refrigerated minced caranx flesh; 2. minced caranx flesh refrigerated after one day; 3. minced caranx flesh refrigerated after two days; 4. minced caranx flesh refrigerated after three days; 5. moist pelleted feed and 6. moist pelleted feed with 4% tyrosine. Seabass fed diets 1 and 6 developed systemic kidney granuloma at 32 and 35 days respectively. The disease symptoms were observed only in the smaller size class of 3-5 cm seabass. The development of kidney granuloma was caused by the deposition of crystalline tyrosine in kidney. Tyrosine accumulation was analysed from the affected kidney. Blood parameters, hematocrit, hemoglobin, red blood cell and thrombocyte count were significantly different in the two size groups. Dietary imbalance was cause due to the species of trash fish used. To eliminate this effect, moist pelleted feed was recommended.

EFFECT OF CARANX FISH (*SELAROIDES LEPTOLEPIS*) FLESH ON THE DEVELOPMENT OF KIDNEY DISEASE IN SEABASS (*LATES CALCARIFER*)

INTRODUCTION

Kidney disease is one of the most serious syndrome occurring in culture seabass *(Lates calcarifer)* in southern Thailand. This disease generally appears at approximately six weeks after hatching or at the beginning of culturing period in the net cages, and in some cases, causing mortality exceeding 90% of the population. Gross signes of the disease demonstrated the swelling of kidney, abdominal distention, exophthalmia and body darkening. The liver turns to grey coloration and mottled accompanying spleenomagalia. Kidney hypertrophy has a gritty texture with a modular surface. Squash preparation of granulomatous kidney revealed the presence of needle-like crystal. Boonyaratpalin et al., (1990) demonstrated that prevalence and severity of kidney granuloma was directly influenced by diet particularly trash fish. The caranx fish (*Selaroides leplolepis*) flesh was found to be the causative agent of the kidney disease in an experimental seabass fry. Therefore in this experiment, an attempt was made to chemically characterize the needle-like crystal granuloma in seabass kidney and identify the affected size of seabass to the kidney disease.

MATERIALS AND METHODS

Experiment 1. The experiment was conducted in 1990 at the National Institute of Coastal Aquaculture, Songkhla. One thousand seabass of length ranging from 1 to 2 cm were obtained from the institute's hatchery. The fish were acclimatized to survive in experimental glass tanks for 2 weeks. Before starting, fifty fish were randomly sacrified and subjected to macroscopic detection to insure the absence of kidney granuloma. The experiment was carried out in eighteen, 0.2x0.5x0.3 m^3 glass tanks containing 25 litres of 25-30 ppt sea water at 27-29 °C. Each glass tank was equipped with ana eration system and constant water flow at a rate of 0.5 l/min. The water supply flowed through a sub-sand filter system to eliminate living organisms if any.

Six different diets were designed before starting the experiment (Table 1-2). They were prepared every week and kept in the freezer at -3 °C. The initial size of the

experimental seabass were 7-9 g in weight and 3-5 cm in length. The experimental fish were graded to reduce cannibalism before stocking in the glass tanks at a density of 20 fish tank for 3 replicates. Fish were fed 'ad libitum' twice a day at 09.30 and 14.30 h. The amounts of feed used were recorded everyday. The glass tanks were cleaned every morning before feeding. The external clinical signs and survival number were also observed and recorded.

At the end of twelve weeks 10 fish were taken from each treatment. Length and weight of each fish were recorded. Blood samples were withdrawn from the caudal blood vessel, using heparin (4 mg/cm^3 blood) as the anticoagulant. Hemoglobin was measured as cyanmethemoglobin (Sigma, 1982), hematocrit levels were measured by the microhematocrit method (Larsen and Sneiszko, 1961). The blood was diluted using Yokoyamas fluid (Conroy, 1970) in order to count red blood cells, white blood cells and thrombocytes (Hesser, 1960). The blood index was calculated using the formula of Johanson et al., (1975). All data of initial weight, final weight and blood parameters were analysed statistically using analysis of variance and Duncan's new multiple range test.

After blood collection, the fish were gross and microscopically examined for kidney granuloma. Gill tissues, kidney and liver were preserved in 10% neutral buffered formalin, dehydrated and embedded in paraffin. The sections were stained with haematoxyline and eosin.

The remaining fish kidney were pool collected and freeze dried for amino acid analysis by Amino Acid Analyzer, Hitachi, Model 835930 (Spindler et al., 1984).

Experiment 2. The materials and methods for the experiments were the same as in experiment 1. The only difference was the initial stocking size of seabass and the experimental units.

The initial size of the experimental seabass were 14-16 g in weight and 7-9 cm in length, at the stocking density of 20 fish/tank with 2 replicates. The experiment was carried out in twelve circular fiberglass tanks containing 100 litres of 25-30 ppt sea water at 27-29 °C. Each tank was equipped with an aeration system and constant water flow at a rate of 1 L/min.

Table 1. Ingredient components of moist pelleted feed

Ingredient	g/100 g
Fish meal	70
Choline chloride	0.5
Vitamin C	0.05
Vitamin premix*	1.5
Mineral premix**	4
Marine fish liver oil	3
Soy bean oil	3
CMC	6
- Cellulose	1.95
- Starch	10

* Vitamin premix (mg/ 100 g of feed): Thiamine HCI 5, Riboflvain 20, Pyridoxin HCI 5, Niacin 75, Ca-Pantothenate 50, Inositol 200, Biotin 0.5, Folic acid 1.5, Cyanocobalamin 10 (ug), Menadione 4, Tocopherol avetate 40, Vitamin A 1,000, Vitamin D 200 (iu), B.H.T. 1.0, Dextrose as a filler.

** Mineral premix (per 100 g of feed): NaCl 0.173 g, $MgSO_4$ $7H_2O$ 0.545 g, $NaH_2PO_4.2H_2O$ 0.347 g, KH_2PO_4 0.945 g, Ca $(H_2PO_4)_2H_2O$ 0.540 g, Fe citrate 0.118 g, Calactate 1.301 g, Kl 0.579 g, $AlCl_3$ 0.597 mg, $CuCl_3$ 0.398 mg, $MnSO_4$ 3.184 g, $CoCl_2$ 3.979 mg, $ZnSO_4$ 11.94 mg.

Table 2. Six experimental diets on the development of kidney disease of seabass (*Lates calcarifer*)

Diet	Description
1	Refrigerated minced caranx flesh
2	Minced caranx flesh that has been left outside for one day andd then refrigerated
3	Minced caranx flesh that has been left outside for two days and then refrigerated
4	Minced caranx flesh that has been left outside for three days and then refrigerated
5	Moist pelleted feed as in Table 1
6	Moist pelleted feed with 4% tyrosine

RESULTS AND DISCUSSION

Experiment 1.

Occurrence in ralation to diets.

Average body weight, feeding weight, survival, first symptom of developing, disease, number of fish with the symptom and number of fish with the kidney granuloma for all treatments are shown in Table 3. Average body weight of seabass fed diets number 1, 2, 5 and 6 were in the range of 26.9 -30.4 g at the end of 12 weeks. At the same time, seabass fed diets number 3 and 4 weighed only 14.4 and 17.6 g respectively. Growth of seabass fed diets number 3 and 4 related to the poor feeding at 521 and 548 g only. The total amount of feed given was 1,655, 1,295, 1,542 and 1,036 g for seabass fed diets 1, 2, 5 and 6 respectively. Survival of seabass fed diets 1 and 6 was (98%) and (75%) while the survival of seabass fed diets 2, 3, 4 and 5 was 100%. This difference in survival rate was probably due to the kidney granuloma damage. The first symptom was shown at 32 and 35 days for seabass fed diets 1 and 6 respectively. Total number of kidney disease seabass in these two treatments were (45%) and (60%) and with kidney granuloma of (25%) and (30%).

41

Table 3. Average growth, survival, symptom and kidney granuloma development of seabass (*Lates calcarifer*) fed with six different diets

Listed item	Diet					
	1	2	3	4	5	6
Initial average weight (g)	8.2	7.3	7.5	8.7	8.5	7.9
Final average weight (g)	28.3	26.9	17.6	14.4	29.4	30.4
Feeding weight (g)	1,655	1,295	548	521	1,542	1,036
Survival rate (%)	98	100	100	100	100	75
First symptom developing (d)	32	-	-	-	-	35
No. fish w Symptom (%)	45	-	-	-	-	60
No. fish w kidney granuloma (%)	25	-	-	-	-	30

Table 4. The blood parameters and some body components of seabass (*Lates calcarifer*) fed with six different diets.

Parameters	Diet					
	1	2	3	4	5	6
Body weight (g)	28.30 ± 2.00^{cd}	26.90 ± 1.79^{c}	17.60 ± 1.90^{b}	14.40 ± 2.55^{a}	29.40 ± 1.65^{de}	30.40 ± 2.12^{e}
Body length (cm)	11.40 ± 0.97^{a}	10.70 ± 1.06^{a}	11.00 ± 0.67^{a}	11.10 ± 0.99^{a}	11.70 ± 0.82^{a}	11.70 ± 0.82^{a}
Hematocrit (%)	24.18 ± 3.84^{b}	25.08 ± 2.86^{b}	23.13 ± 2.24^{ab}	20.91 ± 2.75^{a}	28.32 ± 1.59^{c}	28.53 ± 1.42^{c}
Hemoglobin (g %)	7.30 ± 2.12^{c}	6.72 ± 1.10^{bc}	5.51 ± 1.64^{ab}	5.33 ± 0.40^{a}	7.18 ± 1.84^{c}	7.48 ± 0.88^{c}
RBC (x10^6 cell/mm^3)	4.36 ± 1.02^{bc}	4.06 ± 0.63^{bc}	3.87 ± 0.83^{ab}	3.41 ± 0.30^{a}	4.49 ± 0.48^{bc}	4.57 ± 0.44^{c}
WBC (x10^4 cell/mm^3)	2.60 ± 0.82^{a}	4.22 ± 1.70^{bc}	3.60 ± 0.90^{abc}	3.82 ± 0.52^{bc}	3.36 ± 0.52^{ab}	4.62 ± 1.52^{c}
Thrombocyte (x10^4cell/mm^3)	4.86 ± 1.51^{b}	5.20 ± 1.18^{b}	3.53 ± 1.07^{a}	4.64 ± 0.87^{b}	5.18 ± 0.94^{b}	5.46 ± 1.02^{b}
MCHC (%)	29.64 ± 5.75	28.15 ± 6.48	23.87 ± 6.71	25.92 ± 3.91	25.27 ± 5.81	26.22 ± 2.75^{ns}
MCH (pg)	16.55 ± 2.38	18.26 ± 3.41	14.60 ± 3.78	15.75 ± 1.76	15.94 ± 3.30	16.43 ± 2.09^{ns}
MCV (um^3)	56.79 ± 7.34	61.29 ± 8.59	64.06 ± 24.43	60.17 ± 6.52	63.46 ± 3.71	62.84 ± 6.20^{ns}

Value within the same row having a common superscript are not significantly different (P>0.05)

ns : no significant different

RBC : Red blood cell, WBC: White blood cell

MCHC : Mean corpuscular hemoglobin concentration

MCH : Mean corpuscular hemoglobin, MCV: Mean corpuscular volume

Table 5. Amino acid components from kidney of seabass (*Lates calcarifer*) fed with six different diets.

Amino acid	Diet					
(%)	1	2	3	4	5	6
Asp	4.99	5.19	5.29	4.92	5.02	5.03
Thr	2.71	2.82	2.88	2.52	2.68	2.72
Ser	2.68	2.83	2.87	2.66	2.58	2.64
Glu	6.59	6.99	6.91	6.65	6.84	6.56
Pro	2.32	2.33	2.31	2.22	2.26	2.22
Gly	2.91	2.79	2.73	2.69	2.76	2.61
Ala	2.91	3.03	3.06	3.02	2.95	2.92
Val	2.74	2.65	2.71	2.87	2.95	2.95
Ile	2.01	2.16	2.14	2.14	2.27	2.27
Leu	4.39	4.66	4.75	4.35	4.47	4.33
Phe	2.34	2.44	2.49	2.21	2.27	2.23
Lys	3.75	4.00	3.55	3.69	3.85	3.71
Arg	3.44	3.55	3.55	3.30	3.47	3.31
Tyr	6.43 *	1.18	1.09	1.15	1.33	8.40 *
His	1.34	1.24	1.31	1.19	1.18	1.14

* remarked different from other comparable value .

The body weight and length at the end of experiment with some blood parameters are shown in Table 4. Body weights were significantly different at the end of 12 weeks. The blood parameters that differed significantly were hematocrit, hemoglobin, red blood cell count, white blood cell count and thrombocyte count. Hemoglobin and red blood cell count of seabass fed caranx flesh (diet 1) and moist pelleted feed with 4% tyrosine (diet 6) were high when compared with other treatments, while white blood cell count were lower than in other treatments. There were no significant differences in the body length, mean corpuscular hemoglobin concentration, mean corpuscular hemoglobin and mean corpuscular volume.

The amino acid components from kidney of seabass fed with six different diets are shown in Table 5. The tyrosine from kidney of seabass fed caranx flesh and moist pelleted feed with 4% tyrosine were high with value of 6.43 and 8.4, respectively, when compared with other treatments. It could be assumed that the crystal granuloma in seabass kidney contained tyrosine. The rest of the amino acids from seabass kidneys in other treatments were not different.

Development of Gross Symptoms

Results indicated that seabass fed different diets grew normally and were free from disease symptoms through the first four weeks. After 32 days, fish receiving caranx flesh and moist pelleted feed supplemented with 4% tyrosine developed symptoms. Table 3 shows the incidence of kidney granuloma development disease among the experimental population fed different diets. Gross pathology was characterized as darkening of the body including severe emacination and extended operculum. Abdominal distention and exophthalmia of varying degrees without periorbital hemorrhages was detected. Affected kidneys showed swellings of verying degrees. The granulomatous proliferation was spread over the posterior kidney showing of nodular lesions with gritty texture. These nodules were filled with a mass of discrete, hard needle-shape crystalline (Fig. 1) which was chemically identified as tyrosine. Accumulation of tyrosine in kidney was previously reported bv Paperna et al., (1980) in maricultured spariid fish (*Sparus aurata*).After 32 days, five of twenty fish (25%) fed diet 1 (minced caranx flesh) developed crystal granuloma in kidney while six



Fig. 1 Squash preparation of kidney granuloma exhibited needle-like crystals.

of twenty fish (30%) fed diet 6 (moist pelleted feed supplemented with 4% tyrosine) showed disease symptoms after 35 days.

Histopathological changes

Seabass fed with caranx flesh and moist pelleted diet supplemented with 4% tyrosine showed similar clinical sings and histopathological changes. Histopathological damages consisted of inflammatory and necrotic changes and tissue-specific damage. Secondary gill lamella of the affected fish exhibited edema (Fig. 2). Fusion of secondary gill lamella was also detected (Fig. 2). High vacuolation as well as focal areas of necrosis surrounded by degenerating cells were detected in liver of the affected fish (Fig. 4). Degeneration of hepatocytes was frequently observed (Fig. 6). Moderate and severe lipidosis was well defined due to the nutritional disorder. Most hispathological changes detected in kidney demonstrated necrosis and degeneration in the epithelium of the second proximal seqment of the renal tubules (Fig. 5). The tubules frequently contained a mass of eosinophilic, amorphous material (possible proteinatous material) due to the malfunction of glomeruli. Extensive degeneration and necrosis of the tubular epithelium resulted in the collapse of the renal tubule and the formation of a necrotic lesion (Fig. 7).

Seabass fed with diets number 2, 3, and 4 showed slight histopathological changes in kidney tissue. Although some necrosis and degeneration of hemopoietic tissues of affected kidney as well as infiltation of fibroblastic cells was detected, there was no needle-like crystal deposited in renal tubule observed. No pathological changes was observed in fish fed with moist pelleted feed (diet. 5).

Histopathological and gross external examinations indicated the prevalence and development of kidney granuloma in seabass when fed with caranx flesh and moist pelleted feed supplemented with 4% tyrosine. No sign of kidney granuloma was observed from fish fed with low qualities caranx flesh diets number 2, 3 and 4. Seabass fed with moist pelleted feed (diet 5) showed good growth without kidney granuloma development. The presence of crystal granuloma, necrosis and degeneration in renal tubule of affected kidney were similar to tyrosinaemia and kidney tyrosinosis in gilthead sea bream (*Sparus aurata*) described by Paperna et al., (1980) and Paperna (1987). In diet number 6, the moist pelleted feed overloading of tyrosine also induced crystalline



Fig. 2 Edematous secondary lamella in seabass fed caranx flesh (H&E, x90)

Fig. 3 Hyperplasia and fusion of secondary lamella in seabass fed caranx flesh (H&E, x230)



Fig. 4 Focal necrosis in liver of seabass fed with caranx flesh (H&E, x230)

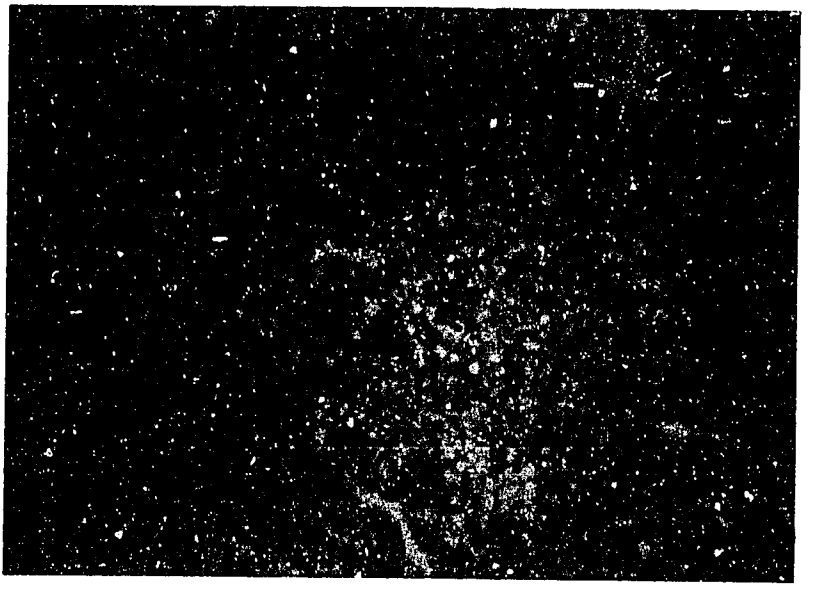

Fig. 5 Fatty degeneration in liver of seabass fed caranx flesh (H&E, x90)

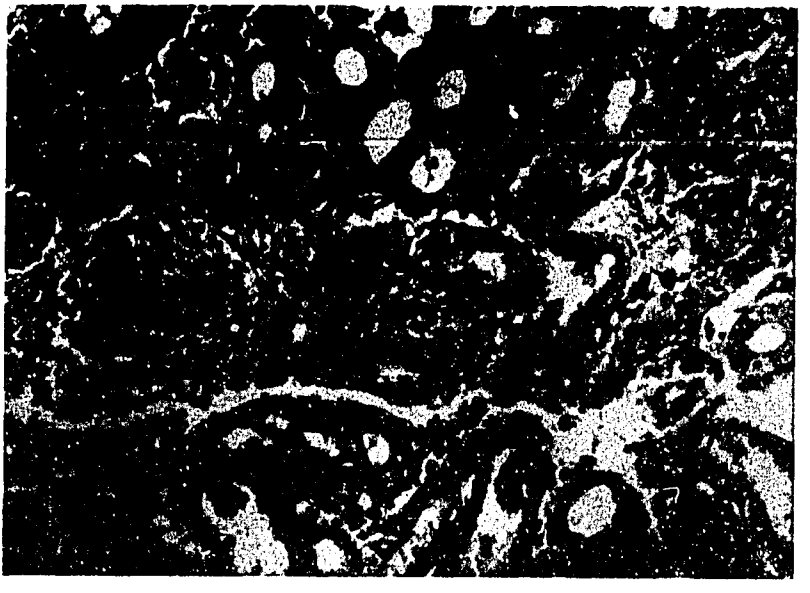

Fig. 6 Necrosis and degeneration of the epithelium of the second proximal segment of the renal tubules in fish fed caranx flesh (H&E, x230)

Fig. 7 Necrosis and degeneration of tubular epithelium with accumulation of eosinophilic materials in tubules in fish fed caranx flesh (H&E, x230)

Table 6. Average growth, survival, symptom and kidney granuloma development of seabass (*Lates calcarifer*) fed with six differant diets.

Listed item	Diet					
	1	2	3	4	5	6
Initial average weight (g)	15.3	14.9	16.0	14.5	14.7	15.5
Final average weight (g)	62.90	25.88	21.85	19.37	56.95	47.58
Feeding weight (g)	2,522	1,877	787	777	2,339	1,426
Survival rate (%)	100	100	100	75	100	100
First symtom developing (d)	-	-	-	-	-	-
No. fish w symptom (%)	-	-	-	-	-	-
No. fish w kidney granuloma (%)	-	-	-	-	-	-

Table 7. The blood parameters and some body. components of seabass (*Lates calcarifer*) fed with six different diets.

Parameters	Diet					
	1	2	3	4	5	6
Body weitht (g)	62.90 ± 26.87^{c}	25.88 ± 10.92^{a}	21.85 ± 3.69^{a}	19.37 ± 6.32^{a}	56.95 ± 9.36^{bc}	47.58 ± 15.25^{b}
Body length (cm)	15.80 ± 2.53^{b}	12.70 ± 1.87^{a}	12.70 ± 0.98^{a}	12.60 ± 1.35^{a}	17.20 ± 1.25^{b}	16.11 ± 1.45^{b}
Hematocrit (%)	25.84 ± 2.47^{bc}	26.60 ± 3.49^{cd}	23.60 ± 2.48^{ab}	21.35 ± 3.94^{a}	28.60 ± 1.39^{d}	28.55 ± 1.69^{d}
Hemoglobin (g%)	8.16 ± 0.83^{c}	7.12 ± 1.06^{abc}	6.13 ± 1.78^{ab}	5.83 ± 0.95^{a}	7.74 ± 2.30^{c}	7.44 ± 0.89^{bc}
RBC (x10^{6} cell/mm^{3})	4.48 ± 0.68^{cd}	4.07 ± 0.61^{bc}	3.82 ± 0.82^{b}	3.27 ± 0.41^{a}	4.70 ± 0.39^{d}	4.50 ± 0.39^{cd}
WBC (x10^{4} cell/mm^{3})	3.34 ± 1.79	4.06 ± 1.79	3.54 ± 0.93	4.13 ± 1.39	3.34 ± 0.63	3.93 ± 1.70^{ns}
Thrombocyte (x10^{4} cell/mm^{3})	5.20 ± 1.85^{b}	5.16 ± 1.68^{b}	3.39 ± 1.73^{a}	4.91 ± 1.43^{b}	5.88 ± 1.50^{b}	5.71 ± 1.21^{b}
MCHC (%)	31.63 ± 1.91	27.19 ± 5.50	26.01 ± 6.89	27.78 ± 4.44	26.95 ± 7.31	26.03 ± 2.37^{ns}
MCH (pg)	18.47 ± 2.41	17.71 ± 2.60	17.03 ± 0.86	18.21 ± 4.49	16.33 ± 4.07	16.59 ± 2.22^{ns}
MCV (um^{3})	58.43 ± 7.62	67.36 ± 18.09	66.19 ± 22.67	64.59 ±13.71	61.04 ± 3.67	63.88 ± 6.25^{ns}

Value within the same row having a common superscript are not significantly different (P>0.05)

ns : no significant different

RBC : Red blood cell, WBC: White blood cell

MCHC: Mean corpuscular hemoglobin concentration

MCH : Mean corpuscular hemoglobin, MCV: Mean corpuscular volume

Table 8. Amino acid components from kidney of seabass (*Lates calcarifer*) fed with six different diets.

Amino aicd	Diet					
(%)	1	2	3	4	5	6
Asp	4.36	4.54	4.32	4.49	4.63	4.72
Thr	2.56	2.67	2.72	2.59	2.69	2.54
Ser	2.67	2.73	2.66	2.52	2.49	2.71
Glu	6.49	6.71	6.65	6.55	6.59	6.72
Pro	2.23	2.37	2.21	2.29	2.40	2.19
Gly	2.78	2.79	2.80	2.69	2.76	2.59
Ala	2.97	3.07	6.10	2.99	2.95	2.93
Val	2.69	2.65	2.71	2.80	2.77	2.83
Ile	1.99	2.02	2.10	2.14	2.09	2.17
Leu	4.42	4.56	4.73	4.37	4.46	4.43
Phe	2.49	2.46	2.29	2.28	2.21	2.30
Lys	3.79	3.68	3.85	3.17	3.72	3.80
Arg	3.40	3.51	3.55	3.39	3.47	3.36
Tyr	1.18	1.23	1.09	1.15	1.29	1.30
His	1.32	1.19	1.26	1.25	1.18	1.20

granuloma in kidney. It is possible that an additional tyrosine may play an important role in contribution of metabolic imbalance of that mineral resulting in the deposition of discrete crystal in kidney. Moreover the analysis of needle-like crystal from kidneys of seabass fed caranx flesh and moist pelleted diet supplemented with 4% tyrosine by amino acid analyzer, showed high tyrosine content with normal levels of other amino acids which is similar to the deposition of tyrosine crystal in kidney caused by overloading tyrosine in feed or demonstration of tyrosinaemia in kidney (Paperna, 1987).

Experiment 2. There were no gross symptom and development of kidney granuloma in seabass fingerling (7-9 cm) fed six different diets within 12 weeks (Table 6). Although, there was significant difference in body weight, body length and some blood parameters of the experimental seabass (Table 7). The amino acid components in kidney of seabass from each treatment were not different.

In conclusion the development of kidney granuloma in seabass is caused by the deposition of crystalline tyrosine in kidney. Seabass affected by the kidney disease was in the range of 3-5 cm. Dietary imbalance in this case was due to the species of trash fish used. To eliminate this possible effect, the moist pelleted feed is recommended as it shows good growth rate with no signs of kidney disease.

ACKNOWLEDGMENTS

This research was supported under Grant No. 936-5542-G-00- 8031-00, Program in Science and Technology Cooperation, Office of the science Advisor, U.S. Agency for International Development. The authors wish to thank Dr. Rao Gayathri for her valuable comments.

REFERENCES

Boonyaratpalin, S., J.L. Fryer, R.P. Hedrick, K. Supamattaya, S. Direkbusarakom, U. Jadesadakraisorn. 1990. Development of kidney disease and occurrence of

pathogens in seabass (*Lates calcarifer*) fed two different diets. Technical paper No. 8. National Institute of Coastal Aquaculture, Songkhla. Thailand 13 p.

Conroy, D. A. and R.L. Herman. 1970. Textbook of fish disease. Jersey city, N.J.: T.F.H. Pub Inc, Translated from E. Amlacher. (NO Date) Tashenbuch Fischkranheiten. Verlag, Jena, DDR.

Hesser, E.F. 1960. Method for routine fish hematology. Prog. Fish-Cult. 22: 164-171.

Hohanson, S.M., G. Dave, A. Larson, K. Lewander and U. Lidman. 1975. Metabolic and hematological effects of starvation in the European eel. *Anguilla anguilla* L. II Hematology. Comp. Biohem. Physiol. 52 A: 431-434.

Larsen, H.N. and S.F. Snieszko. 1961. Modification of the microhematocrit technique with trout blood. Trans.

Paperna, I., Harrison, J.G. and Kissil G.W. 1980. Pathology and histopathology of systemic granuloma in *Sparus auratas* cultured in the Gulf of Aqaba. Journal of Fish Disease 3: 213-221.

Paperana, I. 1987. Systemic granuloma of sparid fish in culture. Aquaculture 67: 53-58.

Sigma Tech. Bull. No. 525. 1982. The calorimetric determination of total hemoglobin in whole blood at 530-550 mm. Sigma Chemical Lo; St. Louis. Mo.

Spindler, M., R. Stadler, and Herbert Tannor. 1984. Amino acid analysis of feedstuffs: Determination of methionine and cystine after oxidation with performic acid and hydrolysis. Journal of. Aqriculture Food and Chemistry. 32: 1366-1371.