TRAINING COURSE IN WOMEN'S HEALTH

Module One

The Female Reproductive System

International Prototype

Developed by the International Women's Health Coalition and converted to self-instructional format by the Institute for Development Training, this manual, and others in the series, is intended as a prototype only. For effective use in training programs, a country adaptation focused on the needs of a specific type of trainee, followed by pre-testing, is considered essential. For information on sources of funding for adaptation workshops, pre-tests and multiple copies of the adapted manual contact:

Institute for Development Training
P.O. Box 2522
Chapel Hill, NC 27515-2522
U.S.A.

INTERNATIONAL WOMEN'S HEALTH COALITION

684 Park Avenue
New York, N.Y. 10021 U.S.A.
(212) 628-3700
Telex: 424 064

Board of Directors
Pouru Bhiwandiwala, M.D.
Chairperson
Joan B. Dunlop
President
Richard B. Gamble
W. David Hopper
Frances Kissling
Karl Mathiasen, III
Barbara Pillsbury
Donna E. Shalala
Ieda Siqueira Wiarda

Medical Board
Sveda Firoza Begum
Bangladesh
Siva Chinnatamby
Sri Lanka
Theodore M. King
U.S.A.
Atiqur Rahman Khan
Bangladesh
Kotha Panikkar
Malaysia
O.A. Ladipo
Nigeria
Sudraji Sumapraja
Indonesia
Rustom Soonawala
India
Judith Tyson
U.S.A.
Jorge Villarreal
Colombia

Advisory Council
Judge Alfredo F. Tadiar
Philippines
Grace E. Delano
Nigeria
Genoveva Mora de Hamilton
Mexico
Aziza Hussein
Egypt
Noeke Slamet
Indonesia
Mufaweza Khan
Bangladesh
Elinor Ratcliffe
Canada
Olga Lucia Toro
Colombia

Founder
Merle S. Goldberg

April 1, 1985

Dear Clinician:

This manual was prepared for your use by a number of able and committed persons, dedicated, as you are, to improving the health care in your country. Every effort has been made to include the most accurate and up-to-date essentials of gynecological health care.

The material was designed and developed by the International Women's Health Coalition, and has been adapted for self-instructional use by the Institute for Development Training.

We do know, however, that as a prototype the material is not suitable for use in all training situations. We hope you will feel free to change anything that is inappropriate.

Your task is a significant and important one. We sincerely hope this manual plays a small part in helping you with your work.

Yours for good health.

Sincerely,

Joan B. Dunlop

Joan B. Dunlop
President

Copyright 1983 © by the International Women's Health Coalition

Any parts of this book, including the illustrations, may be copied, reproduced or adapted to meet local needs without permission from the International Women's Health Coalition, PROVIDED THE PARTS REPRODUCED ARE DISTRIBUTED FREE OR AT COST--NOT FOR PROFIT. For any reproduction with commercial ends, permission must first be obtained from the International Women's Health Coalition.

Introduction to Module One

Module One - "The Female Reproductive System" - is the first of a series of modules which make up the Training Course in Women's Health. Module One focuses on the female reproductive system, including the anatomy of the system and an explanation of how the system functions.

Module One contains basic information which is necessary for you to learn or review - if you are already familiar with the contents - before proceeding with the other modules. Modules Two through Four contain information on interrelated body systems; procedures for examining the organs of the female reproductive system; and treating problems and recognizing the signs of infections and diseases within the system. Subsequent modules also teach procedures for regulating fertility. Module One is a prerequisite for many of the modules. Read and study it carefully before continuing with any other module.

Table of Contents

	Introduction to Module One	1
	Table of Contents	2
	Instructions for the Learner	3
	Prerequisites and Objectives	4
	Pre-test	5
1	Female External Sex Organs	8
2	Female Internal Sex Organs	12
3	Reproductive Functions of the Ovaries	16
4	Reproductive Functions of the Fallopian Tubes	20
5	Reproductive Functions of the Uterus	23
6	Reproductive Functions of the Vagina	32
7	Menstruation	35
8	Fertilization and Implantation	41
	Post-test	47
	Answers to Post-test	50

Instructions for the Learner

This module, which is one of a series of modules, is self-instructional. Self-instruction is a method by which you, the learner, learn by yourself from carefully sequenced materials. The module is divided into short sections of information and each of these sections is followed by a series of questions which give you a chance to practice using the information you have learned. Answers to these questions are given so that you can check your understanding of the information.

The self-instructional method allows you to learn at your own speed and enables you to consistently check your progress in learning the information.

Follow the steps below in order to proceed through this self-instructional module in the most effective way:

1. Read the objectives for the module. They will outline for you what you will learn and be able to do after completing the module.

2. Take the Pre-test to get an idea of what you already know and what you need to learn.

3. Read and study the information in Section 1.

4. Answer the practice questions following the section without looking back at the information. Use a separate sheet of paper.

5. Check your answers using the answer sheet on the page following the questions.

6. If any of your answers are incorrect, reread the information in the section and try to answer the questions again.

7. When all your answers are correct, go on to the next section.

8. Proceed through the rest of the sections in the same way: read section; answer questions; check answers; reread section if necessary.

9. Take the Post-test after you have completed the entire module.

10. Check your answers to the Post-test using the answer sheet at the end of the module.

Prerequisites and Objectives

Prerequisites

This self-instructional module is designed for health clinicians who have a medical science background. Like the training course manual as a whole, the module is not intended as a comprehensive education. It is task specific. Therefore, as a prerequisite for this module, you must have a basic knowledge and understanding of the following terms, concepts, and procedures:

1. The systems of the human body
2. The male reproductive system
3. Metric measurement
4. Terms: pituitary gland, sperm, zygote, embryo, fetus, hormone, gestation

Main Objective

The learner will be able to identify and describe the functions of the organs in the female reproductive system and explain how the system functions, including the processes of menstruation and fertilization.

Sub-objectives

After completing this module, the learner will be able to:

1. identify the areas of the vulva, or female external sex organs, on a diagram
2. identify the 4 female reproductive organs on a diagram
3. describe the female reproductive system in terms of the interrelated functions of the four reproductive organs
4. distinguish among common, varying types of uterus positions
5. describe the process of menstruation
6. list 5 types of menstrual problems
7. describe possible solutions to the following 2 problems - amenorrhea and heavy bleeding
8. describe the process of fertilization and implantation
9. explain the conditions under which an ectopic pregnancy occurs

Pre-test

To the Learner: Before starting this module, try taking the following test. This test will give you an idea of what you already know and what you will learn in this module. You will take the same test again after you have completed the module. A comparison of your two sets of answers will give you an idea of how much you have learned from this module.

Record your answers on a separate sheet of paper. You will find the correct answers to this Pre-test in the last section of the module.

1. Below is a diagram of the female external sex organs. Using the list of organs on the right, label the 11 parts.

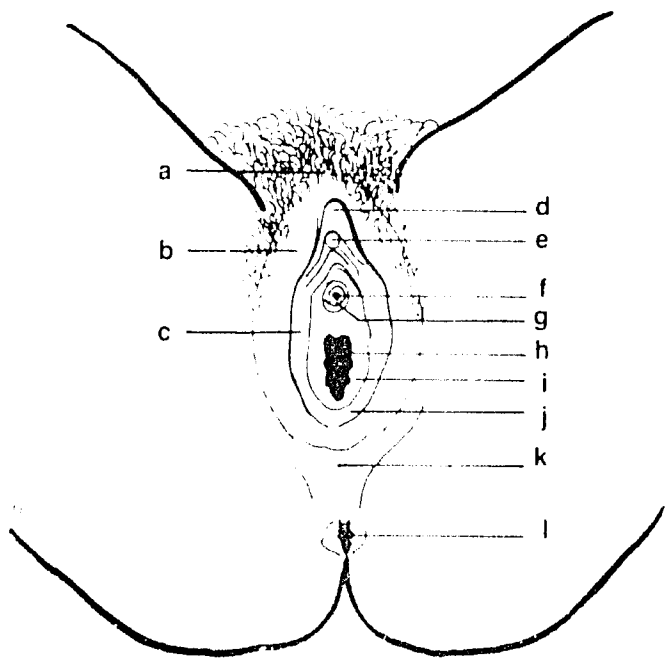

Female External Sex Organs

clitoris

hymen

vaginal opening

labia majora

labia minora

perineum

anus

mons veneris

Bartholin's glands

urethra

hood

Skene's glands

2. Below is a diagram of the female reproductive system. Label the 4 major organs.

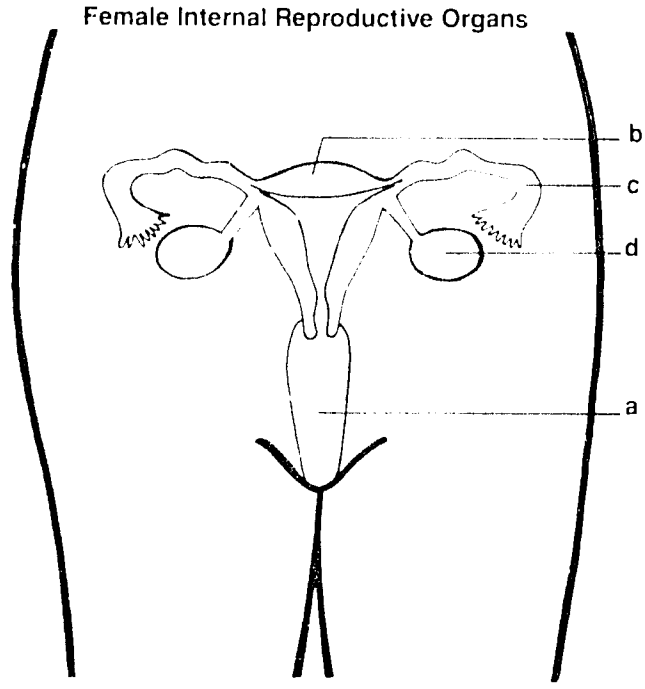

3. Describe the functions of the 4 organs of the female reproductive system.

4. Below are 4 diagrams of the uterus in varying positions. Identify the positions by labeling each diagram with one of the following descriptions:

anteflexed, retroflexed, anteverted, retroverted

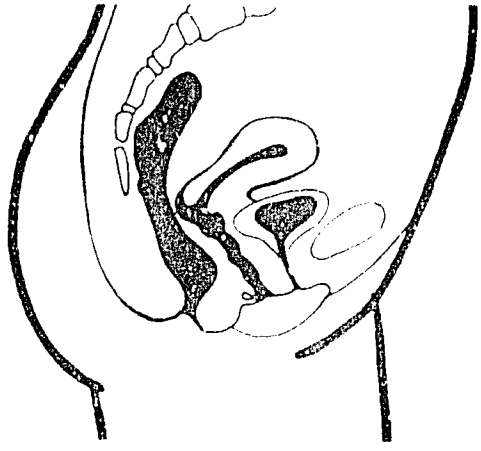

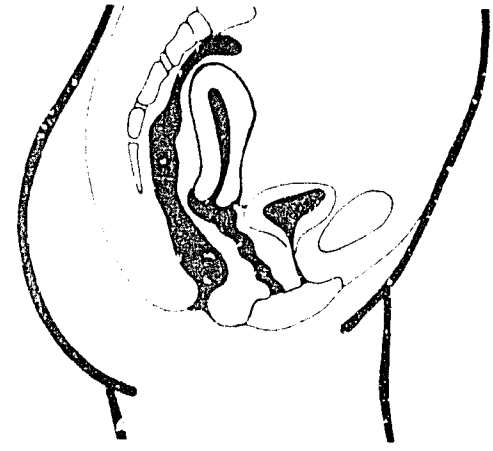

a. _____ b. _____

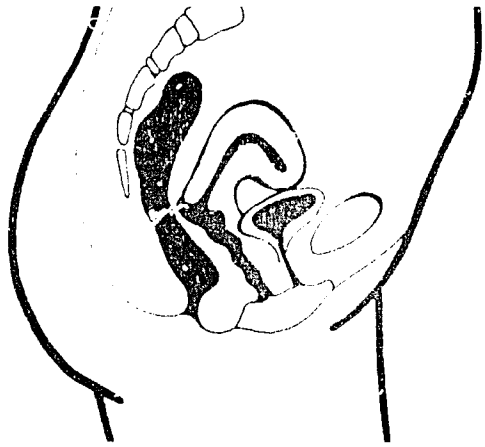

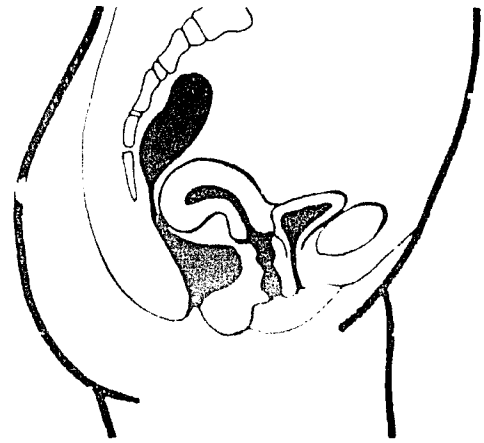

c. _____ d. _____

5. Describe the process of menstruation within the normal menstrual cycle.

6. List the 5 problems a woman might have with menstruation.

7. What treatments or referrals would you recommend for (a) primary amenorrhea and (b) heavy or prolonged bleeding? Describe their symptoms.

8. Describe the process of fertilization and implantation.

9. Explain the conditions under which an ectopic pregnancy occurs. What is the treatment?

1. Female External Sex Organs

The female reproductive system consists of external and internal organs. The external sex organs, or genitals, are known as the vulva. The parts of the vulva are identified in the diagram:

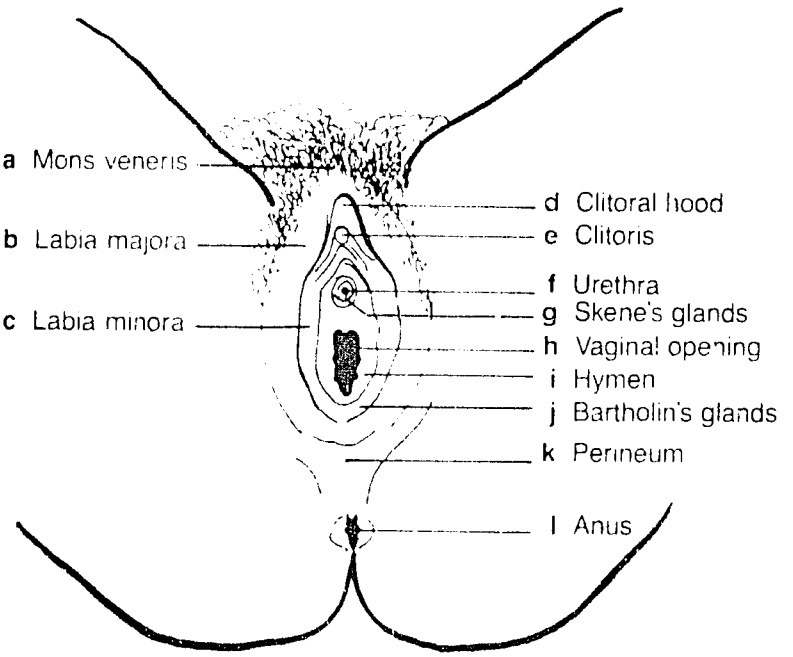

Female External Sex Organs

Look at the corresponding labeled part on the diagram of the vulva as you read the following descriptions of each individual part.

(a) the mons veneris (mount of Venus) or mons pubis, a pad of fatty tissue over the pubic bone. From puberty, this is covered with pubic hair. Extending downward and backward from the mons veneris are the:

(b) labia majora (outer lips), two folds of fatty tissue which protect the reproductive and urinary openings lying between them. These outer lips change size during a woman's life and from puberty their outer surfaces are also covered with hair. Between them lie the:

(c) labia minora (inner lips). These are delicate, hairless folds of skin quite sensitive to touch. During sexual arousal, they swell and darken in color. Below the mons area, the labia minora splits into two folds to form:

(d) a hood under which lies the:

(e) clitoris. This is a small, bud-shaped organ and the most sensitive of the female genitals. During sexual excitement, the clitoris swells with blood. Just below the clitoris are the:

(f) urethra - the external opening of the urinary passage which leads directly to the bladder - and the:

(g) Skene's glands - lie on either side of the urinary opening. They secrete a small amount of mucus and may serve to lubricate the opening.

(h) vaginal opening, the outside entrance to the vagina.

(i) The hymen is a thin membrane just inside the vaginal opening. It varies greatly in shape and size, and, in a virgin, it may be stretched or torn during the first experience of sexual intercourse, but quite often has already been stretched.

(j) The Bartholin's or vestibular glands lie at either side of the vaginal opening. They may occasionally become infected.

(k) The perineum is the triangular area of skin lying between the end of the labia minora and the anus. Below its surface are muscles and fibrous tissue that are stretched during childbirth.

(l) The anus lies below the perineum and is the external opening through which feces pass from the rectum.

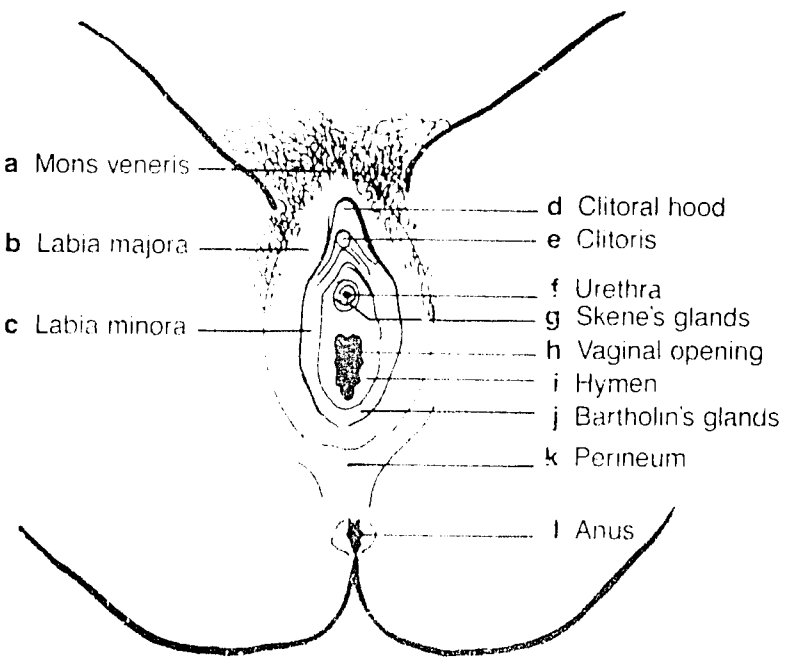

Female External Sex Organs

Practice Questions

1. Label the parts of the female external sex organs, known collectively as the vulva, using the list of terms on the right.

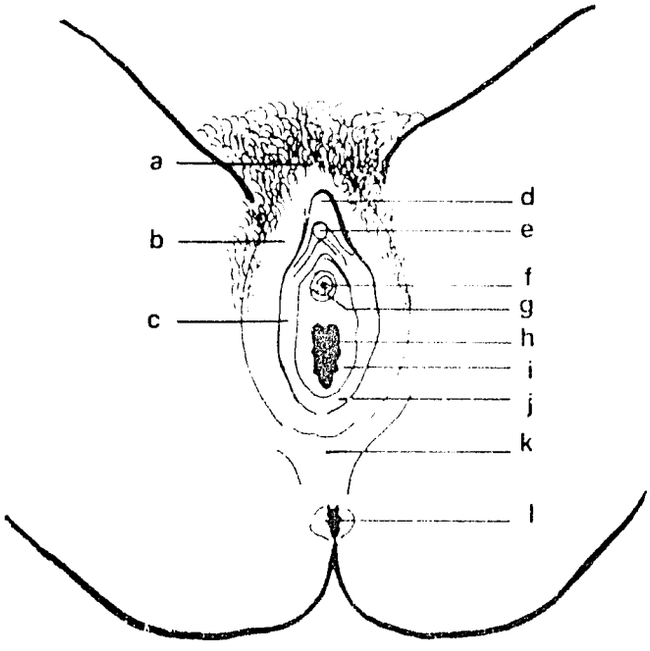

Female External Sex Organs

clitoris

hymen

vaginal opening

labia majora

labia minora

perineum

anus

mons veneris

Bartholin's glands

urethra

hood

Skene's glands

To the Learner: Turn the page to check your answers.

Answers to Practice Questions

1.

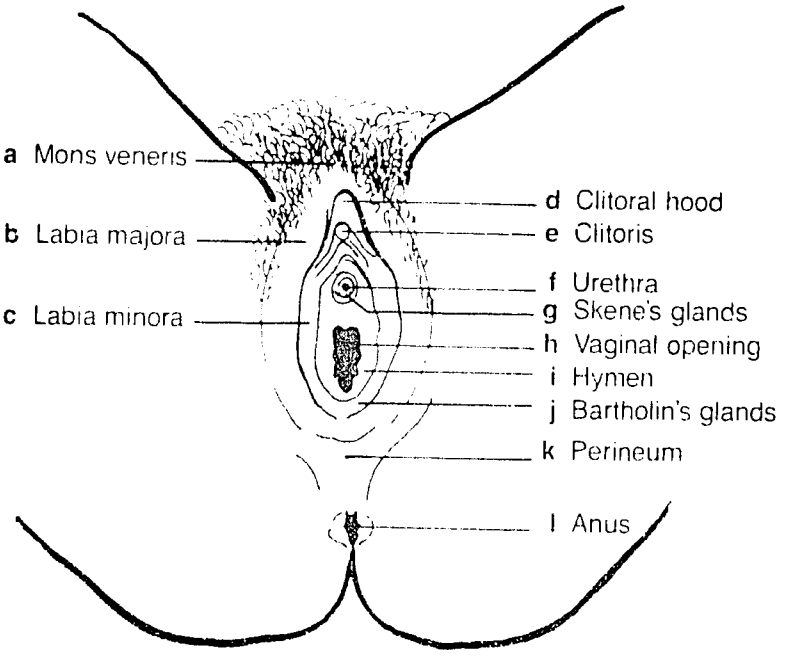

Female External Sex Organs

To the Learner: If you missed any of the answers to the questions, go back to the information section and study it again. When all of your answers are correct, go to section 2 on the next page.

2. Female Internal Sex Organs

The internal sex organs are a woman's reproductive organs. They are (1) the vagina, (2) the uterus, (3) the Fallopian tubes, and (4) the ovaries.

Following are two diagrams: a front view and a side view of the female's internal organs. The four internal sex organs are shaded.

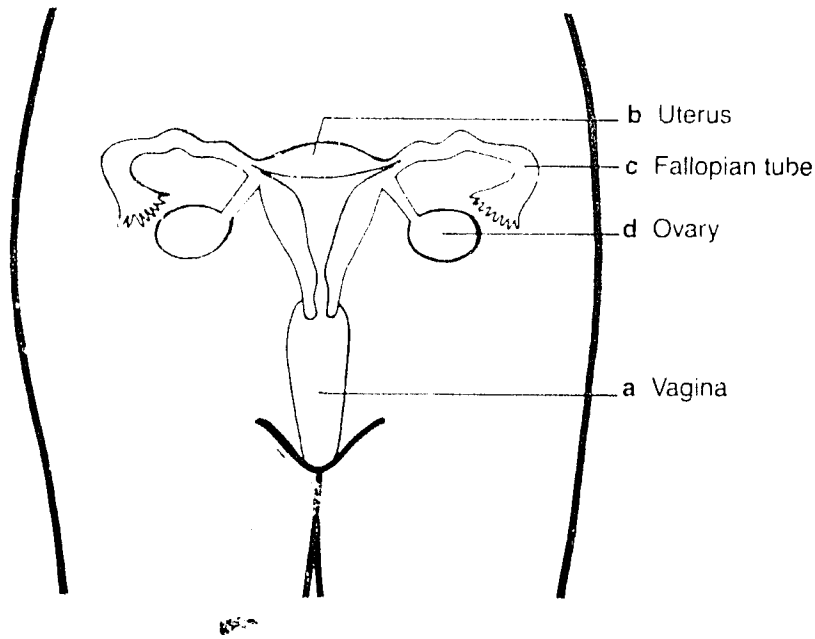

Female Internal Reproductive Organs

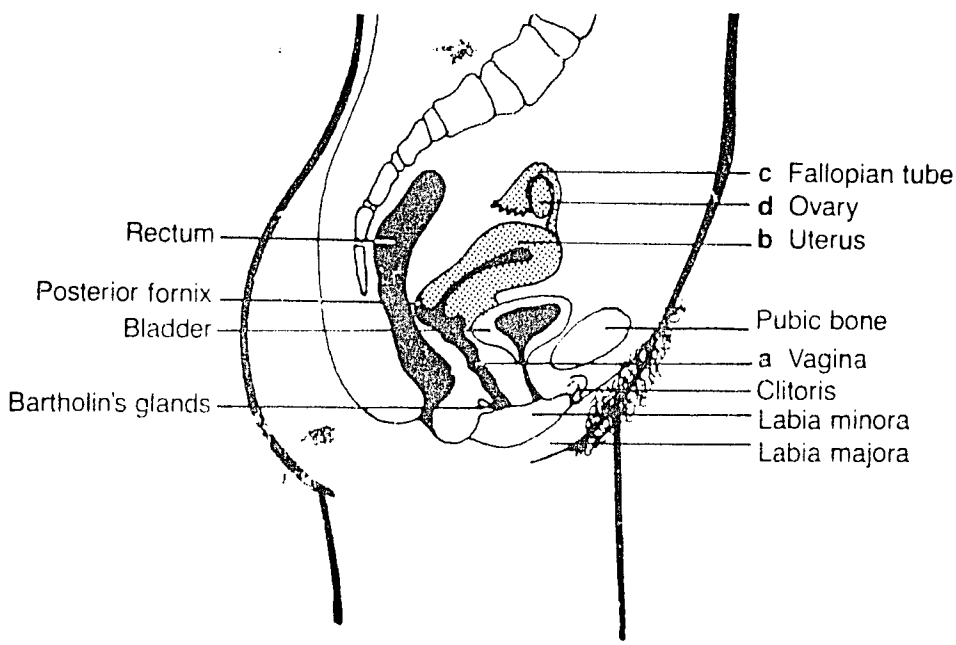

Look at the labeled organ on both diagrams as you read the descriptions of the individual reproductive organs.

(a) The vagina is a muscular passage, lying between the bladder and the rectum. It leads from the vulva upward, and at an angle, to the cervix of the uterus. It is about 10 cm long and capable of great distension. Normally the vaginal walls, which are lined with folds or ridges, lie close together. During sexual intercourse, they stretch easily and extend even more considerably during labor to allow a child to be born. The vagina is usually moist and may vary at different times of the menstrual cycle.

(b) The entire uterus (including the cervix) is a hollow, muscular, pear-shaped organ and, in its nonpregnant state, is about the size of a lemon. Seen from the front, the uterine cavity is triangular in shape, and it is here that the fetus develops during pregnancy. Parts of the uterus include the cervix, the os, the myometrium, and the endometrium.

(c) The Fallopian tubes extend outward and back from either side of the upper end of the uterus. They are about 10 cm in length and reach outward toward the ovaries.

(d) The ovaries are almond-shaped structures that produce the female egg cells (ova). They produce ova and also the female sex hormones, estrogen and progesterone. Once a month an ovum (egg) is released, which floats freely into the end of one of the Fallopian tubes. Estrogen and progesterone enter the bloodstream.

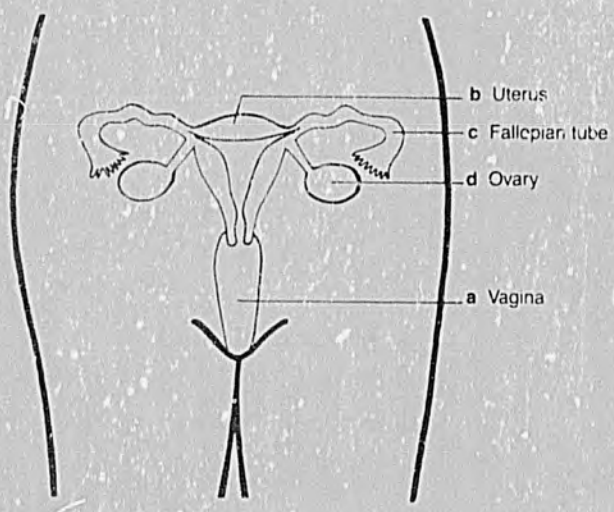

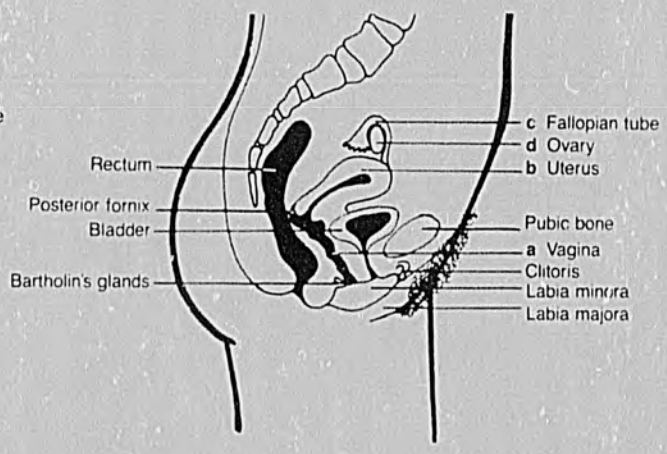

Practice Questions

1. On the 2 diagrams, identify the four internal reproductive organs, and fill in the correct name of the organ next to the letter.

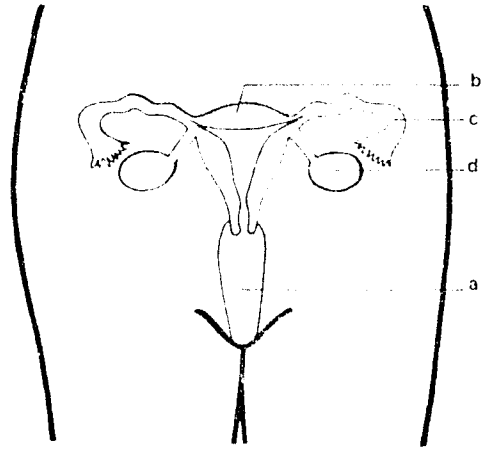

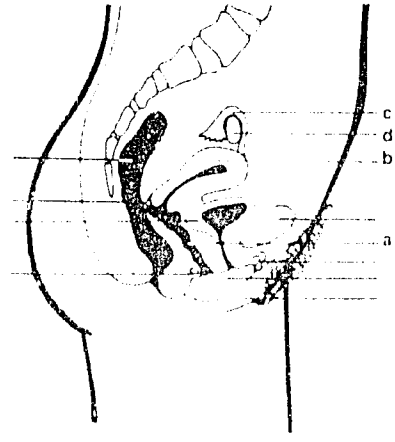

2. Using the following list of organs, identify and fill in the names of the other organs in the diagram above next to the correct letter:

bladder	clitoris	Labia majora
pubic bone	Bartholin's glands	
rectum	Labia minora	

3. Diagram 1 is a _____ (side, front) view of the internal organs while diagram 2 is a _____ (side, front) view.

To the Learner: Turn the page to check your answers.

Answers to Practice Questions

1. and 2. The 2 diagrams should be labeled with the following names of organs next to the letters:

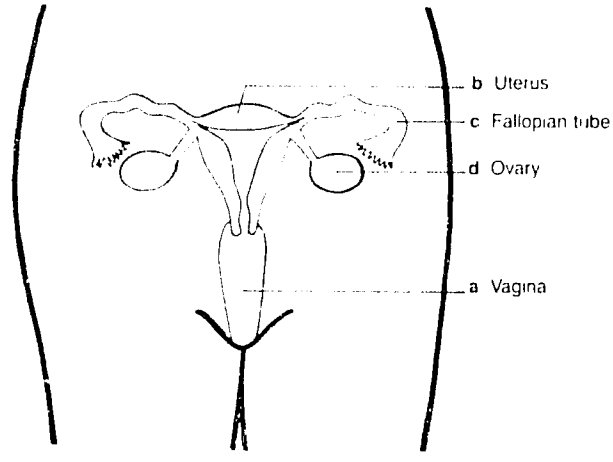

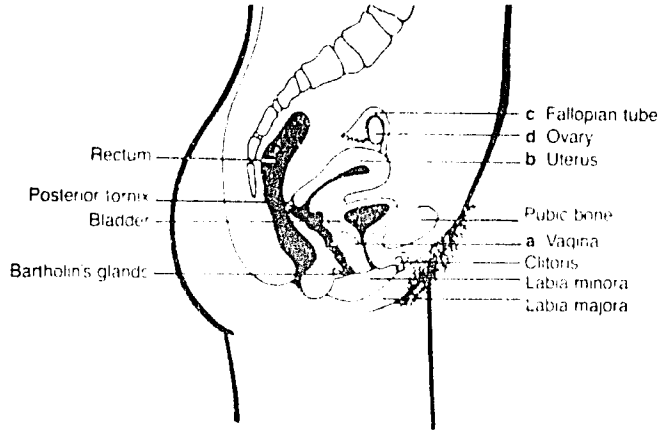

3. Diagram 1 is a side view and diagram 2 is a front view.

To the Learner: If you missed any of the answers to the questions, go back to the information section and study it again. When all of your answers are correct, go to section 3 on the next page.

3. Reproductive Functions of the Ovaries

The two ovaries, almond-shaped glandular organs, each about 3.5 cm long, are the principal structures of the female reproductive system. They are located inside the pelvic girdle, and lie within the broad ligament which attaches the uterus to the pelvic wall.

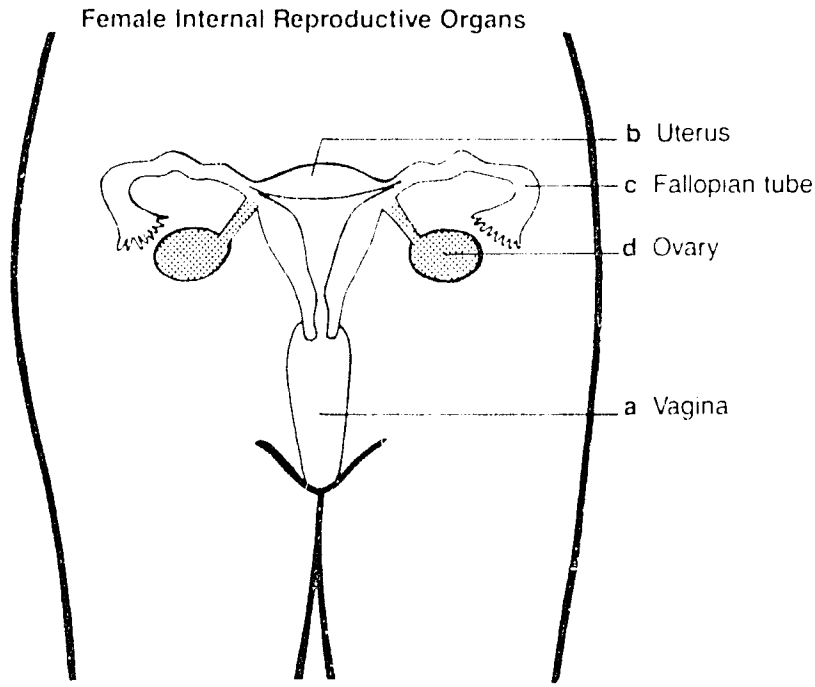

Around the age of 12 or 13 - sometimes earlier, sometimes later - under the influence of hormones produced by the pituitary gland, a number of changes occur within a girl's body. These changes ultimately lead to the ability to reproduce. The egg cells, which have lain dormant so long within the ovaries, begin to mature.

The fluid-filled structure near the surface of the ovary in which the egg cell grows is known as a follicle. When the egg cell becomes ripe, it is released as the follicle ruptures the surface of the ovary. The process whereby an egg, or ovum, is released from the ovary is ovulation.

The ovary does more than just produce egg cells. The ovarian follicle produces two very important female sex hormones. When stimulated by the pituitary gland, the follicle secretes estrogen. Estrogen, when absorbed into the bloodstream, induces ovulation and contributes to the growth and maintenance of the uterus, Fallopian tubes, vagina, and ducts of the mammary glands. Also, estrogen is responsible for the development of secondary sexual characteristics of the female. As soon as estrogen is produced, the uterus begins to prepare itself for receiving and nourishing a fetus, should pregnancy occur.

After the ovary has released the ripe egg, the remains of the follicle (now known as corpus luteum) produces a second important hormone, progesterone. The presence of progesterone in the bloodstream prepares the endometrium of the uterus for the implantation of a fertilized egg should the egg cell and a sperm unite. During pregnancy progesterone causes the mammary glands to enlarge and become secretory.

Practice Questions

Fill in the blanks with the correct answer.

1. One of the main functions of the ovaries is to produce ___ cells.

2. The _____ is the part of the ovarian structure where the egg cell grows.

3. _____ is the process whereby the egg, or ovum, is released by the ovary.

4. A second important function of the ovaries is to produce two female sex hormones named _____ and _____.

5. _____ is the hormone which contributes to the growth and maintenance of the uterus, Fallopian tubes, and vagina.

6. _____ is the hormone which prepares the uterus for implantation of a fertilized egg should the egg cell and sperm unite.

To the Learner: Turn the page to check your answers.

Answers to Practice Questions

1. One of the main functions of the ovaries is to produce egg cells.

2. The follicle is the part of the ovarian structure where the egg cell grows.

3. Ovulation is the process whereby the egg, or ovum, is released by the ovary.

4. A second important function of the ovaries is to produce two female sex hormones named progesterone and estrogen.

5. Estrogen is the hormone which induces ovulation and contributes to the growth and maintenance of the uterus, Fallopian tubes, vagina, and ducts of the mammary glands.

6. Progesterone is the hormone which prepares the uterus for implantation of a fertilized egg should the egg cell and sperm unite. Progesterone also causes the mammary glands to enlarge and become secretory.

To the Learner: If you missed any of the answers to the questions, go back to the information section and study it again. When all of your answers are correct, go to section 4 on the next page.

4. Reproductive Functions of the Fallopian Tubes

The Fallopian tubes (also called oviducts) are muscular channels about 10 cm long and 80 mm wide. They extend, one on each side, from the cornua of the uterus. The tubes turn first out, then back down and in, thus partly encircling the ovaries.

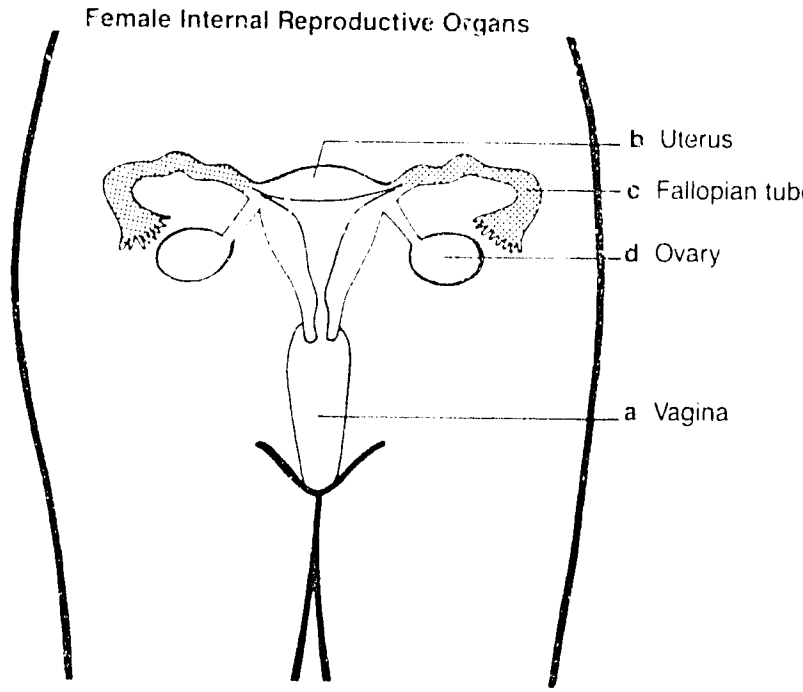

The Fallopian tubes have two functions:

(1) to bring sperm to the ovum
(2) to transport the ova to the uterus

Ova do not have the ability to move. Therefore they must be transported through the Fallopian tubes. There are two ways this is accomplished. Many of the cells lining the ends of the Fallopian tubes near the ovary have cilia, little hair-like processes that beat towards the uterus, creating a current in the tubal fluid. Then successive waves of involuntary contractions called peristalsis propel the egg along the mid-portion of the Fallopian tube, where fertilization takes place, and on to the uterus.

It takes about five days for the ovum to travel from the ovary to the uterus. The fertilized ovum is most often implanted in the endometrium, or lining of the uterine cavity.

Practice Questions

1. Name the two reproductive functions of the Fallopian tubes.

   a.
   b.

2. How is the egg propelled toward the uterus?

3. How long does it take the ovum to travel from the ovary to the uterus?

4. Where is the fertilized ovum implanted most often?

To the Learner: Turn the page to check your answers.

Answers to Practice Questions

1. The two reproductive functions of the Fallopian tubes are

   a. to bring sperm to the ovum
   b. to transport the ova to the uterus

2. The egg is propelled toward the uterus first by the motion of the cilia, and then by waves of involuntary contractions called peristalsis.

3. It takes about 5 days for the ovum to travel from the ovary to the uterus.

4. The fertilized egg is most often implanted in the endometrium, the lining of the uterine cavity.

To the Learner: If you missed any of the answers to the questions, go back to the information section and study it again. When all of your answers are correct, go to section 5 on the next page.

5. Reproductive Functions of the Uterus

Parts of the Uterus

The uterus (womb) is a pear-shaped organ in the pelvic girdle. It is situated between the bladder and the colon. It is a muscular organ.

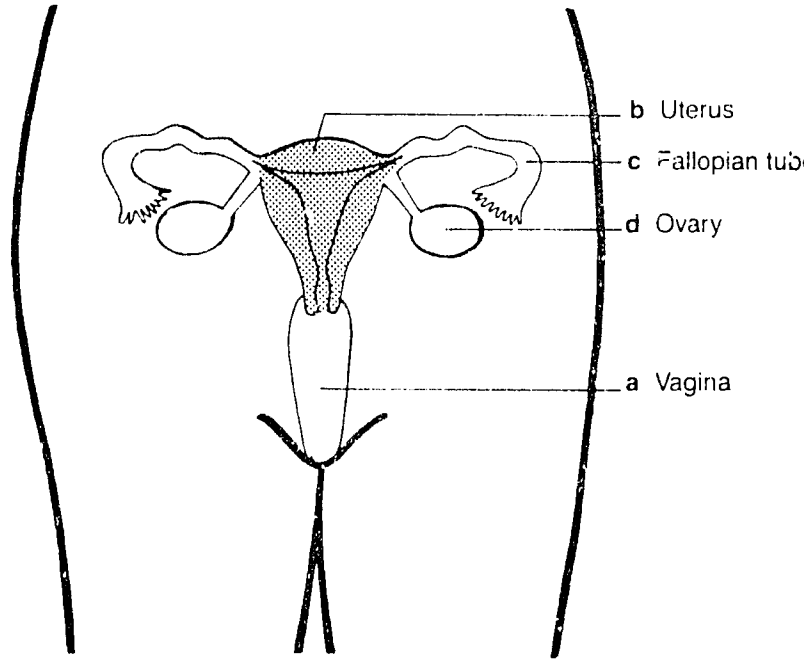

Female Internal Reproductive Organs

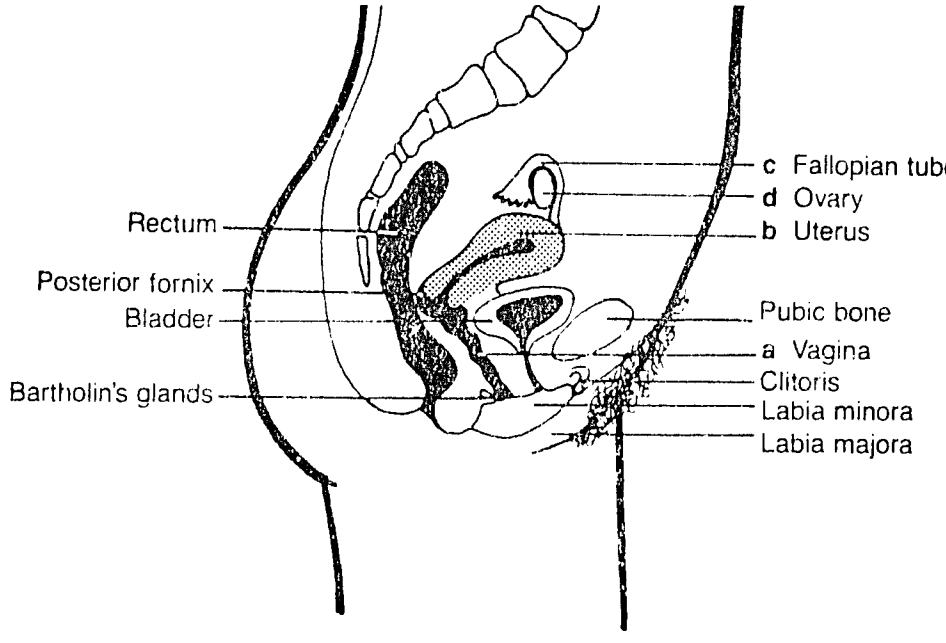

Sectioned View of Uterus

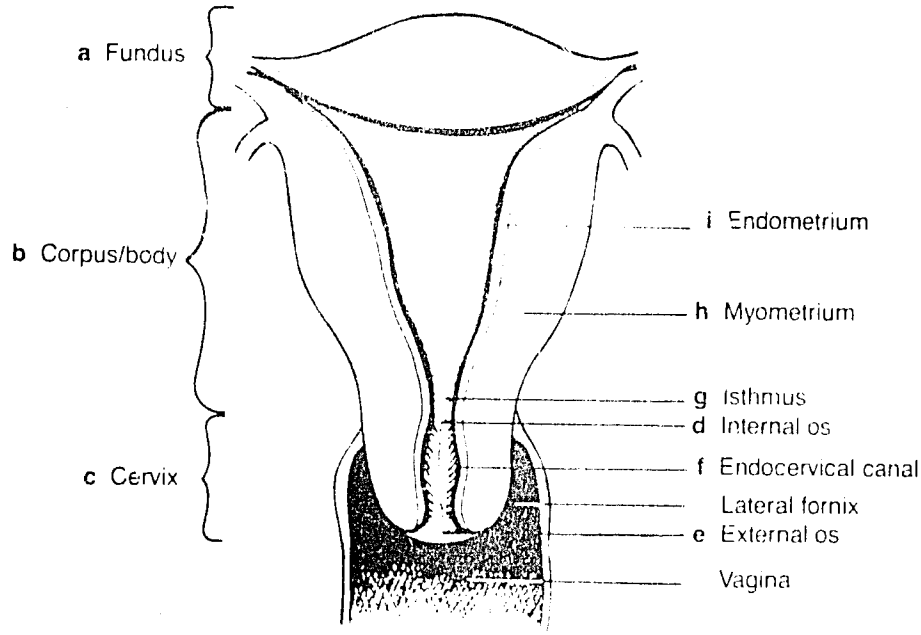

The uterus has four parts:

(a) fundus is the broad upper part of the uterus.

(b) corpus (or body) is the main part of the uterus between the fundus and the cervix.

(c) cervix is the lower narrow part of the uterus which projects into the vagina. It is firm and muscular like the rest of the uterus. It has two openings:

(d) the internal os which opens into the uterus.

(e) the external os which opens into the vagina. The os varies in shape and size depending on whether a woman has had children, but remains very small.

(f) the endocervical canal is the area between the internal and external os. The endocervical canal is lined with tall columnar epithelial cells. The part of the cervix that lies in the vagina is lined with flat squamous cells.

(g) isthmus is a small area between the cervix and the corpus.

The wall of the uterus, a layer of muscle, is called the (h) myometrium. Inside is a potential hollow called the uterine cavity. The lining of the cavity is made of tissue and blood vessels. This lining is

called the (i) endometrium. Surrounding the main part of the uterus, the corpus, is a membrane layer called the peritoneum, which extends from the uterus to the pelvic walls. This area is part of the peritoneal cavity.

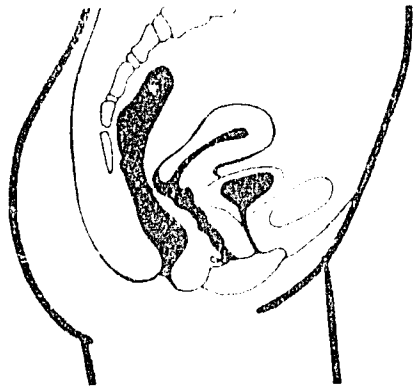

Anteversion

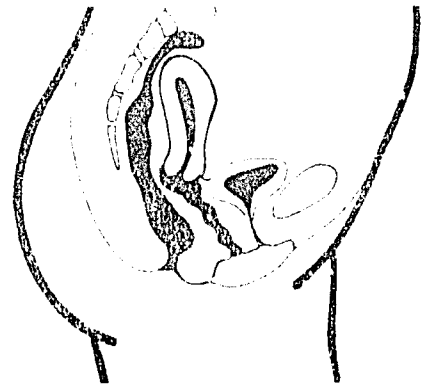

Retroversion

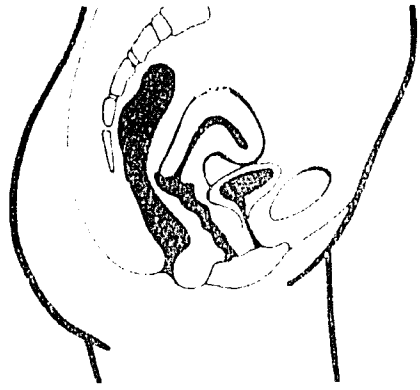

Anteflexion

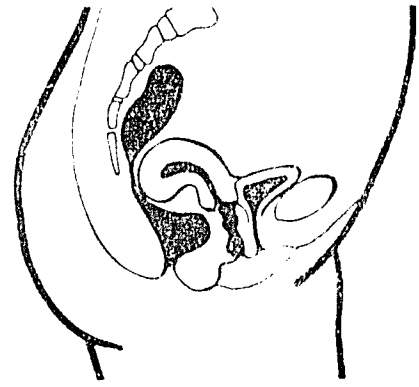

Retroflexion

Varying Positions of the Uterus

The position, contour and size of the uterus has many normal variations. It is important to know the normal variations of the uterus. Two words used to describe the position of the uterus are flexion and version.

Flexion refers to the direction which the naturally curved uterus follows. If it is curved toward the bladder, the uterus is described as anteflexed. If the uterus curves toward the colon, it is called retroflexed.

Version refers to the position of the uterus in relation to the length of the vaginal canal. If the uterus is directed towards the pubis from the vaginal canal, it is called anteverted. If it is directed toward the sacrum, it is called retroverted.

Changes in the Uterus During Pregnancy

The empty uterus is flat with the front and back walls touching each other. The walls of the uterus separate only when there is something in the cavity. The uterus of a woman who has never been pregnant is about 7 cm long. It is about 6 cm wide at the fundus.

During the first week of pregrancy the fertilized ovum, known during this time as a zygote, erodes into the endometrium which provides its early nourishment. As the zygote grows larger, its need for nourishment grows. A separate organ, the placenta, develops, connecting the embryo (2nd - 8th weeks) to the blood vessels within the uterine wall. The placenta serves as a source of nourishment for the developing embryo and fetus, allowing for an exchange of nutrients, as well as waste removal between fetus and mother.*

Uterine size increases with pregnancy. In the first few weeks, the only apparent change is in the shape of the uterus. The front and back walls begin to separate and the corpus becomes round. The cervix becomes soft. This makes the corpus much more flexible than the corpus of a nonpregnant uterus.

As the cervix becomes softer, the rounded corpus seems very flexible and almost separate from the cervix. This early sign of pregnancy can be felt during a bi-manual pelvic examination.

As pregnancy advances, the uterus stretches and gets bigger. The fundus rises from the pelvis to the abdomen. At about 10 weeks since conception (the same as 12 weeks LMP - the time of gestation measured from the first day of the Last Menstrual Period) the uterus can be felt in the abdomen just above the pubic bone. Relative uterine sizes and embryonic and early fetal length are shown on the following table:

	Weeks since Conception	Days LMP	Gestational Age (weeks)	Depth of Uterine Cavity	Length of Embryo/Fetus
Embryo	2	28	4	7 cm	<1 mm
	3	35	5	7 cm	1 mm
	4	42	6	7-8 cm	4-5 mm
	5	49	7	8 cm	1 cm
	6	56	8	9 cm	2.2-2.4 cm
	7	63	9	10 cm	3 cm
	8	70	10	11 cm	4 cm
Fetus	9	77	11	12 cm	5 cm
	10	84	12	13 cm	6-7 cm

After the twelfth week of gestation the fundus rises above the pubis (the upper limit of the pelvic bone) by 2.5 cm (or a woman's two fingers' breadth) every two weeks.

*For a more complete description of implantation see section 8, page 43.

Practice Questions

1. Identify the following parts of the uterus by putting the name of the part next to the letter marking the part in the diagram:

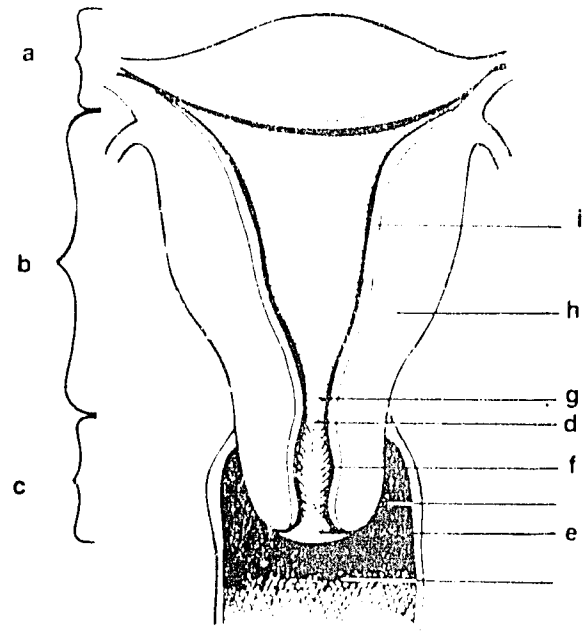

fundus, isthmus, cervix, corpus (body), internal and external os, endometrium, myometrium, endocervical canal

2. Following are diagrams of four common, varying positions of the uterus. Identify the name of each position using the following terms: anteflexed, retroflexed, anteverted, or retroverted.

a. _____ b. _____

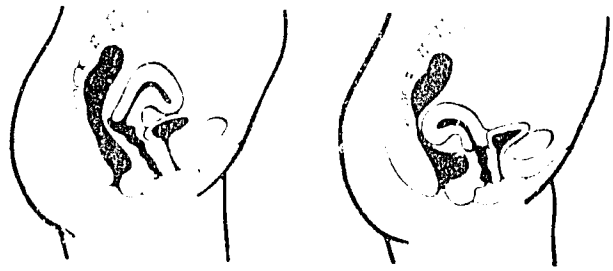

c. _____ d. _____

3. Describe at least two changes that occur in the uterus that may be early signs of pregnancy.

4. What is the function of the uterus in reproduction?

To the Learner: Turn the page to check your answers.

Answers to Practice Questions

1. Parts of the uterus:

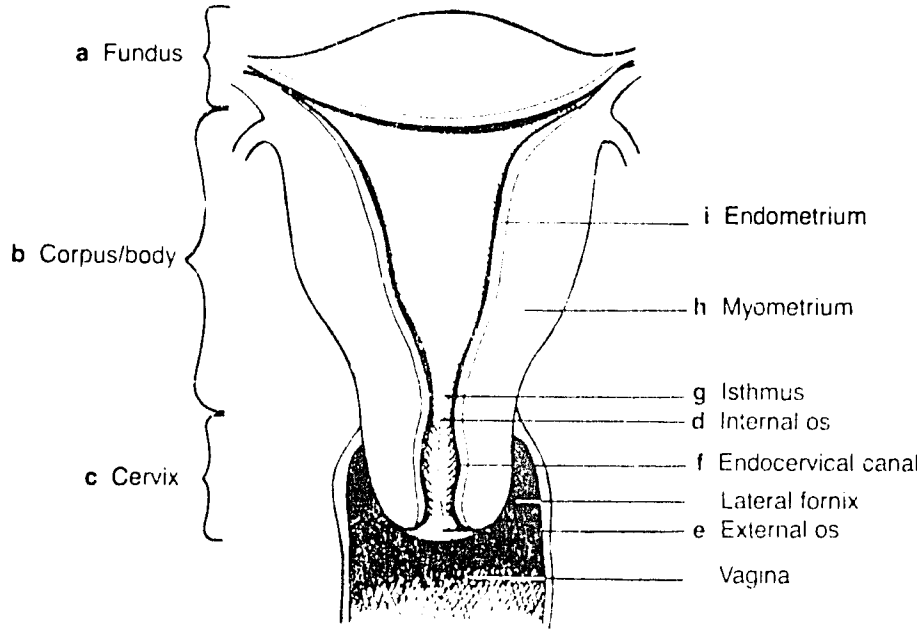

2. Varying positions of the uterus:

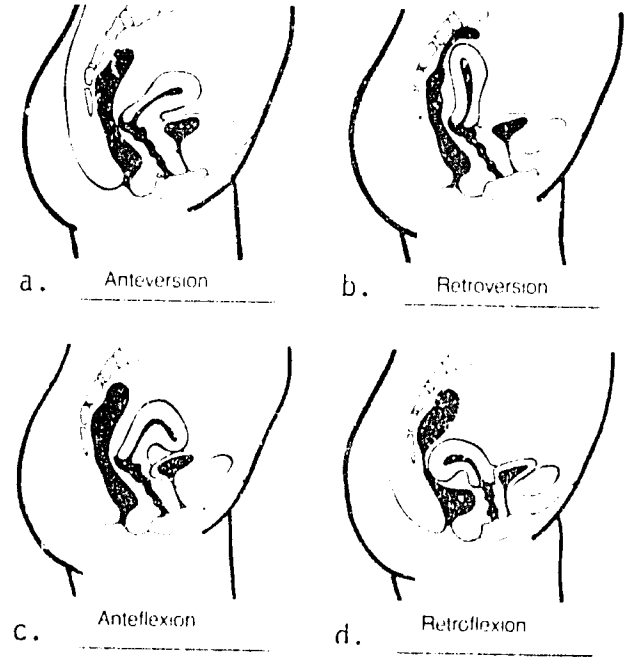

3. Changes in the uterus that can be early signs of pregnancy are any of the following:

   Uterine size increases.

   Corpus becomes round and flexible.

   Cervix becomes soft.

4. The uterus accommodates, nourishes and protects the growing embryo and fetus. The endometrium nourishes the zygote in the first week after conception. Then uterine blood vessels come in contact with placental blood vessels permitting the exchange of nutrients, as well as waste removal between fetus and mother.

To the Learner: If you missed any of the answers to the questions, go back to the information section and study it again. When all of your answers are correct, go to section 6 on the next page.

6. Reproductive Functions of the Vagina

The vagina is a muscular canal about 10 cm in length that leads from the cervix to the outside of the body. The outside opening of the vagina is known as the vaginal introitus. The gutter-like area surrounding the protrusion of the cervix is divided into four regions known as the anterior fornix, posterior fornix, and the right and left lateral fornices.

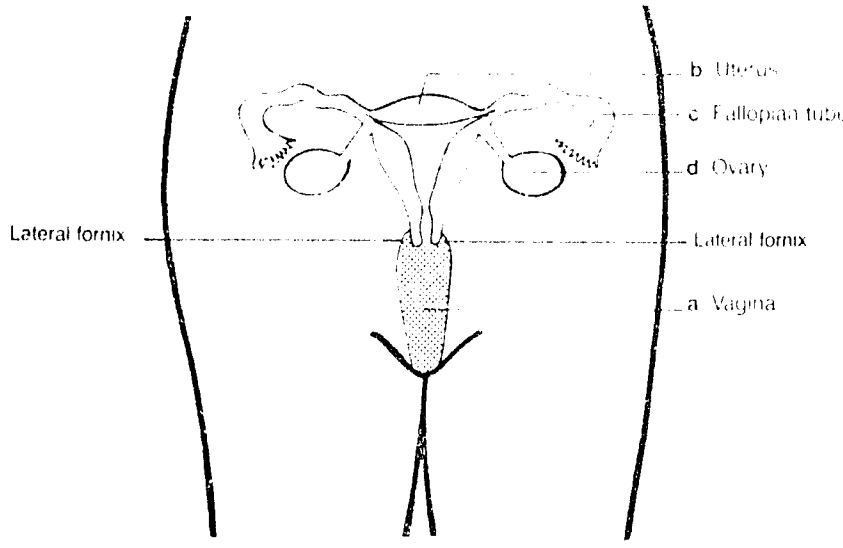

Female Internal Reproductive Organs

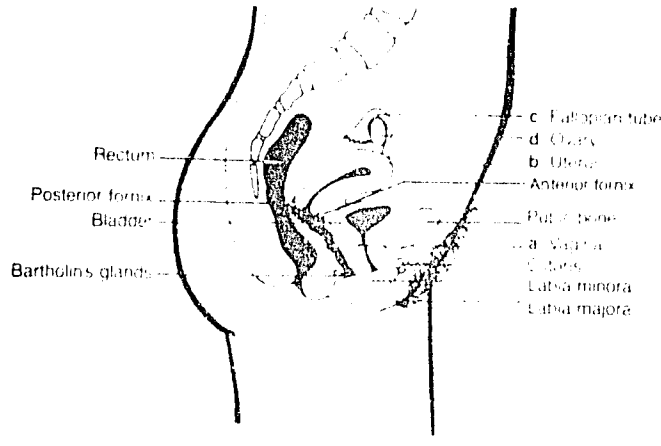

The vaginal canal has two important reproductive functions: First, it serves as the female organ in sexual intercourse. The male sperm are deposited here to begin their journey toward the female's egg, from the vagina through the cervix and the uterus to the Fallopian tubes. Second, the vagina serves as the birth canal and has the capacity to expand significantly to allow the baby to pass from the uterus, through the cervix, to the outside world. The layers of muscles in the vaginal canal have an extraordinary capacity to expand under the pressures caused by childbirth.

Practice Questions

1. List the two reproductive functions of the vagina.

2. Using this diagram to help you, describe the path the male's sperm takes in the journey toward the female's egg.

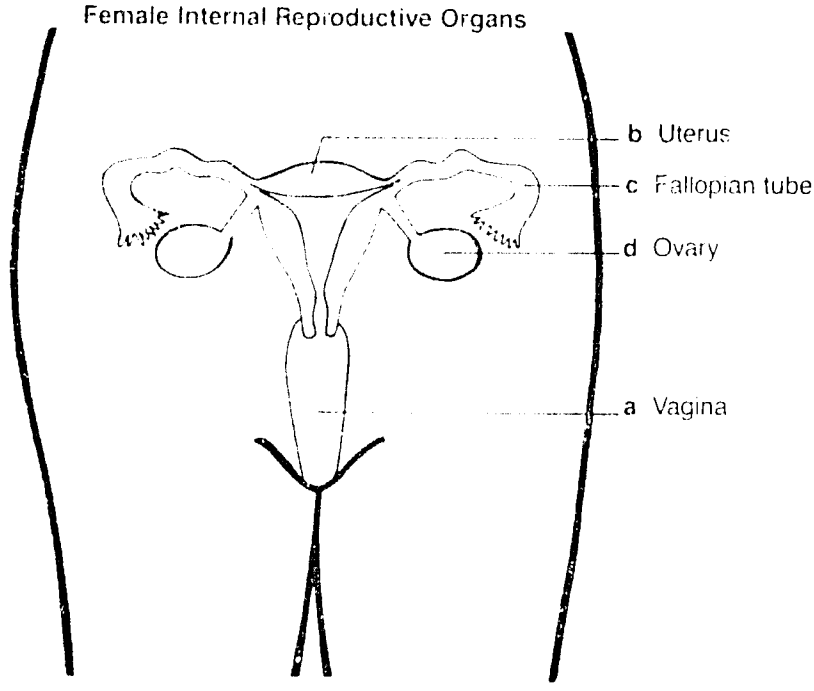

To the Learner: Turn the page to check your answers.

Answers to Practice Questions

1. The two reproductive functions of the vagina are

   a. to serve as the female organ in sexual intercourse, the place where the male's sperm are deposited.

   b. to serve as the birth canal to allow the baby to pass from the uterus to the outside world.

2. Sperm are deposited in the vagina. From there they go through the cervix and the uterus to the Fallopian tubes where fertilization takes place.

To the Learner: If you missed any of the answers to the questions, go back to the information section and study it again. When all of your answers are correct, go to section 7 on the next page.

7. Menstruation

Definition

Around every 28th day, from about the age of 12 to about the age of 47, a woman has a discharge of blood and mucus from the vagina. This is menstruation, or "the period" - the outward sign of the routine cycle of egg production and hormone change in a woman's body. The discharge lasts from 2 to 8 days (4 to 6 is most usual) and may be symptomless, or may be preceded or accompanied by various unpleasant symptoms such as headaches and nausea.

How the Process Works

If the egg is not fertilized by a sperm, it begins to degenerate 24 to 48 hours after leaving the ovary, and eventually passes unnoticed out of the body in the normal flow of fluid from the vagina. But meanwhile the uterus has been preparing to receive a fertilized egg. Hormones have caused the lining of the uterus to thicken, and to excrete a fluid so that the fertilized egg could be nourished while implanting itself. When no fertilization occurs, further hormone stimulation causes the thickened lining to crumble, and to be discharged along with a little blood through the vagina. This process is called menstruation.

This process occurs monthly in a sequence of events called the menstrual cycle. Normally the cycle takes 28 days to complete. Following is a description of what events take place at each stage of the normal menstrual cycle:

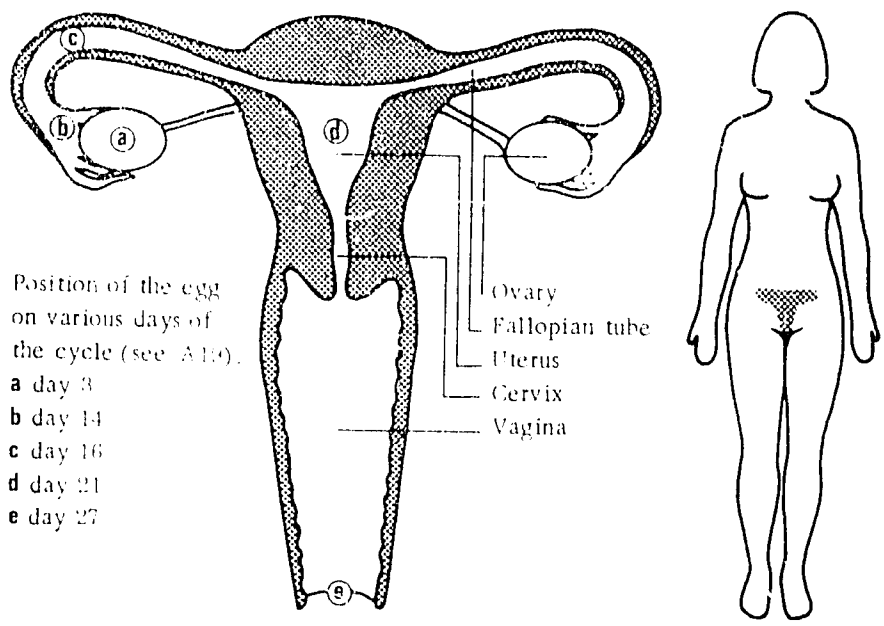

Journey of the Egg by Day of Menstrual Cycle

Normal Menstrual Cycle

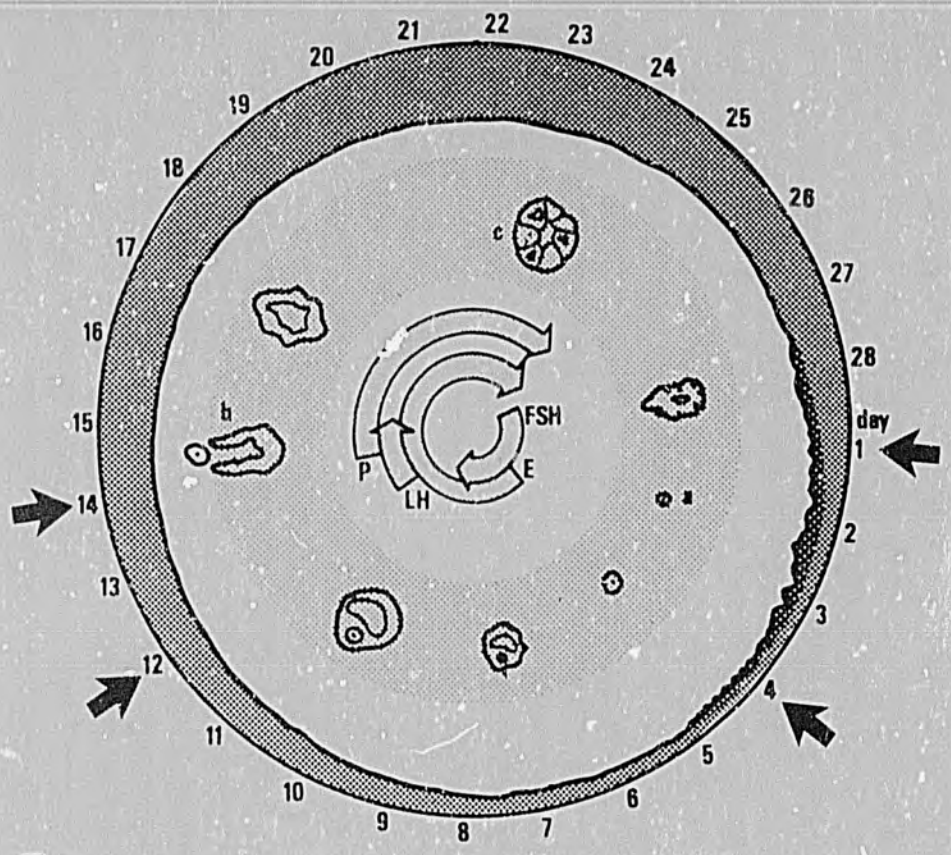

Hormones		FSH	Follicle stimulating hormone
Ovary		E	Estrogen
Uterine wall		LH	Luteinizing hormone
Menstuation		P	Progesterone

Day 1 onward: Pituitary is already producing the follicle-stimulating hormone (FSH) - a new egg begins to mature in one of the follicles.

Day 4 onward: The follicle produces estrogen. As this builds up, it stimulates growth of uterine wall and breasts, halts FSH production, and stimulates the pituitary to release luteinizing hormone (LH).

Day 12 onward: The luteinizing hormone causes the follicle to burst, releasing the egg, and makes the follicle develop into a "corpus luteum," producing progesterone as well as estrogen.

Day 14 onward: Progesterone makes the endometrium prepare for a fertilized egg and halts production of luteinizing hormone. Without this production, the corpus luteum degenerates and estrogen and progesterone levels fall; eventually, the uterine lining breaks up - menstruation (day 28). The estrogen no longer inhibits the follicle-stimulating hormone, and the cycle begins again.

Problems of Menstruation

There are five main types of problems which a woman may experience with her menstrual period. They are premenstrual discomfort, irregularity, absence of periods, heavy periods, and breakthrough bleeding.

1. Premenstrual Discomfort:

Symptoms (most noticeable in the 7 days before the start of the period) can include headaches, backache, nausea, breast tenderness, tension and depression.

2. Irregularity:

Menstruation may be irregular. Some adult women also find, however, that the duration of their menstrual cycle varies from month to month. Regular cycles can vary from between 21 to 35 days.

3. Absence of Periods (Amenorrhea):

There are two types of amenorrhea - primary and secondary. If a girl reaches the age of 18 without experiencing menstruation she is said to be suffering from primary amenorrhea. This rare condition may be the result of an endocrine dysfunction and must be investigated by a specialist.

Secondary amenorrhea is the term used to describe the absence of periods in a woman who has already begun to menstruate. This may be quite normal: menstruation does not occur in pregnant women, and sometimes does not recommence until some weeks after the birth, especially if the mother is breastfeeding her child or when using injectable contraceptives. Secondary amenorrhea, however, can also be caused by emotional stress, strenuous exercise, and also by endocrine dysfunction, illness, drug-taking, traveling, or poor general health.

4. Heavy Bleeding:

During a menstrual period, a woman usually sheds between 2 and 4 tablespoons of blood. Some women, however, discharge considerably more.

If menstrual bleeding is heavy or prolonged (and this frequently happens to women fitted with IUD's), iron-deficiency anemia can result. This can often be remedied by an iron-rich diet or a course of medicinal iron.

Heavy bleeding (and bleeding between periods) can sometimes be symptomatic of problems such as hormone dysfunction, fibroid tumors, or cancer of the uterus. Also, occasionally heavy periods can be caused by psychological factors.

In all cases of excessive bleeding, a specialist should be consulted.

5. Breakthrough Bleeding:

Bleeding between periods is not uncommon for women taking oral contraceptives or using injectable contraceptives. If the bleeding is light, no course of action is necessary. If heavy, a different contraceptive method should be considered.

Practice Questions

1. What is menstruation?

2. Briefly describe the process of menstruation within the normal menstrual cycle.

3. List 5 problems of menstruation.

4. If a girl reaches the age of 18 without experiencing menstruation she is said to be suffering from _____.

   What treatment would you recommend for this girl?

5. Which of the following can be causes of secondary amenorrhea?

   a. pregnancy

   b. emotional stress

   c. poor general health

   d. using injectable contraceptives

   e. illness

6. What treatment might you recommend for a woman with heavy or prolonged bleeding? Who must you consult before treatment?

To the Learner: Turn the page to check your answers.

Answers to Practice Questions

1. Menstruation is the discharge of blood and mucus from the vagina which occurs in a regular cycle.

2. A brief description of the menstrual process:

   If no fertilization occurs, the egg degenerates and eventually passes out of the body in the normal flow of fluid. But hormones have caused the lining of the uterus to thicken and to secrete fluid for nourishing a possible fertilized egg. When no fertilization occurs, further hormone stimulation causes the thickened wall to break down. The lining is discharged with a little blood through the vagina.

3. The 5 problems of menstruation (in any order):

   (1) premenstrual discomfort
   (2) irregularity
   (3) amenorrhea (absence of periods)
   (4) heavy periods
   (5) breakthrough bleeding

4. A girl reaching the age of 18 without experiencing menstruation is said to be suffering from primary amenorrhea.

   She should be referred to a specialist.

5. All of the following can be causes of secondary amenorrhea:

   a. pregnancy
   b. emotional stress
   c. poor general health
   d. using injectable contraceptives
   e. illness

6. A woman with heavy or prolonged menstrual bleeding can be treated with an iron-rich diet or a course of medicinal iron.

   In all cases of heavy bleeding, a specialist should be consulted.

To the Learner: If you missed any of the answers to the questions, go back to the information section and study it again. When all of your answers are correct, go on to section 8 on the next page.

Fertilization occurs in the Fallopian tube within a day or two of ovulation. There may be millions of sperm deposited in the vagina, but generally only a few hundred reach the Fallopian tube.

The diagram below represents the process of fertilization and development. The path of the ovum, from fertilization to implantation is traced, with an enlarged cross-section of the various stages of development.

More than one sperm may reach the ovum's wall. After one sperm breaks through (1), the ovum wall changes, preventing the entry of other sperm.

Soon after fertilization the ovum begins to divide, first into two (2), then into four, and so on. The first division takes about 24 hours. Subsequent divisions take less time. The small bundle of cells (up to 16) is now called a morula (3). The zygote at this point will normally be about to enter the uterus.

As the cell division continues, the morula transforms and becomes known as a blastocyst. The outer cells flatten into a cellular wall, the trophoblast, and the remaining cluster of cells, the inner cell mass, moves to one side (4). The amniotic sac, and fetus develop from these cells.

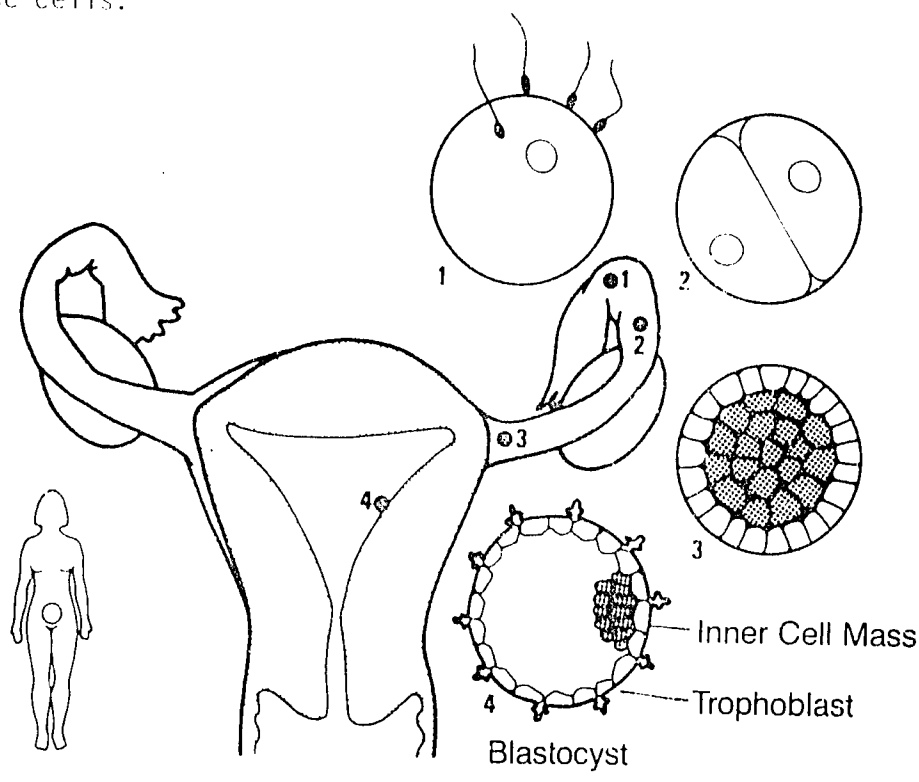

8. Fertilization and Implantation

For fertilization to occur, a male's sperm must unite with a female's egg. This section will describe the process of fertilization and development during the first four weeks of life.

1. Fertilization

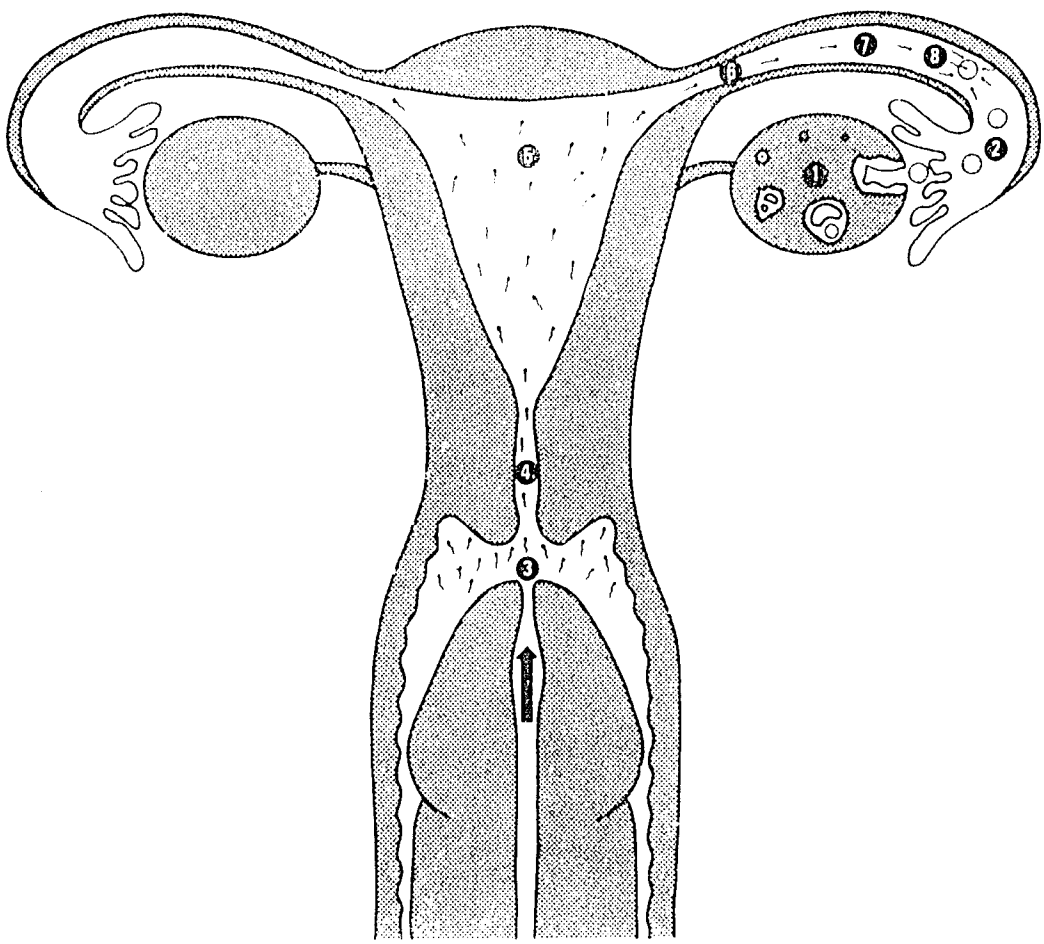

The female's ovary releases the egg which enters the Fallopian tube (1-2).

The male sperm is deposited in the vagina (3). It then travels through the cervix and uterus to the Fallopian tubes where fertilization can occur (4-8).

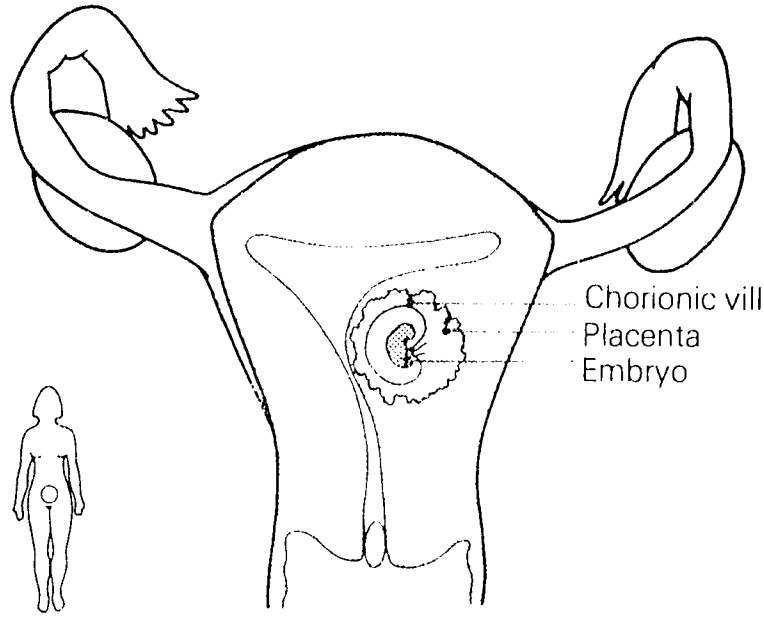

2. Implantation

By about the 12th day, small projections, the chorionic villi, will have formed on the trophoblast. These burrow into the uterine wall to eventually form the placenta.

The embryo undergoes continual change within the uterus. This change, called cell differentiation, takes place with each cell division. Thus this is a vital stage of development and the embryo is easily damaged. This is one of the reasons a pregnant woman should avoid all drugs. It is also the reason why early detection of pregnancy is important. The stunted growth of an organ of the body can occur from the damage or loss of one cell alone.

Implantation in the uterus establishes a basis of embryonic nutrition. After about 18 days, the nervous system begins to form and it continues to develop until a few weeks after birth.

By the end of the first month, the embryo is about 4 mm long, about the size of a pea, with millions of cells intricately organized to carry out specific functions. A primitive heart is now formed. The embryo is already 10,000 times bigger than the original ovum.

Ectopic Pregnancy

Ectopic pregnancy is an extrauterine pregnancy occuring in about one out of every two hundred pregnancies. If the fertilized egg does not reach the uterus within seven days, the tiny armlike protrusions (chorionic villi) which will have formed by then will burrow into the wall of the Fallopian tube. The latter will become sorely distended as it can only stretch to a limited extent. The chorionic villi will continue to burrow into the wall in search of nourishment - which is obviously restricted. Eventually they will break through the muscular wall or into an artery causing bleeding, pain, and the loss of the embryo. (Emergency surgery is always necessary.)

Ectopic pregnancies are not uncommon, and since the same hormones are secreted as in a normal pregnancy, causing the naturally anticipated reactions, they are not always detected until discomfort is felt. One in every ten women who has had an ectopic pregnancy is liable to have another. They are often due to prior inflammation of the Fallopian tube.

Ectopic Pregnancy

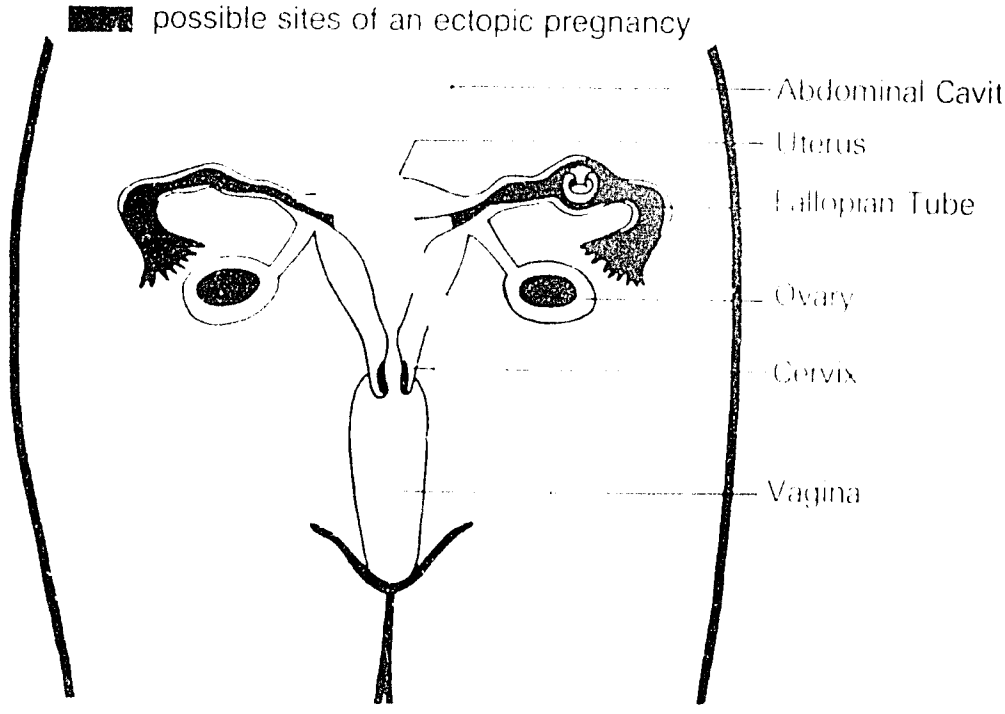

The diagram shows an ectopic pregnancy and possible areas where one might develop. However, at least 90% of extrauterine pregnancies occur in the Fallopian tubes. Bleeding and pain in early pregnancy (6th - 12th week) may be caused by an ectopic pregnancy. In this condition the fertilized egg has failed to reach the uterus and has implanted within a Fallopian tube, or more rarely, within the abdominal cavity.

Practice Questions

1. Briefly describe the process of fertilization by tracing the journey of the sperm and the journey of the egg.

2. What is implantation and where does it normally occur?

3. What is the name of the small projections on the cellular wall of the zygote that burrow into the uterus wall?

4. The continual change that the embryo undergoes with each cell division is called _____

5. Under what conditions does an ectopic pregnancy occur?

6. What is the treatment for ectopic pregnancy?

To the Learner: Turn the page to check your answers.

Answers to Practice Questions

1. The male sperm is deposited into the vagina. It then travels through the cervix and uterus to the Fallopian tubes where fertilization can occur. The female ovaries release the ripened egg cell, or ovum, during ovulation. Fertilization occurs in the Fallopian tube within a day or two of ovulation when one of the many sperm breaks through the ovum wall. The ovum wall permits entry of only one sperm. The fertilized egg then moves to the uterus.

2. Implantation is the process by which the zygote becomes attached, usually to the wall of the uterus. This process allows the embryo to receive nourishment and grow.

3. Chorionic villi are the small projections on the cellular wall (trophoblast) of the blastocyst that burrow into the uterine wall.

4. The continual change that the embryo undergoes with each cell division is called cell differentiation.

5. An ectopic pregnancy occurs when the fertilized egg has failed to reach the uterus and has implanted outside the uterus, most commonly within a Fallopian tube.

6. Surgery for the removal of the embryo is always the treatment for ectopic pregnancy.

To the Learner: If you missed any of the answers to the questions, go back to the information section and study it again. When all of your answers are correct, go on to the Post-test on the next page.

Post-test

To the Learner: This test will tell you how much you have learned from this self-instructional module. After taking the test, check your answers on the page following the test. Be sure to use a separate sheet of paper for recording your answers.

1. Below is a diagram of the female external sex organs. Using the list of organs on the right, label the 11 parts.

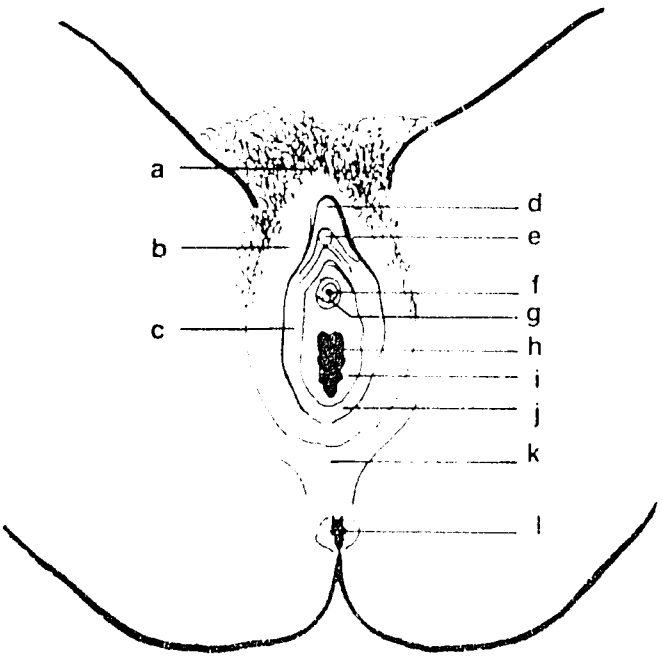

Female External Sex Organs

clitoris

hymen

vaginal opening

labia majora

labia minora

perineum

anus

mons veneris

Bartholin's glands

urethra

hood

Skene's glands

2. Below is a diagram of the female reproductive system. Label the 4 major organs.

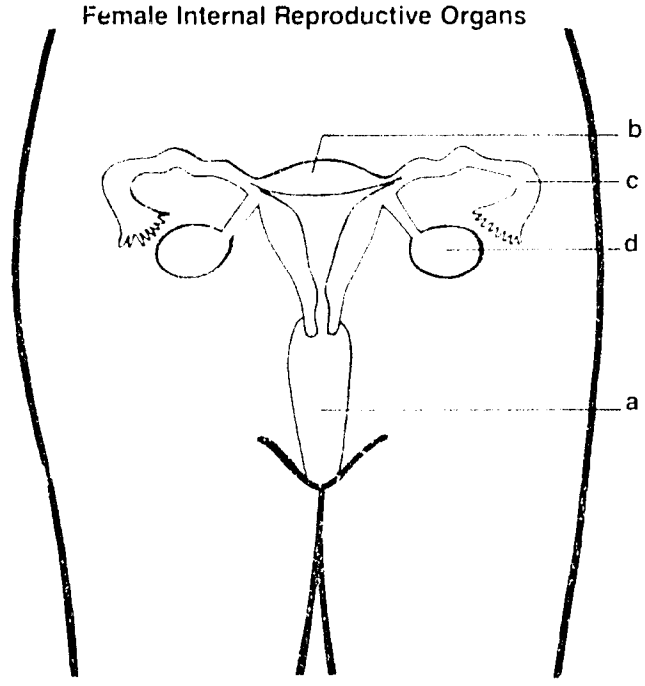

3. Describe the functions of the 4 organs of the female reproductive system.

4. Below are 4 diagrams of the uterus in varying positions. Identify the positions by labeling each diagram with one of the following descriptions:

anteflexed, retroflexed, anteverted, retroverted

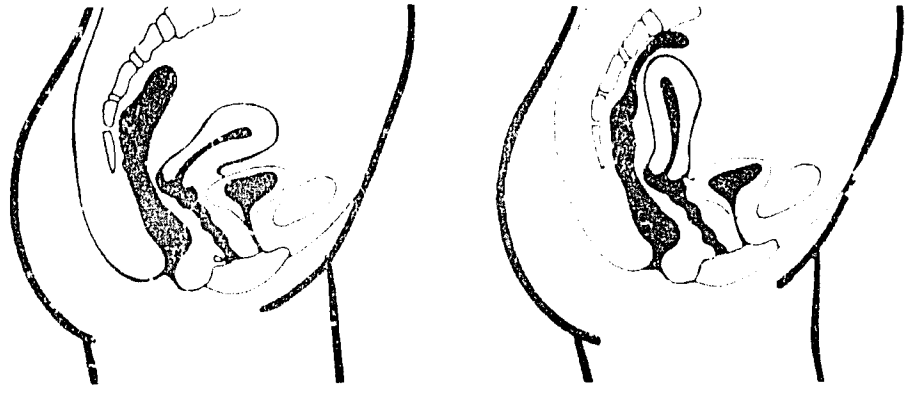

a. _____ b. _____

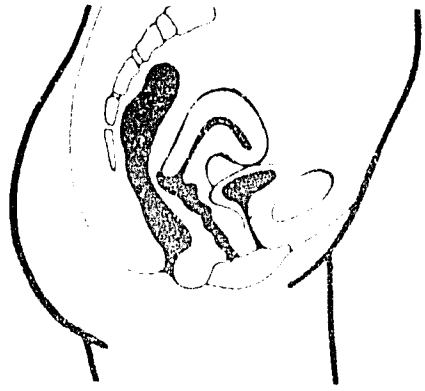

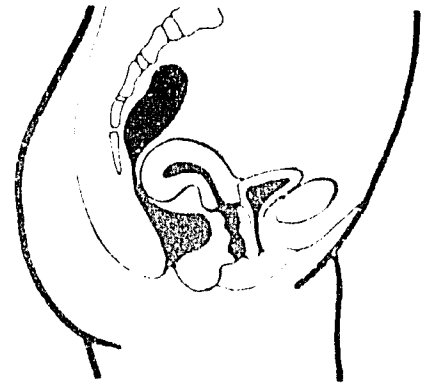

c. _____ d. _____

5. Describe the process of menstruation within the normal menstrual cycle.

6. List the 5 problems a woman might have with menstruation.

7. What treatments or referrals would you recommend for (a) primary amenorrhea and (b) heavy or prolonged bleeding? Describe their symptoms.

8. Describe the process of fertilization and implantation.

9. Explain the conditions under which an ectopic pregnancy occurs. What is the treatment?

To the Learner: Turn the page to check your answers.

Answers to Test

1.

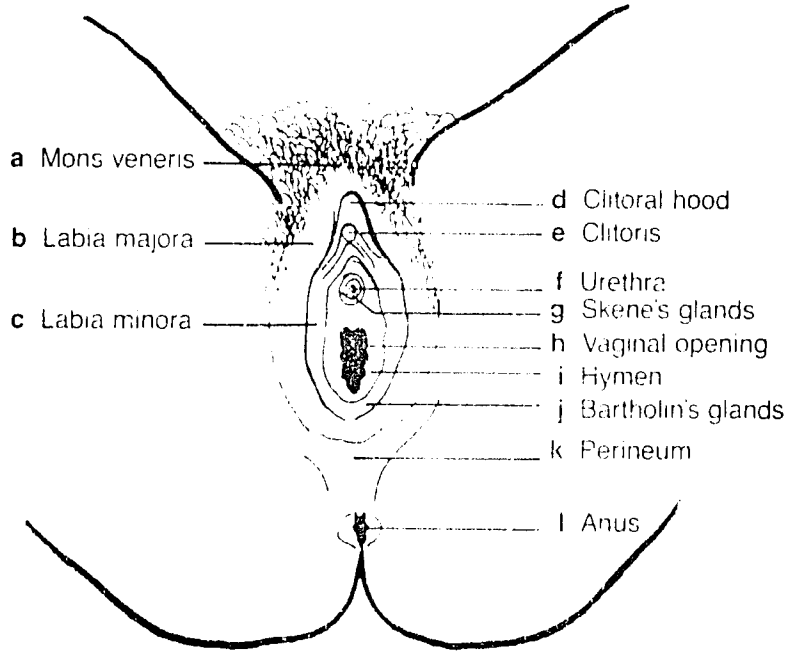

Female External Sex Organs

2.

Female Internal Reproductive Organs

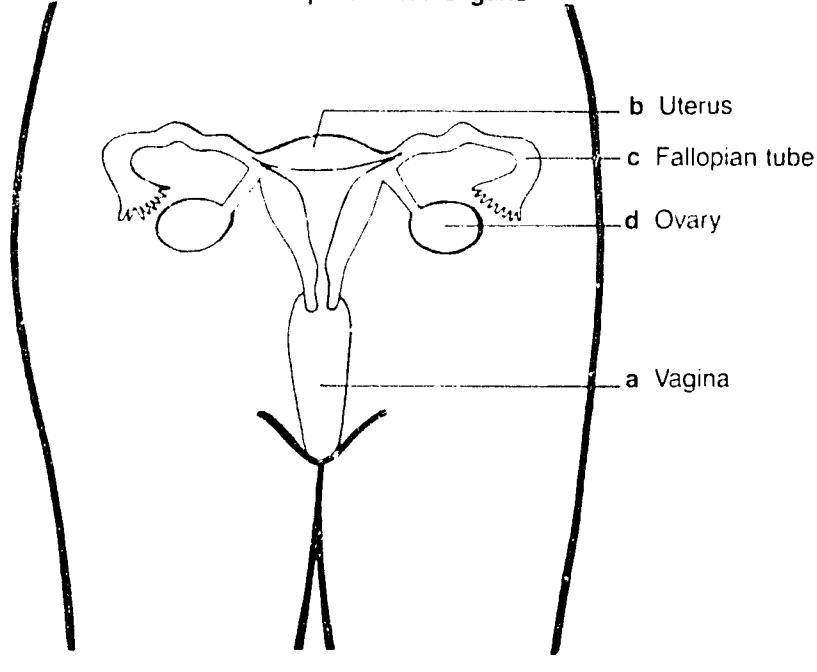

3. Functions of the four female reproductive organs:

   (a) Ovaries:

      (1) produce egg cells
      (2) produce female hormones - estrogen and progesterone

   (b) Fallopian tubes:

      (1) bring sperm to ovum
      (2) transport ovum to uterus

   (c) Uterus:

      contains and nourishes the embryo

   (d) Vagina:

      (1) serves as the female organ of sexual intercourse where the male's sperm are deposited
      (2) serves as the birth canal

4. 4 varying positions of the uterus:

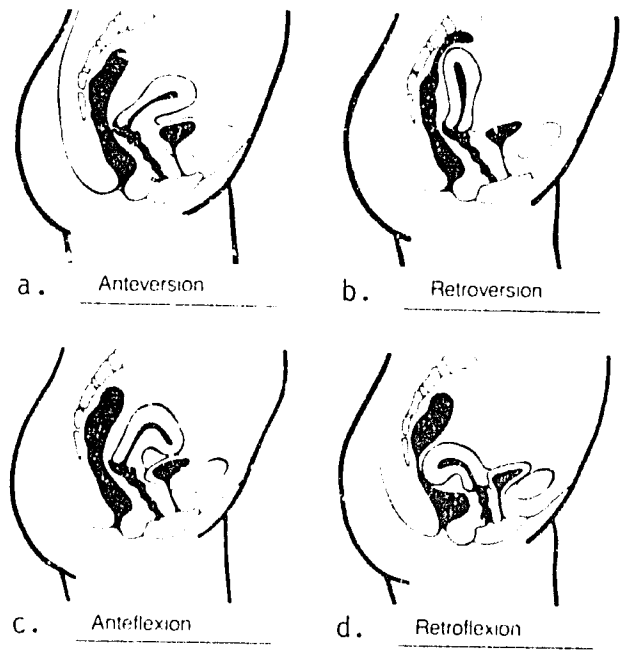

5. The menstrual process:

   (a) If no fertilization occurs, the egg degenerates and eventually passes out of the body in the normal flow of fluid.

   (b) But hormones have caused the lining of the uterus to thicken

and secrete fluid for nourishing a possible fertilized egg.

(c) When no fertilization occurs, further hormone stimulation causes the thickened uterine lining to break down.

(d) The lining is then discharged with a little blood through the vagina.

6. 5 problems of menstruation:

(1) premenstrual discomfort
(2) irregularity
(3) amenorrhea (absence of periods)
(4) heavy or prolonged bleeding
(5) breakthrough bleeding

7. (a) Primary amenorrhea

Symptoms: A girl reaches the age of 18 without experiencing menstruation.

Treatment: Refer to a specialist.

(b) Heavy or prolonged bleeding

Symptoms: A woman discharges a considerable amount of blood during her period.

Treatment: Depending on the cause, the woman may be treated with an iron-rich diet or a course of medicinal iron. A specialist should be consulted.

8. The process of fertilization and implantation:

The male's sperm is deposited in the vagina. It then travels through the cervix and uterus to the Fallopian tubes where fertilization can occur. The female ovaries released the ripened egg, or ovum, during ovulation. Fertilization occurs in the Fallopian tube within one day or two of ovulation when one of the many sperm breaks through the ovum wall. The ovum wall prevents the entry of other sperm. After fertilization the ovum begins to divide. It moves down the Fallopian tube into the uterus. Chorionic villi have formed on the cell wall of the blastocyst and they burrow into the uterine wall seeking nourishment for the embryo to develop and grow.

9. An ectopic pregnancy occurs when the fertilized egg has failed to reach the uterus and has implanted outside of the uterus, most commonly within a Fallopian tube. The treatment is always the surgical removal of the embryo.