PN-AAY-567

Center for Sickle Cell Disease
and
Department of Zoology

HOWARD UNIVERSITY
Washington, D.C.

FINAL REPORT:

Model for the In-Vitro Generation of Human Epidermal Autografts for Potential Use in Treatment of Sickle Cell Leg Ulcers

PARTS I and II

Submitted by:

Carl Alexander Reindorf, M.D., FRCP
Dorothy Walker-Jones, Ph.D.
Co-Principal Investigators

AID Grant No. DAN-5053-G-SS-5102-00 Project-P10/T No. 936-5053-5361544

Co-Investigators, U.S.A

Macy G. Hall, Jr., M.D., *Plastic Surgeon*
Ettienne A. Massac, Jr., M.D., *Plastic Surgeon*
KiMoon Bang, Ph.D., M.P.H., *Statistician*

HOWARD UNIVERSITY
Washington, D.C.

Co-Investigator, Nigeria

A. D. Adekile, M.D., Department of Pediatrics
S. F. Olowule, M.D., Department of Surgery
O. Lawal, M.D., Department of Surgery

UNIVERSITY OF IFE
Ile Ife, Nigeria

PART I

IN VITRO GENERATION OF DIFFERENTIATING EPIDERMAL CELLS FOR POTENTIAL USE AS AUTOGRAFTS IN RECURRENT ULCERATIVE LESIONS

Dorothy G. Walker-Jones, Carl A. Reindorf,
Adekunle D. Adekile, Etienne Massac, Jr., Macy G. Hall, Jr.
Gary L. Harmon, Anthony I. Nunez and Allyson Ambrose

Departments of Zoology and Surgery and The Sickle Cell Center, Howard University; Department of Pediatrics and Child Health, Faculty of Health Sciences, University of Ife, Ife-Ife, Nigeria.

INTRODUCTION

The successful use of in vitro-generated skin autografts in the treatment of burns in humans (O'Connor et al., 1981, Green and O'Connor, 1984) has advanced the potential for application in the treatment of the recurrent ulcerative lesions that occurs in some patients with sickle cell disease and other disorders. Conventional grafts on sickle cell leg ulcers tend to break down, requiring repeated grafting that may eventually result in the lack of suitable donor sites. Therefore, lab-grown autografts that can be generated from smaller skin specimens and cryopreserved for future use, should be beneficial to such patients, in large measure. Since 1940, when Cummer and LaRocco (2) first associated leg ulcers with sickle cell anemia, reports of the prevalence of leg ulcers (world-wide) have ranged up to 75% in adults and 12% in children.

Earlier studies on the application of lab-grown skin in surgically excised wounds utilized the system of feeder layers of lethally irradiated fibroblasts as a substratum for the serial cultivation of human keratinocytes (5). Later, Eisinger et al. (3) cultured human keratinocytes in the absence of feeder layers on plastic or a collagen substratum in culture medium at pH 5.6 - 5.8 at a seeding density of 2.5 X 10/5 cells/sq cm at 36<o>C in humidified 5% carbon dioxide. Under these conditions, epidermal cells grew to confluency in 15-20 days and formed multilayered sheets of differentiated cells that resembled full depth epidermis. Yannas et al. (10) seeded the youngest epidermal cells from experimental animals, first by centrifugation, into a biodegradable collagen-chondroitin- 6-sulfate membrane (Stage II skin) then immediately grafted the membrane with an outer plastic coat. The young epidermal cells migrated upward toward the plastic coat and within 10-12 days a new epidermis was formed and the plastic layer rejected spontaneously. The epidermis then matured over a period of several weeks. The collagen-chondroitin-6-sulfate membrane, called Stage I skin, covered with silicone to prevent infection and fluid loss, has also been used for dermis replacement in large surface burns in humans (4, 9).

The recipient's stromal cells migrate into it and produce a "neodermis." Then, epidermal cells from the recipient are transplanted onto the surface and a new epidermis forms. A Stage II skin (membrane seeded with epidermal cells before implantation to hasten healing) is being developed for use in humans by these investigators (4, 9). Alvarez and Biozes (1) have shown that artificial skin substitutes alone are not adequate for covering denuded skin, either by burns or ulceration, without cicatrization.

The primary aim of this study was the development of a culture procedure for the rapid generation of differentiating human epidermal cells and accessory melanocytes on collagen-proteoglycan biomatrices. The long-term goal is to generate epidermal autografts for recurrent ulcerative lesions in patients with sickle cell disease and other disorders. Dispase/trypsin dissociated innner epidermal cells from dermatome sections from patients undergoing general or plastic surgery were cultured on basement-derived Matrigel (Collaborative Research, Inc.) coated onto plastic coverslips or Type I collagen films/sponges (Hellitrex, Inc.). Growth parameters were established with media with and without serum (or low serum) with added growth and attachment factors. In the process, the growth of adult human epidermal cells on biological substrates also provided for the study of cellular mechanisms (polarity, stratification, desmosomal junctions and interdigitation and progressive changes keratin intermediate filaments) that promote the differentiation of epidermal cells under controlled conditions.

Studies are in progress to determine the degree of viability, attachment and differentiation of epidermal cells on the Matrigel and collagen matrices after cryopreservation with dimethylsulfoxide (DMSO) and deep-freezing in liquid nitrogen to determine the feasibility of establishing an epidermal autograft bank for sickle cell patients with recurrent ulcerative lesions. An important consideration will be the assessment of pigment patterns that would be clinically and cosmetically acceptable.

MATERIALS AND METHODS

Freshly excised adult skin specimens (up to 24 hours following surgery) were transported to the tissue culture laboratory in saline-soaked gauze. The specimens (full-thickness skin and dermatome sections) were rinsed in culture medium containing Penicillin (500 units/ml) and Streptomycin (500 mcg/ml). Full-thickness skin was cleared of as much dermis as possible. The specimens were then treated with the following dissociation agents: (1) dispase (4 units/ml) to separate epidermis from dermis (this treatment also dissociates cells below the granulosum, Figure 1); (2) trypsin-EDTA (0.25%-0.01%) to dissociate remaining viable cells from the epidermis. The cells were collected by centrifugation in culture medium containing 10% fetal bovine serum (FBS) then immediately transferred to fresh medium. The medium used initially for plating the cells contained RPMI 1640 (with 25mM HEPES) 10% fetal bovine serum, Penicillin (100 un/ml) and Streptomycin (100 mcg/ml) or IMEM with gentamycin (25mcg/ml) and 10% FBS. Twenty-four-well cluster dishes were prepared by first placing a 15 mm diam. coverslip in each of 6 or 12 wells (depending on size of specimen) then either coating the coverslip with up to 250 ul of Matrigel (in cold). Matrigel is a biological matrix consisting of the major components of basement membranes: Type IV collagen, laminin and proteoglycans, notably heparan sulfate. Alternatively, Type I collagen discs (films or sponges) (Helitrex, Inc.) were placed on the coverslips, hydrated with medium added dropwise, and, in turn, were coated with Matrigel. A high density of 1 million cells were added to each well and fed with medium plus 10% FBS, reduced to 2% by day 6. Viability of the cells was assessed by trypan blue exclusion. Aliquots of cells were suspended in 0.4% trypan blue in a 1:1 dilution and counted in a hemocytometer. Serum-reduced or serum-free medium supplemented with insulin (5mcg/ml), transferrin (10mcg/ml), hydrocortisone (0.5mcg/ml) and epidermal growth factor (EGF) (10mcg/ml) and more recently bovine pituitary extract (BPE) (70mcg/ml). Changes were made in media formulations as information and new products became available. The cultures were either sealed or placed in a chamber that was saturated with 5% CO_2 then sealed and maintained at 37 oC. Cultures were examined and refed twice weekly. Growth patterns were recorded by light microphotography and morphological evidence of differentiation determined by electron microscopy at 6-8, 12-14 and 18-21 days. The presence of keratin was also determined by immunocytochemistry using rabbit anti-human cytokeratin (Polysciences, Inc.) followed by FITC-labeled goat anti-rabbit IgG, H+L, (Boehringer-Mannheim).

RESULTS

Ninety to 100% of the epidermal cells of most cultures readily attach to Matrigel as single cells or in small clusters. The degree of attachment was determined by the number of viable cells aspirated at the time of the first refeeding at 48 or 72 hours. Growth was assessed to be a factor of an increase in cell number as well as the active, generally inward migration of cells and the formation of larger clusters or aggregates. Figure 2 shows a three-day monolayer culture of nearly confluent cells which comprise four major types in varying proportions. These were: squamous cells, 6%; pigmented cells, 8%; non-pigmented fusiform cells, 18% and round and oval cells (considered to be primarily from the stratum germinativum), 68%. Figure 3 shows an aggregate of rounded cells and, it appears, cells "streaming" inward toward the aggregate. A distinguishing feature of cells grown on Matrigel was the absence of the degree of spreading that is characteristic of cells grown on plastic. Even in sparce cultures, there was a tendency for cells to associate in bilayers and trilayers exhibiting polarity and some of the histotypic characteristics of intact skin: basal regions - flattened with few short cytoplasmic processes but no extensive projections into the Matrigel; basolateral surfaces - numerous desmosomes and, in some cases, interdigitations; apical surfaces - microvillar projections (Figures 4-6). There were varying degrees and patterns of keratinization in the layered aggregates attached to the Matrigel. Sloughing was observed in most cultures after 7-10 days, but appeared to be reduced with low-serum medium probably as a consequence of slower growth and an increase in desmosomal junctions. Figure 7 shows a sloughed aggregate which exhibits gradual flattening of the cells from bottom to top, an increase in keratinization in the uppermost cells and numerous desmosomes in the lower cells. However, pycnotic nuclei and the absence of other organelles indicate advanced degeneration in this mass of cells. Another mass of cells exhibits some of the same features and shows the relation to the viable cells below that are still attached to the Matrigel (Figure 8).

Cells containing varying amounts of melanin were observed to occur singly, in bilayers and in the large aggregates. Several patterns of melaninization were generally observed in these cultures. The patterns observed most frequently were: (1) dense accumulation of melanin granules sequestered in one-half of the cells juxtaposed to mass of keratin bundles; (2) ring of melanin granules internal to a perinuclear ring of keratin bundles; and (3) melanin granules dispersed throughout the cytoplasm and interspersed with keratin fibrils. However, it was beyond the scope of this study to determine which, if any, of these cells were true melanocytes, i. e., cells that synthesized melanin.

A small percentage of dispersed squamous cells were seen throughout the culture period and appeared to be the same cells observed in the early monolayer cultures. They were evidently released during the initial dissociation process and were considered largely non-viable. Of interest was the presence of a few isolated cells that exhibited numerous desmosomal plaques, that were both at the cell surface or were internalized.

DISCUSSION

Evidence is presented that viable adult epidermal cells, that appeared to be derived from layers below the stratum granulosum, readily attach to a basement membrane-derived matrix, Matrigel, which also supported some degree of differentiation of these cells in low-serum medium. Some bilayered and trilayered aggregates exhibited numerous baso-lateral desmosomal junctions and abundant keratin fibrils, two of the the primary histotypic characteristics displayed by epidermal cells in vivo. Polarity, formation of multilayered aggregates and growth on the surface of the Matrigel with no significant penetration into this extra-cellular matrix provided further evidence of differentiation and suggests the lack of teratogenic changes in these cell cultures. The formation of aggregates was an early event that was well established at 3 days. With daily observations, it was determined that the larger aggregates were the result of the active migration of cells and were not introduced into the cultures as such. Sloughing, that followed the formation of the large aggregates, in part, simulates the in vivo condition. A significant difference is the state or stage of the cells that slough in vitro. Cells comparable to the larger polygonal cells in the basal part of the detached aggregate would not be sloughed in vivo, but neither would there be the degree of degeneration that is seen in these cells in vitro. Therefore, while cellular degeneration is part of the normal epidermal developmental process, it appears that the culture condition contributes to the acceleration of this process. Among the causes may be the secretion, accumulation and local activity of proteases or other factors. Or, the Matrigel, in promoting differentiation may accelerate degeneration. Frequent media changes and/or the addition of protease inhibitors may slow the process. On the other hand, if differentiation is being accelerated by the Matrigel it would also be more advantageous, clinically, to use the cultured autografts at 5-7 days. It is noteworthy, that Lerner and Hull (1986) obtained successful grafts in mice with a bilayered skin equivalent.

REFERENCES

1. Alvarez, O. M. and Biozes, D. G. Cultured epidermal autografts for partial thickness and full thickness wounds. Clinic. Dermatol. 1984

2. Cummer, C. L. and LaRocco, C. G. Ulcers on the legs in sickle cell anemia. Arch. Dermatol. Syphilol. 42:1015-1039, 1940.

3. Eisinger, M., Monden, M., Raaf, J. H. and Fortner, J. Wound coverage by a sheet of epidermal cells grown in vitro from dispersed single cell preparations. Surgery 80:287-293, 1980.

4. Fuller, R. A. and Rosen, J. J. Materials for medicine. Scientif. Amer. 255 (4):118-125, 1986.

5. Green, H., Kehinde, O. and Thomas, J. Growth of cultured human epidermal cells into multiple epithelia suitable for grafting. Proc. Nat. Acad. Sci. USA 76: (5) 665-668, 1979.

6. Green, H. and O'Connor, N. Cultured cells for regeneration of epidermis by grafting. In: Wise, D., (ed.) Burn Wound Covering. CRC Press, Inc., 1984.

7. Lerner, M. B. and Hull, B. E. The use of a bilayered skin equivalent in grafting to mice. J. Cell Biol. 103 (5, Pt.2):249a.

8. O'Connor, N. E., Mulliken, J. B., Banks-Schlegel, S. Kehinde, O and Green, H. Grafting of burns with cultured epithelium prepared from autologous epidermal cells. The Lancet 1:75-78, 1981.

9. Quinn, K. J., Courtney, J. M., Evans, J. H., Gaylor, J. and Reid, W. H. Biomaterials 6 (6):369-377, 1985.

10. Yannas, I. V. and Burke, J. F. Tried in the fire:New Treatment for Massive Burns. In: Sutton, S. B. (ed.) Harvard Magaz. Sept.-Oct. pp 1-5, 1984.

FIGURES

1. Section of dispase-separated human epidermis used to generate cell cultures showing separation of outer and inner layers and cellular dissociation.

2. Two-day culture showing four primary cell types growing as a monolayer of loosely associated cells. Hoffman modulation contrast.

3. Three-day culture showing in which cells appear to be "streaming" inward to form a cluster.

4-6. Sections of epidermal cells on Matrigel, forming multilayered aggregates and exhibiting polarity (with some surface microvillar projections and flattened basal surfaces at the cell-Matrigel interface) basolateral interdigitations and desmosomes and small bundles of keratin filaments (6-9 days).

7-8. Large clusters of sloughed cells with pycnotic nuclei, small bundles of keratin, and numerous desmosomal junctions. Tips of cells attached to matrigel are at lower margin of figures. (9 days).

9-12. Patterns of melaninization: (9) internal to dense perinuclear ring of keratin filaments; (10) dispersed throughout the cytoplasm; (11 and 12) sequestered clusters.

ACKNOWLEDGEMENT:

This Study was supported in part by
USAID Grant # DAN-5053-G-SS-5102-00.

1. Section of dispase-separated human epidermis used to generate cell cultures showing separation of outer and inner layers and cellular dissociation.

2. Two-day culture showing four primary cell types growing as a monolayer of loosely associated cells. Hoffman modulation contrast.



3. Three-day culture showing cells which appear to be "streaming" inward to form a cluster.

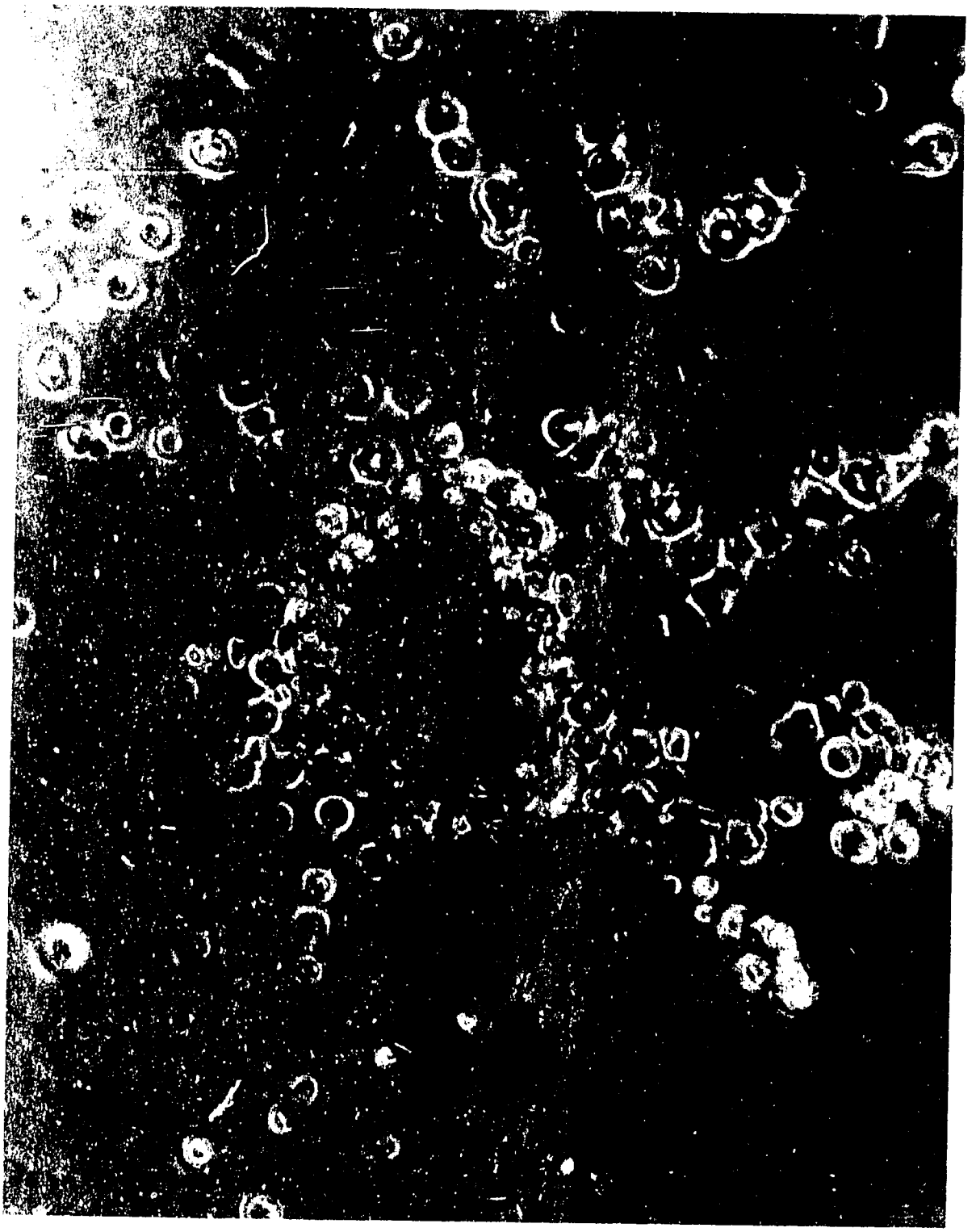

4-6. Sections of epidermal cells on Matrigel, forming multilayered aggregates and exhibiting polarity (with some surface microvillar projections and flattened basal surfaces at the cell-Matrigel interface) basolateral interdigitations and desmosomes and small bundles of keratin filaments (6-9 days).


M
4

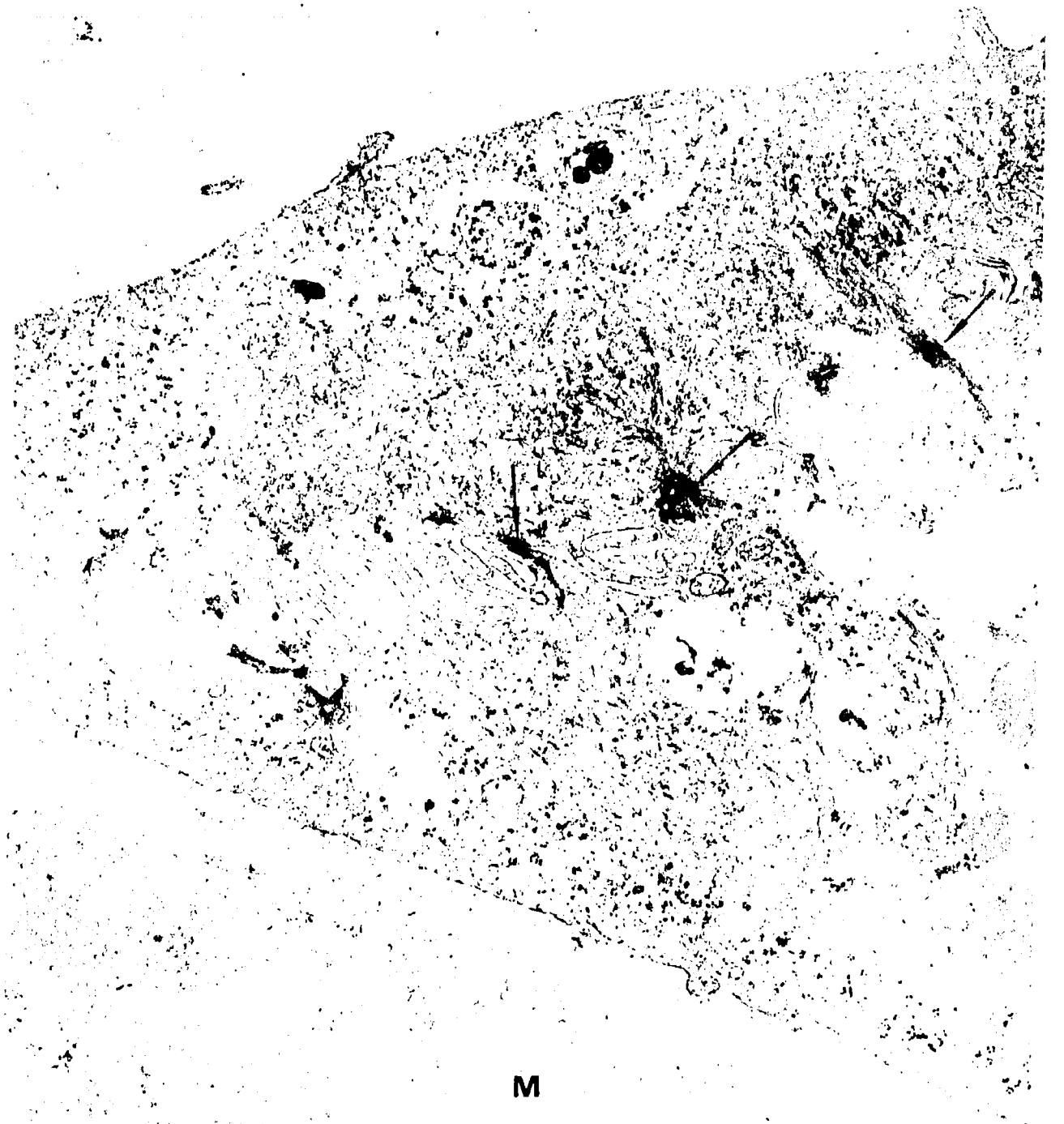

5

6

7-8. Large clusters of sloughed cells with pycnotic nuclei, small bundles of keratin, and numerous desmosomal junctions. Tips of cells attached to matrigel are at lower margin of figures. (9 days).

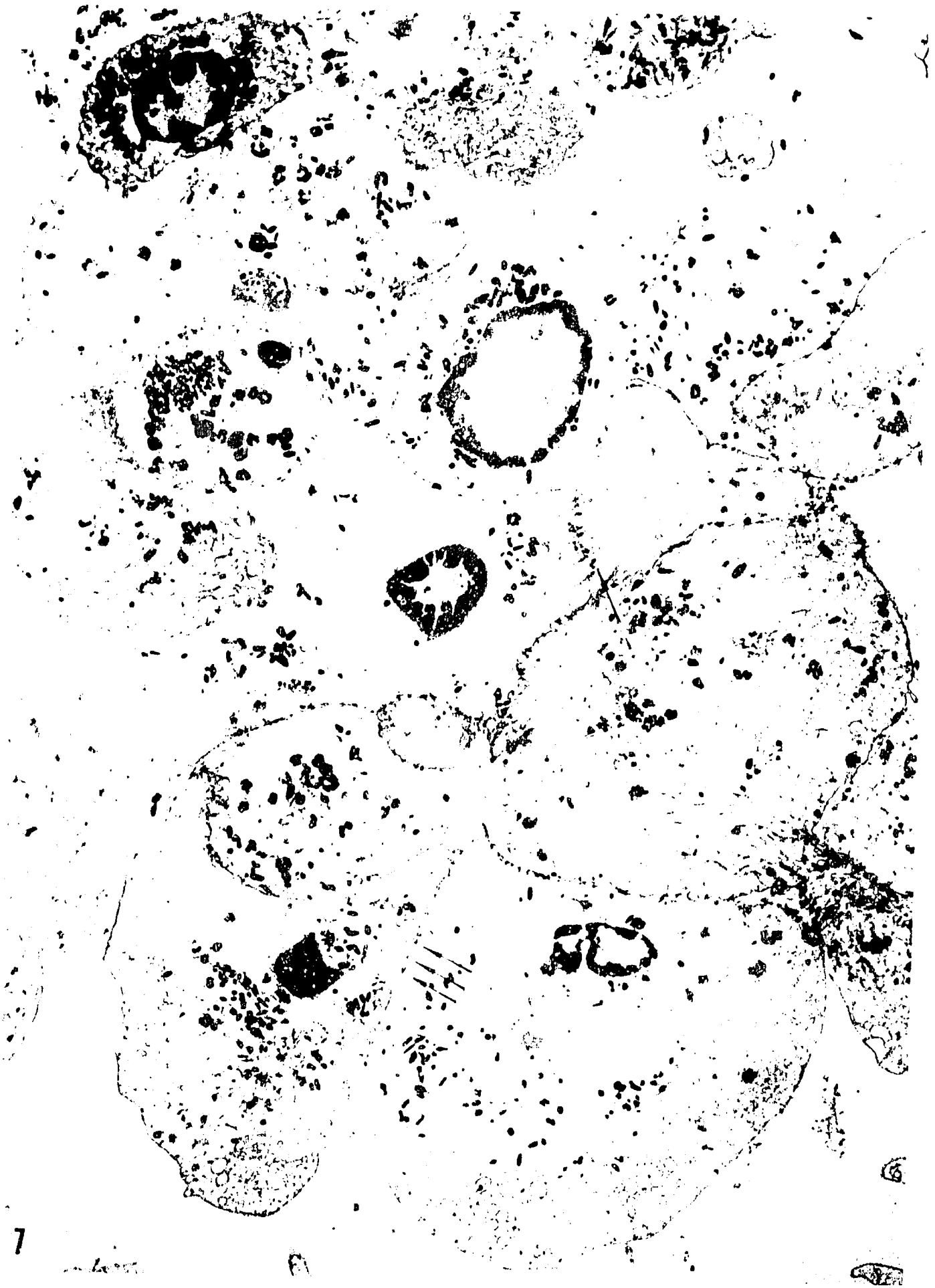

7

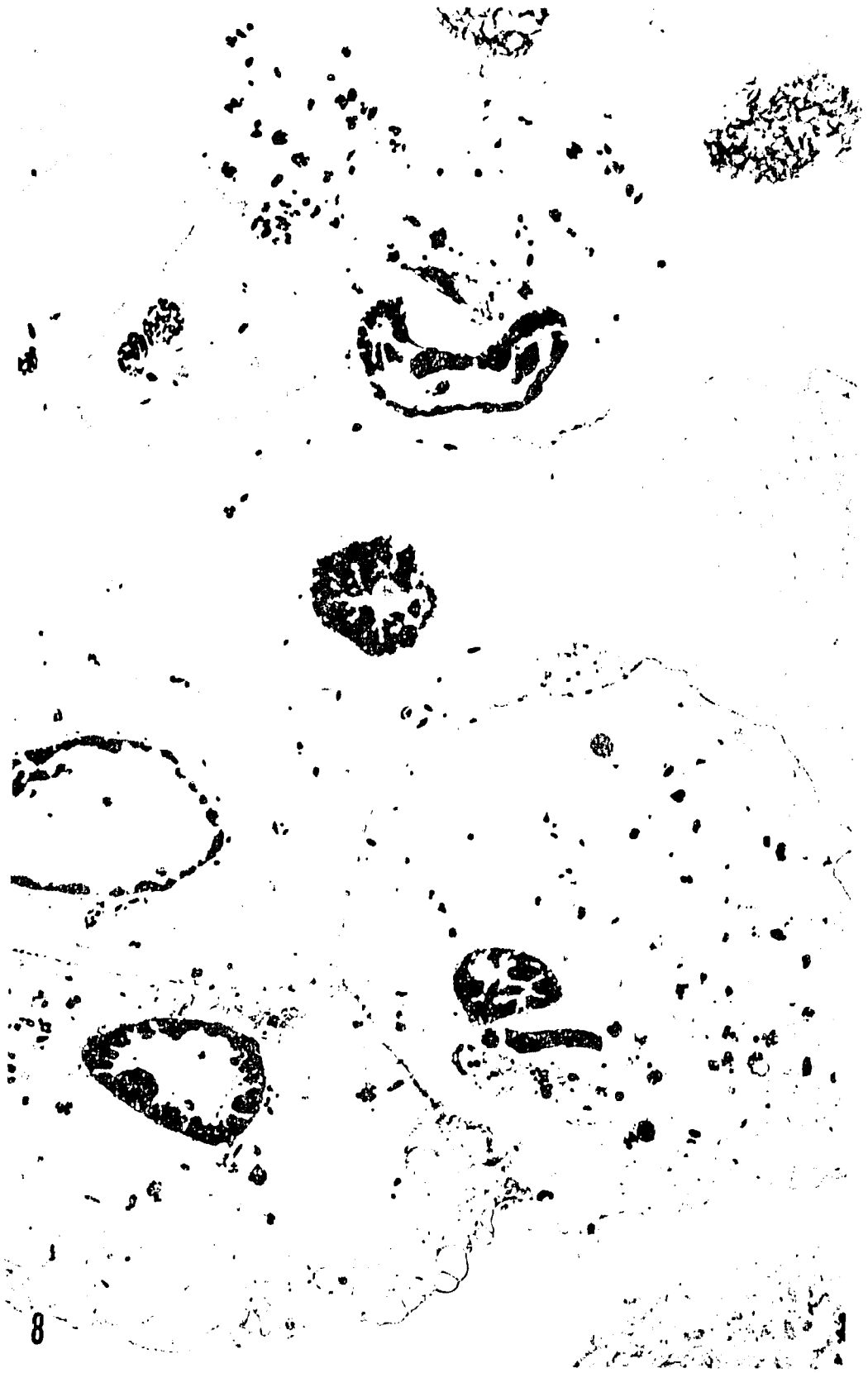
8

9-12. Patterns of melaninization: (9) internal to dense perinuclear ring of keratin filaments; (10) dispersed throughout the cytoplasm; (11 and 12) sequestered clusters.

9



10



M

11

12

PART II

RAPID HEALING OF SICKLE CELL LEG ULCERS TREATED WITH COLLAGEN DRESSING

Adekunle D. Adekile, MD: Department of Pediatrics and Child Health, University of Ife, Ile Ife Nigeria.

Carl Alexander Reindorf, MD, FRCP: Center for Sickle Cell Disease, Howard University, Washington, DC, USA

Dorothy Walker-Jones, Ph.D., Department of Zoology, Howard University, Washington, DC, USA

O. Lawal, MD and S.F. Oluwole, MD: Department of Surgery, Faculty of Health Sciences, University of Ife, Ile Ife, Nigeria

INTRODUCTION:

USAID Grant #DAN-5053-G-SS-5102-00 awarded in 1985 to Carl A. Reindorf, Dorothy Walker-Jones and A. D. Adekile et al on "Model for the in vitro generation of human epidermal autografts for potential use in the treatment of sickle cell leg ulcers" has enabled us to investigate the development of culture procedure for the rapid growth of differentiated human epidermal cell sin vitro, with the eventual aim of using such cultured cells as autografts in the management of chronic ulcers, especially, sickle cell ulcers.

To determine the requirements for optimal growth of the epidermal cells in vitro, several growth-enchancing factors were studied. These included Epidermal Growth Factor (EGF) and Bovine Pituitary Factor, as well as "Matrigel" which contains essential basement membrane components. Furthermore, since the laboratory-generated epidermal cells will need a supporting matrix in order to be applied to the ulcers, we decided to perform a preliminary evaluation of the collagen matrix (Collistat, Hellistrex, Inc.) to assess its independent effect in promoting the healing of sickle cell leg ulcers without the presence of the epidermal autograft.

This communication is a report of 2 Nigerian sickle cell anemia (Hb SS) patients with chronic leg ulcers, who had Collistat dressings for their leg ulcers.

24

CASE REPORTS:

1. J. O. was a 29 year-old female teacher diagnosed as a sickle cell anemia patient (Hb SS) early in childhood. She had been hospitalized on many occasions. She developed a leg ulcer over and above the left medial malleolus 10 years ago. The ulcer was refractory to conventional treatment (antibiotics, bed rest, eusol dressing, etc.). She had skin grafting done in May 1985, but there was a recurrence with 3 months. She was recruited into the present study in June 1986. The size of the ulcer was 6 x 3 cm. Figure 1.

To obtain a control, only the upper half of her ulcer was initially dressed with Collistat. On review after 2 weeks, there was appreciable healing on the part so dressed, and a decision was made to apply Collistat to the whole ulcer surface.

The ulcer was reviewed every 2 weeks, and fresh Collistat applied every 4 weeks. After the first 6 weeks, the ulcer showed further evidence of healing. Figure 2. Figure 3 shows almost complete healing at 9 weeks. By 12 weeks, there was complete healing.

2. O. F. was a 20 year old male administrative officer. He had been hospitalized several times previously. He developed a refractory chronic ulcer over and above the right medial malleolus in 1978. In August 1980, and again in October 1980, he had skin grafts which were unsuccessful in achieving healing. In May 1985, he had another skin graft with good results, but there was recurrence of the ulcer after 8 months. He was recruited into the present study in January, 1987. His ulcer at that time measured 5 x 3.5 cm. Figure 4.

While in the hospital, Collistat was applied to the ulcer, and it was reviewed forthnighly. The dressing was reapplied every 4 weeks. There was progressive healing Figure 5; and by the bedtime he was discharged, after 10 weeks, the ulcer was completely healed.

DISCUSSION:

Chronic leg ulceration is a common complication of sickle cell anemia, with reported prevalence varying from 12% in children to 75% in adults. (1,2). The ulcers tend to occur in areas that have a poor or marginal blood supply and a thin layer of subcultaneous tissue. Therefore, they are seen mainly around the ankles and anterior tibia (3).

The intense pain of leg ulcers usually limits activity and causes absence from school or work. The economic, educational and other implications of this complication are important factors in the morbidity from leg ulcers (4). Accordingly, every effort to improve the treatment of this chronic debilitating complication of sickle cell disease is very important.

Current medical treatment consists of prolonged bed rest, which is beneficial, but impractical. Daily wound dressing with mild antiseptics or desloughing agents and blood transfusion are the other usual modalities of treatment. Since there is usually infection of the ulcer bed, broad-spectrum antibiotics may have to be given. Generally, however, the results of medical treatment have been poor; and when healing has occurred, it has been a very slow process (3).

Surgical treatment (5) usually consists of skin grafting procedures (cross-leg flap, split-skin graft postage stamp or pinch grafts). However, recurrence after healing is frequent and surgical treatment is generally unsatisfactory. (6, 7).

The role of collagen in promoting wound healing is well-established (8, 9). But to our knowledge, it had not previously been tried in the management of sickle cell leg ulcers. The results of the present study are, therefore, very encouraging. The other advantage of collagen over conventional dressing is that it is absorbed, and does not have to be re-applied frequently. However, the ulcer should have been well-debrided and well-cleaned before application. If there is evidence of infection, appropriate antibiotics should be administered.

The 2 patients in this study have been followed for 6 and 3 months respectively. Patient 1 had a recurrence at 3 months, while patient 2 has not shown signs of recurrence.

The other growth-enhancing factors being used in our epidermal culture technique will also be evaluated for their potential in promoting healing of sickle cell leg ulcers.

It is envisaged that the encouraging independent performance of collagen demonstrated in this study will be greatly enhanced by the presence of the layers of laboratory-cultured epidermal cells.

REFERENCES

1. Serjeant, G.R: Leg Ulceration in Sickle Cell Anemia. Arch. Intern. Med: 133; 690-94, 1974.

2. Walshe, M.M. and Milner, P.F: The Management of Leg Ulcers in Sickle Cell Anemia. West Indian Med. J.: Vol. XVI; 10-16, 1967.

3. Gueri, M. and Serjeant, G.R: Leg Ulcers in Sickle Cell Anemia. Trop. Georg. Med: 22; 155-60, 1970.

4. Alleyne, S.I.; Wint, E.; Serjeant, G.R: Social Effects of Leg Ulceration in Sickl eCell Anemia: Southern Med. J. 70, #2, 213-15, 1973.

5. Chernoff, A.I.; Shapleight, F.R.; Moore, C.V.; Therapy of Chronic Ulceration of the Legs Associated with Sickle Cell Anemia. J.A.M.A. 155: 1487-91, 1954.

6. Woolfort, F.G. and Krizet, T.J.: Skin Ulceration in Sickle Cell Anemia. Plast. & Reconst. Surgery 43, 71-77, 1969.

7. Flye, M.W. and Silver, D.; The Role of Surgery in Sickle Cell Disease. Surg., Gynec. & Obst. 137: 115-26, 1973.

8. Bell E.; Erlich, H.P.; Buttle, D.J. and Nakatsuji, T.: Living Tissue Formed in Vitro and Accepted as Skin-equivalent Tissue of Full Thickness. Science: 211: 1052-54, 1981.

9. Alvarez, O.M. and Biozes, D.G.: Cultured Epidermal Autografts for Partial Thickness and Full Thickness Wounds. Clinics in Dermatology.

RAPID HEALING OF SICKLE CELL LEG ULCERS TREATED WITH COLLAGEN DRESSING

Adekunle D. Adekile, MD: Department of Pediatrics and Child Health, University of Ife, Ile Ife Nigeria.

Carl Alexander Reindorf, MD, FRCP: Center for Sickle Cell Disease, Howard University, Washington, DC, USA

Dorothy Walker-Jones, Ph.D., Department of Zoology, Howard University, Washington, DC, USA

O. Lawal, MD and S.F. Oluwole, MD: Department of Surgery, Faculty of Health Sciences, University of Ife, Ile Ife, Nigeria

INTRODUCTION:

USAID Grant #DAN-5053-G-SS-5102-00 awarded in 1985 to Carl A. Reindorf, Dorothy Walker-Jones and A. D. Adekile et al on "Model for the in vitro generation of human epidermal autografts for potential use in the treatment of sickle cell leg ulcers" has enabled us to investigate the development of culture procedure for the rapid growth of differentiated human epidermal cell sin vitro, with the eventual aim of using such cultured cells as autografts in the management of chronic ulcers, especially, sickle cell ulcers.

To determine the requirements for optimal growth of the epidermal cells in vitro, several growth-enchancing factors were studied. These included Epidermal Growth Factor (EGF) and Bovine Pituitary Factor, as well as "Matrigel" which contains essential basement membrane components. Furthermore, since the laboratory-generated epidermal cells will need a supporting matrix in order to be applied to the ulcers, we decided to perform a preliminary evaluation of the collagen matrix (Collistat, Hellistrex, Inc.) to assess its independent efrect in promoting the healing of sickle cell leg ulcers without the presence of the epidermal autograft.

This communication is a report of 2 Nigerian sickle cell anemia (Hb SS) patients with chronic leg ulcers, who had Collistat dressings for their leg ulcers.

CASE REPORTS:

1. J. O. was a 29 year-old female teacher diagnosed as a sickle cell anemia patient (Hb SS) early in childhood. She had been hospitalized on many occasions. She developed a leg ulcer over and above the left medial malleolus 10 years ago. The ulcer was refractory to conventional treatment (antibiotics, bed rest, eusol dressing, etc.). She had skin grafting done in May 1985, but there was a recurrence with 3 months. She was recruited into the present study in June 1986. The size of the ulcer was 6 x 3 cm. Figure 1.

To obtain a control, only the upper half of her ulcer was initially dressed with Collistat. On review after 2 weeks, there was appreciable healing on the part so dressed, and a decision was made to apply Collistat to the whole ulcer surface.

The ulcer was reviewed every 2 weeks, and fresh Collistat applied every 4 weeks. After the first 6 weeks, the ulcer showed further evidence of healing. Figure 2. Figure 3 shows almost complete healing at 9 weeks. By 12 weeks, there was complete healing.

2. O. F. was a 20 year old male administrative officer. He had been hospitalized several times previously. He developed a refractory chronic ulcer over and above the right medial malleolus in 1978. In August 1980, and again in October 1980, he had skin grafts which were unsuccessful in achieving nealing. In May 1985, he had another skin graft with good results, but there was recurrence of the ulcer after 8 months. He was recruited into the present study in January, 1987. His ulcer at that time measured 5 x 3.5 cm. Figure 4.

While in the hospital, Collistat was applied to the ulcer, and it was reviewed forthnighly. The dressing was reapplied every 4 weeks. There was progressive healing Figure 5; and by the bedtime he was discharged, after 10 weeks, the ulcer was completely healed.

DISCUSSION:

Chronic leg ulceration is a common complication of sickle cell anemia, with reported prevalence varying from 12% in children to 75% in adults. (1,2). The ulcers tend to occur in areas that have a poor or marginal blood supply and a thin layer of subcultaneous tissue. Therefore, they are seen mainly around the ankles and anterior tibia (3).

The intense pain of leg ulcers usually limits activity and causes absence from school or work. The economic, educational and other implications of this complication are important factors in the morbidity from leg ulcers (4). Accordingly, every effort to improve the treatment of this chronic debilitating complication of sickle cell disease is very important.

Current medical treatment consists of prolonged bed rest, which is beneficial, but impractical. Daily wound dressing with mild antiseptics or desloughing agents and blood transfusion are the other usual modalities of treatment. Since there is usually infection of the ulcer bed, broad-spectrum antibiotics may have to be given. Generally, however, the results of medical treatment have been poor; and when healing has occurred, it has been a very slow process (3).

Surgical treatment (5) usually consists of skin grafting procedures (cross-leg flap, split-skin graft postage stamp or pinch grafts). However, recurrence after healing is frequent and surgical treatment is generally unsatisfactory. (6, 7).

The role of collagen in promoting wound healing is well-established (8, 9). But to our knowledge, it had not previously been tried in the management of sickle cell leg ulcers. The results of the present study are, therefore, very encouraging. The other advantage of collagen over conventional dressing is that it is absorbed, and does not have to be re-applied frequently. However, the ulcer should have been well-debrided and well-cleaned before application. If there is evidence of infection, appropriate antibiotics should be administered.

The 2 patients in this study have been followed for 6 and 3 months respectively. Patient 1 had a recurrence at 3 months, while patient 2 has not shown signs of recurrence.

The other growth-enhancing factors being used in our epidermal culture technique will also be evaluated for their potential in promoting healing of sickle cell leg ulcers.

It is envisaged that the encouraging independent performance of collagen demonstrated in this study will be greatly enhanced by the presence of the layers of laboratory-cultured epidermal cells.

REFERENCES

1. Serjeant, G.R: Leg Ulceration in Sickle Cell Anemia. Arch. Intern. Med: 133; 690-94, 1974.

2. Walshe, M.M. and Milner, P.F: The Management of Leg Ulcers in Sickle Cell Anemia. West Indian Med. J.: Vol. XVI; 10-16, 1967.

3. Gueri, M. and Serjeant, G.R: Leg Ulcers in Sickle Cell Anemia. Trop. Georg. Med: 22; 155-60, 1970.

4. Alleyne, S.I.; Wint, E.; Serjeant, G.R: Social Effects of Leg Ulceration in Sickl eCell Anemia: Southern Med. J. 70, #2, 213-15, 1973.

5. Chernoff, A.I.; Shapleight, F.R.; Moore, C.V.; Therapy of Chronic Ulceration of the Legs Associated with Sickle Cell Anemia. J.A.M.A. 155: 1487-91, 1954.

6. Woolfort, F.G. and Krizet, T.J.: Skin Ulceration in Sickle Cell Anemia. Plast. & Reconst. Surgery 43, 71-77, 1969.

7. Flye, M.W. and Silver, D.; The Role of Surgery in Sickle Cell Disease. Surg., Gynec. & Obst. 137: 115-26, 1973.

8. Bell E.; Erlich, H.P.; Buttle, D.J. and Nakatsuji, T.: Living Tissue Formed in Vitro and Accepted as Skin-equivalent Tissue of Full Thickness. Science: 211: 1052-54, 1981.

9. Alvarez, O.M. and Biozes, D.G.: Cultured Epidermal Autografts for Partial Thickness and Full Thickness Wounds. Clinics in Dermatology.



FIGURE 1

FIGURE 2

FIGURE 3



FIGURE 4

FIGURE 5