PN-AAT-074

ANATOMY AND PHYSIOLOGY MODULE

STUDENT TEXT

1980
Rural Health Development Project
Ministry of Health and Social Welfare
Maseru, Lesotho

ACKNOWLEDGEMENTS

Nurse Clinician training materials are Lesotho adaptations based upon the MEDEX prototype curriculum for training mid-level health workers.

The prototype MEDEX materials were developed by the Health Manpower Development Staff of the John A.Burns School of Medicine, University of Hawaii. The original prototypes were based on training experience in over a dozen third-world countries. These were revised on the basis of HMDS experience in Micronesia, Thailand, Pakistan, and Guyana before being made available to Lesotho under a U.S.A.I.D. funded contract.

Major adaptation in Lesotho began at the National Nurse Clinician Training Programme Curriculum Adaptation Workshop held at Maseno'd in January 1980. The nearly fifty participants represented all major health and health related activities in Lesotho, both Government and private. These participants and others working as individuals and then as review committees have adapted the Nurse Clinician training materials to meet the conditions and needs of Lesotho.

The Government of Lesotho and particularly the staff of the Nurse Clinician training Programme are grateful to HMDS for supplying the prototype materials and to all those individuals who have helped in the Lesotho adaptation process.

First Edition May 1980

TABLE OF CONTENTS

LIST OF REFERENCES 1

SCHEDULE 3

INTRODUCTION 4

GLOSSARY 5

INTRODUCTORY CONCEPTS 19

SKIN 30

SKELETAL SYSTEM 33

MUSCULAR SYSTEM 41

THORAX 45

CIRCULATORY SYSTEM 49

RESPIRATORY SYSTEM 60

ABDOMEN/DIGESTIVE SYSTEM 66

Anatomy of the Abdomen 67
Digestive System 69

PELVIS & EXTERNAL GENITALIA/URINARY SYSTEM 76

Anatomy of Pelvis & External Genitalia 77
Urinary System 80

REPRODUCTIVE SYSTEM 83

NERVOUS SYSTEM 93

REFERENCES USED IN THE DEVELOPMENT OF THE ANATOMY AND PHYSIOLOGY MODULE

Ashley, R. Human Anatomy. John Wiley and Sons, Inc., New York, 1976, 274 pp. - Programmed text for basic human anatomy and physiology.

Boolootian, R.H. Elements of Human Anatomy and Physiology. West Publishing Co., St.Paul, Minnesota, 1976, 504 pp.- Balanced basic text.

Crouch, J.E. and McClintic, J.R. Human Anatomy and Physiology. John Wiley and Sons, Inc., 1971, 644 pp. - Good basic text with instructor's manual, student's workbook and laboratory manual.

Evans, W.F. Anatomy and Physiology. Prentice-Hall, Inc., Englewood Cliffs, New Jersey, 1976, 463 pp. - Basic anatomy and physiology text with instructor's manual and laboratory guide.

Ferris, E.B. and Skelley, E.G. Body Structure and Functions. Delmar Publishers, Albany, New York, 1973, pp.158 - Very basic text in human anatomy and physiology.

Landau, B.R. Essential Human Anatomy and Physiology. Scott, Foresman and Co., Glenview, Ill., 1976, 598 pp. - Balanced basic text for human anatomy and physiology. Instructor's manual and student workbook included.

Langley, L.L., Telford, I.R. and Christensen, J.B. Dynamic Anatomy and Physiology. McGraw-Hill Book Co., New York, 1969, 817 pp. - Basic text with laboratory manual.

Panshy, B. Dynamic Anatomy and Physiology. Macmillan Publishing Co., Inc., New York, 1975, 684 pp.

Vander, A.J., Sherman, J.H., and Luciano, D.S. Human Physiology. McGraw-Hill Book Co., New York, 1975, 614 pp. - Basic text with heavy emphasis on physiology. Includes student workbook.

MODULE:
ANATOMY AND PHYSIOLOGY MODULE

TEXT ILLUSTRATION REFERENCES		*If not applicable - NA. *Permission Requested (Date and Initial)	Permission Received (Date)
Figure Nos.adapted from source listed in the column to the right.			
AP 17-21, 28, 29, 32, 34, 36-40, 42-46, 48-52	Camera Talks Limited, 31 North Row Park Lane, London, W1R 2 EN, U.K.	NA	
Fig.AP 11, 47	Camera Talks Limited, (See above address)		
Fig.AP 8,23	Ferris, E.D.: Skelley, E.G. Body Structure and Function, Delmar Publishers, Inc., Albany, New York, 1973.	NA	
Fig.AP 1, 2, 12, 13	Strand, Helen R. An Illustrated Guide to Medical Terminology, The William & Wilkins Co., Baltimore, 1968	NA	
Fig.AP 16, 22, 26	MEDEX/Guyana Program, c/o Ministry of Health, Georgetown, Guyana, 1977	NA	
Fig.AP 24, 25, 53, 54	HMDS/Health Instructional Resources Unit, School of Medicine, University of Hawaii	NA	
Fig.AP 14, 15	Coles, T. Health Manpower Development Staff, School of Medicine, University of Hawaii	NA	
Fig. AP 27, 30, 31, 33	King, King's Primary Child Care, WHO 1978		
Fig.AP	The Primary Health Care Worker, WHO 1977		

SCHEDULE

DAY 1	DAY 2	DAY 3	DAY 4	DAY 5

INTRODUCTION

This module is designed to give a basic overview of the anatomy and physiology of the human body. It begins with a definition of some basic concepts a nurse clinician should be familiar with. It then proceeds to describe the organ systems of the body, the components which make up these systems, and the anatomical regions which contain these systems. The student is advised to refer to the glossary prior to reading each chapter in the text to familiarize him or herself with the concepts and terms that will be used in the chapter. The terms are grouped according to the chapter in which they appear, and are listed in the order in which they appear in the chapter text.

More specific descriptions of anatomical regions of the body appear in the clinical modules which follow where more detailed understanding is necessary for the diagnosis and management of specific problems.

The Anatomy and Physiology Module is a core-skills module and should precede the other clinical modules. It is suggested that the Physical Exam Module, which is also a core-skills module, be studied together with the Anatomy and Physiology Module. Studying these two modules together will reinforce the information presented in each.

GLOSSARY

1. anterior - situated in front of or in the forward part of.
2. atrophy - a wasting away or shrinkage in size of cell, tissue, organ or part.
3. dorsal - referring to the back.
4. hyperactive - abnormal over-activity.
5. lateral - referring to a side.
6. medial - pertaining to the middle; in anatomy, nearer the median plane.
7. palpate - to examine by the hand; to feel.
8. percussion - the act of striking a part with short, sharp blows.
9. pitting oedema - the formation of a depression following pressure on a part, due to swelling.
10. posterior - situated behind or toward the rear.
11. prone - lying with face downward.
12. supine - lying on the back, face upward.

GLOSSARY

Anatomical Terms

dorsal - pertaining to the back surface; posterior.

ventral - pertaining to the belly surface; anterior.

medial - pertaining to the middle or midline.

lateral - pertaining to the side and farther away from median plane.

anterior - situated in front of or in the forward part of.

posterior - situated behind or toward the rear.

superior - situated above.

inferior - situated below.

proximal - nearest, closer to any point of reference.

distal - remote, farther away from any point of reference.

GLOSSARY

I. INTRODUCTORY CONCEPTS

cell - the simplest structural and functioning unit of life. Composed of nucleus and cytoplasm.

metabolism - the ability of cells to take in nutrients, digest them, mix them with gases to produce energy and excrete the waste products.

growth - the ability to increase in size and number.

irritability - short-term immediate response of cells to changes in their environment.

adaptation - changes in cells over time to improve ability to live in their environment.

reproduction - the ability of living things to make more organisms like themselves.

nucleus - that structure found inside each cell which contains the information of the cell and passes it from one generation to the next.

cytoplasm - the jelly-like substance contained by the cell membrane and surrounding the nucleus, which contains the rest of the living substances of the cell.

tissue - units of cells grouped together to perform specific functions. The four basic tissues include muscle tissue, nerve tissue, epithelial tissue, connective tissue.

organ - a group of tissues brought together to perform a specific function. Examples of organs include stomach, liver, and kidney.

system - a group of organs with similar specialized functions. Organ systems of the body include: the skin, skeletal, muscular, circulatory (or cardiovascular), respiratory, digestive, urinary, reproductive and nervous system.

thorax - region below the clavicle and above the lower edge of the rib cage.

GLOSSARY

sternum - breast bone.

pelvis - the cavity within the hip bone where the organs of the reproductive system, as well as the rest of the urinary and digestive systems, are located.

perineum - the region into which the digestive, reproductive, and urinary systems open.

axilla - arm pit.

II. SKIN

sweat - salt-containing moisture excreted by the sweat glands.

epidermis - outer layer of skin containing dead cells.

dermis - inner layer of skin made up of living cells, blood vessesl, nerves, oil and sweat glands.

III. SKELETAL SYSTEM

shaft - the long, narrow part of the long bone.

marrow - the fatty material found in the centres of bones from which red and white blood cells are formed.

vertebrae - small, irregular bones which make up the spine.

shoulder area - that part of the skeleton where the arms attach to the shoulders. Made up of two clavicles and two scapulae.

clavicle - collar bone.

scapula - shoulder blade.

humerus - the bone in the upper arm which extends from the shoulder to the elbow.

ulna - the inner and larger bone of the lower arm on the side opposite that of the thumb.

radius - the bone on the outer or thumb side of the lower arm.

GLOSSARY

carpal bones - wrist bones.

metacarpal bones - the five, long bones of the hand found between the wrist and the finger bones.

phalanges - the bones of the fingers and toes.

pelvic area - that part of the skeleton where the legs attach to the hips.

pelvis - the bone structure at the bottom end of the trunk which supports the spinal column and rests on the legs.

ilium
ischium
pubis
} the three bones which make up the pelvis.

sacrum
coccyx
} the two bones at the bottom of the spinal column.

femur - the thigh bone extending from the pelvis to the knee.

tibia - the inner and larger bone of the leg below the knee.

fibula - the outer and smaller bone of the leg below the knee.

tarsal bones - ankle bones.

metatarsal bones - the five, long bones of the foot found between the ankle and the toe bones.

IV. MUSCULAR SYSTEM

voluntary muscles - those muscles which can be moved at will, such as the muscles of the arms and legs.

involuntary muscles - those muscles which cannot be consciously made to move, but move of their own accord when some job is to be done, for example, the stomach muscle.

10

GLOSSARY

tendon - the strong cord of fibres joined together at the ends of the muscle which attaches to the bone.

insertion - the point where a muscle attaches to the bone and moves most.

origin - the point where a muscle attaches to the bone and moves least.

flexion - the movement which bends a joint.

extension - the movement which straightens a joint.

V. ANATOMY OF THE THORAX

jugular notch - the depression formed by the upper end of the sternum at the base of the neck.

sternal angle - the raised area of the sternum about one inch below the jugular notch which is even with the second intercostal space.

intercostal space - the space between each rib.

diaphragm - the dome-shaped sheet of muscle which separates the thorax from the abdomen and is primarily responsible for respiration.

xiphoid process - bottom tip of the sternum.

VI. CIRCULATORY SYSTEM

arteries - vessels which carry blood away from the heart.

veins - vessels which carry blood toward the heart.

systematic circulation - carries oxygenated blood and nutrients from the heart to the cells and brings unoxygenated blood back.

pulmonary circulation - carries unoxygenated blood to the lungs and brings oxygenated blood back to the heart.

lymphatic circulation - collects excess fluids from around the cells and deposits it in the venous side of the systemic circulation.

GLOSSARY

oxygenated blood - blood saturated with oxygen.

unoxygenated blood - blood containing carbon dioxide and cellular waste products, but no oxygen.

capillaries - thin-walled vessels through which blood nutrients, gases and wastes pass to and from cells. The last branches of the arterial circulation which join the arteries to the venous circulation.

plasma - fluid portion of the blood consisting of water, protein, minerals, and organic material.

red blood cells - the major element in blood. Transporters of oxygen from the lungs to the rest of the body.

haemoglobin - substance in the red blood cells which gives them their red colour.

white blood cells - disease-fighting cells of the blood.

antibodies - substances which destroy germs or poisons in the body.

platelets - small cells which are very active in the formation of clots.

atria - the two upper chambers of the heart.

ventricles - the two lower chambers of the heart.

pulmonary valve - valve between the right ventricle and the main pulmonary artery.

aortic valve - valve between the left ventricle and the aorta.

myocardium - special kind of muscle found only in the heart which contracts regularly without conscious stimulation.

systolic pressure - the pressure in the arteries when the heart is contracting. It is felt throughout the system as the "pulse".

diastolic pressure - the pressure in the arteries when the heart is relaxed.

12

GLOSSARY

aorta - the large artery with thick elastic walls into which blood flows from the left ventricle.

carotid arteries - arteries which branch off from the aorta to carry blood to the head.

subclavian arteries - arteries which branch off from the aorta to carry blood to the arms.

iliac arteries - branches off the end of the aorta which supply blood to the legs.

superior vena cava - the large vein into which unoxygenated blood from the head and arms flows before entering the right atrium of the heart.

inferior vena cava - the large vein into which unoxygenated blood from the thorax, abdomen, pelvis, and legs flows before entering the right atrium of the heart.

pulmonary trunk - the main pulmonary artery through which unoxygenated blood flows from the right ventricle towards the lungs.

right and left pulmonary arteries - medium-sized arteries off the main pulmonary artery carrying blood to the lungs.

right and left pulmonary veins - medium-sized veins carrying blood from the lungs to the heart.

oedema - the swelling of tissues when excess water leaks out of the capillaries.

spleen - the organ situated in the upper left corner of the abdominal cavity which functions primarily to remove and destroy worn out cells in the blood, produce lymphocytes, and trap and destroy microbes and other substances in the blood stream.

lymph - or lymphatic fluid, is the part of the blood plasma which has passed through the capillary walls of the systemic circulation and into the lymphatic vessels.

GLOSSARY

VII. RESPIRATORY SYSTEM

alveoli - tiny, bubble-like air sacs in the lungs. Surrounding them are capillaries through which the oxygen from the lungs passes into the blood.

larynx - the voice box which is at the upper end of the trachea.

trachea - the large airway between the throat and chest.

bronchi - the medium-sized airways between the trachea and the bronchioles.

bronchioles - the smallest airways between the bronchi and the alveoli.

diaphragm - the muscular membrane which separates the abdominal and thoracic cavities and which functions in respiration (breathing).

VIII. ANATOMY OF THE ABDOMEN

lumbar vertebrae - the five vertebrae between the thoracic vertebrae and the sacrum.

peritoneum - the slippery layer of cells lining the inside of the abdominal cavity which allows the digestive tract to move around during digestion.

IX. DIGESTIVE SYSTEM

digestive tract - the long tube running from the mouth to the anus, which is part of the digestive system.

palate - the roof of the mouth.

uvula - the projection from the back of the soft palate.

incisors - canines - teeth located in the front of the mouth, used for cutting and tearing food.

bicuspids - molars - teeth located at the sides and back of the mouth, used for grinding.

enzymes - chemical which change food to simple chemical nutrients.

GLOSSARY

saliva - the fluid secreted by salivary glands which serves to moisten and soften food, keep the mouth moist, and convert starches to sugars.

pharynx - (the throat) - that part of the digestive tract and the airway which is between the mouth and the oesophagus.

oesophagus - the muscular tube which transports chewed food from the pharynx to the abdomen.

pyloris - the muscular ring (valve) which separates the stomach from the duodenum and through which the food is forced by muscular contractions of the stomach.

duodenum - the first portion of the small intestine.

bile - a mixture of mineral salts stored in the gall bladder which completes the digestion of fats in the small intestines.

venous system - the system of vessels called veins which bring blood back to the heart from the capillaries.

rectum - the terminal portion of the digestive tract.

colon - the large intestine.

anus - the outlet of the digestive tract.

X. ANATOMY OF THE PELVIS AND EXTERNAL GENITALIA

pubic symphysis - the point at which the two pelvic bones join together at the front of the body.

mons pubis - the layer of fat overlying the pubic bone which becomes covered with hair at puberty.

labia major and minor - the two folds of skin which lay over the opening to the vagina.

clitoris - the mass of erectile tissue formed where the two labias join.

vagina - the canal in the female body into which the penis is inserted during intercourse and through which the baby passes out of the body.

GLOSSARY

urethra - the final tube-like structure through which urine passes out of the body.

scrotum - the external sac on the male body which contains and protects the testes.

testes - the two rounded structures contained in the scrotum which produce sperm.

vas deferens - the long tube which conducts the sperm from the testes to the urethra where it is released from the body.

prostate gland - the gland which in the male surrounds the neck of the bladder and urethra and which secretes a milky fluid into the upper end of the vas deferens.

penis - the male organ used for urination and reproduction.

XI. URINARY SYSTEM

kidney - the organ of the urinary system which actively forms urine, and thus eliminates waste products and regulates the amount of water and minerals in the body.

urine - fluid containing the excess minerals, water and waste products after most of the minerals and water have been absorbed back into the blood.

ureter - the large vessel through which the urine passes from the kidney to the bladder.

bladder - the muscular organ which stores urine and releases it when full.

urethra - the final tube-like structure through which urine passes out of the body.

XII. REPRODUCTIVE SYSTEM

sperm - special cell produced by the male testes which, when combined with the female egg, develops into the new member of the same species. Is composed of a compact head (the nucleus), a middle portion, and a tail which gives it mobility.

GLOSSARY

seminal vesicles - a hollow structure which secretes mucus into the upper end of the vas deferens.

ejaculation - the sudden expulsion (release) of semen through the urethral opening of the penis.

semen - the thick whitish secretion of the reproductive organs in the male. Consists of sperm cells, and the secretions from the prostate gland, the seminal vesicles, and various other glands.

ovum - the female reproductive cell produced and released by the ovary, which when combined with the male sperm, develops into a new member of the same species. It contains one half the information of what the developing foetus will be like.

ovary - the female sexual organ which produces the ova.

fallopian tubes - a pair of slender tubes which connect the uterus to the region of the ovaries in the female reproductive system. It is in this structure that the ovum travels after being released by the ovary and where the ovum may be fertilized by the male sperm.

fertilization - the joining together of a sperm with an ovum which results in the development of a foetus. This joining of the two parent cells determines the physical characteristics and sex of the developing foetus.

uterus - the hollow muscular organ in the female reproductive system which is the home and place of nourishment of the developing embryo and foetus. It is a pear-shaped cavity which opens into the vagina.

menstruation - the uterine bleeding which occurs approximately every four weeks during the reproductive period of the female and which is the result of the inner lining of the uterine wall being shed from the body.

endometrium - the inner surface of the uterus to which the fertilized egg attaches itself and receives its nutrition.

GLOSSARY

foetal membrane- a thin, transparent but tough membrane which attaches to the inner surface of the uterus and forms a sac which completely surrounds the egg.

amniotic sac - the fluid-filled sac formed by the fetal membrane in which the fertilized egg and later, the foetus floats and is protected from sudden movements made by the mother.

foetal- the term used to describe the developing young in the human uterus after the second month of development.

placenta - the structure in the uterus which connects the mother with the developing foetus by means of the umbilical cord. The mother's blood flows through the placenta and provides the food and oxygen necessary for the foetus' survival and growth.

umbilical cord - the structure containing vessels which is attached to both the mother and the developing foetus. Food and oxygen needed by the fetus is received from the mother's blood, and waste products formed by the foetus' metabolism pass into the mother's blood through the umbilical cord.

XIII. NERVOUS SYSTEM

involuntary (or autonomic) nervous system - that part of the nervous system which controls most of the body's internal functions. It regulates blood pressure, heart rate, respiration rate, and the internal organs of the body.

voluntary nervous system - that part of the nervous system which controls voluntary muscles, those over which we have conscious control. It regulates walking, talking, etc.

peripheral nerves - chains of long, thin cells which extend throughout the entire body, forming a spider web-like network.

sensory nerves - those nerves which carry sensations such as pain or temperature to the spinal cord.

GLOSSARY

motor nerves - those nerves which carry messages from the spinal cord to the muscles which tell them how to react.

spinal cord - the thick bundle of nerves connected directly to the brain which runs through the middle of the spinal column. It is responsible for the automatic reflexes of the body, and is the conductor of impulses to and from the brain.

reflex - a motor response that occurs automatically (without thinking) once a sensation is detected and transmitted to the spinal cord, and a message is sent back to the muscles.

cornea - the transparent outer membrane of the eye.

pupil - the opening at the centre of the iris through which light is transmitted into the eye.

iris - the circular coloured portion of the eye behind the cornea consisting of muscular fibres which control the size of the pupil, and therefore, the amount of light that passes into the eye.

retina - the layer covering the back of the eye upon which the image "seen" by the eye is projected. The retina translates the image into nerve impulses and transmits these to the brain.

taste bud - the sense receptor of taste, found in the mouth.

olfactory cell - the sense receptor of smell, found in the nose.

STUDENT GUIDE

INTRODUCTORY CONCEPTS

I. Entry Level Knowledge

Before starting this unit, you should be able to:

1. Define the words listed in the glossary as Introductory Concepts.

II. Objectives

Using the information and experiences provided by the instructor and the module text, you will be able to:

1. Describe the structural components of the human body, cell, tissue, organ, system.
2. Explain the concept internal regulation.
3. Identify and locate the general anatomical regions of the human body and the organ systems primarily contained in each.

III. Evaluation

Upon completion of the module, you will be tested on your attainment of the above objectives. Acceptable performance, 80%.

IV. Activities you will be participating in to accomplish the unit objectives:

1. Read the module text on Introductory Concepts and answer review questions.
2. Write at least one of your own questions about introductory concepts to share with the group during discussion sessions.
3. View and discuss audio-visual presentation on cells and tissues.
4. Draw a diagram of different types of cells - red and white blood cells, epithelial cells, muscle cells, connective tissue and nerve cells.

20

INTRODUCTORY CONCEPTS

The human body is a well-integrated machine. It has many parts, each of which performs a different function. Working together, they produce a very complex orga m, the human body.

The building block of the human body is the *cell*. The entire body is composed of millions of small living structures. Each of these little cells has a specialized function. The cells in the kidney, for example, are specialized for producing urine as needed to clean waste from the blood stream. Cells with the same functions join together in groups and form *tissues*. Kidney cells, for instance, are joined together to form blocks of kidney tissue. In addition, tissues are joined together to form *organs*. The whole kidney is an example of an organ. It has its own blood supply and specific function. The two kidneys plus the ureters, the bladder and the urethra act together as a unit and are referred to as a system. the urinary system.

All of the body's systems work together to keep conditions inside the body (the internal environment) more or less constant. The conditions include such factors as temperature, chemical makeup, blood pressure, etc. The regulation of the internal environment through changes in the functions of the various body systems is referred to internal body regulati n.

In the course of working with this module on Anatomy and Physiology, you will study the structure and function of the body systems. It will help your understanding the material if you keep the necessity of internal body regulation in mind during your study.

Cells

The simplest functioning unit of life is the cell. It is not only the structural and functional unit of the human body, but it is also the basic target of many diseases.

There are four vital functions which cells are able to perform:

1. metabolism
2. growth
3. irritability and adaptability
4. reproduction

Metabolism refers to the ability of cells to take in nutrients (just as the body uses food), digest them, mix them with gases to produce energy, and excrete the waste products. Growth refers to the ability of cells to increase in size and number, and to go through a life cycle like people. They begin as small cells, enlarge and mature into specialized units, then age, and finally die. By irritability and adaptability, it is meant that cells are able to respond to changes in their environment. Irritability refers to the short-term immediate response to changes, much in the same way you respond to a sudden rain by seeking shelter under a tree. Adaptation on the other hand, refers to changes in cells over many generations to improve their ability to live in their environment. This process is termed evolution. The final property of cells is reproduction, the ability to make more of themselves.

The cell is a mass of living matter surrounded by a membrane. The cell membrane acts as a barrier between the cells and its environment. It is the route by which food and gases are taken into the cell, wastes are excreted, and products of cell metabolism are released. Usually in the centre of each cell is a membrane-bound structure called the nucleus. It passes the information of the cell from one generation to the next. It is necessary for cell division, the process by which cells reproduce, and in the production of proteins, the building blocks of all living things.

Between the nucleus and the cell membrane is a jelly-like substance called cytoplasm. This contains the rest of the living substances of the cell.

Tissues

Since the functions of the human body are so complex, one cell is not capable of performing all of them. Consequently, cells have been grouped into units called tissues, which perform only a few of these functions. The cells in each tissue have their own specialized structure which better enables them to perform their functions. There are four basic tissues:

1. muscle
2. nerve
3. epithelium
4. connective

The purpose of the muscle tissue is to produce movement. Voluntary muscles are the muscles over which you have control, such as the muscles in the arms and legs. Involuntary muscle is found in organs whose movement you cannot control, such as the blood vessels and the stomach. Cardiac muscle is the muscle of the heart. It also is an involuntary muscle and has the property of rhythmically contracting by itself.

Nervous tissue allows the various organs of the body to communicate with each other and with the environment. This tissue is constructed to allow impulses pass from one part of the body to another part of the body.

Epithelial tissue lines all the surfaces of the body. It acts as the boundary between the body and its environment and between one organ and another. It is structured to provide protection, to secrete, or to allow absorption. Depending on where they are located, epithelial cells may range in shape from thin, flat, plate-like cells of skin, to the tall, columnar cells of the gut.

Connective tissue, including cartilage, fat, fibrous and elastic tissue, act to physically bind all of the parts of the body together.

Organs and Organ Systems

The ability to perform a large number of different activities is necessary to maintain life. In the human body, each activity is carried out by a separate distinct entity, called an organ. Organs are groups of tissues brought together to perform a specific function. Usually cells of one tissue make up the majority of the organ, and cells from the other tissues help to support it. In the case of a muscle, most of the organ is muscle tissue, but it also contains blood and other connective tissue and nervous tissue. The stomach, another organ, contains living epithelial tissue, connective tissue, muscle tissue and nervous tissue.

All the organs with similar specialized functions are grouped together as systems. This module will discuss nine major organ systems of the body in terms of their roles in the body and the structures that compose them.

The skin has important functions in the body. As the outside barrier of the body, the skin protects the other organs from injury and prevents their dehydration.

The skin also acts as an excretory organ by carrying away waste products through sweating. Sweating also helps to regulate body temperature by cooling the skin through evaporation.

The skeletal system is the main supportive framework of the body. All the other organ systems are attached to the bones. Since they are composed of very hard tissue, the bones also function to protect the softer parts of the body.

The muscular system makes up the flesh of the human body. The main role of the muscles is to move the body by moving the bones at their joints. The circulatory or cardio-vascular, system consists of the heart and all the blood vessels. Its role is to transport, deliver and remove substances used by the cells for metabolism. The blood, which flows in the vessels is pumped by the heart, acts as the carrier for these substances.

The circulatory system is the transport system of the body. The heart (a pump) moves blood through a series of tubes called arteries and veins. The blood contains gases and nutrients necessary for cell metabolism.

The respiratory system removes oxygen from the air and, through the lungs, directs it into the blood. It also removes carbon dioxide from the blood and returns it to the air. Each time you breathe in, oxygen is taken into the body. Each time you breathe out, carbon dioxide is removed.

The function of the digestive system is to acquire, break down, and absorb food, and then to eliminate from the body what remains in the system. The digestive system is a hollow tube which begins at the mouth and ends at the anus. The walls of the tube are the sites of digestive functions.

The urinary system functions to cleanse the blood of most of the waste produced by metabolism. The kidney is the organ which filters the waste substances out of the blood. A series of tubular organs then carry the filtered material to the outside of the body.

The reproductive system functions in producing children. It includes the organs which contain the cells from which new life is made and the tubular organs which care for the cells and the young foetus.

The nervous system integrates the functions of all the systems. It also monitors signals from the environment and produces the responses to these signals.

Internal Regulation

The body is able to regulate itself and maintain itself in a relatively stable condition. The internal environment of our bodies must function within narrow limits. Regulation is therefore essential. Many mechanisms operate to assure this regulation.

For example, the internal temperature of our body is constantly held at around 37°C. This is accomplished by several temperature-regulating mechanisms. The most important is perspiration (sweating). When we perspire, thousands of tiny droplets form on the skin. As these droplets evaporate (dry) heat is lost and the body is cooled.

Some factors which are being constantly regulated and the mechanisms which regulate them are:

Factor	Regulating Mechanism
1. Temperature	perspiration decreased activity → cooling
	shivering increased activity → heating
2. Water content in the blood	thirst →← drinking urine formation
3. Blood pressure	heart rate constriction or dilation of blood vessels
4. Waste products	urine formation faeces
5. Food content in the blood	hunger →← eating storage and release of sugar from liver storage and release of fat

There are many other mechanisms related to internal regulation in addition to those listed above. In fact, every function of our bodies can be looked upon as contributing to the maintenance of a constant internal environment.

Regions of the Body (See Figure AP 1)

For the purpose of further study, the human body must be divided into separate regions. The following is a brief review of them.

The head consists of the skull and the lower jaw. The skull contains the brain. The face has the openings for the respiratory and digestive systems and the extensions of the nervous system by which we hear (ears), see (eyes), smell (nasal cavity), and taste (tongue).

The head rests on the neck. Through this region pass portions of the digestive and respiratory systems en-route to the trunk. Also large blood vessels of the circulatory system carry blood to and from the brain through the neck. The posterior portion of the neck contains the upper portion of the bony vertebral column. The vertebral column supports the head and carries within it an extension of the nervous system, the spinal cord.

The thorax is the region which lies below the neck. Its upper limit is just below the clavicle (collar bone) and its lower limit is the lower edge of the rib cage. Internally, it is a hollow cavity. It contains primarily the respiratory and circulatory systems. The walls of the thoracic cavity are formed by the thoracic portion of the bony vertebral column in back, and the ribs and muscles on the sides and front. The breast bone, or sternum, joins the ribs in front.

The abdomen, another large cavity, extends from the rib cage to the upper edge of the hip bones in front and back. It contains most of the digestive system and part of the urinary system. Its walls are made up of sheets of muscles attached to the third or lumbar portion of the vertebral column in back, the ribs above, and the hip bone below.

The cavity within the hip bone is the pelvis. The organs of the reproductive system, and the rest of the urinary and digestive systems are located here.

Below the pelvis is the region into which the digestive, reproductive and urinary systems open. This is called the perineum.

The two pairs of limbs are referred to as extremities. The arm joins the shoulder at the shoulder joint. The lower arm joins the upper arm at the elbow. The hand joins the lower arm at the wrist. The areas enclosed by the arm, shoulder and thorax is the axilla, or arm pit.

The lower extremity attaches to the pelvis at the hip joint. In back, this area is called the buttock, on the sides, the hips, and in front, the pubis. The area between the buttock and the pubis is called the perineum. The thigh attaches to the pelvic bone at the hip. The leg joins the thigh at the knee. The foot attaches to the leg at the ankle.

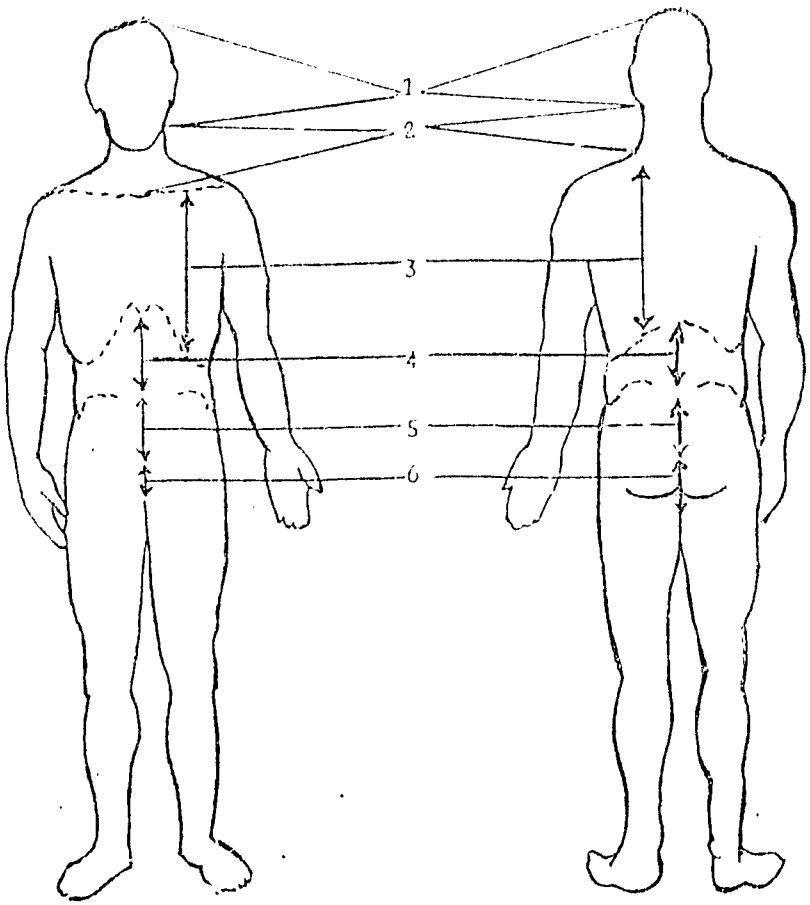

Figure AP 1 - Regions of the Body: 1) Head consists of the skull to lower jaw; 2) Neck; 3) Thorax, from the clavicle to the lower edge of the rib cage; 4) Abdomen, from the rib cage to the upper edge of the hip bones; 5) Pelvic cavity; 6) Perineum.

REVIEW QUESTIONS

1. What are the four (4) vital functions which cells are able to perform?

   1)

   2)

   3)

   4)

2. The nucleus of the cell is vitally important in

   _____ and _____ .

3. The four (4) basic tissues each have specific functions to perform. Match the tissue with their functions below:

____ a. muscle	1. to bind the parts of the body together
____ b. nerve	2. to produce movement
____ c. epithelium	3. to serve as boundary between body and environment
____ d. connective	4. to allow passage of impulses between body organs.

4. Organs are groups of _____ brought together to perform specific functions.

5. Name the nine (9) organ systems of the body.

1)	4)	7)
2)	5)	8)
3)	6)	9)

6. What are some of the factors that the body is constantly regulating, and what are the regulating mechanisms for each?

Factors	Regulating Mechanisms
a.	a.
b.	b.
c.	c.
d.	d.
e.	e.

7. Define the following terms:

metabolism:

irritability:

adaptation:

nucleus:

system:

internal regulation:

8. Label the general regions of the body on the diagram below, and name the organ systems primarily contained in each.

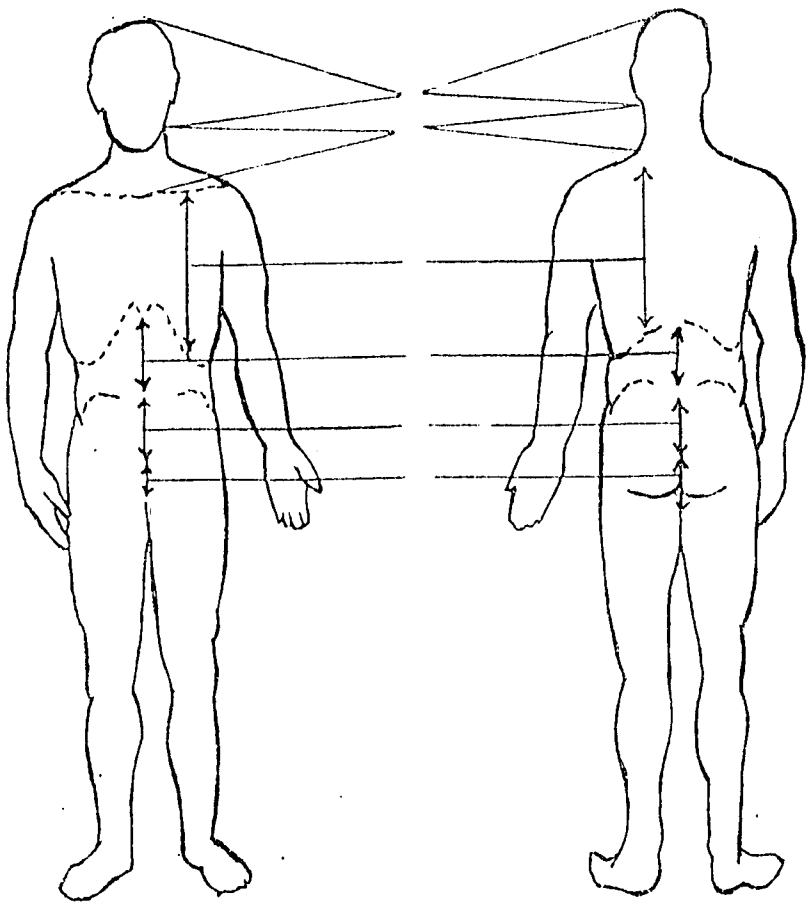

Figure AP 2 - Regions of the Body: For review question 8.

STUDENT GUIDE

SKIN

I. Entry Level Knowledge

Before starting this unit you should be able to:

1. Define the words dermis, epidermis and sweat as given in the glossary.

II. Objectives

Using the information and experiences provided by the instructor and the module text, you will be able to:

1. Define the functions of the skin.

2. Identify, describe and locate the structures of the skin on a diagram or model.

III. Evaluation

Upon completion of the module you will be tested on your attainment of the above objectives. Acceptable performance, 80%.

IV. Activities you will be participating in to accomplish the unit objectives:

1. Read the module text on the skin and answer review questions.

2. Write at least one of your own questions about the skin to share with the group during discussion.

3. Use models and charts to familiarize yourself with the anatomy of the skin.

4. Draw and label a diagram of the skin.

SKIN

Functions

The skin has many important functions. Its most obvious function is to serve as a covering for the body, as well as to keep germs from entering the body. The skin also plays an important role in regulating body temperature. When the body gets too hot, the sweat glands in the skin release salt-containing moisture called sweat. The sweat then evaporates off the skin which helps to cool the body down. The skin also has special receptors which can sense hot and cold, as well as pain and pressure. Therefore, the skin is important in letting the body know what conditions are like in the outside world.

Structure

The skin is made up of two layers, the epidermis and the dermis. The outside layer is called the epidermis. The outside rows of this layer is made up of dead cells. This is the layer which thickens where the skin must be extra tough, such as on the palms of the hands and the soles of the feet. There are no blood vessels in this layer.

The layer of skin which lies under the epidermis is called the dermis. This layer is made up of living cells, blood vessels and nerves. Oil glands and sweat glands are also found in this layer. As the cells from the dermis die, they slowly move up into the epidermis. The dermis is therefore continually supplying cells to the epidermis. (Figure AP 3)

Skin Structures

There are two structures which arise from the skin. These are hair and nails. Various armounts of hair cover the human body. Hair is not very important in keeping the body warm. Rather, it is useful for sensing when the skin is being touched, or is touching something very lightly.

The nails at the ends of the fingers and toes arise from the top layer of skin. The nails are a pinkish colour because of the large number of small blood vessels which are directly under them. There are also many nerves which lie under the nails.

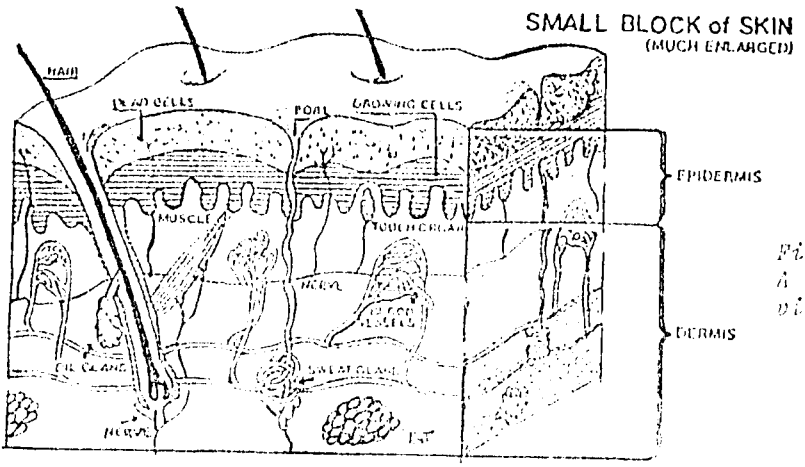

Figure AP 3 - Skin. A cross-sectional view of the skin.

REVIEW QUESTIONS

1. Explain the role than skin plays in regulating body temperature.

2. Which of the following is <u>NOT</u> contained in the inner layer of skin?

   a. nerves
   b. blood vessels
   c. sweat glands
   d. dead cells
   e. oil glands

3. Define the following terms:

   sweat:

   epidermis:

   dermis:

STUDENT GUIDE

SKELETAL SYSTEM

I. Entry Level Knowledge

Before starting this unit, you should be able to:

1. Define the words listed in the glossary pertaining to the skeletal system.

II. Objectives

Using the information and experiences provided by the instructor and the module text, you will be able to:

1. Define the function of the skeletal system.
2. Describe the structures of the skeletal system.
   a. Describe the structure of bone.
   b. Identify the types of joints and give an example of each.
3. Identify and locate the component parts of the skeletal framework.

III. Evaluation

Upon completion of the module, you will be tested on your attainment of the above objectives. Acceptable performance, 80%.

IV. Activities you will be participating in to accomplish the unit objectives:

1. Read the module text on the skeletal system and answer review questions.
2. Write at least one of your own questions about the skeletal system to share with the group during discussion.
3. View and discuss slide presentation about the skeletal system.
4. Work in groups to practice identification of bones and joints using charts and other available visual aids.

SKELETAL SYSTEM

Functions

The human skeletal system has some very important functions. The main function is to support the rest of the body. Muscles are attached to the bones and the bones act as levers moving one way or the other as muscles stretch or contract. In addition to being important for support and movement, certain sets of bones function to protect delicate parts of the body. For example, the bones in the head protect the soft brain from damage. The soft centres of many of the bones in the body produce red and white blood cells which leave the bones after they are formed and enter the blood stream. Bones also store minerals which can be released into the blood stream if they are needed by the body.

Structure

The skeletal system is a framework of the bones in the body attached to each other by joints.

Bones

Bones are classified according to their shapes. Our body contains four basic shapes of bones. Those are long bones, short bones, flat bones, and irregular bones.

Long bones are in the upper and lower arms and legs. Short bones are often cube-shaped. Groups of these cube-shaped short bones are in the ankles and wrists. Flat bones fuse together to form the skull. Irregular bones make up the spinal column (Figures AP 4, 5, 6, 7).

Figure AP 4 - Skeletal System: Long bones of the upper and lower arm and cube-shaped, short bones of the wrist.

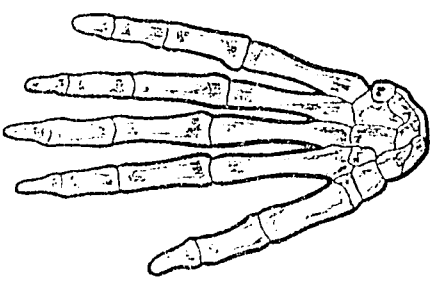

Figure AP 5 - Skeletal System: A closer look at the cube-shaped, short bones of the wrist.

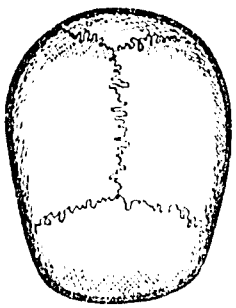

Figure AP 6 - Skeletal System: Flat bones of the skull.

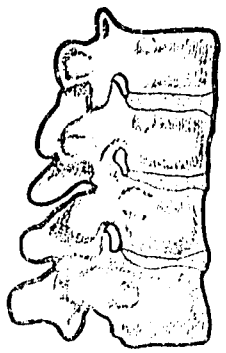

Figure AP 7 - Skeletal System: Irregular bones of the spinal column.

In looking at a long bone, two parts become obvious - the enlarged ends and the long narrow shaft. These long bones grow in length until the person is approximately twenty years of age by the addition of material on the enlarged ends. The shaft itself does not actively grow. Yet, it is able to repair itself if it is broken.

Remember that bones are living structures. The centres of bones are filled with a red and yellow fatty material called marrow. It is in this marrow that the red and white blood cells are formed. Living bones are covered by a dense fibrous material. This layer is very important because muscles attach to these fibres. These fibres in turn are attached to bone. Within the hard shafts of bones are many living bone cells which are continually removing and depositing the minerals which make the bone hard. (Figure AP 8)

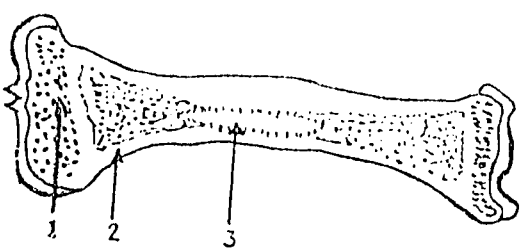

Figure AP 8 - Skeletal System: This cross section of the bone shows: 1) Red Marrow; 2) Hard Bone; 3) Yellow Marrow.

Joints

Bones are attached to other bones by joints. Bones which act as levers and are used for movement are attached by movable joints. There are several types of movable joints. Joints which allow the greatest amount of movement are found in the shoulders and hips and are called ball and socket joints. Some joints only move in one direction. These are called hinge joints. Examples of this type of joint can be found in the elbows and knees. There are also pivot joints in which one bone rotates on another bone. A pivot joint is used in turning one's head from side to side.

Some bones that are attached to each other are not freely movable. One type of joint between these bones is a partially-movable joint. An example can be found in the attachment of the ribs to the spine. The other type of joint between the bones is the immovable joint. An example of this type of joint is the skull, where bones have fused together in early childhood. (Figures AP 9, 10, 11)

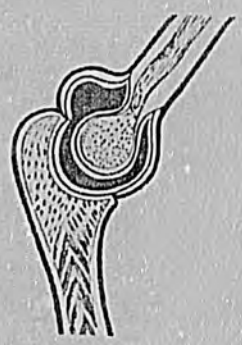

Figure AP 9 - Skeletal Syste : This elbow hoint is an example of a hinge joint.

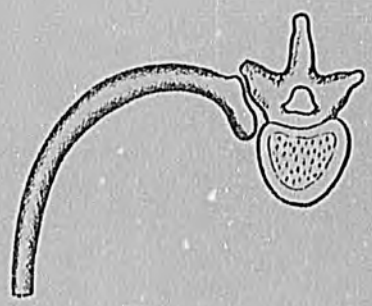

Figure AP 10 - Skeletal System: Where a rib attaches to the spine is an example of a partially movable joint.

Figure AP 11 - Skeletal System: The bones of the skull form immovable joints.

The Skeleton

The framework of bones, the skeletal system, is divided into two parts. The skull, spinal column, ribs and breastbone make up the trunk part of the body. The other part of the skeletal system is made up of the arms, legs, shoulder area and hip area.

The skull is made up of flat bones which protect the brain, and fourteen facial bones. Slight differences in these facial bones are largely responsible for giving each person a unique facial appearance.

The spine is made up of small irregular bones called vertebrae. Between each vertebrae is a small pad of soft material called a disk which acts as a cushion between the bones. The spine has twelve pairs of ribs attached to it. It also supports the head.

The shoulder area is that part of the skeleton where the arms attach to the shoulder. It is made up to two clavicles (collarbones) and two scapulae (shoulder blades). The arm has two portions - an upper arm which contains the humerus, and a lower arm which contains the ulna and radius bones. The wrist has eight carpal bones. The hand has five metacarpal bones. The five fingers contain fourteen bones called phalanges.

Just as the arms attach to the shoulder girdle, so the legs attach to the pelvic girdle. The pelvis is made up of the ilium, ischium, pubis, sacrum and coccyx bones. The leg is similar to the arm in that there is an upper leg which contains the femur, and a lower leg which is made up of the tibia and fibula bones. The ankle has seven tarsal bones. The foot has five metatarsal bones. The five toes contain fourteen bones called phalanges. (Figure AP 12)

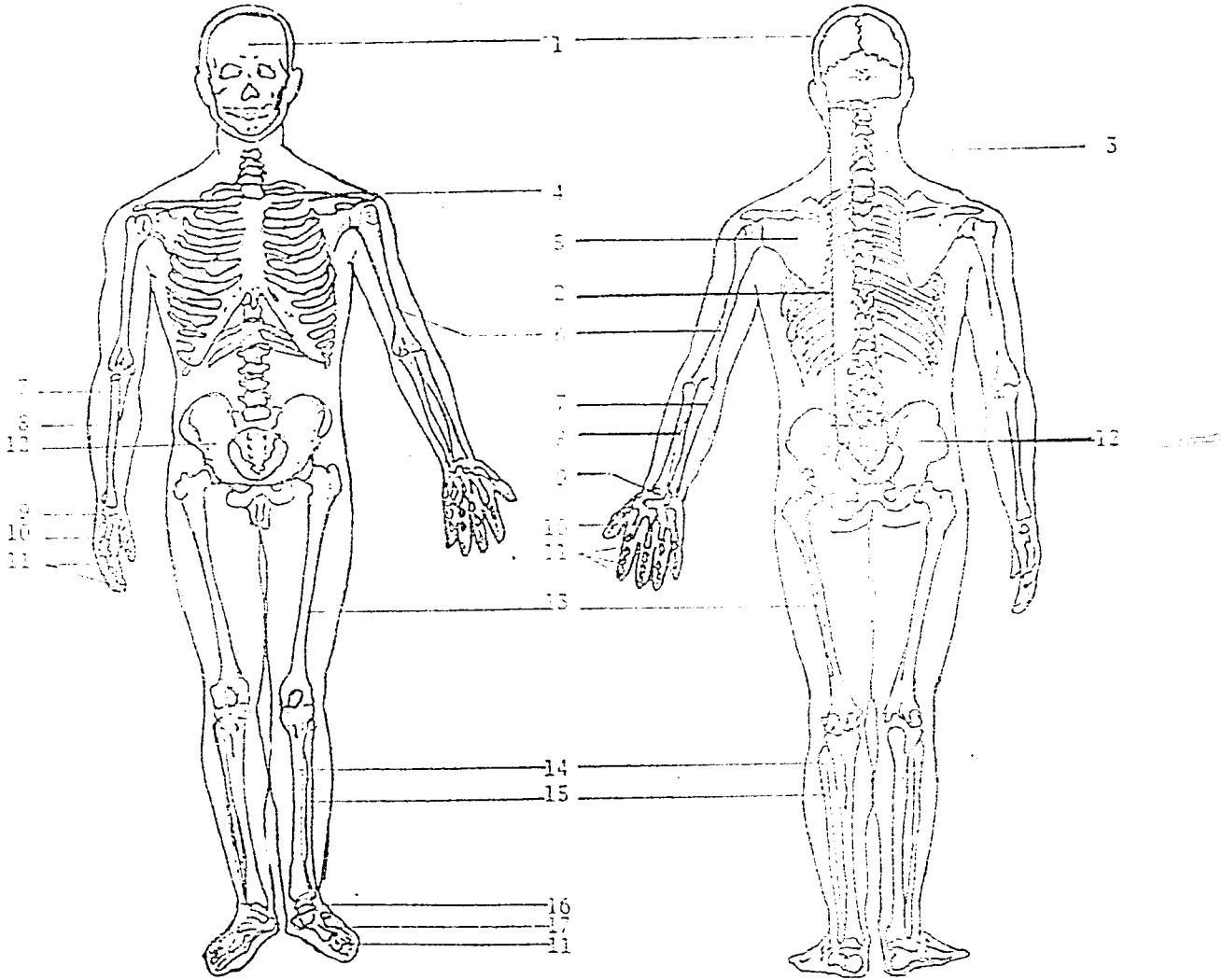

Figure AP 12 - Skeletal System: 1) Skull; 2) Spine; 3) Vertebrae; 4) Thoracic; 5) Scapula; 6) Humerus; 7) Ulna; 8) Radius; 9) Carpal Bones; 10) Metacarpal Bones; 11) Phalanges; 12) Pelvis; 13) Femur; 14) Tibia;

REVIEW QUESTIONS

1. What are the five (5) functions of the skeletal system?

   1)

   2)

   3)

   4)

   5)

2. Bones are attached to other bones by joints. The type of joint which allows for the greatest amount of movement is called a/an _____ joint. The type which is least movable is called a/an _____ joint.

3. Define the following terms:

   marrow:

   disc:

   humerus:

   femur:

   phalanges:

4. Label the skeletal parts of the diagram below.

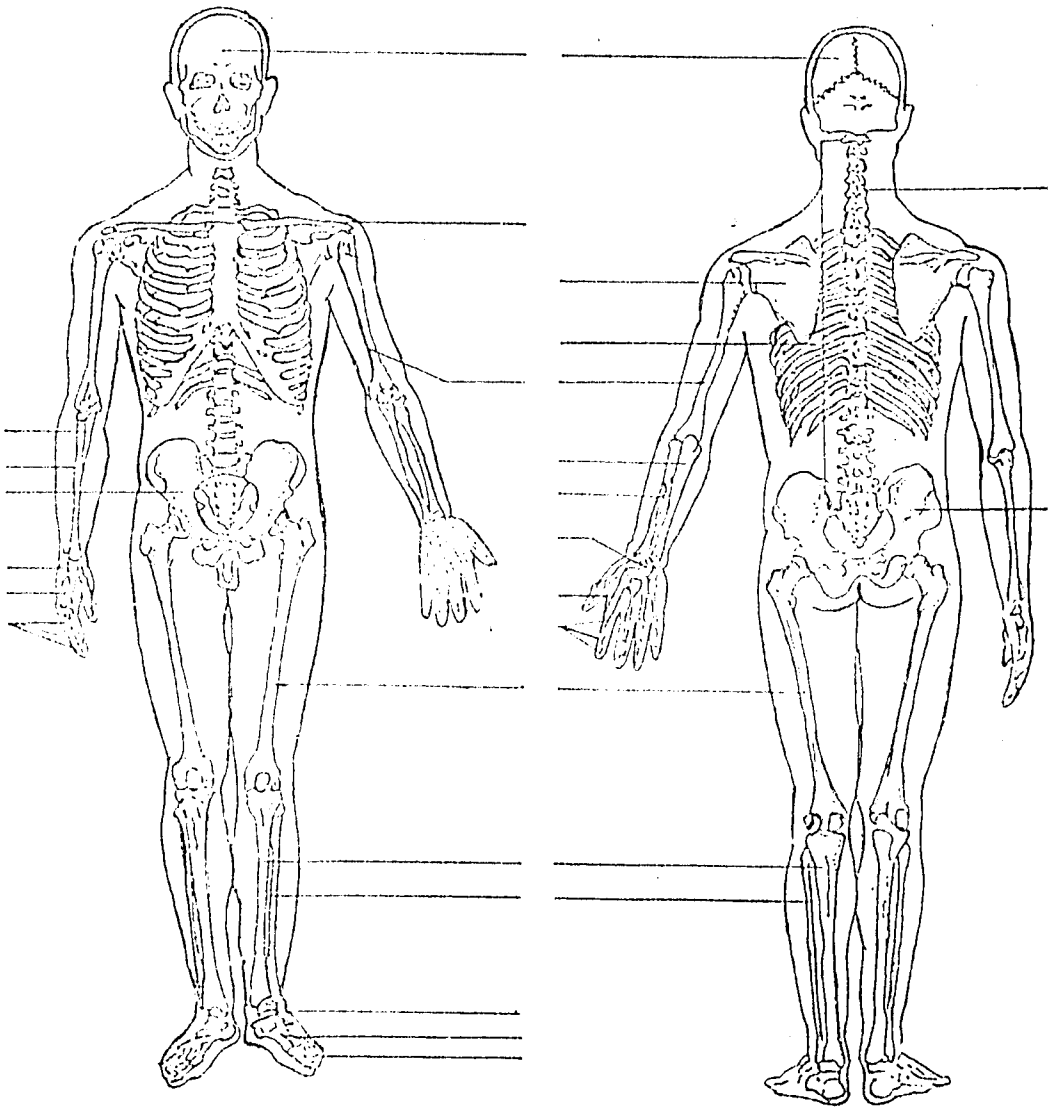

Figure AP 15 - Skeletal System: For review question 4, number each line with the number of the bone the line points to. Some numbers will be repeated. 1) Skull; 2) Spine; 3) Vertebrae; 4) Clavicle; 5) Scapula; 6) Humerus; 7) Ulna; 8) Radius; 9) Carpal Bones; 10) Metacarpal Bones; 11) Phalanges; 12) Pelvis; 13) Femur; 14) Tibia; 15) Fibula; 16) Tarsal Bones; 17) Metatarsal Bones.

STUDENT GUIDE

MUSCULAR SYSTEM

I. Entry Level Knowledge

Before starting this unit, you should be able to:

1. Define the words listed in the glossary pertaining to the muscular system.

II. Objectives

Using the information and experiences provide by the instructor and the module text, you will be able to:

1. Identify the three types of muscles in the muscular system and give examples of each.
2. Describe the structure of skeletal muscle and its attachments.
3. Explain the relationship between the skeletal and muscular systems.

III. Evaluation

Upon completion of the module, you will be tested on your attainment of the above objectives. Acceptable performance, 80%.

IV. Activities you will be participating in to accomplish the unit objectives:

1. Read the module text on the muscular system and answer review questions.
2. Write at least one of your own questions about the muscular system to share with the group during discussion.
3. Students work in groups to practice movements:
   a. Demonstration and identification of different movements described in the module text.
   b. Name the skeletal components affected by muscle movements.
4. Review wall charts and other visual material.

MUSCULAR SYSTEM

Function and Structure

Bones and joints do not move by themselves. They are dependent upon a special type of muscle called the skeletal muscles for movement. Since these muscles can be moved when desired, they are called voluntary. Besides their function in movement, skeletal muscles are important in keeping the body in various positions by stabilizing bones and joints through their constant state of partial contraction.

Another type of muscle forms the walls of many of the internal organs, such as the stomach and intestines. These muscles are called involuntary muscles because they cannot be forced to move at will. However, when there is a job to be done, the muscles will move. For example, when the stomach is filled with food, these muscles will begin to expand and contract to help break down the food.

A third type of muscle, cardiac muscle, is only found in the heart. This muscle is also involuntary since it expands and contracts at its own rate.

The rest of this chapter will be concerned with the skeletal muscles since involuntary and cardiac muscles will be discussed in the chapters on the Digestive and Circulatory systems.

Attachments

Skeletal muscles are formed from bundles of muscle fibres. It is really all of these small fibres contracting together which causes a muscle to shorten. At both ends of the muscle, the fibres join to become a strong white cord called a tendon. These tendons are the portion of the muscle that attaches to the bones. When a muscle is attached to two bones and contracts, one bone moves more than the other. The point of muscle attachment to the bone which moves the most is called the insertion, and the point of attachment which moves least is called the origin. Besides attaching to bones, muscles can also attach to skin and tendons of other muscles. (Figures AP 14 and 15)

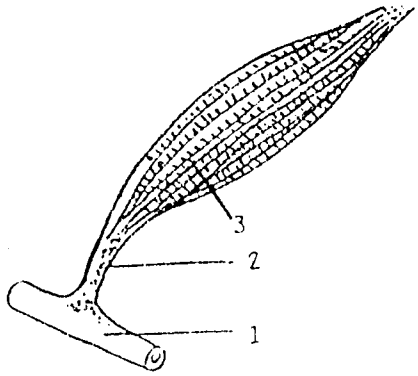

Figure AP 14 - Muscular System: 1) Bone; 2) Tendon; 3) Muscle.

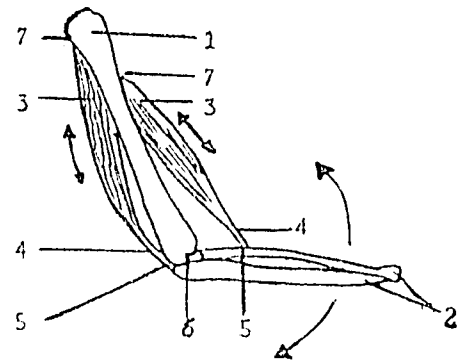

Figure AP 15 - Muscular System: 1) Fixed bone; 2) Moving Bones; 3) Muscles; 4) Tendons; 5) Insertion; 6) Joint; 7) Origin. Arrows indicate movement of muscle and bone.

Movement

Because there are various types of joints and because muscles attach to bones at different locations, the body can move in many directions.

When a muscle, which has each end attached to a different bone, shortens, the two bones move closer to each other and flexion is said to have taken place. Flexion is the movement which bends a joint. Flexion of the fingers would occur by closing an outstretched hand into a clenched fist.

Opening the fist and straightening the fingers is an example of extension. Extension, then is straightening out and causing the two bones which are attached by a joint to move away from each other.

REVIEW QUESTIONS

1. The portion of the muscle that attaches to the bone is the _____.

2. The point where a muscle attaches to the bone and moves least is called the _____.

3. Match the basic movements with their appropriate terms:

____ a.	the movement which straightens a joint	1. flexion
____ b.	the movement which bends a joint	2. extension

4. Define the following terms:

insertion:

voluntary muscle:

involuntary muscle:

STUDENT GUIDE

THORAX

I. Entry Level Knowledge

Before starting this unit, you should be able to:

1. Define the words listed in the glossary referring to the anatomy of the thorax.

II. Objectives

Using the information and experiences provided by the instructor and the module text, you will be able to:

1. Describe the structural components which make up the thorax.
2. Identify the organ systems contained within the thorax.

III. Evaluation

Upon completion of the module, you will be tested on your attainment of the above objectives. Acceptable performance, 80%.

IV. Activities you will be participating in to accomplish the unit objectives:

1. Read the module text on the thorax and answer review questions.
2. Write at least one of your own questions about the thorax to share with the group during discussion.
3. Review slide on structure of thorax.
4. Review the wall and human models and charts to identify the structural land marks of the thorax.
5. Practice identification of thoracic landmarks on fellow students.

ANATOMY OF THE THORAX

The thorax forms a cavity which contains the heart and lungs. The heart is the major organ of the circulatory (cardiovascular) system. The lungs are the major organs of the respiratory system. The thorax extends from the base of the neck above to the lower edge of the rib cage below. The wall of the thoracic cavity consists of skin, muscles of respiration, and a bony framework.

The bony framework of the thorax consists of ribs, the sternum and thoracic vertebrae. The sternum, or breast bone, is located in the centre of the front of the chest. The upper end of the sternum forms a depression, the jugular notch, at the base of the neck. About one inch below the notch is an important landmark, the sternal angle, which is a raised area caused by the joining of two parts of the sternum. The sternal angle is about even with the second intercostal space. This knowledge provides the basis for locating other structures in the thoracic regions. The lower portion of the sternum is called the xiphoid process. (See Figure AP 16.)

Most of the front, sides and back of the thorax is formed by 12 pairs of ribs. The ribs are attached to the sternum by movable bands of tissue, the costal cartilages. The space between each rib is filled with respiratory muscles. It is in these spaces that heart sounds and breath sounds are heard.

All arteries, veins, nerves, and other structures passing between the thorax and the head pass through an opening formed by the first ribs, the sternum, and the first thoracic vertebra. The lower end of the thorax is surrounded by the 12th. pair of ribs, the 12th. thoracic vertebra, the costal cartilages of the seventh through tenth pairs of ribs and the tip of the sternum. This area is closed over a dome-shaped sheet of muscle, the diaphragm. This is a primary respiratory muscle. Its contraction causes a vacuum to form in the thoracic cavity which draws air into the lungs.

The scapula (2 wing-shaped bones) in the upper back of the thorax are a part of the shoulder area. The cover the outer portions of the upper ribs.

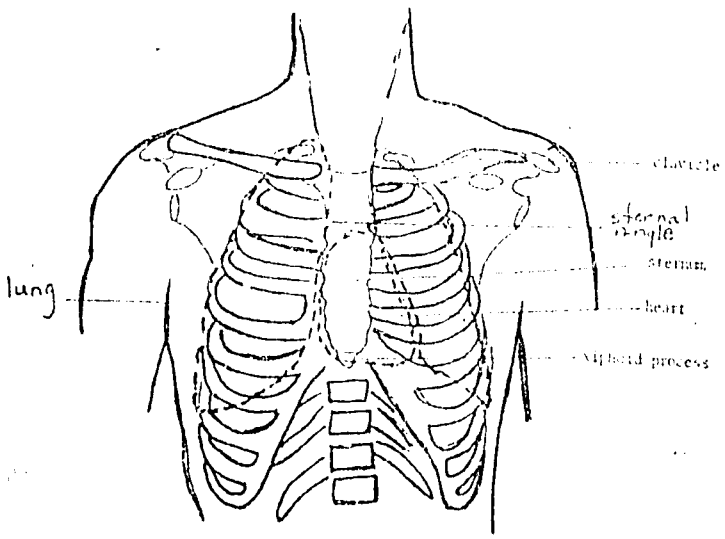

Figure AP 16 - Bony A
Anatomy of the Chest: Anterior

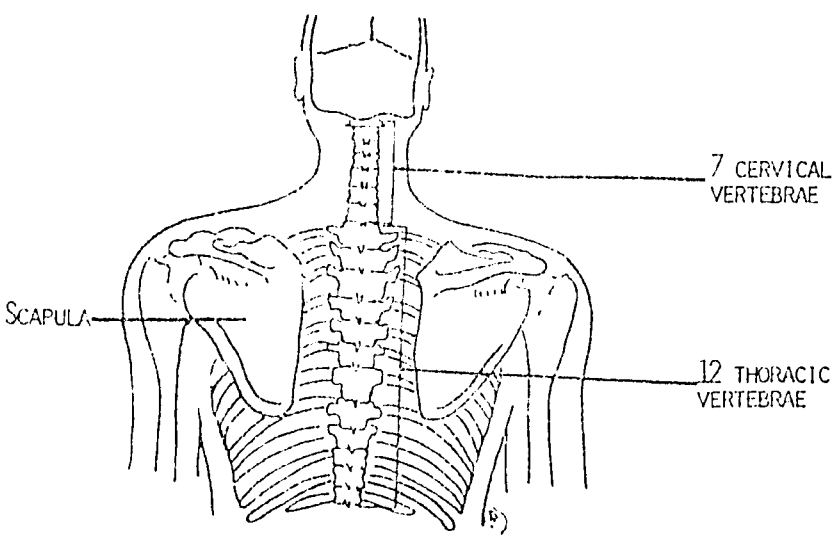

Anatomy of the Chest: Posterior

REVIEW QUESTIONS

1. Define the boundaries of the thoracic cavity.

2. What two (2) organ systems does is primarily contain?

   1)

   2)

3. The bony framework of the thorax consists of _____ and _____ .

4. The _____ is an important landmark because it is about even with the second intercostal space and therefore provides the basis for locating other structure in the thoracic region.

5. There are _____ pairs of ribs attached to the sternum by movable bands of tissue called _____ .

6. Define the following terms:

   jugular notch:

   intercostal space:

   diaphragm:

STUDENT GUIDE

CIRCULATORY SYSTEM

I. Entry Level Knowledge

Before starting this unit, you should be able to:

1. Define the words listed in the glossary pertaining to the circulatory system.

II. Objectives:

Using the information and experiences provided by the instructor and the module text, you will be able to:

1. Define the function of the circulatory system.
2. Describe the structures of the circulatory system: heart, blood vessels.
3. Explain the relationship between the three types of circulation included in the circulatory system: systemic, pulmonary, and lymphatic.

III. Evaluation:

Upon completion of the module you will be tested on your attainment of the above objectives. Acceptable performance, 80%.

IV. Activities you will be participating in to accomplish the unit objectives:

1. Read the module text on the circulatory system and answer review questions.
2. Write at least one of your own questions about the circulatory system to share with the group during discussion.
3. View and discuss slides on the circulatory system.
4. Using the prepared outline of the human figure, draw in the heart and lungs and distinguish between systemic and pulmonary circulation using different coloured pens.

50

CIRCULATORY SYSTEM

Function

The circulatory system is the transport system of the body. Its function is to move the blood, which contains the gases and nutrients necessary for metabolism, to and from the cells. The components of the circulatory system are the blood, a series of tubes called vessels, and a pump, the heart. Another name for this system is the cardiovascular system where "cardio" means heart and "vascular" refers to the vessels.

Structure

Three general categories of vessels are present in this system. Arteries are vessels which carry bleed away from the heart. They are thick-walled in order to withstand the high pressure necessary to move large volumes of blood through the body. Those vessels which carry blood toward the heart are called veins. The third category of vessels are the capillaries. Capillaries have very thin walls. Their function is to allow portions of the blood nutrients and gases to pass through the walls and out of the tubular system to reach the cells, and for wastes to pass back in.

There are three types of circulation in the circulatory system.

a. The systemic circulation carries oxygenated blood (blood saturated with oxygent) and nutrients to the cells and brings unoxygenated blood (blood containing carbon dioxide and cellular wastes, but no oxygen) back to the heart.

b. The pulmonary circulation carries unoxygenated blood to the lungs and brings oxygenated blood back to the heart.

c. The lymphatic circulation collects excess fluids from around cells and returns it to the veins of the systemic circulation.

The Blood

The blood is the transport medium of the cardiovascular system. It is about 55% fluid or plasma, and 45% cells. The cells are suspended in the plasma and the two parts flow through the vessels together. About 8% of body weight is blood.

The plasma is composed primarily of water with some protein, minerals and other organic materials. The plasma proteins remain within the capillaries and aid in preventing too much water from leaking into the spaces around the cells. The proteins also aid in forming the clots produced to stop the bleeding when a blood vessel is cut. The organic and inorganic substances in the plasma are the source of nutrients for the cells. They pass easily through the walls of the capillaries and are easily absorbed by cells. Some of these substances in the blood are waste products of the cells which are absorbed by the capillaries.

There are several formed elements in the blood. The red blood cells are the most numerous. They contain a substance called haemoglobin, which gives them their red colour. Red blood cells carry oxygen from the lungs to the rest of the body.

The other formed elements of the blood are the white blood cells and platelets. The white cells are the disease-fighting cells of the blood in the body. Some white blood cells attack disease agents by surrounding them and digesting them. Other white blood cells destroy the agents by secreting toxic substances called antibodies which kill or destroy germs or poisons in the body. Platelets are fragments of cells which are very active in the clotting of blood.

The Heart

The heart is a muscular organ lying behind and just to the left of the sternum. It is the pump for the circulatory system. Blood is forced through the vessels by the pumping action of the heart. It actually functions as two pumps - one for the pulmonary circulation and the other for the systemic circulation.

The heart is divided into a right and left half by a muscular wall. Each half is divided into two chambers, the upper called the atrium and the lower called the ventricle. (Figure AP 17)

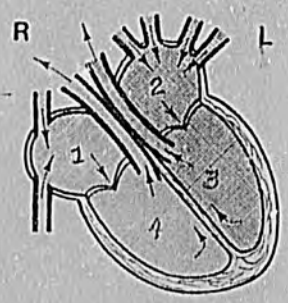

Figure AP 17 - Heart:
1) Right Atrium;
2) Left Atrium;
3) Left Ventricle;
4) Right Ventricle.

Blood returning to the heart from the body enters the right upper chamber or the right atrium. When the right atrium contracts, the blood is forced through the valve into the lower right chamber or the right ventricle. When the ventricle is full, the valve closes. The contraction of the right ventricle forces the blood from the right ventricle through the pulmonary valve into the pulmonary artery which carries the blood to the lungs. This blood, which has been returned to the heart after being circulated through the body, is loaded with cellular waste products and carbon dioxide. When it enters the lungs, the red blood cells are recharged with oxygen and the carbon dioxide is removed. (Figure AP 17)

Oxygeneated blood returning to the heart from the lungs enters the left upper chamber or the left atrium from the pulmonary veins. The left atrium then contracts and forces the blood through a valve into the left ventricle. Contraction of the left ventricle forces the oxygenated blood through the aortic valve into the arteries which will circulate it throughout the body, carrying oxygent and nutrients to the tissues and absorbing the waste products from the tissues. (Figure AP 18)

The four chambers of the heart are made up of a special kind of muscle or myocardium which is found only in the heart. It is peculiar because it contracts regularly without stimulation. All the myocardial cells contract together, first both atria and then both ventricles.

Heart sounds result from the closing of heart valves. The snapping of the valves creates the vibrations heard with a stethoscope. The first heart sound is the closing of the valves between the atria and ventricles as the ventricles contract. The second heart sound is the closing of the pulmonary and aortic valves as the ventricles relax. Together they create the characteristic "lub-dub".

The valves open to allow blood to flow only in one direction. They close to prevent blood from flowing back. These valves are "flap valves". There are two or three thin skin-like flaps overlapping each other and closing off the valve opening. When blood pushes against the valves from one side they open easily and allow it to pass freely. However, when blood pushes from the other direction, the valves seal off the openings preventing blood from flowing back.

The transportation of blood to and from all parts of the body except the lungs is called the systemic circulation. Oxygenated blood, forced from the left ventricle by its contraction, first enters a single large artery with thick elastic walls called the aorta. From the aorta, pairs of large arteries branch off to carry blood to the head and to the arms.

Arteries to the head are called carotid arteries (Figure AP 18) and those to the arms, the subclavian arteries (Figure AP 19).

Figure AP 18 - Systemic Circulation: Carotid Artery.

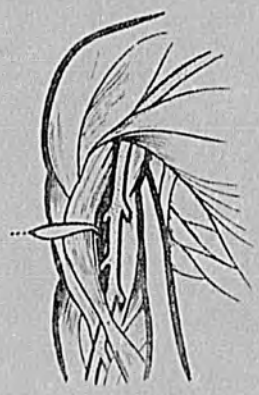

Figure AP 19 - Systemic Circulation: Subclavian Artery.

The aorta curves and descends along the posterior wall of the thoracic and abdominal cavities. In the abdomen, the aorta gives off the single branches to the organs of the digestive system and paired branches to the organs of the urinary and reproductive systems. In the pelvis, the aorta ends by dividing into branches which supply the legs, called the iliac and femoral arteries. (Figure AP 20)

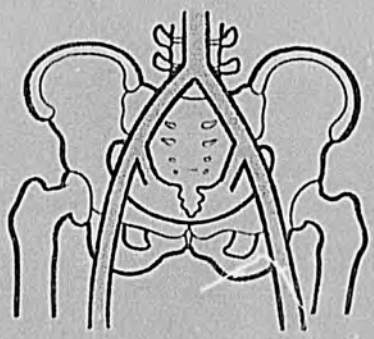

Figure AP 20 - Systemic Circulation: Iliac and Femoral Arteries.

All of the above vessels divide into smaller and smaller branches and end in capillaries within all the organs of the body.

Unoxygenated blood, containing carbon dioxide and cellular waste products, leaves the capillaries throughout the body and is carried to the right side of the heart by veins. The veins that drain a particular region usually can be found next to the artery that supplies the same region. All of these veins drain into either of two large veins before entering the heart. Veins from the head and arms drain unoxygenated blood into the superior vena cava. Veins from the thorax, abdomen, pelvis and legs drain unoxygenated blood into the inferior vena cava. These two veins then drain into the right atrium of the heart.

Blood in the systemic circulation system is under high pressure when it leaves the heart. Waves of pressure spread throughout all the arteries everytime the heart contracts. These waves may be felt over peripheral arteries as a "pulse". The pause between pulses occur when the ventricles are relaxed.

Measuring the blood pressure is measuring the force of the heart's contraction as it occurs in the arterial system. The systolic pressure is the pressure at its peak force. The diastolic pressure is the pressure at its lowest point.

Capillaries

The capillaries are the last branches of the arterial circulation and join the arteries to the venous circulation. Capillaries are very small tubes about the size of a red blood cell. They have very thin walls. The exchange of gases, nutrients, and wastes between the fluid surrounding the cells of the body and the blood takes place across the capillary walls of the vessel. (Figure AP 21)

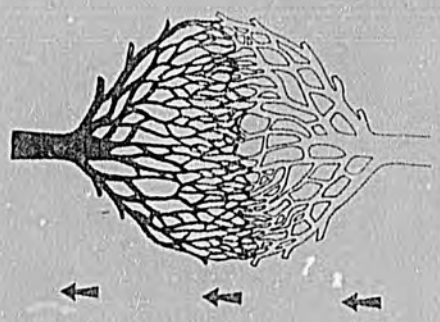

Figure AP 21 - Capillaries are fine, hair-like vessels. It is through the walls of the capillaries where the exchange of gases, nutrients, and waste takes place.

The capillary wall is the barrier between the blood in the vessels and the rest of the body, but it allows some of the substances in the blood to pass out of the capillaries. Red blood cells, plasma proteins and other large substances remain in the capillaries. Water, oxygen, carbon dioxide and small chemical nutrients pass freely through the wall. The normal tendency is for water and other substances to leave the capillaries. However, in the healthy individual the protein in the plasma acts to keep the water inside the capillaries. When capillaries are injured, or when plasmal protein is low, excess water leaks out and produces swelling of tissues, or oedema.

The Spleen

The spleen is an organ which is normally about the size of a fist. It is usually soft and is enclosed in a thin, clear sac. It is located in the abdominal cavity, and is positioned in the left upper corner directly below the diaphragm and behind the lower portion of the rib cage. Blood passes through the spleen as a part of the systemic circulation. The primary functions of the spleen are:

a. The removal and destruction of older "worn out" cells from the blood. The cells are broken down in the spleen. Some of the broken down products are returned to the circulation to be used in the production of new cells; for example, iron.

b. Production of one of the types of white blood cells, lymphocytes.

c. Storage of about 250 ml. of blood that is put into circulation when needed.

d. Trapping and destroying microbes or other substances from the blood stream.

Normally, the spleen cannot be felt upon physical examination. However, it can become enlarged and consequently felt as a result of several different diseases.

The Pulmonary System

The pulmonary circulation carries unoxygenated blood to the lungs and returns oxygentated blood to the heart. The pulmonary circulation begins at the main pulmonary artery.

Blood leaving the right ventricle passes through a valve and enters the pulmonary trunk (or main pulmonary artery). The trunk divides into a right and left pulmonary artery which supply the pair of lungs. These pulmonary arteries follow the airways down into the lungs. At the capillary beds, oxygen is taken up by red blood cells and carbon dioxide is released by the blood plasma. The right and left pulmonary veins follow a separate course carrying blood from the lungs to the left atrium.

The Lymphatic Circulation

The lymphatic circulation functions to return white blood cells and extra fluid from around tissues which have escaped from the systemic circulation back into the systemic circulation. This prevents an excess amount of fluid from circulating around the tissues of the body. The lymphatic circulation surrounds the systemic circulation. It absorbs from the tissues any excess fluid that has passed through the capillary walls of the systemic circulation, and drains this fluid into lymphatic vessels of larger and larger size. The largest of these lymphatic vessels drains into the veins of the systemic circulation. This lymphatic fluid is called lymph.

Lymph nodes are small collections of lymphocyte cells that the lymphatic vessels pass through. They occur behind the knees, in the groin, in the axillary regions and cervical areas. At times of infection in the regions these nodes will enlarge and become palpable or visible. (See Figure AP 22)

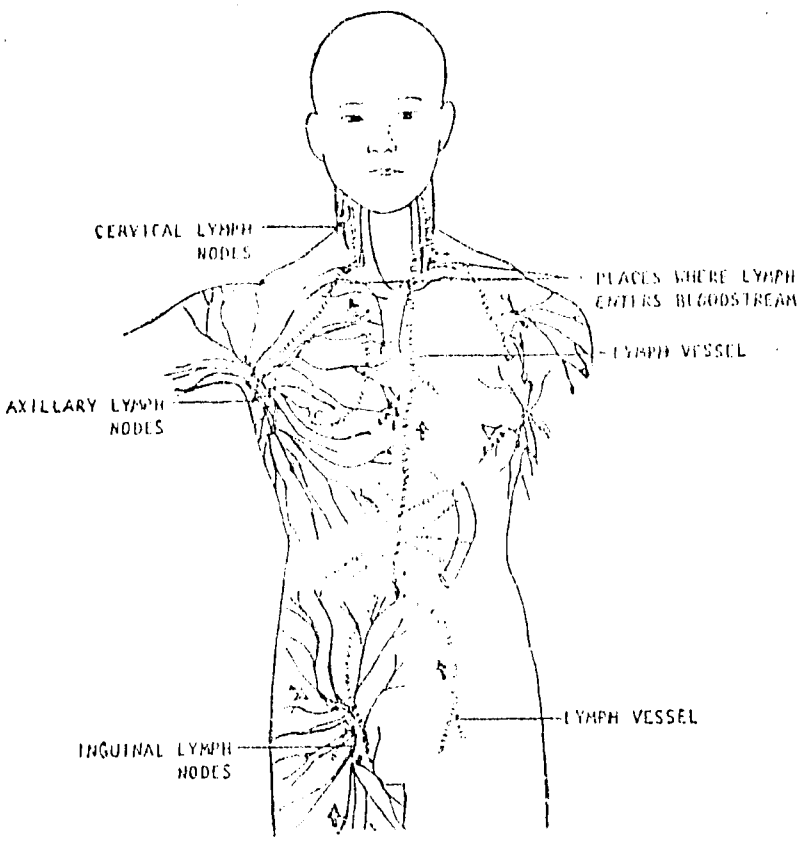

Figure AP 22 - Lymphatic System: lymph drainage is always towards the heart.

REVIEW QUESTIONS

1. The three (3) major components of the circulatory system and their functions are:

   1)

   2)

   3)

2. Vessels which carry blood _____ the heart are called veins.

   Vessels which carry blood _____ the heart are called arteries.

3. Explain two (2) processes by which white blood cells attack disease agents.

   1)

   2)

4. The systemic circulation carries blood to all parts of the body except for the _____.

5. Blood containing carbon dioxide and cellular waste is called _____ blood. This blood is transported through the _____ artery to the _____ where the red blood cells are recharged with oxygen and carbon dioxide is released.

6. Define the four (4) functions of the spleen.

   1)

   2)

   3)

   4)

7. Define the following terms:

plasma:

leukocytes:

antibodies:

systolic pressure:

myocardium:

haemoglobin:

oedema:

STUDENT GUIDE

RESPIRATORY SYSTEM

I. Entry Level Knowledge:

Before starting this unit, you should be able to:

1. Define the words listed in the glossary pertaining to the respiratory system.

II. Objectives:

Using the information and experiences provided by the instructor and the Module Text you will be able to:

1. Define the functions of the respiratory system.
2. Identify and locate the structures included in the respiratory system and define their functions.
3. Explain how oxygen is transported from the lungs to the cells in the body.
4. Explain how carbon dioxide is eliminated from the body.
5. Explain the mechanics of breathing.

III. Evaluation:

Upon completion of the module you will be tested on your attainment of the above objectives. Acceptable performance, 80%.

IV. Activities you will be participating in to accomplish the unit objectives:

1. Read the module text on the respiratory system and answer questions.
2. Write at least one of your own questions about the respiratory system to share with the group during discussion.
3. View and discuss the slides presented about the respiratory system.
4. Using the diagram presented on page 62, draw in and label the structures of the respiratory system. These include:

Nasal cavity	Larynx	Lungs
Oral cavity	Trachea	Bronchitis
Pharynx	Bronchi	Alveoli

RESPIRATORY SYSTEM

Functions

The respiratory system is another system which is important in keeping the body alive. The main function is to draw in oxygen and release carbon dioxide. Oxygen is required by all the cells in the body. It allows them to remain healthy and to grow. Some cells will begin to die in just a few minutes if they do not receive any oxygen.

In order to get oxygen into the body, the lungs draw in air each time the chest expands. The lungs are made up of thousands of tiny air sacs called alveoli which look like large groups of air bubbles stuck together. Each time a breath is taken and air is drawn in, it travels down to the lungs and fills each of these little bubble-like alveoli.

Around each group of alveoli are many small blood vessels called capillaries. The oxygen passes from the alveoli through a capillary and into the blood. In the blood there are many red blood cells. Each of these red blood cells picks up a small amount of oxygen and then carries the oxygen to all the cells in the body. When a red blood cell reaches a cell in the body that has used up its oxygen, the red cell releases the oxygen to that cell. This is the first function of the respiratory system - to continuously supply the cells in the body with oxygen.

The other important function is to get carbon dioxide out of the body. Each cell quickly uses up the oxygen given to it by the red blood cell and then releases carbon dioxide. Carbon dioxide could kill us if it were to build up in the body and, therefore, it must be removed. Each time the red blood cell releases some oxygen to one particular cell, the red blood cell at the same time picks up the carbon dioxide which has been released by that cell. The red blood cells then travel back to the lungs to collect more oxygen and to get rid of the carbon dioxide.

When the red blood cells get back to the capillaries surrounding the alveoli, another load of oxygen is picked up, and at the same time all the carbon dioxide is released. The carbon dioxide goes through the capillary walls and fills the alveoli, which is the opposite direction that the oxygen travels. The final step in removing the carbon dioxide from the body is that the chest contracts and squeezes the lungs which forces the carbon dioxide out of the nose and mouth.

Structure

The air passes through the nose or the mouth, the throat, the larynx, trachea, bronchi, bronchioles and alveoli. (Figure AP 23)

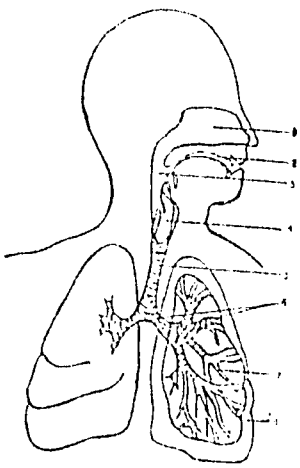

Figure AP 23 - The respiratory system includes: 1) nasal cavity, 2) mouth, 3) throat, 4) larynx, 5) trachea, 6) bronchi, 7) bronchioles, 8) pleural space.

These structures not only provide the pathway for air to follow, but ensure that the air reaching the lungs is warm and clean. The nose, mouth and other structures give off enough heat so that the air is very close to body temperature when it reaches the lungs. The air is also cleansed as it goes down the pathway because many of the small particles in the air stick to the inside surface of the nose, mouth and throat, and are thus filtered out. In addition, the lungs are kept clean because the trachea, bronchi and bronchioles have tiny hair-like structures which move in such a way that mucus and tiny particles are pushed toward the nose and mouth. The mucus and particles are finally eliminated when someone blows their nose or coughs.

Breathing Movements

Air is drawn into the lungs to increase their volume. Similarly, air is forced out by contracting (squeezing) the lungs. The lungs are expanded by flattening out the diaphragm (the muscular membrane which separates the abdominal and thoracic cavities). They are also expanded in another way which is especially important in heavy breathing. Muscles are located between each rib.

When these muscles contract, the ribs are pulled upward. The ribs are designed in such a way that by moving upward the chest becomes larger, thus expanding the lungs and allowing air to be pulled in. (Figure AP 24)

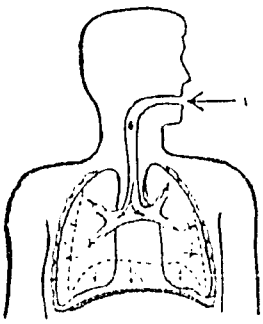

Figure AP 24 - Breathing: When the diaphragm moves downward (3), air is sucked in (1) and the lungs expand (2).

To force air out of the lungs just the opposite occurs. The diaphragm raises upward and the muscles between the ribs relax so that the chest becomes smaller. The effect of these two actions is to force the air out of the lungs. (Figure AP 25a)

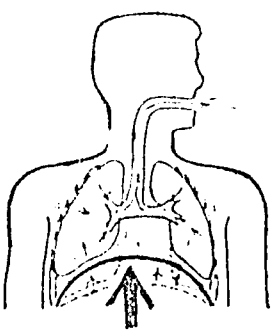

Figure AP 25a - Breathing: When the diaphragm is elevated (3), the lungs (2) compress against the rib cage (4). This forces air into the tracheobronchial tree (5) and into the trachea (6) and out the mouth or nose.

REVIEW QUES IS

1. Label structures of respiratory system.

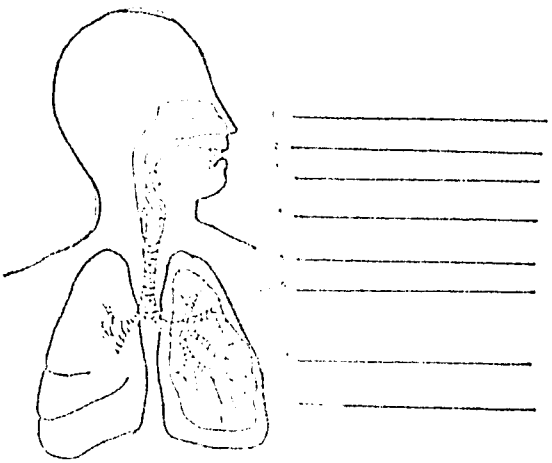

2. Explain briefly how oxygen from the lungs is transported to the cells in the body.

3. Explain briefly how carbon dioxide is eliminated from the body.

4. One of the functions of the structures of the respiratory system is to provide the pathway for the air to follow. What are two (2) other functions of these structures?

   1)

   2)

5. Describe the mechanics of inhaling (breathing in air).

6. Define the following terms:

   alveoli:

   trachea:

   bronchi:

   bronchiole:

STUDENT GUIDE

ABDOMEN/DIGESTIVE SYSTEM

I. Entry Level Knowledge

Before starting this unit, you should be able to:

1. Define the words listed in the glossary pertaining to the abdomen.

II. Objectives:

Using the information and experiences provided by the instructor and the module text, you will be able to:

1. Describe the structural components contained within the abdomen.
2. Identify the organ systems contained within the abdomen.
3. Explain the steps in the digestive process.
4. Identify and locate the structures in the digestive process.
5. Describe the functions of the structures in the digestive system.

III. Evaluation:

Upon completion of this module you will be tested on your attainment of the above objectives. Acceptable performance, 80%.

IV. Activities you will be participating in to accomplish the unit objectives:

1. Read the module text pages and answer the review questions.
2. Write at least one of your own questions about the respiratory system to share with the group during discussions.
3. View and discuss slides of digestive system and A-V presentation on digestion.
4. On a prepared outline of the human figure:
   a. draw in and label the structural component parts mentioned in the module.
   b. draw in and label the structures of the digestive system.
      These are to include:

Oral cavity	Pancreas
Pharynx	Gall bladder
Oesophagus	Large intestine
Small intestine	Rectum
Liver	Anus

ANATOMY OF THE ABDOMEN

The abdomen is the body cavity located below the thorax. It contains almost all of the organs of the digestive system, including the stomach, the small and large intestines, the liver, and the pancreas. It also holds organs from two other systems: the spleen (circulatory system), the bladder, kidneys, and ureters (urinary system), and reproductive organs.

The upper end of the abdomen is the diaphragm, which is also the lower end of the thorax. The lower end of the abdomen is within the pelvic bones. Here the abdomen opens into the pelvis. The wall of the abdomen is composed of three layers of flat muscles lying just under the skin. These muscles are attached to the lower edge of the rib cage above, the pelvic bones below and to the vertebrae in the rear. The only bones in the wall of the cavity are the five lumbar vertebrae in the rear. They do not have ribs attached to them.

The cavity itself extends up behind the rib cage and below the pelvic bone. The inside of the cavity is lined by a slippery layer of cells called the peritoneum. This coating allows the intestines to move around during the digestion of food.

The external vertical surface of the abdomen is commonly divided into four quadrants. The umbilicus is the intersecting point for the vertical and horizontal divisions. The quadrants are labelled right upper, left upper, right lower and left lower. (Figure AP 26)

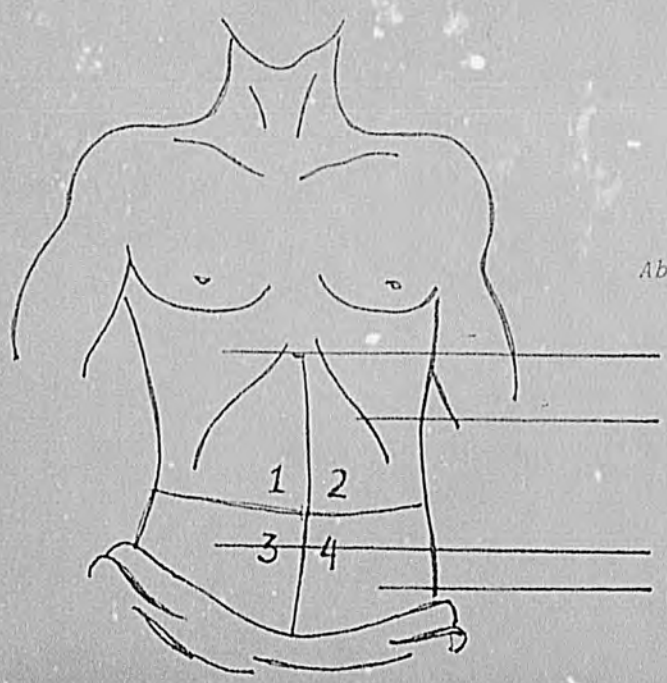

Figure AP 26 - Abdominal quadrants.

REVIEW QUESTIONS

1. What three (3) organ systems are contained in the abdomen?

   1)

   2)

   3)

2. Define the boundaries of the abdominal cavity.

3. The only bones in the wall of the cavity are the

   _____ _____ .

4. The insides of the abdominal cavity is lined with a layer of cells called the _____ . Why is this an important structure?

DIGESTIVE SYSTEM

Function

In order for the cells of the body to live, they must have nourishment in the form of simple chemical nutrients. The source of these nutrients for man is what we call food. The function of the digestive system is to convert complex food items into simpler substances which cells can use. This conversion takes a number of steps.

The first step in the digestive process is to break down the food into pieces small enough to pass through the digestive tract. Next, the food must be mixed with acids and enzymes, which will break the food down into small chemical nutrients. These nutrients must then be absorbed into the blood stream. The excess water must be removed from the unabsorbed remainder. Finally, whatever is not digested by the digestive tract must be removed from it.

Structure

The digestive system consists of the digestive tract, (a long tube running from the mouth to the anus), and the accessory organs which aid the tract in performing its functions. (Figure AP 27)

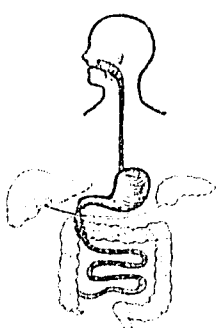

Figure AP 27 - The Digestive System

Mouth

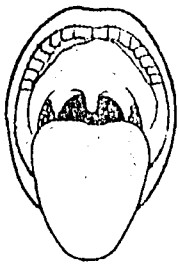

Figure AP 28 - The Mouth.

The mouth or oral cavity is the entry point into the digestive system. Here food is broken down into smaller pieces and mixed with fluid. The walls of the oral cavity are formed by the bones of the jaw and the muscles of mastication, or chewing muscles. The roof is the palate, which is hard and composed of bone in front, and soft and muscular in the back. A projection from the back of the soft palate is the uvula. The accessory organs of the mouth include the teeth, the tongue (Figure AP 28), and the salivary glands (Figure AP 29).

The teeth, which are held in sockets in the upper and lower jaws, are used for breaking up food into smaller bits. They are the hardest structures in the body. The adult has thirty-two teeth - four incisors, two canines, four bicuspids, and six molars in the lower jaw, and the same number in the upper jaw. Young children have a set of temporary teeth, which are replaced by adult teeth as they grow older. Children have 20 teeth - eight incisors, four canines, and eight molars. The incisor and canine teeth are located in the front of the mouth and are used for cutting and tearing food. The bicuspids nd molars are located at the sides and back of the mouth and are used to grind the food. Each tooth has a crown composed of hard, white enamel which is the cutting surface; a neck, covered by the soft fleshy gums; and a root, which is buried in the bone of the jaw. The root contains the nerve and blood supply of the tooth.

The tongue is a muscular structure in the floor of the mouth. It is used to manoeuver food during chewing and aids in swallowing. Its surface is covered with numerous projections which give it its velvety appearance and which are provided with taste receptors. These receptors, or taste buds, sense salty, sweet, bitter and sour tastes.

There are three pairs of salivary glands which secrete enzymes and fluid called saliva into the mouth. Enzymes are chemicals which change foods to simpler chemical forms. Saliva is the fluid which moistens and softens food, keeps the mouth moist, and contains the enzyme which breaks down starches like maize, bread, etc. into sugar. Salivary glands secrete this fluid whenever you smell something good to eat, or when something pleasant stimulates the taste buds. (Figure AP 29)

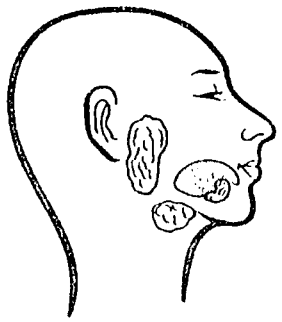

Figure AP 29 - Salivary Glands.

Stomach

After food has been chewed and moistened with saliva, it is swallowed. Chewed food is transported from the back of the mouth to the stomach through the oesophagus, a muscular tube, extending from the throat, through the neck and thorax, to the stomach. (Figure AP 30)

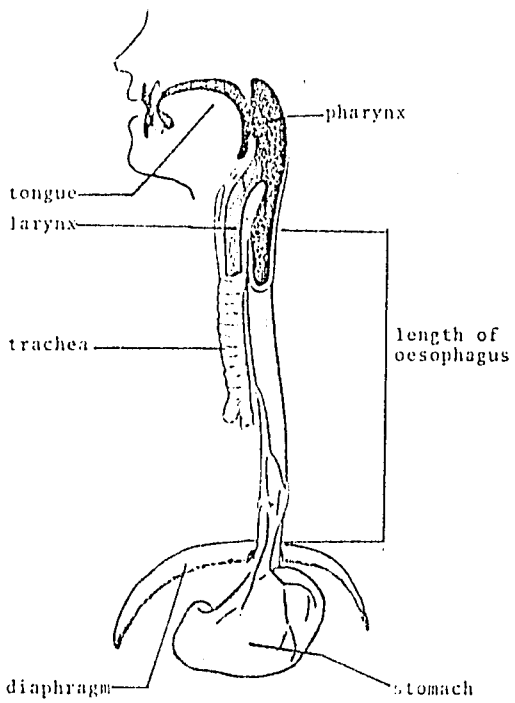

Figure AP 30 - Digestive system from pharynx to stomach.

The stomach is the first organ where chemical digestion takes place. It is a muscular, pear-shaped structure. Its size varies, depending on the amount of food in it. Located on its inner surface are a large number of small glands which secrete acids. The acid causes the milk protein to curdle. Enzymes break down proteins (such as meat), and fats. The mucous substance coats the stomach lining to protect the stomach wall from the action of its secretions. During digestion, the food is mixed with the enzymes and mechanically broken down by muscular contractions of the stomach. Stomach contractions also occur when the stomach is empty or when food is swallowed. (Figure AP 31)

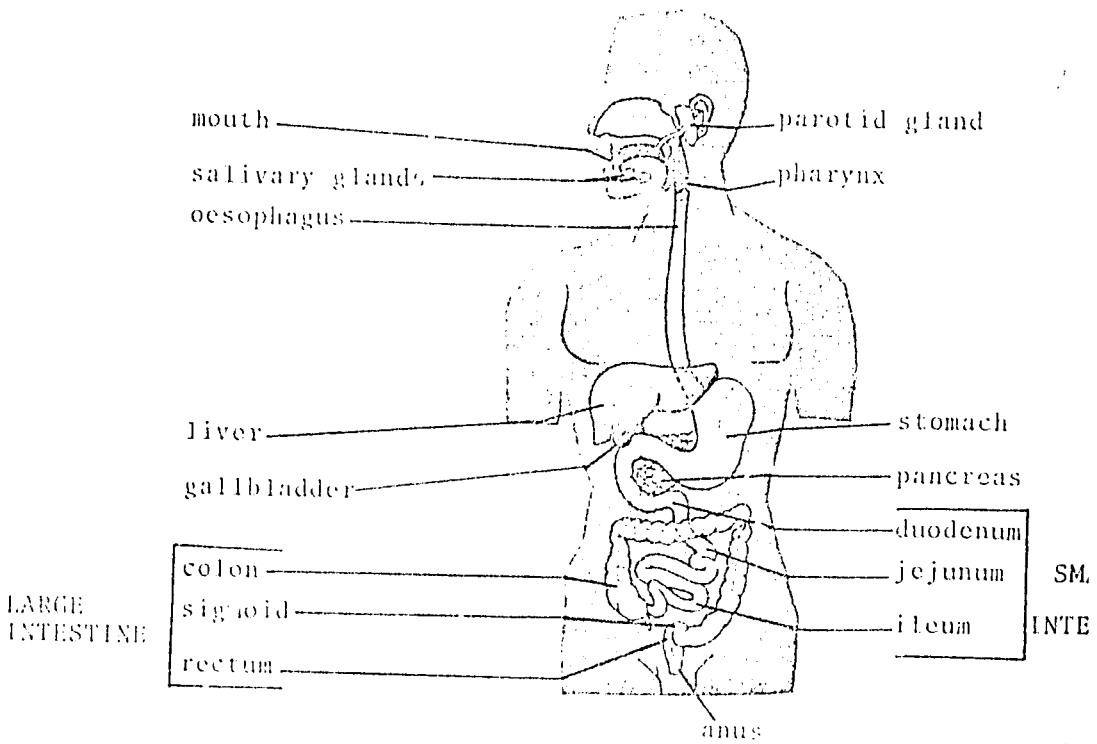

After food has been crushed and chemically broken down, it becomes a very thick liquid. The contractions of the stomach force this liquid through a valve in its lower end called the pyloris. The pyloris is a muscular ring which separates the stomach from the first part of the small intestine, the duodenum.

Small Intestine, Liver, and Pancreas

Food is further dissolved and then absorbed by the small and large intestines.

The small intestine is about 6-8 metres long, and when coiled, fills the majority of the abdominal cavity. The lining of the walls of the tubular small intestine contains small glands which secrete more digestive enzymes, and projections from the surface through which absorption takes place. The three principle substances broken down in the intestine are starches, fats and proteins.

Aiding the digestive enzymes of the stomach and small intestine are the secretions of the liver and pancreas. The liver produces bile, a mixture of mineral salts. Bile is stored in the gall bladder. When fat is to be digested by the small intestine, bile is released by the gall bladder into the small intestine where it completes the digestion of fat. The pancreas secretes enzymes into the small intestine which aid the completion of protein digestion. (Figure AP 31)

Absorption of the chemical nutrients is performed by the intestinal projections. These projections are like millions of tiny fingers which stick down into the digested material. Their outside is covered by epithelium which secretes a protective mucous blanket, and which also absorbs the end products of digestion along with water. Inside the projections are many capillaries and lymphatics. Nutrients are picked up by the capillaries and carried to the liver for further conversion and storage. Large amounts of fatty acid are carried directly into the veins by the capillaries.

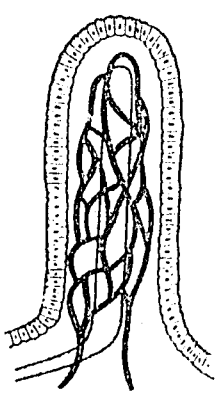

Figure AP 32 - Absorbing projections in the intestines.

Large Intestine, Appendix and Rectum

From the small intestine, the portions of food which cannot be digested or absorbed pass into the large intestine, which is about 1.5 metres long. (Figure AP 33)

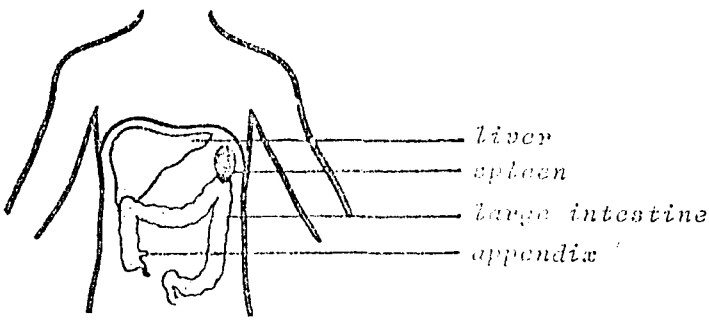

Figure AP 33 - The large intestine and appendix

Together, the large intestine (also called the colon) and the rectum are responsible for collecting the undigestible by-products from the small intestine, absorbing water from them, and moving them towards the anus where they are finally eliminated from the body. (Figure AP 33)

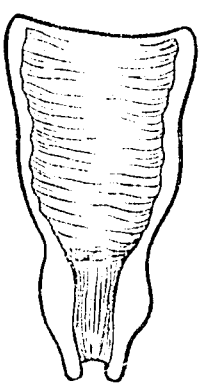

Figure AP 34 The rectum.

The appendix is a narrow small hollow tail-like projection from the first part of the large intestine. It has no digestive function and only becomes a problem when it becomes infected or inflamed. (Figure AP 33)

REVIEW QUESTIONS

The function of the digestive system is to convert complex food items into simpler substances which the cells in the body can use. List the steps involved in this digestive process. Name the body parts involved in each step.

Step	Body Part (s)
1)	
2)	
3)	
4)	
5)	
6)	
7)	
8)	

2. Define the following terms:

palate:

enzymes:

bile:

colon:

STUDENT GUIDE

PELVIS & EXTERNAL GENITALIA/URINARY SYSTEM

I. Entry Level Knowledge:

Before starting this unit, you should be able to:

1. Define the words listed in the glossary pertaining to the pelvis, external genitalia and urinary system.

II. Objectives:

Using the information and experiences provided by the instructor and the module text, you will be able to:

1. Describe the structural components contained within the pelvis.
2. Identify the organ systems contained within the pelvis.
3. Describe the male and female external genitalia.
4. Define the functions of the urinary system.
5. Identify and locate the structures included in the urinary system.
6. Explain the process of urine formation and urination.

III. Evaluation:

Upon completion of this module you will be tested on your attainment of the above objectives. Acceptable performance, 80%.

IV. Activities you will be participating in to accomplish the unit objectives.

1. Read the module text on the pelvis and external genitalia/urinary system and answer review questions.
2. Write at least one of your own questions about the pelvis, external genitalia and urinary system to share with the group during discussion.
3. View and discuss the slides presented on the urinary system.
4. Using the outline on page
   a. Label the structural components of the pelvis.
   b. Draw in and label the male or female external genitalia.
   c. Draw in and label the structure of the urinary system.
5. Practice identification of the components of the urinary system on three dimensional models.

ANATOMY OF PELVIS AND EXTERNAL GENITALIA

Pelvis

The pelvis is the lower part of the trunk. It consists of a cylindrical cavity whose sides are surrounded by bone. The upper end opens into the abdomen. The lower end is covered by a sheet of muscle from which the external genitalia are suspended. The bony walls are made up of two pelvic bones on the sides and front and the lowest part of the vertebral column, the sacrum in the back. The two pelvic bones join each other in front at the pubic symphysis. The two blade-like sides of the bones swerve up to the vertebra.

Organs associated with the reproductive, urinary and digestive systems are located in the pelvis. The most anterior organ, the urinary bladder, is located right behind the pubic parts of the pelvic bones in both males and females. Behind the bladder in females are located all the organs of reproduction: ovaries, fallopian tubes, uterus and vagina. In the male, the only part of the reproductive system in the pelvis are the vas deferens, and postate gland. The last part of the digestive tract, the rectum, is located against the back wall of the pelvis.

Female External Genitalia

The external genitalia of the female include: the mons pubis, labia majora, labia minora, clitoris, and the vaginal opening. The most anterior of these is the mons pubis. It is a layer of fat overlying the pubic bone. At puberty, the skin becomes covered with hair. The labia majora and minora are two folds of skin which overlay the opening to the vagina. At the point where the two labia majora join is a small mass of erectile tissue called the clitoris. Between the folds of the labia majora and minora is the area into which the last parts of both the urinary and reproductive system end. The urethra, from the bladder, opens anterior to that of the vagina proper. The vagina is the cavity through which a baby passes during birth. (Figure AP 35)

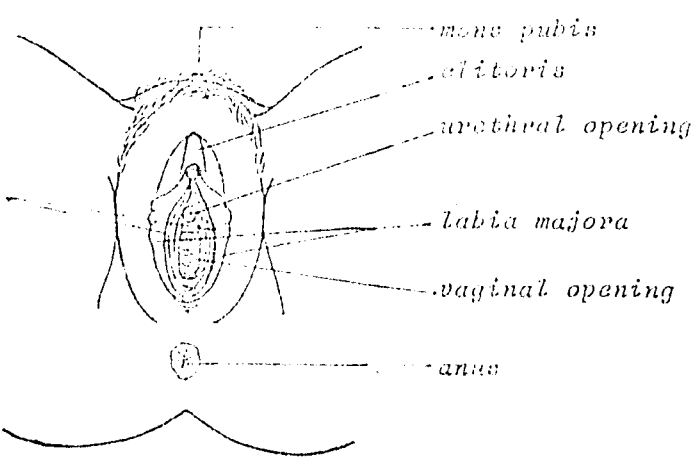

Figure AP 35 - Female External Genitalia

Male External Genitalia

There are two external genital organs visible in the male: the scrotum and the penis. The scrotum is the male counterpart to the labia majora in the female. It is the pouch formed by a fold of skin within which the male reproductive organs, (the testes,) are located. From the testes a tube carries male sperm cells up into the pelvis. The tube is the vas deferens. In the pelvis, it joins the urinary system below the bladder. Both systems empty from the male via a single tube, the urethra. The penis is the male counterpart of the clitoris in the female. It contains a large mass of blood vessels and the urethra. The blood vessels which supply the erectile tissue dilate during sexual arousal, thus causing a tremendous amount of blood under pressure to enter the tissue and results in an enlarged and hardened penis. The products of both the urinary and reproductive systems exit the body through the urethra in the penis. (Figure AP 36)

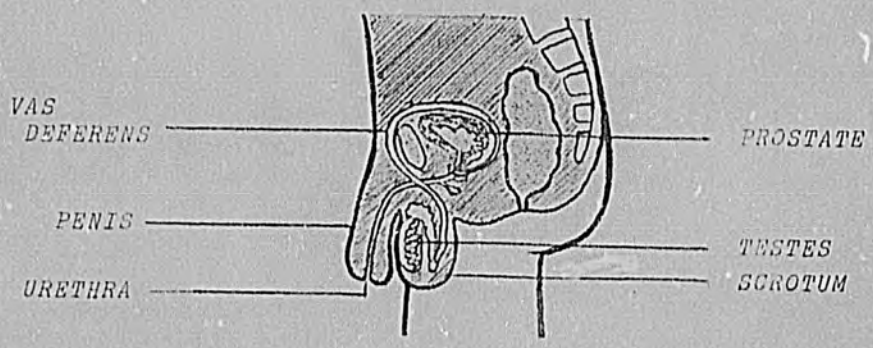

Figure AP 36 - Male External Gentalia and Reproductive Organs

REVIEW QUESTIONS

1. Define the boundaries of the pelvis.

2. Located within the pelvis are organs associated with the reproductive, urinary and digestive systems. Name the organs associated with these systems.

Reproductive

1) 4)

2) 5)

3) 6)

Urinary

1)

Digestive

1)

3. List and define the external genitalia of the female:

1)

2)

3)

4)

5)

4. The two external genital organs visible in the male are the _____ and the _____.

5. The urinary and reproductive systems empty from the male via a single tube called the _____ .

URINARY SYSTEM

Functions

It has been explained in previous sections that the cells in the body require and use oxygen and food in order to grow. In using oxygen and food, however, cells produce many harmful waste products. One of these is carbon dioxide which is removed by the lungs. The urinary system is responsible for removing other wastes as they are given off into the blood by cells in the body.

The urinary system regulates the amount of water and minerals which are carried in the blood stream. The kidneys can either excrete or retain the water and minerals according to body needs. Therefore the urinary system is important for maintaining adequate amounts of water and minerals in the body.

Structures and Urine Formation

The body has two kidneys, each of which are about the size of a child's closed fist. They are the only organs of the urinary system which actively form urine, thus eliminating poisonous waste products and regulating the amount of water and minerals in the body. The rest of the structures in the urinary system serve to transport or store the urine. (Figure AP 37)

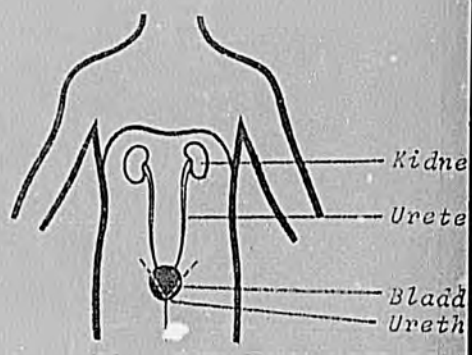

Figure AP 37 - Urinary System: The orga of the urinary system are the two kidney two ureters, the bladder and the urethra

In making a complete trip around the body, all the blood in the body must pass through the kidneys. Like the lungs, the kidneys have thousands of tiny blood vessels called capillaries. In the kidneys, the capillaries allow almost all of the fluid in the blood to pass through. This fluid contains useful mineral, water and harmful waste products from the cells.

The fluid then collects in small sacs. Connected to each sac is a small tube which allows the fluid to drain out. These tubes have special regions which reabsorb the important minerals and water back into the blood. Therefore, all that is left as the fluid reaches the end of the tubule is excess water, excess minerals, and some waste products.

This fluid is called urine. A kidney is really made up of thousands of units of capillaries, sacs, and tubules all working at the same time.

Urination

All of the tubules join together just before leaving the kidney and empty their fluid together. This fluid or urine then passes to the bladder through narrow tubes called ureters. There is one ureter for each kidney which passes down to join the bladder. The bladder is a hollow muscular organ which stores the urine and then releases it all at once. The bladder slowly fills with urine from both ureters until it receives about one pint. When it contains about one pint, the bladder is stretched and feels very uncomfortable. This results in the desire to urinate in order to empty the bladder. Muscles around the bladder contract, squeezing the bladder and forcing the urine through a final tube-like structure called a urethra which leads to the outside of the body.

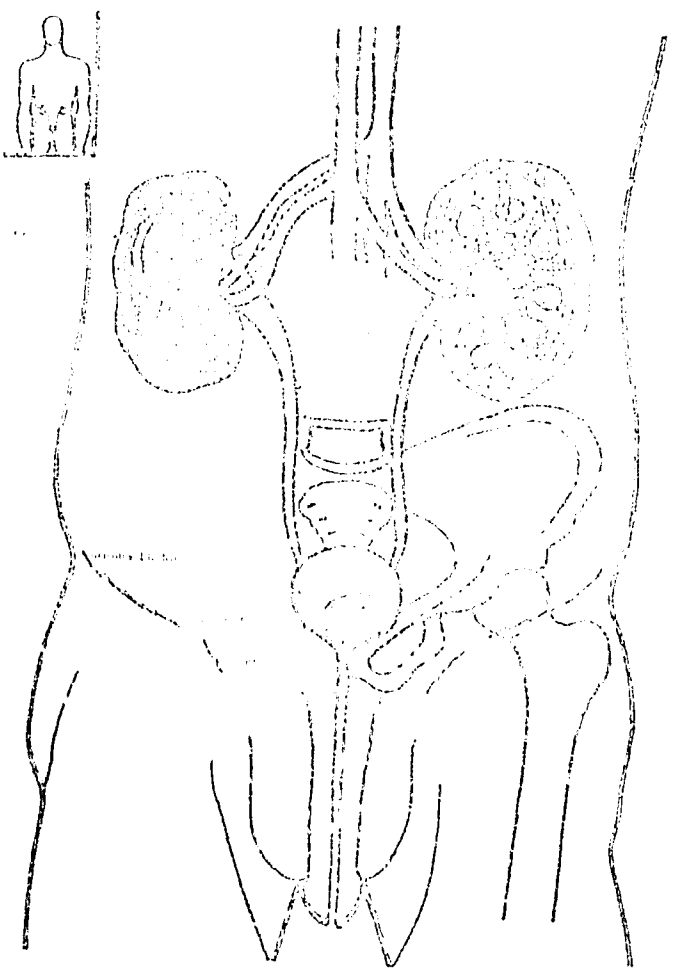

Figure AP 38 - Organs and structures of the urinary system.

REVIEW QUESTIONS

1. Name two (2) important functions of the urinary system.

   1)

   2)

2. Which of the following is <u>NOT</u> a function of the kidneys?

   a. actively forms urine
   b. stores urine until its removal from body
   c. regulates the amount of minerals and water in bloodstream

3. Match the urinary structures with their functions:

____ a. tubules	1. stores urine
____ b. ureter	2. transports urine from kidney to bladder
____ c. bladder	3. passes urine to outside of body
____ d. urethra	4. reabsorbs minerals and water back into blood.

4. Define the following terms:

   urine:

   kidney:

STUDENT GUIDE

REPRODUCTIVE SYSTEM

I. Entry Level Knowledge:

Before starting this unit, you should be able to:

1. Define the words listed in the glossary pertaining to the reproductive system.

II. Objectives:

Using the information and experiences provided by the instructor and the module text, you will be able to:

1. Define the functions of the male and female reproductive systems.
2. Identify and locate the structure of the male and female reproductive systems and define their functions.
3. Explain the process of fertilization.
4. Describe the anatomical changes which take place during pregnancy.

III. Evaluation:

Upon completion of this module you will be tested on your attainment of the above objectives. Acceptable performance, 80%.

IV. Activities you will be participating in to accomplish the unit objectives:

1. Read the module text and answer the review questions.
2. Write at least one of your own questions about the reproductive system to share with the group during discussion.
3. View and discuss slides of the male and female reproductive systems.
4. Use three dimensional models and wall charts to identify structures of reproductive system and changes which take place during pregnancy.
5. Label the drawing in the module text with the correct names of the structures of the reproductive systems.

THE REPRODUCTIVE SYSTEM

Function

In order for humans to continue to inhabit the earth they must have the ability to produce babies which will grow and replace those persons who have died. Both males and females are important in the reproductive process because a baby cannot develop from a cell (ovum) produced inside the female unless the ovum first comes into contact with a cell called a sperm from the male. Therefore, the human body has special structures in both males and females to allow reproduction to occur.

Male Structure and Function

The scrotum is an external sac which contains and protects the testes. The testes are two oval structures which produce sperm.

A sperm cell is a special cell consisting of a compact head and a tail which enables the sperm to swim to the ovum once it is inside the female body. Each sperm contains half the information of what the baby will be like (i.e. physical appearance, sex, etc.) while the other half of the information is contained in the ovum produced by the female. For this reason, it is necessary that the sperm and the ovum join together before a baby can begin to develop. (Figure AP 39)

After a male reaches about the age of fifteen, millions of sperm cells are continually produced in special tubules in the testes. After the sperm are produced they are stored in these tubules, and remain almost totally inactive.

When a male becomes sexually excited, the nerve impulses in the reproductive organs cause the arteries in these organs to dilate (become larger).

Figure AP 39 - Reproductive System; Male: Sperms are the male sex cells. This is a sperm highly magnified.

As a result, a large quantity of blood enters the tissue of the penis and causes it to become enlarged and hard. During intercourse (the sex act) the male's penis is inserted into the female vagina and the sperm is released by passing through a long tube called the vas deferens, and on through seminal vesicles, the prostate gland and out through the penis itself through the urethra. The urethra is specially designed so that no urine can pass out at the same time that the sperm is being released from the body. This process of sperm being suddenly expelled is called ejaculation. It moves the sperm from the testes where they are produced, out the tip of the penis and into the vagina. (Figure AP 40)

In addition to the sperm, mucus from the seminal vesicles and milky fluid from the prostate gland are released during ejaculation. All these fluids plus the sperm are called semen.

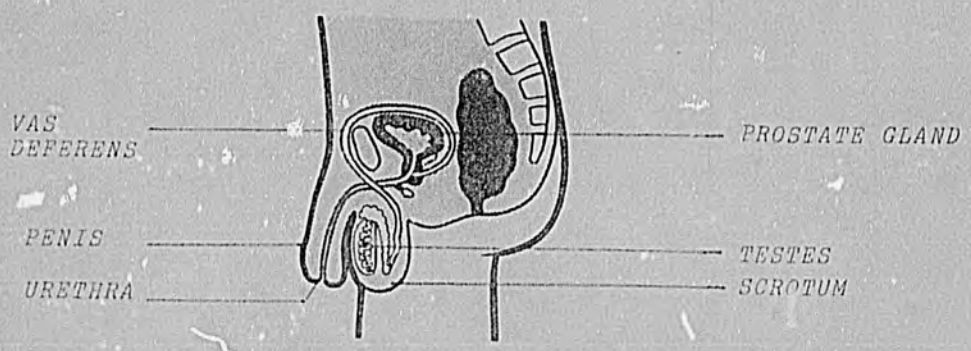

Figure AP 40 - Reproductive System; male: Sperms are produced in the testes. Semen passes along the vas deferens. Secretions from the seminal vesicles and the prostate gland are added to it. It finally leaves the body through the urethra.

Female Structure and Function

A female has her reproductive structures contained within her body. Ovaries produce egg cells called ova and the uterus supports the baby as it grows inside the female body. (Figure AP 41)

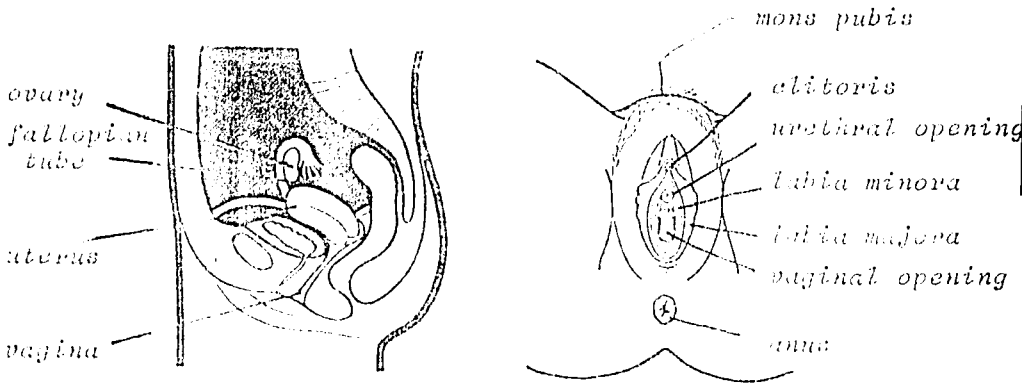

Figure AP 41 - Female Reproductive System: On the left are the major internal anatomical structures of the female reproductive system. On the right are the external anatomical landmarks associated with the female reproductive system.

An ovum, which is not large enough to be seen by the eye, is produced and released from an organ called an ovary, about once a month. A female has two ovaries which alternate in releasing an ovum each month. The ovum then travels down a small tube called the fallopian tube. Sperm, which through intercourse have been released into the vagina in the female body, swim up to the fallopian tube to join with the egg.

If an ovum and a sperm are in the tube at the same time, they may join together, and the ovum is then said to be fertilized. The fertilized ovum will then travel within the female body to a special hollow structure called the uterus, where the ovum develops into a foetus. (Figures AP 42, 43, 44)

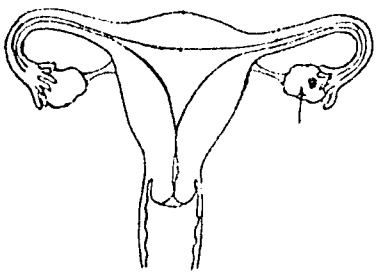

Figure AP 42 - Reproductive System; Female: The ovum released by the follicle is directed into the fallopian tube by its fringed ends.

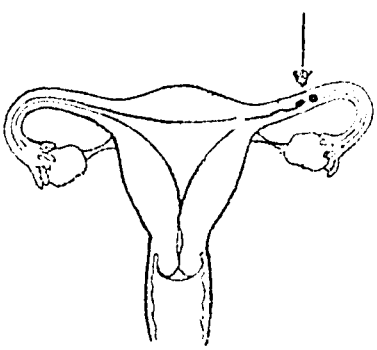

Figure AP 43 - The sperm and ovum join in the tube and fertilization takes place.

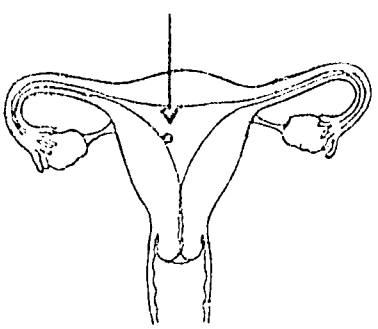

Figure AP 44 - The fertilized ovum has reached the uterus and embeds itself into the wall of the uterus.

If there is no sperm in the fallopian tube, or if there are sperm but the ovum does not join with any, the ovum continues down and out of the vagina. Ovulation is the term used for the release of the ovum. A woman is most fertile (able to become pregnant) at the time of ovulation. This is because an ovum dies after two days if it is not fertilized. Sperm from a male can live inside a female for three days. This means that an ovum can be fertilized by a sperm which entered the tubes two to three days before or two to three days after ovulation.

Menstruation

Each month the uterus builds up its lining to receive the fertilized ovum. If the ovum is not fertilized, it is not received by the uterus. Therefore, the ovum and the lining of the uterus are shed causing bleeding from the vagina for three to five days. This bleeding is called menstruation.

Menstruation usually starts 14 days after ovulation. This monthly cycle of events is called the menstrual cycle. The menstrual cycle varies in length. In the average woman it is 28 days but varies from about 25 to 31 days in different women.

A woman conceives (becomes pregnant) during her reproductive years. These are the years between puberty (12 to 15 years) and menopause (40 to 50 years). It is during these years that a woman has a monthly period or menstruation.

Fetal Development

Once an ova is fertilized, it travels to the uterus and attaches itself to the inside wall (endometrium) of the uterus. Even before the ovum has attached itself, the endometrium has stored large quantities of nutrients needed by the developing ovum (egg).

At this time, a thin, transparent but tough membrane (fetal membrane) attaches to the inner surface of the uterus and forms a sac which completely surrounds the egg. This then fills with fluid and acts as a cushion for the free-floating egg, to protect it from sudden movements made by the mother. This protective sac is called the amniotic sac or the bags of waters.

The structure in the uterus which supplies the developing fetus with nutrients is called the plaecenta. It is this structure, covering about one-fourth the surface of the uterus which connects the mother with the developing fetus by means of the umbilical cord. (Figure AP 45)

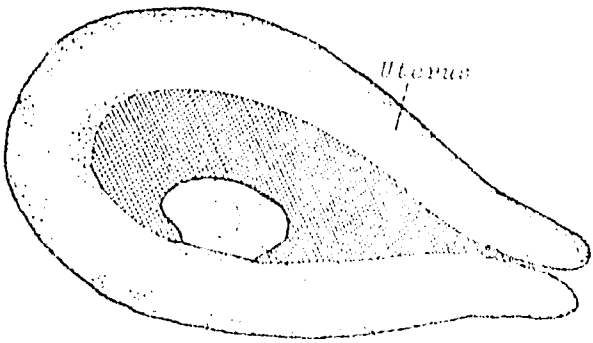

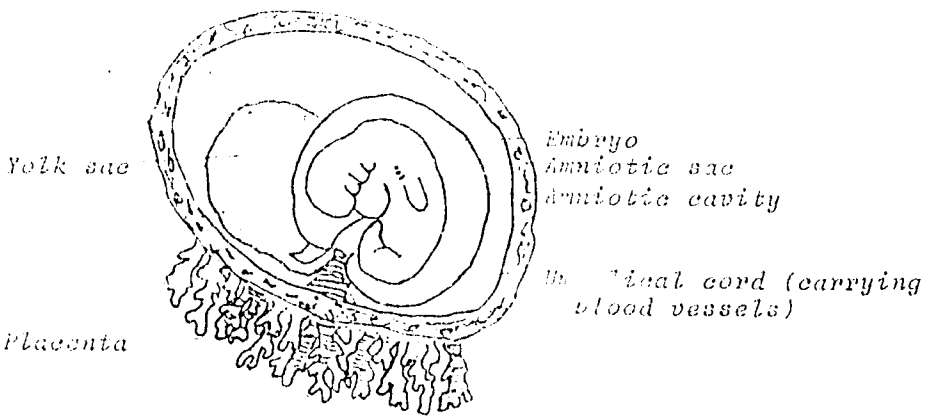

Figure AP 45 - The embryo, its placenta and membranes

The umbilical cord is that vessel through which the food and oxygen needed by the fetus in order to survive and grow is provided from the mother's blood. The function of the umbilical cord is to carry the blood from the foetus to the placenta where it picks up nutrients and then to carry this back into the developing foetus. It is also through the umbilical cord that waste products resulting from the fetus' metabolism pass into the mother's blood and out of her body through her excretory organs. (Figure AP 46)

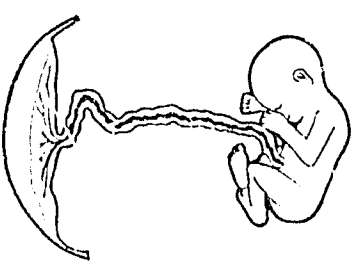

Figure AP 46 - The umbilical cord. The umbilical cord connects the foetus to the placenta.

It normally takes about nine months for the egg to grow into a fully-developed baby within the female. At the end of these nine months, the baby is born. (Figures AP 47-50)

Figure AP 47 - The foetus at six weeks.

Figure AP 48 - The foetus at seven weeks with fingers and toes.

Figure AP 49 - The foetus at eight weeks showing human form.

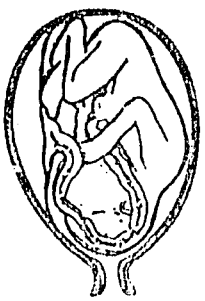

Figure AP 50 - The foetus at fu term (40 weeks). The usual position of the foetus is with head downwards and lying in a b of fluid.

REVIEW QUESTIONS

1. Explain why it is necessary that the male sperm and the female egg join together before a baby can begin to develop.

2. The opening in the penis through which semen is expelled into the female body is the _____ _____ .

3. Sperm cells are produced in the _____ .

4. Egg cells are produced in the _____ .

5. Explain the process of fertilization.

6. What happens during menstruation?

7. Why is the placenta important in the development of the fetus?

8. What function does the umbilical cord have?

9. Define the following terms:

seminiferous tubules:

semen:

egg cell:

fallopian tube:

amniotic sac:

fetus:

STUDENT GUIDE

NERVOUS SYSTEM

I. Entry Level Knowledge:

Before starting this unit, you should be able to:

1. Define the words listed in the glossary pertaining to the nervous system.

II. Objectives:

Using the information and experiences provided by the instructor and the module text, you will be able to:

1. Define the function of the nervous system.
2. Describe the structure of the nervous system:

   Nerves, spinal cord, brain.

3. Explain how nerve impulses are relayed to and from the brain.
4. Explain the difference between reflex and the conscious movement of walking, talking, etc.
5. Explain why the brain is said to be responsible for keeping the body in a stable condition.
6. Describe the structures of the special senses:

   sight, hearing, tasting, smelling.

III. Evaluation:

Upon completion of the module you will be tested on your attainment of the above objectives. Acceptable performance, 80%.

IV. Activities you will be participating in to accomplish the unit objectives:

1. Read the module text pages and answer the review questions.
2. Write at least one of your own questions about the nervous system to share with the group during discussion.
3. View and discuss the slides presented of the nervous system.
4. Using an outline of the human figure draw in and label the following parts of the nervous system:

   a. Brain
   b. Spinal cord.

5. Draw an example of how a stimulus of pain in a given part of the body is transmitted into a motor reflex.
   Drawing should include: a sensory neuron in the skin, a connective neuron near the spinal cord, and a motor neuron connected to a muscle.
6. Identify structures of special senses on three dimensional models.

NERVOUS SYSTEM

Function

The nervous system is the main communications system for the body. It sends information to, and receives information from, all parts of the body. For example, if you have a stone in your shoe, you will know about it because of the nervous system. You will feel the pain. If, however, the nerves are damaged and the "message" is not able to get through to your brain, the pain will not be felt. This happens with patients who have leprosy, a disease which damages nervous tissue.

The nervous system's function is to coordinate all of the activities of the body. When you become aware of the stone in your shoe, your brain sends messages out for your body to stop, bend down, and remove the stone before any damage is done. The patient with leprosy does not do this because he does not feel the pain. This is why his feet become damaged.

Messages are being sent around the body all of the time. However, we are not aware of most of these messages such as the ones which help to control blood pressure, heart rate, respiratory rate, or the digestive tract and other internal organs. These messages are regulated by that part of the nervous system referred to as the involuntary (or autonomic) nervous system. These messages which we are aware of are regulated by the voluntary nervous system. This system controls such movements as walking, talking, writing, etc. since it controls the voluntary muscles.

Structure

The nervous system consists of nerves, the spinal cord, and the brain, each of which perform different functions yet work together as a single system.

Nerves (or peripheral nerves)

The peripheral nerves, usually referred to simply as nerves, are made up of chains of very long, thin cells, which pass messages to and from the brain.

Nerves are classified as either sensory or motor, depending on the type of information they are carrying. Sensory nerves carry sensations such as pain and temperature to the spinal cord, while motor nerves carry messages from the spinal cord to the muscles which tell them how to react.

Nerves become increasingly larger as they near the spinal cord. This is because they are joined by more and more nerve cells. They are like many small streams flowing into small rivers, which in turn flow into larger and larger rivers. All nerves eventually land into the spinal cord.

Spinal Cord

The spinal cord is simply a very large nerve. It is made up of all of the nerve cells leading to the brain. The spinal cord runs through the middle of the spinal column, and is, therefore, well-protected from injury. If the spinal cord is cut, as happens occasionally in severe accidents, all communication between the brain and the lower parts of the body is stopped. The patient cannot feel sensations, and loses movement of body parts below the level of the cut in the spinal cord.

Brain

The brain is the organ which is important for gathering all the information from the spinal cord and then deciding what commands to send out to the body. In addition to receiving information and giving commands to muscles, the brain also enables us to think, learn and remember past experiences.

Another important function of the brain is to maintain the correct temperature and the correct amount of water in the body. The brain can do this because it has special sensory areas which can detect the temperature and the amount of water and nutrients contained in the blood. The brain can send signals to the body to shiver if it is too cold or to perspire if it is hot. If there is not the correct amount of water in the body, the brain can cause the body to feel thirsty in order to obtain more water. In the situation of too much water in the body, the brain signals the kidneys to get rid of the excess. The brain also makes the body feel hungry or full in order to keep the right amount of nutrients in the blood. Thus, the brain is responsible for keeping the body in a stable condition.

Reflexes

A reflex is a motor response that occurs automatically once a sensation is detected, transmitted to the spinal cord and then sent back to the muscles. A reflex occurs, for instance, when the tendon of a muscle is hit with an object

The sensory message goes from the nerve into the spinal cord and then crosses over the spinal cord without going up to the brain, passing out the motor nerves and telling the muscles to move. Since the brain is not involved, and we do not think about how to respond each time the tendon of a muscle is hit, the sensory and motor messages are always the same, and cause the muscles to contract the same way each time.

Reflexes are exceptions to the usual way messages are first sent and then a response occurs.

A good example of a reflex is the knee jerk reflex. When the tendon just below the knee cap is hit, it automatically causes the lower leg to jerk as a response to the stimulus. Many of our automatic responses are controlled primarily by the spinal cord and not by the conscious portion of the brain.

SPECIAL SENSES

Eyes

The eye can be considered part of the nervous system since it brings information to the brain. Light must pass through several structures in the eye before the information reaches the brain. First, the light passes through an opening in the iris which is called the pupil. The iris regulates the amount of light passing into the eye by making the pupil larger or smaller. It contracts if the light is intense (too bright), Figure AP 51, and opens up if the light is dim, Figure AP 52. Once the correct amount of light has been allowed to pass through the pupil, it passes through the lens to the back of the eye which is called the retina. The retina has specialized light-sensitive cells, some are important in night vision and some are used mainly during the day. The light is then picked up as signals by nerve cells and are sent to the brain. The eyes are therefore continually letting the brain know what is going on outside the body.

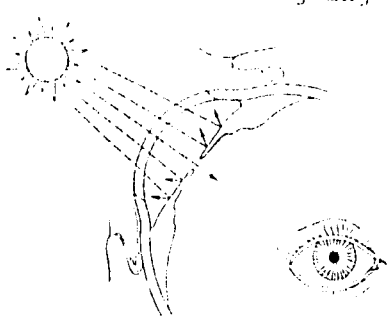

Figure AP 51 - Special Senses; Eye: When there is too much light, the iris makes the pupil smaller.

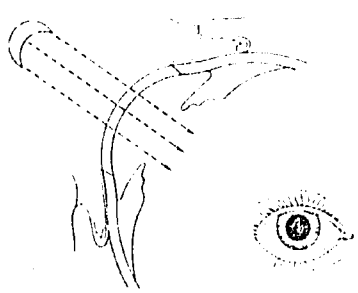

Figure AP 52 - Special Senses; Eye: When there is very little light, the iris dilates the pupil, making the pupil larger.

Structure of Eyes

Externally the eyes are composed of several parts that can be identified on close examination. (Figure AP 53.)

1. Eyelids
3. Eyelashes
4. Lid margins
5. Conjunctiva
8. Iris
9. Pupil

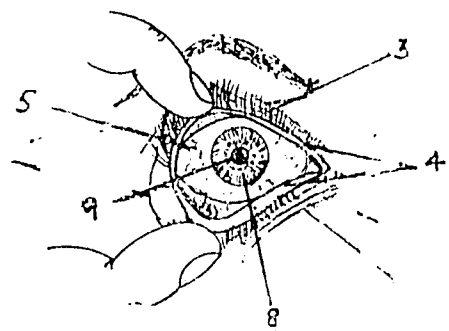

Figure AP 53 - Anatomy Eye: The parts of the eye that can be easily seen upon examination.

Internally they contain further structures to enable the person to see. (Figure AP 54.)

1. Eyelids
2. Tears
3. Eyelashes
4. Lid margins
5. Conjunctiva
6. Sclera
7. Cornea
8. Iris
9. Pupil
10. Lens
11. Retina

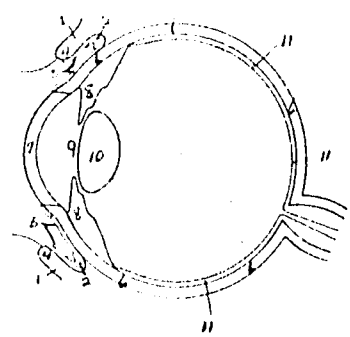

Figure AP 54 - Anatomy Eye: Side view of the eye showing the different parts of the eye.

Ears

The ears are another way of providing information to the brain. Sound travels in waves, and the ear is specialized to convert these waves into signals that the brain can understand. The sound waves first enter the ear. They reach the ear drum, a membrane which vibrates differently with different sounds. Connected to the ear drum are three bones which conduct the sound to the inner ear.

The inner ear has many fine fibres covering its surface, and it is to these fibres that nerve cells are attached. Each time a fibre is stimulated and vibrates, a signal is sent to the brain. The vibrations of the fibres vary according to the different sounds, and this causes many different patterns of signals to be carried to the brain. The brain assembles all of these patterns and interprets them as sound.

Structure of the Ear (Figure AP 55)

The external auditory canal is curved. It leads to the tympanic membrane, and the middle ear which is connected to the inner ear. Leading from the middle ear is the Eustachian tube, it connects the middle ear with the pharynx.

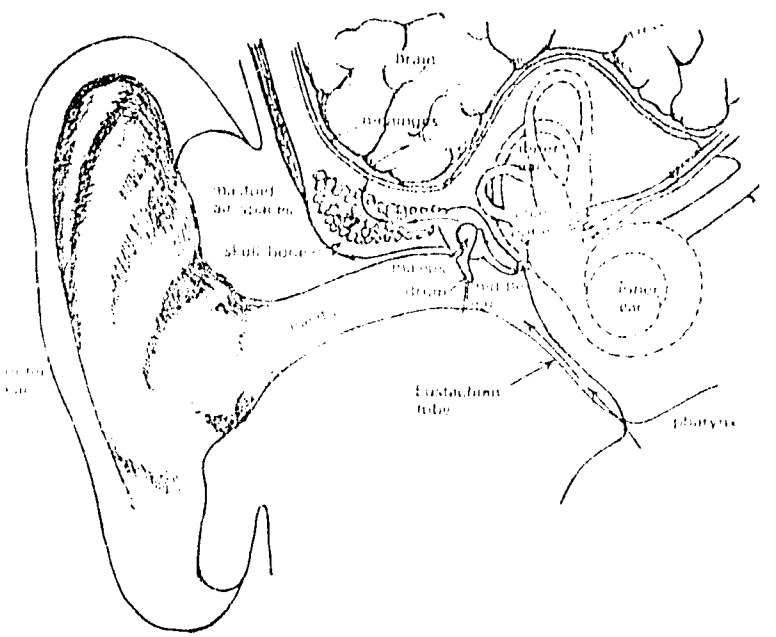

Figure AP 55 - The Ear

Taste and Smell

Very special nerve endings in the mouth and nose provide us with the ability to taste and smell. These nerve endings are sensitive to chemical substances contained in the food we eat and in the air. The nerve endings send the information they receive to the brain where is is interpreted as the different tastes and smells.

The sensory receptor for taste is the taste bud. Because of it we can detect four primary taste sensations: salty, sweet, bitter, and sour. The sense receptor for smell is the olfactory cell. It is the hairs on these cells that actually detect the different odours in the air.

REVIEW QUESTIONS

1. That part of the nervous system which regulates the internal functions of the body is referred to as the _____ nervous system.

   That part of the nervous system which controls movement such as walking, talking, etc. is referred to as the _____ nervous system.

2. Name the three (3) components of the nervous system.

   1)

   2)

   3)

3. The _____ fibre picks up messages from adjoining nerve cells.

   The _____ fibre passes messages to the next nerve cell in the chain.

   These fibres, connected to a central cell body, make up the nerve cell or _____ .

4. How does an automatic reflex such as the knee jerk reflex differ from a conscious movement, such as walking?

5. Which of the following is NOT a function of the brain:

   a. receives information from the spinal cord and sends commands to the muscles.
   b. enables us to think, learn and remember past experiences.
   c. maintains the correct temperature in the body.
   d. maintains the correct amount of water in the body.
   e. controls automatic reflexes.

6. True or False (T or F)

_____ The pupil is the coloured portion of the eye which controls the amount of light that passes into the eye.

_____ The retina is the transparent outer membrane of the eye.

_____ The retina contains special light sensitive cells.

_____ The nerve endings responsible for taste and smell are sensitive to chemical substances in food and in the air.

_____ The four primary taste sensations include: sweet, sour, spicy and bitter.