FS 114

Quinacrine-Induced Pathologic Changes in the Fallopian Tube

ROHIT V. BHATT, M.D., ARTURO APARICIO, M.D., LEONARD E. LAUFE, M.D.,
TIMOTHY PARMLEY, M.D., AND THEORDORE M. KING, M.D., PH.D.

Reprinted from June 1980 Fertility and Sterility

PUBLISHED MONTHLY BY THE AMERICAN FERTILITY SOCIETY, BIRMINGHAM, ALABAMA
Copyright© 1979 The American Fertility Society

FERTILITY AND STERILITY
Copyright © 1980 The American Fertility Society
Vol. 33, No. 6, June 1980
Printed in U.S.A.

QUINACRINE-INDUCED PATHOLOGIC CHANGES IN THE FALLOPIAN TUBE*

ROHIT V. BHATT, M.D.†
ARTURO APARICIO, M.D.†
LEONARD E. LAUFE, M.D.‡
TIMOTHY PARMLEY, M.D.§
THEODORE M. KING, M.D., PH.D.§

International Fertility Research Program, Research Triangle Park, North Carolina 27709, Duke University Medical Center, Durham, North Carolina 27710, and The Johns Hopkins University School of Medcine, Baltimore, Maryland 21205

Sterilization has become the single most prevalent method of family planning on an international scale. It is estimated that approximately 80 million surgical sterilization procedures have been performed since the early 1950s, and the majority of these have been female.[1] The demand for female sterilization is growing, and there is a clear need for a safe and effective nonsurgical method to terminate fertility. A transcervical chemical method is most desirable as it eliminates the need for surgery and thus could be a major contribution to family planning programs.

For the past decade, Zipper and associates[2] have been exploring the use of intrauterine quinacrine, a sclerosing agent, for the tubal ostia. Early experiments using multiple instillations of a quinacrine solution produced an unacceptably high pregnancy rate until the three instillations were completed. Recently, Zipper et al. have employed quinacrine pellets delivered through a modified intrauterine device (IUD) inserter. By compacting the quinacrine into pellets to delay solution time and delivering 250 mg of these quinacrine pellets postmenstrually for 3 consecutive months, Zipper et al.[2] have eliminated the pregnancies which occurred between the instillations of quinacrine solution. The pregnancy rate postinstillation has no significant difference for either the quinacrine solution or the quinacrine pellets. It is of interest to note that in over 400 patients to date no ectopic pregnancy has occurred.

Received September 11, 1980; revised January 14, 1980; accepted January 18, 1980.

*Supported in part by the International Fertility Research Program and the Office of Population, United States Agency for International Development (Grant AID/pha-C 1172).

†International Fertility Research Program.

‡International Fertility Research Program and Duke University Medical Center. To whom reprint requests should be addressed at International Fertility Research Program, Research Triangle Park, N. C. 27709.

§The Johns Hopkins University School of Medicine.

MATERIALS AND METHODS

To determine the specific histologic effects of quinacrine pellets upon the tubal ostia, 23 women awaiting hysterectomies for nonorganic conditions voluntarily accepted the intrauterine instillation of a single dose of 250 mg of quinacrine pellets. Thirty days after delivery of the quinacrine the uterus was removed and blocks of tissue containing the intramural portion of the fallopian tubes were removed from both cornua. The blocks of tissue were then oriented so that the plane of histologic section would be parallel to the axis of the tube, and routine hemotoxylin and eosin sections were prepared.

RESULTS

Twenty-three hysterectomy cases (46 tubes) were studied. The changes identified were easily divided into three groups: group 1 (16 cases), no identifiable damage to the fallopian tube (Fig. 1);

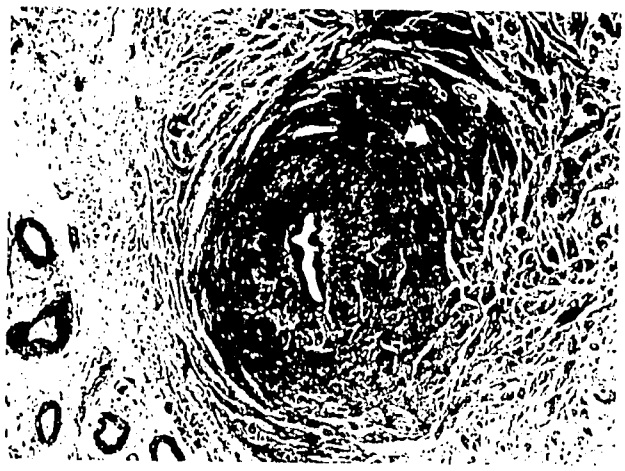

FIG. 1. A tube from group 1 (×65).

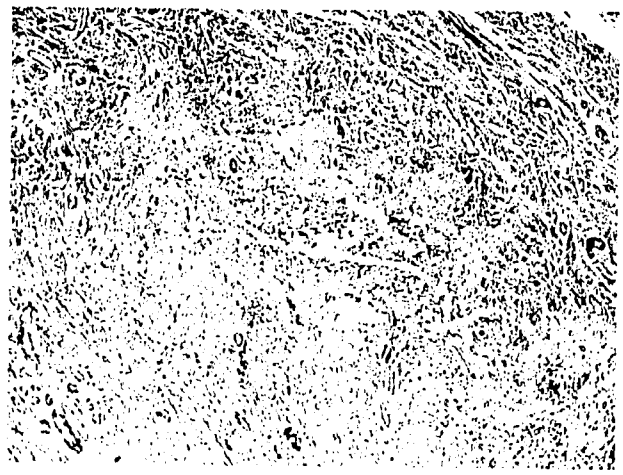

FIG. 3. A tube from group 3 (×65).

group 2 (6 cases), subepithelial hyalination and scarring with involvement of both the lamina propria and the muscularis of the tube (Fig. 2); group 3 (23 cases), destruction of the epithelium of the tube, as well as the changes seen in group 2 (Fig. 3). In one case, tubal damage was associated with a foreign body that appeared to be unrelated to the experiment.

Despite thorough sectioning of the cornual area, the tube could not be specifically identified in four cases. We believe that the tube had been obliterated by the quinacrine and we have included these four cases in group 3. In no case did damage extend beyond the wall of the tube into the myometrium, but in a few it extended a few millimeters into the isthmic portion of the tube.

DISCUSSION

The lesions observed to date appear to be self-limiting, and there appears to be no doubt that quinacrine can induce tubal fibrosis with subsequent permanent tubal occlusion (Figs. 2 and 3).

FIG. 2. A tube from group 2 (×65).

The most striking finding of this limited study was the erratic distribution of pathologic lesions. The presence of a lesion in the tubes studied was not predictable. In a single specimen, the right tube might have revealed luminal obliteration while the left tube appeared to be intact. This finding may relate to the delivery system and may explain the need for three instillations to achieve an acceptable pregnancy rate for a chemical sterilization program. The International Fertility Research Program is undertaking further international clinical trials of three instillations of quinacrine pellets to confirm the findings of Zipper and associates and is exploring alternate delivery systems. An 80% mixture of quinacrine and polyethyleneoxide (PEO) is being molded over T and υ vectors in an attempt to deliver quinacrine directly to the tubal ostia. This mixture goes into solution within approximately 4 hours and should provide a more prolonged exposure of the tubal ostia to the drug. Preliminary results from eight hysterectomy cases are most encouraging and reveal that tubal closure throughout the intramural portion of the tube can be accomplished by using an IUD as the delivery system. These findings will be reported in detail at a later date.

REFERENCES

1. Green CP: Voluntary sterilization: world's leading contraceptive method. Population Reports, Special Topic Monographs, No 2, M-37, 1978
2. Zipper J, Cole LP, Goldsmith A, Wheeler R, Rivera M: Quinacrine hydrochloride pellets: preliminary data on a nonsurgical method of female sterilization. IFRP unpublished data