Edited by William H. Spencer, MD
Pacific Medical Center, San Francisco, CA 94115

Clinicohistopathologic Correlations in Xerophthalmic Ulceration and Necrosis

Alfred Sommer, MD; W. Richard Green, MD; Kenneth R. Kenyon, MD

• Corneal tissue from five eyes of three children with active xerophthalmic keratopathy and stromal loss was studied histopathologically. Stromal dissolution was strikingly focal, sometimes occurring beneath an intact epithelium and often, though not always, accompanied by extensive inflammatory reaction and bacteria.

(*Arch Ophthalmol* 1982;100:953-963)

At least a quarter of a million children with xerophthalmia have corneal involvement develop every year.[1] A majority suffer potentially blinding stromal loss: either sharp-margined ulceration, or localized or total corneal dissolution.[2,3] The pathogenesis of these changes remains obscure. Clinical reports suggest bacterial infection[4] while animal experiments suggest that release of proteolytic enzymes by invading leukocytes[5,6] or regenerating epithelium play an important role. This report presents histopathologic material from three well-documented cases in human subjects.

METHODS

One hundred sixty-two consecutive patients with vitamin A deficiency-related corneal xerophthalmia were studied, treated, and followed up at the Cicendo Eye Hospital, Bandung, Indonesia, between June 1977 and September 1978.[2,3,7,8] Corneal tissue was obtained from a small proportion, either at enucleation or necropsy (always within two hours of death). All corneal material was immediately immersed in Karnovsky's 4% formaldehyde-1% glutaraldehyde fixative, and transported to the Eye Pathology Laboratory of the Wilmer Institute for processing and examination by light, phase contrast, and transmission electron microscopy.

Serum vitamin A levels were determined by the method of Neeld and Pearson,[9] holo-retinal-binding protein (holo-RBP) by that of Glover et al,[10] and transferrin by the technique of Mancini et al.[11] Vitamin A determinations were all carried out within two weeks, and holo-RBP within eight months of collection. Anthropometric status was compared with Western standards.[12]

RESULTS

Histopathologic material was available from five eyes of three patients with active stromal loss. One cornea contained small, sharply circum-

Accepted for publication Sept 29, 1981.

From the International Center for Epidemiologic and Preventive Ophthalmology (ICEPO), The Johns Hopkins Medical Institutions, Baltimore, the Nutritional Blindness Prevention Project, Bandung, Indonesia, and Helen Keller International, New York (Dr Sommer); the Eye Pathology Laboratory, Wilmer Institute, The Johns Hopkins Hospital, Baltimore (Dr Green); and the Department of Ophthalmology, Harvard Medical School, the Cornea Service, Massachusetts Eye and Ear Infirmary, and the Department of Cornea Research, Eye Research Institute of Retina Foundation, Boston (Dr Kenyon).

Reprint requests to Wilmer Institute, The Johns Hopkins Hospital, 600 N Wolfe St, Baltimore, MD 21205 (Dr Sommer).

Three cases of xerop[illegible]imic ulceration and keratomalacia studied histologically. Top left, Case 1, left eye. Two circum[illegible]ed ulcers present inferiorly. Top center and top right, Case 2, right and left e[illegible]es. Both eyes ha[illegible]harp-margined shallow ulcers inferiorly. Bottom left and bottom center, Same eyes of patient 2 c[illegible]ird hospital day. Inferior two thirds of both corneas are necrotic. Bottom right, Case 3, left eye. [illegible]mplete necrosis of all but 1 to 2 mm of peripheral cornea.

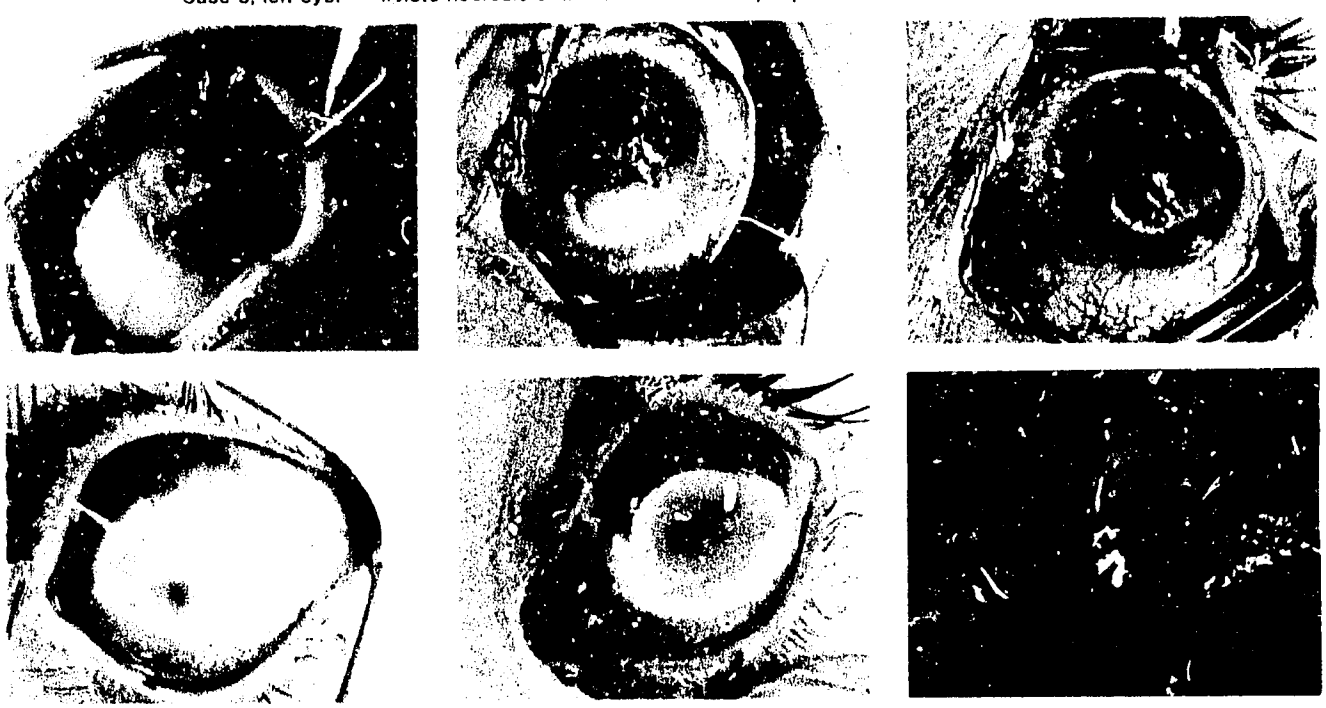

Reprinted from the Archives of Ophthalmology
June 1982, Volume 100
Copyright 1982, American Medical Association

Fig 3.—Case 1, left eye. Top left, Survey light microscopy of peripheral area of lesion illustrates sharp delineation of saucer-shaped ulcerated zone with intact keratinized epithelium (hematoxylin-eosin, ×45). Top right, Phase contrast microscopy of corresponding area shows desquamating keratinized epithelium (asterisk) overlying stroma that is heavily infiltrated by inflammatory cells (paraphenylenediamine, ×650). Bottom, Transmission electron microscopy of this area confirms presence of densely staining keratinized epithelium (E) plus several polymorphonuclear leukocytes in various stages of degranulation, phagocytosis, and degeneration. Stromal collagen (asterisks) shows great fibrillar disorganization and degradation (×13,000).

Fig 1.—Case 1, left eye. Top left, Survey light microscopy shows keratinized corneal epithelium overlying sharply delineated saucer-shaped area of stromal disintegration. Descemet's membrane is disrupted centrally (hematoxylin-eosin [HE], ×30). Top right, Higher magnification of area circled (in top left) shows edematous and keratinized epithelium covering disorganized stroma that contains some fibroblasts and inflammatory cells (HE, ×310). Center left, Light microscopy at margin of lesion demonstrates sharp delineation (between arrows) with normal-appearing stroma to right, but with decreased numbers of keratocytes in marginal zone and stromal dissolution to left (HE, ×100). Center right, Phase contrast microscopy of ulcerated area (above) and normal stroma (below) shows former to contain numerous clusters of inflammatory and fibroblastic cells (paraphenylenediamine, ×650). Bottom, Transmission electron microscopy of ulcerated area (compare with center right) depicts several polymorphonuclear neutrophils and macrophages clustered between disorganized stromal lamellae (×7,500).

Fig 2.—Case 1, left eye. Top left, Light microscopy of lateral posterior aspect of affected area emphasizes sharp delineation between normal stroma (right) and affected area (left), with latter zone having loosely fibrillar lamellae and numerous spindle-shaped fibroblasts (arrowheads) but relatively few inflammatory cells (hematoxylin-eosin, ×320). Top right, Higher-magnification transmission electron microscopy resolves normal diameter and macroperiodicity of stromal collagen fibrils whose lamellar organization has been disrupted (×45,000). Bottom, Transmission electron microscopy resolves attenuated fibroblastic cell centrally with rough-surfaced endoplasmic reticulum, bordered by leukocytes (×11,000).

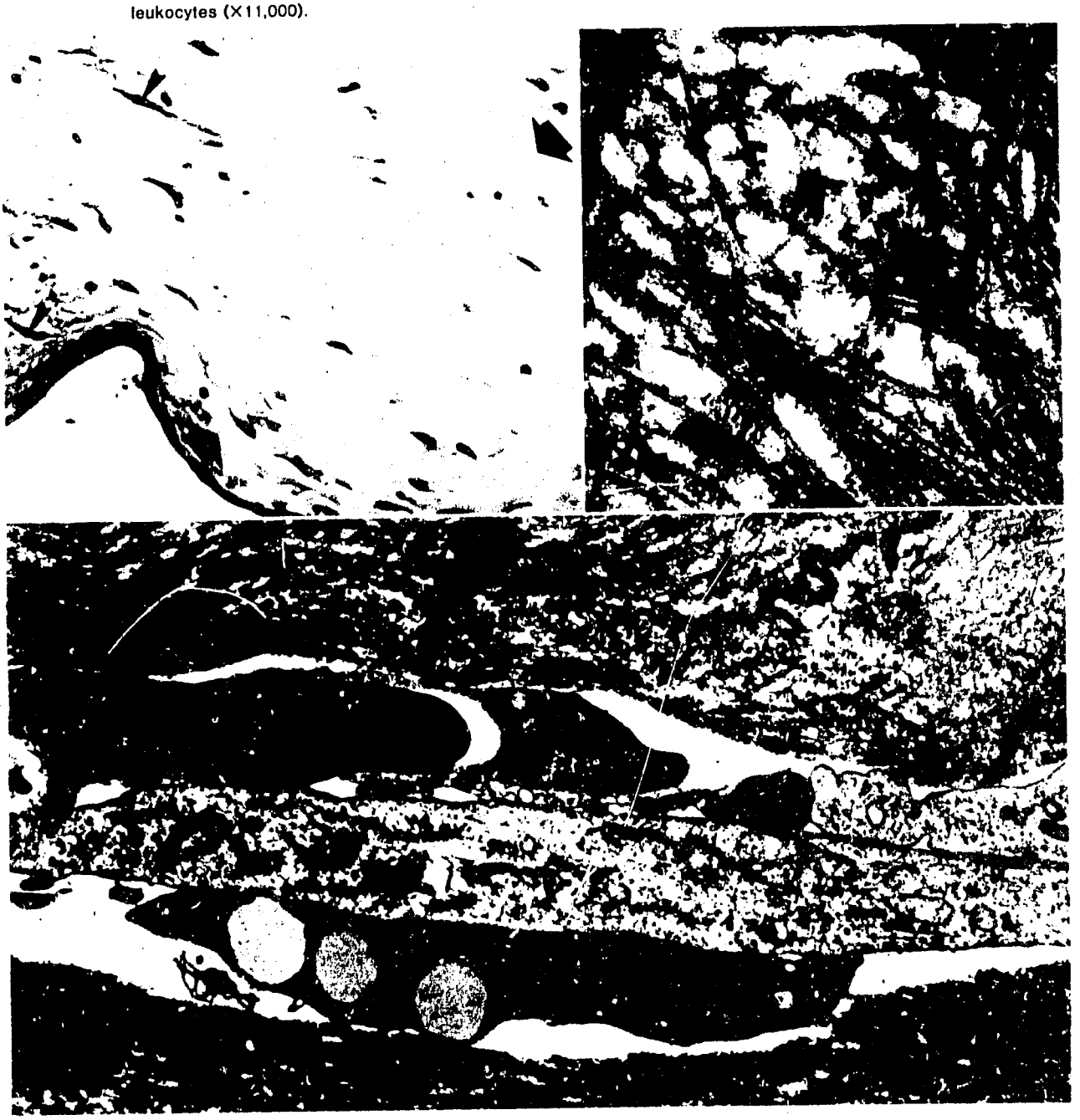

Fig 4.—Case 1, right eye. Top left, Light microscopy shows intact, keratinized epithelium covering fibrinous remnants of stroma (bracketed) that is populated by inflammatory and fibroblastic cells. Pigmented iris is adherent to posterior corneal surface (PAS, ×575). Top right, Phase contrast microscopy similarly illustrates keratinized, thickened epithelial layer overlying approximately 25-μm-thick remnant of stroma (S). Fragment of ruptured Descemet's membrane (DM) is also apparent (paraphenylenediamine, ×800). Bottom, Transmission electron microscopy of this stroma demonstrates active fibroblast (F), polymorphonuclear neutrophil (PMN), and macrophage (M) within degraded stroma (×13,000). Inset (bottom, upper right) resolves filamentary remains of collagen and probable fibrin (×50,000).

Fig 5.—Case 2, right eye. Top left, Light microscopy of corneal biopsy specimen shows intense polymorphonuclear neutrophil infiltration at periphery of extensive stromal necrosis (arrowheads) (hematoxylin-eosin, ×30). Top right, Phase contrast microscopy of this area confirms innumerable polymorphonuclear neutrophils within stroma and disorganized epithelium (paraphenylenediamine, ×350). Bottom left, Higher-magnification light microscopy resolves numerous Gram-negative bacilli (Brown and Hopps, ×1,400). Bottom right, Transmission electron microscopy of degraded stroma shows few fragments of collagen fibrils interspersed among granular material. Electron-dense aggregates of fibrin are also prominent (×27,000).

scribed ulcers. The other four appeared totally necrotic: in two, necrosis occurred just prior to necropsy; in the other two, the process had been present longer.

REPORT OF CASES

CASE 1.—This patient was a marasmic (weight for height, <60% of standard) 1-year-old boy. His serum albumin level was 2.2 g/dL; transferrin level was 40 mg/dL; vitamin A level was 10 μg/dL; and holo-RBP level was 2 μg/mL, all extremely low values. He had a history of night blindness.

The left cornea contained two sharply punched-out, adjacent ulcers (Color Figure, top left). Each was three-fourths deep, 1 to 2 mm in diameter, and surrounded by a thin rim of infiltrate. The anterior chamber was deep and intact. The right cornea appeared to be a total descemetocele, except for its peripheral 1 mm, which was hazy but otherwise normal.

He received 200,000 IU of vitamin A orally on admission and again the following day, as well as frequent topical doses of antibiotics and systemic doses of penicillin G potassium and streptomycin sulfate. By the day following admission, the ulcers in the left cornea were already filling in. By the second day, the ulcerated area appeared more infiltrated. The appearance of the right cornea was unchanged. The child died the morning of the next day and biopsy specimens were taken of both corneas.

Histopathologic examination of sections of the left cornea disclosed a central area where there was a loss of most of the corneal stroma and disruption of Descemet's membrane (Fig 1). A loose fibrillary material covered by edematous and keratinized epithelium bridged this central defect in the posterior aspect of the cornea. The central area exhibited an abrupt loss of Bowman's layer and stroma in a saucer-shaped configuration. At the margin of the lesion, there was an abrupt transition between normal intact collagen, but with decreased numbers of keratocytes, and the central zone of collagen necrosis and dissolution (Fig 1). Between the central area of stromal loss and peripheral normal stroma, the stroma appeared loose, fibrillar, and contained numerous clusters of acute inflammatory cells and fibroblasts, both superficially (Fig 1) and deep (Fig 2).

Sections at the periphery of the lesion

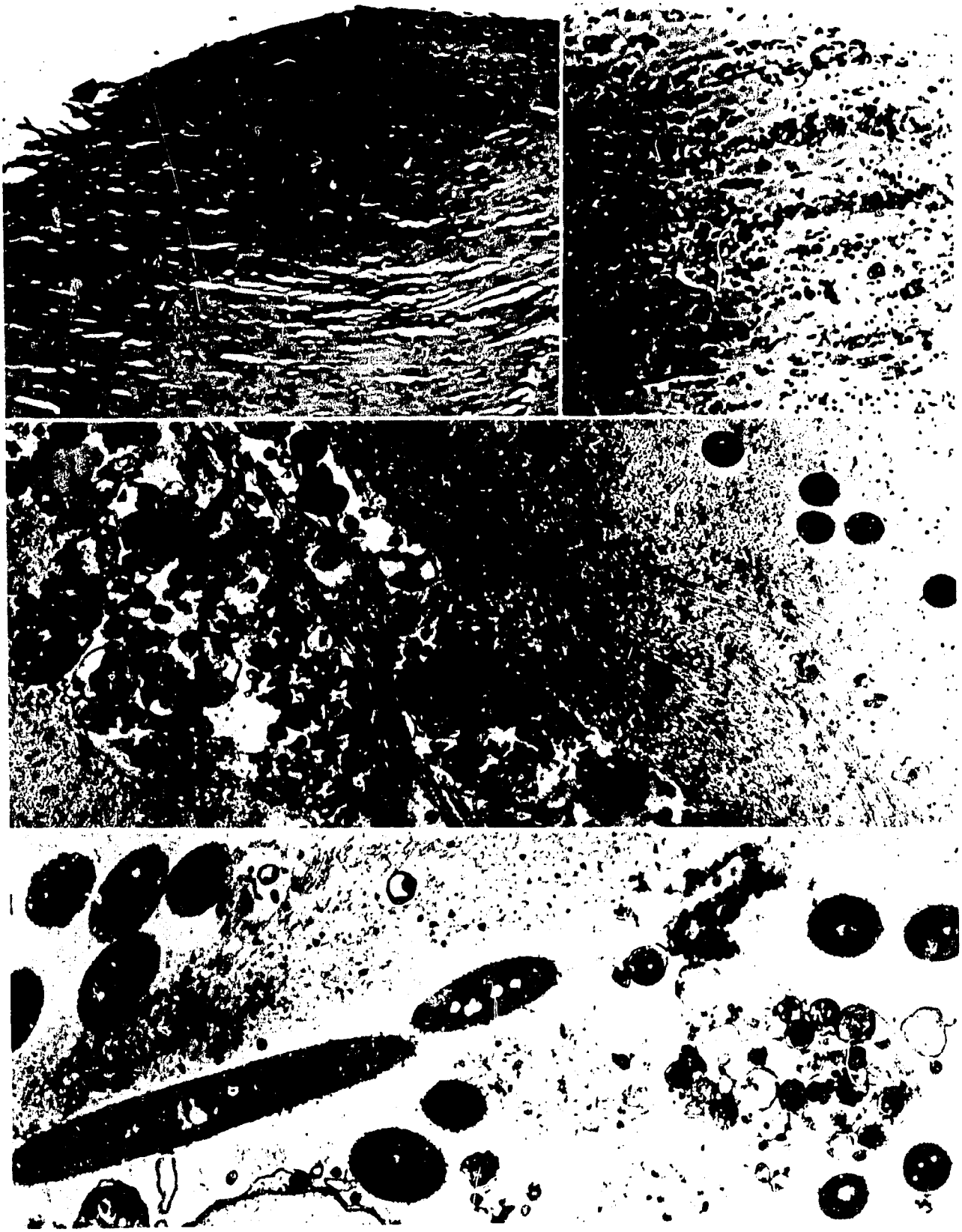

Fig 6.—Case 2, left eye. Top left, Light microscopy illustrates stromal necrosis (arrow) and moderately intense polymorphonuclear neutrophil infiltration (hematoxylin-eosin, ×100). Top right, Phase contrast microscopy of ulcerated area exhibits inflammatory cell debris and innumerable filamentous and spherical microorganisms (paraphenylenediamine, ×700). Center, Transmission electron microscopy of this area shows necrotic inflammatory cellular debris at left and several densely staining microorganisms at right (×10,600). Bottom, At higher magnification, encapsulated filaments of approximately 0.5 μm in diameter are evident interspersed among cellular and extracellular debris (×19,000).

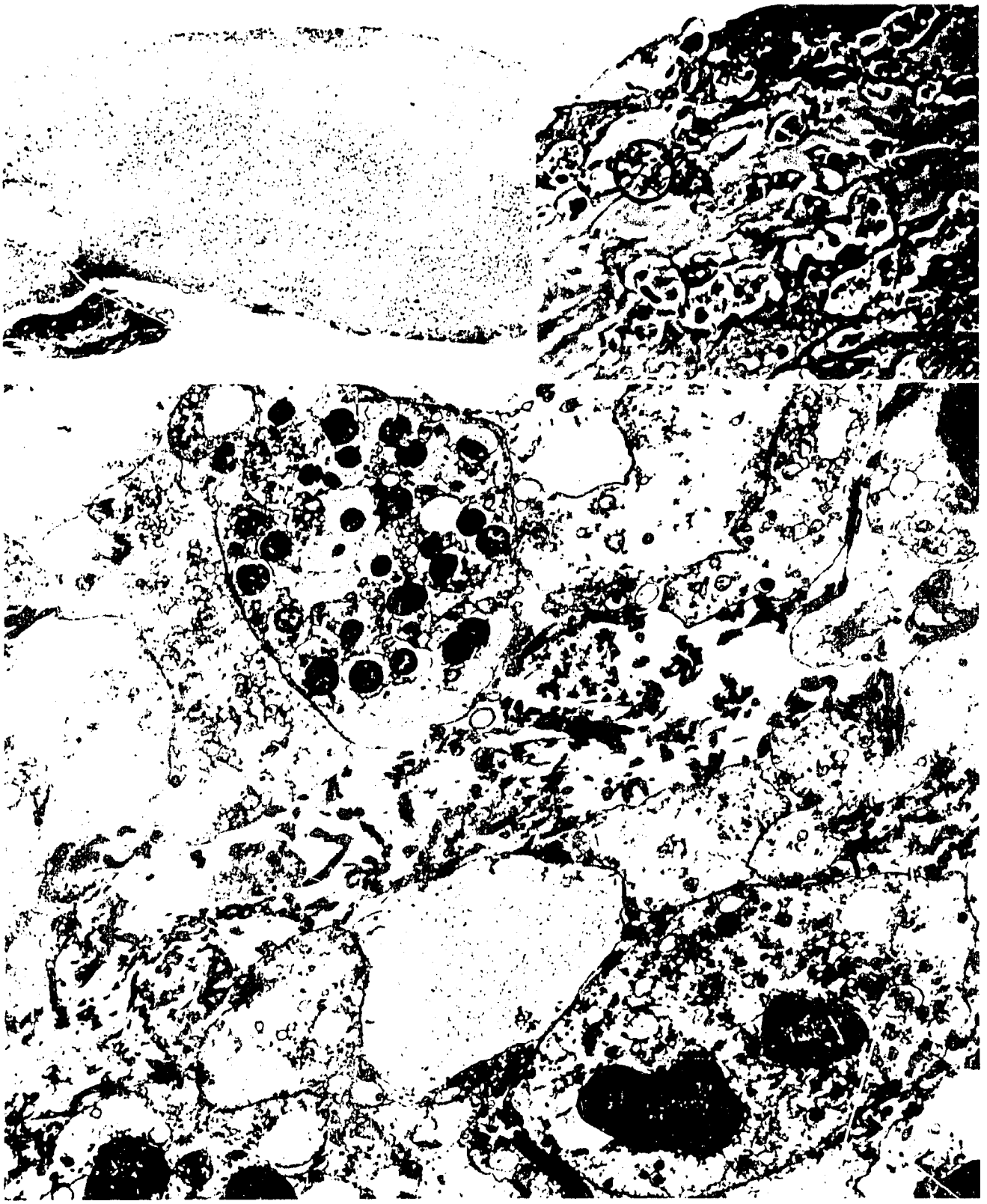

Fig 7.—Case 3, left eye. Top left, Light microscopy of corneal biopsy shows fibrinopurulent exudate (hematoxylin eosin, ×50). Top right, Phase contrast microscopy resolves clusters of bacterial forms (circled) within polymorphonuclear neutrophil-infiltrated stroma (paraphenylenediamine, ×850). Bottom, Transmission electron microscopy of this area shows numerous diplococci within degenerating inflammatory cell. Other polymorphonuclear neutrophils are adjacent. Stroma remains as degraded filamentary aggregates. Remains of stromal collagen appear as dispersed filamentous aggregates (×9,000).

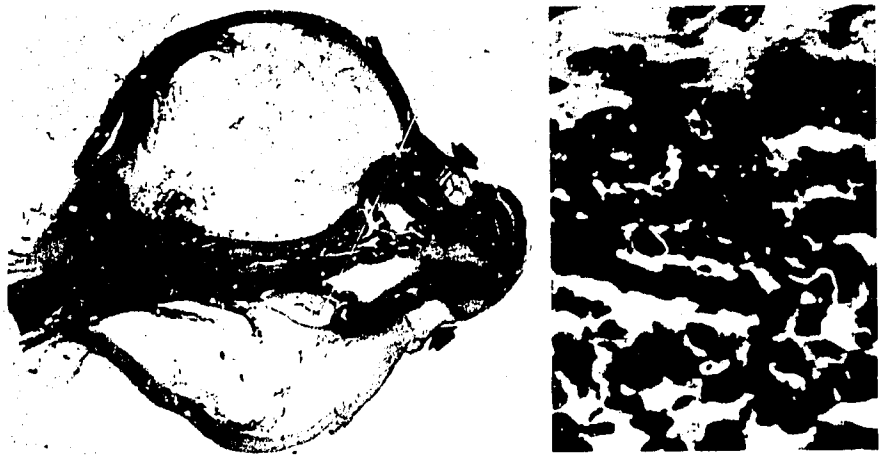

Fig 8.—Case 3, left eye. Left, Enucleated globe exhibits only peripheral cornea (at arrowheads) remaining. Iris is prolapsed centrally and covered by fibrinopurulent exudate. Retina, choroid, and ciliary body are greatly detached. Extensive abscess is present in collapsed and partially prolapsed vitreous (asterisks) (hematoxylin-eosin, ×5). Right, Higher-magnification light microscopy shows numerous Gram-positive cocci within vitreous abscess (Brown and Hopps, ×1,100).

again showed a distinct delineation between the normal and affected area (Fig 3). Hypercellularity due to an increased number of polymorphonuclear neutrophils was noted superficially. Bacteria were not present in any of the sections.

The right cornea showed total dissolution of corneal stroma and consisted of keratinized epithelium, a fibrinous material with fibroblasts, macrophages and neutrophils, and iris adherent to the posterior corneal surface (Fig 4). No bacteria were seen.

CASE 2.—During the ten days preceding admission, an 8-year-old girl had a rise in body temperature, a hemorrhagic rash of her face and extremities, and "white spots" on both corneas. On admission, she was moderately ill and mildly malnourished. Serum albumin level was 2.2 g/dL and transferrin level was 58 mg/dL. Although vitamin A levels were determined during a period of equipment malfunction that tended to inflate values, hers, all run on the same day, were low: 13 μg/dL on admission, 21 μg/dL four hours after her first oral dose of vitamin A, and 9 μg/dL two days (and an additional oral dose) later.

The appearance of both eyes was similar: the conjunctivae were injected; the corneas were hazy, especially inferiorly, and both contained a 2- to 3-mm oval, sharp-margined shallow ulcer 1 to 2 mm above the inferior limbus (Color Figure, top center and top right). Gentamicin sulfate and polymyxin-neomycin-bacitracin ointment (Mycitracin) were administered five times a day to the right eye. The lids remained well opposed, and by the second hospital day, the eyes displayed minimal improvement. On day 3, she became comatose. The lower halves of both eyes were noted to be exposed and the conjunctivae were white and quiet. The lower two thirds of the right cornea was yellow, opaque, and necrotic in appearance (Color Figure, bottom left). The left cornea was gelatinous centrally (Color Figure, bottom center). She died within a few hours, and biopsy specimens were taken from the nasal quadrants of both corneas.

Histopathologic examination of the right cornea showed extensive necrosis (Fig 5) and foci of Gram-negative rods. The peripheral stroma was densely infiltrated by polymorphonuclear neutrophils. Centrally, necrotic stroma was relatively devoid of inflammatory cells.

The left cornea showed a central ulcerated area with near total loss of stroma. The superficial margin of the ulcer showed prominent necrosis. An intense infiltration of polymorphonuclear leukocytes was present throughout the involved stroma (Fig 6). Thinned, keratinized epithelium lined the cornea peripheral to the ulcer. *Actinomyces*-like organisms were present in the superficial portion of the ulcer near the margin (Fig 6).

CASE 3.—This patient was a 4-year-old boy with a history of measles, fever, and diarrhea one month earlier, and a red, tearing, photophobic left eye of two weeks' duration for which he had received antibiotic eyedrops and unknown pills and injections. Serum vitamin A level was 6 μg/dL and albumin level was 2.4 g/dL.

On admission, the conjunctiva and cornea of the right eye were xerotic. The conjunctiva of the left eye was injected, and the cornea was yellow, soft, necrotic, and bulging, with a gelatin-like central protrusion of vitreous or lens (Color Figure, bottom right). The peripheral 1-mm corneal-limbal ring was normal. A small biopsy specimen was taken of the centrally perforated cornea with the use of a strict sterile technique; 100,000 IU of water-miscible vitamin A was given intramuscularly, and preparations were made for enucleation. By the next day, a purulent exudate had developed in the left eye, which was then enucleated.

Histopathologic examination of the biopsy specimen revealed a fibrinous exudate with innumerable polymorphonuclear neutrophils, plus a segment of Descemet's membrane and iris (Fig 7). Some areas contained moderate numbers of Gram-positive cocci.

The enucleation specimen showed preservation of only the peripheral corneal stroma (Fig 8). The central 7 mm of cornea was absent and replaced by ectatic tissue consisting of fibrinopurulent exudate and iris. Epithelium was present only in the periphery of the cornea and was keratinized. There was an abrupt transition between the peripheral, relatively intact cornea and the fibrinopurulent exudate in the dissolved area of cornea centrally (Fig 9). An intense polymorphonuclear leukocytic infiltration in this area accompanied numerous diplococcal bacteria. A virtreous abscess also contained Gram-positive cocci (Fig 8).

COMMENT

Our data confirm, histologically, unique aspects of corneal dissolution in human xerophthalmia. One of the most striking characteristics of xerophthalmic ulceration is its sharply focal nature.[2,3] In each of the five specimens studied histologically, the transition between normal and abnormal stroma was remarkably abrupt.

Clinical reports suggest that xerophthalmic dissolution may proceed beneath an intact epithelium.[2,3,13-15] Wason[16] reported similar changes in the vitamin A-deficient rat. Histopathologic changes in one of our subjects support these clinical observations. Areas of stromal dissolution of both the ulcerated left cornea and necrotic right cornea of the first case were covered by epithelium. Since healing had already begun before the biopsy specimens were obtained, it is possible that in areas where the epithelium is thinned, it had been absent when necrosis originally occurred. In other areas, however, it is thickly keratinized. In at least one area of the ulcerated left cornea, destruction was more severe posteriorly than anteriorly, with rupture of Descemet's membrane despite the clinical appearance of a deep, intact anterior chamber. Collagenases released by regenerating epithelium[17,18] would not explain this pattern of stromal loss, suggesting that interruption of the epithelial layer may not be essential to initiation of corneal melting in xerophthalmia.

Pirie[6] has suggested that collagenases and other proteinases released by infiltrating leukocytes[5,19,20] may be responsible for corneal melting in xerophthalmia. Seng and co-workers[21] recently demonstrated that when corneas are exposed to a thermal burn, those from vitamin A-deficient animals became more heavily infiltrated by polymorphonuclear neutrophils,

Fig 9 —Case 3, left eye. Top left, Light microscopy of enucleation specimen shows intact peripheral cornea (asterisk) that is covered by epithelium. Fibrinopurulent exudate (between arrowheads) replaces central cornea and is lined posteriorly by iris (hematoxylin-eosin, ×100). Top right, Phase contrast microscopy of peripheral cornea confirms keratinized epithelium and inflammatory cells within disorganized stroma (paraphenylenediamine, ×750). Bottom, Transmission electron microscopy discloses active polymorphonuclear neutrophil containing numerous phagocytosed diplococci. Diplococci are also evident extracellularly (×13,000).

produced more collagenase, and were more likely to ulcerate than those from pair-fed control animals. Although several clinical observers have reported corneal infiltration early in xerophthalmic keratopathy,[22,23] they may have confused stromal edema[2,3] with true inflammatory infiltration. Other clinical reports suggested that corneal infiltration is a relatively late change.[2,3,24-26] Histopathologic studies of corneal necrosis in vitamin A-deficient animals revealed intense inflammatory infiltration,[27,28] but ocular and periocular inflammation, early and prominent manifestations of xerophthalmia in rats, are often minimal or absent in the human condition.[2,15,24] Smith et al[29] noted a lack of inflammatory cells in their relatively fresh case of keratomalacia. In our four eyes demonstrating recent, active necrosis, acute inflammatory cells were prominent, particularly at the periphery of the lesions. Two of these eyes, however, contained areas of necrosis relatively devoid of inflammatory infiltrate.

Valenton and Tan[4] found a direct correlation between the severity of corneal involvement and the frequency with which pathogenic organisms were recovered. Necrotic corneas of vitamin A-deficient rats often contain large numbers of bacteria.[27] However, in several clinical studies, positive cultures were not substantially more frequent from ulcerated than nonulcerated eyes,[2,24] and healing was unrelated to the use of antibiotics.[2] Of the two early cases of necrosis in the present series, one (case 1) received systemic doses of antibiotics. Both eyes of this patient and one eye of the other patient (case 2) received topical doses of antibiotics. However, the course of treatment was short and unlikely to account for the absence of organisms from both eyes of the former patient. No doubt secondary, potentially contributory infections do occur, accounting for the panophthalmitis in the most long-standing case (case 3).

The roles of inflammatory cells and bacterial infection in the keratomalacia-like ulceration of the vitamin A-deficient rat cornea following epithelial abrasion have been recently emphasized.[30,31] Studies of human noninfected corneal ulcers have demonstrated the correlation between collagenolytic enzymes and polymorphonuclear neutrophils in tears.[32] The ability of a glued-on contact lens or tissue adhesive alone to prevent stromal ulceration in the chemically or thermally burned rabbit cornea is related to the exclusion of acute inflammatory cells.[19] The presence of bacteria and inflammatory infiltrate in our patients suggests that similar mechanisms may be responsible for at least some aspects of corneal ulceration and necrosis in human xerophthalmia. It is still uncertain, however, whether infection and inflammation initiate the necrosis or merely contribute to it. Loss of keratocytes from the marginal zone of otherwise normal-looking stroma and necrosis deep to an intact epithelium in the left eye of our first patient, absence of bacteria from both eyes of the same patient, and the relative lack of inflammatory cells in some areas of necrosis in our first two patients suggest that as yet undefined biochemical abnormalities consequent to impaired vitamin A metabolism may play an important role.

This investigation was prepared under cooperative agreement DSAN-CA-0267-931-0045 between the Office of Nutrition, US Agency for International Development, and ICEPO (Dr Sommer); supported by research grant 1 R01 EY 01684-3 from the National Eye Institute (Dr Green); by Academic Investigator Award EY00156 from the National Eye Institute, National Institutes of Health; by the Research to Prevent Blindness James S. Adams Award; by a grant-in-aid from Fight for Sight, Inc, New York; by biomedical research support grant PHS 5507RR05527 from the National Eye Institute; and by the Massachusetts Lions Eye Research Fund Inc (Dr Kenyon).

Laila A. Hanninen gave ultrastructural assistance.

References

1. Sommer A, Tarwotjo I, Hussaini G, et al: Incidence, prevalence, and scale of blinding malnutrition. *Lancet* 1981;1:1407-1408.

2. Sommer A: *Nutritional Blindness: Xerophthalmia and Keratomalacia*. New York, Oxford University Press, 1982.

3. Sommer A, Tjakrasudjatma S: Corneal xerophthalmia and keratomalacia. *Arch Ophthalmol* 1982;100:404-411.

4. Valenton MJ, Tan RV: Secondary ocular bacterial infection in hypovitaminosis A xerophthalmia. *Am J Ophthalmol* 1975;80:673-677.

5. Pirie A, Werb Z, Burleigh MC: Collagenase and other proteinases in the cornea of the retinol-deficient rat. *Br J Nutr* 1975;34:297-311.

6. Pirie A: Effect of vitamin A deficiency on the cornea. *Trans Ophthalmol Soc UK* 1978;98:357-360.

7. Sommer A, Muhilal H: Nutritional status in corneal xerophthalmia and keratomalacia. *Arch Ophthalmol* 1982;100:399-403.

8. Sommer A, Tarwotjo I, Muhilal H, et al: Oral versus intramuscular vitamin A in the treatment of xerophthalmia. *Lancet* 1980;1:557-559.

9. Neeld JR, Pearson WN: Macro and micromethods for the determination of serum vitamin A using trifluoroacetic acid. *J Nutr* 1963;97:451-462.

10. Glover J, Moxley L, Muhilal H, et al: Micromethod for fluorometric assay of retinol-binding protein in blood plasma. *Clin Chem Acta* 1974;50:371-380.

11. Mancini G, Carbonara AO, Heremans JF: Immunochemical quantitation of antigens by single radial immunodiffusion. *Immunochemistry* 1965;2:235-254.

12. Jelliffe DB: *Assessment of the Nutritional Status of the Community*. Geneva, World Health Organization, 1966, pp 224-234.

13. Pillat AP: Does keratomalacia exist in adults? *Arch Ophthalmol* 1929;2:256-287.

14. Sweet LK, K'ang HJ: Clinical and anatomic study of avitaminosis A among the Chinese. *Am J Dis Child* 1935;50:699-734.

15. Bloch CE: Clinical investigation of xerophthalmia and dystrophy in infants and young children (xerophthalmia et dystrophia alipogenetica). *J Hyg* 1921;19:283-301.

16. Wason IM: Ophthalmia associated with a dietary deficiency in fat soluble vitamin (A): A study of the pathology. *JAMA* 1921;76:908-912.

17. Slansky HH, Gnadinger MC, Hoi M, et al: Collagenase in corneal ulcerations. *Arch Ophthalmol* 1969;82:108-111.

18. Dohlman CH, Kalevar V: Cornea in hypovitaminosis A and protein deficiency. *Isr J Med Sci* 1972;8:1179-1183.

19. Kenyon KR, Berman M, Rose J, et al: Prevention of stromal ulceration in the alkali-burned rabbit cornea by glued-on contact lens: Evidence for the role of polymorphonuclear leukocytes in collagen degradation. *Invest Ophthalmol Vis Sci* 1979;18:570-587.

20. Johnson-Muller B, Gross J: Regulation of corneal collagenase production: Epithelial-stromal cell interaction. *Proc Natl Acad Sci USA* 1978;75:4417-4421.

21. Seng WL, Glogowski JA, Wolf G, et al: The effect of thermal burns on the release of collagenase from corneas of vitamin A-deficient and control rats. *Invest Ophthalmol Vis Sci* 1980;19:1461-1470.

22. Herbert H: Epithelial xerosis in natives of India. *Trans Ophthalmol Soc UK* 1896;18:103-104.

23. Kirwan EG, Sen K, Bose N: Nutrition and its bearing on preventable blindness and eye diseases in Bengal. *Indian J Med Res* 1943;31:49-62.

24. Kuming BS, Politzer WM: Xerophthalmia and protein malnutrition in Bantu children. *Br J Ophthalmol* 1967;51:649-665.

25. Ten Doeschatte J: *Causes of Blindness in and Around Surabaja, East Java*, thesis. Jakarta, Indonesia, 1968, pp 159-211.

26. Bors F, Fells P: Reversal of the complications of self-induced vitamin A deficiency. *Br J Ophthalmol* 1971;55:210-214.

27. Mori S: Primary changes in eyes of rats which result from deficiency of fat-soluble A in the diet. *JAMA* 1922;79:197-200.

28. Wolbach SB, Howe PR: Tissue changes following deprivation of fat-soluble A vitamin. *J Exp Med* 1925;42:753-777.

29. Smith RS, Farrell T, Beiley T: Keratomalacia. *Surv Ophthalmol* 1975;20:213-219.

30. Sendele D, Kenyon K, Wolf G, et al: Epithelial abrasion precipitates stromal ulceration in the vitamin A deficient rat cornea. *Invest Ophthalmol Vis Sci* 1981;20(suppl):173.

31. Besson M, Van Horn D, Moulder J, et al: Susceptibility to corneal infection in vitamin A deficient rats reared under conventional and gontobiotic conditions. *Invest Ophthalmol Vis Sci* 1981;20(suppl):173.

32. Burnett J, Smith L, Prause J, et al: Acute inflammatory cells and collagenase in tears of human melting corneas. *Invest Ophthalmol Vis Sci* 1981;20(suppl):173.

Printed and Published in the United States of America