NUTRITIONAL BLINDNESS

NUTRITIONAL BLINDNESS

PN-AAL-238

NUTRITIONAL BLINDNESS

Xerophthalmia and Keratomalacia

ALFRED SOMMER, M.D., M.H. SC.

One of the oldest known human afflictions, nutritional blindness remains a major clinical and public health problem. An easily preventable disease, it affects most acutely the depressed populations in developing countries. More than half a million children and countless adults are stricken each year.

The first comprehensive, thoroughly documented book on human xerophthalmia, this text provides a complete description of the pathologic, clinical, and epidemiologic dimensions. Based on an extensive research project directed by Dr. Sommer in Indonesia, it also gives a full review of other studies and programs for prevention.

Major topics considered include the clinical manifestations of the disease and their evolution and diagnosis; the importance of vitamin A-protein interaction in determining the severity of the disease; factors responsible for corneal destruction; the value of oral vitamin A therapy; and steps and procedures for selecting intervention strategies.

Sixty-seven illustrations—including thirty-two color plates—enhance the text. A valuable reference for ophthalmologists, nutritionists, pediatricians, and public health professionals, the book will have special relevance for those working in developing countries.

ISBN 0-19-502977-1

"This is a splendid book. Through use of well planned epidemiological methods a great deal of new information has been collected. This information increases our knowledge of the complex interactions between nutrition, intercurrent disease and vitamin A deficiency that lead to nutritional blindness."

Antoinette Pirie, Hon. Secretary, Xerophthalmia Club

"Each year, amongst the poorest communities of the Third World, at least 200,000 infants are blinded by xerophthalmia. The world cannot afford, and should not tolerate, this totally avoidable scourge. Dr. Sommer's outstanding work and this book point the way to effective control."

Sir John Wilson, Director, Royal Commonwealth Society for the Blind

The Author

Alfred Sommer, M.D., M.H. Sc., is Director, International Center for Epidemiologic and Preventive Ophthalmology, Wilmer Ophthalmological Institute, The Johns Hopkins University. He is also Medical Advisor, Helen Keller International, and Project Scientist, Indonesian Nutritional Blindness Prevention Project. He is author of *Epidemiology and Statistics for the Ophthalmologist* (Oxford 1980) and *Field Guide to the Detection and Control of Xerophthalmia* (World Health Organization 1978).

Jacket design by Egon Lauterberg

Nutritional Blindness

XEROPHTHALMIA and KERATOMALACIA

ALFRED SOMMER, M.D., M.H.Sc.

Director, International Center for Epidemiologic
and Preventive Ophthalmology of the
Wilmer Ophthalmological Institute and the
Johns Hopkins School of Hygiene and Public Health

Medical Advisor, Helen Keller International

New York Oxford
OXFORD UNIVERSITY PRESS
1982

Copyright © 1982 by Helen Keller International, Inc.

Library of Congress Cataloging in Publication Data
Sommer, Alfred
Nutritional blindness.
Bibliography: p. Includes index.
1. Blindness—Nutritional aspects. 2. Xerophthalmia.
3. Cornea—Diseases—Nutritional aspects.
4. Xerophthalmia—Indonesia. 5. Xerophthalmia—Statistics.
6. Vitamin A deficiency in children. I. Title.
[DNLM: 1. Xerophthalmia. 2. Blindness—Etiology.
3. Vitamin A deficiency—Complications. WW 208 S697n]
RE91.S57 617.7'12 81-16771
ISBN 0-19-502977-1 AACR2

Printing (last digit): 9 8 7 6 5 4 3 2 1

Printed in the United States of America

To my wife, Jill
whose patience and understanding
have ensured us home and friends
in diverse cultures

Preface

Xerophthalmia (keratomalacia, nutritional blindness), one of the most ancient of human afflictions, remains a major clinical and public health problem. It affects individuals with liver disease, malnutrition, and a variety of malabsorptive states, but most acutely, depressed populations in developing countries. Half a million or more children probably develop potentially blinding corneal xerophthalmia every year and another 5 to 10 million incur milder forms of the disease.

Several monographs contain chapters that address the problem. But none are devoted to a detailed discussion of the clinical and epidemiologic nature of the disease. This reflects the paucity of carefully controlled observations of the disease in its natural state. In an attempt to rectify this situation and answer major questions still hindering the development of effective intervention programs, an intensive, multifaceted three-year research program was recently concluded in Indonesia. For the first time, correlative clinical, biochemical, therapeutic, and histopathologic studies were carried out in conjunction with large-scale longitudinal, cross-sectional, and case-control epidemiologic investigations. By simultaneously examining many of the major questions from multiple standpoints, these questions can now be answered more definitively, and with greater precision, than was previously possible.

The purpose of the present monograph is to make use of these unique, newly available data in order to resolve many of the apparent inconsistencies and contradictions of earlier reports, and to provide a comprehensive and up-to-date description of xerophthalmia, particularly those aspects critical to its diagnosis, treatment, and prevention. Because the Indonesian data are essential to the discussion, reflect techniques and approaches applicable to other situations, and are not readily available to many workers in the field, they are presented in considerable detail.

It is hoped that this book will prove useful to ophthalmologists, pediatricians, nutritionists, scientists, and public health workers engaged in designing and implementing programs aimed at curbing xerophthalmia and reducing the terrible and needless toll of nutritional blindness.

Baltimore, Maryland A.S.
May 1981

Acknowledgments

This volume is the result of nearly a decade of interest and involvement in nutritional blindness. During that period I have had the opportunity to examine the problem, in varying detail, in half a dozen countries and to benefit from the advice of many times that number of colleagues. The annual deliberations of the International Vitamin A Consultative Group have been a particular delight and a source of valuable information.

Much of the analysis rests upon results of the Indonesian Nutritional Blindness Prevention Project, in which I was privileged to take part. It was especially satisfying as the research data were speedily transformed into practical intervention strategies. I am grateful to Helen Keller International for sponsoring the project, to the Ministry of Health, Government of Indonesia for undertaking it, and to the Office of Nutrition, United States Agency for International Development for underwriting much of its cost.

It was an intensive undertaking, involving at times over 100 individuals and multiple national, international, and bilateral organizations. Among the many people involved, two deserve special mention. Pak Tarwotjo was my counterpart and close friend. His wise council and hard work contributed, more than anything else, to the devotion and esprit de corps that characterized the staff. I wish him well in his new post as Director of Nutrition for the Ministry of Health, Government of Indonesia. Dr. Susan T. Pettiss, HKI's Director of Blindness Prevention, was very much a member of the project's full-time staff, though formally headquartered in New York. She played a major role in the project's conception and realization. As a social worker, she never let us forget that our primary goal was not pedantic research, but preventing young children from going blind.

Senior members of the staff included Professors J. S. Sulianti and A. A. Loeden, successive Directors General of Indonesia's National Institute for Health, Research, and Development; Dr. R. Soebekti, Director General of Community Health; Dr. Sugana Tjakrasudjatma, Director of the Cicendo Eye Hospital; Drs. G. M. Hussaini, N. Emran, E. Djunaedi, Hermawan, and S. Sedibyo, ophthalmologists; Drs. T. Tamba (deceased), E. Suroto, J. Asikin, and Z. Sulaeman, pediatricians; Dr. U. Rafei, Director of Health Services, West Java; Dr. D. Karyadi, Director, National Nutrition Research Center; Messers. S. Effendi, D. Muksin, S. Latinulu, B. Budiman, and D. Kartono, nutritionists. Dr. Muhilal was Director of Biochemical

Services, Mr. J. Susanto, Director of Statistical Services, Mr. T. Soegiharto, Chief Administrative Officer, Mr. Carl Fritz, Liaison Officer, and Mrs. Apong Amanah, Head Nurse.

I owe my thanks to Drs. Martin Forman, Irwin Hornstein, John McKigney, and members of successive Site Visit Teams of the office of Nutrition, USAID; and to Mr. Thomas Niblock and his staff of the USAID Mission, Jakarta.

Outside collaborators included Professor John Glover of the University of Liverpool; Drs. Richard W. Green and Kenneth R. Kenyon of the Eye Pathology Laboratory, Wilmer Institute, Johns Hopkins Hospital; and Mr. Hugh Donovan of the Computer Section, Institute of Ophthalmology, University of London. Drs. Antoinette Pirie, James Olson, and Hugh Taylor, and Mr. David Andrews offered valuable suggestions for the preparation of this monograph. Ms. B. J. Ottey typed the many drafts with some help and much frustration from the Wilmer computer. Hoffman La Roche, Basle, supplied vitamin A compounds while UNICEF and the World Health Organization supplied laboratory equipment and logistical support. Bacteriologic studies were conducted in collaboration with Bio Farma, Bandung, and parasitologic examinations by the Public Health Laboratories, University of Padjadjaran.

Preparation of this monograph was carried out under contract No. AID-ta-c-1321 (Helen Keller International) and Cooperative Agreement No. CA-0267-931-0045 (ICEPO, Johns Hopkins) with the Office of Nutrition, United States Agency for International Development.

Contents

I Introduction

1. Background, 3

Historical development, 3
Nomenclature, 4
Biochemical considerations, 6
The Indonesian project, 8
Interpretation of epidemiologic data, 15

II Clinical considerations: diagnosis, classification, histopathology, and pathogenesis

2. Retinal involvement, 19

Nightblindness, 19
Fundus lesions, 24

3. Conjunctival involvement, 28

The conjunctiva in precorneal xerophthalmia, 29
The conjunctiva in corneal disease, 48
Evolution and diagnosis of conjunctival xerosis, 51

4. Corneal involvement
I. Clinical considerations, 55

Punctate keratopathy, 58
X2: Corneal xerosis, 60
X3: Stromal loss, 65

5. Corneal involvement
II. Clinical-histopathologic correlations, 76

X2: Corneal xerosis, 76
X3: Corneal ulceration/necrosis, 77
Clinical-histopathologic schema of corneal change, 83

6. Corneal involvement
III. Etiologic significance of local and systemic factors, 89

Local factors, 89
Systemic factors, 96

III Risk factors and associations

7. Nutritional status, 107

Vitamin A status, 107
Hypoproteinemia, 109
Vitamin A–protein interaction, 110
General nutritional status—height and weight, 116

8. Contributory and precipitating diseases, 123

Diarrhea/gastroenteritis, 126
Respiratory tract disease, 128
Measles, 129
Worm infestation, 136
Urinary tract disease, 137
General health status, 138

9. Vitamin A intake, diet, and stores, 139

Prenatal period, 139
Neonatal period, 140
Weaning and early childhood, 144

IV Epidemiologic considerations

10. Clustering, 153

Age, 153
Sex, 155
Location, 157
Socioeconomic status, 159
Seasonality, 161

11. Magnitude and distribution, 162

Incidence of active corneal disease, 163
Incidence and spontaneous cure rates, 164
Countrywide rates and numbers of cases, 165
Validity of WHO prevalence criteria, 168
Worldwide distribution of the problem, 172
Worldwide magnitude of the problem, 174

12. Blindness and mortality, 176

Resultant blindness, 176
Mortality, 179

V Treatment and prevention

13. Treatment, 187

Systemic vitamin A, 188
Protein and calories, 205

Topical vitamin A, 207
Surgical intervention, 208

14. Prevention, 209

Periodic dosing, 209
Fortification, 216
Increasing natural dietary intake, 218

Appendix I: The Indonesian nutritional blindness prevention project, 223

Background and methods, 223
Study I, 225
Studies II/III, 229
Study IV, 234
Problems in data analysis and coverage, 240

Appendix II: 1981 revision of WHO recommendations, 243

Appendix III: Detailed descriptions of selected cases of corneal xerophthalmia (Study II), 245

References, 249

Index, 277

1 Introduction

1. Background

> Never whilst memory lasts, can one obliterate the mental pictures of those pitiful little bundles of marasmic, apathetic humanity. . . . Their faint, feeble, fretful wails ring still in ones ears today, summoning up visions of wasted stick-like limbs, of distended abdomens, of dry, inelastic, scurfy, scaly skins, of hair scanty, brittle and dry, and of sightless desiccated eyes. . . .
>
> R.H. Elliot, 1920

> We feel confident that these cases of xerophthalmia reported by Mori and Bloch should be looked upon as a deficiency disease not hither to recognized in its true relationship to diet. It is not, as these authors believe, a "fat starvation" which produces the condition, but a lack of the unidentified dietary factor, Fat-Soluble A, which occurs in just those foodstuffs which they observed to possess curative properties.
>
> E.V. McCollum, 1917

> One of the worst scandals of our time is that . . . young children go permanently blind every year because of the lack of minute amounts of retinol in their diets. . . . There is an abundance of retinol . . . collecting and processing it . . . to meet the recommended intakes of all children in the world would be a trivial and cheap technical achievement in comparison to sending a man to the moon. A much more difficult task is that of distributing it to the children in need and of educating their mothers to its value.
>
> *FAO Handbook on Nutritional Requirements*, 1974

Historical development

Clinical manifestations of vitamin A deficiency are among the oldest recorded afflictions of mankind. Reversible nightblindness was known to both the ancient Egyptians [1] and Greeks, as was the therapeutic value of animal liver. It is unclear when related changes in the front of the eye were first recognized, but it had certainly occurred by the early 1700's when corneal destruction was noted following severe systemic diseases like measles [2]. By 1816 the first animal model already existed: dogs "starved" on sugar and distilled water developed perforating corneal ulcers [3], much as was observed in "ill-nourished infants" [4,5]. Hubbenet, [6], in a report that preceded Bitot's [7] but that proved to be both shorter and more prescient, accurately described the progression of chronic disease from night-

blindness through conjunctival and finally corneal involvement, attributing it to a faulty diet.

Blessig [8] was one of many authors who observed the complete spectrum of xerophthalmia during the long Lenten fasts. Numerous reports in severely malnourished patients in Europe [9–13] and elsewhere [14–18] soon followed.

In a particularly well-documented study, Snell [19] demonstrated the specific curative effects of cod liver oil on both nightblindness and Bitot's conjunctival spots. By 1892, meat, milk, and cod liver oil were being recommended for treatment of corneal ulceration and keratomalacia [20]. In 1904 Mori [18] published an exhaustive clinical and epidemiologic description of *Hikan*, as the disease was known in Japan. He recognized the entire sequence of ocular and systemic changes; the central role played by deficiency of fats, particularly fish liver oils, from either faulty diet or faulty absorption; the importance of diarrhea, kwashiorkor, and other contributory and precipitating events; and the specific curative powers of cod liver oil administered either orally or intramuscularly.

Shortly afterward, it was found that animals fed "pure" diets of fats, starch, protein, and inorganic salts developed inflammatory ocular disease and corneal ulceration [21–22] and ceased to gain weight. Administration of certain "accessory factors" present in the lipid fractions of milk, eggs, butter, and cod liver oil restored them to health [23–27]. McCollum termed the critical factor "Fat-Soluble A" [28]. Both he [29–30] and Goldschmidt [27] associated the animal disease with human xerophthalmia. Bloch's [31–32] clinical and epidemiologic observations confirmed their supposition. Thus by 1920 the disease and its cause and cure were already well established. It was not until many years later that vitamin A was first crystallized [33] or xerophthalmic patients shown to have decreased levels in their blood [34].

Nomenclature

One of the most confusing aspects of xerophthalmia is its terminology. Different names have been applied to the same condition, and more confusing still, the same term has been applied to different conditions [35].

Nightblindness has been called "nyctalopia" [19] (Greek: *nux*, night; *alaos*, blind; *ops*, eye) and "hemeralopia" [6,7,36] (Greek: *hemera*, day), terms which have exactly opposite meanings. We will refer to it simply as "nightblindness."

"Xerosis" means, quite simply "dryness" (Greek: *xeros*). Hence "conjunctival xerosis" refers to a dry-appearing conjunctiva, and "corneal xerosis" a dry-appearing cornea. Differences arise over which clinical changes justify these appellations, particularly as they relate to vitamin A deficiency. Previous uses, and those suggested by the results of the Indonesian Project, are discussed in appropriate sections. Other pathologic processes, by interfering with mucus or tear production, may also give rise to "dry eye." These are exceedingly rare in children in developing countries. Unless otherwise noted "xerosis" will refer specifically to changes consequent to vitamin A deficiency.

Loss of Stroma (corneal thickness) in vitamin A deficiency is variously referred to as "ulceration" or "keratomalacia." In common ophthalmic parlance "ulcer" (Latin: *ulcus*) refers to any circumscribed loss of corneal substance, and is therefore an appropriate description of many forms of corneal damage encountered in the disease. Strictly speaking, "keratomalacia" means corneal "softening" (Greek: *keras*, horn; *malakos*, soft), but has come to mean the characteristically full-thickness, often limbal-to-limbal, necrosis observed in the severest cases, thus differentiating this striking, almost pathognomonic alteration from the more commonplace ulceration seen in vitamin A deficiency and a variety of other diseases. While there may be some value in continuing this practice, primarily because of their differing prognosis for useful vision, it has so confused the literature that a recent, authoritative publication referred to xerophthalmia and keratomalacia as distinct and separate diseases [37].

"Xerophthalmia" is itself a purely descriptive term. In fact, "xerophthalmia" was first coined by Schmidt (cited in MacKenzie, ref. 4) nearly 200 years ago as a nonspecific term for dry eyes entirely unrelated to the nutritional disease under discussion. It has since become synonymous with this nutritional disease [38]. A problem still remains in deciding which clinical manifestations justify application of the term. To some investigators, like Blegvad [39], xerophthalmia included conjunctival and corneal changes but not nightblindness, while to others it meant the corneal changes [40], conjunctival changes [41], all changes except "softening of the corneal tissue" [42], concomitant presence of both conjunctival and corneal changes [43,44], and any manifestation of vitamin A deficiency, ocular or not [45]. We will apply the term to any ocular manifestation of the disease, including nightblindness [35,46].

In 1974 participants at an international conference on vitamin A deficiency proposed a standard classification of xerophthalmia, which has since

Table 1–1. Xerophthalmia classification (WHO, 1976) [47]

Classification	Signs
	Primary
X1A	Conjunctival xerosis
X1B	Bitot's spot with conjunctival xerosis
X2	Corneal xerosis
X3A	Corneal ulceration with xerosis
X3B	Keratomalacia
	Secondary
XN	Nightblindness
XF	Xerophthalmia fundus
XS	Corneal scars

found wide acceptance (Table 1–1) [47]. It will be repeatedly referred to in the course of our discussions, and modifications proposed.

Biochemical considerations

Detailed discussions of the biochemistry and metabolism of vitamin A are beyond the capabilities of the author and scope of this book, and the reader is referred to Moore's classic treatise [48] and recent reviews [49–51]. A brief summary will prove useful, however, in understanding the clinical and epidemiologic facets of xerophthalmia.

Vitamin A is a fat-soluble substance found in ester form (usually as retinyl palmitate) in animal foods and dairy products. After ingestion it travels to the small intestines where it is hydrolyzed to the alcohol (retinol), incorporated into mixed micelles, and absorbed into the mucosal cells. Carotene, the naturally occurring progenitor of vitamin A, is synthesized by plants. The most potent of the provitamin A carotenoids is all-*trans* beta-carotene. Beta-carotene is absorbed into the mucosal cells and split into two molecules of retinaldehyde, most of which is promptly reduced to retinol. Dietary lipids, pancreatic enzymes, and bile salts play an important role in the intraluminal digestion and assimilation of these agents.

Although some retinol is absorbed directly into the portal system, most is reesterified, enters chylomicra, and makes its way to the bloodstream via the lymphatics. In the liver retinyl ester in the chylomicron remnant is taken up by lipocytes and probably by parenchymal cells as well. During its uptake the ester is hydrolyzed and then is reesterified, largely with palmitic acid. Retinyl palmitate is then stored in vitamin A containing lipid

globules in the lipocytes and to some extent in the parenchymal cells. Roughly 95% of the vitamin A in the body is stored in the liver, which accounts for animal and fish livers being such potent sources of the vitamin.

Free retinol is a highly active, membrane-toxic substance, ordinarily circulating in extremely small amounts. Instead, retinol is released from the liver in combination with a specific transport protein, apo-RBP (retinol-binding protein). The complex, composed of a single molecule of retinol and a single molecule of apo-RBP is termed holo-RBP, and in humans circulates in a 1:1 molar ratio with prealbumin. Holo-RBP receptor sites on target cells bind the complex. After the retinol enters the cell the apo-RBP is released from the receptor site and ultimately degraded in the kidney. Interference with protein metabolism of the liver can depress RBP synthesis and holo-RBP release.

Retinol's role in the visual cycle of the photoreceptors is remarkably well worked out. It also participates in RNA and glycoprotein synthesis and is required for proper differentiation and maintenance of a variety of epithelial structures. But the precise mechanism by which vitamin A deficiency causes the conjunctival and corneal changes in xerophthalmia is yet to be determined.

A variety of body tissues and biochemical techniques can be used for assessing vitamin A status. With due consideration to the size of the sample and the area from which it is obtained [52], vitamin A concentration in the liver is an accurate reflection of total body stores [53]. But liver specimens are rarely available, except in autopsy material, and provide no information on the amount of vitamin A available to peripheral target cells. Serum samples suffer neither of these limitations, but even when protein status is adequate to support RBP synthesis, serum vitamin A is a poor reflection of liver stores, except when these are severely depleted [54–56].

There are several techniques for measuring vitamin A content of serum [57–59]. Ordinarily total vitamin A (retinol plus retinyl esters) is measured, although the two can be separated on a simple column and reported individually [60–61]. Unfortunately, "total" vitamin A is sometimes referred to as "retinol," a practice which should be abandoned. Although none of these procedures is complex, they require careful attention to detail. Results from different laboratories have often varied significantly. A new technique, employing high-pressure liquid chromatography [62] may improve reproducibility.

Immunoassay of retinol-binding protein (RBP) [63–64] is a simple technique capable of being carried out almost anywhere in the world. Unfor-

tunately, it fails to distinguish between RBP which is complexed with-retinol (holo-RBP), and RBP which is not (apo-RBP). Even in severe vitamin A deficiency, substantial quantities of denatured apo-RBP continue to circulate [65–66], although the "total" level of RBP will be depressed.

Holo-RBP can be assayed independently of apo-RBP [65]. But the technique is complex, and available in only a few laboratories at present. It probably provides the most accurate index of the circulating level of physiologically active retinol, but, as will be seen, may prove less sensitive than "total vitamin A" for distinguishing between various degrees of severe xerophthalmia.

The Indonesian project

The xerophthalmia "story" did not always unfold as clearly as the historical outline would suggest, and numerous controversies still exist. It was to settle these, and provide more precise and definitive information about the factors responsible for the large numbers of cases arising in the "developing" areas of the world that the Indonesian Project was undertaken. This section will serve as a brief introduction to that project. A more detailed description is provided in Appendix I.

The Indonesian archipelago contains 13,000 islands straddling the equator, ranging in size from tiny uninhabited coral reefs to such giant land masses as Irian Jaya (the Indonesian half of New Guinea). The present population, which exceeds 130 million, is concentrated on the islands of Bali, Sumatra, Sulawesi (formerly the Celebes), Kalimantan (formerly Borneo) and especially Java, the cultural and administrative capital.

The people are basically of Malay stock. Over 90% claim adherence to Islam, but animistic and Hindu/Buddhist influences are strongly felt and women often attain high social and administrative positions. Eighty-five percent of the population is rural, living in rather large villages without electricity, protected water supplies, or adequate means of waste disposal. Enteric and respiratory-tract infections are therefore common. Per capita income in the 1970's was roughly $100 per year, but has been rising, somewhat unequally, with increasing exploitation of oil and other mineral resources. Annual population growth rate in the mid-1970's was estimated at 2.5%, but is probably falling in the face of a remarkably successful family planning program. In short, Indonesia has all the characteristics of a poor tropical country, but is not as poor as those on the Indian subcontinent or

most of those in Africa, and has had some success in improving its people's lot.

Indonesia is one of the traditional "homes" of xerophthalmia. Many of the local languages and dialects contain specific terms for nightblindness. One of the earliest, most astute descriptions of xerophthalmia came from Bandung [68] and Indonesian patients were the first to have serum vitamin A levels measured [34]. Large numbers of cases still occur [69–71]. This ambitious project was undertaken because skilled biochemists, clinicians, and public health officials were interested in doing something about it. The early history of the project and its administrative and logistical arrangements have been described in detail [72]. Three major studies were undertaken.

Study I: Longitudinal field study

The first study to be initiated was a two-year, prospective longitudinal field investigation of 4600 preschool-age (zero to six year old) children in six villages of a district in West Java known for its high endemicity of xerophthalmia. The children were reexamined every three to four months, for a total of seven examination rounds. In addition to the clinical examination (Fig. 1–1) and recording of interval illnesses, the weight and height of each child were measured (Fig. 1-2). Dietary histories were collected on all children with evidence of xerophthalmia, age/sex/neighborhood-matched controls, and a predetermined systematic subsample of all children enrolled in the study. During the first round, blood samples were collected from these same abnormals and controls, and on alternate children selected for the subsample.

Studies II/III: Hospital-based study

A team of similar composition to that in Study I examined all individuals attending the Cicendo Eye Hospital Clinic with evidence of xerophthalmia (including a history of nightblindness) (Fig. 1-3). An elaborate ocular and general examination was performed, historical, dietary, and socioeconomic data collected, and specimens obtained for biochemical and microbial studies. On some, a small conjunctival biopsy was performed, and the procedure repeated, at a predetermined interval after treatment, on the other eye. Final follow-up was obtained on all children by visiting the homes of

Fig. 1-1. Routine eye examinations in the field were performed with a handlight.

Fig. 1-2. Children were weighed on a "dacin" (local bar balance).

Fig. 1-3. A "papoose board" was convenient for restraining children while examining them at the slitlamp biomicroscope.

Fig. 1-4. With effort, study teams in the countrywide survey could reach almost half the sample sites by vehicle.

those who had not been seen within two months of completion of the study.

Study II was concerned with 162 consecutive patients having active corneal xerophthalmia. Four additional cases had already received both antibiotics and vitamin A and their lesions had begun to resolve, and two cases with active measles had stromal lesions atypical for pure xerophthalmia. Eleven children with active corneal disease of clearly other etiologies were excluded from the study.

All children were offered hospitalization on a special ward where they received the best dietary and systemic care available.

After stratifying the cases by severity of corneal involvement, a subsample was systematically selected for control studies. The team visited each of their communities, and identified age/sex/neighborhood-matched controls who were encouraged to return to Cicendo. Sixty such controls were recruited, nine of which proved, on careful examination, to have active xerophthalmia. The 51 clinically normal children belonged to 33 corneal cases. Where more than one control was available for an index case, their average value (for the parameter in question) was used for each paired comparison: for measurement data (e.g. serum carotene) the mean (μ) was employed; for attribute data (rates) fractional rates of positivity were calculated. The severity of corneal disease among the 33 abnormals for whom there were matched controls was similar to that of all 162 abnormals in the Study (Table 1-2).

Table 1–2. Severity of corneal disease among all abnormals (X2/X3) and those with matched controls (Study II)

	Percent distribution	
Category	All abnormals (n = 162)	Abnormals with matched controls (n = 33)
1	14.8	15.2
2	14.8	15.2
3	3.1	3.0
4	27.8	33.3
5	3.1	0.0
6	21.0	12.1
7	8.0	18.2
8	7.4	3.0
1–3	32.7	33.3
4–5	30.9	33.3
6–8	36.4	33.3

From Sommer et al. [259].

Table 1–3. Therapeutic response of cases of conjunctival xerosis (Study III)

Outcome	Number	Total
Responded within 2 months[1]		50
Cured	36	
Improved	14	
Unresponsive within 3 months		9
Indeterminate response		24
Inadequate early follow-up	18	
Miscellaneous	6	
Total cases examined		83

1. Responsive lesions include those with definite but incomplete resolution (improved) and those which totally disappeared (cured) following one or more doses of 200,000 IU vitamin A.

From Sommer et al. [101].

Study III involved 83 consecutive cases of conjunctival xerosis/Bitot's spots, as well as 21 cases of isolated nightblindness. Patients were originally randomly allocated to receive a high (200,000 IU) or low (700 IU) dose capsule, all receiving an additional high-dose capsule after three months. Because several low-dose recipients deteriorated alarmingly, this trial was discontinued.

In 50 of these 83 cases of conjunctival xerosis/Bitot's spots, the lesions diminished in size ("improved") or disappeared entirely ("cured") within two months of receiving a single oral dose of 200,000 IU vitamin A (Table 1-3). Nine cases failed to respond in the slightest for at least three months after receiving two, and occasionally a third massive dose ("unresponsive"). In 24 patients the response was difficult to determine: 18 had inadequate early follow-up; 4 low-dose recipients improved spontaneously (presumably on an improved diet); and in 2 patients the initial lesions were minimal and their diagnoses and response to therapy uncertain.

Study IV: Countrywide survey

Three teams carried out a xerophthalmia prevalence survey in the 23 provinces representing over 96% of the Indonesian population (Fig. 1-4). The rural sample was an accurate representation of the rural population. The urban sample was limited to slums, where the vast majority of urban cases were thought to reside.

Procedures were similar to those employed in the other field investigations.

Table 1–4. Age distribution of study population, Study IV (40/41)

Age (years)	Males		Females		Total	
	n	%	*n*	%	*n*	%
0	2905	15.7	2907	16.5	5812	16.1
1	2934	15.9	2842	16.2	5776	16.0
2	3142	17.0	2852	16.2	5992	16.6
3	3110	16.8	2989	17.0	6099	16.9
4	2835	15.3	2767	15.7	5602	15.5
5	3237	17.5	2929	16.6	6166	17.1
unkn.[1]	314	1.7	299	1.7	613	1.7
Total	18,475	99.9	17,585	99.9	36,060	99.9

1. Under 6 years but age unknown or miscoded.

36,060 preschool-age children (98% of all three months to five year-old children residing in 21,349 eligible households) were examined in 254 sample sites (Table 1-4).

358 children had Bitot's spots. The number of matched controls available, 340, was slightly smaller. Twenty-one children had active corneal disease (X2/X3). Conjunctival xerosis/Bitot's spots were present in all but one of these.

151 children had corneal scarring. In 47 it almost certainly represented healed xerophthalmia (XS).

Anthropometric and dietary data were missing on 2% of all children examined, leaving 35,274 children, including all abnormals, matched controls, and members of the random sample, for comparison. In the analyses of anthropometric data these totals are slightly reduced, by exclusion of individuals on whom the values were obviously in error (out of range).

Because of programming problems, dietary data (aside from breast feeding) are not available on the matched controls. Dietary intake of the abnormals is therefore compared to that of the random sample. The resulting loss in precision is likely to be small: for almost all variables on which data are available on matched controls the results differed little from those of the larger group of randomly sampled children.

Analysis

Because of equipment failure and the necessity that all vitamin A analyses be carried out within two weeks of collection of the sera, vitamin A determinations are not available on Study II/III patients for the period of July

16, 1977 to January 14, 1978. Similarly, holo-RBP determinations are not available for the period after May 15, 1978.

Interpretation of epidemiologic data

Previous attempts at defining factors (individual, familial, or environmental) associated with the development of xerophthalmia have often been hampered by the absence of suitable controls. Use of age/sex/neighborhood-matched controls provides the best opportunity for identifying those factors responsible for the development of xerophthalmia in some children, but not in other children living under similar conditions. In Study II, where the number of controls is small, paired comparisons are generally employed. In Study IV, where larger numbers are available, non-paired, grouped comparisons are used. Relative risks are calculated by both case-control and prospective methods [73–74].

In evaluating the presentation in the following chapters, four limitations to these analytical techniques should be borne in mind.

a. An important risk factor may be so common in the community at large that it is impossible to detect a statistically significant difference in its prevalence among the finite numbers of abnormals and cases available for comparison.

b. Alternatively, a risk factor may be so uncommon, that although it contributed to disease in a significant proportion of cases at large, it was not present in the small numbers of corneal cases in Study II for which there are matched controls.

c. While matching is an effective means of eliminating extraneous variables, it can obscure the significance of factors closely associated with those used in the matching process. As we shall see, vitamin A deficiency has a strong tendency to cluster by neighborhood. Since abnormals and controls were matched by neighborhood, some of the factors responsible for vitamin A deficiency may appear less significant than they actually are.

d. Just because a factor is associated with xerophthalmia does not necessarily mean it contributes to the disease. For example, protein-energy malnutrition (PEM) may be more common among abnormals than controls because PEM increases the risk of xerophthalmia; because children who consume inadequate quantities of vitamin A-containing foods also consume little of anything else; or because vitamin A deficiency is one of the factors that contributes to PEM.

II Clinical considerations: diagnosis, classification, histopathology, and pathogenesis

2. Retinal involvement

> Man's knowledge . . . of the vast universe which appears in the heavens each night, comes in the first place from the stimulation, by their light rays of delicately poised molecules of vitamin A.
>
> T. Moore, 1957

> The attention of the State Public Health Officials was first attracted by the fact that a young woman . . . , while returning home at dusk, walked straight into a well.
>
> S. Rao et al., 1953

Nightblindness (XN) and fundus specks (XF) were, respectively, the first and last of the principal clinical manifestations of vitamin A deficiency to be described. Despite the common practice of treating them as distinct and separate entities of only marginal significance [47], they both arise in the retina and probably reflect different degrees of impaired visual pigment metabolism, and they are as sensitive and specific indicators of vitamin A deficiency as are the clinical signs of the anterior segment (conjunctiva and cornea).

Nightblindness (XN)

The influence of nutrition on scotopic vision has long been recognized. Physicians of ancient Egypt and Greece were familiar with nightblindness. By the end of the 19th century it was appreciated that nightblindness occurred primarily in the poorer strata of society, especially during periods of dietary deprivation [6,75–77]; was exacerbated by photic stress [78,79]; and could be cured by ingestion of liver or liver oils [6,19,80]. In fact, it was through their association with nightblindness that xerophthalmic changes of the outer eye were first appreciated [6,7,19,79]. Thus the symptom, and its cure, were recognized before vitamin A was discovered and the nature of the biochemical processes understood.

Fridericia's observations, [81] that vitamin A was required for regeneration of visual purple (rhodopsin) explained both the nutritional nature of nightblindness and its exacerbation by photic stress. Subsequent studies, primarily by Wald and co-workers, elucidated the visual cycle [82]. Vitamin A combines with specific proteins, called opsins, to form the photosen-

sitive visual pigments of rods and cones [49]. In vitamin A deficiency rhodopsin levels decline, rod thresholds rise, and nightblindness ensues [83].

Despite the tremendous avidity of the retina [84], particularly its pigment epithelium, [85–87] for retinol, impaired dark adaptation appears to be the earliest clinical sign of vitamin A deficiency. In both vitamin A deprived rats [83,88] and human volunteers [89–91], elevated rod thresholds and nightblindness precede other ocular manifestations of deficiency. Impaired dark adaptation has proven useful in diagnosing subclinical vitamin A deficiency among older children and adults suffering from a variety of malabsorptive states [92–96]. Even frank, often severe, nightblindness during the second and third trimesters of pregnancy [97–99] characteristically occurs in the absence of other stigmata of vitamin A deficiency.

It is likely that impaired dark adaptation occurs equally early in young children. Rather than being unreliable, secondary evidence of vitamin A deficiency [178], an appropriately elicited history of nightblindness can be highly specific for active disease.*

As befitting an earlier sign, twice as many children examined during the first round of Study 1 had a history of nightblindness as had conjunctival xerosis (Table 2-1) [100]. Mean serum vitamin A levels among cases of isolated nightblindness, isolated conjunctival xerosis, and the two combined were significantly lower than among age/sex/neighborhood-matched controls (Table 2-2). Yet the mean serum vitamin A level, and proportion of individuals with "adequate" [47] levels was only slightly higher among

*This conclusion is reflected in the 1981 revision of the WHO prevalence criteria (Appendix II).

Table 2–1. Nightblindness and Bitot's spots as independent screening criteria for xerophthalmia (Study 1)

Clinical status[1]	n	Mean Serum vitamin A (μg/dl)[2]	SE	Proportion total cases identified
XN	273	13.4	0.35	84%
X1B	132	12.6	0.46	41%
XN and/or X1B	325	13.4	0.31	100%

1. XN includes cases with and without conjunctival xerosis (X1A), Bitot's spots, or X1B. X1B includes cases with and without nightblindness (XN).
2. Serum vitamin A values were unavailable on 3 of 273 cases of nightblindness (XN), 2 of 132 cases of conjunctival xerosis with Bitot's spots (X1B), and 4 of 325 cases with either.

From Sommer et al. [100].

Table 2–2. Serum vitamin A level by clinical status (Study I)

Clinical status[1]	n	Mean (μg/dl)	SE (μg/dl)	Percent of individuals: Deficient (0–9 μg/dl)	Low (10–19 μg/dl)	Adequate (≥20 μg/dl)
XN(+), X1B(−)	174	13.9	0.45	27	55	18
Controls	161	17.6	0.62			
XN(−), X1B(+)	51	13.4	0.77	31	57	12
Controls	45	17.1	1.19			
XN(+), X1B(+)	79	12.1	0.56	38	53	9
Controls	76	18.3	1.00			
Random sample	268	20.0	0.48	9	38	53

1. XN = nightblindness; X1B = conjunctival xerosis with Bitot's spots; XN (+), X1B (+) = XN, and X1B coexistent in the same child.
Mean serum vitamin A and proportion of cases with "adequate" levels higher in less severe lesion: XN (+), X1B (−) > XN (−), X1B (+) > XN (+), X1B (+), $p < .05$ by linear trend.
Difference in mean serum vitamin A between each group of abnormals and their matched controls, $p < .001$.
Difference in collective mean serum vitamin A of controls and random sample, $p < .001$.

From Sommer et al. [100].

cases with an isolated history of nightblindness than among children with either isolated conjunctival lesions or the two combined ($p < .05$ by linear trend). Even those with levels above an arbitrarily "adequate" 20 μg/dl may have been abnormal. In carefully controlled depletion studies, impaired dark adaptation has been documented at vitamin A levels between 20 and 30 μg/dl [90–91]. Furthermore, of the 210 children said to be nightblind and tested in the field 97% had grossly impaired scotopic vision [100]. The mean serum vitamin A level of the test negatives was identical to that of the test positives (13.7 μg/dl), suggesting the parent's history was a more accurate predictor than our clinical test. Some children with a positive history, especially those with a negative test, were said to be nightblind only after a photic stress, such as flying a kite on a sunny day. Dr. Dinesh Sinha noted the same phenomenon in W. Bengal (personal communication).

If impairment of dark adaptation precedes conjunctival changes, most children with active vitamin A related xerosis should also be nightblind. This appears to be the case [101]. On the basis of their response to vitamin A therapy, cases of conjunctival xerosis in Study III were divided into three groups: those in whom the conjunctival lesions disappeared or improved within two months and those in whom the lesions remained unchanged for at least three months (refer to Table 1-3). Eighty-three to ninety-one per-

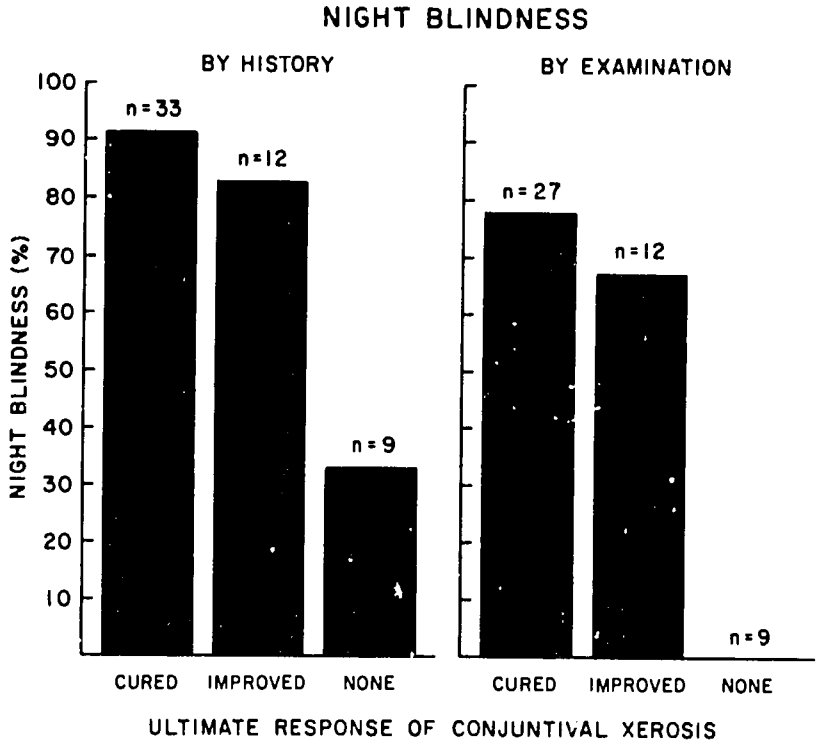

Fig. 2-1. Nightblindness was more frequent among individuals whose conjunctival xerosis disappeared or improved following vitamin A therapy than among those who failed to respond to treatment (disappeared: nonresponsive, and improved: nonresponsive, each $p < .001$ by history and examination.) Study III. (Drawn from Sommer et al. [101])

cent of those with responsive lesions claimed to be nightblind (Fig. 2-1), an extraordinary proportion considering the severity of impairment required before patients are usually aware of the problem [90,91,102]. This rate is considerably higher than among cases of conjunctival xerosis in Study I (61%), probably because those aware of their nightblindness are more likely to seek help than those who are not [79].

Excluding two cases of retinitis pigmentosa and one of Best's disease, 21 individuals presented to Study III with an isolated history of nightblindness. Surprisingly, only 12 (57%) had a positive test, suggesting that the method by which scoptopic vision was assessed in the clinic was far less sensitive than that in the field. Nonetheless, 67–78% of patients with-vitamin-A-responsive conjunctival xerosis enrolled in Study III had a posi-

tive test (Fig. 2-1). This suggests that they suffered more severe impairment of scotopic vision than those with an isolated history of nightblindness. As in Study I, the history of several children with a negative test indicated that they were nightblind only after experiencing a photic stress. In one case this was provided by "watching too much television," an interesting commentary on the disassociation possible between economic advancement and cultural determinants of vitamin A deficiency.

Cases of corneal involvement (Study II) provided a strikingly similar picture. Data on nightblindness were available on 147 (91%) of the cases, most of the others being too young for parents to have noticed interference with scotopic vision. Fifty-seven percent (83/147) were said to be nightblind. The rate was higher among those without stromal disease (75% vs 47% of those with the disease, $p < .01$) (Table 2-3). But there was no difference in the proportion of cases in which nightblindness had been noted for at least three weeks prior to presentation, suggesting that blepharospasm, common and severe in stromal cases, obscured nightblindness of more recent onset. This is probably one reason why a history of nightblindness was less common among cases of corneal disease (Study II) than among cases of purely conjunctival involvement (Study III) (57% vs 89%, $p < .001$). Additionally, corneal cases tend to be younger, hence the consequences of impaired scotopic vision are less apparent; if parents fail to recognize nightblindness,

Table 2–3. History of nightblindness among cases of active corneal xerophthalmia (Study II)[1]

Corneal severity (category)	History available (n)	History positive	
		≥ 3 weeks (%)	Total (≥ 1 day) (%)[2]
Xerosis (1–3)	51	33	75[3]
Local ulcer/necrosis (4–6)	79	39	45
Complete necrosis (7–8)	18	44	56
Total	147	36	57

1. See Chapter 4 for definitions.
2. Positive [illegible] xerosis (categories 1–3) vs ulcer/necrosis (categories 4–6), $p < .01$.
3. Includes 2 cases, where duration of nightblindness uncertain, excluded from numerator and denominator in calculating proportion positive at ≥3 weeks.

their children may become sufficiently depleted to develop corneal disease; and in many instances, systemic diseases cause a precipitous deterioration in vitamin A status and onset of corneal involvement, probably earlier in the course of deficiency than ordinarily occurs in uncomplicated, gradual depletion. Clinical assessment of dark adaptation was not possible in most cases of active corneal disease.

Impaired dark adaptation and nightblindness of nutritional origin respond rapidly, usually within a few hours, to administration of vitamin A [88,90,91,103–105]. In nearly all our cases nightblindness had disappeared by the next examination, usually one or two days after the initial dose of vitamin A.

Fundus lesions (XF)

At the turn of the century it was noted that xerophthalmic eyes occasionally contained fundus abnormalities [79,106–108]. In 1922 Wright [109] described these as a fine, white mottling, resembling, to some degree, retinitis punctata albescens. In 1928 Uyemura [110] reported the first of his cases in which the changes disappeared following vitamin A therapy [111].

On ophthalmoscopy the retinal lesions appear to be small, discrete, yellowish-white dots deep to the vessels and distributed about the equatorial region and periphery of both eyes [110–114] (Plate 1). Although they occasionally approach the disc [104,113], the lesions remain outside the temporal vascular arcades. On close examination they have an irregular appearance suggesting mottled depigmentation at the level of the pigment epithelium, an impression supported by fluorescein angiography [104].

The more numerous the lesions the brighter and more distinct their appearance and the more posterior their extent—changes related, at least in part, to the chronicity and severity of vitamin A deficiency. In the case of self-imposed dietary deprivation followed by Fells and Bors [115], the lesions became more numerous over time. The prevalence of fundus changes is more common among cases of corneal xerosis (Study II) than among cases of vitamin-A-responsive conjunctival xerosis (Study III); in both cases prevalence increases with age (Fig. 2-2). Teng's [116] results were similar: lesions were more common among patients with concomitant nightblindness and conjunctival xerosis than among those with nightblindness alone, the prevalence rising to a plateau by age ten.

In most instances the lesions fade or disappear within one to three months of vitamin A therapy (Plate 2) [104,110,111,113,114,116]. They can

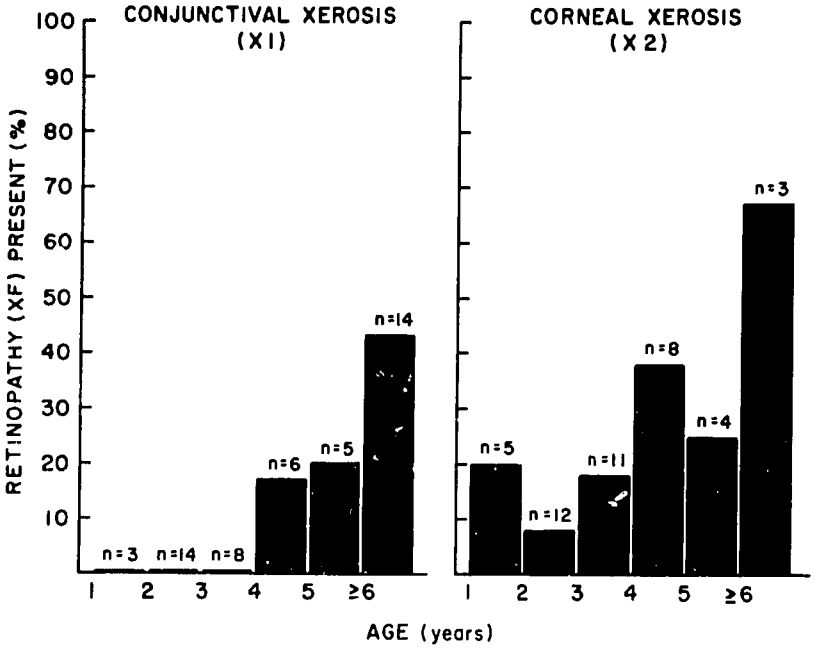

Fig. 2-2. Xerophthalmic retinopathy was more prevalent among cases of corneal xerosis than among cases with purely vitamin A responsive conjunctival xerosis. It was also more prevalent in those four years and older than in younger children (for conjunctival xerosis, $p < .01$; for corneal xerosis, $.1 > p > .05$). Fine, peripheral lesions of questionable significance were present in three additional children with conjunctival xerosis (ages 2, 3, and 4 years) and one with corneal xerosis. Studies II/III.

also recur, probably with greater alacrity than the initial episode. A 24-year-old otherwise healthy well-nourished woman presented with nightblindness, severe conjunctival and corneal xerosis, and extensive retinopathy (Plate 1). Visual fields (measured on day 5, following corneal clearing) were severely constricted in a butterfly distribution that mirrored the shape of lesion-free retina (Fig. 2-3). She received a total of 600,000 IU oily vitamin A, one-third parenterally and the remainder by mouth, over a three-day period. By day 4 nightblindness had disappeared, and by day 14 the visual fields had returned to normal. Somewhat surprisingly, the retinal lesions became brighter and more distinct during this period. By two months, however, they had largely disappeared, especially posteriorly (Plate 2), though faint window defects were still visible on fluorescein angiography. By the time she was next seen a year later, Bitot's spots and

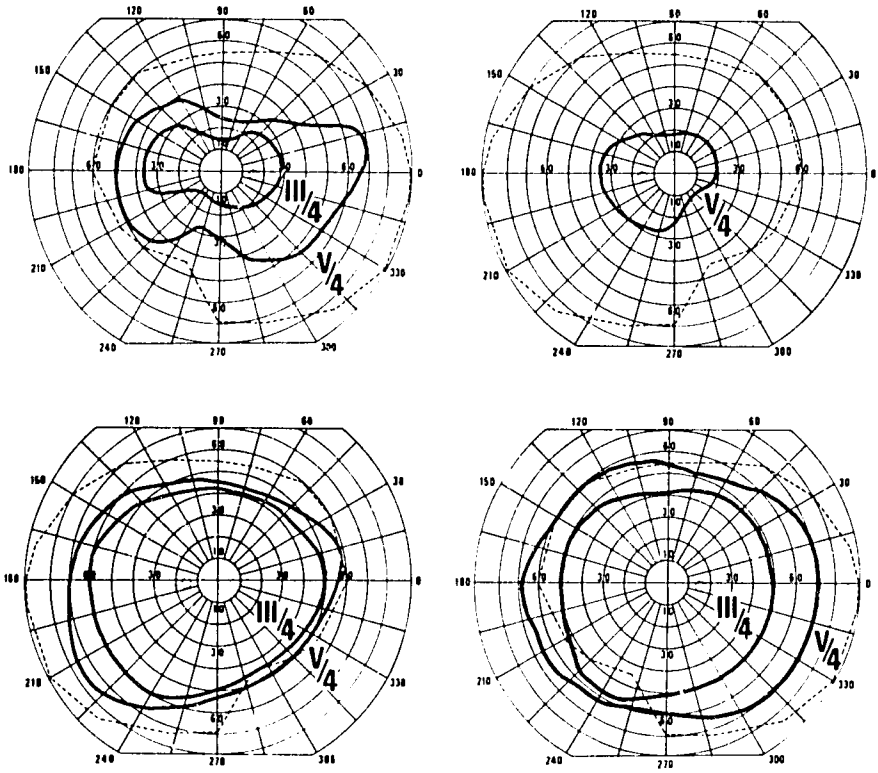

Fig. 2-3. Top: Visual fields of right and left eyes are severely constricted in a 24-year-old Indonesian woman five days after receiving vitamin A for corneal xerosis. The corneas were already clear, and vision 20/40, at the time these were performed. Bottom: Nine days later visual fields were normal. (From Sommer et al. [104])

retinopathy as florid as at the initial examination had developed in both eyes. Since she could not have been vitamin A deficient for very long, the reappearance of symptoms suggests either a predisposition to the retinopathy of vitamin A deficiency, or persistent pigmentary alterations enhancing visibility of the new lesions.

In all likelihood, retinal lesions represent disrupted outersegments of rods and cones and accompanying alterations in the retinal pigment epithelium (RPE) [104]. In vitamin-A-deprived animals, impairment of dark adaptation is followed by decreased production of photoreceptor outersegments [117] and declining levels of the opsins of which they are largely composed [83,118]; degeneration of both rods and cones, beginning with

the distal portions of their outersegments [83,118–122]; and alterations and loss of pigment epithelium [83,121]. The latter appears to be related to the inanition and generalized interference in cellular metabolism that accompanies severe vitamin A deficiency, rather than to specific interference in visual pigment synthesis [103]. Although there is a paucity of correlative histopathologic studies [123], one monkey that developed typical retinal lesions was found to have degenerated rods, cones, and RPE [121]. In traumatic retinopathy, which may have a similar clinical and angiographic appearance [124], retinal whitening (comotio) in owl monkey eyes was related to disruption of outersegments of rods and cones and their phagocytosis by cells originating in the RPE. Finally, functional defects and clinical recovery in man closely parallel the reparative process in experimental animals.

Degeneration of a large proportion of rods and cones should decrease visual thresholds in the affected area, causing alterations in the visual fields. Although Uyemura [110], Fuchs [112], and Teng [113] all reported normal visual fields in their patients, vitamin-A-responsive constriction has been noted in deficient subjects [79,125], including two carefully studied cases with fundus lesions [104,115]. In one [104], the defect was absolute and congruent with the area of retinal lesions. Recovery occurred in three stages: nightblindness disappeared within four days, presumably because vitamin A was now available to regenerate rhodopsin in outersegments lying outside the area of structural damage; visual fields returned to normal between days 7 and 14, probably as still-viable rods and cones in the affected area produced sufficient opsin (and outersegment) to support function; and retinal lesions disappeared within one to three months as the histologic alterations were reversed. A similar time course has been demonstrated for functional and histologic recovery in vitamin A deficient rats [83,103,120].

3. Conjunctival involvement

> (These spots) became a pathognomonic sign of nightblindness to me as none of the hemerolopia patients was without them.
>
> C. Bitot, 1863

> Taking all the available evidence into consideration it seems highly unlikely that a primary vitamin A deficiency gives rise to Bitot's spots.
>
> F.C. Rodgers, 1963

None of the clinical signs of xerophthalmia has elicited as much controversy and confusion as those of the conjunctiva. In large part this reflects three separate influences: historical accident; the desire to identify earlier, subtler evidence of disease; and the inconvenient fact that some of these changes are encountered in the absence of active vitamin A deficiency.

Partially through convenience and partially by accident, "Bitot's spot" acquired an identity all its own. By the early 1800's, conjunctival xerosis had already been described among patients with severe liver disease [4], though these observations were not widely known or accepted until Bass [126] published his treatise on "Ophthalmia Hepatica" many years later. A similar fate befell Hubbenet. In 1860 [6] he described progressive epithelial dryness and scaling of the conjunctiva and cornea in ill-fed nightblind soldiers that responded to ingestion of beef liver. Instead of receiving acknowledgment as the landmark observation it was, his report was largely overlooked by his contemporaries.

In 1863, Bitot [7] described localized silvery-white foamy conjunctival lesions in nightblind but otherwise healthy children, and three years later von Graefe [9] reported conjunctival xerosis and corneal destruction in children suffering from encephalitis. Von Graefe's failure to recognize the connection between Bitot's "hemerolopic spot" and his own cases was credited, as long ago as 1883 [12], with fostering an artificial division between these two clinical presentations. Despite subsequent reports suggesting that they represented the same condition [8,18,20,31,76] the dichotomy has largely persisted.

The situation has not been helped by doubts cast upon the significance of Bitot's spot.

Bitot claimed that his spots invariably preceded or accompanied nightblindness, and that nightblindness never occurred in their absence. Having

witnessed cases of nightblindness that lacked foamy spots (from the same epidemic observed by Bitot), Netter [127] disagreed, concluding the two had nothing to do with one another. Subsequent observations [8,17,18,20,76,106,128–130] largely confirmed that the two conditions frequently coexist and [19] respond to cod liver oil.

By the turn of the century the association between nightblindness and Bitot's spots had become widely accepted [12]: both seemed to arise from a deficiency of Fat Soluble A [32]. More recent work has reopened the issue. Bitot's spots have been repeatedly observed in the absence of clinical or biochemical evidence of vitamin A deficiency, and failed to respond to its administration [35,41,45,105,131–143]. Subjects enrolled in human depletion studies have failed to develop Bitot's spots [89–91,144], and patients with classical corneal involvement are sometimes free of typical foamy lesions [115,136,145–150]. Therefore, a number of investigators have concluded that Bitot's spots may not be related to vitamin A deficiency after all [131,133,135,137,138,140,142,143,151], and WHO now recommends that only those Bitot's spots accompanied by conjunctival xerosis be accepted as valid evidence of vitamin A deficiency [47].

As will be seen, most of these apparent contradictions can be resolved, and a reasonably coherent picture of conjunctival involvement developed.

The conjunctiva in precorneal xerophthalmia

Clinical and histopathologic changes

Because serum vitamin A levels in subjects with and without mild xerophthalmia overlap, the most conclusive evidence for a relationship between a particular lesion and clinically significant vitamin A deficiency is its response to therapy. As already discussed (Chap. 1) [101], typical Bitot's spots or conjunctival xerosis in 50 patients responded to vitamin A therapy and in 9 did not. Those that responded did so reasonably rapidly (Table 3-1) [152]. Serum vitamin A levels (Table 3-2) confirm that those with responsive lesions were more likely vitamin A deficient.

The clinical appearance of responsive and nonresponsive lesions was identical. The mildest lesions consisted of small patches of xerosis easily recognized by the irregular, granular, nonwettable appearance of their surface on oblique illumination (Plate 3). Such lesions were sometimes pinpoint in size. If tearing was copious, a deep lacrimal lake often covered, thereby obscuring, the irregular surface. On retracting the lids the excess drained away and the spots reappeared like "sandbanks at receding tide"

Table 3–1. Speed of improvement in responsive cases of conjunctival xerosis (Study III)

Duration since therapy (days)	Cases examined[1]	Cases improved	
		n	%
1–4	20	11	55
5–7	23	28	100
8–14	4	4	100
15–21	3	3	100
22–31	3	2	67
32–62	2	2	100

1. Excludes cases already improved at an earlier examination.

From Sommer et al. [101].

Table 3–2. Initial serum vitamin A levels among responsive and unresponsive cases of conjunctival xerosis (Study III)

	I Cured	II Improved	III[1] Unresponsive
Number of subjects	22	9	4
Mean Vit. A (μg/dl)	13.5	10.1	29.5
SE	1.47	2.10	4.17

1. I plus II vs III, $p<.001$

From Sommer et al. [101].

[46]. Slit-lamp examination revealed small epithelial "bubbles." Some larger (focal) lesions had a similar appearance (Plate 4), while others, likely the equivalent of "acute" and "chronic" spots of Nicholls and Nimalasuriya [153] and "pearly" and "mucoid" spots of Rodger et al. [137] were covered by a foamy (Plates 4–7) or cheesy (Plates 6 and 8) looking substance. This material was easily removed with a cotton-tipped applicator revealing, in every instance, a typically xerotic base below.

Histopathologic studies [154] confirm these clinical observations. Nine responsive and eight nonresponsive lesions were biopsied (Table 3-3). All showed evidence of typical keratinizing squamous metaplasia (Fig. 3-1 to 3-3): a thickened, superficial layer of flattened cells almost always containing a keratinized surface; a prominent granular cell layer; acanthotic thickening accompanied by an irregular maturational sequence with mild-to-moderate disorganization of the basal layer and enlarged cells and nuclei

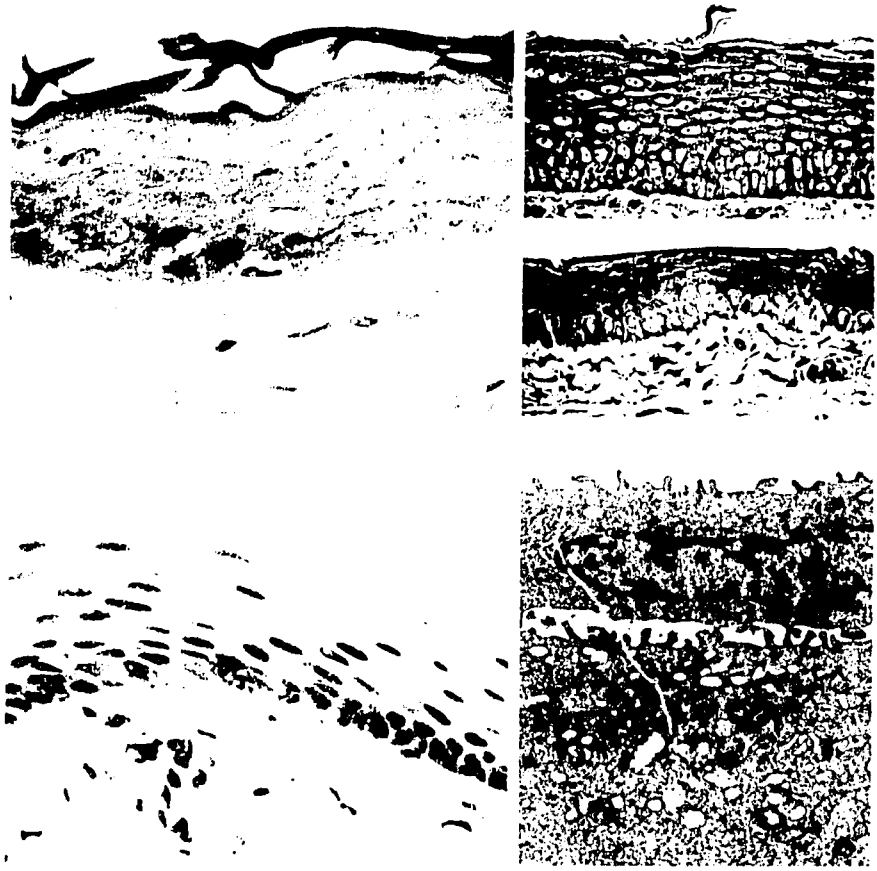

Fig. 3-1. Top left: By light microscopy, pretreatment temporal biopsy (right eye) has a prominently keratinized surface (Dane's, × 528). Top right: Phase-contrast microscopy of same area resolves surface keratinization, keratohyaline granules, acanthosis, and dyskeratosis (paraphenylenediamine, × 480). Bottom left: Biopsy of temporal conjunctiva (left eye) seven days following vitamin A therapy appears normal by light microscopy (hematoxylin-eosin, × 528). Middle right: Phase contrast photomicrograph of same area shows decrease in epithelial thickness (cf. top right; paraphenylenediamine, × 480). Bottom right: TEM (transmission electron microscopy) of same area illustrates partial return of surface membrane infoldings and microvillae (× 10,700). Study 11. (From Sommer et al. [154])

Fig. 3-2. A 13-year-old female with nonresponsive foamy Bitot's spots. Top left: Light microscopy of temporal conjunctival biopsy (right eye) exhibits abrupt transition (arrowhead) between the abnormal, heavily keratinized surface (right) and more normal adjacent conjunctiva (left), (Dane's, × 495). Top right: Another section from the same specimen similarly demonstrates by light microscopy the abrupt transition between normal epithelium (left) and abnormal epithelium (right) with keratin, granular cell layer, and irregular maturational sequence (PAS, × 495). Bottom inset: Phase contrast photomicrograph of inferonasal conjunctiva illustrates chronic inflammatory infiltrate of the stroma, predominantly composed of plasma cells (circled) (paraphenylenediamine, × 450). Bottom: TEM of area circled in inset reveals clustered plasma cells having typical nuclear and cytoplasmic features (× 5700). Study III. (From Sommer et al. [154])

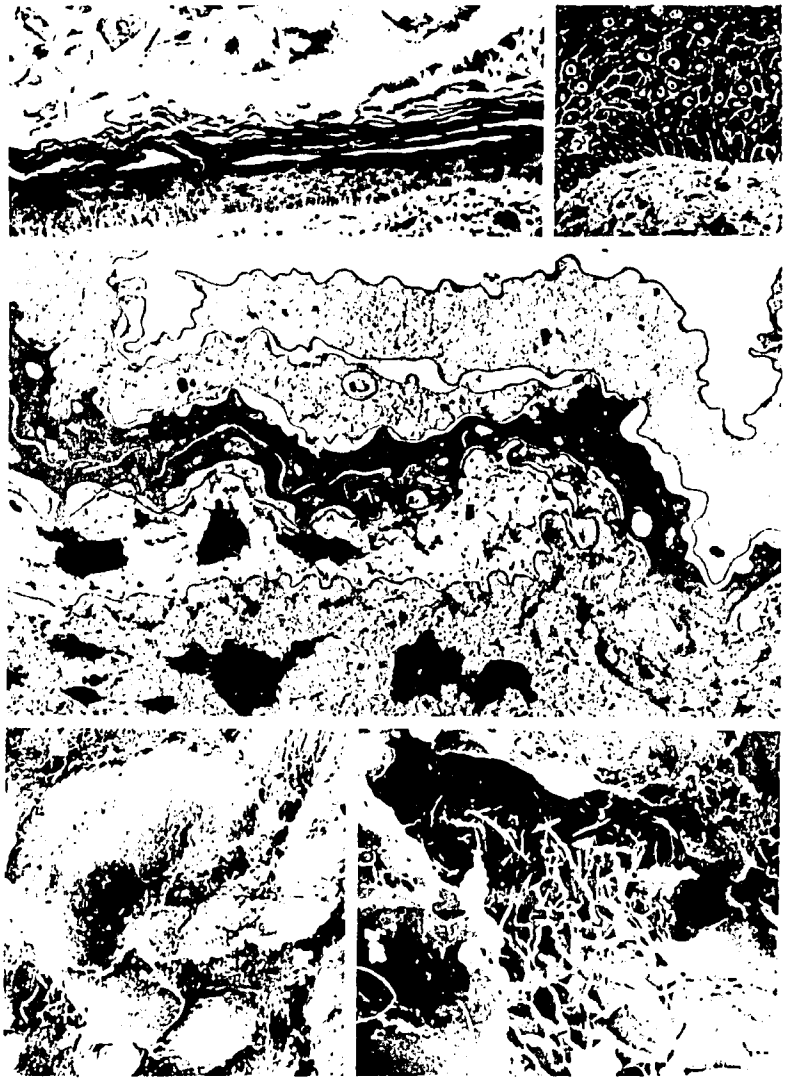

'ig. 3-3. A 20-year-old male with prominent "cheesy" Bitot's spots that were non-esponsive to vitamin A therapy. Top left: Temporal conjunctiva (left eye) by light nicroscopy shows enormous plaque of material overlying the keratinized surface Dane's, × 70). Top right: By phase contrast microscopy, extensive surface kera-inization, keratohyaline granule formation, and acanthosis are seen in the same pecimen (paraphenylenediamine, × 412). Middle: TEM of this biopsy specimen onfirms presence of extensively keratinized superficial cells containing large kera-ohyaline granules (× 7425). Bottom left: Low-magnification SEM (scanning elec-ron microscopy) of adherent keratinized debris in this specimen shows multiple aminations of devitalized cellular remnants (× 1100). Bottom right: At higher nagnification, SEM resolves amorphous cellular material and coarse fibrillary sub-tance (× 5500). Study III. (From Sommer et al. [154])

Table 3–3. Histopathology[1] of conjunctival biopsies

Case/Eye	Clinical lesion[2]	Keratin[3]	Granular layer	Surface bacteria[3]	Goblet cells	Subepithelial inflammatory infiltrate	Organization of basal layer	Epithelial thickness[3]	Cell size	Prominence of nucleoli
Pretreatment responsive cases and controls										
Temporal										
1	B	2	1.5	0	0	0	2.5	34	1	1
2	B	2	3	1.5	0	0	3	24	0.5	0.5
3	A	3	1.5	0	0	0	3	23	0.5	0.5
4	B	0	0	0	0	0.5	2.5	15	0.5	0.5
5	B	2	3	0	0	1	4	18	0	0
6	B	3	3	3.5	0	0.5	3.5	25	0.5	0.5
7	B	2	3	1.5	0	0	4	33	0.5	0.5
8	B	2	3	1.5	0	0	3	25	1.5	1.5
9[4]	+/−	0	0	0	0	0	4	25	0	0
10[4]	0	0	0	0	0	0	4	16	0	0
Nasal										
5	B	3	3	0	0	1	4	24	0	0
9[4]	0	0	0	0	0	0	4	12	0	0

Unresponsive cases										
Temporal										
13/13[5]	B	4	2	4	0	1.5	3	20	0	0
14/14	B	1	2	1.5	0	0	3.5	22	0.5	0.5
14/15	B	2	0.5	1.5	0	0.5	3	40	0.5	0.5
15/16	C	2	3	2.5	0	0.5	3	25	0	0
15/17[5]	C	4	3	4	0	1.5	3	35	0	0
16/18[5]	C	4	3	4	0	1.5	3	30	0	0
16/19	0	0	0	0	0	0	4	25	0	0
17/20	B	2.5	2.5	1.0	0	2	3	30	0.5	0.5
Nasal										
15/16	B	1	3	3	0	0.5	4	27	0	0

1. Scoring: keratinization, graded 0–4; number of granular cell layers; intrakeratin bacteria, graded 0–4; number of goblet cells per high-power field; inflammatory infiltrate in substantia propria, graded 0–4; organization of basal layer (normal = 4; complete disorganization = 1); thickness of epithelium from base of basal layer, in reticule units; increased size of cells, graded 0–2; increased prominence of nucleoli, graded 0–2.
2. "A" denotes pure conjunctival xerosis (X1A); "B" denotes "foamy" Bitot's spots; "C" denotes "cheesy" Bitot's spot. "+/−" denotes a few tiny isolated epithelial "bubbles."
3. Temporal lesion, case 4 lacked keratin but had a thickened layer of flattened cells at the surface.
4. Case (eye) 9, probably minimal xerophthalmia; case (eye) 10, nonxerophthalmic individual with retinitis pigmentosa.
5. Eyes 13, 17, and 18 contained a thick, frayed mass of keratin and bacteria on the surface. Epithelial thickness was measured from the intact keratin surface to the base of the basal layer.

From Sommer et al. [154].

with prominent nucleoli; complete absence of goblet cells; and in some, mild, chronic inflammatory cell infiltration of the substantia propria. The surface was frequently covered by a frayed mass of keratin intermixed with gram-positive bacilli, other bacteria, and even fungi. In "cheesy" lesions, this debris sometimes reached mammoth proportions (Fig. 3-3). Nonresponsive lesions had a greater propensity for surface bacteria and chronic inflammatory infiltration, and responsive lesions for enlarged cells and prominent nucleoli (Table 3-4). Similar changes have been reported in typical lesions that were [12,104,130,155–159] and were not [131,132,140,142] associated with active vitamin A deficiency. Since keratinizing metaplasia (and resulting "xerosis") is intrinsic to both responsive and nonresponsive lesions, there seems to be little point in attempting to distinguish between them on this basis.

What sets the two conditions apart is the extent and location of conjunctival involvement. In cases with and without active vitamin A deficiency, the lesions almost always involve the temporal quadrant of both eyes [7,19,96,109,130,139,140,143,153,160,161] (Table 3-5). In no instance in our series did an involved eye lack temporal involvement. In contrast, nasal involvement is far more frequent in cases with active deficiency [7,17,19,96,101,109,130,161] than in those without [101,139,140,143,153,160] (Table 3-6). When present, nasal lesions are often less prominent, but never more prominent, than their temporal counterparts [7,19,35,101,109,130,142] (Table 3-7).

Table 3–4. Mean histopathologic alterations in conjunctival biopsies of responsive and nonresponsive temporal lesions

	Responsive ($n = 8$)		Nonresponsive ($n = 7$)	
	Mean[1]	SE	Mean[1]	SE
Keratinization	2.0	0.33	2.8	0.46
Granular layer	2.3	0.40	2.3	0.34
Surface bacteria[2]	1.0	0.44	2.6	0.51
Subepithelial inflammatory infiltrate[2]	0.3	0.13	1.1	0.28
Organization of basal layer	3.2	0.21	3.1	0.07
Cell size[2]	0.6	0.16	0.2	0.10
Prominence of nucleoli[2]	0.6	0.16	0.2	0.10

1. Rounded to nearest tenth.
2. Difference statistically significant at $p < .05$.

From Sommer et al. [154].

Table 3–5. Binocularity of conjunctival xerosis (X1) (Study III)

	Clinical outcome		
	Cured	Improved	Unresponsive
Cases of conjunctival xerosis[1]			
number	36	14	9
Cases with binocular involvement			
number	34	12	7
percent	94	86	78

1. In every affected eye the temporal quadrant was clinically involved.

Table 3–6. Proportion of eyes with conjunctival xerosis in which the nasal quadrant was clinically involved (Study III)

	I Cured	II Improved	III[1] Unresponsive
Total eyes (number)	70	26	16
Eyes with nasal lesions			
number	46	15	1
percent	66	58	6

1. Responsive vs unresponsive eyes, $p < .001$.

From Sommer et al. [101].

Table 3–7. Symmetry of temporal and nasal lesions in eyes with responsive conjunctival xerosis (Study III)

Nasal lesion	Temporal lesion				
	None	X1A	X1B(F)	X1B(C)	Total
None	4	7	28	1	40
X1A		4	13		17
X1B (F)[1]			40		40
X1B (C)[1]				3	3

1. X1B (F) is foamy Bitot's spot; X1B (C) is cheesy Bitot's spot. $p < .001$ by chi-square distribution.

From Sommer et al. [101]

More extensive changes were observed in three cases, all with responsive disease. In two the inferior half, and in one all of the bulbar conjunctiva was involved. In the latter instance severe punctate keratopathy (see Chap. 4) was already present. Two weeks after receiving low-dose therapy this case developed frank corneal xerosis (X2) bilaterally and a small par-

axial ulcer (X3A) in the right eye, all of which cleared on massive vitamin A therapy.

It appears that conjunctival involvement outside the temporal area strongly suggests the presence of active vitamin A deficiency. Although useful when present, such extratemporal (primarily nasal) involvement was absent in over one-third of our responsive cases.

Differences in the distribution of responsive and nonresponsive involvement is more apparent histologically [154]. In nonresponsive cases pathologic changes are confined to the lesions themselves (see Fig. 3-2). In responsive eyes the process is generalized: although keratinization is most marked at the site of clinically detectable disease, similar changes are apparent throughout the bulbar conjunctiva. Even the epithelium of the inferonasal quadrant, ordinarily packed with mucus-producing goblet cells [162] and disease-free on clinical examination was abnormal, especially when contrasted with its appearance in biopsies from nonresponsive and posttreatment responsive eyes (Fig. 3-4) (Table 3-8; 3-9). These findings are consistent with the systemic nature of the deficiency, the importance of vitamin A for maintenance of mucus-secreting epithelium [163], and the multiorgan squamous metaplasia that occurs in animals [164–166] and man [12,40,155,167] in its absence. They also explain Rodger's (originally puzzling) report [140] that conjunctiva from the upper fornix of cases of nonresponsive Bitot's spots contained numerous goblet cells.

As already noted, conjunctival xerosis responds rapidly to vitamin A therapy (Table 3-1), although complete disappearance takes longer (Table, 3-10). In his classic report of 1881, Snell [19], noted that most Bitot's spots begin to resolve within four days of administration of cod liver oil, and disappear within ten. Similar results have been reported by others [18,142,156,168]. With healing, the lesions shrink and lose their covering debris. Before disappearing entirely they appear as small xerotic patches or tiny epithelial blisters located 1–2 mm from the limbus.

Healing usually progresses symmetrically in the two eyes, nasal lesions tending to disappear before temporal ones [101,156]. Among 6 of the 23 "cured" patients in whom both sites were involved, the two cleared at different times [101]. In each instance the nasal lesion vanished first (on the average by 15 days and 1.2 clinic visits). Among seven "improved" patients with both temporal and nasal lesions at presentation who were followed for more than two months, the nasal lesions disappeared in all, usually within one to two weeks, while the temporal lesions persisted (albeit in much reduced form). Five of these cases were followed even longer.

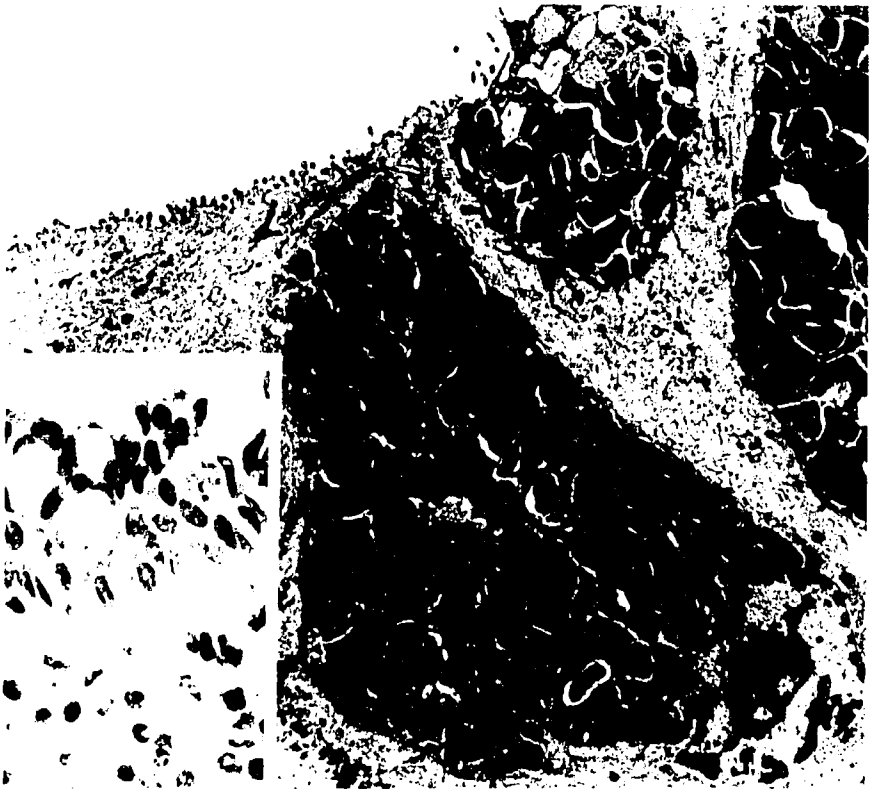

Fig. 3-4. A 13-year-old female with nonresponsive foamy Bitot's spots. Inset: Inferonasal conjunctiva (left eye) by light microscopy appears normal with respect to absence of surface keratinization and presence of numerous goblet cells (hematoxylin-eosin, × 545). Main figure: TEM of area illustrated in inset discloses epithelial cells having usual surface membrane projections and devoid of keratohyaline material. The three goblet cells shown are similarly unremarkable, having secretory granules of various electron density and reticulation (× 6270). Study III. (From Sommer et al. [154])

In three, tiny temporal Bitot's spots persisted for at least three to five months. In the two remaining cases the persistent temporal lesions were composed of two to three tiny blisters. In one they resolved at five months. In the other, perhaps the most instructive of the series, the originally sizable spots shrank by day 20 to two tiny temporal bubbles; at both one and two months they had grown into small, classical Bitot's spots; at four months both eyes were clear of all abnormalities; but by six months the

Table 3–8. Histopathology[1] of inferonasal conjunctival biopsies

Case and eye	Clinical lesion[2]	Keratin[3]	Granular layer	Surface bacteria	Goblet cells	Subepithelial inflammatory infiltrate	Organization of basal layer	Epithelial thickness	Cell size	Prominence of nucleoli
Pretreatment responsive cases and control										
2	0	0.5	0	0	0	0	4	15	0	0
3	0	0.5	0	0	0	0	3	17	0.5	0.5
5	0	0	0	0	0	0	4	24	0	0
6	0	0.5	0	0	0	0.5	3	13	0.5	0.5
7	B	2	2.5	1.5	0	1.5	4	25	0.5	0.5
8	0	0	0	0	0	1	3.5	23	0.5	0.5
10[4]	0	0	0	0	15/5	0	4	13	0	0
Nonresponsive cases										
13/13	0	0	0	0	46/5	0	4	20	0	0
14/14	0	0	0	0	15/5	0	4	15	0	0
14/15	0	0	0	0	4/4	0	4	12	0	0
15/16	B	0	0	0	22/7	0	4	26	0	0
15/17	0	0	0	0	7/3	0.5	4	21	0	0
17/20	0	0	0	0	20/5	0.5	4	18	0	0

1. Scoring: see Table 3–3.
2. "B" denotes "foamy" Bitot's spot.
3. Case 8 lacked keratin but had a thickened layer of flattened cells at the surface.
4. Case/eye 10 from nonxerophthalmic subject with retinitis pigmentosa.

From Sommer et al. [154].

Table 3–9. Histopathology[1] of conjunctival biopsies from post-treatment responsive cases

Case and eye[2]	Clinical lesion[3]	Interval since therapy	Keratin	Granular layer	Surface bacteria	Goblet cells	Subepithelial inflammatory infiltrate	Organization of basal layer	Epithelial thickness	Cell size	Prominence of nucleoli
Temporal											
1	B/A	7 days	(0)	(0)	0	0	0	(3.5)	(24)	(0.5)	(0.5)
3	A/+/–	7 days	(0)	(0)	0	0	0	3.0	(18)	0.5	0.5
4	B/O	7 days	0.5	0.5	0	0	(0)	(4)	17	(0)	(0)
	B/O	2 months	(0)	0	0	(3/5)	(0)	(4)	23	(0)	(0)
	B/O	4 months	(0)	0	0	0	(0)	(4)	17	(0)	(0)
6	B/+/–	14 days	(0)	(0)	(0)	0	(0)	3.5	(17)	(0)	(0)
11	B/O	1 month	0	0	0	0	0	4	16	0	0
12	B/O	3 months	0	0	0	0	0.5	4	15	0	0
Inferonasal											
3	0/0	7 days	0.5	0	0	0	0	3.5	18	0.5	0.5
4	0/0	2 months	0	0	0	2/5	0	4	16	0	0
6	0/0	14 days	(0)	0	0	(4/1)	0	(4)	14	(0)	(0)
11	0/0	1 month	0	0	0	0	0	4	13	0	0
12	0/0	3 months	0	0	0	35/7	1.5	4	16	0	0

1. See Table 3–3 for scoring. Parentheses, ( ) indicate improvement over pretreatment biopsy, where available.
2. All post-treatment biopsies are from the opposite eye biopsied pretreatment.
3. Pretreatment appearance of lesion/appearance at time of post-treatment biopsy. "A" denotes conjunctival xerosis (X1A); "B" denotes "foamy" Bitot's spot; "+/–" denotes a few tiny isolated epithelial "bubbles".

From Sommer et al. [154].

Table 3–10. Speed with which conjunctival xerosis disappeared in cured cases (Study III)

Duration since therapy (days)	Cases examined[1]	Cases cured[1]	
		n	%
1–4	16	0	0
5–7	21	14	67
8–14	9	6	67
15–21	4	3	75
22–31	9	8	89
32–62	5	5	100

1. Excludes cases in which the lesions disappeared at an earlier examination.

temporal bubbles had reappeared, despite serum vitamin A levels remaining at their posttreatment high (>25 μg/dl).

The histologic response largely parallels the clinical (see Table 3-9). In the majority of cases keratin and granular cell layers disappear within 1–2 weeks of administration of vitamin A. It takes considerably longer to repopulate the conjunctiva, especially its inferonasal quadrant, with a normal complement of goblet cells (Table 3-9) [104,147,154].

Associated factors

In addition to the distribution and extent of conjunctival involvement, patients with active vitamin A responsive lesions can be distinguished by a number of associated factors. One of the most useful is age.

Age. The age distributions of responsive and nonresponsive cases were distinctly different (Fig. 3-5), the proportion of nonresponsive cases rising from 3% among children less than six years of age to 60% among those ten years and older (Fig. 3-6) ($p < .001$).

Study I confirms, under unbiased field conditions, the association between active vitamin A deficiency and Bitot's spots in young children. Serum vitamin A levels among children with Bitot's spots at the time of the first clinical round were significantly below those of their age/sex/neighborhood-matched controls, and in 90%, less than 20 μg/dl (all were below 30 μg/dl) [100] (refer to Table 2-2). Results of the therapeutic trial initiated midway through the seventh round, almost two years later, are in good agreement. Children with characteristic conjunctival lesions were randomly allocated to receive either a massive-dose (200,000 IU) or

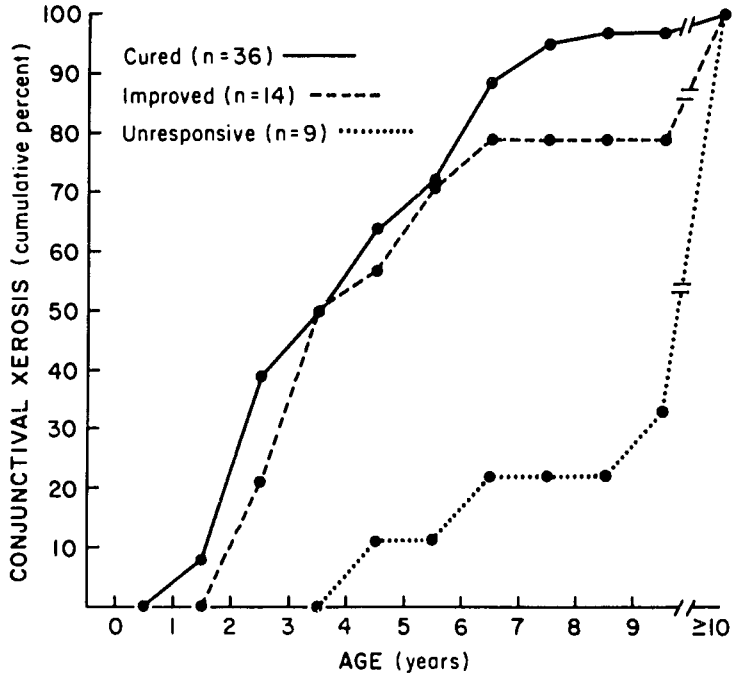

Fig. 3-5. Individuals whose conjunctival xerosis failed to respond to vitamin A were considerably older than those who responded ($p < .01$). Study III. (Drawn from Sommer et al. [101])

low-dose (700 IU) vitamin A capsule, and were reexamined by the same ophthalmologist, in double-masked fashion, two to three weeks later. The lesions disappeared in almost 80% of high-dose recipients (Table 3–11). The spontaneous cure rate among low-dose recipients was only 50% ($p < .05$). The 80% "cure" rate over two to three weeks suggests a "response" rate approaching 100%. It will be recalled that less than 72% of proven responsive cases in Study III lost their lesions over this same period of time. In fact in two of the eight "noncured" high-dose recipients in Study I the lesions had originally been present nasally and temporally, and in both cases the nasal lesions disappeared during the two to three-week follow-up.

Results of Study III and Rounds 1 and 7–8 of Study I are remarkably consistent, and suggest that at least 90–95% of preschool-age Indonesian children with Bitot's spots suffer from active, clinically significant vitamin A deficiency. This supports suggestions that Bitot's spots are a useful index of vitamin A deficiency in young children [35,47,71,149]. Whether the

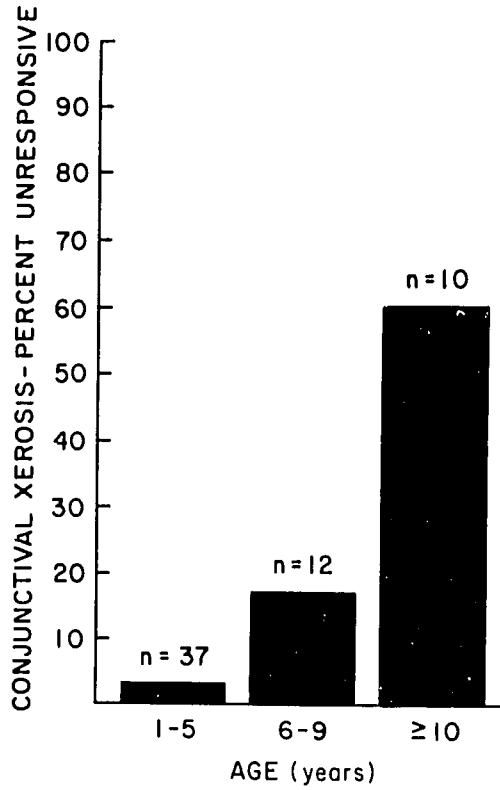

Fig. 3-6. The proportion of cases of conjunctival xerosis refractory to vitamin A therapy increased with age ($p < .001$ by linear trend). Study III. (Drawn from Sommer et al. [101])

same is true in other countries largely depends on the prevalence of clinically active vitamin A deficiency in this age group and their propensity for developing typical nonresponsive lesions.

For example, nonresponsive lesions are reported to be particularly prevalent in certain parts of India, where they sometimes represent a substantial proportion of Bitot's spots encountered, even among young children. In a longitudinal study in West Bengal [141], the prevalence of Bitot's spots among preschool-age children fluctuated between 8% and 20%, roughly half representing nonresponsive lesions. Similarly, almost one-third of Indian children treated for conjunctival xerosis at a day-care center failed to respond to massive vitamin A over a five-week follow-up period [169].

Individuals with responsive lesions would logically be expected to exhibit other evidence of vitamin A deficiency, which indeed is the case.

Table 3–11. Disappearance of conjunctival xerosis following vitamin A therapy (Study I: Rounds 7–8)

Diagnosis	Treatment	
	Vitamin A	Placebo
XIB		
Total (*n*)	37	32
Cured (*n*)	29	16
Cured (%)	78	50

Difference in cure rate between vitamin A and placebo recipients, $p < .05$.

Nightblindness. Nightblindness is far more common among responsive than nonresponsive cases, both by history and objective assessment [101] (see Fig. 2-1). In 3 of 30 patients with curable conjunctival lesions, nightblindness testing could not be completed: they simply sat down and cried. All three had a positive history and were among the youngest children examined, suggesting that their lack of cooperation may have been a manifestation of impaired dark adaptation.

Although none of the nonresponsive cases proved to be nightblind, three claimed that they were. It is possible that one or more were correct: as already noted a history can be more reliable than our crude test, and there is no reason nightblindness cannot occur in someone with a nonresponsive lesion. But the serum vitamin A level available on one of the three was reasonably normal (22 μg/dl).

The prevalence of nightblindness among cases of conjunctival xerosis/Bitot's spots varies widely. At clinics, where nightblindness is often the reason help was sought in the first place [79], it is likely to be very high. Eighty percent of all patients in Study III (see Fig. 2-1) claimed to be nightblind. Comparable rates have been reported from England [19,130], France [7,36], Russia [8], Japan [18], Africa [170], Indonesia [105], and elsewhere. But in field surveys, where the proportion of conjunctival lesions associated with active vitamin A deficiency may be smaller, and a larger segment of nightblind individuals are unaware of their problem, it is likely to be very much lower. During the first round of Study I, when practically all cases of xerosis/Bitot's spots were likely to be vitamin A deficient, only 61% had a positive history of nightblindness.

Punctate keratopathy. As will be discussed at greater length, fluorescein-positive punctate keratopathy (Plate 11) is an early, mild manifestation of

Table 3–12. Superficial punctate keratopathy in patients with conjunctival xerosis (Study III)

SPK status	Classification of conjunctival xerosis[1]		
	Cured	Improved	Unresponsive
No. tested[2]	27	12	8
No. positive[3]	26 (96%)	10 (83%)	1 (13%)
Density[4]			
Mean	1.8	1.9	1.0
SE	0.16	0.18	–
Area[4]			
Mean	2.2	2.1	1.0
SE	0.25	0.41	–

1. Ultimate response following vitamin A therapy.
2. Number of cases.
3. Overall distribution $P < .001$; cured vs improved $P < .16$; improved vs unresponsive $P < .01$; and cured vs unresponsive $P < .001$.
4. Density and area is the average of both eyes for each positive case. Density was graded 1–3 (mild, moderate, severe) and area 1–4 (inferonasal quadrant, inferior half, inferior three fourths, and entire corneal surface).

From Sommer et al. [101].

vitamin A deficiency [171]. It was present in 92% of responsive cases but only 13% (one-eighth) of nonresponsive ones (Table 3-12). In the latter instance it was mild and of limited extent.

Recognition of active cases

There is no foolproof method for identifying which cases of conjunctival xerosis/Bitot's spots are associated with active, clinically significant vitamin A deficiency, short of actually recording their response to therapy. The most specific clues are involvement of more than just the temporal quadrant and the presence of other signs and symptoms of vitamin A deficiency: nightblindness of recent onset and punctate keratopathy. Unfortunately, the sensitivity of these clues is only 50–30%: a sizable proportion of active cases lack clinical (if not histologic) evidence of extratemporal xerosis; nightblindness may be subclinical or otherwise overlooked; and identifying early punctate keratopathy generally requires the aid of a slit lamp. Age is a useful clue: lesions are more likely to be active in preschool-age children than in older individuals. But the ratio of active to inactive cases, even among preschoolers, may vary from one community to another.

In summary, the presence of extratemporal involvement, nightblindness, and punctate keratopathy all suggest active disease, especially in preschool-

age children. But their absence is far less helpful: in many communities cases of Bitot's spots without these signs are more likely than not to be Vitamin A deficient.

The origin of nonresponsive spots

Available evidence suggests that a substantial proportion of nonresponsive lesions are sequelae of past vitamin A deficiency [101,154]. Nonresponsive lesions almost invariably occupy the temporal quadrant [101,139,140,143,153]. This same area is the most susceptible to the effects of vitamin A deficiency. Although vitamin A deficiency induces keratinizing metaplasia throughout the bulbar conjunctiva, clinically detectable involvement is more frequent, more pronounced, and slower to heal temporally than elsewhere. This may be related, at least in part, to its exposed location and relative freedom from lid abrasion. Appelmans [172] reported a Bitot's spot in the 12 o'clock position deep to a coloboma of the upper lid; McLaren reported a typical Bitot's spot in association with ectropion of the lower lid; Metivier [139] reported two instances of unilateral (nonresponsive) lesions, one in an eye of a child with complete, longstanding ptosis in the other eye, and one in an eye proptosed by an orbital osteoma. We have observed severe, plaquelike xerosis on the surface of a protuberant staphyloma (from keratomalacia) in a xerophthalmic child disappear following systemic vitamin A therapy.

Keratinizing metaplasia of the temporal quadrant induced by vitamin A deficiency appears capable of escaping, for variable periods, from the normal affects of vitamin A. In a number of cases [101], vitamin A therapy results in prompt clinical and histopathologic disappearance of nasal lesions, but only a reduction in the size of temporal ones. These may then wax and wane for months. It is as if the localized metaplasia has become self-perpetuating, analogous to carcinoma in situ. We have never witnessed the return of nonresponsive lesions following surgical excision.

The observations of Sinha and Bang [141] are of particular significance in this regard. Twenty-five preschool-age children with Bitot's spots were given 200,000 IU vitamin A orally every four months for one year: in eight the lesions promptly disappeared, never to return; in eight they initially disappeared but returned during follow-up; and in nine they never disappeared. Only 0.8% (2/255) of children initially free of Bitot's spots and placed on the same schedule developed spots during the second year, vs 9% placed on a placebo regimen. It appears that once keratinizing meta-

plasia occurs, other factors, in addition to the availability of vitamin A, determine their prominence. In Sinha and Bang's study administration of vitamin A virtually eliminated the formation of new, "nonresponsive," "nonvitamin A deficiency-associated" lesions.

The reason some temporal lesions become persistent while others do not remains unknown, although the age of the individual and chronicity of vitamin A deficiency probably play a role. As already discussed, patients with responsive lesions tend to be younger than those with nonresponsive ones. Interestingly, the age distribution of the seven persistent, partially responsive cases in our series more closely approximated that of the nonresponsive than cured cases. Our nonresponsive cases were also twice as likely to claim a past xerophthalmic episode (2/9 vs 4/50) and to have had their lesions for at least two months (48% vs 19%). Accumulation of surface bacteria and presence of subepithelial inflammatory infiltration, which may be chronic changes, were significantly more prominent and frequent in nonresponsive than responsive lesions [154] (see Table 3-4). A majority of nonresponsive patients examined by Sie-Boen-Lian [132] and Metivier [139] claimed their lesions had first appeared in early childhood suggesting they were long standing.

Despite repeated suggestions that protein or other forms of malnutrition may be responsible for nonresponsive lesions [77,135,142,143,150, 151,173], this seems unlikely: protein-energy malnutrition is principally a disease of young children, while nonresponsive spots commonly occur in older individuals. Indeed, the general nutritional status of most of our responsive cases was quite good for Indonesian children [101]: only 4 of 50 had a weight for height below 80% of Western standards [174]; only two had kwashiorkor; serum albumin was at least 3.5 g/dl in 70%, and below 3 g/dl in only 4%; angular stomatitis was rare. Befitting their older age, the nutritional status of the nonresponsive cases was even better: only a single preschooler had a weight for height below 90% of standard; and none had edema, a serum albumin below 3.5 g/dl, or angular stomatitis.

The conjunctiva in corneal disease

Severity of conjunctival involvement

The severity and extent of conjunctival xerosis is related to the duration and degree of vitamin A deficiency. Conjunctival changes are therefore more pronounced in patients with active, uncomplicated corneal involvement [6,18,20,155,517] (Table 3-13). In only 7% of eyes of the 50 (non-

Table 3–13. Clinical extent of conjunctival involvement (Studies II/III)

Patient's clinical classification[1]	Number of eyes	Extent of conjunctival xerosis (percent of eyes)			
		0	Temp.	Temp. +nasal	≥180°
X1*	100	5	37	51	7
X2*	106	4	9	40	47
X2/X3	167	8	12	35	45

1. X1 Includes all eyes of 50 vitamin A responsive cases of conjunctival xerosis (Study III).
X2 Includes all eyes of cases with corneal xerosis in worst eye (Study II, grades 1–3)
X2/X3 Includes eyes in X2, plus all nonulcerated eyes of cases of xerophthalmic ulceration/necrosis in one eye (Study II, grades 1–7).

* Difference in distribution between X1 and X2 (or X2/X3), $p < .01$

From A. Sommer [517].

corneal) responsive cases did xerosis involve 180° or more of the conjunctiva, and two of these seven eyes were in the untreated case of severe punctate keratopathy that ultimately developed bilateral corneal xerosis and unilateral ulceration two weeks after receiving low-dose therapy. By contrast, 3 or more quadrants of the conjunctiva were xerotic in 47% of eyes in cases of corneal xerosis, and 45% of all nonulcerated eyes in cases with corneal involvement in at least one eye [517]. The reason for excluding eyes with corneal ulceration will soon be apparent.

The more extensive the area of conjunctival involvement, the more severe the change. In advanced disease, the conjunctiva appeared thickened and stiff (Plates 9,10,17–19,28,31), forming fixed folds concentric with the limbus. This was occasionally noted in large, isolated patches of temporal xerosis (Plates 9,10), but was far more common when 180° or more of the conjunctiva was involved. In the latter instance the conjunctiva often acquired a frankly corrugated, skinlike appearance.

Apparent absence of conjunctival xerosis

On occasion, eyes with frank corneal involvement appear free of conjunctival xerosis (Plates 14,22,24,25) [175]. At least two mechanisms account for this: conjunctival xerosis can be hidden or reversed by inflammation; and when vitamin A status rapidly deteriorates, clinically observable changes in the cornea can precede those in the conjunctiva [517].

In 20 cases of corneal disease conjunctival xerosis was present in one eye but not the other (Table 3-14) [517]. In 15 the nonxerotic eye was in-

Table 3–14. Asymmetry of conjunctival injection and severity of corneal involvement among patients with conjunctival xerosis in only one eye (Study II)

	Conjunctival injection[1]		Severity of corneal lesion[1]	
Case	Xerotic eye	Nonxerotic eye	Xerotic eye	Nonxerotic eye
1	Absent	Present	X2	X2
2	Present	Present	Staphyloma	X3B
3	Absent	Present	X2	X2
4	Absent	Present	–	X3A
5	Absent	Present	–	X3A
6	Present	Present	X2	X3A
7	Absent	Present	X2	X3A
8	Absent	Present	X2	X3A
9	Present	Absent	X3A	–
10	Absent	Present	X2	X3B
11	Absent	Present	X2	X3B
12	Absent	Present	X2	X3B
13	Present	Present	X3A	X3B
14	Absent	Present	–	X3B
15	Absent	Present	X2	X3B
16	Present	Present	X3A	X3B
17	Absent	Present	–	X3B
18	Absent	Present	X2	X3B
19	Absent	Present	X2	X3B
20	Absent	Present	X2	X3B

1. Difference between xerotic and nonxerotic eyes, $p < .001$.

From A. Sommer [517].

flamed while the xerotic eye was not, the reverse being true in only a single case ($p < .001$). In 16 of the 17 cases with necrosis in at least one eye, the necrosis was either less severe or absent in the xerotic eye ($p < .001$). Whether inflammation actually reverses the xerosis or merely masks its presence is unclear, as histopathologic material is unavailable. As already noted for biopsies from the inferonasal quadrant of children with active temporal Bitot's spots, histologically abnormal conjunctiva may have a normal clinical appearance.

In situations of rapid deterioration of vitamin A status, clinically detectable alterations in the cornea may precede those in the conjunctiva. This was well documented in our case No. 200/011.

Case 200/011: A severely malnourished two-year-old presented with extensive, severe, bilateral conjunctival and corneal xerosis and a unilateral ulcer. All ocular abnormalities disappeared within ten days of systemic vitamin A therapy. His

1

2

Plate 1. Xerophthalmic retinopathy in a 24-year-old otherwise well nourished Indonesian women who presented with nightblindness, constricted visual fields (see Fig. 2-3), and severe conjunctival and corneal xerosis (see Plate 19).

Plate 2. Two months after vitamin A therapy the small yellowish-white retinal lesions seen in the patient in Plate 1 have largely disappeared.



3

4

Plate 3. Localized area of dry, granular conjunctival xerosis temporally in a 5-year-old Indonesian boy.

Plate 4. Tiny, localized areas of foam or bubbles of conjunctival xerosis in a 4-year-old Indonesian boy.

A

5



6

Plate 5. Classical foamy Bitot's spot in a 29-year-old Indonesian man that largely resolved within two months of vitamin A therapy.

Plate 6. Classical Bitot's spot in a 20-year-old Indonesian man. The superior aspect is foamy in character; the inferior aspect is denser and cheesy in appearance. There was no history of nightblindness and the Bitot's spot failed to respond to vitamin A therapy.

7

8

Plate 7. Foamy Bitot's spot in a 3-year-old girl from South India. Note the heavily pigmented appearance of the conjunctiva.

Plate 8. Thick, cheesy Bitot's spot in a 4-year-old boy from South India. The child had been nightblind for two months.

9



10

Plate 9. Thick, stiffened temporal conjunctiva in a 4-year-old Indonesian girl with advanced conjunctival xerosis. Haziness of the inferior cornea represents mild corneal xerosis.

Plate 10. Thickened, skinlike temporal conjunctiva in a 1-year-old Indonesian boy with early corneal xerosis. The eye had been stained with Rose Bengal.

11

12

Plate 11. Extensive punctate keratopathy in 10-month-old Indonesian boy. The cornea appeared crystal clear to handlight examination; but fluorescein-staining punctate epithelial lesions were apparent on examination with the slit-lamp biomicroscope. The cornea of the other eye was entirely necrotic (Plate 12).

Plate 12. Fellow eye of subject described in Plate 11. The cornea was entirely necrotic and bulging forward. Dark, pigmented iris is visible in areas where most of the stroma had already sloughed.

13

14

Plate 13. Inferior corneal xerosis in a severely malnourished 3-year-old Indonesian boy. The keratinized surface is sharply demarcated. The cornea of the other eye was entirely necrotic (Plate 14).

Plate 14. Fellow eye of case described in Plate 13. Except for the peripheral 1 mm the cornea is entirely necrotic, most having already sloughed, resulting in a large central descemetocele. The conjunctiva is moderately inflamed and without evident xerosis.

15

16

Plate 15. Heavily keratinized corneal surface in the eye of a 2-year-old Indonesian girl two days after initiation of therapy. A portion of the keratinized surface has already peeled off inferiorly, forming a scroll below. The clear area is now devoid of its keratinized layer. At the initial examination the identical area of the other eye contained a typical ulcer (Plate 16).

Plate 16. Fellow eye of case described in Plate 15. A typical, sharp-margined oval ulcer is present inferiorly. The conjunctiva is not inflamed, and contains extensive xerosis most apparent in the inferior quadrant adjacent to the cornea.

17

18

Plate 17. Extensive conjunctival xerosis and heavily keratinized corneal surface in a 3-year-old Indonesian boy. See text for fuller description (case 200/069).

Plate 18. Same eye shown in Plate 17, two days following initiation of therapy. The heavily keratinized corneal plaque inferiorly has sloughed, leaving a small, round, sharply demarcated superficial ulcer in its place. Crevices of the surrounding keratinized surface converge on the ulcer, most apparent above the inferior limbus. Keratinized plaques are still present in the interpalpebral zone.

19

20

Plate 19. External appearance of one eye of the case already described in Plate 1. Marked xerosis of both the conjunctiva and cornea are present.

Plate 20. Heavily keratinized corneal plaque in a 2-year-old Indonesian girl with poor lid closure and severe malnutrition. Conjunctival and corneal xerosis are extensive.

21

22

Plate 21. Right eye of a 3-year-old Indonesian girl. A classical punched-out, shallow round ulcer was present anteriorly, with pigment (presumably adherent iris surface left behind following dilitation) posteriorly, with normal appearing stroma in between. Two pinpoint ulcers were present superiorly. The left eye is shown in Plate 22. See text for more detailed description (case 200/158).

Plate 22. Left eye of case described in Plate 21. A large, circumscribed area of cornea is missing centrally, with iris bulging through the defect. The surrounding cornea was hazy but viable. The conjunctiva was xerotic and not inflamed.

23

24

Plate 23. The left eye of a 4-year-old Indonesian boy. Corneal xerosis is apparent inferiorly, and a classically sharp, round, punched-out three-fourths depth ulcer superonasally. The ulcer reached Descemet's membrane.

Plate 24. A characteristically fluorescein-staining oval, inferior corneal ulcer in a 2-year-old Indonesian girl. A small hypopyon is present and the conjunctiva is inflamed.

F

25

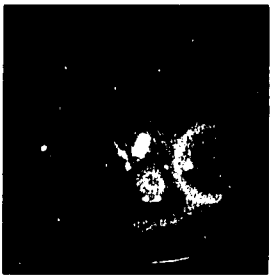

26

Plate 25. A 19-month-old Indonesian boy. The right eye contained extensive conjunctival xerosis and punctate keratopathy. The left eye, shown here one day following initiation of vitamin A therapy, contained three areas of surface abnormality. One area was irregular, composed of mounds (clear epithelial or superficial stromal vesicles) alternating with dellen-like depressions. Temporal to this area was a depression. In its center was a sharp, deeper, cylindrical ulcer, the only part that stained with fluorescein. A second, larger depression with a centrally staining ulcer was present more temporally. The bases of the two ulcers, originally clear, were by now moderately opaque. A small hypopyon was present and the conjunctiva was inflamed. See text for fuller description (case 200/160).

Plate 26. Same eye shown in Plate 25, three days after presentation, stained with fluorescein and observed through a blue filter. The superonasal area is less irregular and the adjacent ulcer has largely healed. But now the most temporal ulcer has enlarged, the entire area of depression being deeper and staining edge-to-edge. The hypopyon has increased.



27



28

Plate 27. Same eye shown in Plates 25 and 26, five days after presentation. The irregular, nasal area is only minimally hazy; the adjacent ulcer has healed as a saucer-shaped depression; but the most temporal ulcer has a focal, deep-stromal, necrotic appearance. The latter eventually healed as a dense leukoma.

Plate 28. Opaque, necrotic cornea in a 2-year-old Indonesian boy. The conjunctiva is both xerotic and inflamed. The fellow eye contained an area of inferior, focal, corneal necrosis.

29



30

Plate 29. Sharply focal necrotic lesion in the right eye of a 2-year-old Indonesian boy. The stroma has largely sloughed, a bulging descemetocele filling the defect. The rest of the cornea is hazy and xerotic. The conjunctiva is inflamed. The other eye had moderately severe corneal xerosis.

Plate 30. Same eye shown in Plate 29, two months later. The defect has healed as a remarkably small, peripheral adherent leukoma leaving a clear pupillary zone.

31



32

Plate 31. Left eye of an otherwise well nourished 2-year-old Indonesian boy. A large, nonstaining, focally necrotic, bulging, opaque corneal lesion is present inferiorly. The conjunctiva is both inflamed and xerotic. Abnormalities in the other eye were limited to dense punctate keratopathy.

Plate 32. Same eye shown in Plate 31, one month later. The previous lesion has healed as a surprisingly small adherent leukoma, preserving a clear, central, pupillary zone.

Color plates 1, 2, and 19 are from Sommer et al. [104]; 4, 7, and 8 from Sommer [152]; 6 from Sommer et al. [101]; and 12, 15, 17, 21–23, 25–27, and 31 and 32 from Sommer et al. [197].

H

mother refused to allow hospitalization. When next seen, two weeks later, his general nutritional status was even worse, with gross edema in both legs. Severe corneal xerosis had reappeared bilaterally and both corneas contained small ulcers. Despite the absence of inflammation, the conjunctiva was clinically normal in both eyes. The corneal ulcers promptly responded to additional vitamin A, but the child died three days later.

A similar pattern was observed in another two-year-old (case 200/068) in the absence of corneal ulceration.

Despite previous suggestions that inflammation [17,18,149,176,177] and sudden deterioration of vitamin A status [39,43,149,178,179] can modify the clinical picture, mechanisms other than vitamin A deficiency have been proposed to explain classical corneal destruction unaccompanied by conjunctival xerosis [136,145]. As recently as 1971 vitamin A was being withheld from severely malnourished children with corneal haziness and ulcers [145] because of the absence of conjunctival xerosis. After a week at least one child developed a corneal ulcer in a previously hazy right eye and perforated an existing ulcer in his left eye. The author laments that "unfortunately (at this point) the mother absconded with the child" (and probably a good thing too!). Pillat's [156] suggestion that "examination of the conjunctiva is the only guard against a mistaken diagnosis" has, unfortunately, proven incorrect, at least in cases of rapidly evolving disease or bilateral ulceration/necrosis.

Evolution and diagnosis of conjunctival xerosis

As should now be clear, vitamin A deficiency induces a squamous metaplasia throughout the conjunctiva. Because it is most pronounced in the temporal quadrant, this is the site where clinical "xerosis" first appears. Its "nonwettable" keratinized surface is dotted by fine, lustrous irregularities or bubbles, although in some instances heavier accumulations of keratinized debris and saprophytic bacteria (primarily "xerosis bacilli") form a highly visible foamy or cheesy covering, known as "Bitot's Spots." Since these are nothing more than localized variants of the basic xerotic process there is little reason for continuing to divide them into those with and without accompanying xerosis [47].*

In general, these metaplastic changes are exquisitely sensitive to vitamin A status. But occasionally, for reasons not entirely clear, areas of temporal metaplasia become self-perpetuating, persisting long after vitamin A levels

*This conclusion is reflected in the 1981 revision of the WHO classification (Appendix 2).

have returned to normal. This accounts for at least some instances of "non-vitamin A deficient" conjunctival xerosis/Bitot's spots. The exact proportion of nonresponsive cases due to past vitamin A deficiency, and the proportion, if any, due to other causes, is unknown and may well vary from one population to another.

As vitamin A status deteriorates further, keratinizing metaplasia becomes more severe. Although histologic changes are widespread early in the disease, clinically demonstrable xerosis first appears temporally, then nasally, then inferiorly, and finally superiorly, a progression suggesting the influence of exposure and susceptibility to lid abrasion. The more extensive the involvement the more severe the changes. The conjunctiva becomes increasingly stiff, thickened, and resistent to deformation, eventually assuming a wrinkled, leathery, skinlike appearance with prominent folds concentric with the limbus. These are advanced changes, almost always accompanied by frank corneal involvement in eyes in which the diagnosis would never be in doubt, precisely the condition under which they were originally described [32,68,77,109,129,156,158,180]. Confusion arose with attempts to develop more sensitive criteria of mild vitamin A deficiency. Kruse [181] claimed that fine wrinkling and thickening, evident on biomicroscopic examination of the bulbar conjunctiva, were useful signs of active vitamin A deficiency. Despite the fact that many months were required for these "abnormalities" to disappear after vitamin A therapy, and Berliner's [182] demonstration that similar changes were common in normal individuals, "wrinkling" and "thickening" have been regarded as evidence of mild "conjunctival xerosis," which resulted in frequent overdiagnosis [47]. In our experience [101], mild degrees of wrinkling and thickening, as described in the recent WHO classification [47], are poorly reproducible and almost as common among normal children as among those with vitamin A responsive nightblindness and mild conjunctival xerosis/Bitot's spots (X1), a judgment shared by others [183].

Sauter [45,184] has suggested that conjunctival staining with vital dyes, especially with Lissamine Green, is a useful index of preclinical xerosis and a basis for distinguishing Bitot's spots associated with active vitamin A deficiency from those that are not. Unfortunately, subsequent experience indicates the technique is neither as specific nor as sensitive as claimed [169,185–188, and E. Sutter, personal communication, 1979]. In our own series [187], over 11% of normals developed definite staining of one or both eyes, as did 83% of cases of nonresponsive Bitot's spots (Table 3-15). Similar staining patterns were absent in two-thirds of cases of nightblind-

Table 3–15. Lissamine green staining of patients with clinical xerophthalmia and controls (Studies II/III)

Clinical status		Total cases	Definite 2 eyes	Definite 1 eye	Indefinite 1 or 2 eyes	Negative 2 eyes
Normal Controls	*n*	51	2	4	3	42
	(%)	(100)	(3.9)	(7.8)	(5.9)	(82.4)
Night blind	*n*	14	3	1	2	8
	(%)	(99.9)	(21.4)	(7.1)	(14.3)	(57.1)
Nonresponsive Bitot's spots	*n*	6	5	1	–	–
	(%)	(100)	(83.3)	(16.7)	–	–
Responsive Bitot's spots and/or conjunctival xerosis	*n*	31	18	3	1	9
	(%)	(100)	(58.1)	(9.7)	(3.2)	(29.0)
Corneal xerophthalmia	*n*	51	22	12	4	13
	(%)	(99.9)	(43.1)	(23.5)	(7.8)	(25.5)

From Emran et al. [187].

ness and one-third of all cases of vitamin-A-responsive conjunctival xerosis/Bitot's spots or frank corneal involvement. Kajal, a common India cosmetic containing carbon particles in oil has been used to increase the visibility of Bitot's spots [183].

Conjunctival xerosis requires time to develop. When vitamin A status deteriorates rapidly, as in measles and other catastrophic illnesses, clinical involvement of the cornea may precede that of the conjunctiva. Conjunctival pigmentation, much commented on in the past and still a recommended sign of xerosis [17,46,109,189] is an even more chronic change, if in fact it is related to vitamin A deficiency at all [35,45,101,136,149, 155,190,191].

Classically, xerophthalmic corneal destruction is said to occur in relatively noninflammed, "white and quiet" eyes (Plates 16,21,22)[13,39,136]. Nonetheless, conjunctival inflammation of varying degree is present in a substantial proportion, perhaps a majority, of such cases (Plates 12,14,23,25,29) [17,18,35,176]. Whether it results from secondary infection, concomitant illness (e.g. measles), or simply corneal destruction itself, such conjunctival inflammation may mask or reverse the underlying xerosis.

The failure of otherwise well-nourished adult volunteers, placed on diets deficient in vitamin A, to develop typical conjunctival xerosis or Bitot's

spots [89–91,144] is hardly surprising. Well-fed adults have large vitamin A reserves. In most instances, the period of attempted depletion lasted less than one year, and rarely as long as two years. Many participants never developed serum vitamin A levels in the abnormal range, and only a few were sufficiently depleted to develop clinically detectable nightblindness. The previously healthy, well-nourished case reported by Bors and Fells [115] was allegedly on a diet entirely free of vitamin and provitamin A for five years before developing significant ocular pathology.

4. Corneal involvement

I. Clinical considerations

> In emaciated infants, particularly, I have repeatedly seen the cornea of one or both eyes become thin and prominent and give way, without much, and even without any apparent inflammation. The wasted state of the body in such subjects arose from various causes, as chronic diarrhea, cough following measles, and syphilis. . . . I have sometimes been led to compare the state of such eyes to those of the dogs of Magendie's experiments which being fed, or rather starved, on white sugar and distilled water, died from exhaustion, their death being preceded by perforating ulcer of the cornea and evacuation of the humours.
>
> William Mackenzie, 1834

Corneal manifestations of malnutrition may have been recognized even before those of the conjunctiva. Over 250 years ago, Duddell [2] described corneal necrosis resulting in adherent leukomas and staphylomas in poor children and "sometimes . . . after measles."

There is no mistaking Brown's [192] early 19th-century description of a "case of ulcerated cornea from inanition" in a "poor babe." The six-month-old severely emaciated child developed rapidly progressive ulceration in both eyes, the contents of which were expected to be "expelled" within 24 hours.

Mackenzie [4], another Scot, was obviously familiar with the disease. He provided an accurate description of keratomalacia, its relationship to nutritional status, and its precipitation by severe systemic illnesses. He also described less severe corneal ulceration, under similar circumstances, among "scrofulous subjects."

Similar observations were soon made by others [5,9,193]. Hubbenet [6], who first reported the "hemerolopic spot" for which Bitot later became famous, may also have been the first to describe early changes in the cornea. He noted that "as the disease progresses . . . the cornea itself becomes cloudy . . . the vision becomes blurred, and consequently the patient has poor vision in artificial light, objects appearing to him as if they were wrapped in a halo."

Within six years of Hubbenet's observations, Blessig [8] encountered the entire spectrum of disease, nightblindness through corneal melting, in the presence of conjunctival xerosis. Many excellent descriptions of conjuncti-

val and corneal xerosis, occasionally progressing to ulceration and widespread melting, soon followed [17,18,20,68]. Concluding with Bloch [32], these early workers had assimilated diverse clinical observations into a single recognizable ocular syndrome associated with the lack of a specific nutrient, often precipitated by severe infections, and responding to foods rich in Fat Soluble A.

Unfortunately, subsequent attempts to explain the etiology and pathogenesis of the various corneal changes dwelt upon their diversity, resulting in the confused terminology that has impeded development of our understanding of the disease. Etymologically, "corneal xerosis" should mean, quite simply, dryness of the cornea (i.e. its surface), and "keratomalacia," a softening (or loss) of the corneal stroma. This, in fact, was the way the terms were initially employed [18,32]. Thus Pillat [156] divided the disease into three stages: nightblindness and/or conjunctival xerosis; corneal xerosis; and corneal ulcers through complete melting, much in the way subsequent classifications stressed the difference between reversible and irreversible changes [46,71,146,160,161]. As observations became more acute, so did classifications. Pillat [189] recognized subtler changes of the corneal surface, "an uncharacteristic dullness of the cornea due to vitamin A deficiency," as "prexerosis," distinguishing it from the "well circumscribed white or whitish-grey deposits on the cornea similar to Bitot's spots" which represented "true xerosis." Although this was no more than Hubbenet had already done 90 years earlier, the distinction was adopted in classifications that followed [146,155,194].

More problematic was the classification of the various forms of stromal involvement. Mori [18] clearly distinguished corneal "ulcers" from "necrotic disintegration (keratomalacia)." Kirwan [160] divided active corneal disease into four stages: prexerosis and xerosis ("the earliest stage of keratomalacia"); "keratomalacia without breakdown of the cornea" (in which the areas of infiltration or degeneration were thought to occur in the deeper layers of the stroma below an intact epithelium); "keratomalacia with breakdown" (resulting in permanent damage); and total disruption of the cornea. Oomen [35] was concerned with the fact not all stromal loss appeared to proceed in the same manner. He distinguished "corneal xerosis," (including "bean-like protrusions" or perforations, occasionally becoming multiple or even involving the entire cornea) from keratomalacia by the fact the cornea retained its general shape. He regarded kertomalacia as a "colliquative necrosis" in which "vast stretches of the corneal surface are immediately affected" and the original shape of the cornea ultimately lost. McLaren [43] objected to the use of a single term, "xerosis," to cover both

"dryness" and "ulceration," arguing that "any ulceration was a malacia," thus echoing the sentiments of Owen [195]. A consensus, of sorts, was finally achieved. McLaren, Oomen, and Escapini [46] distinguished between "ulceration," a partial or full-thickness loss of substance from (usually) the lower cornea, and "keratomalacia," characterized by softening of the entire thickness of a part or more often the whole of the cornea "invariably leading to deformation or destruction of the eyeball," an imprecise but reasonably successful division still in use [161,47].

In 1974 a modification of a classification long used in Indonesia [71] was proposed for international use [47] (Table 1-1). It retains the practical distinction between reversible (X2) and irreversible (X3) corneal damage. The latter is less precisely subclassified into X3A, "corneal ulceration with xerosis"; and X3B, "keratomalacia" distinguished by "colliquative necrosis," involvement of the full thickness (and usually whole extent) of the cornea, and by "invariably leading to deformities or destruction of the eye."* Unfortunately, this classification was not based on new or revealing information. We therefore carried out detailed observations (Studies II/III) to assess its validity, refine the descriptions where necessary, and identify factors responsible for the various changes.

Table 4–1. Clinical classification of corneal cases (Study II)

Class	Category[1]	Clinical description	Cases (*n*)
X2	1	*Mild xerosis:* haziness and loss of luster	24
	2	*Moderate xerosis:* surface has dry, peau d'orange appearance	24
	3	*Severe xerosis:* presence of keratinized plaques	5
X3A	4	*Small ulcer(s):* sharply demarcated, 1–3 mm in diameter, superficial or deep	45
	5	*Large ulcer:* usually full-thickness, may be variant of category 4 or 6 lesion	5
X3B	6	*Localized stromal necrosis*	34
	7	*Complete corneal necrosis:* unilateral	13
	8	*Complete corneal necrosis:* bilateral	12

1. Classified by most severe lesion in worst eye.

From Sommer et al. [197].

To document the clinical spectrum of corneal involvement and assess the etiology and significance of the various changes, the 162 consecutive cases

*It is symptomatic of the problem that plagues these definitions that in the first publication to make use of this classification [45] it is misquoted and its intent thereby subverted: X3A is defined as a corneal erosion and X3B as an "ulcer or keratomalacia."

of presumed corneal xerophthalmia in Study II were divided into 8 clinical categories (Table 4-1) on the basis of the appearance of the worst lesion in the most severely affected eye [196,197]. To preserve the terminology and practical distinctions embodied in the WHO classification these categories may be grouped, by severity, outcome, and potential pathogenesis, as follows:

X2: *categories 1–3* corneal xerosis	Minimal inferior haze apparent on handlight examination, through frankly thick, elevated, keratinized plaques on the corneal surface.
X3A: *categories 4–5* corneal ulcers with xerosis	Stromal loss in the form of relatively small, round to oblong, sharply demarcated, shallow to full-thickness ulcers accompanied, in most (but not all) instances, by evidence of X2.
X3B (I): *category 6* keratomalacia (localized)	Localized corneal dissolution or "necrosis."
X3B (II): *categories 7–8* keratomalacia (generalized)	Generalized corneal dissolution or necrosis of one or both eyes.

Cases with punctate keratopathy but apparently clear corneas (on handlight examination) are classified by their other manifestations of vitamin A deficiency (XN or X1).

Punctate keratopathy

The earliest, mildest corneal change observed in vitamin-A-deficient individuals appears to be a fine, fluorescein-positive, superficial punctate keratopathy (SPK) (Plate 11), usually beginning inferiorly, especially inferonasally (Fig. 4-1) [171]. As the disease progresses the lesions become more numerous, concentrated, and affect a larger portion of the corneal surface (Fig. 4-2). Sixty percent of corneas of patients with confirmed nightblindness and 75% of those of patients with vitamin A responsive conjunctival xerosis were affected, even though their cornea appeared crystal clear on handlight examination. Punctate keratopathy was far less prevalent among

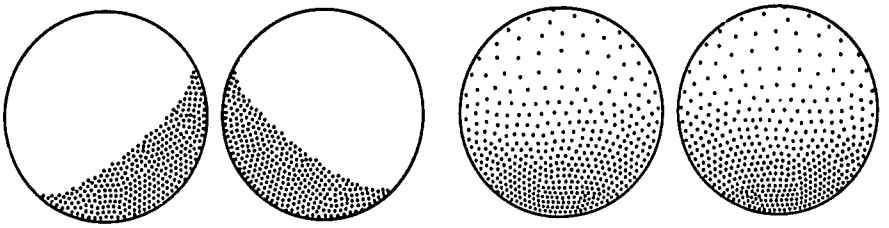

Fig. 4-1. In xerophthalmia fluorescein-staining punctate lesions have a strong predilection for the inferior and nasal aspects of the cornea. (From Sommer et al. [171])

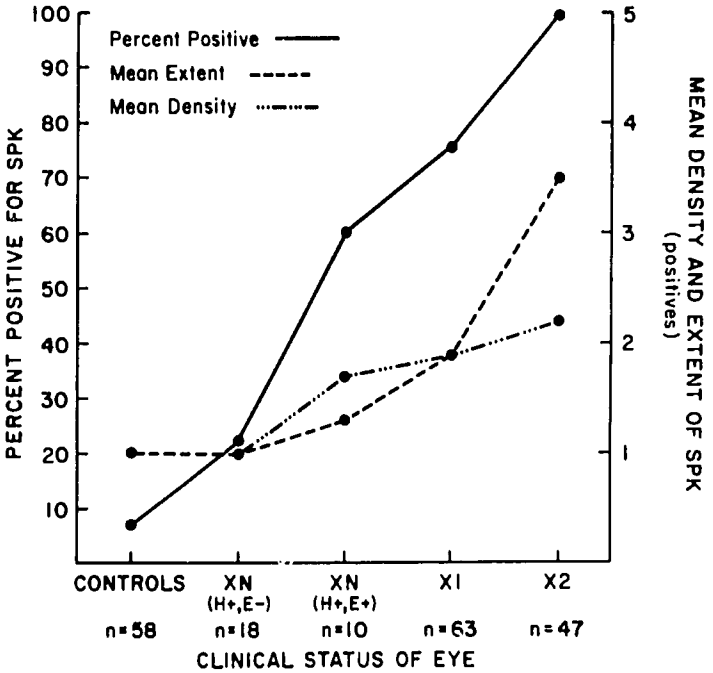

Fig. 4-2. The prevalence, extent, and density of fluorescein-staining punctate keratopathy increased with the severity of xerophthalmia ($p < .01$ for linear trend). Numbers smaller than elsewhere because analyzed and published before recruitment for other purposes completed. Extent graded: 1 (inferonasal), 2 (inferior half of cornea), 3 (inferior three-fourths of cornea), 4 (entire corneal surface). Density graded: 1 (mild), 2 (moderate), 3 (heavy). Studies II/III. (Drawn from Sommer et al. [171])

Table 4–2. Response of punctate keratopathy to 200,000 IU vitamin A (Study III)

Duration since treatment	Number of eyes	Percent improved	Percent cured	Total percent improved or cured
1–3 days	20	40	0	40
4–7 days	24	75	25	100
2 weeks	20	20	80	100
1 month	26	–	100	100

From Sommer et al. [171].

controls or patients with vitamin A nonresponsive conjunctival xerosis (also see Table 3-12), and, when present, was sparse and limited in extent [101].

Punctate keratopathy responds rapidly to vitamin A therapy [171]. In patients receiving a single oral dose of 200,000 IU vitamin A, all affected eyes improved within one week, and were cured within four (Table 4-2).

Healing begins with loss of staining, producing a mixture of staining and nonstaining white specks. Within one to two weeks many of the nonstaining specks become lightly pigmented. By the fourth week only nonstaining, pigmented epithelial or subepithelial specks remain, most prominently inferiorly, where they may persist for months.

As controls, 18 eyes with Bitot's spots of 10 patients who received low-dose (700 IU) vitamin A were followed closely [171]. By the end of the month none had improved and 11 (61%) had actually deteriorated, four of them alarmingly so. These patients were then treated with a single oral dose of 200,000 IU vitamin A and all improved within nine days. Both eyes of one low-dose recipient healed spontaneously, at 65 days, presumably from an improved diet or treatment outside the study.

By the time punctate keratopathy covers most of the corneal surface, involvement is generally apparent on handlight examination, thus qualifying the condition for the designation "corneal xerosis" (X2).

X2: Corneal xerosis (categories 1–3)

Corneal xerosis (of any severity) was present in 93% of all eyes of patients with frank corneal involvement in at least one eye.

Category 1: The first visible change on handlight examination is a haziness of the corneal surface, usually most pronounced adjacent to the inferior limbus but occasionally centrally instead (Plates 9,10). The haziness

becomes more distinct a few seconds after the lids have been retracted, the tear film having had a chance to run off, revealing the dry, "nonwettable," finely irregular surface below. Mild involvement may be missed by the casual observer; many such cases have been referred to us for nightblindness or Bitot's spots. In more advanced disease haziness and decreased wettability are apparent over a larger portion of the corneal surface, although usually remaining most pronounced inferiorly. In 83% (20/24) of cases both eyes were involved, usually symmetrically.

The most prominent abnormalities seen on slit-lamp examination are the punctate epithelial changes already described (Plate 11). Some corneas present with a mixture of staining and nonstaining specks, suggesting previous episodes of active disease. An occasional case presents with nonstaining, fine epithelial microcysts with or without more typical punctate lesions (SPK) interspersed between them. These cysts are often water repellent, appearing even less fluorescent than the tear film itself. Within one to two days of systemic therapy the cysts usually disappear, being replaced, in many instances, by typical staining punctate lesions.

The other abnormality apparent on slit-lamp examination is stromal edema. As with the surface changes the inferior aspect of the cornea is usually first and most severely affected.

The extent of corneal haze is directly related to the density (Table 4-3) and extent (Table 4-4) of punctate changes and degree of stromal edema (Table 4-5). Dense accumulations of healed, residually pigmented specks may cause inferior haziness to persist indefinitely. Central corneal haze, when present, is therefore a better index of activity.

Corneas with active disease often have a ground-glass appearance on retro-illumination. This is most prominent in areas of dense punctate ker-

Table 4-3. Corneal haze and density of punctate keratopathy in mild xerosis (category 1)

Extent of corneal haze	Density of SPK[1] (percent of eyes in row)			Total eyes (n)
	mild	moderate	severe	
0	20	60	20	5
Inferior 1/3	6	69	25	16
Inferior 2/3			100	2
Entire surface		16	84	25

1. Difference in SPK density between ≤1/3 corneal haze and ≥2/3 corneal haze, $p<.001$.

Table 4–4. Corneal haze and area of punctate keratopathy in mild xerosis (category 1)

Extent of corneal haze	Area of SPK[1] (percent of eyes in row)				Total eyes (n)
	Inferior/ Nasal	Inferior 1/2	Inferior 3/4	Entire surface	
0	20	60		20	5
Inferior 1/3	13	56		31	16
Inferior 2/3				100	2
Entire surface			8	92	25

1. Difference in corneal area covered with SPK ≤1/3 corneal haze and ≥2/3 corneal haze, $p<.001$.

Table 4–5. Corneal haze and degree of stromal edema in mild xerosis (category 1)

Extent of corneal haze	Corneal thickness (× normal)[1] (percent of eyes in row)			Total eyes (n)
	1	1.5	≥1.75	
0	100	–	–	5
Inferior 1/3	63	37	–	16
Inferior 2/3	100	–	–	2
Entire surface	12	88	–	25

1. Difference in corneal thickness with SPK ≤1/3 corneal haze and ≥2/3 corneal haze, $p<.001$.

atopathy, the same sites at which tear film break-up time is usually briefest.

Category 2: In more severe involvement, the corneal surface has a dry, granular, peau d'orange appearance (Plates 13,19), which is usually most prominent inferiorly, either adjacent to the limbus or as a horizontally oval area 2–3 mm above it. Occasionally these changes first became apparent one to two days after initiation of therapy. Multiple patches of similar appearance are sometimes distributed about the corneal surface. Involvement is generally symmetrical in the two eyes. Haziness tends to be more severe than in category 1.

The frankly xerotic nature of the changes is often apparent, even on handlight examination of the fluorescein stained cornea. Many eyes have severe, dense punctate staining while in others the flourescein stains or pools in cracks on the cornified surface, presenting a "treebark" appearance (Plates 15,17,18).

The entire cornea usually has a markedly ground-glass appearance on retro-illumination, while the surface tends to be completely covered by punctate lesion (96% vs 65% in milder disease (grade 1), $p < .01$). The density of these lesions, however, is the same in both groups, even after correction for the degree of haziness. The fluorescein-staining punctate lesions are sometimes very dense, almost confluent.

"Treebarking" appears to represent a solid sheet of cornified epithelium. Although fluorescein pools in the cracks, the surface is usually free of punctate staining (Plate 15). Following therapy the cornified layer loses its attachment to the surface below and peels off (Plate 15). The free end may fold over or break off and slough. The central, interpalpebral zone is generally the last to clear, presumably because of the limited abrasive action of the lids at this site (compare Plates 17 and 18).

The severity of edema tends to be greater than in category 1: corneal thickness was at least twice normal in over one-fifth of eyes.

Category 3: Thick, elevated, frankly xerotic plaques are the most severe form of nonulcerating surface change (Plates 17,18,20). Relative protection from lid abrasion and the greater potential for exposure probably account for their predominance in the interpalpebral zone. Particularly heavy plaques are foamy or amorphous in nature, suggesting an agglomeration of bacteria and fragmented keratin as in thick Bitot's spots. Plaques, xerosis, and corneal haziness were present in both eyes of all five subjects.

In all ten eyes punctate keratopathy was of the densest sort, especially surrounding the plaques. The surface of the plaques themselves generally stain as linear or whorl-like crevices. With healing the plaques fragment and slough, sometimes being (transiently) replaced by areas of densely packed, fluorescein-positive punctate lesions.

Stromal edema was present in all eight eyes (four cases) in which it was sought.

At least one-third (20) of the 53 cases of X2 (categories 1–3) presented with a chief complaint compatible with corneal derangement: 12 because the child was keeping his eyes closed, 6 because he avoided bright lights, and 2 because he complained of "itchy eyes." A 24-year-old woman examined before this study began [104], with moderate corneal involvement (category 2), denied any foreign body sensation, grittiness, or dryness, but was moderately to severely photophobic.

Aside from their ocular appearance, there was little to distinguish cases of grade 1 from those of grade 2. Cases in category 3, however, were clearly more protein deficient and ill than those with milder disease.

Table 4–6. Protein status of cases of corneal xerosis (Study II)

	Clinical classification			
	1	2	3	Total
Albumin (μg/dl)				
number	24	24	5	53
mean	3.35	3.25	2.50	3.22
SD	0.50	0.45	0.41	0.52
Transferrin (mg/dl)				
number	22	21	4	47
mean	159	155	94	151
SD	85	95	124	93
Albumin: 1 vs 3: $p<.001$			Transferrin: 1 vs 3: $p<.01$	
2 vs 3: $p<.01$			2 vs 3: $p<.05$	

Age: Mean age fell with increasing severity of corneal disease (3.3, 2.8, and 2.6 years, respectively, for categories 1, 2, and 3).

Vitamin A status: Mean serum vitamin A and holo-RBP levels were similar in all three groups.

Protein Status. Levels of serum albumin and tranferrin (Table 4-6) were similar in groups 1 and 2. Levels among cases of category 3, however, were significantly below those of the other two ($p<.01$). In keeping with their poorer protein status, pedal edema was far more prevalent among cases in group 3 than among those in the other two groups (60% vs 15%, $p<.001$).

General nutrition: Weight for height was similar in all three groups. Other forms of nutritional deficiency (stomatitis, cheilosis) were rare.

Systemic illness: 80% of cases in category 3 (4/5) had a history of a recent febrile illness, vs 33% (8/24) of those in category 2 and 17% (4/24) of those in category 1 ($p<.01$ for linear trend). In addition, all five cases in group 3 were at least mildly/moderately ill; three (60%) of them were severely ill, a prevalence considerably higher than among those in the other two groups (5% and 18%, respectively) ($p<.02$). This is reflected in their higher mortality (Table 4-7).

Chronicity: There was no evidence from the history of nightblindness that vitamin A deficiency had been present any longer among cases in category 3 than among those in categories 1–2. Roughly 80% of cases in all three groups had such a history, and in 25% of these, nightblindness was said to have been present for at least one month. Conjunctival xerosis was no more extensive among eyes of patients in category 3 than in those of categories 1–2.

Table 4–7. Mortality among cases of corneal xerosis (Study II)

	Clinical classification			
	1[1]	2	3	Total
number	24	24	5	53
Died				
number	1	3	2	6
percent	4.2	12.5	40.0	11.3

1. All but the one death in category 1 occurred at least 1 month following presentation.

X3: Stromal loss (categories 4–8)

It is more difficult to devise a meaningful clinical subdivision for cases with stromal loss, since different mechanisms, with potentially similar outcomes, may be at work. Categories 4 and 6 contain cases with active, locally destructive corneal lesions of distinctive appearance. Category 5 contains cases with large, often perforating ulcers that may represent a transitional stage between the other two. Categories 7 and 8 contain cases with complete corneal destruction of one or both eyes, respectively.

The prevalence of binocular stromal loss increased with the severity of loss in the worst affected eye (Fig. 4-3), ($p < .001$ by linear trend). A statistically significant difference was present at each transition:4–5: 6, $p < .01$; 6: 7–8, $p < .01$.

X3A: Corneal ulceration (categories 4–5)

Since category 5 may be an extension of category 4, and the number of cases is relatively small, they are dealt with together.

Category 4: These cases were characterized by the presence of one or more sharply demarcated ulcers of varying depth. Detailed pictures are available on 46 of the 53 ulcerated eyes. The commonest form of stromal loss, present in over 70% (33/46), was a punched-out, smooth-walled, cylindrical ulcer, looking as if a cork borer or trephine had been applied to the eye (Plates 21,23). The margins were regular, not undermined, and in only a minority of instances (5/33, 15%), swollen. In 13% (6/46) of affected eyes the worst lesion was a smooth, saucer-shaped depression, otherwise similar in appearance to the punched-out form. Infiltration, if present, was slight and confined to the base, inner wall, or a thin rim about the ulcer (Plate

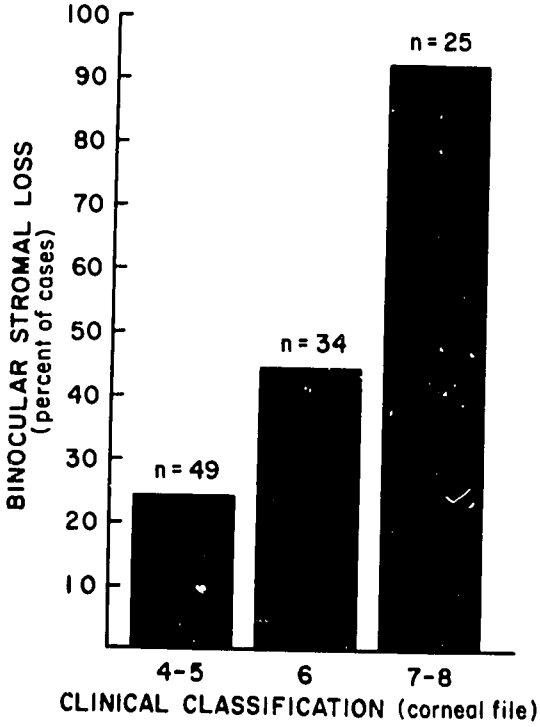

Fig. 4-3. The more severe the xerophthalmic stromal damage in the worst affected eye, the greater the likelihood of active stromal loss in the other eye ($p < .001$ for linear trend). One case in category 4, with a unilateral staphyloma, is omitted. Study II. (Drawn from Sommer et al. [197])

25). In rare instances a pinpoint infiltrate was present at a distance from the main ulcer, occasionally at the base of an erosion or second, superficial ulcer. In an additional 7% (3/46) of affected eyes such shallow, saucer-shaped, infiltrated ulcers were the most severe lesion. In 9% (4/46) of affected eyes the worst lesion was a mild, seemingly transitional stage in which a large, subepithelial bulla, sometimes encountered in categories 1–3, ruptured, leaving a densely staining erosion or superficial ulcer.

91% (48/53) of affected eyes contained only a single ulcer, 6% (3/53) contained 2 ulcers, and 4% (2/53) three. Over three-fourths of all ulcers were located in the inferior and/or nasal quadrants, most commonly the former. The vast majority were round, 91% (40/44) being 0–2 mm in diameter regardless of location. Of those in the inferior quadrant, 45% (9/20) were horizontally oval, 1–3 mm in length, and at least 1–2 mm above the limbus (Plates 16,24).

The depth of the main ulcer was recorded in 42 of 53 affected eyes. In 55% it was between one-fourth and one-half corneal thickness. In only one instance (2.4%) was it greater than three-fourths depth.

Among the 44 cases in which both corneas were involved, ulcers were present bilaterally in 8. In all but one of these eight the location, shape, size, and depth of the lesions were symmetrical in the two eyes, often amazingly so: in one case two ulcers of 1 mm diameter each were located inferonasally in both eyes; in another, a single ulcer was present in the (rarely affected) superior-nasal quadrant of both eyes. In only one case were they in different locations: inferonasal in one eye, inferotemporal in the other, both being superficially staining infiltrates.

Conjunctival injection, of varying intensity, was present in a majority of eyes with ulcers (41/52, 79%, 1 case not recorded). A hypopyon, usually less than 20% in size, was present in one-third of eyes with ulcers (Plates 24,25,27). It was almost twice as prevalent (34%) among cases with conjunctival injection as among those without (18%), and often adherent to the posterior surface of the cornea immediately deep to the ulcer.

Two cases of corneal xerosis included in categories 2 and 3 developed ulcers while under observation. Both were ill and severely protein deficient. Both died, one seven months and the other one month following presentation. They illustrate potential mechanisms by which corneal ulceration might develop in xerotic corneas.

Case 200/068: a two-year-old severely malnourished child with rhonchi, pedal edema, stomatitis, and draining right ear was referred for Bitot's spots. Both eyes had extensive corneal xerosis with a treebark, cornified layer in the inferonasal quadrant. With hospital therapy (including a high protein diet and 2 massive doses of vitamin A) his general condition and eyes improved. By day 3 the pedal edema had largely subsided, the conjunctival xerosis had disappeared, and the cornified layer begun to breakup and slough, especially adjacent to the inferior limbus. By day 7 the cornified layer was completely gone. During the second week the child's general condition deteriorated: he developed diarrhea, anorexia (requiring a feeding tube), and the pedal edema returned. Although the diarrhea was soon controlled, serum albumin had fallen from an already low 2.5 to 2.1 g/dl by day 15. Both corneas deteriorated: by day 15 numerous fluorescein-positive punctate lesions and nonstaining epithelial microcysts appeared inferiorly despite good lid closure. On day 17 the surface of the inferior portion of the right cornea developed an irregular, bumpy appearance, due to the presence of 5 small bubblelike mounds, all sharply demarcated cystic swellings in the superficial stroma. The tear film in both eyes was irregular and unstable. Within five days a sharply demarcated, perfectly clear, intensely staining noninfiltrated shallow ulcer replaced the bubblelike

mounds inferocentrally. The ulcer was surrounded by a moderately hazy zone, the rest of the cornea being minimally hazy, studded with SPK, and 1.5 times normal thickness. Three days later the left cornea assumed an identical appearance. By day 28 the erosion/ulcer of the left eye had healed without a trace. The child died on day 37.

Case 200/069: a severely ill, malnourished (marasmic-kwashiorkor) three-year-old boy with bloody diarrhea was seen with skinlike changes of his entire conjuctiva, and heavy xerosis with treebark cornification and adherent amorphous white plaques inferiorly in both corneas (Plate 17). His serum albumin was 1.9 and holo-RBP 1. Two days after admission and initiation of therapy a sharp margined, punched-out, flourescein positive depression formed at the receding, inferior edge of the xerotic plaque (Plate 18). This presented a striking appearance, the crevices of the remainder of the plaque converging on the ulcer, suggesting that underlying epithelium and perhaps stroma as well had been lost when the overlying plaque sloughed. There was no evidence of infiltration and the margins were not swollen. By day 8 the xerotic plaque in the left eye was confined to a small, nasally remote area inferiorly. What remained of the cornified layer was folded upon itself some distance from where the ulcer had been. The ulcer itself had reepithelialized, forming a clear, nonstaining, shallow depression. The child's general condition also improved, his edema disappeared, and his albumin rose to 2.6 by the end of the first week.

A number of cases presented with both ulcers and potentially precursor lesions. In some, ulcers were located amid treebark cornification; in others they were associated with stromal bullae. Several are detailed in Appendix III. In one case a classical punched-out ulcer evolved from a cluster of bullae.

Case 200/168: The left eye of this two-year-old girl contained a greyish-white, cystic, bulging, necrotic lesion (category 6). However, the right eye appeared, on handlight examination, to contain a classically small (1 mm), circular, sharply demarcated hazy lesion with central staining, suggesting a punched-out ulcer. Slit-lamp examination revealed that the lesion actually consisted of a rosette of clear epithelial or subepithelial microcysts. The central cyst had apparently broken, resulting in the staining. Of perhaps greater significance, a clear cleft parallel to the surface was present in the anterior stroma. Although centered below the more superficial bullae, and widest at that point, it extended beyond their area of involvement. Serum albumin was 3.3 g/dl and vitamin A 1 μg/dl. The child received 200,000 IU vitamin A in oil orally and topical retinoic acid. By the fourth day the bullous lesion had become a classical, ¼ depth punched-out ulcer. By day 10 the ulcer had healed, leaving a small leukoma behind.

Another case presented an extraordinary picture containing many of the elements already discussed and suggesting the potential role of localized desiccation and dellen formation [198–200].

Case 200/160: A 19-month-old boy had a serum vitamin A of 4 μg/dl, albumin of 3.2 g/dl, and a weight for height greater than 90% of standard. The right eye was white and quiet, with conjunctival xerosis involving the inferior 180 degrees of bulbar conjunctiva and heavy punctate keratopathy, though the cornea still appeared clear by handlight examination. The conjunctiva of the left eye was injected but not xerotic looking. Centrally the corneal surface was irregular (Plate 25), due to alternating mounds (clear epithelial or thin-walled superficial stromal vesicles) and depressions, the latter looking as if there were stromal loss or more likely, desiccation, as in dellen. If these were, in fact, dellen they were atypical: areas of superficial desiccation overlying stroma two to three times normal thickness. None of these irregularities stained (Plate 26). Break-up time (BUT) in the area was zero seconds. Inferior to this irregular patch were 2 ulcers of peculiar appearance. Both were oval with saucer-shaped, gently sloping, nonstaining walls of one-fourth corneal depth (Plate 25). Midway between the outer rim and center of each ulcer the walls abruptly assumed a more typically cylindrical shaped, punched-out, intensely staining configuration extending an additional one-fourth to one-half depth into the stroma (see smaller ulcer, Plate 26). It is tempting to speculate that a clear, central stromal vesicle had broken, resulting in a typically punched-out staining ulcer surrounded by a nonstaining, epithelial covered, dellenlike depression.

As part of a therapeutic trial the child received 200,000 IU oil-miscible vitamin A intramuscularly, and topical retinoic acid to the left eye three times daily. The inferior ulcer proceeded to heal uneventfully: at two days a sharply demarcated area of whitish (presumably) infiltration appeared at the base, the only area still staining. By the next examination, on day 5, the entire area of the ulcer had become a clear, nonstaining corneal depression (Plate 27). At two days the area of irregularity superior to this ulcer was unchanged (Plate 26). By day 5, however, it had an identical appearance to the inferior ulcer: the alternating bumps (clear, intrastromal cystic spaces) and depressions had been replaced by a clear, nonstaining, saucerlike depression, and the generalized stromal edema in the area had disappeared.

The temporal ulcer did not fare as well as the inferior one. By day 2 the complex saucer/cylindrical shape had been converted to a deeper "V" shaped gutter, now staining edge-to-edge (Plate 26). Although topical antibiotic therapy (garamycin/bacitracin five times daily) was instituted at this point, the ulcer continued to deteriorate. By day 5 the area was opaque, (Plate 27), its surface a fluorescein positive bulging mass, like an abcess more typical of cases in category 6. The patient was removed from the hospital on day 6 and when next seen, at three months, had two leukomas: a dense one in the area of the initial temporal ulcer, and a much paler one in the area of the initial inferior ulcer. The depression found in the area of original irregularity was barely discernible. At least a partial explanation for the poor response in this patient was the use of oil-miscible vitamin A intramuscularly: the vitamin A level, initially 4 μg/dl, peaked at 9 μg/dl at 4 h, and was back down to 4 μg/dl at one day, where it persisted. His serum albumin was a reasonable 3.2 g/dl.

As already suggested, one of the earliest responses to therapy is formation of a whitish, presumably infiltrated area, usually at the base or within the wall of the ulcer. In some instances, especially where infiltration is prominent or the ulcer large, deep, or adjacent to the limbus, the ulcer "fills in" with marked infiltration/edema in the base and surrounding area, and eventually scars over. Shallow, central ulcers tend to reepithelialize uneventfully, usually within two to three days, forming clear depressions easily missed on routine handlight examination.

Category 5: This group contained five cases, distinguished from those in category 4 by the presence, in at least one eye, of a large, full-thickness, stromal ulcer (reaching to, or beyond, Descemet's membrane). These cases were also more likely to have bilateral stromal defects (4/5). The corneal defects were all localized and sharp-margined. They probably represent a modification or late stage of the processes encountered in categories 4 (surface ulcers) and 6 (necrotic stroma). Most cases provide interesting transitional changes between these two other groups, often containing lesions typical of one or the other in the same or fellow eye. Two such cases are presented below and two others in Appendix III.

Case 200/091: a three-year-old boy with kwashiorkor, an albumin of 2.8 g/dl, and transferrin of 30 mg/dl presented with a right cornea that was 3 times normal thickness and contained a sharp-margined ulcer which had perforated centrally. The walls about the perforation were more swollen and opaque than characteristic for category 4. The anterior chamber was flat. The left eye had two distinct areas of treebark xerosis: one inferiorly, adjacent to the limbus, and another, a sickle-shaped swath 2 mm above the first, which terminated nasally in a 1 mm ulcer of ½ depth and slightly edematous, shaggy appearance. Both corneas healed without consequence, the right as an inferior adherent leukoma, the left as a small inferonasal leukoma.

Case 200/158: A severely ill, three-year-old female with marasmic-kwashiorkor died on the day of admission. Serum vitamin A had been 4 μg/dl, albumin 1.9 g/dl, and transferrin 20 mg/dl. The right eye contained a classical punched-out 2 mm shallow ulcer superotemporally of ¼ corneal depth and two pinpoint ulcers superonasally (Plate 21). Although an anterior synechia had not been noted initially, slit-lamp examination following dilitation revealed densely pigmented tissue caught up in the posterior aspect of the cornea deep to the shallow ulcer, and clinically normal stroma in between. The left cornea displayed a large (5 mm) central, perfectly round, punched-out, full-thickness defect, through which Descemet's membrane, and iris behind, were bulging (Plate 22). The inferior margin of the defect was moderately hazy.

The age distribution of categories 4 and 5 were identical. But cases in the latter group were clearly sicker and more malnourished: the prevalence

Table 4–8. Biochemical parameters in mild (category 4) and moderate (category 5) xerophthalmic ulceration (Study II)

	Clinical classification	
	4	5
Serum vitamin A (μg/dl)		
number	28	4
mean[1]	7.6	3.3
SD	3.9	1.5
Serum albumin (g/dl)		
number	44	4
mean	3.2	2.7
SD	0.6	0.7
Serum transferrin (mg/dl)		
number	41	4
mean	134	75
SD	78	102

1. $p<.05$

of respiratory tract infection, fever, anorexia, pedal edema, and "life threatening illness" was at least twice as common as among cases in category 4 while their mean serum levels of vitamin A, albumin, and transferrin were all lower (Table 4-8).

X3B: Corneal necrosis (categories 6–8)

Except for the size of the area involved, the clinical appearance of grade 6–8 lesions are identical and readily distinguished from those of grades 1–4.

Category 6: Grade 6 was characterized by the presence of localized, deep stromal necrosis. The lesions were opaque, grey to yellow in color, and ranged in size from 2 mm to involvement of almost the entire cornea (by definition the cutoff between categories 6 and 7/8) (Fig. 4-4; Plates 27,29,31).

In general, greyish lesions were extremely edematous and cystic. Although their surface often appeared flush (or even protruding above) surrounding, generally edematous cornea, they lacked much, if not most, of their stroma. With treatment, edema disappeared and the lesions collapsed. Previously indistinct borders contracted down to sharply demarcated deep stromal defects, often considerably smaller than one originally

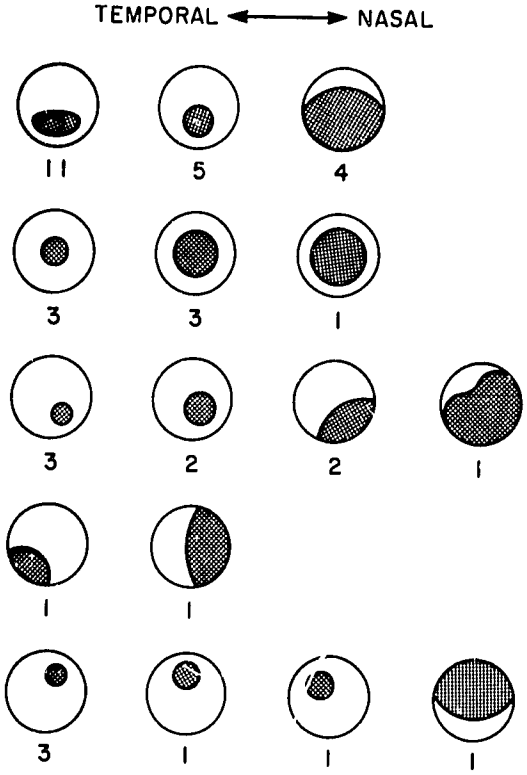

Fig. 4-4. In the vast majority of cases with focal corneal necrosis (category 6) the lesions were located in the inferior and/or nasal quadrants. Study II.

anticipated (compare plates 29 with 30; 31 with 32), suggesting reversible changes surrounding an area of sharply focal, irreversible cylindrical dissolution. Occasionally some of the edematous tissue sloughed. Deep stromal loss was attended by descemetoceles. With inadvertent pressure these could rupture, resulting in perforation and iris prolapse. There was rarely any evidence of infiltration about the lesions.

Other lesions were yellowish in color, suggestive of heavy, focal inflammatory cell infiltration rather than quiet dissolution. Some of these cases represent a different stage in the same process. In a number of instances these formed protuberant, dome-shaped lesions (Plates 29,31), sometimes with smooth, glistening surfaces. Several failed to stain with fluorescein at the time of admission, suggesting that necrosis might have proceeded below an intact epithelium. On the other hand, almost all began to stain within one to three days. Whether initial absence of staining was due to

some unrecognized factor masking epithelial loss, or subsequent staining was secondary to changes induced by the reparative process, is uncertain. The necrotic tissue sloughed, revealing a descemetocele below. Purulent discharge was rarely present.

Descemetoceles, especially large (≥ ¾ corneal surface) perforated ones, scarred extremely slowly. Small ones (< ¼ corneal surface) reepithelialized rapidly (two to five days), and scarred quickly (especially if some stroma remained to serve as scaffolding). The smaller, rapidly healing lesions became adherent leukomas, while the larger, more recalcitrant ones, anterior staphylomas (eventuating in shrunken, phthisical globes).

The inferior quadrant was most commonly affected (63%) (Fig. 4-4) though the lesions often extended beyond its borders. The nasal quadrant was more commonly involved than the temporal.

Serum levels of vitamin A and transferrin tended to be lower among patients with larger lesions, though not to a statistically significant degree (perhaps because of the small numbers involved).

In categories 6–8, the cornea of the "second" eye was more severely affected than among cases in category 4: 44% suffered stromal loss (vs only 18% in group 4 ($p < .05$)). Fully 88% had some degree of frank xerophthalmic involvement. Of the four corneas seemingly clear on handlight examination, three had extensive SPK and the other had bilateral conjunctival xerosis.

Typical (category 6) necrotic lesions were present bilaterally in nine cases: in all, the size and location of the lesions in the two eyes were virtually identical. In the 6 instances in which the stromal lesion in the second eye was milder (grade 4, punched-out type) the location of lesions in the two eyes was still symmetrical.

Generalized stromal edema was extremely common, and often severe. Corneal thickness sometimes reached three to four times normal with marked shallowing of the anterior chamber, even in the absence of corneal perforation. Only rarely was there evidence of corneal exposure.

The following case illustrates the reversibility of some areas of apparent necrosis.

Case 200/171: A three-year-old girl presented with conjunctival xerosis and two small, classically punched-out staining ulcers in the right eye, and a large, greyish, opaque, nonstaining bulging lesion involving three-fourths of her left cornea. Her protein status was reasonably good (serum transferrin 102 mg/dl, albumin 3.5 g/dl) but serum vitamin A only 2 μg/dl. She received 200,000 IU vitamin A orally on admission and again the following day. By day 1 the surface of the swollen, opaque

lesion in the left eye had begun to stain. By day 5, the last follow-up, it had already shrunk to one-third its original size, and involved only the inferior area. Except for some mild, generalized edema (reduced from three times normal thickness on admission) the rest of the cornea appeared normal. This is an extreme example of the fact that some apparent "necrosis" is largely (and rapidly) reversible.

In the following case of vitamin A and protein deficiency, classical focal necrosis was precipitated by measles; the rest of the cornea was seemingly free of clinical disease; and the area of irreversible destruction was smaller than it initially seemed.

Case 200/124: Measles rash and "conjunctivitis" appeared in this 19-month-old boy ten days prior to presentation. Three days later he closed both eyes and had kept them closed since. On admission he was noted to have a "healing" measles rash, pneumonia, and marasmic-kwashiorkor. Serum albumin was 2.6 g/dl, transferrin 115 mg/dl, vitamin A 4 μg/dl, and holo-RBP 2 μg/ml. Both conjunctivae were injected, without evidence of xerosis. Neither cornea looked xerotic. In the inferior half of the right cornea was a horizontally oval, sharply demarcated, slitlike ½ thickness ulcer surrounded by an area of moderately heavy haze, which itself was surrounded by less dense haze. An opaque, necrotic, "mushy" looking lesion with central descemetocele and probable iris prolapse occupied the inferior one-half to two-thirds of the left cornea. The opaque area was greyish and edematous. The transition between the lesions and remaining cornea (superiorly) was dramatic, especially in the left eye, where it was crystal clear and free of any SPK. On vitamin A therapy the two eyes healed uneventfully, the right eye as a faint macula, the left as an adherent leukoma involving only the inferior two-third of the extent of the original lesion.

Categories 7–8: In these groups the necrotizing or melting process involved the entire cornea of one (category 7) or both eyes (category 8). In some instances the entire cornea resembled a relatively firm, yellowish-white abscess whose surface was seemingly intact (Plate 28). In others, what cornea was left resembled thick mush or gelatin (Plates 12, 14). The final result was the same: the corneal stroma sloughed, usually within 1–3 days, resulting in an enormous descemetocele (occasionally retaining a thin stromal or fibrinous covering) (Plate 22) or (rarely) complete prolapse. The peripheral 1 mm corneal/limbal zone was spared dissolution: it was usually edematous and opaque on admission but remained vital (Plates 12,14,22,28). Unlike some instances in category 6, where the surface of the localized "abscess" did not stain initially, all lesions in categories 7–8 did.

Two forms of healing are seen, depending on the amount of residual stroma. Where some stroma remains, a mixture of scarring and (often multiple) descemetoceles develop, all of which eventually scars over. Where all stromal tissue has melted away a peculiarly cross-banded star pattern of

iris covered by Descemet's membrane bulges forward in the quadrants (Plate 22). This scars slowly, the individual remaining at risk of complete prolapse for weeks to months. Both situations commonly result in a large, protuberant staphyloma, which may later shrink as the eye becomes phthisical.

In some cases the "necrotic" cornea is completely clear, white, and cystic. In one instance a clear descemetocele was present centrally, as if there was insufficient stroma left to swell and produce the characteristically opaque appearance. In this instance the anterior chamber was formed and iris in its normal position. It healed as a flat, vascularized scar.

The clinical course in several patients suggests that the initial process is one of stromal dissolution, followed by infiltration of the devitalized tissue.

Case 200/096: A two-year-old girl with kwashiorkor and serum vitamin A of 3 μg/dl, holo-RBP of 2 μg/ml, albumin of 2.9 g/dl, and transferrin of 20 mg/dl presented with an almost pure descemetocele of the right cornea, and white, opaque dissolution of the entire left cornea. One to two days later the left cornea was yellow, more opaque, and bulging.

In only a single case in category 7 was the opposite eye normal on handlight examination, while 54% (7/13) of cases suffered bilateral stromal loss. By definition, all cases in category 8 suffered complete corneal destruction bilaterally. Otherwise the two groups of cases did not differ, clinically or biochemically.

5. Corneal involvement

II. Clinical-histopathologic correlations

Corneal tissue was available for histopathologic examination from a small number of study participants who either died or underwent enucleation [520].

X2: Corneal xerosis

Two cases of corneal xerosis, both responding poorly to therapy, died while their corneas were still hazy. One cornea retained numerous, confluent, fluorescein-staining punctate lesions. In neither case was there evidence of residual keratinization.

Case 200/084: A severely marasmic two-year-old girl (case 200/084) presented with minimal inferior haze and mild punctate keratopathy in both eyes. Serum holo-RBP on admission was 1 μg/ml. Therapy included 100,000 IU vitamin A intramuscularly on admission, 200,000 orally the following day, and retinoic acid topically to the right eye once a day. By day 4 the right cornea was crystal clear and the left still had minimal-mild haze and a few SPK. The eyes remained unchanged through day 10. The following day she developed severe diarrhea, and despite the appearance of pedal edema on day 11, became functionally dehydrated. Her Schirmer test, which had registered 2–4 mm on admission, dropped to 0 mm of wetting in both eyes. Both eyes looked worse: the right contained minimal inferior haze, moderately dense punctate keratopathy, and nonstaining epithelial microcysts over most of its surface; the left had moderate haze, especially inferiorly, and large areas containing confluent SPK. The child died the same day.

Histologic specimens of the superior and inferior-nasal quadrants of the right cornea appeared normal. The epithelium in the inferior-nasal quadrant of the left cornea appeared thin and attenuated, and in two areas there were epithelial facettes (shallow defects in Bowman's membrane filled in, and covered over, by epithelium). The epithelial facettes may represent healing of early, minimal superficial ulceration.

Case 200/078: This child presented with advanced, marked, horizontally oval xerotic plaques 2 mm above the limbus in each eye. As in other severely malnourished children who fail to thrive, his ocular lesions responded poorly to vitamin A. By 3½ weeks, the right cornea was clear although the left was still mildly hazy inferiorly. The child died six days later. Inferonasal corneal specimens were entirely normal to light microscopy.

X3: Corneal Ulceration/Necrosis

Histologic material was available from three study participants with active corneal destruction of varying severity and duration [196].

Case 200/101, with relatively fresh disease, was extremely informative. One cornea contained small, classically punched-out ulcers. The other cornea was almost entirely descemetocele. Light and electron microscopy confirmed the sharply focal nature of both sets of lesions, scarcity of inflammatory cells in many areas of active necrosis, and the absence of bacteria.

Case 200/101: A severely marasmic (weight for height <60% of standard) one-year-old boy had a serum albumin of 2.2 g/dl, transferrin of 40 mg/dl, vitamin A of 10 μg/dl, and holo-RBP of 2 μg/ml. He had a history of nightblindness. The right cornea was largely replaced by a near limbal to limbal descemetocele. The left cornea contained two ¾ depth, sharply punched-out, adjacent ulcers, each 1 mm in diameter, and a deep, intact, anterior chamber. These ulcers were surrounded by a moderate (1 mm) rim of infiltrate. The child received 200,000 IU vitamin A orally on admission and again the following day, and frequent topical antibiotics and systemic penicillin and streptomycin. On day 1 the ulcers were clearly filling in, a process which was even more advanced by day 2. On the morning of day 3 the child died, and both corneas were biopsied. The right cornea, which had received topical retinoic acid in addition to the other agents, had remained unchanged throughout.

Histopathologic examination of the right cornea revealed keratinized epithelium overlying a thin layer of lush, early fibrous tissue lined posteriorly by iris (Fig. 5-1A). The iris was infiltrated with mononuclear cells. No bacteria were noted.

The left cornea contained keratinized epithelium that was markedly edematous but lacking in a granular cell layer. The basal layer contained large, plump cells with prominent nucleoli. There was an abrupt loss of Bowmen's layer and corneal stroma in a wedge-shaped configuration extending three-fourths of the way through the stroma (Fig. 5-1B). This area contained strands of necrotic collagen, a greater number of plump, spindle-stellate appearing fibroblasts than normal, and marked stromal edema, all below an intact epithelium. Most significantly, there was little inflammatory infiltrate and no bacteria in the area of collagen dissolution. The keratocytes had been replaced by large fibroblastic-type cells. At either side of this area the stroma was normal except for a paucity of keratocytes. In some areas Descemet's membrane was broached (Fig. 5-1C,D), despite the absence of clinical evidence for perforation. Such areas were covered anteriorly by edematous, necrotic material and overlying epithelium.

In the second case, 200/037, corneal material was obtained shortly after widespread necrosis replaced small, sharply demarcated ulcers. Although inflammatory infiltration was extensive, it was often most intense in otherwise normal areas surrounding involved stroma.

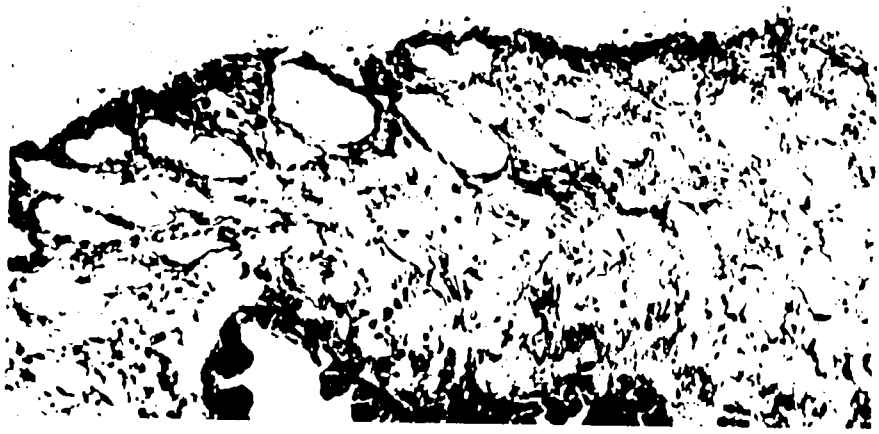

Fig. 5-1A. Right eye of case 200/101. There is total dissolution of corneal stroma. Intact keratinized epithelium covers fibrinous material and iris behind. No bacteria, and only rare inflammatory cells were present (periodic-acid Schiff, × 575). (From Sommer et al. [520])

Fig. 5-1B. Left eye of case 200/101. Peripheral area of lesion demonstrates sharp delineation and saucer-shaped configuration of stromal disintegration which was covered by intact keratinized epithelium (hematoxylin-eosin, × 45). (From Sommer et al. [520])

Fig. 5-1C. Same eye as in 5-1B, showing central area of lesion. Most of the stroma is destroyed as is Descemet's membrane behind. The sharply delineated saucer-shaped configuration of involvement is readily apparent. The entire area is covered by keratinized epithelium (hematoxylin-eosin, × 30). (From Sommer et al. [520])

Fig. 5-1D. Higher power view of section shown in Fig. 5-1C. The sharply focal nature of the lesion, and lack of both bacteria and significant inflammatory infiltrate, are readily apparent (hematoxylin-eosin, × 100). (From Sommer et al. [520])

Case 200/037: 10 days prior to admission this eight-year-old girl developed high fever, five days later a hemorrhagic rash on her face and extremities, and two days later "white spots" on both corneas. On admission she was considered moderately ill and only mildly (grade I) malnourished. The conjunctiva of both eyes was injected and the corneas hazy, especially inferiorly. 1–2 mm oval, sharp-margined shallow ulcers were present 2 mm above the inferior limbus, within the area of densest haze. Serum transferrin was 58 mg/dl and albumin 2.2 g/dl which was surprising given the absence of edema or other evidence of kwashiorkor, and suggested acute decompensation of protein metabolism. Unfortunately vitamin A levels were determined during the period of intermittent mechanical misfunction, and the results are therefore excluded from the tabulations. But while most determinations during this period were high, hers (all run in coded fashion on the same day) were low: 13 μg/dl on admission, 11 μg/dl one hour and 21 μg/dl four hours after the first oral dose of vitamin A, falling to 9 μg/dl two days (and an additional dose) later. Gentamycin and mycetracin were administered 5 times a day to the right eye. The lids were well opposed during the next two days and the eyes showed minimal improvement. On day 3 she became comatose, and the lower half of both eyes was noted to be exposed. The conjunctivae were white and quite ou. The entire right cornea had a yellow, opaque, necrotic appearance. The left cornea was gelatinous centrally with iris seen through the center. She died within a few hours and the nasal quadrants of both corneas were biopsied.

Histopathologic changes in the right cornea included necrosis and foci of gram-negative rods. Some areas of necrosis were acellular, but surrounded by otherwise normal stroma infiltrated by neutrophils (Fig. 5-2A). Gram-negative bacilli were present (Fig. 5-2B).

The specimen from the left eye was lined, in places, by keratinized epithelium. There was an abrupt transition to stromal necrosis with fraying of collagen. Polymorphonuclear leukocytes were present throughout the stroma, sometimes surrounding rather than within the area of necrosis (Fig. 5-2C). Actinomyces-like organisms lined the exposed margin of necrotic stroma in the peripheral area of the descemetocele (Fig. 5-2D).

The last and most chronic of the three cases, 200/006 documents the risk of secondary bacterial infection and endophthalmitis in the xerophthalmic eye.

Case 200/006: A four-year-old boy presented with a history of measles, fever, and diarrhea one month prior to admission, and a red, tearing, photophobic eye of two weeks' duration. He had received antibiotic eye drops, pills, and injections. Serum vitamin A was 6 μg/dl and albumin 2.4 g/dl. The conjunctiva and cornea of the right eye were mildly xerotic. The conjunctiva of the left appeared mildly injected but not xerotic. The left cornea was yellow, soft, necrotic, and bulging, with a gelatin-like central protrusion of vitreous or lens. The peripheral corneal/limbal ring was normal. A small biopsy was taken of the centrally necrotic and perforated cornea. 100,000 IU water miscible vitamin A was given intramuscularly, and preparations made for enucleation of the left eye the following day. In the interim the

Fig. 5-2A. Corneal biopsy from right eye of case 200/037. The main area of corneal necrosis (superior-central) is surrounded, in part, by heavy inflammatory cell infiltration. The central area of necrosis however is relatively free of inflammatory cells (hematoxylin-eosin, × 26). (From Sommer et al. [520])

Fig. 5-2B. Higher power view of an area in Fig. 5-2A containing gram negative bacilli (Brown and Hopps, × 1500). (From Sommer et al. [520])



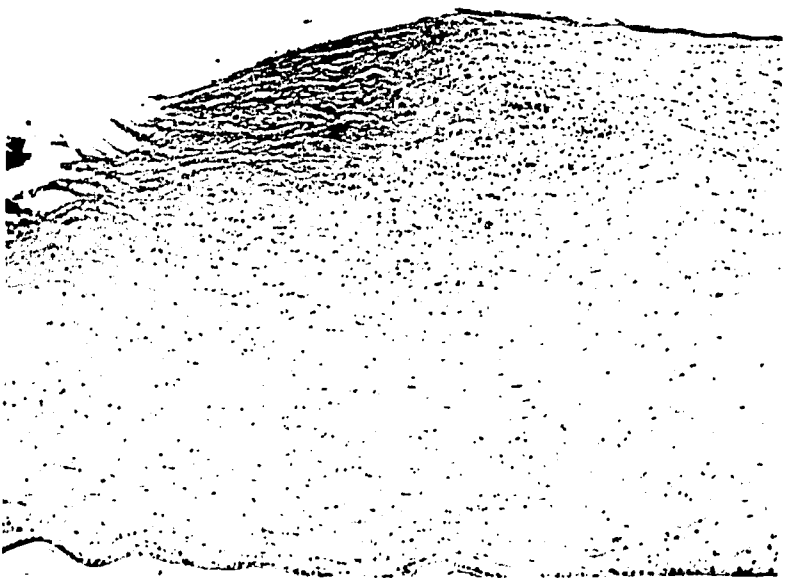

Fig. 5-2C. Biopsy from left eye of case 200/037. Margin of ulcer showing frayed collagen surrounded by polymorphonuclear leukocytic infiltration (hematoxylin-eosin, × 88). (From Sommer et al. [520])

Fig. 5-2D. Higher power view of superficial margin of ulcer (Fig. 5-2C) showing branching filamentous organisms (Brown and Hopps, × 970). (From Sommer et al. [520])

left eye developed a purulent exudate. The biopsy specimen resembled a fibrinous exudate containing a segment of Descemet's membrane and, in some areas, moderate number of diplococci (Fig. 5-3A). Examination of the enucleation specimen revealed an abrupt transition between peripheral cornea, which was relatively intact except for fraying of collagen bundles and areas of acute inflammatory cell infiltrate and vascularization, and the central fibrinopurulent full-thickness exudate (Fig. 5-3B). The margins of preserved stroma showed a dense neutrophilic infiltrate (Fig. 5-3C). Keratocytes, present in the periphery, looked large and active with nucleoli; none were seen in the necrotic zone. Epithelium covering the limbal cornea showed minimal keratinization (increased number of flattened surface layers, edema, and exocytosis), and below, areas of vascularization and infiltration by acute and chronic inflammatory cells. Large gram-positive cocci were noted in the vitreous abscess (Fig. 5-3D).

Clinical-histopathologic schema of corneal change

Surface changes clearly predominate early in the disease (X2). Minimal punctate keratopathy and inferior haze can occur in the absence of obvious histopathologic alterations on light microscopy, though a presumably similar clinical appearance, in the rabbit, corresponds to focal areas of squamous metaplasia [190]. In many instances punctate erosions are preceded by, and probably arise from, nonstaining intraepithelial microcysts. These changes are earlier than those generally described. Even "prexerosis" [146,189] was more consistent with changes observed in category 2 xerosis. Pillat [156] did describe a case in which slit-lamp examination revealed "a remarkable number of vacuoles in the epithelial layer," but whether this referred to Bitot's spot-like material, attached to or floating on the corneal surface, intraepithelial microcysts, or the peau d'orange effect is unclear.

The haziness spreads and patches of cornified epithelium begin to cover the surface, initially inferiorly, but eventually the entire cornea. In particularly ill, malnourished children amorphous, localized plaques may cover the cornified surface, especially in the interpalpebral zone. Their strong resemblance to Bitot's spots suggests aggregation of desquamated keratin and bacteria. Histopathologic observations at this stage of disease, in both man and animals, indicate frank keratinization of the corneal surface [12, 27,155,164,165,201].

The mildest stromal change is generalized edema, which also begins inferiorly. Whether this is secondary to changes in the epithelium or endothelium, or a primary effect of vitamin A deficiency on the stroma itself, is unclear. In general the severity of edema parallels the severity of surface changes. But it also parallels the severity of vitamin A deficiency quite

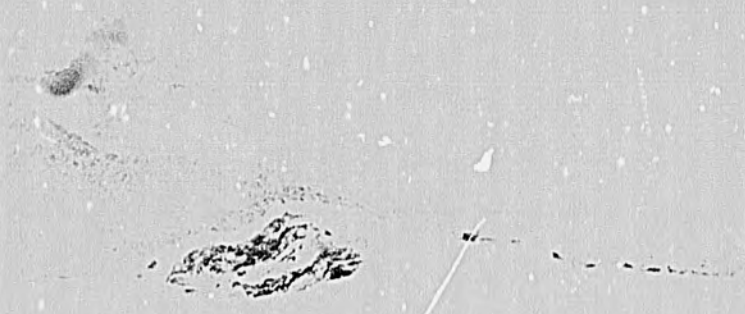

Fig. 5-3A. Biopsy specimen of case 200/006 showing a fibrino-purulent exudate (Brown and Hopps, × 45). (From Sommer et al. [520])

Fig. 5-3B. Enucleation specimen showing preservation of only peripheral cornea. Iris is prolapsed centrally. Retina, choroid, and ciliary body are detached. An abscess is present in the collapsed vitreous (hematoxylin-eosin, × 41). (From Sommer et al. [520])

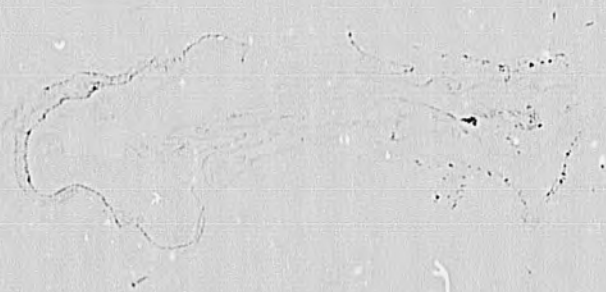



Fig. 5-3C. Peripheral area showing intact stroma covered by epithelium. A fibrinopurulent exudate replaces central cornea and is lined posteriorly by iris (hematoxylin-eosin, × 86). (From Sommer et al. [520])

Fig. 5-3D. Gram-positive cocci are present in the vitreous abscess (Brown and Hopps, × 946). (From Sommer et al. [520])



independently of surface changes, as evidenced by the fact that edema was more prominent in nonulcerated xerotic "other" eyes of cases in category 6 (focal necrosis) than in category 4 (punched-out ulcers). There is no convincing histopathologic evidence of endothelial alterations early in the course of corneal xerophthalmia, although vacuolated endothelial cells have been observed in the vitamin-A-deficient rabbit [202].

Stromal loss appears to occur through a multiplicity of mechanisms, some primarily anterior (categories 4–5), others posterior or at least simultaneously full thickness in nature (categories 6–8).

Traumatic baring, if not loss of anterior stroma, probably initiates the process in some heavily xerotic corneas. As pieces of the cornified layer are sloughed they may take a full-thickness plug of epithelium (with or without deeper tissue) with them. In one case the ulcer was located adjacent to a large plaque, exactly at the point where a large, inferior segment had recently broken off and sloughed. These ulcers might also represent a breakdown of dellen caused by their proximity to a steep-margined plaque [199, 200].

The other mechanism of anterior stromal baring or loss does not require a heavily keratinized surface, and, in fact, commonly occurs in its absence. Deep epithelial or superficial stromal bullae, observed in our cases as well as the vitamin A deficient rabbit [202] may rupture. The mechanism of cyst formation is unclear. In several of our cases it appeared to result from dellen formation in a central, depressed, nonstaining area of apparently superficial stromal desiccation. In at least one animal model drying is most intense centrally, occasionally resulting in epithelial loss followed by stromal dissolution [200].

Posterior and rapid full-thickness stromal necrosis, in some instances apparently deep to an intact epithelial layer, is not easily explained by currently accepted mechanisms of stromal dissolution. It is appealing to think [203–204] that collagenases and other proteases known to be released by regeneration epithelium [205–208], infiltrating leukocytes [209–211] and even keratocytes [212–213], and present in the stroma of ulcerating eyes [214], may be responsible for corneal melting in xerophthalmia. Apparently epithelial changes may even control polymorphonuclear cell infiltration [210]. Whether this accounts for the cylindrical shape of anterior–posterior ulcers and sharply demarcated appearance of (localized) full-thickness necrosis remains to be seen. But it fails to explain deep stromal necrosis beneath intact epithelium, as suggested by several of our cases, those re-

ported previously [32,155,156] and occasionally seen in the vitamin A deficient rat [201].

Especially disturbing is the paucity of inflammatory cells in the recently melted cornea. Corneal "infiltration" has been described as an early, prominent component of the xerophthalmic process, before epithelial integrity is lost [17,32,160]. But it is unclear whether these observations refer to inflammatory cell infiltration, which in our experience and those of others [18,20,68,71,114,136,156] rarely occurs until late in the course of human disease, or merely stromal edema. Although inflammatory cell infiltration is prominent, histopathologically, in corneas of vitamin A deficient animals [27,164,165,201,215], it has not been convincingly demonstrated in preulcerated or newly ulcerated xerophthalmic human corneas. Most importantly, several cases, especially those in which histopathologic material was obtained soon after necrosis commenced, contained large areas devoid of keratocytes and suffering collagen fragmentation and dissolution in the absence of significant numbers of inflammatory cells. Smith also commented on the paucity of inflammatory cells in his relatively fresh case of keratomalacia [157]. This suggests the possibility that sufficiently impaired vitamin A metabolism results in devitalization of corneal stroma, with secondary infiltration by inflammatory cells. The cornea of the vitamin A deficient rat is more susceptible to melting following trauma than is that of pair-fed controls [216]. Specific vitamin A receptors have been found in corneal epithelium, stroma, and endothelium [217] among other tissues, while vitamin A appears to be required for normal glycoprotein biosynthesis in the rat cornea [218]. The manner in which protein deficiency may contribute to these changes, and the role of local infection, will be dealt with later. The beneficial effects of ascorbate therapy in the burned rabbit cornea [219,220] suggest an additional mechanism that may bear on the problem, though corneal melting is not observed in classical scurvy nor were our cases clinically scorbutic.

Punched-out ulcers (X3A category 4) can proceed to typical necrosis. Whether this is the common course of events, or merely incidental, is unknown. The fact that all xerophthalmic alterations can be seen in the same case, and occasionally the same eye, suggests that if one does not contribute to the other, they at least represent staging posts along the course of a common disease.

Corneal dissolution is sharply focal, both clinically and histopathologically, but often, especially in focal necrotic cases (X3B, category 6), the

area of ultimate stromal loss may be considerably smaller than initial clinical observation suggests. Perhaps the area of (seemingly) normal collagen devoid of keratocytes that surrounds a focus of infiltration and frank dissolution represents viable and reversible corneal damage. Alternatively, we may simply be witnessing resolution of particularly optically disruptive edema, or in some instances, inflammatory infiltration.

6. Corneal involvement

III. Etiologic significance of local and systemic factors

Local factors

Tear film

Over 150 years ago Mackenzie [4] recognized two types of "xerophthalmia" (a term he did not apply to the equally well recognized nutrition-related disease under discussion), one "lacrimal," due to decreased tearing, the other "conjunctival," due to a decrease in "mucus which in the natural state lubricates the eye."

Mori [221] believed that xerosis was due to disturbed secretion of the lacrimal gland. Wolbach [164] demonstrated that the primary change, at least in rats, was a keratinizing metaplasia, and that the lacrimal glands were not affected until late in the disease. Since then, lacrimation has rarely been mentioned, except to indicate that xerotic eyes may look dry despite copious tears. Tear production is said to remain unchanged in xerophthalmic rabbits [202].

Despite these negative reports, difficulties in assessing basal tear secretion in young children, and limitations of the Schirmer test (see methods, Appendix I) [222,223], our studies indicate that xerophthalmia is clearly associated with decreased tearing [521]. Limited tear production was far more frequent in eyes of patients with active corneal disease than in those of their matched controls (Fig. 6-1) ($p < .001$ overall; $p < .01$ to $< .001$ for group-specific comparisons of abnormals and their controls in categories 1–3, 4–5, and 6–8, not shown in figure) (categories defined on page 58). Fall in tear production appears to occur early in the course of the disease: decreased tearing was less frequent among the group of matched controls of corneal cases than among patients with vitamin-A-responsive conjunctival xerosis (Study III), and less frequent among those with conjunctival xerosis than among patients with even the mildest (category 1) degree of corneal xerosis (Table 6-1) ($p < .001$ by linear trend).

The Schirmer test was affected by protein status. In an analysis limited to cases of X2, to reduce the influence of ulceration on tear production, the prevalence of decreased tearing was inversely related to transferrin level (Table 6-2; $p < .01$). Eyes in almost half the cases with transferrin

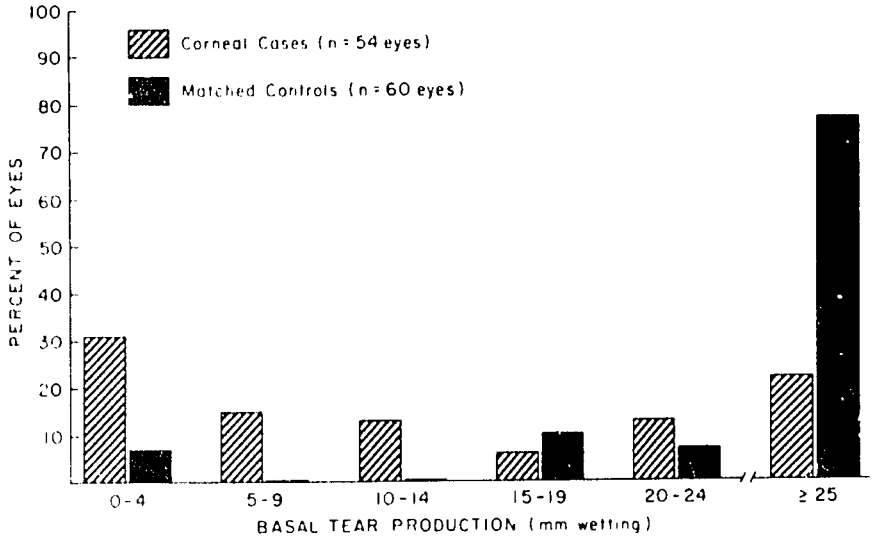

Fig. 6-1. Schirmer test results (with topical anesthesia) indicate subnormal tearing was more prevalent among cases of corneal xerophthalmia (X2 X3) than among their matched controls ($p < .001$). Results were unavailable on 12 eyes of abnormals and 6 eyes of controls. Study H. Drawn from Sommer et al. [521]

levels less than 50 mg/dl had less than 5 mm of tearing. This may, in part, represent functional dehydration, since many of these children appeared "dry" despite pedal edema. In one case diarrhea led to dehydration, pedal edema, a fall in tearing and deterioration of corneal status.

Tear production is also affected by vitamin A status, quite apart from the influence of protein status. In otherwise normally nourished children, the more severe the xerophthalmia, hence the vitamin A deficiency, the higher the prevalence of deficient tearing (Table 6-3) ($p < .01$ by linear trend).

Response to isolated vitamin A therapy provides further evidence of the effect of vitamin A status on basal tear secretion (Table 6-4). To minimize the potential influence of other treatments, and the transient nature of improvement in severely malnourished children, analysis is limited to outpatients (who received only vitamin A therapy) and response was determined at seven to ten days. The proportion of eyes developing increased and decreased tearing was determined only for those capable of demonstrating such a change: cases in which the initial levels were less than 15 mm and more than 5 mm of wetting respectively. Only a change of at least one category [(< 5 to > 15 or > 15; < 15 to > 15 or > 5)] was considered signif-

Table 6–1. Tear production in controls and cases of conjunctival and early corneal xerophthalmia (Studies II-III)[1]

Clinical classification	Eyes examined (n)	Eyes with > 15 mm wetting (n)	(Percent)
Controls	60	4	6.7
Conjunctival xerosis (X1)	72	16	22.2
Corneal xerosis (category 1)	46	18	39.1

1. Controls: matched controls of corneal cases, Study II
Conjunctival xerophthalmia: vitamin A responsive cases, Study III.
Early corneal xerophthalmia: corneal xerosis, category 1, Study II.

Test for linear trend, $p < .001$
Test MC:X1, and X1:X2 (category 1) $p < .05$

From Sommer et al. [521].

Table 6–2. Tear production and transferrin levels in cases of corneal xerosis (categories 1–3, Study II)

Wetting, mm	Transferrin (mg/dl) (percent of eyes in column) < 50	50–100	>100
0–4	44.4	16.7	22.0
5–9	27.8	16.7	10.0
10–14	5.6	33.3	4.0
15–19	11.1	–	12.0
20–24	–	–	8.0
≥25	11.1	33.3	44.0
Total (n)[1]	18	12	50

1. Schirmer data unavailable for 13, and transferrin levels for 12 additional eyes
chi-square = 23.6, df = 10, $p < .01$

From Sommer et al. [521]

icant. The proportion of eyes in which tearing increased was significantly greater than the proportion in which it decreased ($p < .001$ for corneal cases, $p < .01$ for all xerophthalmia). Net increase (p increase − p decrease) was statistically significantly greater than zero ($p < .001$).

The concomitant presence of dehydration, vitamin A deficiency, and protein deficiency should have a marked effect on tear production, and probably explains the severity of corneal xerosis among cases in category 3.

More attention has been paid in the past to the loss of mucus-producing goblet cells, which in humans virtually disappear from the bulbar conjunc-

Table 6–3. Basal tear production in otherwise well-nourished[1] controls and cases of xerophthalmia (Studies II–III)

Clinical classification	Eyes examined (*n*)	Eyes with < 15 mm wetting (*n*)	(Percent)
Controls[2]	86	8	9.3
Conjunctival xerosis (X1)	38	9	23.7
Corneal xerophthalmia (X2–X3)	62	17	27.4

1. All had serum albumin > 3.5 g/dL and weight for height > 80% of standard.
2. Includes multiple controls for the same abnormal corneal case (unpaired).

Test for linear trend, $p < .01$

From Sommer et al. [521]

Table 6–4. Change in basal tear production following isolated vitamin A therapy for xerophthalmia[1] (Studies II–III)

	Initial tear production net change[2]						
	< 5 mm			< 15 mm		≥ 15 mm	
	0	+		0	+		0
X2–X3 eyes (*n*)	0	3	1	2	5	2	21
X1–X2–X3 eyes (*n*)	4	3	1	5	8	8	46

1. Limited to cases receiving isolated massive dose oral or water-miscible intramuscular vitamin A.
2. Increase (+) or decrease (–) 7–10 days after presentation requires change of at least one category (e.g. < 5 to < 15 or ≥ 15). Analysis limited to those cases with potential for such change: "increase" based on cases with initial level < 5 and < 15; "decrease" on cases with initial level < 5.

p increase vs *p* decrease:
Corneal (X2–X3): 73% (8/11) vs 10% (3/31), $p < .001$
Total (X1–X3): 52% (11/21) vs 13% (9/68), $p < .01$

tiva by the time clinically detectable conjunctival xerosis first appears ([101]; see Chap. 3). Mucus stabilizes the tear film (224) by interfacing between its aqueous component and the hydrophobic surface of the cornea [225,226]. It therefore seems reasonable to suspect [47,203] that its loss results in rapid tear film breakup and epithelial "exposure," with consequent drying and damage to the corneal epithelium, much like primary mucus-deficient states [227].

Despite these findings, most evidence suggests that alterations in the quantity and quality of the tear film contribute little to the xerotic process; instead they occur pari passu with other changes. Keratinizing metaplasia of

the corneal epithelium is almost certainly the direct consequence of altered vitamin A metabolism, just as it is in the epithelium of the bladder and renal pelvis [40,164], despite their constant bathing by an aqueous medium. Corneal keratinization, in the rat at least, precedes alterations in the lacrimal gland, and in both the rat [164,228] and guinea pig [229] occurs in the presence of abundant conjunctival goblet cells. Since goblet cells have already disappeared in mild conjunctival xerosis, it is difficult to imagine how their absence could account for more severe disease, and corneal healing (see Tables 13-5 through 13-8), of all degrees of severity, begins within one to three days, and is often completed within four to seven, long before goblet cells return in any numbers [101,104,117]. Except for early punctate epithelial erosions [198], ocular changes in keratoconjunctivitis sicca and other dry eye states [198, 230–234] generally do not resemble those in our patients, even though dry eyes may be deficient in both tears and goblet cells [235,236]. Although it is possible that alterations in the amount of mucus produced by the lacrimal gland [237,238] could account for some of this, histopathologic changes in rats whose lacrimal glands are surgically removed are far milder than in those made vitamin A deficient [239]. Occasionally patients with Sjögren's syndrome associated with rheumatoid arthritis develop steep-margined, noninfiltrated ulcers similar to those of category 4 patients [210].

Composition of skin surface lipids is altered in protein-energy malnutrition [241]. It is conceivable that comparable changes in the lipid phase of the tear film could contribute to the xerophthalmic process. This, however, has received little attention.

Even if changes in tear film dynamics are not responsible for initiating keratinizing metaplasia, they may contribute to the predilection of mild corneal abnormalities (punctate keratopathy and early haze) for the inferior and nasal quadrants, the exaggerated accumulation of keratin debris in severe corneal xerosis (category 3), and dellen formation, epithelial degeneration, and the like, especially in functionally dehydrated individuals.

Although the vast majority of cases appeared to have complete lid closure and normal Bell's phenomenon, exposure may exaggerate the effects of tear film instability. Patients with keratitis sicca who are presumed to have incomplete lid closure during sleep [242] develop punctate keratitis and intraepithelial microcysts in the inferior cornea. Some even develop sterile ulcers, most commonly inferonasally, though not of the circular, punched-out variety typical of xerophthalmia.

Accumulation of heavy plaques (category 3) in the interpalpebral zone

may be influenced by the relative exposure and lack of lid action at this site.

Bacteria and fungi

The keratinized surface of xerophthalmic eyes presents a good culture medium for a host of bacteria, particularly the xerosis bacillus, but also *Staphylococcus*, *Pneumococcus*, *Hemophilus* and others, which are commonly encountered in large numbers [12,156,165,189]. There is rather less evidence to support suggestions that infection, as opposed to colonization, is more common or responsible for stromal ulceration and necrosis [43,136,145,215,243]. The large numbers of bacteria Pillat discovered in smears from corneal cases disappeared following vitamin A therapy [156].

In advanced experimental xerophthalmia of rats, necrotic corneas frequently contain large numbers of bacteria [27,165,215]. But these could be secondary infections and need not reflect the situation in humans. Ocular and periocular inflammation, conspicuous in xerophthalmic rats, is often minimal or absent in the human condition (Chap. 3) [32,39,68,136].

Clinical reports generally describe isolated instances of positive cultures from ulcerated eyes [145,147]. But a culture does not distinguish primary from secondary infection, or either from mere colonization. Only a tiny proportion of eyes harboring *Pseudomonas* [244] or *Staph. aureus* [245] are ulcerated. To be of pathogenetic significance, positive cultures should be more prevalent in ulcerated than in nonulcerated eyes. Valenton et al. [243] found that the frequency of recovery of pathogenic organisms (*Pseudomonas*, *Pneumococci*, *Moraxella*, *Staph. pyogenes*, *Klebsiella*, *E. coli*, or *Proteus*) increased with the severity of clinical xerophthalmia. But in another study [136] that claimed to demonstrate the importance of infection, positive cultures in malnourished children were no more prevalent in those with ulcerated corneas than in those without; even the spectrum of organisms was the same.

Our own series included controls as well as eyes with xerophthalmia of varying severity. Conjunctival/corneal swabs (and scrapings in ulcerated necrotic corneas) grew a wide variety of organisms. The most common and potentially pathogenic were *Pseudomonas*, *Staph. aureus*, and *E. coli*. Positive cultures were more prevalent among eyes of cases with active xerophthalmia than among controls, though not to a statistically significant degree (Table 6-5). The prevalence of positive cultures among ulcerated and nonulcerated eyes of xerophthalmic patients was similar, even

Table 6-5. Positive bacterial cultures in controls and cases of corneal xerophthalmia (Study II)

Corneal status	Total eyes (n)	Percent of eyes with positive cultures			
		Pseudom.	Micro. aur. coag. +	*E. coli*	Total positive
Controls	50	24	24	4	46
X2 (1–3)	117	25	30	9	53
X3A (4–5)	65	31	28	14	60
X3B (6)	44	36	23	11	57
X3B (7–8)	35	31	34	11	54
X2/MC		1.04	1.25	2.25	1.15
X3A/X2		1.24	0.93	1.56	1.13
X3B (6)/X2		1.44	0.77	1.22	1.08
X3B (7–8)/X2		1.24	1.13	1.22	1.02

by pairwise comparison (not shown) of ulcerated and nonulcerated eyes in the same patient ($n = 33$). Other organisms, which included strains of *Hemophilus*, *Strep. viridans*, diphtheroids, and *Aerobacter*, were common in all groups. *Proteus* was cultured from a single eye (with corneal xerosis).

Various fungi, which may have been contaminants, were recovered from 17 eyes (*Penicillium* (12), *Aspergillus* (3), and *Candida* (2)). There was no consistent difference in the frequency of positive isolates among the various forms of corneal ulcer-necrosis. Positive isolates were more frequent from ulcerated necrotic corneas (9%) than from purely xerotic ones (3.4%), but the difference missed statistical significance ($p = .07$).

Once convinced that these lesions neither looked nor acted like bacterial ulcers, we instituted a formal diagnostic/therapeutic trial: one eye of each patient was systematically assigned to receive frequent topical antibiotic ointment (at a minimum, gentamycin plus bacitracin five times a day). Twenty-seven consecutive hospitalized patients with corneal ulceration were studied before a single nonrecipient eye was found to fare worse than its matched recipient.

Case 200,080, a severely malnourished child presented with identical small, inferior ulcers in each eye. By day 3 the cornea receiving antibiotic was clearly better while the ulcer in the nonrecipient eye was worse. The only organism recovered from the nonrecipient eye at this point was a coagulase-negative *Staph. albus*.

Despite the fact that similar, initial deterioration was occasionally observed in eyes receiving antibiotic, the trial was discontinued at this point

and all subsequent cases of ulceration were treated with both topical and systemic antibiotics.

Unfortunately, the formal trial was not conclusive: most cases required and received systemic antibiotic therapy for nonocular conditions (tuberculosis, respiratory tract infection, gastroenteritis, etc.). By including patients outside the formal trial (because they refused hospitalization), observations were available on 22 ulcerated (category 4) or locally necrotic (category 6) corneas unexposed to either topical or systemic antibiotics. All but two (9%) healed rapidly and uneventfully on systemic vitamin A therapy only. One of the two exceptions (case 200.080) was already discussed; the other contained an ulcer (category 4) that had enlarged by the next visit, at day 4, but began to resolve spontaneously by day 6.

Observations of the noninfected appearance of most ulcers, the frequent absence of bacteria and fungi from areas of stromal dissolution studied histopathologically, and the rapid healing induced by vitamin A [156,246] and retinoic acid (247 – see Chap. 13), combined with the previous observations, suggest that local bacterial and fungal infections rarely initiate and only occasionally contribute to xerophthalmic ulceration or melting. However, there is no reason why ulcerated or perforating lesions should not become secondarily infected [155,248] and even lead, on occasion, to panophthalmitis. But even *Pseudomonas* – which releases proteases [249] and exotoxin [250], attracts collagenase and proteolytic enzyme-producing leukocytes [251], and can cause rapid corneal melting – has a different clinical appearance: whereas keratomalacia (categories 7–8) invariably spares peripheral cornea, *Pseudomonas* recognizes no such limits [252]. Even when *Pseudomonas* or other pathogenic organisms are more frequently encountered in severly xerophthalmic eyes of malnourished children [243] this may merely represent a potentially transient change in flora, such as that observed among burn patients [244].

Systemic factors

In general, the more severe the xerophthalmia the poorer the vitamin A [42,136,151,253,254], protein [42,131,151], and anthropometric [32,71,255] status, and the younger [32,39,256,257] and sicker [32,258] the patient. But few studies have distinguished among varying forms of corneal involvement [35,136].

Study II allows us to examine the relationship of each of these parameters to corneal involvement, and establish their significance for ulceration and necrosis [259].

Vitamin A and protein status

Vitamin A status. A number of obstacles preclude precise estimation of circulating levels of vitamin A and holo-RBP associated with the corneal changes observed in each case.

1. Because of equipment failure initial vitamin A and/or holo-RBP determinations are not available on all patients. Fortunately, different items of equipment fail at different times, so that initial values on almost all cases are included in one or the other analysis.
2. Some patients received vitamin A before presenting to the study. In most instances this was an oil-miscible injectable preparation having little effect on serum levels, but two cases with the highest levels in group 7 (42 μg/dl and 13 μg/dl), and one in group 2 showing the highest level in the entire series (21 μg/dl), were among them. These are included in the tables. Two cases, both in group 8, were known to have received oral vitamin A therapy (which has a marked effect on serum levels) just prior to presenting to the study, and are therefore excluded from the analysis.
3. There is always the possibility of laboratory error, even when equipment failure is not recognized, or of the patient having received therapy unbeknown to the investigators. One or the other of these factors was suspected in two cases; one case, in category 6, had a serum vitamin A level 5 SD removed from the mean but still below 20 μg/dl (17 μg/dl), and is retained in the analyses, the other, in category 7, had a serum vitamin A level grossly out of range (32 μg/dl). It was 6 SD from the mean and higher than any value observed among cases of Bitot's spots or normal matched controls. Both eyes were injected. The right cornea contained a classical (category 4) saucer-shaped ulcer without infiltrated or swollen margins, while the left cornea was completely necrotic except (classically) for a 1 mm peripheral zone. This single case was excluded from the analysis.

With the exceptions listed above, serum vitamin A levels were depressed in all cases of corneal involvement (Table 6-6). In fully 75% it was below 10 μg/dl, and in 95%, below 15 μg/dl. Only the case that had recently received an oil-miscible injection of vitamin A was above 20 (at a borderline 21 μg/dl). By contrast, only one-third of cases with Bitot's spots and fewer than 10% of randomly sampled children in Study I had levels below 10 μg/dl (refer to Table 2-2). It appears that (in our laboratory) frank corneal involvement is uncommon at serum levels above 15 μg/dl.

Mean serum vitamin A levels were severely depressed in all forms of corneal involvement and the more severe the involvement the more severe the depression ($r = 0.9637$, $p < .01$). The only statistically significant "break" or difference in serum vitamin A levels among subjects with adjacent categories of clinical severity was between those with ulcers (group 4) and those with localized necrosis (group 6) ($p < .01$).

Table 6-6. Serum vitamin A levels in corneal xerophthalmia

Category	Cases (n)	Percent distribution by serum vitamin A levels (μg/dl) < 10	10–14	15–19	≥20	$\bar{\mu}$[a]	SE
1–3	26	61.5	26.9	7.7	3.8[1]	8.2	0.94
4–5	32	68.8	28.1	3.1	0.0	7.2	0.70
6	25	92.0	4.0	4.0	0.0	5.4	0.72
7–8	15	80.0	20.0	0.0	0.0	5.2	1.01
Total	98	74.5	20.4	4.1	1.0		

1 Represents a single borderline case (serum vitamin A of 21 μg/dl).
[a] $r = 0.964$, $p < .01$

From Sommer et al. [259]

Thus, every subject with frank corneal involvement had a low serum vitamin A level; the degree of depression was correlated with the severity of corneal involvement; and a statistically significant difference distinguished the transition from ulcers (category 4) to localized necrosis (category 6). Differences in serum vitamin A level do not so clearly explain the transition from corneal xerosis (categories 1–3) to ulcers (category 4), or from localized (category 6) to generalized necrosis (categories 7–8). Kuming et al. [136] also found the greatest change in serum vitamin A between cases with "mild-moderate" ulcers and those with "severe ulcers/keratomalacia." While Oomen [35] reported no significant difference in vitamin A levels between patients with corneal xerosis/ulceration and those with keratomalacia, differences in definition, laboratory technique, and protein status probably account for at least part of the discrepancy.

Holo-RBP levels (Table 6-7, see Fig. 13-1 and 13-2) confirm the severe depression of circulating retinol in patients with active corneal disease. In contrast with serum vitamin A, however, there was no correlation between serum holo-RBP levels and the severity of corneal involvement. This may represent limited precision of the holo-RBP assay technique. On the other hand, some form of vitamin A, unlinked to RBP may be physiologically active, accounting for the variation in corneal severity and its correlation with total serum vitamin A.

Protein status. Serum albumin and transferrin are useful indices of basic protein status. Serum transferrin responds more rapidly than albumin, which has a half-life of 14 days [260] to alterations in diet [261–263]. Both are more stable than prealbumin [261,264]. With a half-life of two to three

Table 6–7. Serum holo-RBP in corneal xerophthalmia (Study II)

File	Cases (n)	Holo-RBP (μg/ml) $\bar{\mu}$	SE
1–3	38	1.13	0.22
4–5	28	1.00	0.23
6	15	1.33	0.31
7–8	14	1.07	0.22

From Sommer et al. [259].

days, prealbumin [265,266] is very sensitive to acute, moderate alterations of protein intake, even in well nourished individuals [261]. Retinol-binding protein, with a half-life of only one-half day [265,267,268] and dependence on retinol stores is an even less appropriate index of basic protein status than prealbumin, especially in vitamin A deficient populations.

Serum albumin and transferrin levels spanned a wide range (Tables 6–8, 6–9). Unlike serum vitamin A levels, they were relatively normal in a substantial proportion of cases, including some with severe disease (categories 7–8).

Case 200/103, excluded from the formal series because scarring and vascularization of the left, totally destroyed cornea was already advanced, provided additional evidence that severe xerophthalmia is compatible with normal protein status. One month previously, the child developed fever and closed his eyes. At presentation, the right cornea had typical punctate keratopathy but was clear to handlight examination. Conjunctival xerosis was present temporarily and nasally on. Serum vitamin A was 4 μg/dl and holo-RBP 0 μg/ml. Serum transferrin was 183 mg/ml and albumin consistently >3.8 g/dl over 2 weeks of observation.

Table 6–8. Serum albumin levels in corneal xerophthalmia (Study II)

Category	Cases (n)	Percent distribution serum albumin (g/dl) >3.5	3.4–3.0	2.9–2.5	2.4–2.0	< 2.0	$\bar{\mu}$	SE
1–3	53	35.8	34.0	24.5	3.8	1.9	3.20	.07
4–5	48	29.2	35.4	25.0	6.3	4.2	3.12	.08
6	33	27.3	27.3	36.4	6.0	3.0	3.07	.09
7–8	25	20.0	4.0	28.0	44.0	4.0	2.65	.15
Total	159	29.6	28.3	27.7	11.3	3.1		

Mean levels (μ) categories 1–6 vs. 7–8, $p < .01$.

From Sommer et al. [259].

Table 6-9. Serum transferrin levels in corneal xerophthalmia (Study II)

		Percent distribution transferrin (mg/dl)						
Category	Cases (n)	≥200	199–150	149–100	99–50	<50	$\bar{\mu}$	SE
1–3	47	36.2	12.8	17.0	12.8	21.3	151.3	13.4
4–5	45	17.8	17.8	31.1	13.3	20.0	128.6	12.0
6	30	26.7	13.3	20.0	16.7	23.3	135.9	18.3
7–8	22	9.1	4.5	9.1	27.3	50.0	75.4	15.1
Total	144	24.3	13.2	20.8	16.0	25.7		

Mean levels (μ) categories 1–6/7–8, $p < .01$

From Sommer et al. [259]

Mean albumin levels were inversely related to the severity of corneal disease (Table 6-8). Although the trend is not statistically significant, the transition between local and total corneal necrosis is (categories 6:7 and 6:7–8 both $p < .01$). This is consistent with results reported by Oomen [35]. Mean transferrin levels among patients with localized necrosis (category 6) were also significantly different from levels among those with more severe disease (7–8) (Table 6-9) ($p < .01$).

Vitamin A–protein interaction. Examined in isolation, differences in circulating levels of vitamin A largely explain the transition from corneal ulcers (category 4) to localized necrosis (category 6); and differences in protein status the transition from local (category 6) to total (categories 7–8) necrosis. However, while local factors, such as those already discussed (e.g. quality of tear film, abrasion, infection), may largely account for the transition from corneal xerosis (categories 1–3) to ulcers (categories 4–5), these analyses ignore potentially important interactions between vitamin A and protein, discussed in Chapter 7.

Age

Patients ranged in age from 1 month to 12 years, the vast majority (82%) being in the second through fifth years of life with the median during the third (Table 6-10). The one-month-old presented with severe bilateral xerosis and complete dissolution of one cornea. His mother claimed he was born with Bitot's spots. Although his mother was free of clinical disease, her serum vitamin A was only 13 μg/dl. The oldest patient encountered

Table 6-10. Age distribution of corneal cases (X2/X3) (Study II)

File	Cases (n)	Age in years (percent of total in row) 0	1	2	3	4	5	≥6
1	24	0	8	21	33	21	8	8
2	24	0	13	42	17	17	8	4
3	5	0	0	60	20	20	0	0
4	45	4	11	42	16	13	9	4
5	5	0	0	60	40	0	0	0
6	34	15	24	29	15	15	3	0
7	13	23	31	23	8	15	0	0
8	12	17	25	8	17	8	8	17
Total	162	7	15	33	19	15	6	4

From Sommer et al. [196].

was a 24-year-old woman with group-2 level corneal xerosis in each eye examined prior to initiation of the formal study [104].

The proportion of very young children was directly related to the severity of corneal involvement (Fig. 6-2), ($p < .001$ for linear trend). Although ulceration and necrosis were encountered in preschoolers of every age, not a single case of pure corneal xerosis (or active conjunctival xerosis) presented during the first year of life. As this was a clinic rather than a representative population, some of the difference may be one of referral: mothers of neonates may be more likely to overlook milder forms of disease. The number of cases of active corneal disease encountered in Study IV is too small to answer this question under unbiased field conditions. But only 1 of the 358 cases of Bitot's spots encountered among preschoolers in the countrywide survey was below 1 year. Liver stores among very young children may be particularly inelastic, hence when vitamin A deficiency and xerophthalmia occur, they rapidly assume a severe form.

Clinical, nutritional, and anthropometric status

Weight for height (expressed as percentage of "normal" standard) is a convenient measure of adequacy of body mass (or inadequacy, designated "wasting"). It is a better index of current status than weight for age, which may be affected by past episodes of growth retardation ("stunting").

Although normal weight for height is compatible with all forms of corneal xerophthalmia (Table 6-11), the more severe the involvement, the more prevalent moderate to severe wasting (<80% of standard, $P < .02$ for linear

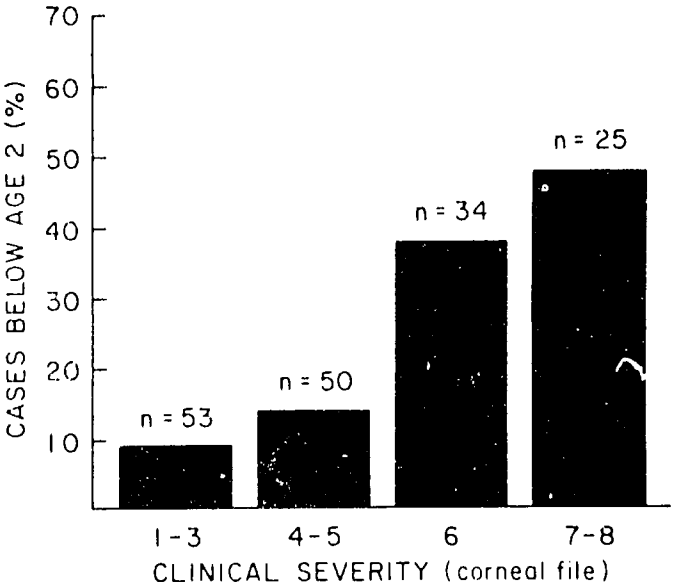

Fig. 6-2. The proportion of cases below age 2 increased directly with the severity of corneal involvement ($p < .001$ for linear trend). Study II. (Drawn from Sommer et al. [197])

Table 6–11. Weight for height of xerophthalmia cases (Studies II/III)

Clinical severity[1]	Cases n	≥90	Percent of standard[2] 80–89	70–79	60–69	<60
Conjunctival	50	62.0	30.0	4.0	2.0	2.0
Corneal (category)						
1–3	53	32.1	30.2	30.2	3.8	3.8
4–5	49	20.4	38.8	32.7	8.2	0.0
6	32	12.5	34.4	50.0	0.0	3.1
7–8	25	8.0	28.0	24.0	24.0	16.0
Total	159	20.8	33.3	34.0	7.5	4.4

1 Conjunctival vitamin A responsive conjunctival xerosis (Study III).
2 Adapted from Jelliffe [174].

Difference in distribution X1 vs X2 X3, $p < .001$, and X1 vs X2, $p < .01$. Degree of wasting correlated with severity of corneal involvement, $p < .02$ by linear trend.

From Sommer et al. [259].

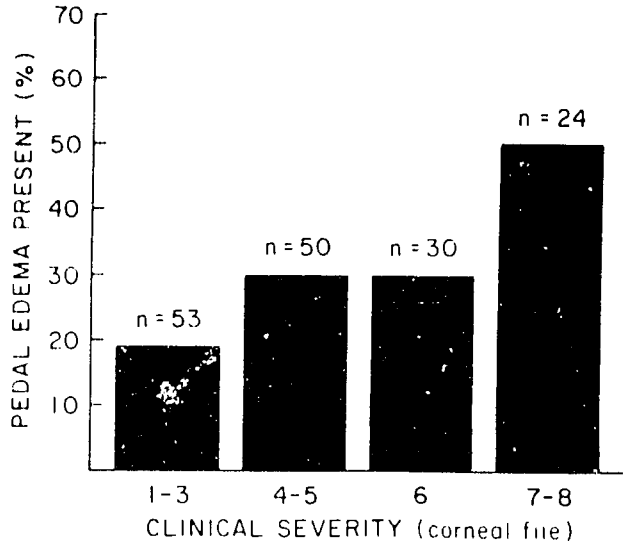

Fig. 6-3. The proportion of cases with pedal edema increased with the severity of corneal involvement (categories 1–6; 7–8, $p < .05$). Study II. (Drawn from Sommer et al. [197])

trend). The largest transitional differences occurred between ulcers (categories 4–5) and local necrosis (category 6), and between local (category 6) and total (categories 7–8) necrosis, though only the latter was statistically significant ($p < .01$).

Pitting edema was present in 30% of corneal cases (Fig. 6-3). As expected, its prevalence generally mirrored the pattern of albumin and transferrin levels. Although the prevalence of pitting edema in categories 7–8 was not statistically significantly different from that in 6, it did differ from that in categories 1–6 as a whole ($p < .05$). Interestingly, there were differences within major groups: categories 1–2 (mild-moderate X2), (14.6%) vs 3 (severe X2) (60.0%) ($p < .01$), emphasizing the presence of *functional* dehydration in children with the dryest corneas and highest prevalence of minimal-to-absent tearing despite edema; and category 4 (24.4%) vs 5 (80.0%) ($p < .02$).

Stomatitis was present in 21% of cases, without any consistent variation by type or degree of corneal involvement. Cheilosis was present in only two cases, both in category 6.

Associated diseases

Respiratory tract infection, severe (life-threatening) general status, and a recent history of fever all increased in prevalence with the severity of corneal involvement. A statistically significant difference in the prevalence of respiratory tract infection occurred at only one transition: from ulcers (group 4) to local necrosis (group 6) (29% vs 53%, $p < .05$). A significant difference in life threatening status occurred at two transitions: from ulcers (group 4) to local necrosis (group 6) (12% vs 36%) and from local (group 6) to general necrosis (categories 7–8) (73%) (both $p < .02$).

Gastroenteritis was present in 7% of cases, otitis in 5%, a recent (≤ one month) history of passing worms in 30%, diarrhea (4 or more loose stools in one day) in 72%, cough in 20%, and anorexia/vomiting in 21%. The prevalence of these conditions did not correlate with the severity of corneal disease.

As systemic infections and other diseases can exacerbate and precipitate xerophthalmia, presumably by interfering with vitamin A metabolism, we will return to the subject in Chapters 7–8 where the relevance of these diseases to xerophthalmia as a whole is discussed.

III Risk factors and associations

Less is known about the epidemiology of xerophthalmia than about its clinical manifestations. To a large degree this reflects the difficulties inherent in conducting properly organized population-based studies. Although care must obviously be taken in extrapolating epidemiologic data from one community to another, in many instances it is not so much a question of uncovering new associations as of confirming and quantifying those already suspected on the basis of clinical observations and anecdotal reports.

PROTECTED PAGE

7. Nutritional status

> The organism's lack of fat soluble A factor, of which xerophthalmia is the characteristic symptom, may therefore arise partly from a deficient supply, that is food poor in the fat soluble A factor, or diseases of the digestive tract which hinder digestion and the absorption of this factor, and partly from increased consumption during the periods of growth and in wasting infections.
>
> C.E. Bloch, 1924

> It is doubtful whether a deficiency disease ever occurs uncomplicated in man or animals.
>
> E.V. McCollum, 1925

Vitamin A status

Since xerophthalmia is an expression of inadequate delivery of vitamin A to target tissues, it might be supposed that serum vitamin A levels could precisely define individuals with and without clinical disease. For a variety of reasons this is not the case:

1. Except at very low levels, serum vitamin A, currently the only practical method of assessing vitamin A status, is not an accurate reflection of body liver stores [54–56, 269–272].
2. Only some of the vitamin A in the serum is carried by the physiologic transport mechanisms (holo-RBP), and this proportion may vary [61,246].
3. The clinical "adequacy" of body stores, or even circulating levels, will depend on demand.
4. The ability to respond to varied demands depends not only on vitamin A stores but also on potential retinol carrying capacity (primarily adequacy of protein synthesis).

For the above reasons, innate biological variation, and perhaps as yet unrecognized factors, there is considerable overlap of serum vitamin A levels between normal individuals and those with mild (XN/X1) xerophthalmia, and between cases with (X2/X3) and without (X1/XN) corneal involvement. Nonetheless, the presence and severity of clinical disease generally correlate with mean vitamin A levels (refer to Tables 2-2, 3-2, 6-6) [34,35,60,248,253,254] and it is possible, within certain broad limits, to

define levels below which xerophthalmia becomes especially frequent and severe.

Nonconneal xerophthalmia (XN/XN)

The vast majority (85%) of preschool children with nightblindness and/or Bitot's spots in the Study 1 field area had serum vitamin A levels below 20 μg/dl (see Table 2-2). This seems like a reasonable cut-off for mild xerophthalmia (41% had levels above 15 μg/dl, which is therefore far too insensitive a cut-off). The prevalence of XN/XIB among children with vitamin A levels above and below 20 μg/dl was 1.2% and 9.7% respectively. The risk of XN/XIB among children with levels below 20 μg/dl was therefore eight times the risk among those with higher levels, even when the random sample is age adjusted to the abnormals.

The situation among matched controls, living in the immediate vicinity of an active case, is somewhat different. Their vitamin A levels are lower than in the random sample as a whole (see Table 2-2) and a larger proportion is probably at risk of eventual xerophthalmia. The relative risk of clinical xerophthalmia, calculated by the case-control technique appropriate to these data (74), is therefore somewhat lower: children whose vitamin A levels were below 20 μg/dl incurred 3 times the risk of XN/XI, as compared to those whose levels were higher (Table 7-1).

Table 7-1. Calculation of relative risk of mild xerophthalmia (XN/XI) among children with vitamin A levels below and above 20 μg/dl[1]

Serum vitamin A (μg/dl)	Number in cell	
	XN/XI	Matched control
< 20	230	181
≥20	38	87
Total	268	268

Relative risk: $\frac{(230)(87)}{(38)(181)} = 3.4$

1. Case–Control analysis of abnormals (nightblind and/or conjunctival xerosis) and matched controls in Study 1. Only includes *paired* abnormals and controls. Analysis of abnormals and random sample (not matched for neighborhood) yields higher relative risk, 8.1.

Similar calculations applied to data reported from the Phillipines [273] and Sri Lanka [274] reveal comparable relative risks for XN/XIB.

Corneal xerophthalmia

Mean vitamin A levels in cases of vitamin A responsive conjunctival xerosis (see Table 3-2) were significantly higher than in cases with mild (X2) corneal disease (refer to Table 6-6) ($p < .01$).

In our experience (and laboratory), corneal disease (X2/X3) is exceedingly rare at serum vitamin A levels above 15 μg/dl (see Table 6-6). Based on the 16 matched pairs (Study II) for whom blood samples were available, children with vitamin A levels below 15 μg/dl incurred 49 times the risk of active corneal disease as compared to those whose levels were higher.

Relative risk can also be calculated, in less matched fashion, by comparing the distribution of vitamin A levels among all corneal cases (Study II, $n = 98$) and the randomly sampled (Study I) population ($n = 268$). The results are essentially identical: the relative risk of active corneal disease among those whose levels are below 15 μg/dl compared to those whose levels are higher is 51:1.

Hypoproteinemia

Numerous reports attest to the frequent association between hypoproteinemia and xerophthalmia, especially its blinding form [31,34,275]. In the Indonesian studies, serum albumin levels were inversely related to the severity of xerophthalmia (see Table 6-8). Mean serum albumin in vitamin A responsive conjunctival xerosis (Study III) 3.63 g/dl (SE .06) was significantly higher than in corneal xerosis (X2, Study II) ($p < .001$). This is especially meaningful because the children presented for their eye complaints and not, as is frequently the case, for their malnutrition. Albumin and transferrin levels of corneal cases (Study II) were 0.84 ± 0.13 g/dl ($n = 32$ pairs) and 18 ± 22 mg/dl ($n = 24$ pairs) respectively, below those of their matched controls ($p < .001$).

The (case-control) relative risk of corneal xerophthalmia for children whose serum albumin levels were below 3.5 g/dl and those whose levels were higher is 49:1, the same as that for vitamin A levels below and above 15 μg/dl. But whereas 95% of corneal cases had serum vitamin A levels below 15 μg/dl, only 70% had serum albumin levels below 3.5 g/dl. The more severe the disease however, the greater the proportion that did (see

Table 6-8). Only 30% of cases of vitamin A responsive Bitot's spots (Study III) had albumin levels below 3.5 g/dl.

Edema was present in 29% of cases with corneal involvement, the prevalence increasing with the severity of disease (see Fig. 6-3). Only 4% (2/48) of cases of vitamin A responsive Bitot's spots (Study III) were edematous, a rate significantly below the 19% for corneal xerosis (X2) ($P < .01$). Twenty-one percent of corneal cases in the pairwise comparisons, but none of their matched controls, were edematous ($n = 33$, $p < .01$).

Although edema was not consistently assessed until late in Study IV, its prevalence among preschool-age Indonesian children was well below 1%. Clearly the relative risk of corneal disease among edematous children is extremely high (probably >40:1). But only one-third or less of corneal cases (and less than one-tenth of noncorneal cases) had edema.

Vitamin A–protein interaction

At least two factors account for the association between xerophthalmia and protein deficiency. One is dietary: it is reasonable to suspect that children whose diets are deficient in protein are likely to be deficient in other nutrients as well [276]. In at least one instance, however, the opposite occurred [277]: desperately poor children forced to subsist on cassava (including its leaves) were malnourished but relatively free of xerophthalmia, whereas nightblindness and Bitot's spots were common among their otherwise better nourished rice-eating, vegetable-avoiding peers.

The other factor is metabolic: a direct interaction between protein and vitamin A status. In protein deficiency, synthesis of retinol-binding protein is depressed and the capacity for retinol transport thereby reduced (Chap. 1). Even in the presence of adequate vitamin A stores, serum vitamin A levels may be low [56]. High-protein diets can raise serum vitamin A levels [134,263,278,279] by liberating retinol from liver stores (278). Smith et al. [279] reported elevation of both serum vitamin A and total RBP within 2 weeks of feeding malnourished children a high-protein diet, although the concomitant rise in serum carotene in these same subjects suggests that they may have consumed provitamin A-containing foods as well. Ingenbleek [263] observed a doubling of both serum vitamin A and total RBP within 8 days after starting children with kwashiorkor on a high-protein diet providing only 60 IU of vitamin A per day. Even more to the point, we shall see that the holo-RBP response to a massive dose of vitamin A is directly related to baseline protein status (Chap. 13).

In rats at least, protein deficiency can also interfere with vitamin A storage in the liver [280–282]. This may explain, at least in part, the transient nature of the clinical response in some of our persistently severely hypoproteinemic patients (Chap. 13).

It is likely that additional mechanisms exist by which protein deficiency exacerbates the effects of vitamin A deficiency and that the interaction between the two determines the relative adequacy of vitamin A metabolism of target cells. Precise estimation and correlation of protein and vitamin A status might result in a mathematical model defining this relationship and distinguishing levels of vitamin A "adequacy" associated with each of the clinical changes observed. An approach to this problem is possible with the serum albumin and vitamin A data at hand (Study II) [259].

As already noted (Chap. 6), serum albumin and transferrin are useful indices of baseline protein status, but serum vitamin A is not necessarily an accurate reflection of vitamin A status: serum vitamin A may be little altered by changes in liver stores [56,84,283], may be affected by other diseases [269,284], and is often related to protein status. Although the correlation between serum vitamin A and protein is generally ascribed to the importance of RBP synthesis for retinol transport, we have already discussed clinically significant variations in serum vitamin A among patients with corneal xerophthalmia in the virtual absence of detectable levels of holo RBP. Possibly under these extreme circumstances serum levels of vitamin A (retinyl ester and/or free retinol) provide a reasonably accurate index of physiologically available vitamin A stores.

To investigate the interrelationship between vitamin A and protein status, clinically normal matched controls and cases of mild to moderate (categories 1–5) and severe (categories 6–8) corneal disease, all from Study II, were individually spotted by their serum levels of vitamin A and albumin (Fig. 7-1). The overlap between abnormals and normals, when vitamin A and albumin are considered independently of one another, virtually disappears when the two are considered together. The difference is most pronounced and boundaries evident for corneal necrosis. Figure 7-2 indicates that these boundaries hold up reasonably well when tested against a larger sample of clinically normal children from a different population (matched controls and random sample from Round 1, Study I).

This represents more than a tendency for diets poorer in vitamin A to be poorer in protein as well [285]. At every vitamin A level (15–19 μg/dl, 10–14 μg/dl, and <10 μg/dl), the distribution of clinically normal children, cases of mild to moderate (X2/X3A) corneal xerophthalmia, and cases of

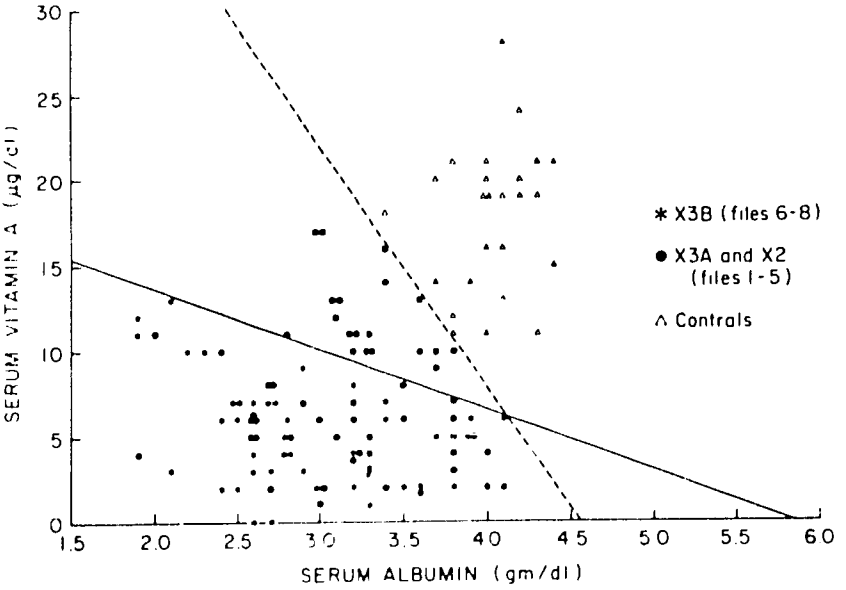

Fig. 7-1. Corneal cases and matched controls plotted by serum vitamin A and albumin levels. All cases of stromal loss (X3A X3B) fall below the broken boundary, all cases of necrosis (X3B) below the solid boundary. Study II. (From Sommer et al. [259])

Fig. 7-2. The serum vitamin A/albumin boundaries in Fig. 7-1 applied to clinically normal children included in the random sample of Round 1, Study I. (From Sommer et al. [259])

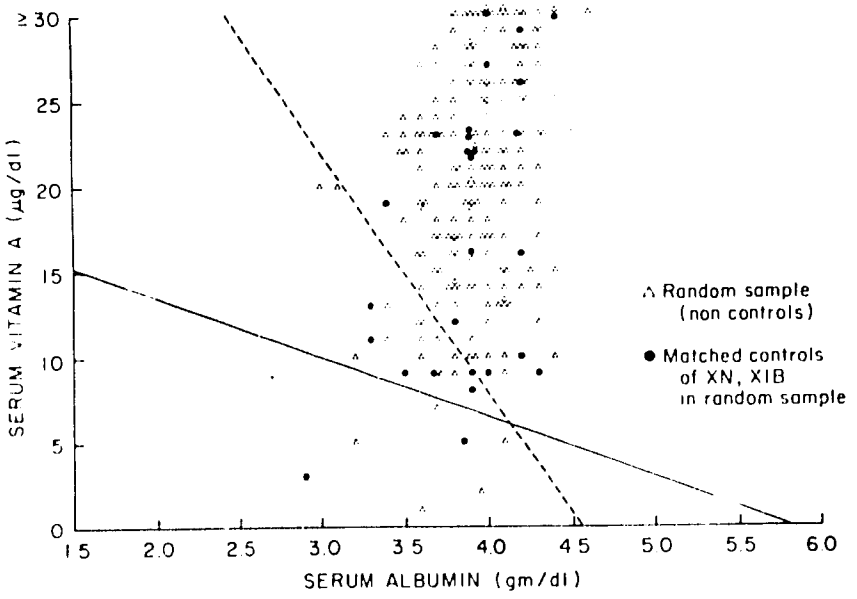

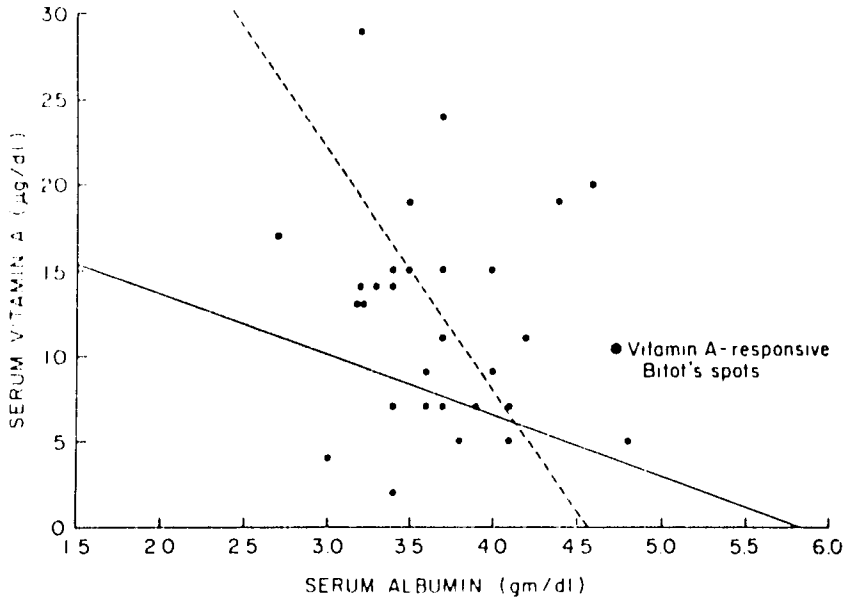

Fig. 7-3. The serum vitamin A albumin boundaries in Fig. 7-1 and 7-2 applied to cases of vitamin A responsive conjunctival xerosis. Study III.

severe (X3B) corneal disease across these boundaries are statistically significantly different from one another ($p < .001$ for each comparison). Although this linear model is undoubtedly a gross simplification of a more complex relationship, the distribution of vitamin A responsive cases of conjunctival xerosis (Study III) across these same boundaries (Fig. 7-3) is also statistically significantly different from corneal cases of corresponding serum vitamin A level ($P < .004$ at 10–14 μg/dl; $p < .001$ at < 10 μg/dl).

Even when standardized for serum albumin, serum vitamin A levels among cases of X3B are significantly different from those of milder corneal disease (Table 7-2). The significance of vitamin A–protein interaction in the development of corneal necrosis (X3B) is readily apparent from this same set of data. If corneal dissolution represents severely depressed vitamin A metabolism, patients whose protein status is relatively normal would need to be *severely* vitamin A deficient; those only moderately vitamin A deficient would need to be *severely* protein deficient. This would produce an inversion of the correlation ordinarily observed between protein and vitamin A status. Such in fact was the case: the slope of serum vitamin A on albumin among cases of X3B (categories 6–8) is *negative* ($p < .05$), and sta-

Table 7–2. Albumin-standardized serum vitamin A levels

Albumin category (g/dl)	Clinical classification of individual[1]			
	Normal	X2 (category 1–3)	X3A (category 4)	X3B (category 6–8)
>3.5–4.0				
Number	110	9	7	6
Albumin $\bar{\mu}$	3.8	3.8	3.7	3.8
Vitamin A $\bar{\mu}$	19.6	7.8	8.4	3.8
SD	7.7	5.5	3.2	2.0
>3.0–3.5				
Number	10	11	12	8
Albumin $\bar{\mu}$	3.3	3.2	3.2	3.3
Vitamin A $\bar{\mu}$	14.5	8.9	9.2	4.1
SD	5.7	5.2	4.6	2.6
≤3.0				
Number	3	5	7	25
Albumin $\bar{\mu}$	2.5	2.7	2.4	2.5
Vitamin A $\bar{\mu}$	13.3	8.4	6.4	5.6
SD	9.3	2.1	2.6	3.5

1 Normals: random sample (Study 1)
Serum vitamin A among X3B significantly lower than that among X2 and X3A at albumin levels of >3.0–3.5 and >3.5–4.0 ($p < .05$)

From Sommer et al. (259)

tistically significantly different ($p < .01$) from the *positive* slope in normal, randomly sampled children in Round 1, Study 1 (Table 7-3). The signs of the slopes for milder forms of xerophthalmia, where vitamin A metabolism is less severely depressed (providing room for greater interplay between these two factors), are indefinite.

This may explain why serum carotene levels are sometimes higher in xerophthalmic children with kwashiorkor than in those without [134]: because of their better protein status, vitamin A intake (as reflected in carotene levels) must be more restricted in the latter group for them to develop xerophthalmia. It also accounts for the severest forms of xerophthalmia being commonly accompanied by protein deficiency; and for earlier observations [59], that xerophthalmia was generally limited to severely malnourished individuals unless primary vitamin A deficiency was widespread and severe. Sinha [286] found that only rats concomitantly starved of both protein and vitamin A developed keratomalacia.

As holo-RBP is severly depressed in all forms of corneal xerophthalmia,

Table 7–3. Regression analysis of vitamin A on albumin[1]

Clinical status (category)	r	y intercept	slope	SE
Normal	+0.8849	1.498	+4.521	2.33
1–3	−0.5592	10.352	−0.610	2.14
4	+0.7983	2.430	+1.792	1.54
6–8	−0.9618	9.303	−1.499	0.39

1. From Table 7–2. Linear regression (least squares) and correlation based on mean vitamin A and albumin levels for each of the 3 albumin categories, thus giving equal weighting to the relationship at each of the data points along the curves. Since none of the abnormals had a serum albumin ≥ 4 g/dl, normals this high were excluded from the analysis.

From Sommer et al. [259].

protein deficiency must act at additional loci, not simply by depressing apo-RBP synthesis. One potential site is within the target cell itself. Preliminary data from the Hyderabad laboratories suggest that cellular RBP is depressed in protein-deficient rats [287]. Transport RBP is not essential for entry of retinol into some cell culture lines [288]. In fact, the presence of transport RBP may decrease retinol uptake.

Nonetheless, except among children "in extremis" [289] protein deficiency appears to be of little ocular consequence unless accompanied by primary vitamin A deficiency. Otherwise, one would not expect the wide variation in frequency of ocular involvement reported in kwashiorkor [254]. Despite extremely low serum vitamin A levels in both Smith's [279] and Ingenbleek's [263] studies, the children were free of xerophthalmia. Certainly corneal cases in our own series suffered from depleted stores: essentially all responded to administration of vitamin A with an outpouring of holo-RBP, and vitamin A alone induced healing in even the most severely protein deficient children (Chap. 13) [60,246,290].

Three studies are regularly quoted as evidence that protein, rather than vitamin A deficiency is responsible for corneal xerophthalmia [42,145,179], but none are incompatible with the formulation presented above. Yap [42] observed a greater difference in serum albumin than vitamin A levels between ten cases of "xerophthalmia" and ten of "keratomalacia." No information is provided on how these 20 were selected from the vast pool available, or how he defined his terms. Kuming [179] stressed that the "sine quo non for xerophthalmia is *protein* malnutrition," but only examined children already admitted for protein-energy malnutrition [136]. Vitamin A

levels among a subsample of children with moderate to severe corneal lesions were below those of malnourished children without eye lesions, while the prevalence of clinical edema, and serum protein values are never stated. Emiru [145] simply did not recognize clinical xerophthalmia. Any doubts on this point are dispelled by his own histopathologic studies: frank keratinization was present in at least four of the ten eyes examined from children said to be free of xerophthalmia.

Chronic protein deficiency may have a paradoxical effect on vitamin A status: by inhibiting growth and depressing the metabolic rate [291] it may conserve existing stores [56,292]. Protein-deficient rats utilize RBP at only half to two-thirds the normal rate [293,294]. Hence a child with depleted stores is in a precarious balance: anything that increases vitamin A demands, including a protein-induced growth spurt [145] can precipitate clinical xerophthalmia. Gopalan [134] observed malnourished children fed protein-rich diets develop xerophthalmia and Bloch [176] attributed the seasonality of xerophthalmia in Denmark to demands placed on limited vitamin A reserves by the spring growth spurt. This is the reason for insisting that skimmed milk powder used by food relief programs be fortified with vitamin A [295]. Where vitamin A reserves are adequate, protein feeding probably increases retinol carrying capacity sufficiently quickly to avert ocular disaster.

General nutritional status—height and weight

The existence of "Fat-Soluble A" was first recognized by its effect on growth. Young rats made vitamin A deficient fail to grow normally, or even to maintain their original weight [23–25], and only subsequently develop ocular changes [215].

In a unique, unplanned human experiment, Bloch [3,176] observed the same sequence in children: orphans who developed xerophthalmia had failed to gain weight during the preceding winter, in contrast with their nonxerophthalmic peers who had consumed diets of similar protein and calorie content, but higher vitamin A. Addition of cod liver oil to the diets of the xerophthalmic children resulted in prompt disappearance of their eye lesions and an increase in their weight. Bloch was so struck by this association he termed the disease "dystrophia alipogenetica": "dystrophia" for the stunting, "alipogenetica" because it arose from the lack of a substance present in some fats.

Ordinarily the relationship between growth and vitamin A status is more

complex, it may reflect an association between vitamin A intake, calorie and protein intake, and the prevalence of infectious diseases, as much as it does any growth-promoting properties of the vitamin. Most of Mori's [18] patients with "Hikan" were underweight. But they were also hungry, which suggests that calorie and/or protein deficiency may have been a limiting factor. Blackfan's [40] observations that height and weight were below normal and cessation of bone growth common were made on children with minimal, if any, clinical evidence of vitamin A deficiency and sufficiently severe generalized malnutrition and/or systemic illness to reach autopsy. In most early clinical reports, xerophthalmia was largely confined to severely malnourished individuals [4,15,17,20,39,68,77], and the relative paucity of cases of mild ocular involvement suggests that primary vitamin A deficiency may have been uncommon and rarely severe. Ten Doeschate [71,258] and Oomen [35] both reported that malnutrition parallels the severity of corneal involvement, and Brown [275] found that children hospitalized in a malnutrition ward with xerophthalmia were even more malnourished (by weight for age and weight for height) than similarly hospitalized children without clinical evidence of vitamin A deficiency.

Whatever the relative influence of these various factors, data from Indonesia suggest that xerophthalmia is more closely associated with stunting than wasting, but that the latter, which can be assessed without recourse to age, is useful in identifying individuals at particularly high risk of corneal involvement.

Wasting

Because it is self-correcting for stunting, "weight for height" is a practical means of assessing adequacy of acute nutritional status.

Among 159 (of 162) cases of corneal disease in Study II in which weight and height were recorded, 46% were at least moderately wasted (< 80% of Western standards; 12% severely so; see Table 6-11.) The severity of wasting was greater among corneal than among noncorneal cases (Study III) and increased with the severity of corneal involvement. The percent standard weight for height among corneal subjects was, on the average, 15 ± 2.5% below that of their matched controls (n = 32 pairs, p < .001). The case-control relative risk of corneal disease among children with a weight for height less than, vs "equal to or greater" than, 80% of standard was 35.1

Results of the more representative, but far smaller, sample from the

country-wide survey (Study IV) are remarkably similar. Among the 22 cases of active corneal disease 10 (45%) were at least moderately wasted, 5 (23%) severely so. Wasting increased with the severity of corneal involvement (mean 76% vs 83% of standard for X3 and X2 respectively, $p < 0.2$), and was significantly more severe among corneal than noncorneal (Bitot's spot) cases (mean weight for height 80± 4.7% SE vs 95± 0.5% SE respectively, $p < .001$). This could not be attributed to a difference in the age of corneal and noncorneal cases: they were similar, and the mean weight for height among noncorneal cases at least 86% at every age (Table 7-4). The relative risk of corneal disease among individuals with (<80%) and without (>80%) moderate wasting, as calculated from wasting-specific prevalence rates of active corneal disease, is 19:1, slightly more than half that calculated in Study II.

In contrast with corneal disease, mild (noncorneal) xerophthalmia was

Table 7–4. Mean percent of standard[1] weight for height by age and clinical status (Study IV)

Age (years)	Clinical classification: Bitot's spots	Matched controls	Normal
0 number	1	2	5630
mean	100	102	99
wl number	25	24	5590
mean	86	94	92
2 number	70	64	5704
mean	94	94	93
3 number	94	84	5773
mean	95	96	96
4 number	70	67	5327
mean	98	99	97
5 number	97	98	6425
mean	98	97	96
Total number	357	339	34,449
mean[2]	95	96	95
SE	0.5	0.8	0.05

1. Standards adapted from Jelliffe [174], with extrapolation down to 45.5 cm.
2. For comparison, in cases of active corneal xerophthalmia mean was 80%, SE 4.7% ($n = 22$). Difference in mean between corneal cases and Bitot's spot cases, $p < .001$.

Table 7–5. Distribution weight for height by deciles of standard[1] (Study IV)

Age years	Clinical classif.[2]	Total n	Distribution by decile (percent of total) 5-6	7	8	≥9
1	XIB	25	12.0	20.0	24.0	44.0
	MC	24	–	8.3	29.2	62.5
	N	5589	1.2	8.1	34.3	56.4
2	XIB	70	–	4.3	35.7	60.0
	MC	64	1.6	4.7	26.6	67.2
	N	5704	0.8	4.3	30.1	64.7
3	XIB	94	1.1	5.3	23.4	70.2
	MC	84	–	2.4	20.4	77.4
	N	5773	0.5	2.5	20.5	76.5
4	XIB	70	–	1.4	15.7	82.9
	MC	67	–	–	20.9	79.1
	N	5327	0.3	1.4	18.3	80.0
5	XIB	97	–	1.0	10.3	88.7
	MC	98		–	15.3	84.7
	N	6425	0.3	1.6	20.6	77.4

1. Standard adapted from Jelliffe [174] with extrapolation down to 45.5 cm.
2. MC, matched controls; N, all normal children.

not associated with increased wasting. The mean weight for height (Table 7-4) of subjects with Bitot's spot, and distribution of their weight for height by deciles (Table 7-5) were essentially identical to those of their matched controls and other normals in Study IV. They were also identical to those of cases of vitamin A responsive conjunctival xerosis in Study III (for whom controls were never recruited).

Cases of Bitot's spots in Study IV weighed less for their age than their matched controls (μ = 0.6 kg, p < .01), but the difference is related to their stunting and not their acute nutritional status.

This lack of association between mild xerophthalmia and wasting has been reported in cross-sectional studies from India [183], Sri Lanka [274], and Jordan [296]. Although there was insufficient clinical material to make a similar comparison in Guatemala, excessive wasting was limited to children whose serum vitamin A levels were extremely low (< 10 μg/dl) [297]. A recent report, of nonxerophthalmic children, suggests beta carotene intake is not a significant determinant of weight corrected for height [298].

Stunting

Unlike wasting (based on weight for height), height for age reflects long-term growth, which is susceptible to caloric and protein restriction, severe systemic illnesses, and other insults.

In comparison with their matched controls, children with active corneal disease in Study II were clearly stunted, the mean difference in percent standard height for age being 2.7% (n = 27 pairs, p < .05). The magnitude of the difference (i.e., the degree of "excess" stunting) was *inversely* related to the severity of corneal involvement (Table 7-6, p < .001). This somewhat surprising finding probably reflects the inverse relationship between age and severity of corneal involvement (see Fig. 6-2): being younger, the severer cases experienced inhibited growth for a shorter period and the effects therefore were less pronounced. Seventy percent of these corneal cases and 40% of their controls had heights below 90% of standard for age, and a relative risk of corneal involvement below and above this criterion of 2.6:1. Lower cutoffs of height for age include many fewer cases of corneal disease without any significant increase in relative risk.

Because of the rapid nature of the country-wide survey, and multiplicity of methods by which age is calculated in the many cultures examined, recorded age in months was not considered sufficiently precise or reliable to permit the use of height-for-age standards in analyzing data from Study IV. Instead, mean height for age (in years) was computed and compared among the different clinical groups. As in Study II, subjects with active corneal disease (X2 X3) were clearly stunted (Fig. 7-4). They were shorter, at every age, than children with Bitot's spots, matched controls (of the cases of Bi-

Table 7–6. Pairwise difference in percent standard height for age of corneal cases and controls (Study II)

Comparison	Pairs (n)	$\bar{\mu}\Delta$	SE
X2-MC	8	−3.95	2.43
X3A-MC	10	−2.72	2.43
X3B-MC	9	−1.62	1.86
Total			
X-MC	27	−2.72	1.27

r = .9995, p < .001; b = −1.164, m = 5.09

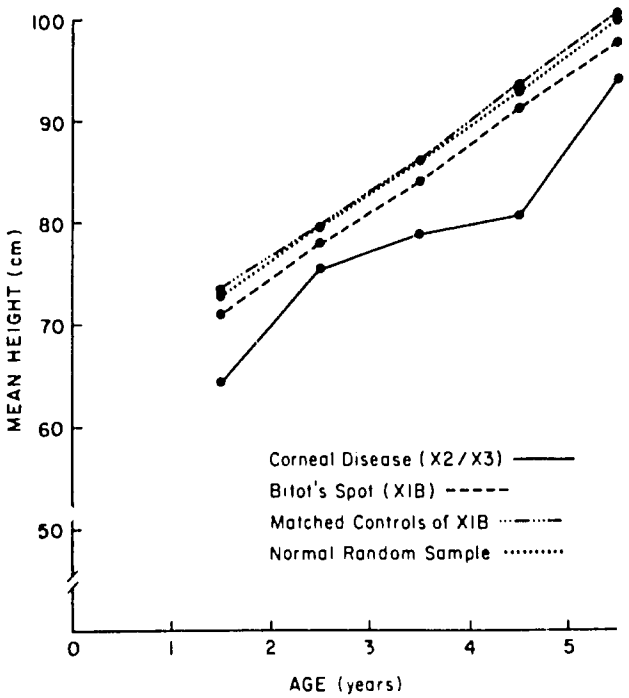

Fig. 7-4. Children who had active corneal disease were shorter for their age than those who had Bitot's spots ($p < .01$), and children who had Bitot's spots were shorter than their matched controls ($p < .01$). There was no significant difference in mean height for age between random sample normals and the matched controls. Study IV.

tot's spots), and the rest of the population ($p < .01$). In contrast to wasting, even mild xerophthalmia (X1B) was associated with stunting: cases of Bitot's spots were, on the average, 2.6 cm shorter than their matched controls ($p < .01$).

In Sri Lanka, Bitot's spots were far more closely associated with stunting than wasting [274], and in Guatemala [297], children with severely depressed serum levels of vitamin A (< 10 μg/dl) were more severely stunted than those with higher levels. In nonxerophthalmic Peruvian children, beta carotene intake was strongly associated with attained height (298).

The intimate association between xerophthalmia and stunting, and the absence of an association between xerophthalmia and wasting (except in severe, X2/X3 disease), is remarkably consistent with the sequence of changes originally observed in vitamin A-starved rats [23–25,215]: they

first stopped growing, only later, after their vitamin A deficiency had become severe, did they lose weight. Despite multiple dietary deficiencies, gastroenteritis, and other diseases typical of developing countries, vitamin A deficiency, per se, appears capable of having a significant impact on growth and development. Conversely, whatever the impact of acute malnutrition, wasting, and its milieu on xerophthalmia, it appears to be limited to cases of corneal involvement.

8. Contributory and precipitating diseases

. . . in weakly ill nourished infants, cough, great emaciation and ulceration of the cornea ending in staphyloma, are not uncommon sequelae of measles.

MacKenzie, 1834

In . . . tuberculous meningitis, . . . infantile diarrhea, . . . measles, . . . whooping cough, . . . bronchitis, . . . and malignant varicella, where there had been much exhaustion, the cornea was not infrequently seriously damaged by large perforating ulcers.

Spicer, 1892

Although it is true that in a number of patients the onset of clinical signs of vitamin A deficiency was preceded by episodes of fever, infections and alimentary disorders, such episodes were apparently no more frequent in children showing signs of vitamin A deficiency than in those of the same socio-economic group not suffering from this deficiency.

Gopalan, 1960

Besides protein-energy malnutrition (Chap. 7) a number of diseases have traditionally been associated with xerophthalmia. For some, like cystic fibrosis [96] and chronic small bowel disease [94,95,272,299,300], vitamin A malabsorption is clearly responsible. For others, like liver disease, the relationship is more complex [4,12,38,193,301,302]. It may be due to poor diet [92,303], impaired absorption [92,95,168,299,304], decreased capacity for storing or transporting the vitamin [64,95], urinary loss [305], or the influence of concomitant diseases [306].

The association with infectious diseases, however, is the most prevalent and complex of all, which is hardly surprising given the ubiquity of these diseases in developing cultures (turn of the century Europe as much as today's Third World) and their intimate interactions with nutritional status, feeding practices, and one another. Xerophthalmia commonly occurs along with respiratory tract infections [20,32,40,71,155,307–309], diarrhea [9,11,16,17,32,71,106,142], tuberculosis [20,35,155,273], childhood exanthems (chickenpox and measles) [27,32,45,71,309–313], pertussis [20,273], scarlet fever [5,9,32], typhoid [32,314], malaria [35], and encephalitis [9]. Fluctuations in xerophthalmia incidence have been attributed to

the seasonal occurrence of "precipitating" infectious diseases: diarrhea [18,39,106,155,248], respiratory tract infections [309], and measles [149].

General and specific mechanisms exist by which infectious diseases can affect vitamin A status. Some diseases (especially those observed in early European reports) like chronic diarrhea, measles, tuberculosis, malaria, and encephalitis may lead to severe wasting and debilitation [4,9,17,20,32], with accompanying protein and vitamin A deficiency, dehydration, and multiple secondary infections. Both measles and dysentery [289] may precipitate kwashiorkor in children in borderline nutritional status.

Serum vitamin A levels decline in a variety of infections [272, 297,299,315], sometimes by as much as 20–30 μg/dl [315]. In some instances, the degree of decline is related to the severity and duration of the infection [299]. In part, this fall in serum vitamin A represents a nonspecific response to fever [299,316], and may persist for days after the temperature has returned to normal [299]. In children with rheumatic fever, serum levels dropped by 50% when their temperature exceeded 100°F [317].

Some infections have a particularly pronounced affect on vitamin A metabolism. Serum vitamin A levels are routinely depressed in respiratory disease [272,299,315,318]. Ordinarily, vitamin A does not appear in the urine, but during respiratory tract infections enormous amounts (in excess of 3000 IU/day) may be lost by this route [305,319,320]. Respiratory infections also interfere with absorption of beta carotene and vitamin A. Beta carotene absorption may fall as much as 50–80%, remaining at this level as long as two weeks after the last day of fever [300]. Dietary intake ordinarily capable of raising serum vitamin A may fail to maintain preexisting levels [318]. Absorption of vitamin A administered in moderate amounts, ordinarily 90% or higher, may fall to as low as 30% (mean 74%) [321]. The average rise in serum vitamin A levels in persons with tuberculosis, following a massive oral dose, is only half that in normals [322].

Intestinal infections have a similar effect on absorption. Absorption is seriously impaired in steatorrhea [323], in gastroenteritis not accompanied by fat malabsorption [321], in chronic salmonellosis [324], and even in asymptomatic infection with parovirus and certain strains of *E. coli* [325].

Animal experiments provide additional evidence that bacterial and/or viral colonization can affect vitamin A status. Vitamin A-deprived weanling rats raised in conventional surroundings grow for only a short period of time, with cessation of growth soon followed by death. When equally deprived rats are maintained in a germ-free environment, growth continues,

albeit at a reduced rate, and they often survive longer [228,326,327]. It is likely that their available stores were consumed more slowly. If germ-free rats are then exposed to a conventional environment, growth ceases and death ensues, but if fed vitamin A, growth resumes and the rats survive [326].

The magnitude and rapidity of the fall and subsequent recovery of serum vitamin A levels in children with various acute infections and or fever suggests direct interference with vitamin A release and transport in addition to the potential depleting affects of impaired absorption and increased utilization and excretion.

Given these interactions, it is easy to see how chronic respiratory tract infections and diarrhea, by decreasing vitamin A absorption and increasing its utilization and excretion, would eventually deplete liver stores, particularly in children whose intake and reserves are limited to begin with. And it is evident that chronic wasting diseases and acute infections, by interfering with vitamin A release and transport, can precipitate xerophthalmia in children whose serum vitamin A levels are already depressed. The difficulty lies in demonstrating that these infections actually contribute to the development of xerophthalmia in a significant proportion of cases. If they do, such infections should be more common among children with xerophthalmia than among those without. But few studies include a control group of nonxerophthalmic children for comparison (Table S-1). In those that do, results depend upon the manner in which data are collected and controls selected, how recent or acute the infection in question is, and the severity of the xerophthalmia. For example, diarrhea was present in almost all severely malnourished hospitalized Jordanian children [248] and so could not be more prevalent in one group than another. If precipitation of severe protein-energy malnutrition (PEM) is the major mechanism by which infection contributes to xerophthalmia [328], comparison with a control group of severely malnourished nonxerophthalmic children would obscure this influence; this probably happened in a series from Bangladesh [275]. Lastly, depending on the severity of underlying vitamin A deficiency in the community, infections will play a larger or smaller role in precipitating clinical xerophthalmia. Where severe hypovitaminosis A exists for purely dietary reasons, infection may not contribute to as large a proportion of the cases as it does where dietary deprivation is more mild. These factors probably explain the conflicting results reported.

Gopalan [134] concluded that infections were no more common in Indian children with than in those without xerophthalmia. The prevalence of diar-

Table 8-1. Presence of an association between childhood infections and xerophthalmia

Study	Cough URI	Diarrhea GI	Measles	TB	Round Worms
Bangladesh [275]					
Guatemala [297]	+	+			
Philippines [273]	+			+	
Jordan [296]		+			+
Indonesia					
X1		+			+
X2 X3	+	+	+		?

rhea, enteric infections, pneumonia, or tuberculosis was the same in malnourished hospitalized Bengali children with and without xerophthalmia though "one or more major infections" was present more frequently in the former (93% vs 73%) [275]. Fever, respiratory tract infection, and gastroenteritis were all more frequent among those Guatemalan children with vitamin A levels below 10 μg/dl [297]. Tuberculosis and whooping cough were more frequent among Filipino children with than without mild (XN X1) xerophthalmia but diarrhea and measles were not [273]. A history of recurrent diarrhea, but not respiratory tract infection, was more common in Jordanian children with than among those without xerophthalmia [296].

In Indonesia, where the role of infection was examined from several perspectives, diarrhea, respiratory tract disease, measles, and worm infestations were all associated with xerophthalmia (see Table 8-1).

Diarrhea/gastroenteritis

Differences were not as pronounced for clinically detectable gastroenteritis as for a history of diarrhea.

Gastroenteritis was diagnosed at initial examination in 2% (1/50) of children with responsive Bitot's spots (Study III) and 7% (11/156) with active corneal disease (Study II) whose records contained a completed pediatric examination (96% of the total). As these results would suggest, the prevalence of gastroenteritis did not vary with the severity of corneal involve-

ment. Gastroenteritis was present in more than twice as many corneal cases (12%) for which there were matched controls as in the controls themselves (5%), but the difference is not statistically significant ($n = 33$ pairs).

Sixty-six percent of cases of Bitot's spots (Study III) and 72% of all 162 cases of active corneal disease (Study II) had a history of 4 or more loose stools per day sometime during the preceding month; again, the latter rate was independent of the severity of corneal involvement. The rate among the subgroup of active corneal cases for which there were matched controls was comparable, 79%, but among the controls themselves only 23% ($n = 33$ pairs, $p < .001$). Case-control analysis suggests that children with a history of diarrhea during the previous month are at 13 times the risk of active corneal disease as children without such a history. A majority of the diarrheal episodes were said to have occurred within the previous week. Children in the countrywide survey (Study IV) were not examined for gastroenteritis, but were queried about recent diarrhea. Results were similar to those above. A history of diarrhea during the previous two months was significantly more common among cases of Bitot's spots (61%) than their matched controls (52%) ($p < .01$). The greatest difference occurred during the previous week (10.1% vs 3.5%, $p < .001$) (Table 8-2), when a significant difference was present for each year of age, two through five (statistically significant for two through four), and the overall risk of Bitot's spots among children in this age range who had such a history was five times that of children who did not. There was no meaningful, consistent difference in

Table 8–2. History of diarrhea[1] by clinical status (Study IV)

Age (in years)	Number in class			Percent with positive history[2] of diarrhea					
				Past week			Past month[3]		
	XIB	MC	N	XIB	MC	N	XIB	MC	N
0	1	2	5674	0.0	0.0	5.5	0.0	0.0	6.4
1	25	24	5607	12.0	16.7	7.6	18.2	20.1	11.8
2	70	64	5723	12.9	3.1	5.7	16.4	20.9	11.5
3	94	85	5793	13.8*	4.7	3.9	16.0	11.2	10.6
4	70	67	5338	10.0*	1.5	2.7	12.7	12.1	9.3
5	92	92	5843	4.3	1.1	2.1	10.2	7.7	7.6
Unkn.	6	6	598	0.0	0.0	0.8	0.0	16.7	1.5

1. Defined as 4 or more loose stools in one day.
2. Most recent episode. MC, matched controls; N, all normals.
3. Those positive in past week excluded from at-risk group.
* XIB vs MC, $p < .05$.
Overall rate: XIB vs MC, $p < .01$ for past week plus past month; $p < .001$ for past week alone.

the diarrheal histories of males and females in any of the disease categories.

Since the association between Bitot's spots and diarrhea was greatest for the week immediately preceding examination, when the majority of Bitot's spots were likely to have already been present, we must suppose that the underlying vitamin A deficiency contributed to the diarrhea, or, more likely, the reliability of this historical data declined with the duration between the event and its recall.

Respiratory tract disease

Clinically detectable respiratory tract disease (fever plus cough/rales) was the commonest condition accompanying cases in Studies II and III, the prevalence increasing with the severity of xerophthalmic involvement ($p < .01$) (Fig. 8-1). It was significantly more common among matched cases of X3B than their normal controls (7/11, 64%, vs 1/11, 9%, $p < .01$), but not more common among matched corneal cases of lesser severity (X2/X3A) than among their controls.

Confirming the pattern for clinically detectable respiratory tract disease, a history of cough during the preceding month was significantly more common among cases of X3B (27%) than among those with milder corneal disease (X2, 17%, X3A, 16%) ($p < .01$). In pairwise comparisons a history of recent cough was more prevalent among the matched subgroup of corneal cases as a whole (30%) than among their nonxerophthalmic controls (9%) ($n = 33$ pairs, $p < .05$). Although the numbers are too small for statistical significance, the difference between abnormals and matched controls was greatest for the subgroup with stromal loss.

A number of factors may explain the particularly high frequency of respiratory tract disease among cases of corneal necrosis (X3B). These children were generally more malnourished and debilitated than children with milder disease, conditions generally associated with a high prevalence of respiratory infections [289]. Furthermore, vitamin A deficiency, most severe in this group, is associated in both animals [164–166] and man [40,155] with keratinizing metaplasia of the epithelial surfaces of the larynx, trachea, and bronchi, which may in turn increase susceptibility to colonization and infection [40,329]. Alternatively, the profound influence respiratory tract infection has on vitamin A metabolism may have contributed to the severity of these children's corneal disease.

The relationship between respiratory disease and xerophthalmia was not investigated in the countrywide survey (Study IV).

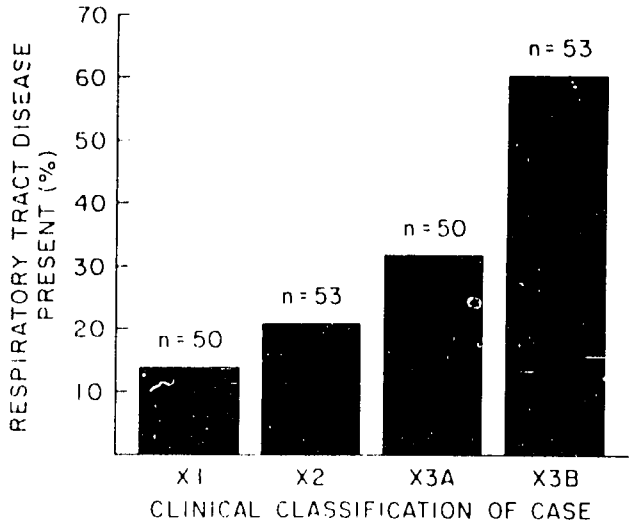

Fig. 8-1. The prevalence of respiratory tract disease increased with the severity of xerophthalmia ($p < .01$ for linear trend). X1 (vitamin A responsive conjunctival xerosis, Study I); X2, X3A, X3B (corneal xerosis, ulceration, and necrosis respectively, Study II).

Measles

Five of the six potentially xerophthalmic cases of corneal disease originally excluded from Study II had evidence of active or recent measles. Two of these (200/166 and 200/17) had bilaterally active but atypical corneal changes and were excluded because of clinical uncertainty at the time of initial diagnosis. One (200/166) first seen 12 days after onset of measles contained three inferocentral, superficial, saucer-shaped infiltrated ulcers in a perfectly straight horizontal line in the left eye, and a linear central ulcer resembling a traumatic lesion in the right eye. Both corneas of the other case contained extensive, dense SPK and multiple tiny, intensely white, fluorescein-positive superficial ulcers/erosions in a horseshoe distribution about the inferior three-fourths of the corneal periphery. The latter subject had been successfully treated for nightblindness with low-dose vitamin A pills three months previously, but a week prior to admission developed fever, cough, diarrhea, and measles rash coincident with the return of nightblindness. Initial serum vitamin A levels were extremely low in both cases (7 μg/dl and 5 μg/dl) despite evidence of reasonably adequate protein status (serum albumin 3.1 and 3.5 g/dl and transferrin 183 and 244

mg/dl). Both cases received massive vitamin A. The first case was not seen again for one month, when the right cornea contained a healed leukoma, and the left cornea appeared clear. The second case was followed closely; the ulcerating peripheral lesions virtually disappeared within three days. In retrospect, both cases appear to have been instances of measles-precipitated xerophthalmia in which the viral disease may have modified the corneal changes.

The three remaining measles-associated, but excluded, cases all presented late, after corneal healing had commenced. All three were severely malnourished and had stromal involvement (potentially categories 4–6). Two of these cases, one with a long history of nightblindness, had already received large amounts of oil-miscible vitamin A intramuscularly. Even so, their serum vitamin A levels were still below normal: 13 and 16 μg/dl. As far as we knew the third case had not received any vitamin A; his holo-RBP was 0 μg/ml.

Despite this disproportionate exclusion of measles cases from the formal series, six children with active corneal disease (4%) in Study II (but none with vitamin A responsive Bitot's spots in Study III) had evidence of measles at the time they presented. All had classical corneal necrosis, five localized (group 6) and one total (group 8). The prevalence of active measles was therefore statistically significantly greater among categories 6–8 than among cases with milder corneal disease (11.6% vs 0%, $p < .001$). Each and every one of these six cases had extremely low levels of serum vitamin A and/or holo-RBP.

Besides these six children, five additional cases of active corneal disease (Study II) with extremely low vitamin A and/or holo-RBP levels (for a total of 11) had a history of measles during the preceding two months. In nine (82%) the measles had appeared during the past month (Table 8-3). Ten of the eleven suffered corneal necrosis, eight localized (group 6) and two generalized (one each in categories 7 and 8). Once again recent measles, this time by history, was more prevalent among cases of necrosis than among those with milder corneal disease (17% vs 2%, $p < .01$). Even if the two excluded cases of active, atypical corneal ulceration are included in category 4, the prevalence of recent measles is still statistically significantly higher in categories 6–8 than category 4, alone or in combination with categories 1–3 ($p < .05$). Two of the matched abnormals and none of the controls had measles by history and/or examination, numbers which are small and not statistically significant. None of the cases of Bitot's spots (Study III) had a history of recent measles.

Table 8–3. History of recent measles among cases of corneal xerophthalmia (Study II)

Corneal cases		Onset of measles[1] (n)					Total with measles	
Severity (category)	Total n	≤7 days	≤2 weeks	≤3 weeks	≤1 month	≤2 months	n	%
1–3	53					1	1	1.9
4–5[2]	50						0	–
6–8	59	1	1	5	2	1	10	16.9

1. Mutually exclusive time intervals before initial examination.
2. Two atypical cases of corneal involvement excluded from category 4 entirely, one with measles onset at ≤7 days, the other at ≤2 weeks.

Difference in prevalence for categories 1–5 vs 6–8, $p < .01$.

The association between measles and severe corneal xerophthalmia was even more pronounced in the countrywide survey (Study IV). Five and nine-tenths percent of children with Bitot's spots, 4.8% of their matched controls, and 4.7% of other normal children were said to have had measles during the month preceding their examination, rates which are not statistically significantly different from one another (Table 8-4). In contrast, 8/22 (36%) of subjects with active corneal disease claimed to have had measles during the past month; a rate many times that of the rest of the population ($p < .001$). Case-control estimation of relative risk indicates that children with a history of recent measles are 11 times more likely to develop corneal xerophthalmia than those without such a history. When the question was phrased differently, 64% of all corneal cases (79% of cases with stromal

Table 8–4. History of measles during the month preceding examination (Study IV)

Age (years)	Total examined (n)			History of measles (%)		
	XIB	MC	N	XIB	MC	N
0	1	2	5674	–	–	5.1
1	25	24	5607	8.0	8.3	6.0
2	70	64	5723	8.5	9.4	5.4
3	94	85	5793	7.5	3.5	4.4
4	70	67	5338	4.3	6.0	4.0
5	92	92	5843	3.3	–	3.2
Unkn.	6	6	598	–	16.7	3.0
Total	358	340	34576	5.9	4.8	4.7

involvement (X3A/B) claimed that the onset of their ocular disease had been preceded, within 1–4 weeks, by measles.

Comparable results were reported by subjects with corneal scarring (XS) encountered in Study IV: 24/51% claimed their ocular disease followed, by one to four weeks, the onset of measles. Consistent with this claim, the number said to have suffered measles during the month preceding the survey was half that of the population as a whole.

The absence of a significant association between measles and Bitot's spots is consistent with observations in the Philippines [273]. It is likely that measles acutely decompensates vitamin A status, resulting in more severe corneal disease. Besides measles' systemic effects on vitamin A metabolism, direct viral invasion may condition the corneal response. This may explain why measles was more closely associated with corneal xerophthalmia, especially XS, in Study IV than with active corneal cases in Study II. Of the 142 children with completed pediatric examination and follow-up in Study II, bilaterally blinding disease was more common in those with measles (3/10, 30%, vs 13/132, 10%; $P = .056$). They were also more likely to survive, which would account for their increased prevalence in the community study (Study IV). Mortality per child month of observation for corneal cases (Study II) as a whole was 4 per 100, vs 0 per 100 for the subgroup with measles ($p = .001$). A total of 15 bilaterally blinded cases in Study II survived for at least two months. Three were associated with measles. Only 1/3 of the measles cases, but 11/12 nonmeasles cases had been severely malnourished at presentation. Assuming that all severely malnourished children would die under usual field conditions, measles-associated cases would account for 67% of surviving bilateral xerophthalmic blindness in the community. If only 75% die, the figure would be 39%. It is unlikely that these estimates of long-term mortality are terribly excessive: over 25% of severely malnourished children treated (most in hospital) in Study II died (see Chap. 12).

Clinically severe corneal xerophthalmia has been observed to follow measles in Europe [2,4,32,193,311,312], the Middle East [248,330], Asia [74,155,308,309,313], and Africa [45,331–335]. Fifty-seven percent of El Salvadorean [336] and 16% of Haitian [337] children with corneal scarring typical of xerophthalmia claimed that their active disease had been accompanied by measles, and more malnourished hospitalized children with typical corneal ulceration and necrosis claimed recent measles than those without these corneal changes [338]. Following vitamin A fortification of sugar in Guatemala, most cases of corneal scarring (clinically XS) were associated

with measles [297]; when pure, dietary-induced vitamin A deficiency is milder and less prevalent, measles may assume a proportionately greater precipitating role.

Typically, measles is accompanied by conjunctival injection and photophobia from punctate keratopathy [339,340], related to viral multiplication in the affected epithelium [45]. The child frequently recovers, only to fall victim to postmeasles diarrhea, bronchopneumonia, and the like, followed by corneal destruction. In some instances the transition is more rapid: the parents becoming fearful when the child fails to open his eyes after subsidence of the acute disease. On the other hand, the course may be prolonged. Sweet and K'ang [155] traced a case of classical conjunctival xerosis and bilateral corneal ulceration to an episode of measles 3 months earlier. The measles had led to severe diarrhea, poor dietary intake, and weight loss. One month prior to admission the now severely malnourished child developed a chronic cough and finally, ocular disease. At autopsy, keratinizing metaplasia was present in a wide variety of epithelial-lined organs.

The propensity with which measles precipitates xerophthalmia can be explained, in large measure, by its devastating effect on health and nutrition, especially when these are precarious to begin with. Fever, by itself, increases protein breakdown in excess of synthesis, resulting in negative protein balance [341]. Even well nourished African children develop net negative protein balance with measles, and the situation must be far worse for children with kwashiorkor, whose baseline level of protein synthesis is subnormal to begin with (A. Tomkins, personal communication). In addition, measles induces a protein-loosing enteropathy [342]; in many areas of the world it is common practice to withhold food and fluid from children with measles [330,343,344]; severe measles is commonly accompanied by mouth ulcers, interfering with feeding [331,344,345] and by diarrhea, bronchopneumonia, sepsis, and anorexia that all take their toll [343–345]. It is hardly surprising that in some instances a quarter of affected children lose 10% of their body weight [344], or that measles is frequently cited as an important precipitating event in severe protein-energy malnutrition [289,344,345]. The combined metabolic effects of measles, fever, malnutrition, diarrhea, and other associated problems on vitamin A status are likely to be catastrophic, especially when vitamin A stores are limited to begin with. Voorhoeve [334] described the typical course in a Nigerian child: initial acute, measles-associated ocular discomfort resolved spontaneously, but measles-induced diarrhea persisted for four weeks, when the child presented as a "marasmic skeleton" with inferior perforations in both eyes.

An important, and as yet unresolved, question is the contribution xerophthalmia makes to the enormous problem of postmeasles blindness in Africa. Empirical observations suggest that it may be significant. In many parts of Africa measles is cited as the major cause of childhood blindness [310,343,346–353]. An area of Zambia in which it was particularly common, the Luapula Valley, achieved notoriety as "the valley of the blind" [354]. Most such children suffer a particularly virulent form of measles [310,340,345]. The genesis of this severe form is not entirely clear but appears to be related to the severity of existing protein-energy malnutrition [45,344,355,356], and most of the children who develop significant ocular complications are malnourished [45,331,332,334,340,345,348,356–358]. The problem is probably exaggerated by the fact that in Africa measles traditionally comes during the dry season, when food is scarce [359]. A similar situation has been reported among Haitians, who are primarily of African origin [360].

A vicious cycle is therefore established: malnutrition leading to more severe measles and severe measles causing a further deterioration of nutritional status. Children with underlying malnutrition are more likely to be vitamin A deficient, and interference with protein metabolism will prove catastrophic to those in borderline vitamin A balance. Oomen [333] observed classical cases of xerophthalmia following measles among reasonably well nourished African children with gastroenteritis, dehydration, or respiratory tract disease. Blindness was noted to be extremely prevalent in Luapula Valley communities in which Red Palm oil (an excellent source of pro-vitamin A carotenoids) was not consumed, but virtually absent from those in which it was [335].

Typical xerophthalmia, in the absence of precipitating measles, has been observed in most areas of Africa in which measles-associated blindness occurs [45,310,332,334,335,343,346,351,354,359,361–367]. Estimates that one-fourth to one-half the cases of corneal involvement are associated with measles [310,335,362,366,368] are consistent with our observations in Indonesia, and reports from El Salvador [336], Vietnam [309], Japan [313], and Jordan [248].

Clinical descriptions of postmeasles corneal destruction are similar to those for classical xerophthalmia [45,331,340,349,350,354,359,360,365,368], and the time course is the same as for documented postmeasles xerophthalmia. In a particularly informative case an African child with measles-associated kwashiorkor was fed a high-protein diet. Despite a general improvement in his condition, he suddenly developed classical xerophthalmic corneal melting [334]. Sauter [310] claims, unfortunately without suppor-

tive data, that administration of massive amounts of vitamin A prevented the expected development of ocular lesions in Tanzanian children with measles. Among Nigerian children hospitalized for severe measles, those with "keratomalacia" had lower serum vitamin A and albumin levels than those without keratomalacia [518].

A number of observers have concluded that measles-associated corneal destruction is merely an expression of underlying vitamin A deficiency [331–333,354,362,365], although it remains to be shown that this accounts for the majority of cases. The situation is further complicated by the common African practice of placing herbal medicines in eyes of children with active measles [344,359,368]. Neither chemical keratitis, nor secondary bacterial infection [343], however, is likely to account for a substantial proportion of cases of corneal dissolution [335,359].

Recent data suggest a possible role for ocular herpes simplex [340,345]. The virus was identified by culture or immunofluorescence in corneal scrapings from half the cases of measles-associated ocular ulceration studied, including those with deep stromal loss and total corneal necrosis. Many of these children had mouth ulcers as well, a large proportion of which were also positive for herpes. Typical herpetic corneal lesions have been observed in children with concomitant measles and malnutrition in Africa [45] and elsewhere [519]. The frequent bilaterality of the lesions suggests immune incompetence. Both malnutrition [369–372] and measles [373,374] impair the cell-mediated immune response, and herpes pneumonitis and hepatitis have been recorded in children with severe PEM (protein-energy malnutrition) and measles [375,376]. Although vitamin A deficiency is also said to affect immune status [377] there is little evidence for this in man.

The conclusion that vitamin A deficiency played little role in the herpetic cases of postmeasles corneal dissolution [340] may be correct, but is unsupported by the data. Serum (total) RBP levels in measles cases with ulcers was lower than in otherwise healthy well-nourished measles cases without such ulcers. The fact that RBP levels were even lower in a group of measles cases with more severe malnutrition but without corneal destruction is biased by the known, independent effect of severe malnutrition on RBP synthesis. Even so, the four lowest RBP levels were in children with corneal ulcers. Sandford-Smith's claim that half the cases with ulcers had "normal" RBP levels (>15 μg/ml) is questionable. In a series of classical corneal xerophthalmia cases unassociated with measles, from India, half had levels above this value [378]. We found the same to be true in Indonesia. More pertinent is Sandford-Smith's observation that the severity of corneal

ulceration was related to the severity of accompanying PEM. Herpetic infection may therefore be yet another manifestation of severe, underlying malnutrition. Its contribution to the development of measles-associated corneal dissolution, however, remains to be determined.

Interestingly, five cases of postmeasles corneal melting were observed in Leipzig, Germany, in a three-month period in 1955 (379). The authors could not explain its genesis. Although the children were generally very ill, the authors ruled out vitamin A deficiency by the absence of any significant clinical response to vitamin A therapy. But the vitamin A was administered as an oily injection, which is relatively ineffective, late in the course of corneal disease, when little viable corneal tissue may still have been present. One of the earliest reports of classical vitamin A deficiency (by dietary history) xerophthalmia was published from this same clinic exactly 40 years earlier [27].

Worm infestation

Ascariasis [380,381] can interfere with the absorption of vitamin A, reducing it in some instances by as much as 70% [382]. Roundworm infestation may therefore exaggerate the effects of borderline dietary intake, contributing to vitamin A deficiency and xerophthalmia.

The two conditions are commonly linked in the popular mind: Indonesian villagers refer to Bitot's spots as "worm feces" [383], and in our experience blame roundworm infestation for their presence. Although roundworms are found in a large proportion of xerophthalmic patients [41, 71,106,142], worm infestation is so prevalent in depressed communities that it is difficult to assess the significance of this observation in the absence of suitable controls.

In a cross-sectional survey in the Philippines, roundworms were no more common in cases of (mild) xerophthalmia than in the rest of the population (273), although in Jordan they were [296]: at least 43% of normals and 60% of abnormals harbored the parasite.

In Indonesia 30% of cases of Bitot's spots (Study III) and active corneal disease (Study II) of all degrees of severity claimed to have passed worms during the preceding 30 days. Twenty-four percent ($^{8}/_{33}$) of the matched corneal cases (Study II) and 18% ($^{6}/_{33}$) of their normal controls had a positive history, rates which are not significantly different from one another. *Ascaris* eggs (and frequently *Trichuris* eggs as well) were identified in stool samples from half the cases of active corneal disease. The rate among matched controls was similar, but as only one-third could produce samples

Table S-5. History of having shed worms (Study IV)

Age in years [2]	Positive history (%) [1]								
	Past week			Past month [3]			Ever		
	XIB	MC	N	XIB	MC	N	XIB	MC	N
1	12.0	0.0	2.5	32.0	0.0	7.9	68.0	20.8	23.7
2	5.7	3.1	3.0	25.7	23.4	11.6	51.4	[illegible].6	39.8
3	12.8	3.5	2.7	20.2	11.8	11.7	56.4	52.9	44.1
4	2.9	3.0	2.5	20.0	11.9	9.9	60.0	53.7	44.7
5	5.4	2.2	2.1	20.0	14.1	9.3	50.0	44.6	45.5
Unkn	0.0	0.0	1.0	16.7	0.0	5.5	66.7	83.3	32.6

1. Number at risk same as in Table S-2. Most recent episode listed.
2. Children (10) years old contained only 1 abnormal, 2 matched controls, both with negative histories. Overall positive rate for normals, 3%.
3. Including within past week.

Abnormals vs matched controls, $p = .02$ overall, $p = .01$ for difference in positive rates during past week.

during their brief clinic visit, and the production of samples might be related to the presence of worms, this comparison is potentially biased.

In the much larger, representative comparison afforded by the country-wide survey (Study IV), a history of shedding worms during the preceding 30 days was present in 22% of children with Bitot's spots, 14% of their matched controls, and 9% of all others, rates which are significantly different from one another ($p = .01$ for linear trend) (Table S-5). The case-control relative risk of Bitot's spots among individuals with and without a positive history for worms, however, is only 2.1, varying with age but not sex.

Although the beneficial effect of deworming on vitamin A absorption may last at least 2 months [384] reinfestation is extremely common [385].

Urinary tract disease

Urinary tract infections are reportedly common in xerophthalmic children [32,307]. In one series, 17% of severely malnourished children without xerophthalmia, but an astounding 78% with xerophthalmia had positive urine cultures [275]. The fact that few were symptomatic suggests that positive cultures represented bacterial colonization of the keratinizing surface of the genitourinary tract [40,155,164,167], similar to that of the xerotic conjunctiva, rather than true tissue invasive infection. Bacteriuria may be more a result than a cause of vitamin A deficiency and xerophthalmia. Indeed, Bloch discovered that urinary tract "infections" in xerophthalmic children disappeared with administration of vitamin A [176].

General health status

The impression exists that children with severe xerophthalmia are likely to be seriously ill, while those without corneal involvement are not [32,71], suggesting that isolated dietary deficiency rarely interferes sufficiently with vitamin A metabolism to provoke severe corneal disease [39,71]. This certainly appears to be true in Indonesia.

At the time of initial presentation, all 50 children in Study III (X1) and 141 of the 162 (87%) in Study II were examined and classified by the pediatrician according to their general clinical status: normal, or minimally, moderately (requiring bed rest), or severely (life-threateningly) ill (Table S-6). Only 6% of children with Bitot's spots vs. 58% with corneal disease were moderately or severely ill. Over half of all cases of corneal necrosis were severely ill. The severity of the general clinical condition clearly paralleled the severity of ocular involvement ($p < .01$ by linear trend).

Fifty-eight percent of matched corneal cases (Study II) were moderately or severely ill vs. none of their controls ($n = 33$ pairs, $p < .001$). Twenty-seven percent of the matched controls were minimally ill.

The absence of moderately to severely ill matched controls precludes formal calculation of the relative risk of corneal disease among children who were and were not moderately to severely ill, but it is clear that it must be very high, and the more severe the corneal involvement under question, the higher the risk. As an example, had one of the matched controls been moderately or severely ill, the risk of corneal disease (of any severity) among children moderately to severely ill would have been 43 times the risk of healthier children. Had there been two such matched controls the relative risk would have been 21:1.

Table S-6. General clinical condition of xerophthalmia cases (Studies II, III).

Ocular status	Total cases n	Severity of systemic illness (%)			
		None	Minimal	Moderate	Severe
X1	50	58	36	6	0
X2	48	44	19	21	17
X3A	46	30	9	46	15
X3B	47	9	15	23	53
X2-X3B	141	28	14	30	28

$p < .01$ for presence of illness, and presence of moderate plus severe illness, by linear trend.

9. Vitamin A intake, diet, and stores

> The European waste product—sweetened skimmed milk, was responsible for . . . blindness.
>
> J.H. De Haas, 1938

> Following the fall of Singapore keratomalacia virtually disappeared along with sweetened condensed milk and its propagandists.
>
> A.D. Williamson, et al., 1949

> It was difficult to get unskimmed milk unless one had a cow . . .
>
> C.E. Bloch, 1921

None of the factors that influence vitamin A status is more obvious, critical, or amenable to intervention than the amount of vitamin A consumed by the child. This should be sufficient for daily requirements and development and maintenance of adequate liver reserves. Such reserves are especially critical where availability of foods rich in vitamin A and provitamin A is seasonal—intake may virtually cease for months on end, with reserves representing the only source of vitamin A available to meet demands. Where liver stores are marginal, the individual is in a precarious state. Any interruption of exogenous supplies or increase in requirements (due to growth or disease) may precipitate clinically significant vitamin A deficiency and xerophthalmia.

Vitamin A sources potentially available to an individual are largely age dependent.

Prenatal period

The fetus depends on vitamin A that crosses the placenta from the maternal circulation. When the mother is well nourished, fetal supplies will be adequate and vitamin A supplementation of the mother will have no effect on the level in the cord blood [386–388] (which generally runs one-half to two-thirds that of maternal levels [386,387,389]). However, animal experiments suggest that some of the additional vitamin A may be stored in the fetal liver [386].

When the mother's own stores are inadequate the situation is quite dif-

ferent. Pregnancy itself is a stress, whether because of the demands of the fetus or hormonal alterations [390,391]. Maternal serum vitamin A levels may fall progressively [392,393], and even precipitate clinical disease [97–99,111]. In some cultures nightblindness is so prevalent that it is considered a normal accompaniment of pregnancy, much the same as morning sickness [99]. These milder manifestations often disappear spontaneously within a few days after delivery [99]. Vitamin A supplementation prevents this fall in vitamin A and the attendant xerophthalmia [386,387].

When the mother's vitamin A status is poor, fetal blood levels and stores will be depressed. If sufficiently severe, xerophthalmia may develop in utero. Maxwell [394] described a child born with bilateral keratomalacia, the diagnosis having been confirmed by Professor Pillat. One case in our own series was said to have been born with bilateral Bitot's spots. When first seen a month later, with keratomalacia, the mother was apparently healthy and free of clinical disease though her serum vitamin A level was only 13 μg/dl. Under these circumstances vitamin A supplementation of pregnant mothers can substantially raise serum vitamin A levels of the cord blood [392].

Because their livers are less developed, premature infants are at particularly high risk of early xerophthalmia.

Neonatal period

Even well-nourished children are born with limited vitamin A reserves [48,395–397] and require rapid introduction of exogenous sources of vitamin A. For those whose mothers were vitamin A deficient during pregnancy, the situation is even more critical.

In most cultures where xerophthalmia occurs, breast milk, or its equivalent, is the primary source of vitamin A for the first 6–12 months of life. If the quantity of milk consumed, or its retinol content, is low, the child may receive inadequate amounts of the vitamin. In the past this problem was particularly apparent among hand-reared infants [12,13,20,31,39,109,192]. Most had been fed milk from which the lipids, hence most of the Fat Soluble A, had already been removed (centrifuged, separated, or skimmed). Skimmed milk contains 0–10% of the vitamin A of fresh whole milk [48]. Even when fortified with vitamin A, as is now common, the milk is frequently overdiluted by the mother, often with contaminated water. Bloch [32] attributed much of the xerophthalmia epidemic in Denmark to the disappearance of whole milk from the market, and xerophthalmia

epidemics in both Singapore [41] and Indonesia [34,398,399] have been attributed to the substitution of sweetened condensed milk for breast feeding. Indeed, xerophthalmia is said to have disappeared from Germany during the First World War because mothers were rewarded for nursing their own children [400]. It is one of those ironies of nature that warfare was responsible for the disappearance of xerophthalmia in Germany and at least two other countries: interruption of vegetable oil imports (required to manufacture margarine) and dairy exports during World War I forced the Danish government to ration butter, guaranteeing minimal, if adequate amounts for everyone [32,39], and the invasion of Singapore during World War II interrupted production of sweetened condensed milk, fostering a return to the breast [41].

Breast feeding does not necessarily confer protection from xerophthalmia: sick and malnourished mothers may produce too little milk [409], sick and malnourished children may feed inadequately [39], and the milk of vitamin A deficient women may contain too little vitamin A. In 1891 Priestly Smith [401] warned his fellow members of the Ophthalmological Society of the United Kingdom to pay particular attention to the corneas of children whose mothers were prostrate with disease.

Xerophthalmia was rampant among both mothers and nurslings during the Russian Lent Quadragesima, when these women subsisted largely on potatoes, cabbage, and onion [20,402,403]. Both mother and child could be restored to health by feeding the mother cod liver oil [403]. Where seemingly adequately breast-fed children have developed xerophthalmia, the vitamin A content of the milk has been very low [34,404].

Except for colostrum, in which it is high, the vitamin A concentration of breast milk is roughly equivalent to that of the serum, and drops progressively with the duration of breast feeding [48,389]. Because their mothers' milk contained only 40% of the vitamin A concentration of well-nourished populations, Patwardhan [296] estimated that Jordanian children received, on the average, only 170 μg/day during the first 6 months of life. As the Russian experience suggests, supplementing mothers' diets with vitamin A can raise the concentration in the breast milk [389,392,405,406].

Although breast-fed children may become vitamin A deficient, on balance, breast feeding is likely to be superior to bottle feeding, and may confer significant protection against xerophthalmia. Blankhart [405] discovered that although xerophthalmic children consumed less beta-carotene than their normal peers, the difference in vitamin A intake by their mothers was even greater. This would suggest that in these young children vi-

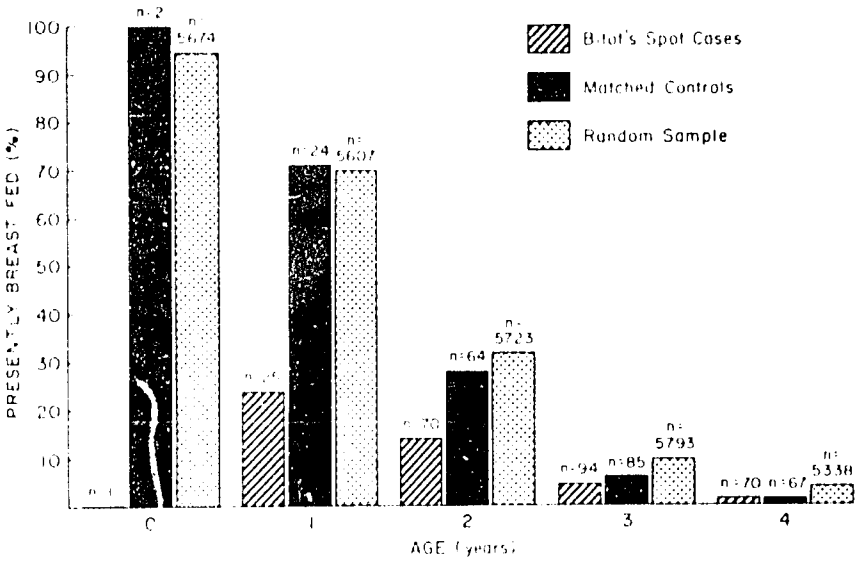

Fig. 9-1. Breast feeding was far less common among cases of Bitot's spots than among their matched controls or the random sample children ($p < .001$). Study IV. (Drawn from Tarwotjo et al. [67])

tamin A stores, acquired during fetal development and breast feeding, may have been, more important than current dietary intake. Similarly, Venkatachalam has attributed a lack of correlation between dietary intake and vitamin A status to existing liver stores [392]. McLaren [150] suspected that differences in birth spacing and duration of breast feeding accounted for the difference in xerophthalmia rates of two Indian tribal groups. The Indonesian countrywide survey (Study IV) provides direct confirmatory support for these suppositions [67].

Breast feeding was far more common among matched controls (and non-matched normals) than among cases of Bitot's spots ($p < .001$) (Fig. 9-1). Among one-year-olds, the youngest group in which there were significant numbers of cases, only 24% of abnormals but 71% of matched controls were being breast fed; among two-year-olds, the figures were 14% and 28% respectively. The (case-control) relative risk of Bitot's spots among children not currently being breast fed ranged from 8:1 at one year of age to 1:1 at age three (Table 9-1). During the second year of life (age 1) as much as 68% of the cases of Bitot's spots might be related to absence of breast feeding (attributable risk).

Table 9-1. Relative risk of Bitot's spots among children who are and are not breast fed (Study IV)

Age (years)	Relative risk[1] Method I bf:nbf[2]	Method II bf:nbf
1	8 : 1	7 : 1
2	2 : 1	3 : 1
3	1 : 1	2 : 1

1. Method I based on rates for abnormals and matched controls, method II on abnormals and all normals.
2. bf:nbf = breast fed:not breast fed.

The fall in relative (and attributable) risk with age follows the decline in the prevalence of breast feeding. Somewhat surprisingly, breast feeding appears capable of contributing a significant proportion of the vitamin A available to children during the third year of life (age 24–35 months), though this is likely to be more a reflection of earlier breast feeding practices and consequent accumulation of liver stores than current intake.

The association between breast feeding and xerophthalmia appears to be causal, rather than an indirect reflection of the relative health of the mother or child. The reason cited for discontinuing breast feeding among abnormals, matched controls, and the rest of the sample were essentially identical (Table 9-2). In the vast majority of instances the mother either thought it no longer necessary or had become pregnant. Both, of course, occurred earlier in the life of the abnormal child, as compared to the normal child.

Table 9-2. Reason breast feeding was discontinued (Study IV)

Reason cited	Clinical classification (n) XIB	MC	N	Clinical classification (%) XIB	MC	N
Mother pregnant	126	102	7653	38.3	35.8	35.0
Mother gave birth	15	13	656	4.6	4.6	3.0
Child sick	6	5	440	1.8	1.8	2.0
Child separated	2	1	233	0.6	0.4	1.1
Mother working	2	2	399	0.6	0.7	1.8
No milk	7	6	656	2.1	2.1	3.0
Not needed	171	156	11810	52.0	54.7	54.1
Total	329	285	21847	100.0	100.0	100.0

Among children still breast fed, the median frequency of feeding was the same in all groups — six/day, the maximum category listed on the form. There were no significant sex-specific differences in the prevalence of breast feeding, or age at which weaning began.

Weaning and early childhood

During and after the first year of life other sources of vitamin A become increasingly important. Classical methods of dietary assessment, which attempt to quantitate the exact amount of vitamin A consumed, are fraught with problems [35, 47–48, 407–411]. A simpler, potentially more reliable (if less precise) approach was adopted in the Indonesian work. Mothers were asked to estimate the frequency, in broad categories, with which the child consumed specific foods during the preceding two months.

Results of Study IV (countrywide survey) are extremely informative [67]. As already discussed, data entry problems precluded evaluation of dietary intake of matched controls, but their breast feeding practices, already presented, and family dietary patterns (Chap. 14) are so like those of other normals that a comparison between abnormals and the normal random sample seems justified.

The major difference, during the earliest years of life, was in the consumption of fruits rich in beta carotene (mango and papaya) (Table 9-3). Normals were more frequent consumers at every age, though a statistically significant difference was present only during the earliest ages, 1 and 2 years ($p = .62$ and $p = .03$ respectively). The earlier these fruits were introduced into the child's diet, the less likely the development of xerophthalmia. Among one-year-olds, only 36% of abnormals, but 67% of normals were consuming these fruits regularly (at least once a week). The rate among normals stays relatively constant through age five, while the rate among abnormals climbs progressively. The (case-control) risk of Bitot's spots among one-year-olds not consuming these fruits at least once a week was almost four times the rate among those who were.

The other major source of beta-carotene in the Indonesian diet, dark green leafy vegetables (dglv), was also consumed more frequently, at every age, by normals than abnormals. The difference became statistically significant ($p = .01$) only after the second year of life (Table 9-4). Interestingly, the chi-square value for the difference in consumption by abnormals and normals was greatest for ages three and five, exactly those at which the prevalence of Bitot's spots was also highest. By age four, over 70% of ab-

Table 9-3. Frequency of consumption of mango papaya during the two months preceding survey (Study IV)

Age (years)	Dx	Total n	Frequency of consumption (%)			
			≥ 1/day	≥ 1/week	≥ 1/month	< 1/month
0	XIB	1				
	NRS[1]	1034	33	22	7	37
1*	XIB	25	16	20	40	24
	NRS	1097	27	40	23	11
2*	XIB	70	16	46	26	12
	NRS	1017	28	40	26	6
3	XIB	94	16	44	35	5
	NRS	1064	26	41	26	6
4	XIB	70	29	36	20	15
	NRS	937	27	43	25	5
5	XIB	92	23	37	30	10
	NRS	997	26	43	26	5

*$p < .05$ by χ^2, XIB vs NRS.
1 "Normal random sample" (i.e. random sample less abnormal and matched controls).

From Tarwotjo et al. [67]

Table 9-4. Frequency of consumption of green leafy vegetables during the two months preceding survey (Study IV)

Age (years)	Dx	Total n	Frequency of consumption (%)			
			≥ 1/day	≥ 1/week	≥ 1/month	< 1/month
0	XIB	1				
	NRS[1]	1034	12	9	1	78
1	XIB	25	40	24	4	32
	NRS	1097	35	32	6	27
2*	XIB	70	23	43	16	19
	NRS	1017	43	41	6	10
3*	XIB	94	29	40	14	17
	NRS	1064	46	41	6	6
4*	XIB	70	40	33	10	17
	NRS	937	47	40	5	7
5*	XIB	92	36	33	13	18
	NRS	997	47	38	7	7

*$p < .01$ by χ^2, XIB vs NRS.
1 "Normal random sample" (i.e. random sample less abnormals and matched controls).

From Tarwotjo et al. [67]

normals and over 80% of normal children were consuming gly (green leafy vegetables) on a regular basis.

Differences in consumption of fruits appear to play an important role early in childhood, and consumption of gly later. The fact that a significant proportion of abnormals claimed to consume fruit and/or gly at least once a day is somewhat surprising. Aside from the obvious possibility of reporting error, this frequency may be too low, the quantity consumed in each feeding too small, the contribution of other vitamin and provitamin-A containing sources paramount, or other factors may have interfered with the utilization of ingested beta carotene.

The only vitamin-A-containing (as opposed to provitamin) food consumed significantly and consistently more frequently by normals than abnormals was eggs (Table 9-5). The difference, present at every age, only became statistically significant after the second year of life (like gly, but in contrast with fruits). In both normals and abnormals the proportion consuming eggs at least once a week remained relatively constant and small; one-third to one-half of the children never consumed them at all.

Only a tiny proportion of children consumed meat as often as once a week, and a statistically significant difference was present only among five-year-olds.

Table 9-5. Frequency of egg consumption during the two months preceding survey (Study IV)[a]

Age, years	Dx	Total n	Frequency of consumption (%) ≥1/day	≥1/week	≥1/month	<1/month
0	XIB	1				
	NRS	1034	2	10	6	83
1	XIB	25	8	16	20	56
	NRS	1097	8	30	21	42
2**	XIB	70	1	20	24	54
	NRS	1017	6	32	27	35
3*	XIB	94	2	26	28	45
	NRS	1064	6	35	26	33
4**	XIB	70	6	13	34	47
	NRS	937	4	36	30	30
5**	XIB	92	0	24	27	49
	NRS	997	5	35	27	33

*$p < .05$ by χ^2 XIB vs NRS **$p < .01$

From Lawson et al. [67]

Twice as many children consumed fresh fish as consumed meat on a regular basis. This was the only instance in which there was a sex-specific difference: males consumed fish more frequently than females. Only the difference in consumption between normal and abnormal five-year-old males, however, was statistically significant ($p < .01$).

The absence of a significant association between Bitot's spots and the consumption of meat and fish is consistent with the fact that fish flesh and meat are relatively poor sources of vitamin A, and support the validity of this survey technique. The absence of an association between consumption of these relatively expensive food items and the presence of xerophthalmia supports other evidence suggesting that differences in socioeconomic status play a relatively minor role, within the predominantly rural population of Indonesia, in the development of the disease.

The association between mild xerophthalmia and dietary practices in Study IV are mimicked by that of severe corneal disease and dietary practices in Study II [67]. In order to maximize the information from the limited pairwise comparisons available, and gain insight into the relative importance of "patterns" of food consumption for the development of severe xerophthalmia, an additional analysis was performed. Frequency of consumption was serially ordered on a scale of 1 to 6 (1 meaning equal to or greater than one per day, 6 meaning never), and the mean difference between the members of each pair (X2/X3 − MC) calculated (Table 9-6). Matched con-

Table 9-6. Mean difference in frequency of food consumption by pairwise comparison between corneal cases and matched controls[1] (Study II)

		Food item[2]							
		Liver	Meat	Eggs	Fish	Soy	GLV	Carrots	Fruit
$\bar{x}\Delta$[3]		+.032	+.358	+.617*	+.467*	+.042	+.842*	+.875**	+.217
Consuming n =									
1 week	X2/3	1	3	2	5	23	10	0	5
	MC	1	5	9*	6	27	18*	6*	9
1 month	X2/3	3	12	14	13	27	19	6	8
	MC	1	17	24**	17	29	27*	15*	11
Ever	X2/3	5	21	21	17	27	19	11	12
	MC	10	23	25	26**	29	27*	21**	14

*$p < .05$ **$p < .01$ for difference between X1B and MC.
1 n = 30 pairs, so 30 X2/3 and 30 MC for comparison.
2 Fish = fresh fish; GLV = green leafy vegetables; fruit = mango/papaya.
3 See text for method of calculation. X2/3 − MC: "+" indicates controls more frequent consumers than abnormals.

From Lumbantobing et al. [67]

trols were more frequent consumers, to varying degrees, of every food item listed. The greatest differences were in the consumption of "beta-carotene-rich" carrots and dark green leafy vegetables. A far larger proportion of children in both groups consumed glv than carrots (carrot consumption was not investigated in the countrywide survey). This association appears to be causal. The "case-control" relative risk of active corneal disease was inversely related to the frequency of glv consumption: those never consuming dark green leafy vegetables were at 3.7 times the risk of those consuming glv at least once a month but less than once a week, and at 7.3 times the risk of those consuming glv at least once a week.

A similar pattern existed for carrots.

Differences in fruit consumption were smaller than for the other major sources of beta-carotene, and, in this overall (age-pooled) comparison, not statistically significant.

Of the potential sources of preformed vitamin A, only the consumption of eggs and fish was significantly more frequent among normals than abnormals. As with glv and carrots, the association between egg consumption (a good source of vitamin A) and xerophthalmia was likely causal. The relative risk of disease decreased with increasing frequency of egg consumption: nonconsumers were at 2.3 times the risk of those eating eggs at least once a month but less than once a week, and at 8 times the risk of those consuming eggs at least once a week. By contrast, the relative risk among nonconsumers of fish did not vary in any consistent or meaningful way with the frequency of consumption in the comparison group, and is therefore compatible with findings in the countrywide survey. The difference between abnormals and controls in consumption of eggs and fish was smaller and less consistent than for glv.

Differences in the frequency of consumption of soy, a non-vitamin-A-containing food, and liver, rich in vitamin A, were insignificant. Soy was consumed by the vast majority of abnormals and matched controls, and liver by hardly anyone.

Differences in beta-carotene consumption revealed by the dietary data are confirmed by a comparison of serum carotene levels in children with and without xerophthalmia [67]. Serum carotene is a useful index of recent, regular intake, at least for comparing groups of individuals: children on a regular diet show little fluctuation during the course of the day (272), while total withdrawal of carotene from the diet results in a prompt, though gradual, decline in serum levels to half the initial value in roughly one to three weeks [90,299].

In a pairwise comparison between cases of active corneal disease and their matched controls (Study II), serum carotene levels were 11.6 ± 1.9 μg/dl (μ ± SE) higher among the controls (n = 15 pairs, p < .001). The same is true for milder xerophthalmia. Blood samples were not obtained in the countrywide survey, but in the longitudinal study (Study I, Round IV), serum carotene levels were 8.5 ± 1.2 μg/dl (μ ± SE) higher among controls than their matched cases of Bitot's spots (n = 110 pairs, p < .001).

Thus results of dietary and serum carotene analyses of Studies I, II, and IV are remarkably consistent: major differences exist in the consumption of vitamin A, particularly provitamin A-containing foods by normal children and those with mild (X1) and severe (X2/X3) xerophthalmia. Xerophthalmia has been associated with decreased carotene and/or vitamin A intake in studies from widely scattered points of the globe [183,273,277,412,413]. Methodologic problems or preexisting stores probably account for studies in which this association has not been found [134,414]. In older individuals xerophthalmia can almost always be traced to dietary restrictions or malabsorptive states [93,104,115,148,157,180].

Beta carotene containing foods are often the primary dietary sources of vitamin A in populations in which xerophthalmia regularly occurs

Table 9–7. Frequency of consumption of edible oils during the two months preceding survey (Study IV)

Age years	Dx	Total n	Frequency of consumption (%) ≥1/day	≥1/week	≥1/month	<1/month
0	X1B	4				
	NRS	1034	9	6	2	84
1	X1B	25	36	28	8	28
	NRS	1097	43	26	6	25
2	X1B	70	51	29	9	11
	NRS	1017	56	32	6	6
3*	X1B	94	47	31	13	10
	NRS	1064	56	31	6	6
4	X1B	70	53	33	7	-
	NRS	937	61	30	5	5
5	X1B	92	50	35	7	9
	NRS	997	62	28	6	4

*p < .05 by χ^2, X1B vs NRS

From Tarwotjo et al. [67].

[273,318,392–412,415,416]. Difference in consumption of red palm oil—an excellent source of beta-carotene—is said to explain the high prevalence of xerophthalmia in the north of Nigeria and its comparative absence from the south [333,362,367]—and it is the apparent reason why some villages in Zambia's Luapula Valley have a high prevalence of xerophthalmia and others do not [335].

Except for red palm oil, most vegetable oils are poor sources of provitamin A carotenoids, but a minimal level of oil intake apparently facilitates utilization of carotenoids present in other dietary constituents [417,418]. Perhaps because of the small amounts required, it has proved difficult to demonstrate an association between fat intake and xerophthalmia in field studies. The Indonesian countrywide survey (Study IV) revealed that children with Bitot's spots consumed edible oils less frequently, at every age, than normals, the greatest differences occurring at ages 3 ($p = .04$) and 5 ($p = .06$) (Table 9-7), the years of peak prevalence of Bitot's spots. No association was found in a recent study in the Philippines [273], but the number of abnormals on whom dietary data were collected was small.

IV Epidemiologic considerations

10. Clustering

"Drinkwater promised me tobacco in exchange for my daily egg. I want the tobacco and he can have the egg."

"There's no harm in that," Drinkwater blustered, "no harm in giving the boy some tobacco. He asked me for it. In exchange for an egg."

"You been up to Ward Six recently?" . . . "Did you help them admit Lyles? Your last batman? He's got no eyes now."

"That's not my fault. I didn't do anything about him."

"How many of his eggs did you have?"

James Clavell in *King Rat*

Differences in diet (Chap. 9) and exposure to precipitating and contributory diseases (Chap. 7–8) cause xerophthalmia cases to cluster within specific social and demographic strata, and often impart a seasonality to their occurrence. Although resulting patterns may vary from one area, and era, to another, some are practically universal. Foremost among them is age.

Age

Xerophthalmia can occur at any age. The youngest child enrolled in Study II was a boy (case 200/104) said to have been born with Bitot's spots, who presented at one month of age with complete corneal dissolution in one eye and a large ulcer in the other. Maxwell [394] reported a case with bilateral corneal destruction at birth.

The oldest encountered by project staff, before Study II formally began, was an otherwise well-nourished 24-year-old woman with severe corneal xerosis in both eyes [104]. Because of their poor diet and high rate of chronic debilitating disease (especially tuberculosis), army recruits, apprentices, students, and factory workers accounted for a significant proportion of the xerophthalmia cases in China during the first third of this century [155, 156]. Nightblindness was once common among sailors, especially when fish and fresh vegetables were scarce [74,75,77]. Minimally vitamin A nourished Russian women assiduously observing Lenten fasts were at high risk of xerophthalmia [8,402,403,419] as are pregnant women in India today [98,99,302,392,150]. But the temporary nature of the precipitating stress in both groups of women means that most will suffer only mild forms of the disease. Aside from these rather unusual circumstances, most adult

cases represent sporadic instances of bizarre dietary preferences (including alcoholism) [92,104,115,148,157,168,180,301,303] or deranged vitamin A metabolism (most commonly malabsorption) [11,93,94,148,300].

Most xerophthalmia, especially its severe, destructive form, is found in young children. In turn-of-the-century Europe, when the major problem was inadequate breast feeding, cases were usually emaciated and under one year of age [4, 9, 12, 192]. In the stable, chronic pattern that has evolved in developing communities the age distribution is broader, generally peaking at 2–4 years [14,15,18,20,31,41,42,68,160,161,273,274,296,337,421], although in some parts of India the prevalence of Bitot's spots (an unknown, but large proportion of which are inactive) continues to climb into early adulthood [183,422]. Even so, the younger the child with active disease, the more severe the xerophthalmia is likely to be [16,31,39,41,42,71,257,361,423,424].

This is well documented by the Indonesian data. Eighty-nine percent of individuals with active Bitot's spots, but only 22% with inactive spots who presented to the hospital in Bandung (Study III) were below the age of seven (preschoolers—refer to Fig. 3-5). The vast majority of active cases were two–four years of age. Although not necessarily representative of the situation at large, whatever bias present should inflate rather than minimize the contribution of older individuals: being more likely to notice their disease, they should also be more likely to seek medical attention.

The same pattern was observed in the more-representative countrywide survey (Study IV), which was restricted to children five years and younger. The prevalence of Bitot's spots plateaued at age three (Fig. 10-1). Not all Bitot's spots encountered among older children may have been active. The prevalence of nightblindness (by history) among cases of Bitot's spots fell precipitously between the ages of four and five, from 47.1% to 30.6% ($p < .05$). In addition, the proportion of cases in which the spots were present temporally as well as nasally also declined, from 23% at age four to 14% at age five (a difference which is not statistically significant).

In both studies (II and IV) cases of Bitot's spots were exceedingly rare during the first (and to a lesser degree, second) years of life.

The age distribution of active corneal cases was slightly younger, peaking, in both the hospital-based (Study II) and countrywide (Study IV) studies during the third year of life (age two) (compare Tables 6-10 and 10-1). As a result, the prevalence of corneal scarring peaked in the fourth year of life (Table 10-1). The younger the child, the more severe the disease; al-

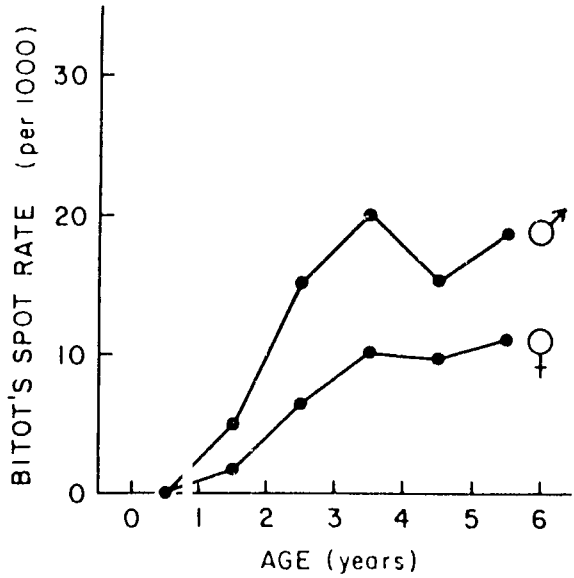

Fig. 10-1. The prevalence of Bitot's spots increased significantly ($p < .01$) at 1, 2, and 3 years of age. Bitot's spots were more common among boys (12.5/1000) than girls (7.2/1000) ($p < .001$). Denominators same as in Table 1-4, Study IV.

most half the cases of limbus-to-limbus corneal necrosis (categorie 7–8) in Study II occurred before age two (see Fig. 6-2).

Sex

Xerophthalmia is commonly believed to be more prevalent among males than females [35,43,47,48,71]. Attempts to attribute this to underlying physiologic differences have, to date, been largely unconvincing. Certainly cultural factors were responsible for the preponderance of affected soldiers in China and fasting women in Russia. On the other hand, boys regularly appear to be at greater risk of developing xerophthalmia, at least its mild variety, than girls, even allowing for the bias of hospital-based statistics (parents more often seeking help for male offspring) [155,338].

Males accounted for 58% of the cases of vitamin-A-responsive Bitot's spots presenting to Study III. In the more representative countrywide survey (Study IV) Bitot's spots were almost twice as prevalent among boys than among girls ($p < .001$) (Fig. 10-1). Interestingly, the age distribution

Table 10-1. Age distribution of corneal xerophthalmia (Study IV)

Age (years)	Active disease (X2/X3)		Old disease (X5)			
			At onset[1]		At present	
	n	(%)	*n*	(%)	*n*	(%)
0	1	(5)	10	(23)	0	(0)
1	3	(14)	9	(20)	3	(6)
2	9	(41)	14	(32)	6	(13)
3	6	(27)	9	(20)	14	(30)
4	2	(9)	2	(5)	14	(30)
5	1	(5)	0	(0)	10	(21)

1 Three, with unknown age of onset, excluded.

was similar in the two sexes, suggesting the importance of shared cultural factors. Although unlikely, the difference may be related in part to persistence of old, inactive lesions among the males; concomitant nasal and temporal involvement was more frequent among females than males with Bitot's spots (27.6% vs 18.2%, $p = .05$).

By contrast, the risk of corneal disease was independent of gender. Males accounted for only 53% of the cases of active corneal involvement (X2/X3) presenting to Study II (Table 10-2), while in the more representative countrywide survey, active corneal disease was actually more prevalent among females (7.1 vs 4.9 per 10,000). In neither study was the difference statistically significant. The prevalence of corneal scarring attributed to xe-

Table 10-2. Sex distribution of active corneal xerophthalmia (Study II)

Diagnostic classification (category)	Sex				Total
	Male		Female		
	n	(%)	*n*	(%)	*n*
1	12	(50)	12	(50)	24
2	12	(50)	12	(50)	24
3	4	(80)	1	(20)	5
4	22	(49)	23	(51)	45
5	4	(80)	1	(20)	5
6	18	(53)	16	(47)	34
7	8	(61)	5	(39)	13
8	6	(50)	6	(50)	12
Total	86	(53)	76	(47)	162

rophthalmia (XS) in Study IV was higher among males than females (16.2 vs 9.7 per 10,000 respectively), though the difference is not statistically significant and might reflect different mortality rates [338].

In general, these results are similar to those previously reported. Although males and females sometimes have equivalent rates of mild xerophthalmia [18,7,296], rates reported for males are often 1-2 to as much as 10 times those for females [69,71,160,161,256,273,274,361,413]. In some instances the differential increased with age [35,413,421].

The relationship between gender and corneal disease is commonly less pronounced. Although McLaren [361] reported the same male predominance, others have found that it largely disappears [71,160,256]. Xerophthalmia was no more frequent among males than females hospitalized with severe malnutrition in Bangladesh [275]. In Haiti, xerophthalmic scarring (XS) was more prevalent among girls than boys (2.8 vs 2.2 per 1000) [337].

Why boys should be at greater risk of mild xerophthalmia is unknown. The fact that this differential varies from one area to another, and disappears entirely in severe disease, strongly suggests that its genesis lies more in cultural factors than in any intrinsic physiologic difference between the sexes.

Location

Xerophthalmia is obviously more common in some areas than others. Regional variations in xerophthalmia prevalence (Table 10-3) [274,337] are explained by differences in wealth, availability of foods, dietary preferences, disease patterns, cultural practices, and the like. These same factors encourage geographic clustering at more local levels: within regions, within villages, within neighborhoods, and even within families.

At its most intimate level, clustering may be present within families. Many of the cases in Studies II/III were siblings of children who had presented with more severe disease a week or two before. Snell [19] observed an English family in which all 5 of the children, including a baby, were nightblind. Teng [116] found the prevalence of xerophthalmic retinopathy higher in members of families with an index case than in those without.

The risk of xerophthalmia is also greater among clinically normal children living in the immediate vicinity of an active case than among those living in the same village, but further away [100]. During the first round of the longitudinal study (Study I) serum vitamin A levels were determined in

Table 10–3. Regional prevalence of xerophthalmia in Indonesia (Study IV)

Zone	Families n	Children n	Bitot's spot n	Bitot's spot %	X2–X3 n	X2–X3 per 10,000	X8 n	X8 per 10,000
West Java								
rural	2759	4147	62	1.5	4	9.6	9	21.7
urban	309	499	10	2.0	–	0.0	1	20.0
Central Java								
rural	2952	4577	45	1.0	2	4.4	7	15.3
urban	1133	1812	26	1.4	–	0.0		0.0
East Java								
rural	2756	3949	31	0.8	–	0.0	–	0.0
urban	559	978	6	0.6	1	10.2	2	20.4
Sumatra								
rural	2393	4267	38	0.9	6	14.1	7	16.4
urban	711	1401	5	0.4	–	0.0	–	0.0
Sulawesi								
rural	2010	3378	17	0.5	1	2.7	4	11.8
urban	527	892	10	1.1	–	0.0	2	22.4
Composite (#6)								
Bali								
rural	774	1326	11	0.8	1	7.5	3	22.6
urban	293	507	3	0.6	–	0.0	–	0.0
Lombok								
rural	1405	2353	37	1.6	5	21.2	5	21.2
Kalimantan								
rural	1159	2056	15	0.7	1	4.9	2	9.7
urban	989	1856	14	0.8	–	0.0	3	16.2
Ambon								
rural	556	1031	21	2.0	–	0.0	2	19.4
Jakarta								
urban	405	686	5	0.7	–	0.0	–	0.0

three groups of children: abnormals (XN/X1); their normal age/sex/neighborhood-matched controls; and 83% of a preselected random subsample of all children enrolled in the study (10% were not at home and 7% refused to cooperate). As already indicated, serum vitamin A levels in the matched controls were higher than in the abnormals (see Table 2–2). But they were lower than in the random subsample ($p < .001$), predominantly composed of normal children living in neighborhoods (of the same village) free of active cases. "Correcting" the random sample mean, by removing all abnormals and controls, increases this difference; the "cor-

rected" mean is significantly higher than each of the three control groups individually ($p < .05$, $p < .01$). Results are unaffected by age-sex adjustment of the random sample to the controls.

Given the intimate nature of xerophthalmia clustering, it should also occur at the grosser village level. Such is the case. The sampling unit in the countrywide survey (Study IV) was a collection of two to four adjacent neighborhoods, one such site per village. We found that Bitot's spots clustered in villages (sample sites within each of the regions surveyed, $p < .05$, $p < .001$).

Because of the smaller number of cases of active corneal disease and scarring, village (sample site) level clustering could not be analyzed independently for each region. Such clustering was present, however, (X2, X3, and XS), each $p < .001$) for the sample as a whole.

Ten Doeschate [74] noted that most of her cases in Surabaya came from particularly xerophthalmia-prone regions of the city. Awdry [335] recognized marked variation in the prevalence of xerophthalmia within the "valley of the blind," which he related to village-specific patterns of red palm oil consumption.

Socioeconomic status

Traditionally, xerophthalmia cases arise almost exclusively from the most disadvantaged strata of society [6,32,39,75,155,156,274,296]. They invariably fill public rather than private wards [149,336]. This association is largely explained by feeding practices, but feeding practices are influenced by factors other than simple purchasing power. Mori [48] credited the decline in Hikan to an increase in general socioeconomic status. But Williamson [41] concluded that increased purchasing power and greater opportunities for employment among women led to abandonment of breast feeding, culminating in the xerophthalmia epidemic that swept Singapore. In Cebu, the Philippines, vitamin A deficiency is more closely associated with maternal employment than with income [273]. Impoverished cassava-consuming children, forced to eat the leaves of the plant, may be at lower risk of xerophthalmia than their otherwise better-off rice-consuming peers [277]. Xerophthalmia prevalence in West Java is higher than in East Java (Table 10.3), exactly the reverse of per capita income. We have already mentioned the child who suffered from nightblindness after "watching too much television."

Nevertheless, a restricted choice of foods (especially of palatable sources

of the preformed vitamin—poorer hygiene standards, and more limited education ensures that children of lower class families will generally be at higher risk of vitamin A deficiency [115], and that their mothers will have lower levels of vitamin A in their blood [392] and breast milk [425]. Most studies compare the extremes of socioeconomic status (SES). The association between xerophthalmia and SES is more pertinent—but less easily documented—within that 80–90% of the predominantly rural, broadly depressed population from which xerophthalmia cases arise.

Twelve variables were analyzed in the Indonesian countrywide survey (Study IV). Six might be thought of as primarily economic in nature (though they have social behavioral implications as well): composition of the walls of the house, source of lighting, source of drinking water, principal bathing facility, principal occupation of the head of the household, and frequency of meat consumption by the family. Six might be thought of as primarily social or demographic: number of people living in the house, number of children less than six years of age in the house, highest education of the head of the household, person primarily caring for the child, number of live births to the child's mother, and death rate among those live births. Data were available for the 358 cases of Bitot's spots, their 340 age-sex-neighborhood-matched controls, and 34,576 "normals" (the rest, all normals less the 340 matched controls). Because normals are not matched by neighborhood with the others, some differences could conceivably represent neighborhood clustering of cultural attributes quite apart from any influence on xerophthalmia risk. In only 1 of 12 variables, however (composition of the walls of the house), was the difference between "controls" and "normals" statistically significant. That is precisely the variable expected to show the most village/regional-level variation.

By almost every parameter there was a distinct gradation in socioeconomic status, being lowest for families of the abnormals and highest for those of the normals. For three of the economic variables one or more facets of the difference between abnormals and matched controls were statistically significant: principal bathing facility ($p < .05$); principal occupation of the head of the household ($p < .001$); and frequency of meat consumption ($p < .05$). Statistically significant differences were also present for three of the social/demographic variables: number of people living in the house ($p < .02$); highest education of the head of the household ($p < .05$), and mortality among live births to the child's mother (16.2% of siblings of abnormals, 13.2% of those of matched controls, and 11.8% of those of normals, $p < .001$ by linear trend). For only two variables were the responses

of all three groups similar: the number of children less than six years of age who lived in the household, and the person primarily responsible for the child's care (mothers accounted for 95% of the total in all three groups).

Seasonality

The vitamin A status of children at risk of xerophthalmia is largely determined by their general nutritional status, consumption of provitamin-A-containing foods, and the presence or absence of systemic infections. Significant seasonal fluctuations in any or all of these factors may result in seasonal variations in xerophthalmia incidence. The magnitude and pattern of the effect will depend on the relative importance of each factor, and the magnitude and timing of its fluctuation in relationship to that of the others. When several coincide, the effect is likely to be pronounced.

In many areas of the world, particularly the East, xerophthalmia reaches a peak during the hot dry months, precisely when green leafy vegetables are most scarce and diarrhea most prevalent [70,71,257,338,426]. Such a pattern exists in Indonesia [71], and was observed for corneal cases presenting to Study II. The pattern was independent of the severity of corneal involvement, as confirmed by the smaller (but unbiased) number of corneal cases detected in the longitudinal field study (Study I). The number of cases presenting during the "high season," March through August, was significantly greater than during the rest of the year ($p < .001$). The sharp decline in September–October ($p < .02$) immediately follows Lebaran, the feasting period terminating the fasting month of Eid. It is tempting to speculate that food consumed by children and lactating mothers during Lebaran accounted for the prolonged drop in xerophthalmia incidence that followed. On the other hand, the rate of disease also declined sharply in Denmark during June; Blegvad [39] attributed this decline to an increase in the vitamin A content of cow's milk consequent to the shift from stall (winter) to pasture (summer) feeding, while Bloch ascribed it [32] to a falling off of the childrens' spring growth spurt. Similarly, for reasons that are poorly understood, there was also a sharp July decline in xerophthalmia incidence in the predominantly Hindu village in Bengal studied by Sinha and Bang [426].

Sweet and K'ang [155] identified two peaks in China: January–March, when green leafy vegetables were least available, and July, when diarrhea was most prevalent. Mori [18] attributed the summer peak of Hikan to diarrhea. Of course the spring peak in 19th century Russia was related to the Lenten fasts.

11. Magnitude and distribution

> . . . Diseases due to deficiency of vitamin A are perhaps the most common of all in the Colonial Empire. There are reports from a wide selection of territories of affections of the eye—nightblindness, xerophthalmia, keratomalacia . . .
>
> Report on Nutrition in the Colonial Empire, 1939

Any discussion of the magnitude and distribution of xerophthalmia requires careful attention to the manner in which it has been defined (e.g. vitamin A "deficiency," corneal destruction, etc.), criteria for a "problem" established, and data collected. For obvious reasons the simplest techniques have been those most widely employed.

By assembling available data on food production, dietary practices, and hospital and clinic experience from large numbers of countries, Oomen, McLaren, and Escapini [427] were able to identify those likely to have a significant xerophthalmia problem. Although of immense value, such analyses are invariably biased by the quantity, quality, and distribution of data available, and cannot be quantified [59,152].

Properly conducted xerophthalmia prevalence surveys suffer neither of these limitations [152] and consequently have become increasingly popular [273,274,336,337,429]. They provide accurate data on the proportion of individuals affected at the time they are examined. But as some subjects will subsequently get better, some get worse, and some die, to be replaced by disease in other, previously normal individuals, these surveys shed little light on the numbers involved over time. Such data require carefully executed prospective longitudinal field studies in which the same children are reexamined at frequent intervals, and the incidence, or number of new cases occurring over a defined period (e.g. 1 year), is calculated. Study I was just such an investigation [430].

As already detailed, roughly 4000 preschool-age children were regularly reexamined at frequent intervals and only those with active corneal disease treated. Even so, *observed* incidence was probably significantly below *true* incidence: children were reexamined only once every two to four months; hence those who developed disease and either recovered spontaneously (from nonscarring xerophthalmia) or died between examinations went unrecognized. Furthermore, the mere presence of the survey team, treatment, and hospitalization of all early corneal cases, and referral of ill and

severely malnourished children to local hospitals and dispensaries must certainly have reduced the incidence and severity of xerophthalmia in the study population.

Incidence of active corneal disease (X2/X3)

Annual incidence is based on the 12-month period encompassed by Rounds 2 through 5 (July 1977 through June 1978), thus eliminating seasonal influence (Table 11-1). The first round provided the baseline population of corneal xerophthalmia-free children. Two estimates are calculated. For the first (almost 6 per 1000 (CI_{95}: 3.0–8.6 per 1000), the denominator employs a strict definition of "at risk" children: the average number examined in each of the four rounds who had also been examined (and found free of corneal disease) in the immediately preceding round. For the second, and lower rate (3.5 per 1000 (CI_{95}: 1.8–5.2 per 1000), the denominator is the average number of children enrolled in the study (hence eligible for examination) during each of the four rounds, whether or not they were ever examined. The actual rate probably lies somewhere in between. The first

Table 11-1. Annual incidence of active corneal xerophthalmia (X2/X3) (Study 1, Rounds 2–5)

		Method I		Method II	
Village	No. of cases	Mean no. examined	Annual incidence per 1000	Mean no. eligible for exam	Annual incidence per 1000
Cilalang	2	900	2.2	1445	1.4
Cikao	1	202	5.0	283	3.5
Cilegong	1	239	4.2	357	2.8
Kembang	1	187	5.3	276	3.6
Gandasoli	8	793	10.1	1146	7.0
Citeko	3	453	6.6	1088	2.8
Total	16	2773	5.8	4595	3.5
CI_{95}			3.0–8.6		1.8–5.2

Method I: Denominator is number of children examined at each round who were also examined, and found to be free of corneal disease, during the preceding round, averaged over the 4 rounds (numbers 2–5) constituting a complete annual cycle. See text.

Method II: Denominator is average number of children eligible for examination at each of the 4 rounds, whether or not they were ever examined. See text.

From Sommer et al. [430]

(and higher) rate assumes children not examined had the same rate of disease as those who were. This is a standard assumption but probably leads to some degree of overestimate; whereas all the cases of active corneal disease discovered in each round had also been examined in the previous round, not all children free of corneal disease had been. The second (and lower) rate, which assumes all children not examined were free of disease, is certainly an underestimate. A conservative approach is to assume that the actual rate lies between the two, and is closer to the higher than the lower. Subtracting one-third of the difference between them from the higher rate yields an overall, conservative estimate of 5.0 per 1000 per year (CI_{95}: 2.6–7.5 per 1000). At this rate, 3% (1.6–4.5%) of children born into the study area would develop corneal xerophthalmia (X2/X3) before reaching their sixth birthday (0.5% × 6 years at risk).

Although strictly comparable data are not available from any other country or area, results of a small village study in West Bengal, India, suggest a problem of similar magnitude. Among 312 children followed for 18 months [426], 4 developed signs of "progressing xerophthalmia" requiring immediate therapy [141]. Assuming that this alludes to active corneal involvement (Bitot's spots and nightblindness were not treated), the annual incidence would be roughly 8 per 1000.

Incidence and spontaneous cure rates

Essentially all cases of noncorneal xerophthalmia in Study I represent active, clinically significant vitamin A deficiency, as already discussed. Incidence and spontaneous cure rates (Table 11-2) are based on the "strict" definition of "at risk": only children examined in both the round under discussion as well as the immediately preceding round are included in the calculation.

The incidence of noncorneal xerophthalmia ranged from 1.7 to 2.7 per 100 for each of the 2–4 month intervals between examinations, a cumulative annual rate (for the 12-month period encompassed by Rounds 2 through 5) of 9%. Data from a previous study in North Central Java (Reedy, 510) suggested an annual incidence of 8.2%. Spontaneous cure rates between the rounds ranged from 43 to 59%. If each of the children who developed xerophthalmia had never had it before (i.e. once cured of the disease they never got it again), half of all children born into the study area would develop noncorneal xerophthalmia before reaching their sixth

Table 11-2. Prevalence, incidence, and spontaneous cure rates for nonconneal xerophthalmia (Study 1)

Clinical round	Prevalence %	Incidence %	Spontaneous cure (%)
1	7.4	N.A.	N.A.
2	5.7	2.7	53.2
3	4.8	2.2	47.8
4	4.1	1.7	47.0
5	4.3	2.2	43.1
6	3.9	1.8	52.4
7	3.8	2.3	58.6

Nonconneal xerophthalmia includes cases of XIB (Bitot's spots with conjunctival xerosis) and/or XN (a history of nightblindness). Average interval between clinical rounds was 3 months. (Preliminary hand tabulated data.)

birthday (9% ÷ 6 years at risk). In fact, roughly one-third of the cases had had it before, and the risk of an initial episode of clinical xerophthalmia was probably closer to 36%. In an earlier study, 27% of preschool-age children of low income employees of a Nutrition Research Centre in West Java developed nightblindness (accompanied by Bitot's spots in half) during the three years they were followed [105].

In the Indian study already alluded to [141], almost 9% of 125 initially normal preschool-age children developed Bitot's spots over a nine-month period (an annual rate of roughly 12%). The rate among matched vitamin A recipients was less than 1%, indicating that the majority of lesions represented active, clinically significant vitamin A dificiency. Although spontaneous cure rates were not calculated, fluctuations in prevalence (falling, at one point, from 20 to 7%), suggest that it was appreciable. Mori [18] noted that in many cases mild (XI, XN) xerophthalmia ("Hikan") disappeared spontaneously, reappearing during the "dangerous months" of the following year.

Countrywide rates and numbers of cases

In general, incidence rates are generated on small, relatively selected populations, as in Study 1. If spontaneous cure rates and differential mortality (between children with and without xerophthalmia) in the population at large is the same as that in the special study area (a not unreasonable assumption when the intensity of disease is similar), the incidence rate in the

Table 11-3. Xerophthalmia prevalence in rural Indonesia (Study IV)

Zone	X1B (per 100)		X2/X3 (per 10,000)		X8 (per 10,000)	
	P	$CI_{95\%}$	*P*	$CI_{95\%}$	*P*	$CI_{95\%}$
W. Java	1.5	0.9–2.1	10	0–21	22	8–36
C. Java	1.0	0.6–1.4	4	0–10	15	2–28
E. Java	0.8	0.4–1.1	0		0	
Bali	0.8	0.2–1.5	8	0–23	23	0–48
Lombok	1.6	0.8–2.3	21	3–39	21	3–39
Sumatra	0.9	0.5–1.3	14	4–24	16	4–28
Sulawesi	0.5	0.2–0.8	3	9–9	12	2–22
Kalimantan	0.7	0.2–1.2	5	0–15	10	0–24
Ambon	2.0	0.3–3.7	0		19	0–47
Indonesia (weighted)	1.0	0.9–1.1	6	3–10	13	9–18

From Sommer et al. [430].

population at large will be related to that of the special study area in rough proportion to the prevalence rates in the two areas [74]. This is especially true for *active* corneal disease (X2/X3), a transient condition not expected to accumulate in the population to any significant extent.

The average (weighted) prevalence of active corneal disease (X2/X3) in the rural population of Indonesia was 6.4/10,000 ($CI_{95\%}$: 3.2–9.6 per 10,000) (Table 11-3), 53% of the average prevalence in Study I (Table 11-4).[a] With a (conservative) incidence of active corneal disease in Study I of 5 per 1000 per year, the annual incidence for rural Indonesia as a whole would be 2.7 per 1000. As a *rough estimate*, 63,000 Indonesian children develop new, active, corneal xerophthalmia (X2/X3) every year (Table 11-5) [430]. This is a minimal figure; our own hospital and clinic data and those of others

[a] Average prevalence during the four incidence generating Rounds (2–5) in Study I was calculated by dividing the number of children with active corneal disease by the number of examinations performed, the technique available to Study IV. Since all such abnormals were treated and removed from the study, the numerator used for calculating incidence and prevalence are the same. Had the denominator been chosen the same way, the average prevalence during the four clinical rounds would have exactly equaled one fourth of one or the other incidence rate instead of falling between them. Removal of active cases prevents their accumulation in the population, artificially lowering observed prevalence in Study I. Since cases of active corneal disease do not ordinarily linger for very long, the potential error is likely to be small. Indeed, only four cases of active corneal disease were encountered during the first clinical round, essentially the same prevalence as in each of the four succeeding rounds from which incidence was determined.

Table 11-4. Average prevalence of active corneal disease (X2/X3) in special study area (Study I: Rounds 2–5)

Village	Cases (n)	Examinations (n)	Prevalence (per 10,000)
Citalang	2	4260	4.7
Cikao	1	929	10.8
Ciregong	1	1124	8.9
Kembang	1	883	11.3
Candasoli	8	3701	21.6
Citeko	3	2438	12.3
Total	16	13,335	12.0

From Sommer et al. [430]

[70,71] suggest that the countrywide prevalence survey was carried out during the period of lowest prevalence; and it excludes those who are 6 years and older as well as urban children (among whom slum dwellers, at least, were found to be at risk of disease).

For reasons discussed at greater length in Chapter 14, it was more difficult to elicit a history of nightblindness from many of the (linguistically and culturally diverse) communities encountered in Study IV than it had been in the relatively uniform, Sundanese population of Study I. It is therefore more appropriate to extrapolate the incidence of noncorneal xerophthalmia (XN plus Bitot's spots) from Study I to Study IV according to the relative

Table 11-5. Estimated number of active corneal xerophthalmia cases annually in rural Indonesia

Prevalence of X2/X3 (Study IV) / Prevalence of X2/X3 (Study I)	×	Annual incidence of X2/X3 (Study I)	=	Annual incidence in population at large
6.4 / 12.0		5.0/1000/year		2.7/1000/year

Annual incidence	×	Proportion of population under age 6	×	Proportion of population that is rural	×	Total population of Indonesia	=	No. of new corneal cases in rural areas each year
2.7/1000	×	0.20		0.85	×	(138×10^6)	=	63,342

From Sommer et al. [430].

prevalence of Bitot's spots alone (a more objective criterion than night blindness). Approximately 40% (see Table 2-1) of cases of noncorneal xerophthalmia encountered in Study 1 had Bitot's spots, an average prevalence for the four incidence-generating rounds of roughly 1.9% (see Table 11-2). The average (weighted) prevalence among rural preschool-age Indonesian children was 1% (see Table 11-3). 53% of this figure, exactly the ratio for active corneal disease. Since the annual incidence of primary attacks of noncorneal xerophthalmia (XN plus XIB) in Study 1 was 6 per 100, the countrywide incidence would be 3.2 per 100. At this rate, roughly 840,000 preschool-age rural Indonesian children would develop a primary episode of noncorneal xerophthalmia every year, and almost 20% of all Indonesian children develop the disease before reaching their sixth birthday [430].

Validity of WHO prevalence criteria

Even in the absence of incidence data, prevalence rates provide an unbiased estimate of levels of disease for comparison with other areas or with outside reference standards.

In some relatively small countries like El Salvador [429], prevalence may be relatively uniform, while in others like Haiti [337], it may vary widely. In countries as large and diverse as Indonesia, it will almost certainly be higher in some areas than others (compare Tables 10-3, 11-6).

In the Indonesian study, sample size was chosen [431] to detect prevalence rates of X1 and XS on a regional basis when they reached levels constituting a significant public health problem (Table 11-7) [47, 152]. With rates of this order of magnitude (see Table 10-3), little can be made of apparent variations between intrazonal subdivisions in Indonesia. As an obvious example, with an expected rate of active corneal disease of 1 per 10,000, one such case may be encountered among 5000 examined, as in Sulawesi. The fact that this single case came from South Sulawesi (Table 11-6) does not mean there is more disease in S. Sulawesi than in the other provinces of Sulawesi. On the other hand, extraordinary levels of disease may be detectable because sample size, though small, is adequate for the prevalence rates achieved (often in all three clinical parameters, as in Lombok, Aceh, etc.).

As a guide to health planners, prevalence rates of active corneal disease (X2 X3), healed destruction (XS), and Bitot's spots (XIB) exceeding certain

Table 11–6. Intrazonal rural prevalence (Study IV) provincial rates for Sumatra, Sulawesi and Kalimantan

Zone	Children n	Bitot's spot n	Bitot's spot %	X2–X3 n	X2–X3 per 10,000	XS n	XS per 10,000
Sumatra							
Aceh	620	15	2.4	3	48.4	1	16.1
Bengkulu	460	3	0.7	1	21.7	1	21.7
W. Sumatra	611	8	1.3	1	16.4	1	16.4
S. Sumatra	606	2	0.3	1	16.5	3	49.5
N. Sumatra	463	2	0.4	–	0.0	1	21.6
Jambi	550	5	0.9	–	0.0	–	0.0
Riau	467	2	0.4	–	0.0	–	0.0
Lampung	490	1	0.2	–	0.0	–	0.0
Sulawesi							
S. Sulawesi	1240	5	0.4	1	8.1	1	8.1
S.E. Sulawesi	809	4	0.5	–	0.0	3	3.7
C. Sulawesi	477	5	1.0	–	0.0	–	0.0
N. Sulawesi	852	3	0.4	–	0.0	–	0.0
Kalimantan							
C. Kalimantan	450	3	0.7	1	22.2	–	0.0
W. Kalimantan	460	2	0.4	–	0.0	1	21.7
S. Kalimantan	680	10	1.5	–	0.0	1	14.7
E. Kalimantan	466	0	0.0	–	0.0	–	0.0

arbitrary levels were said to reflect a xerophthalmia problem of public health magnitude (Table 11–7) [47]. One point purposely left undefined was the overall population or region that these criteria were to encompass. A high rate in, say, Aceh, and very low rate elsewhere in Sumatra might or might not appear to be significant: it all depends on whether the overall "population" is limited to Aceh or includes all of Sumatra. Common sense suggests that regardless of the size of an area or population, if it is found to have a high rate of disease it has a significant problem, whether or not it is part of a larger, low-rate region. Of greater concern is that limitations in size or distribution of the sample may cause high-risk areas to go undetected. These criteria represent rough guidelines, not absolute figures. The risk of disease is likely to be just as high in areas in which the rate of Bitot's spots is just below 2% as in those in which it is just above, even if the confidence limits do not overlap. Unfortunately, this point is frequently overlooked [274].

Table 11–7. WHO criteria for a xerophthalmia problem of public health magnitude (WHO, 1976) [47]

Clinical	*Prevalence Rate*
X1B	>2/100
X2 + X3A + X3B	>1/10,000
XS	>1/1000
Biochemical	
Vitamin A < 10 μg/dl	>5/100

Of the 3 clinical criteria that define a significant public health problem, the rate of *active* corneal involvement is the most important: it represents the severe, potentially blinding form of disease that is the raison d'etre of most intervention programs, and diagnosis is more reliable than for healed corneal destruction (XS). But the speed with which active corneal disease resolves, either in cure, death, or scarring, ensures that its prevalence will never be high, requiring a large sample for precise estimation.

Corneal scars, because they accumulate in the population, should achieve a higher prevalence. The WHO criteria suggest an expected ratio of active (X2/X3) to old (XS) disease of 1:10. A perusal of Tables 10-3 and 11-6 indicates that in Indonesia, at least, the ratio is more commonly 1:2, perhaps because of a higher than expected mortality (a point which will be discussed at greater length in Chap. 12). The ratio of XS to active corneal disease recorded in other countries has been similarly low: 3:1 (XS:X3) to 1:2 (XS:X2) in Bangladesh [432], roughly 1:1 (XS:X2) in the Philippines [273], and 1:1 (XS:X2/X3) in Jordan [296].

The least valuable of the clinical criteria is Bitot's spots (X1B). Although these generally have the advantage of easier recognition and higher prevalence, they are removed from the blinding end of the spectrum. The relationship between the prevalence of Bitot's spots and corneal disease is highly variable: in some areas, like India, Bitot's spots are extremely common while in others, like Haiti, they are exceedingly rare [337] even though the rates of corneal disease in these areas may be similar. With what we now know of the two conditions, this is hardly surprising: widespread mild, chronic vitamin A deficiency will result in a high prevalence of Bitot's spots, however more focal, severe, and especially rapid deterioration of vitamin A status, or severe protein deficiency, can result in low rates of Bitot's spots but a high prevalence of corneal disease.

Table 11–8. Prevalence of Bitot's spots and fulfillment of (WHO) corneal criteria for a public health problem (Study IV)[1]

A. 34 Domains[2]

Rate of XIB (%)		Domains positive for corneal criteria	
Group	*Mean*	*n*	*Probability*
≥2.0	2.6	2/2	1.00
1.5–1.9	1.7	4/6	0.67
1.0–1.4	1.2	4/6	0.67
0.5–0.9	0.7	3/7	0.43
0.0–0.4	0.2	5/13	0.38

B. Regression analysis[3]

Rate of XIB (per 100)	0.0	0.5	1.0	1.5	2.0
Probability site positive for corneal criteria	0.29	0.43	0.56	0.69	0.82

1. X2X3 = (10,000/XS) × (1000/WHO, 47).
2. Sample size: mean ± SD = 658 ± 186.
3. Least-squares applied to Domain data.

When the WHO criteria were established it was assumed, for lack of appropriate data, that a rate for Bitot's spots of 2% would correspond to levels of disease that just met the corneal criteria. The Indonesian data suggest otherwise. In Table 11-8, 34 intrazonal domains are grouped by their prevalence of Bitot's spots, and the proportion is determined in which one or both corneal criteria were exceeded. Despite the fact that the sample sizes were small (658 ± 186), linear regression suggests that over 40% of those areas with a rate for Bitot's spot of 0.5% will meet one or both corneal criteria for a significant public health problem. Among larger-sized samples (three islands of sample size 1570 ± 694, and six regions of 3129 ± 911 respectively) a rate of Bitot's spots in excess of 0.5% was almost invariably accompanied by rates of corneal disease that surpassed criteria for a public health problem.

Obviously for some places, like Indonesia, a cutoff for Bitot's spots of 2% is far too high, significant levels of corneal disease commonly occur at lower rates. Even in areas like India, where a substantial proportion of Bitot's spots are no longer associated with active vitamin A deficiency, a rate of 0.5% may be more appropriate than one of 2%. In a study near Hyderabad [124], the ratio of Bitot's spots to XS varied (by age) from 3:1 to 10:1, suggesting a critical rate for Bitot's spots of 0.3–1%; in a study in North India [183], the ratio between Bitot's spots and active corneal disease

X2 X3 among preschoolers was 5/10,1, suggesting a critical rate of 0.1%. In Bangladesh [432] a rate for Bitot's spots of 0.7% was associated with a prevalence of X2 40 times, X3 six times, and XS almost twice the WHO criteria; in the Philippines [273] the ratio between Bitot's spots and XS was 6:1 and between Bitot's spots and X2 3:1, suggesting a critical rate of 0.5% or less. In Jordan [290] a prevalence of Bitot's spots of 0.6% was associated with a rate of XS twice, and X2 X3 20 times the WHO criteria. Although there is no reason why the ratio of Bitot's spots to active or healed corneal disease should be the same in all situations, it is clear that if the prevalence of Bitot's spots is to be used as an index of potentially serious levels of xerophthalmia, a rate considerably below 1% should be employed.[a]

As we have already seen, mean levels of serum vitamin A correlate well with the presence and severity of clinical xerophthalmia. But individual readings are widely scattered, with considerable overlap between clinically normal children living in areas where xerophthalmia occurs and those with clinical, but noncorneal involvement (refer to Table 2-2). The most that can be said is that clinical xerophthalmia is uncommon above 20 μg/dl (recognizing the considerable variation that exists in results of different laboratories, especially under field conditions), and becomes increasingly frequent below. Active corneal involvement occurs, for the most part, below 15 μg/dl (see Table 6-6). There is likely to be a prevalence of very low levels above which corneal disease should reach significant proportions. The WHO criteria assume that this occurs when serum levels of less than 10 μg/dl are present in 5% or more of the children. Data from Round 1, Study 1, suggest that this is a reasonable assumption: 9% or more of all children sampled had levels below 10 μg/dl (see Table 2-2), while the prevalence of Bitot's spots was 0.8%. In Cebu, the Philippines [273], 17% of the children had serum vitamin A levels below 10 μg/dl, while 1.7% had Bitot's spots, 5/1000 X2, and 3/1000 XS, essentially equivalent results.

Worldwide distribution of the problem

Aside from unusual cases secondary to liver disease, intestinal disease, cystic fibrosis, eccentric diets, and the like, which can occur anywhere in the world, the disease is overwhelmingly located in developing countries. On the basis of available data, most often anecdotal reports; brief "expert vis-

[a] This conclusion is reflected in the 1981 revision of the WHO prevalence criteria (Appendix II).

its", and cultural, dietary, and economic patterns, as many as 72 countries are considered to have potentially serious xerophthalmia problems [295].

Xerophthalmia constitutes a problem of enormous magnitude throughout much of Asia and Southeast Asia, the traditional "homes" of the disease, where more is known about it than anywhere else. Numerous surveys in India report prevalence rates for Bitot's spots, active corneal disease (X2/X3), and corneal scarring (X8) many times higher than those in Indonesia [183, 422–424, 426, 433, 434]. Most of these data originate from central and especially southern India, where the disease is considered most prevalent [149, 434], but large numbers of cases are also seen in the north (Venkataswamy, personal communication).

In Bangladesh the situation is probably comparable. In a recent survey the prevalence of Bitot's spots, X8, and X3 were similar to those in Indonesia, and that of X2, considerably higher [432]. In the Philippines, large numbers of cases of X2/X3 are regularly seen in and around Manila [243], while prevalence rates of Bitot's spots, X2, and X8 on the island of Cebu are in excess of those in Indonesia [273]. Although the situation in Sri Lanka is said to have improved, it is still significant [435]. A recent countrywide survey [274] reported overall prevalence rates for Bitot's spots and X8 roughly comparable to those in Indonesia.

In 1930 keratomalacia was the commonest cause of blindness in clinic patients in Peking, accounting for over one-third of all cases [436]. Although the situation has undoubtedly imporved, it still accounts for 7.5% of all blindness in Heilungkiang province [437]. Numerous cases of xerophthalmia were previously observed in Vietnam [309]. Little is known of the current situation in that area, but the disease has been observed in Kampuchean refugees crossing over into Thailand [438]. The disease still occurs, primarily in pockets, in Thailand [389] and Malaysia, though it may be more widespread in Burma. It appears to have disappeared entirely from Singapore.

The situation in Africa is, at the moment, confused. Cases of classical xerophthalmia have been reported from many areas, especially those in which protein-energy malnutrition is common and red palm oil not regularly consumed [45,310,331–334,346,350,361–364,413,439]. But larger numbers of children are said to develop corneal destruction in association with severe measles. If measles is merely precipitating severe xerophthalmia in children with preexisting subclinical vitamin A deficiency (dealt with at length in Chap. 8), as seems possible, xerophthalmia may be even a bigger problem in Africa than in Asia.

Xerophthalmia is also known to occur—probably in foci, in areas of Middle and South America and the Caribbean. In Haiti, the prevalence of XS was twice that in Indonesia [337] while in El Salvador it was one-fourth [336,429]. The author has observed active cases in Guatemala, where—in a recent survey—the prevalence of XS was 10 times the WHO criterion [297]. One controversial report estimated that 1000 preschoolers were going blind every year from xerophthalmia in northeastern Brazil [140].

In an intensive study conducted in Jordan in the mid-1960's [296] the prevalences of Bitot's spots—X2/X3—and XS were all comparable to those in Indonesia, and the mean vitamin A level, 20.3 μg/dl, similar to that in Round 1, Study 1. The situation is since thought to have improved, but by how much is unknown. There are few published reports from elsewhere in the Middle and Near East, but it must be remembered that many reasons besides the absence of disease would account for this, especially the absence or maldistribution (geographic as well as socioeconomic) of ophthalmic services. Serious xerophthalmia is not reported in Iran, but numerous cases are seen each year among members of the migrant Quashghai camping in the vicinity of Shiraz (which had a well-equipped eye unit) (A. Khoudadous, personal communication), and the serious nature of the problem in Haiti was unrecognized among local ophthalmologists, who largely live in the southern cities, where the disease is least common, and minister to a more affluent population [337].

Worldwide magnitude of the problem

Given the fragmentary and limited nature of available data, it is obviously impossible to develop precise estimates of the number of cases of vitamin A deficiency or xerophthalmia occurring worldwide each year. But it is possible to estimate the order of magnitude of the problem, at least in terms of active corneal disease [430].

As already discussed, the annual incidence of active corneal disease among preschool-age rural Indonesian children was conservatively estimated at 2.7/1000, resulting in at least 63,000 new cases each year. The disease is likely to be at least as common throughout much of Asia, especially in India, Bangladesh, and the Philippines. At the annual incidence of 2.7/1000, 400,000–500,000 preschool-age children in India, Indonesia, Bangladesh, and the Philippines will develop active xerophthalmic corneal involvement (X2/X3) every year [430]. This is an absolutely minimal estimate of the problem in Asia: it only includes four countries; it assumes that the rates in three are the same as those in the fourth (Indonesia), when

available evidence suggests they are higher, and it only includes preschoolers, whereas hospital data indicate that a substantial proportion of cases are older. Also, the incidence rate itself is underestimated by the proportion who developed corneal disease and then died or cleared (spontaneously or with treatment outside the study or any of its specially monitored clinics) between rounds. It does not include those other countries in Asia in which the disease is known to occur, nor those in Africa, Middle and South America, the Caribbean, or the Middle East. The true figure for the number of cases of active corneal disease each year may well approach 1 million. Indeed, using the best available data, Shah recently estimated the prevalence of active corneal disease in India at 2.4/1000 [434], nearly four times the Indonesian rate. Assuming that the incidence rate was twice the prevalence—in all likelihood an underestimate—he calculated that 440,000 preschoolers develop active xerophthalmic corneal involvement every year in India alone.

These figures are higher than those suggested previously [43,290, 411,412]. Each new estimate has been based on firmer, more refined data, and each has been higher than those that preceded it. But this probably explains only part of the difference. Even though xerophthalmia no longer occurs in some countries it once did, it has since come to light where it was previously unsuspected. In addition, populations have grown, often at phenomenal rates, increasing the number of children at risk, and in some instances contributing to a further deterioration in nutritional status [443]. Should these trends continue the situation may yet get worse.

To place the present level of disease in perspective, it is worth recalling that the xerophthalmia epidemic that struck Denmark early in this century [39]—universally accounted as a serious and tragic event, was probably attended by a prevalence rate less than one-fifth to one-tenth WHO criteria for a significant public health problem.

The number of children who develop noncorneal xerophthalmia each year will be considerably greater [290]. There is no reason the ratio of noncorneal to corneal disease should be fixed, but in many countries the pattern appears to be similar to that in Indonesia. The incidence of noncorneal xerophthalmia (XN, Bitot's spots, or the two combined in individuals previously free of disease) in Indonesia was 12 times that of corneal involvement (32/1000:2.7/1000 per year). It therefore seems reasonable to suspect that 5 million preschool-age children in India, Indonesia, Bangladesh, and the Philippines alone develop an initial episode of noncorneal xerophthalmia every year, and that the worldwide total may be twice this figure.

12. Blindness and mortality

> What here has once been lost the treatment can never restore.
>
> O. Blegvad, 1924

> In the course of treatment not a single eye was lost that had not already previously been destroyed.
>
> J.H. De Haas, 1938

Among the hundreds of thousands of children who develop corneal xerophthalmia (X2-X3) every year, some recover (spontaneously or with specific treatment), some go blind, and some die. It is difficult to establish the proportion that follow each of these paths: the outcome is likely to be very different in a tiny group of children coming under regular care and observation than among the vast majority that do not. Nonetheless, rough, ballpark figures can be derived from available data.

Resultant blindness

In most instances vitamin A therapy results in prompt and dramatic healing (Chap. 13). Whether or not a child goes blind largely depends on the severity and extent of corneal destruction at the time treatment is first begun. Children with corneal xerosis (X2) or typically eccentric ulcers sparing the pupillary zone rarely go blind, even if a small perforation has already appeared (see color plates).

But eyes with large perforating ulcers, persistently flat anterior chambers, or extensive central corneal destruction are unlikely to regain useful vision. These are usually instances of localized or generalized keratomalacia (X3B).

Potential visual outcome in Study II was estimated from the final degree of central corneal clarity [197]. Follow-up examinations were available on 156 (96%) of all 162 cases. One hundred and forty-seven (94% of those with follow-up examinations) survived at least 3 weeks, by which time visual outcome was obvious. Table 12-1 indicates that central corneal clarity compatible with normal (6/6) acuity in at least one eye was achieved in the vast majority: virtually all children in categories 1–5 (corneal xerosis through localized ulcers), 93% of children with localized full-thickness necrosis in one or both eyes (category 6), and even 82% of children with complete full

Table 12–1. Visual outcome as estimated corneal clarity among cases of active corneal xerophthalmia (Study II)

		Final visual acuity[1]			
		Numbers of cases			% of cases
Original classification	Number of cases[2]	≥6/6 on	≥6/6 better eye	< 6/60 on	≥6/6 one or both eyes
X2 (1–3)[3]	51	50	1	–	100
X3A (4–5)	46	36	10	–	100
X3A/B (6)	27	13	12	2	93
X3B (7)	11	–	9	2	82
X3B (8)	12	–	–	12	0
Total	147	99	32	16	89

1. No cases resulted in acuity of the better eye judged to lie between < 6/6 and < 6/60.
2. Of all 162 cases 7 did not have a follow-up examination; of those that did, 9 died in under one month, leaving 147 (91%) potential survivors in whom visual outcome was assessed by the degree of central corneal clarity.
3. One case listed as 6/6 on, initially cleared but developed bilateral ulceration between days 15 and 25 and died after 1 month. The single case with less than 6/6 in one eye contained a staphyloma from old, healed keratomalacia.

From Sommer et al. [197]

thickness corneal dissolution in one eye (category 7). It was not uncommon for an area of localized scarring to shrink with time, as observed by ten Doeschate [71].

Among children with complete, bilateral, full-thickness corneal dissolution of course the outlook is abysmal: none of our cases recovered useful vision in either eye. Twelve of the fifteen (80%) bilaterally blind children who survived more than two months were originally severely malnourished. It is unlikely they would have survived without intensive treatment.

Results suggest a favorable outcome for the vast majority of xerophthalmia cases treated before irreparable damage occurs in the central portion of both corneas. The prognostic value of this distinction may prove useful as the basis for a simplified classification of corneal involvement.*

Although definitions, severity of corneal involvement, and methods of conducting follow-up clinical examination undoubtedly vary from one study to another, results from the Indonesian project are compatible with reports from other hospitals and clinics. Mc.ion and colleagues [444] were able to follow up one-fourth of children treated for corneal xerophthalmia in the

*This conclusion is reflected in the 1981 revision of the WHO classification (Appendix II).

Hyderabad facility. Among 23 survivors of "keratomalacia" (by which he appears to mean any degree of stromal loss, although five cases reportedly healed without scarring) five (22%) were blind in both eyes and an additional 9 (39%) in one. Of 37 surviving children treated at the Nutrition Rehabilitation Center in Madura for "keratomalacia" (X3B), and followed up [255], five (14%) were blind in both eyes and nine (24%) in one. None of the cases of "xerophthalmic ulceration" (X3A) were said to have gone blind, but only 2 were thought to have developed scarring at all. Blegvad [39] reported that fully 27% of 298 survivors of "keratomalacia" (by which he obviously meant severe corneal destruction) in the Danish epidemic went blind, and an additional 24% were left with poor visual acuity in both eyes. Twenty-nine percent of survivors treated in the central hospital in Jakarta were blinded in both eyes [307,399], as were 50% of survivors treated in 19th century London [175].

What happens under natural field conditions is less certain. Of 22 children with active corneal disease (X2,X3) detected during Rounds 2 through 7 of Study I, six (27%) already had bilateral and another 7 (32%) unilateral corneal ulceration/necrosis. In only nine cases (41%) was involvement limited to corneal xerosis. Among the 16 cases identified during Rounds 2 through 5 (upon whom incidence was based) the rates were comparable: 31% had severe bilateral stromal loss and 19% unilateral loss at the time they were discovered. These data suggest that *at least* one-third of children with xerophthalmic corneal involvement are likely to go blind under ordinary conditions. The actual rate is probably considerably higher. All of these children had been free of frank corneal involvement during the preceding round; hence their disease was of relatively recent onset. Left untreated, a large but unknown proportion with corneal xerosis or unilateral stromal loss might lose vision in both eyes. Indeed one case, already discussed in detail, with extensive conjunctival xerosis and punctate keratopathy without manifest corneal xerosis on handlight examination, developed corneal ulceration within two weeks of receiving a low-dose capsule.

A more realistic, though still underestimated, appraisal of the natural state is provided by the countrywide survey (Study IV) and Round 1 of Study I, since in a greater but unknown percentage the disease was not cut short by treatment during an earlier examination. Bilateral corneal necrosis was present in two of the four cases (50%) detected during the first round of Study I, and another case (25%) had unilateral necrosis (category 7). Of the 22 children with active corneal disease identified in the course of study IV, 8 (36%) had large corneal ulcers or necrosis in both eyes and

an additional 4 (18%) in one eye. In four other children (18%) there were shallow ulcers or erosions bilaterally and in one (5%) unilaterally. Only six cases (27%) had intact xerotic corneas.

These unbiased field results suggest that perhaps half or more of the children with active corneal xerophthalmia ordinarily go blind. Indeed, almost half (15% = 21/47) the children with xerophthalmic scarring (XS) in the countrywide survey (Study IV) were without useful vision in either eye. Only 12% (6/47) had useful vision in both eyes. Before the beneficial effects of vitamin A were widely appreciated, 50/85% of Danish children treated for xerophthalmia went blind [39]. Stephenson [175] reported similar results for turn-of-the-century England.

Mortality

The problems discussed above also arise when estimating mortality. Data are more readily available on cases receiving treatment than on the great majority who do not.

Study II provides the most complete data available on a population of treated (but not always hospitalized) patients. Children who did not return for follow-up during the last two months of the study were visited at home. Where a family had moved to another area in West Java, and the new address was known, they were visited there. Where the address was unknown and the family could not be located, but relatives or neighbors were certain the child was alive at the time of the move, follow-up was considered to have lasted until the move took place. If relatives or neighbors were uncertain of the child's status at the time of the move, follow-up was considered to have terminated at the last examination. Only 9 of the 162 children (5.6%) could not be followed through completion of the study: one returned home on the day of examination and did not return during the remaining two weeks of the study, six moved outside West Java, and two were at an unknown address.

A modified life-table analysis was employed (Table 12-2). Cumulative mortality over the 14-month period of follow-up was 12.6%. Most of the deaths occurred soon after presentation.

The single most important determinant of mortality was general nutritional status. Mortality among children with severe protein-energy malnutrition was almost seven times the rate of those better nourished (25.7% vs 3.8% respectively). Most of the severe PEM was kwashiorkor or a mixed type: edema was present in 72%; in an additional 17% serum albumin was

Table 12–2. Mortality among cases of active corneal disease (Study II)

Duration of follow-up	Not severely malnourished				Severely malnourished[1]				Total cases			
	Total	Died			Total	Died			Total	Died		
	n	*n*	(%)	Cum. %	*n*	*n*	(%)	Cum. %	*n*	*n*	(%)	Cum. %
1 week	96	0			65	4	(6.2)	6.2	161	4	(2.5)	
2 week	92	0			59	2	(3.4)	9.6	151	2	(1.3)	3.8
1 month	90	1	(1.1)	1.1	57	4	(7.0)	16.6	147	5	(3.4)	7.2
2 month	81	0		1.1	50	2	(4.0)	20.6	131	2	(1.5)	8.7
3–4 month	74	2	(2.7)	3.8	48	1	(2.1)	22.7	122	3	(2.5)	11.2
5–6 month	55	0		3.8	45	0		22.7	100	0		11.2
7–8 month	41	0		3.8	33	1	(3.0)	25.7	74	1	(1.4)	12.6
9–10 month	28	0		3.8	24	0		25.7	52	0		12.6
11–12 month	24	0		3.8	18	0		25.7	42	0		12.6
13–14 month	14	0		3.8	11	0		25.7	25	0		12.6
Total		3		3.8		14		25.7		17		12.6

1. *Severe malnutrition* defined as any of the following: edema, albumin ≤ 2.5 g/dl or weight for height <70% of standard.
Difference in mortality between the two groups, $p < .01$.

Table 12-3. Cumulative 12-month mortality among cases of corneal xerophthalmia (Study II)[1]

Clinical classification (category)	Deaths (n)	Cumulative mortality (%)
1–3	6	17.8
4–6	9	12.4
7–8	2	9.0
Total	17	12.6

1 Calculated in same manner as Table 12-2.

less than or equal to 2.5 g/dl. Almost all excess mortality among children with severe PEM occurred during the first one to two months, consistent with the time-related leveling of mortality among children of varying nutritional status observed under ordinary field conditions [445,446]. The severity of corneal involvement, hence vitamin A deficiency, had no appreciable influence on mortality (Table 12-3). If anything, those with the severest disease had, quite unexpectedly, the lowest mortality. The numbers, however, are small and differences may partially reflect the assiduousness with which care was delivered.

It therefore appears that short-term mortality among children with severe (i.e. corneal) xerophthalmia treated in a clinic or hospital is primarily a function of general nutritional status; when xerophthalmia is unaccompanied by severe PEM, mortality probably runs around 1–3%, and when accompanied by severe PEM, 15–25%. Therefore, overall mortality would depend on the relative proportion of cases with and without severe PEM, as indeed available data from other areas would suggest. Only 7% of xerophthalmic children (most but not all of whom were malnourished) treated at a nutrition rehabilitation center in India died, vs 10% of nonxerophthalmic children admitted for general malnutrition [447]. Among children hospitalized for xerophthalmia in El Salvador, most of whom were severely malnourished, the overall mortality rate was 21%; in the most severely malnourished subgroup it was 25% [161]. Another estimate for the same country suggests that 16% of severely malnourished children with corneal xerophthalmia, and 11% without died in hospital [338]. Many years ago, 30–35% of severely malnourished children treated in the central hospital in Jakarta died whether or not they had accompanying xerophthalmia [34]. In one African report, overall hospital mortality for severely malnour-

ished children, 25%, rose to 30% for children with ulcerated corneal lesions and 37% for those with diarrhea [136]. In a study in Bangladesh, mortality among severely malnourished children without xerophthalmia was 10% and in those with xerophthalmia 15% [275]. Although this difference was not statistically significant, those with xerophthalmia were even more undernourished and hypoproteinemic than those without, even when matched for age and type of malnutrition. Mortality during the Danish epidemic, in which most of the children were severely malnourished, reached 39% for those one to three months of age, dropping to 11% among those one year and older [39].

As bad as they are, these results do not compare with the 100% mortality reported by Hirschberg in 1868 [10] or the 50–80% reported by some authors earlier in this century [175, 448]. Given the lack of understanding of kwashiorkor at the time, these rates are probably close to the untreated, natural history of the disease today.

One of the more controversial questions concerning early xerophthalmia mortality is whether vitamin A deficiency per se increases the risk of dying. Data presented above would suggest that it does not; at least not to any appreciable degree when compared with the effect of general nutritional status. McLaren, however [248], has reported mortality rates for malnourished children with xerophthalmia of 56–64%, four times that of children without xerophthalmia but with a similar PEM classification. Similar, though less dramatic, results were reported by Pereira et al. [254]: mortality among children with both keratomalacia and kwashiorkor was 28%, twice that among children with kwashiorkor alone. But as Brown et al. have shown [275], children with xerophthalmia may be even more severely malnourished than those without, even though both are considered to suffer from severe PEM. In El Salvador, mortality among severely malnourished females hospitalized with xerophthalmia was twice that of those without, but rates for males was identical [338]. This finding was interpreted as evidence that admission of females was delayed until they were more severely malnourished. It is possible that xerophthalmic children in McLaren's and Pereira's series were similarly more severely malnourished than those without xerophthalmia. Severe malnutrition, especially protein deficiency, may have precipitated their xerophthalmia or those with the poorest protein and caloric intake may have had the poorest vitamin A intake as well. Indeed, Scragg and Rubidge [289] reported an in-hospital mortality among 1565 severely malnourished African children (over 90% with edema) of 52%. In general, those who died had lower serum protein

values than those who survived. Fourteen of these children had rapidly developing corneal perforation in eyes that often appeared entirely normal the day before. The mortality in this subgroup was an astounding 93% (13/14). Scragg specifically notes that 5 were admitted "in extremis," dying within a few hours.

Long-term mortality in xerophthalmia is generally conceded to be excessive, both because these children belong to that subgroup at risk of malnutrition (and parasitic and infectious diseases), and because those blinded are ill-equipped to compete with their normally sighted siblings for limited resources. The relative contribution of these two factors is unknown. We occasionally encountered children suffering from severe malnutrition and bilateral corneal destruction (X3B) in the field whose parents refused hospitalization without some guarantee that the child would see again. On the other hand, late mortality among children with bilateral corneal destruction enrolled in Study II was essentially nil (Tables 12-2, 12-3), perhaps because of the counseling and encouragement their families received through an ancillary program, the Blind Babies Project [449]. Menon [444] reported that 20% of xerophthalmic children died within 3–4 months of leaving the hospital. Rates were highest for cases with keratomalacia or complicated by edema, though it is impossible to assess the influence of one or the other from the available data. Venkataswami [447] reported that 20% of xerophthalmic children, but 50% (of presumably more malnourished) nonxerophthalmic children died following discharge from a nutrition rehabilitation center. Ten Doeschate [71] found that 43% of the children in Surabaya blinded from xerophthalmia, and an identical percentage blinded from other causes, died within a one to six year follow-up. Unfortunately, comparative data are not available on sighted children.

Mortality among xerophthalmic children is clearly excessive, even among the "fortunate" few receiving treatment. Under natural field conditions the rates will be still higher. For obvious reasons these cannot be observed and documented directly. But they can be estimated by comparing the prevalence of corneal scarring (XS) expected with that actually observed. If mortality among children with xerophthalmic scarring is the same as among those without, estimated and observed prevalence of XS in the population should be reasonably similar [74,152].

As we have seen, the annual incidence of active corneal disease among Indonesian children up to age six is 2.7/1000 (Table 11-5), and the proportion of active cases that will result in observable scarring in one or both eyes (i.e. the proportion of corneal cases in Study IV with advanced X3) is

at *least* 55% (12/22). At the resultant *minimal* annual incidence of xerophthalmic scarring of 1.5/1000, and mean period of accumulation of three years, the average prevalence of XS among children up to age six should be 4.5/1000. The prevalence actually observed in Study IV was 1.3/1000, suggesting a survivorship among cases of irreversibly unilateral or bilateral xerophthalmic corneal damage equal to only 29% of that of the rest of the population. Even if the seven children with Group Two corneal scarring (not accepted as XS for want of supportive data) are included, the observed prevalence would still be only 1.5/1000 or 33% of that expected. Similar analysis indicates that mortality among children in the subgroup with blinding xerophthalmic scarring was comparable. These are likely to be minimal estimates, since the incidence of active corneal disease, hence expected prevalence of xerophthalmic scarring, is probably underestimated. On the other hand it is possible, though unlikely, that incidence rates were lower in previous years resulting in fewer children with xerophthalmic scars (though there is no evidence to suggest they were); that a larger proportion of the 104 cases of corneal scars not ascribed to xerophthalmia may have been due to the disease, or that a disproportionate number of blinded children were not home to be counted (this was specifically inquired about; the age group generally is not employed in begging, and there are no institutions for preschool-age children to which they might have been sent). It has already been suggested that only 20% of children sure to go blind (Study II) would probably have survived without treatment.

Mortality is obviously very high—comparable to that reported from turn-of-the-century Europe [175,448]. The rate in any one country will largely depend on the degree to which xerophthalmia is associated with severe malnutrition, the cultural significance of blindness in young children, and the availability of prompt and optimal treatment.

V Treatment and prevention

13. Treatment

> I have no experience treating nightblindness by incarcerating sufferers in a darkened room as advised by Wharton and Netter . . . nobody can be astonished however that patients declare themselves free from hemeralopia after a longer or shorter confinement in places of the sort. It would indeed be wonderful did that symptom long survive means of so rigorous and penal a kind.
>
> S. Stephenson, 1896

> The effect of cod liver oil on nightblindness and conjunctival xerosis is very marked . . . it appears, in fact, almost specific.
>
> S. Snell, 1881

> The order of sequence of medical action should regard: first the eye, second the patient, third his kitchen.
>
> H.A.P.C.Oemen, 1961

For millennia, nightblindness has been treated with substances rich in vitamin A. Ancient Egyptians, Hippocrates, Paul of Aegina [450], and Galen [1] all recommended liver, a popular folk remedy in India [160], Japan [48], and Europe. Wolf [1] observed that the Papyrus Ebers (c. 1520 BC) did not recommend eating the liver, but favored applying it directly to the eye. In speculating on how the vitamin A made its way from the conjunctival sack in the front of the eye to the retina behind, he suggested that it might trickle down the lacrimal duct and eventually be absorbed. Topical application of liver juices remains a popular remedy in rural Indonesia [451], where the mode of action is more obvious: after completing the prescribed "treatment," the patient is fed the remaining organ. Although the Indonesian villager does not consider the latter action an essential part of therapy, Aetius [452] prescribed exactly this sequence.

During the 19th and early 20th centuries, clinicians became increasingly familiar with the therapeutic value of fish liver oil, especially that of the cod [18, 20–32, 129, 453]. Schiele [403] discovered that he could cure breast-fed children by feeding cod liver oil to their mothers.

Both Morr [18] and Blegvad (cited in ref. 38) administered cod liver oil parenterally with good results. Bloch [38] was convinced that addition of parenteral to oral therapy speeded clinical recovery, and recommended it in cases of corneal involvement. Although oily injections are widely used

and are capable of curing xerophthalmia [71,248,451-455,456]; biochemical studies indicate that relatively little vitamin A is actually released from the injection site [455,457]. In reasonably healthy children with varying degrees of PEM, parenterally administered oily preparations produce the least rise in serum vitamin A, parenterally administered water-miscible preparations the highest, and orally administered oil or water-miscible preparations levels in between [457].

On the basis of these biochemical results, and suggestions that diarrhea [321] and PEM [458] further reduce absorption of an oral dose, it was recommended [47] that all cases of xerophthalmia receive an immediate intramuscular injection of 100,000 IU water-miscible vitamin A, followed, the next day, by an oral dose. Although widely recognized, this "official" schedule is rarely followed: water-miscible parenteral preparations, costly needles and syringes, and personnel trained in their use are generally unavailable at the periphery of the medical network where the disease is commonly encountered.

Since the recommended water-miscible parenteral regimen had never been clinically tested against more practical oral ones, controlled trials were incorporated into Study II [246].

Systemic vitamin A

Clinical response

All involved eyes in Study II meeting the following criteria were included in the analyses: frank corneal involvement with at least some potentially viable stroma remaining (corneal xerosis through focal necrosis); absence of topical retinoic acid therapy (used in a concurrently running protocol); and reexamination at least once within 2 weeks of initial therapy.

Single dose trials. 100,000 IU water-miscible vitamin A intramuscularly vs 200,000 IU oily vitamin A orally

Initially, all children with corneal xerophthalmia (Study II) were alternately assigned to receive a single dose of vitamin A, either 100,000 IU of the water-miscible preparation intramuscularly or 200,000 IU of the oily preparation orally. For reasons discussed below, this trial was soon terminated. Despite the relatively small number of cases involved, the two groups were reasonably comparable (Table 13-1). Clinical response over the first two weeks was similar, though a larger proportion of eyes of parenteral recipients deteriorated during the first four days (Table 13-2).

Table 13–4. Comparability of corneal cases in single-dose treatment groups (Study II)

	Treatment regimen[1]			
	Oral		Parenteral	
	n	(%)	*n*	(%)
Total eyes	19	(100)	18	(100)
Hospitalized	11	(58)	9	(50)
Clinical diagnosis				
X2	12	(63)	10	(56)
X3A	5	(26)	6	(33)
X3B[2]	2	(11)	2	(11)
Diarrhea[3]	10	(53)	7	(39)
PEM[4]	7	(37)	7	(39)
Mortality	4	(21)	2	(11)

1 Oral: 200,000 IU oil-miscible vitamin A palmitate, parenteral: 100,000 IU water-miscible vitamin A palmitate intramuscularly.
2 Eyes with limbal-to-limbal necrosis excluded
3 Four or more loose stools per day
4 One or more of the following: serum albumin < 3.0 g/dl or transferrin < 50 mg/dl, weight for height < 70% of standard, pedal edema

These were all instances of delayed corneal response, and all recovered, and healed, spontaneously. Of greater concern were two cases which, after initiating or completing healing, suffered severe relapse.

Case 200,003 was a four-year-old boy with diarrhea, a weight for height 95% of standard, and an initial albumin of 2.7 g/dl and transferrin of 20 mg/dl. He had a one-month history of nightblindness and presented with localized necrosis in the right eye and mild inferior haze in the left. He received 100,000 IU of water-miscible vitamin A IM (intramuscularly). The left eye deteriorated at first, developing frank xerotic patches by day 3, but cleared completely by day 6. The necrotic lesion in the right cornea perforated on day 3, but by day 5 was healing nicely. Serum vitamin A, 7 μg/dl on admission, rose to 13 by 1 hour, 118 by 4 hours, and 145 by day 1, but fell to 30 μg/dl by day 4. Serum holo-RBP, 2 μg/ml on admission, reached 16 by 4 hr and was 19 on day 10. On day 6, however, the tissue covering the prior perforation appeared to be thinning. By day 10 the perforation had enlarged and more iris was exposed than ever before. A suspicion of active pulmonary tuberculosis was confirmed radiologically and streptomycin begun. On day 12 the perforation was twice its original size and the child had classical varicella skin lesions. Serum albumin was 3.2 g/dl, transferrin 158 mg/dl, but vitamin A only 17 μg/dl and holo-RBP 7 μg/ml. He was given 200,000 IU vitamin A PO (orally). By day 19 serum vitamin A was 32 and healing of the perforation had resumed. The child was discharged. When next seen on day 54 albumin was 3.7 g/dl, vitamin A 29 μg/dl, and the right eye completely healed with an inferonasal adherent leukoma and clear pupillary zone.

Table 13–2. Clinical response of corneal lesions in single-dose recipients Study II[1]

Days since therapy		Worse		Static		Improved		Cured		Total	
		n	(%)	*n*	(%)	*n*	(%)	*n*	(%)	*n*	(%)[2]
1	Oral	1	(11)	5	(56)	3	(33)	–	–	9	(48)
	IM	3	(23)	10	(77)	–	–	–	–	13	(72)
2–4	Oral	–	–	2	(13)	9	(60)	4	(27)	15	(79)
	IM	5	(29)	3	(18)	8	(47)	1	(6)	17	(94)
6–8	Oral	–	–	–	–	7	(54)	6	(46)	13	(68)
	IM	–	–	–	–	9	(64)	5	(36)	14	(78)
12–16	Oral	–	–	–	–	5	(33)	10	(67)	15	(79)
	IM	1	(7)	–	–	4	(29)	9	(64)	14	(78)

1. Oral therapy: 200,000 IU vitamin A PO. IM: 100,000 IU water-miscible intramuscularly. Eyes with limbal-to-limbal necrosis excluded.
2. Percent of all eyes in series examined in the interval.

It appears that in this case a single IM dose provided insufficient vitamin during the added stress of chicken pox, perhaps because of initially severely depleted stores (possibly exacerbated by active tuberculosis) [322].

Case 200/011, already mentioned, was a two-year-old with a two-month history of nightblindness who presented with pitting edema of both hands and legs, severe conjunctival and moderate corneal xerosis on (in both eyes) and a localized area of fluorescein-staining stromal edema inferiorly in the left eye. Serial blood chemistries are shown in Table 13-3. He received 200,000 IU vitamin A orally. The mother refused hospitalization. Despite continued, severe depression of both albumin (consistently 1.5–1.7 g/dl) and transferrin (consistently ≤ 20–25 mg/dl)

Table 13–3. Serial blood chemistries: case 200/011

Time since therapy[1]	Serum vitamin A (μg/dl)	Serum holo-RBP (μg/ml)	Serum carotene (μg/dl)
0 hours	3	0	9
4 hours	16	6	6
1 day	9	4	10
2 days	16	–	14
4 days	31	7	9
7 days	11	12	12
23 days	–	0	–

1. 200,000 IU vitamin A in oil, orally.

throughout the first two weeks, the clinical course was unremarkable; both corneas had improved by day 2, by day 4 conjunctival xerosis had disappeared and the ulcer had healed as a depressed (25% corneal thickness) pale maculae; by day 9 both eyes were entirely free of active disease. During this interval holo-RBP rose to 12 μg/ml, though vitamin A, curiously peaking at 31 μg/dl on day 4, fell, by day 7, to 11 μg/dl. When next seen, on day 15, the child's general condition was worse; edema was still extensive and his weight had dropped from 85 to 59% of standard for height. Though both corneas were still clear, punctate keratopathy had reappeared. The mother still refused hospitalization. Blood samples taken that day were hemolized. Because the mother did not return as promised, a team visited the house, returning with the mother and child on day 23. The conjunctiva of both eyes still looked perfectly normal, but both corneas had a dry, pebbly, moderately xerotic (category 2) appearance, each with an ulcer. Lid closure was weak but complete and a Bell's phenomenon present. Holo-RBP had fallen to zero μg/ml. The mother finally agreed to hospitalization. The child received a second oral dose of vitamin A and a high-protein diet and liquids via a nasogastric tube. By the next day both corneas showed improvement. The following day (day 25) the child expired.

This case clearly demonstrates that xerophthalmia can respond to isolated vitamin A therapy despite severe, persistent protein deficiency. The response, however, was not sustained, suggesting an inability to store and subsequently utilize the massive dose. Others [20,155,428] have also encountered cases in which the corneas responded rapidly to vitamin A therapy, even though the children died soon afterward. Osborne [459] recalled the same phenomenon in animals. The corneas of two additional children, one an oral, the other an IM recipient also deteriorated three weeks to three months after their single dose.

Double dose trials. 100,000 IU water-miscible vitamin A IM + 200,000 IU oily vitamin A PO the following day vs 200,000 IU oily vitamin A orally on two successive days [246].

Because of the early, severe relapses encountered above, the single-dose trial was modified: in addition to the parenteral water-miscible or oral oil-miscible dose received on admission, all children received 200,000 IU oily vitamin A by mouth the following day (day 1). When the supply of water-miscible parenteral vitamin A was exhausted, 200,000 IU oil-miscible parenteral vitamin A were given in divided doses on the day of admission instead. This was the standard form of therapy in Indonesia at the time, and was not followed by an oral dose the next day. These oil-miscible parenteral recipients are excluded from the double-dose comparisons below.

The two groups of double-dose recipients (IM water-miscible/PO oil-miscible and PO oil-miscible/PO oil-miscible) were comparable in all major

Table 13–4. Comparability of corneal cases in double-dose treatment groups (Study II)

	Treatment regimen[1]			
	Oral		Parenteral	
	n	(%)	*n*	(%)
Total eyes	88	(100)	58	(100)
Hospitalized	67	(76)	45	(78)
Clinical diagnosis				
X2	50	(57)	38	(66)
X3A	26	(30)	9	(16)
X3B[2]	12	(14)	11	(19)
Diarrhea[3]	35	(40)	20	(34)
PEM[4]	47	(53)	30	(52)
Mortality	8	(9)	3	(2)

1. Oral: 200,000 IU oil-miscible vitamin A palmitate PO on 2 consecutive days. Parenteral: 100,000 IU water-miscible vitamin A palmitate on day 1, followed by the oral dose the next day.
2. Eyes with limbal-to-limbal necrosis excluded.
3. Four or more loose stools per day.
4. One or more of the following: serum albumin < 3.0 g/dl or transferrin < 50 mg/dl, weight for height < 70% of standard, pedal edema.

From Sommer et al. [246]

factors expected to influence outcome (Table 13-4). The clinical response was remarkably similar in both groups: approximately one-fourth of all eyes examined one day, two-thirds examined two to four days, and 95% examined six to eight days after the start of therapy improved or healed (Table 13-5). Results were similar when analysis was limited to cases with diarrhea (Table 13-6) or severe PEM (Table 13-7). There is no evidence that parenteral recipients fared any better than those receiving purely oral therapy.

Double dosing did not entirely eliminate the problem of early relapse: two cases receiving intramuscular plus oral (IM-PO) therapy relapsed within three weeks, and two receiving PO-PO therapy within one month. These were all severely ill, malnourished children; three of the four died soon afterward.

Case 200084: A two year-old severely malnourished marasmic girl (weight for height 60% of standard; serum transferrin < 20 mg/dl but albumin 3.1 g/dl) with a one-month history of nightblindness was referred from Study 1. She had conjunctival and corneal xerosis (category 1) in both eyes. Holo-RBP on admission to the hospital was 1 μg/ml. She received 100,000 IU water-miscible vitamin A intramuscularly on admission and 200,000 IU oily vitamin A orally the following day. Conjunctival and corneal xerosis disappeared by day 4. Despite attempts at feeding,

Table 13–5. Clinical response of corneal lesions in double-dose recipients (Study II)[1]

Days since therapy	Worse		Static		Improved		Cured		Total	
	n	(%)	*n*	(%)	*n*	(%)	*n*	(%)	*n*	(%)[2]
1 Oral + 2	3	(6)	29	(62)	15	(32)	–	–	47	(53)
IM + Oral	7	(23)	16	(53)	7	(23)	–	–	30	(52)
2–4 Oral + 2	7	(10)	11	(16)	39	(57)	12	(17)	69	(78)
IM + Oral	3	(7)	14	(30)	23	(50)	6	(13)	46	(79)
6–8 Oral + 2	–	(–)	4	(6)	34	(51)	29	(43)	67	(76)
IM + Oral	2	(4)	–	(–)	29	(55)	22	(42)	53	(91)
12–16 Oral + 2	–	(–)	1	(2)	12	(24)	36	(73)	49	(56)
IM + Oral	2	(5)	0	(0)	11	(27)	28	(68)	41	(71)

1. Oral therapy: 200,000 IU oil-miscible vitamin A PO on 2 successive days. IM: 100,000 IU water-miscible vitamin A intramuscularly on day 1 followed by the oral dose the next day.
2. Percent of all eyes in series examined in the interval.

From Sommer et al. [246].

Table 13–6. Clinical response of corneal lesions among double-dose recipients with diarrhea[1] (Study II)

Days since therapy	Worse		Static		Improved		Cured		Total	
	n	(%)	*n*	(%)	*n*	(%)	*n*	(%)	*n*	(%)
1 Oral + 2	1	(7)	12	(80)	2	(13)	–	(–)	15	(43)
IM + Oral	3	(30)	5	(50)	2	(20)	–	(–)	10	(48)
2–4 Oral + 2	2	(7)	5	(17)	20	(70)	2	(7)	29	(83)
IM + Oral	–	(–)	7	(39)	7	(39)	4	(22)	18	(86)
6–8 Oral + 2	–	(–)	1	(4)	19	(68)	8	(29)	28	(80)
IM + Oral	–	(–)	–	(–)	14	(74)	5	(26)	19	(91)
12–16 Oral + 2	–	(–)	–	(–)	5	(24)	16	(76)	21	(60)
IM + Oral	2	(11)	–	(–)	6	(32)	11	(58)	19	(91)

1. Subgroup of individuals in Table 13–5 with 4 or more loose stools per day.

From Sommer [516].

she lost weight over the first week and a feeding tube was put in place. Two days later she developed severe diarrhea, edema, and frank dehydration. Despite electolyte therapy, corneal xerosis returned and she died on day 17. Follow-up holo-RBP values were not available, but total RBP, 14 μg/ml on admission, rose to 33 at 4 hours, declined to 23 on day 1, rose to 29 on day 3 (the typical biphasic curve we will discuss later) but fell again, by day 11 to 20.

Table 13-7. Clinical response of corneal lesions among double-dose recipients with PEM[1] (Study II)

Days since therapy		Worse		Static		Improved		Cured		Total	
		n	(%)	*n*	(%)	*n*	(%)	*n*	(%)	*n*	(%)[2]
1	Oral + 2	2	(10)	12	(57)	7	(33)		(–)	21	(45)
	IM + Oral	5	(24)	12	(57)	4	(19)	–	(–)	21	(70)
2–4	Oral + 2	7	(18)	6	(15)	24	(62)	2	(5)	39	(83)
	IM + Oral	3	(12)	8	(32)	12	(48)	2	(8)	25	(83)
6–8	Oral + 2	–	(–)	4	(12)	19	(56)	11	(32)	34	(72)
	IM + Oral	2	(7)	–	(–)	20	(69)	7	(24)	29	(97)
12–16	Oral + 2	–	(–)	1	(3)	9	(31)	19	(66)	29	(62)
	IM + Oral	2	(8)	–	(–)	8	(33)	14	(58)	24	(80)

1 Subgroup of individuals in Table 13-5 with one or more of the following: serum albumin < 3.0 g/dl or transferrin < 50 mg/dl, weight for height < 70% of standard, or pedal edema.

2 Percent of all eyes in series examined in the interval.

From Sommer [516].

Case 200068. A two-year-old boy with a two-week history of nightblindness had kept his eyes closed for the past ten days. He was admitted to the hospital with marasmic kwashiorkor (pitting edema, serum albumin 2.5 g/dl, and serum transferrin < 20 mg/dl), respiratory tract infection, severely (life-threatening) general status, and conjunctival and corneal xerosis in both eyes (grade 2) (serum vitamin A 9 μg/dl). He received 100,000 IU water-miscible vitamin A on admission and the standard oral massive dose the following day. Conjunctival xerosis disappeared by day 5 and corneal xerosis was all but gone by days 9–11. Serum albumin began to rise and edema declined. Diarrhea intervened during the second week, edema worsened, and a nasogastric tube was used for feeding. Corneal status of both eyes deteriorated on day 14, a superficial ulcer appearing in the right eye. Serum albumin fell (2.1 g/dl on day 15), and an ulcer formed in the left eye by day 25. He died on day 30.

Case 200111, a two-year-old male presented with conjunctival and corneal xerosis and a shallow (one-fifth depth) ulcer in each eye, pitting edema, a serum vitamin A of 9 μg/dl, and albumin of 2.4 g/dl. He received 200,000 IU oil-miscible vitamin A on admission and again the following day. His general condition and ocular lesions improved and edema disappeared by the end of the first week, when his mother removed him from the hospital. When next seen, at two weeks, both conjunctivae were completely normal, and only minimal inferior haze was present in both corneas (the ulcers having healed as pale maculae). When next seen at one month, nasal and temporal conjunctival xerosis had returned in both eyes. The corneas were unchanged and serum albumin was 3.0 g/dl. He did not return for follow-up. When the team eventually visited his home they were told he had died at two months following a bout of cough, fever, and diarrhea.

Table 13-8. Clinical response of corneal lesions among parenteral recipients of oil-miscible vitamin A (Study II)[1]

Days since therapy	Worse		Static		Improved		Cured		Total	
	n	%	*n*	%	*n*	%	*n*	%	*n*	%[2]
1	2	(17)	10	(83)	–			–	12	(55)
2–4	1	(7)	4	(27)	10	(67)	–	–	15	(68)
6–8		–	2	(14)	11	(79)	1	(7)	14	(64)
12–16	–	–	–	–			10	(100)	10	(45)

1. 200,000 IU oil-miscible vitamin A intramuscularly in a divided dose
2. Percent of all eyes in series examined in the interval

Case 200/147: This 2-year-old female had a three-month history of nightblindness for which she received 200,000 IU oil-miscible vitamin A IM at the local health clinic one month before presenting with complete necrosis of her right cornea and a one-fifth depth 2-mm ulcer in the left. She was severely malnourished, with frank anasarca, serum albumin of 1.9 g/dl, and transferrin 20 μg/ml. She received 200,000 IU orally on two successive days. The ulcer showed definite improvement by day 3, and by day 5 could only be discerned as a limited area of fluorescein staining. By two weeks edema had disappeared. Although the ulcer appeared to be getting worse, the mother insisted on discharging the patient. When next seen at three weeks, serum albumin was still only 1.8 and a central one-fourth depth ulcer occupied 75% of the corneal surface in the left eye. The mother refused to allow hospitalization. An additional oral dose of vitamin A was given. When next seen, a week later, the ulcer had completely healed and only a dense leukoma remained.

Oil-Miscible parenteral recipients. Although the number of eyes available for analysis among children receiving only 200,000 IU oil-miscible vitamin A parenterally was small, they were comparable for all criteria with those in the other treatment groups. Response during the first two weeks was also similar (Table 13-8). Relapses, however, were common: 3 cases containing 6 of the 22 eyes in the series required additional therapy between 3 weeks and 3 months.

Biochemical response

Mean serum vitamin A and holo-RBP levels for the two groups of double-dose recipients are shown in Table 13-9. Only cases in the clinical comparison, on whom there were biochemical values for the same parameter (vitamin A or holo-RBP), on at least two occasions during the first seven days, are included.

Table 13–9. Serum vitamin A and holo-RBP levels among double-dose vitamin A recipients (Study II)[1]

Time since initial dose		Vitamin A (μg/dl) Oral	Vitamin A (μg/dl) IM	Holo-RBP (μg/ml) Oral	Holo-RBP (μg/ml) IM
0 hours	$\bar{\mu}$	6.8	6.1	1.2	1.3
	SD	3.9	3.8	1.4	1.8
	n	35	16	35	29
4 hours	$\bar{\mu}$	33.6	47.6	19.5	15.1
	SD	26.9	36.4	15.1	10.2
	n	36	16	23	11
1 day	$\bar{\mu}$	**22.1	107.7	*12.1	20.0
	SD	24.2	46.2	10.0	9.8
	n	35	10	22	13
3 days	$\bar{\mu}$	**28.1	152.8	18.6	21.6
	SD	34.1	86.5	12.4	9.8
	n	37	17	18	15
7 days	$\bar{\mu}$	**22.9	53.0	24.7	27.4
	SD	8.0	39.8	10.1	16.3
	n	37	18	20	16

1 Limited to cases of corneal involvement included in the analysis of clinical response, Tables 13–4 and 13–5 on whom at least 2 values were available. Oral: 200,000 IU oil-miscible vitamin A at 0 hours and 1 day. IM: 100,000 IU water-miscible vitamin A intramuscularly at 0 hours plus 200,000 IU oil-miscible vitamin A orally at 1 day.

* Difference between oral and parenteral (IM) group statistically significant at $p < .05$, ** at $p < .001$.

From Sommer et al. [246]

Serum Vitamin A. Among double-dose recipients (Table 13-9) serum vitamin A levels were higher following parenteral than following oral therapy, though never reaching the heights reported by Srikantia (457) in nonxerophthalmic children. The difference between the two groups, minimal at 4 hours, was statistically significant from day 1 through day 7.

Among oral recipients each dose was followed by a rise and then a fall in serum vitamin A, though at the intervals sampled only the change between T_0 and T_1 was statistically significant ($p < .001$) (Table 13–9). The second rise was not present among single-dose recipients (Table 13-10), and their prolonged plateau between T_{3d} and T_{3d} was entirely due to a single case (200/017) in whom the level at $3d$ was 97, three times that of the next highest.

Table 13-10. Serum vitamin A among single-dose vitamin A recipients (Study II)[1]

Time since initial dose		Treatment regimen[2] Oral	IM (water)	IM (oil)
0 hours	$\bar{\mu}$	8.0	9.7	5.8
	SD	4.7	5.1	4.2
	n	10	11	12
4 hours	$\bar{\mu}$	41.4	70.0	6.0
	SD	32.6	44.1	4.5
	n	7	11	12
1 day	$\bar{\mu}$	28.0	108.7	7.6
	SD	13.6	47.3	10.0
	n	9	11	9
3 days	$\bar{\mu}$	30.5	83.5	9.4
	SD	33.5	46.7	6.1
	n	6	11	10
7 days	$\bar{\mu}$	24.4	28.0	15.9
	SD	10.3	6.7	13.4
	n	5	5	7

1. Limited to cases of corneal involvement included in the analysis of clinical response, Tables 13-2 and 13-8. Holo-RBP response omitted because numbers very small. Serum vitamin A in μg/dl.
2. Oral: 200,000 IU oil-miscible vitamin A PO; IM (water): 100,000 IU water-miscible vitamin A intramuscularly; IM (oil): 200,000 IU oil-miscible vitamin A intramuscularly.

The response among double-dose parenteral (IM-PO) recipients (Table 13-9) peaked at three days, the rise from T_0–T_1, and decline from T_{3d}–T_{7d} being statistically significant ($p < .001$). By contrast, serum vitamin A among single-dose (water-miscible) parenteral recipients (Table 13-10) peaked on day 1, at a level identical to that among double-dose recipients, but fell rapidly thereafter.

Despite initial clinical improvement, the serum vitamin A response among children who received only an intramuscular injection (200,000 IU) of *oily* vitamin A was minimal (Table 13-10), especially during the first three days. At day 3, levels were below 10 μg/dl in 6/10 cases, and below 20 μg/dl in 9/10; by day 7 they were still below 10 μg/dl in 4/7 cases. By comparison, levels among oral single-dose recipients were below 10 μg/dl in only one of six cases on day 3, and none of five by day 7.

Differences in serum vitamin A response are not necessarily meaningful.

"Total" vitamin A includes both retinyl esters and retinol. Only the latter, combined with retinol-binding protein (RBP) ordinarily comprises the physiologically active agent (holo-RBP).

Holo RBP response. Unlike total vitamin A response, there was almost no difference in the holo RBP response among parenteral (IM PO) and purely oral (PO PO) double-dose recipients (Table 13-9). The only difference to approach statistical significance occurred at day 14 ($t = 2.27$, $p = .05$ for a single comparison, but lower here as one of five serial comparisons).

Even if the difference at Day 14 was real, the level achieved by oral recipients (12.4 μg/ml) was still adequate (>60). Biological variability and the time lag between changes in retinol adequacy in target cells and serum levels of holo-RBP precludes defining a serum holo-RBP level above which clinical disease does not occur and below which it invariably does. Figure 13-4 presents initial serum holo-RBP levels in clinically normal (but, due to the clustering effect, probably vitamin A deficient) matched controls of corneal cases and patients with xerophthalmia (Studies II-III) of varying severity. Although levels among the matched controls span a wide range, all are greater than 3 μg/ml, and 74% (20/27) are greater than or equal to 5 μg/ml. By contrast, levels among cases of severe xerophthalmia (corneal necrosis, categories 6–8) are all below 5 μg/ml, and in 93% (27/29) below 3 μg/ml. It appears that levels of 3–5 μg/ml are probably reasonably safe, at least transiently, though not necessarily chronically where serum holo-RBP might more accurately reflect retinol depletion in target cells and an acute precipitating event might suddenly depress levels even further, resulting in corneal necrosis.

Although the *mean* level among double-dose oral recipients was clearly adequate at day 14, the same cannot be said for each individual case. To estimate the proportion of patients within the danger zone (below 3–5 μg/ml) with better precision, a larger number of patients is included in the analysis: 4 all cases in the trials, even if only a single holo-RBP determination is available; 2 cases in which both eyes had total corneal necrosis formerly excluded because their clinical response was not determinable, and 3 single-dose recipients at T_0, T_1, and T_{14}, since therapy at these intervals was identical to that of double-dose recipients. Initial levels (T_0) among this subset of oral and parenteral recipients (Fig. 13-2) is, as expected, extremely low, only 10% being < 3 μg/ml, of which 2.3% were < 5 μg/ml. By 14 hours 94% (29/31) of oral recipients and 90% (19/21) of parenteral recipients had values < 3 μg/ml, and 90% and 81% values < 5

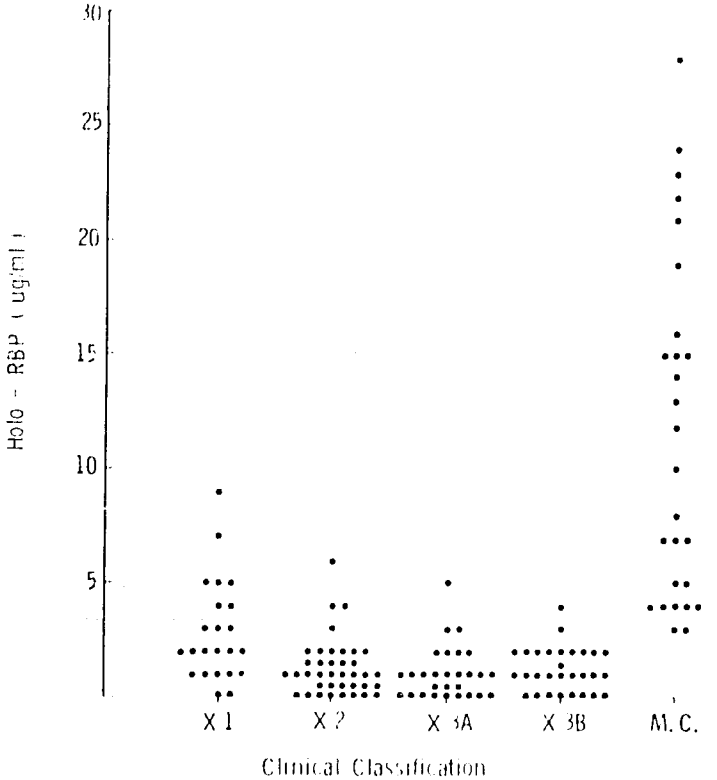

Fig. 13-1. Initial serum holo-retinol binding protein levels among controls were all above 3 μg/ml, and in 74%, 5 μg/ml or greater. Among the vast majority of corneal xerophthalmia cases (X2, corneal xerosis, X3A, ulcers, X3B, necrosis) the levels were below 3 μg/ml. (Studies I, II, III). (From Sommer et al. [460])

μg/ml respectively. At 24 hours, when the mean level among oral recipients had dropped below that of parental recipients, 94% of oral recipients still had levels > 3 μg/ml and 78% > 5 μg/ml. Levels among all parenteral recipients were above 5 μg/ml, though the situation is reversed at days 3 and 7. These minor differences seem to have had no practical effect, since clinical response in the two groups of double-dose recipients was identical.

The pattern of serum holo-RBP response provides further insight into the metabolic processes taking place. Among double-dose oral recipients the response is clearly multiphasic, the greatest net increase in circulating holo-RBP occurred at $T_0 - T_1$ ($p < .001$ by grouped comparison). Paired comparisons between individuals with values available for adjacent deter-

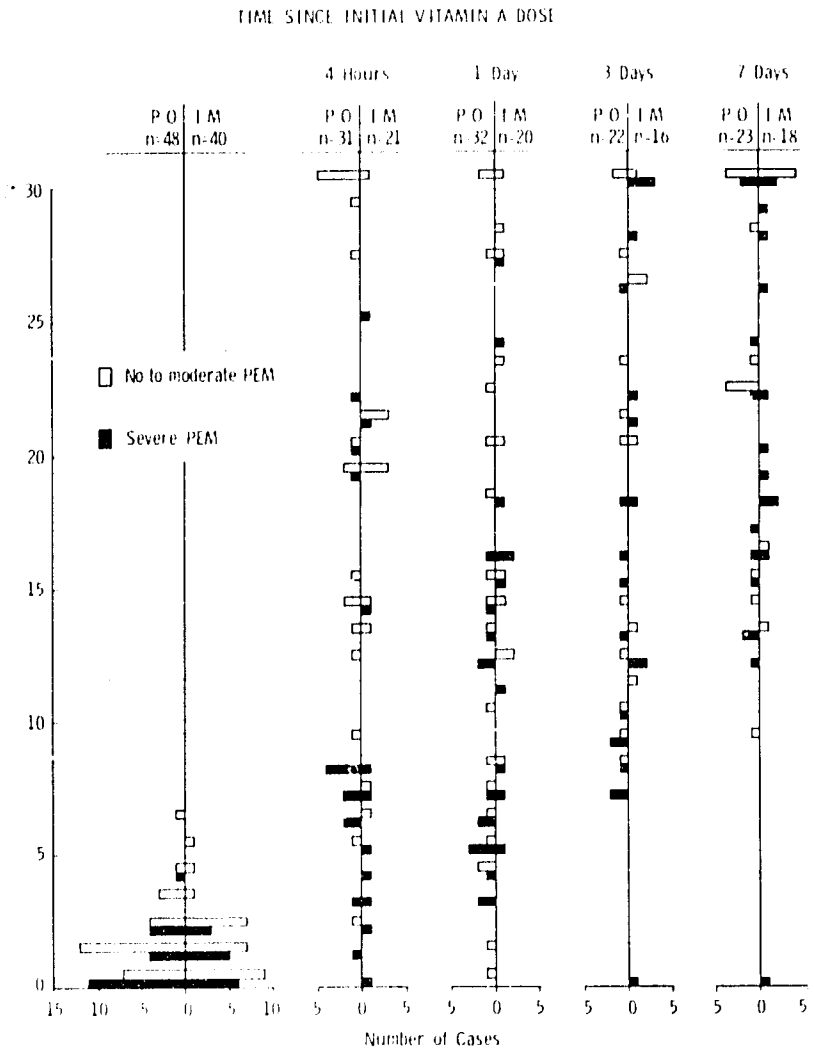

Fig. 13-2. Within 4 h of receiving a massive oral (200,000 IU oil-miscible) or intramuscular (100,000 IU water-miscible) dose of vitamin A, over 90% of cases of corneal xerophthalmia achieved a holo-retinol binding protein level of 3 μg/ml or higher. Levels rose further following a second dose, at 24 h. Study II. (From Sommer et al. [460])

minations indicate a drop of 7.4 ± 2.8 μg/ml ($\mu \pm$ SE, $p = .02$) between T_0 and T_{1d}, a second rise of 9.2 ± 4.14 ($\mu \pm$ SE, $p = .05$) between T_{1d} and T_{3d} followed by a slightly smaller rise between T_{3d} and T_{5d} statistically significant by grouped ($p = .001$) but not paired comparisons. By contrast, the response among parenteral dose (IM-PO) recipients did not drop in overall values; instead, there was the same (though less extensive) rise between T_0 and T_1 ($p = .001$ by grouped comparison), a further rise between T_1 and T_{1d}, plateau between T_{1d} and T_{3d}, and further rise between T_{3d} and T_{5d}. The overall increase between T_1 and T_{5d} was statistically significant ($p = .05$ by grouped comparison). None of the individual interval changes (except T_0–T_1) was statistically significant by paired or unpaired comparison. Absence of the statistically significant decline in serum holo-RBP observed among oral-dose recipients at day 1 suggests that the supranormal vitamin A levels achieved by parenteral dosing may have been more effective at promoting continued holo-RBP release.

The early pattern and magnitude of holo-RBP response was affected by baseline protein status [460]. All corneal cases eligible for inclusion in Fig. 13-2 were separated, on the basis of their initial serum albumin, into four groups (Table 13-11). Each individual's interval change in holo-RBP, and the mean of these individual changes (μ), was calculated. Mean initial holo-RBP levels of individuals included in the T_0–T_1 change are also presented for comparison. The smaller number of IM-PO recipients precludes estimates for some cells. By limiting analysis to the first 24 hours, single-dose and double-dose recipients can be pooled, and the effect that feeding might eventually have on protein synthesis ignored.

A statistically significant holo-RBP response was elicited at T_0–T_1 regardless of protein status ($p = .001$ – $p = .05$). The magnitude of the response was entirely independent of the route of administration but was directly related to protein status ($r = 0.9586$, $p = .02$ for oral recipients; $r = 0.9700$, $p = 0.1$ for the fewer cells among parenteral recipients).

The response at T_1–T_{5d} was more complex. Among both oral and parenteral recipients the net change in holo-RBP was inversely related to protein status ($r = -0.996$, $p = .001$ and $r = -0.983$, $p = .05$ respectively). Those with the highest serum albumin, and greatest rise in holo-RBP at T_0–T_1, now experienced the smallest rise. In this instance, however, the route of administration affected outcome. Oral recipients in the 3 highest albumin categories suffered a net decline in serum holo-RBP equivalent to 41–55% of their initial rise. By contrast, parenteral recipients either maintained the same level or registered a further rise in serum holo-RBP.

Table 13-11. Holo-RBP response in corneal cases of varying protein status (Study II)

Time since dose (h)	Serum albumin (g/100 ml) >3.5	3.4–3.0	2.9–2.5	<2.5
Oral dose[1]				
0 *n*	9	6	6	6
$\bar{\mu}$	1.7	1.3	0.3	1.3
SD	1.4	1.2	0.5	1.0
0–4 *n*	9	6	6	4
$\bar{\mu}\Delta$[a]	+26.2**	+14.5**	+8.7**	+5.8**
SD	17.2	3.4	5.0	1.7
4–24 *n*	10	4	7	3
$\bar{\mu}\Delta$[a]	−10.7*	−8.0*	−3.6	+0.3
SD	15.2	4.2	6.0	3.2
IM dose[1]				
0 *n*	2	6	9	–
$\bar{\mu}$	0.0	1.3	0.9	–
SD	0.0	0.8	0.9	–
0–4 *n*	2	6	9	
$\bar{\mu}\Delta$	+26.5**	+12.3**	+6.7*	–
SD	7.8	6.3	8.2	–
4–24 *n*	1	8	6	–
$\bar{\mu}\Delta$	3.0	+1.1	+9.2*	–
SD		7.0	8.9	–

1. Oral: 200,000 IU oil-miscible vitamin A PO at time 0. IM: 100,000 IU water-miscible vitamin A intramuscular at time 0. Some cases received a second dose after 24 blood drawn. $\bar{\mu}\Delta$ are all paired comparisons. Cases at 0 h are those available for paired comparison at 4 h. $\bar{\mu}\Delta$ correlated with serum albumin category.
oral change at 0–4 h: $r = .9586$, $p < .02$; change at 4–24 h: $r = .9957$, $p < .001$; IM: change at 0–4 h: $r = .9700$, $p < .1$; change at 4–24 h: $r = .9826$, $p < .05$.

* net change: $\bar{\mu}\Delta$: $p < .05$
** net change: $\bar{\mu}\Delta$: $p < .01$

Data from Sommer et al. [460].

When rats are deprived of vitamin A, serum RBP falls [283,294] by 75%, the remainder being denatured apo-RBP incapable of combining with retinol [65,66]. At the same time, apo-RBP accumulates in the liver, reaching 4 times normal levels [283]. On administration of vitamin A, newly available retinol combines with stored apo-RBP and the resultant holo-RBP pours forth from the liver. After peaking at 2–5 hours [283,294,461], serum RBP levels decline, by 24 hours, to a more normal steady state [283,294]. Rats suffering combined protein and retinol deficiency respond in much the same way, though the magnitude of the 4-hour peak is lower [294].

Our patients responded in almost identical fashion: holo-RBP levels peaked at 4 hours, the magnitude of the response being directly related to protein status. Presumably the better the protein status, the more apo-RBP had accumulated in the liver. By 24 hours, serum holo-RBP levels among oral recipients declined, suggesting that baseline apo-RBP synthesis could not support holo-RBP release at this same rate. Large et al. [66] observed the same phenomenon under similar study conditions.

Since the magnitude of the drop in holo-RBP at T_{24} was related to protein status (Table 13-11), it would seem original RBP stores, and initial rate of holo-RBP release among severely protein-deficient children, were more in line with synthetic capacity than among children of better protein status, though decreased metabolism of holo-RBP might have played a role [293,294]. Despite poorer apo-RBP stores, protein-deficient children were able to elevate their serum holo-RBP levels above baseline at both 4 hours and 24 hours after receiving an oral dose. The rise in physiologically active holo-RBP can be masked by the presence of incompetent, denatured apo-RBP if only total (immunologically detectable) RBP is measured [66,462,378]. Although protein deficiency may limit retinol and RBP response [66,278,279,458,463] it clearly does not eliminate it [460].

Parenteral recipients in our series demonstrated the same general pattern of response, but the decline at T_4–T_{24} was much less pronounced, especially among those having poor protein status. If this was not laboratory artifact (as suggested by J. Glover, personal communication), availability of vitamin A might also be rate limiting, and the supranormal levels achieved by this route better able to sustain high levels of holo-RBP release. Although there are discrepancies in the T_0 vitamin A levels reported by Reddy et al. [60], the response of their severe PEM group (17/20 of whom were said to have corneal xerophthalmia) to intramuscular administration of 100,000 IU water-miscible vitamin also lacked the biphasic pattern of our oral recipients.

Whether or not serum holo-RBP declines between T_4 and T_{24}, it certainly rises between Days 1 and 7 (see Table 13-9) [66,378,462]. Essentially all children achieved "safe" levels by day 3 (Fig. 13-2). No doubt some of the rise is consequent to the effect of improved diet on general protein status [378]. But specific, delayed stimulation of apo-RBP synthesis by vitamin A probably plays a role. The clearest example is Case 200/011 already described. He refused hospitalization and received only a single oral dose. Despite severe, persistent protein deficiency (albumin consistently below 1.5–1.7 g/dl and transferrin below 20–25 mg/dl) the fa-

nular biphasic holo-RBP response occurred (see Table 13-3). This is the only instance in which we can completely isolate the response from other variables. Additional, if less conclusive, evidence is provided by five corneal cases, one with depressed protein status (initial albumin 2.7 g/dl, transferrin < 20 mg/dl) and four with more normal status (albumin > 3.0 g/dl, transferrin > 200 mg/dl) who refused hospitalization and received double-dose oral therapy. Four of the five displayed the biphasic response; so did pooled comparisons from seven to eleven double-dose oral recipient corneal cases with initial serum albumin levels > 3.5 g/dl, all but one of whom were hospitalized (Table 13-12). It is unlikely that improved diet would have had much of an effect on the protein status of the latter group, or that the second vitamin A dose (administered on day 1) which raised their mean serum holo-RBP from 18.3 μg/dl on day 4 to 22.9 on day 3 could explain the rise to 31.0 by day 7 (a difference however which does not reach statistical significance).

The effectiveness of massive oral dosing is hardly surprising. Total vitamin A in the liver of a well-nourished 7.5 kg child is roughly 30,000 IU [204], one seventh the amount in a single capsule. Under normal circumstances 50% of a massive oral dose is retained [464,465]. Even if absorption drops because of PEM [458], diarrhea [321], worm infestation [380, 382,384], and the like to 20–30% as Olson suggests [53], this would still supply all the vitamin A required. Animal studies indicate that the proportion of the total dose deposited in the liver following an oral oil-miscible dose is at least as great as that following a parenteral water-miscible one [457], and that despite absence of a significant rise in serum vitamin A following oral or IM dosing in severe protein deficiency, the added vitamin A is stored in the liver. Even so, the difference in vitamin A response among single-dose and double-dose recipients, and early relapse occasionally encountered among severely protein-deficient children, suggests that administration of a second dose, at 24 hours, is to be preferred.

Whether one employs the double-dose parenteral (IM-PO) or purely oral (PO-PO) regimen appears to make as little difference biochemically as it does clinically.[1] Toxicity from either regimen is minimal. Not a single case developed symptoms of acute toxicity. Only 2/30 (6.7%) of cases with reasonably clear corneas (X2) reexamined within seven days of therapy developed transient papilledema: one, a six-year-old, had received double-dose

[1] This conclusion is reflected in the 1981 revision of the WHO recommendations for therapy of xerophthalmia (Appendix II).

Table 13-12. Holo-RBP response among corneal cases with initial serum albumin levels <3.5 g/dl who received double-dose oral therapy (Study II)

Duration since therapy	Serum holo-RBP (μg/ml)			
	Number	$\bar{x}$	SD	Median
0 hour	8[1]	1.8	1.5	1.2
4 hours	11	27.2	18.1	27
1 day	9	18.3	13.2	18
3 days	9	22.9	15.6	20
7 days	7	31.0	9.3	32

1. Only includes cases with values at one or more subsequent periods

oral therapy; the other, a four-year-old, 200,000 IU oil-miscible vitamin A intramuscularly. A 24-year-old well-nourished woman with extensive corneal xerosis developed asymptomatic papilledema after receiving an oily injection of 200,000 IU followed by two oral doses one day apart [104]. Four vitamin A responsive cases of conjunctival xerosis developed transient papilledema after receiving a single oral dose. Finally, a malnourished three-month-old baby inadvertently received two oral doses; although he did not develop papilledema he did develop a bulging fontanelle, suggesting transient elevation in intracranial pressure. Administration of 300,000 IU oil-miscible vitamin A as a single dose to preschool-age children at large caused transient signs of acute toxicity in only 4% [424], vs 25% after oral administration of a water-miscible dose of the same size [466]. Bagchi appears to have given children with Bitot's spots 50,000 IU PO each day for 28 weeks without untoward effects.

Protein and calories

In most cases of severe PEM, xerophthalmia will respond to isolated administration of vitamin A (compare Tables 13-5 and 13-7). Mori noted clinical improvement "soon after" administering cod liver oil to children with kwashiorkor. Reddy [60] described corneal xerosis disappearing after giving vitamin A to children with PEM who refused hospitalization. Retinol can certainly enter at least some cell lines even when unattached to transport RBP [288].

But the clinical response among cases with severe PEM need not be as rapid, nor, more importantly, as sustained, as in better nourished individ-

nals [460]. Case 200/011 was probably the clearest example of the risks inherent in failing to correct underlying PEM. Even double-dose therapy fails to eliminate this differential response. Among cases of X2, PEM was present in 78% of cases with transient initial "worsening," and 100% of cases that relapsed within two months, percentages which are statistically significantly ($p < .01$) higher than among cases suffering neither of these reverses (Table 13-13). Presence of gastroenteritis did not have the same significance.

A similar situation prevailed among cases of X3 (categories 4–7), though analysis is more complex: all cases that did poorly suffered initial "worsening"; and all either received additional vitamin A, died, or relapsed. PEM was present in all such cases (Table 13-13), at a rate twice that among those who did well. (With the small numbers involved this difference just misses statistical significance).

Although the presence of PEM clearly has a deleterious effect on corneal healing, the practical consequences should be kept in perspective. In 74% (43/58) of PEM cases receiving double-dose therapy the corneas healed without incident. Due to the higher mortality among poor responders/relapsers, only 8% (4/51) of PEM survivors suffered significant

Table 13–13. Risk factors among double-dose recipient corneal cases with poor therapeutic response (Study II)

Clinical category[1]	Total cases	PEM[2]		Diarrhea[2]		Mortality	
	n	*n*	(%)	*n*	(%)	*n*	(%)
X2 (grades 1–3)							
deterioration	9	7	(78)	3	(33)	1	(11)
relapse	3	3	(100)	1	(33)	3	(100)
total reverses	12	10	(83)*	4	(33)	4	(33)*
uneventful cure	52	18	(35)*	17	(33)	0	(0)*
X3 (grades 4–7)							
clinical reverse	5	5	(100)	3	(60)	1	(20)
uneventful cure	45	25	(56)	17	(38)	2	(4)
Total (grades 1–7)							
clinical reverse	17	15	(88)*	7	(41)	5	(29)*
uneventful cure	97	43	(44)*	34	(35)	2	(2)*

1. Deterioration: initial deterioration followed by recovery; relapse: cure followed, within 2 months by deterioration; cure: uneventful healing without relapse within 2 months.
2. Defined as in Tables 13–6 and 13–7.
* Difference between those with and without clinical reverse, $p < .01$.

From Sommer et al. [460].

additional corneal damage after receiving the first of their two doses. Many of these cases were hospitalized where they received a high protein diet, however, so the situation is not strictly analogous to isolated vitamin A therapy.

The relapse rate was significantly higher among corneal cases with PEM who received only a single dose of vitamin A (PO or IM) than among those who received two doses (3/8, 38% vs 6/58, 10%; $p < .05$).

These clinical results are in accord with the biochemical data already discussed. There seems little doubt that correction of underlying PEM is critical to the maintenance of corneal improvement, and that repeated massive dosing with vitamin A (every two weeks) is advisable until protein status improves.

Topical vitamin A

Despite its long popularity as a folk remedy [1,451], topical administration of vitamin A is neither recommended nor employed by most experts. Systemic administration, required to reach distant sites and build up liver stores, also induces corneal healing [18,114,290,454,456]. Unfortunately, the corneal response to systemic therapy is often delayed two to four days, during which time the cornea may deteriorate further [190,247, 290,455,467] (Tables 13-5 to 13-7), especially among children with severe PEM. Price [468] suggested that PEM-associated depression of RBP synthesis might be responsible for this delay and demonstrated that topically applied retinoic acid had a beneficial effect on the cornea of vitamin A depleted rats. Retinoic acid supports normal epithelial differentiation [103] and apparently does not circulate in association with a specific transport protein [469,470].

A controlled clinical trial of topical retinoic acid as an adjunct to systemic therapy was carried out on cases in Study II. A 25 μl drop of 0.1% retinoic acid in arachis oil was applied to one eye, and the arachis oil alone to the other at a rate of one drop, eventually increased to three drops, per day. Preliminary results [247] demonstrated that conjunctival xerosis, and corneal xerosis and ulceration, improved more rapidly in eyes receiving retinoic acid than in those receiving the placebo, results subsequently confirmed in xerophthalmic rabbits [471]. Additional cases we studied since our original report confirm these findings, and indicate, in addition, that:

1. Conjunctival inflammation is common when the frequency of administration is increased from three to five drops per day.

2. Although ulceration heals more quickly, eyes receiving retinoic acid occasionally develop denser scarring.
3. More rapid healing induced by topically administered retinoic acid rarely makes a clinically significant difference in ultimate corneal recovery and visual outcome.

These results suggest that topical administration of retinoic acid should not exceed three drops/day and should be reserved for eyes without central ulceration (or for one eye of cases with central ulceration in both) to ensure that at least one eye will remain intact, even if at risk of heavier scarring). Under field conditions, where it is likely to be difficult to maintain sterility and adequately supervise administration of the drug, complications may outweigh benefits.

The exact mode of action is uncertain; specific retinoic acid receptors have not been identified in the epithelium of the cornea, although they have been found in the conjunctiva [472], and topically applied retinoic acid reportedly stimulates re-epithelialization of the mechanically denuded cornea of normally nourished, non-vitamin-A-deficient rabbits [473]. Whether retinoic acid offers any advantages over ordinary preparations of vitamin A (retinyl esters) is equally unclear: Parnell et al. [420] found that topically administered vitamin A had a beneficial effect on corneal epithelium in vitamin-A-deficient rats. Bors et al. [111] reported that vitamin A drops (150,000 IU/ml) administered every two hours led to symptomatic improvement in their single case, but so did topical chloramphenicol [115], suggesting a local lubricant effect of the vehicle.

Surgical intervention

In general, active xerophthalmia does not lend itself to surgical intervention. Ben-Sira et al. [350] reported successful use of "covering grafts" in children with active xerophthalmic corneal ulceration. In 48/50 eyes, the anterior chamber was eventually restored. In 41/50 with eccentric ulcers the corneas eventually healed with clear pupillary zones. These results are no different from those of our (entirely nonsurgical) series. The vast majority of ulcers are eccentric, become plugged with iris, thereby preserving the anterior chamber, and heal rapidly on vitamin A therapy.

Complete corneal necrosis precludes any possibility of grafting. In those few instances in which localized ulcers are too large or central for spontaneous maintenance or restoration of the anterior chamber, the angle is usually already lost by the time the child first presents.

14. Prevention

> I am sometimes struck by the volume and elegance of scientific research on nutrition on the one hand and by the fumbling and clumsy methods which we follow in trying to prevent deficiency disease and raise levels of nutrition on the other.
>
> W.R. Ackroyd, 1958

> Although almost all mothers, when questioned about what they should feed their children would rattle off the general diet advised by the NRC, the number who actually followed these instructions to any extent was disappointingly low.
>
> G. Venkataswamy, 1979

> Green leafy vegetables are unbottled medicines.
>
> E.V. McCollum, 1925

That many factors influence vitamin A status is both a curse and a blessing: it accounts for the enormous size of the problem but at the same time provides multiple avenues for attack. Control of contributory and precipitating disease may have a dramatic impact on the problem. In a large proportion, perhaps a majority, of surviving children blinded by xerophthalmia in Indonesia, corneal destruction was precipitated by measles. An effective measles vaccination program would probably reduce the numbers appreciably. But only by ensuring that children receive adequate supplies of vitamin A will the basic underlying cause of the problem be removed.

In general, three techniques have been tried, with varying success, for increasing vitamin A intake: periodic administration of large doses of vitamin A, addition of vitamin A to one or more commonly consumed items (fortification), and increasing the amount of vitamin- and provitamin-A-rich foods in the diet [152,474].

Periodic dosing

Periodic dosing takes advantage of the fact that large quantities of vitamin A can be banked away in the liver for future use. It will be recalled that well-nourished adults reared on normal Western diets require years to become depleted [90,91,115]. This suggested the possibility of periodically "immunizing" children with large doses of vitamin A. Because of the logis-

tical problems involved, it was hoped that it would be unnecessary to dose the children more than once or twice a year. But children's livers are smaller than adults', the amount of vitamin A absorbed is inversely related to the size of the dose and influenced by the presence or absence of concomitant illnesses [321,464,465], and, most critical of all, there are limits to the amount of vitamin A that can be safely administered at any one time [424,465,475,476].

Vitamin A requirements of children have been largely extrapolated from studies on a limited number of healthy adults [477]. In a classic experiment it was concluded that 4300 IU retinol per day was the absolute minimal requirement for a healthy adult. Given biological variability and the effects of disease and metabolic status, the minimal recommended daily allowance (RDA) was set at twice this amount, 2500 IU/day [90]. FAO recommended a RDA for children up to nine years of age of 250–400 μg (825–1320 IU) per day [478,479]. More recent work suggests that this may be a moderate underestimate [91].

Assuming a RDA of 2500 IU/day and 50% retention of a massive dose [464,465], 300,000 IU were expected to "top-up" dietary supplies by an average 400 IU/day for one year [424]. This proved overly optimistic: infections and infestations, generally common in the target population, guarantee that less will be ordinarily absorbed, and the rate at which vitamin A leaves the liver is related to the size of liver stores (with $T_{1/2}$ of roughly 50 days) [53]. Although oil-miscible vitamin A enters liver stores as readily as water-miscible preparations [457], with lower risk of toxicity [424,466], even the 4% incidence of transient diarrhea and vomiting associated with the 300,000 IU oil-miscible dose discourages community participation [424]. As a result, an oral regimen of 200,000 IU oil-miscible vitamin A, every six months, has been widely adopted.

Oral administration of 150,000–300,000 IU reportedly fails to maintain normal serum vitamin A levels for more than one to three months [416,480–482], perhaps because of extremely low vitamin A content of the basal diet [308]. Strictly controlled trials indicate that administration of 200,000 IU every four to six months protects the recipient from mild xerophthalmia (XN, XI) [69,141,483]. Less well controlled observations of actual field programs suggest similar levels of efficacy [422,484,485]. Logistical difficulties and ethical considerations preclude concurrent, prospective controlled study of the value of periodic massive dosing for preventing serious corneal disease. However, introduction of mass distribution programs in El Salvador [338], India [G. Venkataswamy, personal communication], and Bangladesh [M. Jalil, personal communication] have not been accom-

panied by a reduction in the number of cases presenting to clinics and hospitals. Several factors could account for this. Hospital statistics might not represent what is happening in the community, children at greatest risk may be just those missed by the distribution mechanism, or the severity of their vitamin A deficiency, general malnutrition, and concomitant illnesses might render the capsules ineffective.

Results of the hospital based Indonesian studies (Studies II-III) suggest that the vast majority of corneal cases would be prevented if children regularly received 200,000 IU vitamin A. Almost all children with severe corneal disease responded rapidly to vitamin A therapy (Chap. 13). If vitamin A can cure established corneal disease, it should also prevent its occurrence, especially since periodic dosing should prevent serum vitamin A levels from ever falling so low. However, this analysis is complicated by the fact that most children with corneal disease also received supportive therapy. But not all. A total of 22 cases refused hospitalization and therefore received only vitamin A (7 a single 200,000 IU dose, 15 a second dose the following day). Ten of these 22 were severely malnourished (seven having frank pedal edema) and 11 had stromal involvement. In all 22 cases the cornea improved or healed completely, indicating that isolated vitamin A therapy will indeed prevent corneal xerophthalmia. One question remains: for how long?

Two cases, both showing corneal improvement by day 3 (one having received a single capsule, the other two capsules) subsequently agreed to hospitalization. A third, also showing improvement (on two capsules) was lost to follow up and died at three weeks. Of the remaining 19 cases followed without hospitalization for 0.5–4+ months (mean 7.6 months; two-thirds > six months) only one suffered significant early relapse. This child (case 200.011) was severely malnourished (albumin 1.5 g/dl). After healing completely, bilateral ulcers returned 16–23 days after he received his single dose. Healing commenced within a day of receiving a second dose, but the child died two days later. None of the other cases relapsed within 6 months, although 1 severely malnourished child developed corneal xerosis 8 months after receiving a single capsule, and an additional severely malnourished child developed nightblindness 13 months after receiving two doses. Hence, only 1 out of 19 (5%) cases (0/18 survivors) with extended follow up suffered a corneal destructive relapse within six months of receiving one to two massive doses of vitamin A for severe xerophthalmia. Children who received two capsules or who were not severely malnourished fared better than their less fortunate peers.

This is a "worst case" test. Distribution programs should theoretically

reach children before they become anywhere near this depleted. Perhaps long-term follow-up on the 14 who received two capsules a day apart (an additional fifteenth case was one of those hospitalized on day 3) provides a closer approximation. One died (after healing at three weeks) and only one relapsed at all (the child who developed nightblindness at 13 months).

Individuals who continue to receive a diet markedly deficient in vitamin and provitamin A may relapse within 12 months of receiving massive therapy. This occurred in two individuals examined before Study II began. One was a four-year-old boy who presented with kwashiorkor and corneal xerosis. Bitot's spots and corneal xerosis returned eight months after administration of a single capsule. The second was a 24-year-old otherwise well nourished woman (104). She received 100,000 IU oil-miscible vitamin A intramuscularly plus two massive (200,000 IU) oral capsules for severe corneal xerosis. When examined a year later nightblindness, Bitot's spots, and xerophthalmic retinopathy had all returned.

The relapse rate among children with Bitot's spots (Study III) treated with a single oral dose may be most analogous to the potential efficacy of periodic massive dosing for the *prevention* of xerophthalmia. A modified life table analysis (Table 14-1) indicates that protection should last at least six months, and remain substantial considerably longer. All children were accounted for by home visits at the end of the study, although not all returned for each monthly examination (see methods).

The vast majority of children receiving 200,000 IU vitamin A every six months should therefore be protected from severe corneal xerophthalmia. Although adequacy of the basal diet and prevalence of generalized malnutrition and systemic infections may influence results, the major problem is in reaching the children at greatest risk. No matter how well conceived and organized, programs rarely reach more than 80–90% of the children

Table 14-1. Relapse rate of clinical xerophthalmia (Study III)

Follow-up months	Eligible For exam	Examined		Relapsed		
	n	*n*	%	*n*	(%)	Cum. %
1–2	48	33	68.8	0	(–)	
3–4	47	20	42.6	0	(–)	
5–6	41	19	43.2	0	(–)	
7–10	35	19	54.3	1	(5.3)	5.3
11–14	24	18	75.0	1	(5.6)	10.9

on the first round, with coverage invariably falling on each subsequent round [338,429,483,486–488]. Results from other public health programs suggest that those missed are likely to be the ones at highest risk [489]. In addition, the cost of distribution can be excessive. Where distribution is accomplished through existing health channels it may only be a few cents per child, but where entirely new, single-purpose workers need to be employed the cost can be many times higher [486].

One method for increasing efficiency, and even efficacy, is by targeting distribution to those children at greatest risk. Since children with diarrhea, respiratory tract infection, generalized malnutrition, severe systemic illnesses, measles, and so forth are at particularly high risk of xerophthalmic corneal destruction, administering vitamin A to all such children, wherever encountered in the medical network (from the village-level health or family planning worker up through the referral hospital) should have a high benefit/cost ratio. Of course, children not encountered by medical workers will remain unprotected. The tendency for vitamin A deficiency to cluster in "space" (Chap. 10) may also be capitalized upon. Vitamin A distribution (as well as nutrition education, fortification, etc.) can be targeted to geographically defined high-risk groups: regions [274,337,490], villages, or even neighborhoods where the prevalence of xerophthalmia is particularly high. Since children living in the same neighborhood as an active, clinically recognized case are at higher risk of disease than those living further away, it may prove more effective, and efficient to treat the entire neighborhood rather than just the active case.

Massive doses and geographic targeting can be combined with innovative screening programs. The problem lies in recognizing mild xerophthalmia. All children with Bitot's spots or more severe disease should obviously receive vitamin A. But this requires that highly trained observers examine every child, which may be more costly and less efficient than simply supplying all children with a capsule. In many areas where xerophthalmia is prevalent, nightblindness is well recognized, with specific terms describing its presence [45,77,105,274,426]. Study I demonstrated that the sensitivity and specificity of a history of nightblindness could be extremely high (Chap. 2). Although specificity appeared to be equally high throughout Indonesia, sensitivity was not. Sixty-one percent of the cases of Bitot's spots in Round 1, Study I (located in West Java) had a history of nightblindness. In the countrywide survey (Study IV) the proportion varied from 10% to 76% (Table 14-2). Reassuringly, the rate in West Java was again 61%, even though three teams, all different from that in Study I, collected data inde-

Table 74-2. Proportion of cases of Bitot's spots with a history of nightblindness (Study IV)

Geographic area	Cases of XIB n	History positive for XN n	%
Urban	83	39	47.0
W. Java	62	38	61.3
C. Java	45	34	75.6
E. Java	31	4	12.9
Bali	11	3	27.3
Lombok	37	17	45.9
Sumatra	38	25	65.8
Sulawesi	17	7	41.2
Kalimantan	13	9	69.2
Ambon	21	2	9.5

pendently of one another. The marked variation in sensitivity from one region to another may reflect the degree to which inhabitants recognize the condition, or the difficulty that the teams, all from West Java, had in identifying locally appropriate terms. Village-level health workers are unlikely to experience this problem, though in some areas the local term may be inappropriate, and a description of the condition required. Cobb [354] found that the term used in the Luapula Valley to describe nightblindness also referred to cataracts. Analyses of published data suggest that a history of nightblindness may be as sensitive in other countries as in West Java, and even more specific than the presence of Bitot's spots. Prior to initiation of a pilot intervention program in Cebu, the Philippines, the prevalence of nightblindness was 1.5 times that of Bitot's spots [483]. After intervention both rates fell, but nightblindness fell by much more, suggesting that many of the Bitot's spots had been persistent, inactive lesions, as documented in Bengal [141]. Venkatachalam [134] reported that 54% of Indian children with conjunctival lesions were nightblind, a figure very close to that of West Java, which is surprising given the high proportion of inactive spots in that population. Similarly, in a baseline survey Swaminathan [424] found that the prevalence of nightblindness rose from 0% at ages zero and one to 2.5% by age five, vs rates for Bitot's spots of 0.8% and 7.5% respectively. After periodic massive dosing, the rate for Bitot's spots fell by only 50%, and by even less in the older age group, again suggesting a large proportion of inactive lesions. It is not clear whether Swaminathan's classifications of

nightblindness and Bitot's spots were mutually exclusive; if they were, total nightblindness rates would have been still higher. Even so, surveys in Bangladesh [432], Sri Lanka [274], the Philippines [273], and Jordan [296] all record nightblindness rates comparable to, or greater than, those for Bitot's spots. In a survey in northern India [183] the prevalence of nightblindness was the same as that of bilateral Bitot's spots (cases of unilateral X1 were probably not actively vitamin A deficient). Among East Africans examined by Mackenzie in the 1930's [170], formation of Bitot's spots was always preceded by nightblindness.

When children with positive histories for nightblindness were tested in West Bengal [426] and Kenya [45] they invariably proved to be nightblind.

Fortunately, the high specificity of a history of nightblindness makes it unnecessary to confirm its presence by objective assessment of dark adaptation. Despite ingenious attempts [491], it is still impractical to precisely measure dark adaptation in children below six to seven years of age [155,160,272,492]. If one could, the prevalence of clinically detectable hypovitaminosis A would probably be much higher. Chou [102] found that 13 of 20 patients with early ocular signs of vitamin A deficiency had impaired dark adaptation, but only four complained of nightblindness; in the Sheffield study only two adult subjects thought they "might have noticed" impaired dark adaptation, at rod thresholds 1/10 and 1/100 their initial levels; and it has already been noted that nightblindness was so prevalent among pregnant Indian women that they did not bother to report its presence [99]. In fact, Bitot's [7] primary interest in conjunctival lesions lay in their potential for objectively "making a diagnosis of nightblindness, whereas we are at present at the mercy of the patient's affirmations and reports."

Nightblindness screening may be especially unhelpful in urban areas. The ratio of XN to XB in an Indonesian study [69] was 67:66 in a rural area, but 0:53 in an urban. Whether the difference is related to greater exposure to bleaching sunlight in the rural area, the presence of municipal lighting in urban areas, or some other factor is uncertain.

Despite potential limitations in sensitivity, a history of nightblindness appears to be an easily elicited, highly specific means of identifying large numbers of early xerophthalmia cases, and the high-risk neighborhoods within which they reside. Unfortunately, nightblindness is rarely detected in children below one year of age; since they have not yet begun to ambulate, or feed on their own, the presence of impaired dark adaptation is less apparent.

The proportion of potential corneal cases detected by periodic screening will depend upon the frequency with which it is performed. Study I children were reexamined, on the average, every 2.5–3.5 months. Almost half (47%) of those who eventually developed corneal disease lacked evidence of mild xerophthalmia (X1/XN) during any of the (1–6) preceding rounds. Only 35% had evidence of xerophthalmia during the immediately preceding round. Sensitizing the population to the dangers of xerophthalmia, for example by teaching school children to detect nightblindness in younger siblings and reporting such cases as soon as they arise, may prove more effective than periodic examination by medical workers.

Finally, massive dosing may prove effective in at least one "captive group": newborn babies and their mothers [493]. Births are usually attended by some health professional, commonly a traditional midwife, and these may be instructed in the administration of large doses of vitamin A. Newborn infants do not absorb vitamin A as well as older children [494] and are more susceptible to toxicity following very large doses [484]. But they can safely receive 50,000 IU without untoward effects, producing a net rise in serum vitamin A for at least six months [389]. Administration of 300,000 IU to mothers increases vitamin A content of the breast milk, and serum vitamin A of the child, for an equal period [389]. Giving the vitamin A directly to the child ensures that he or she will get some boost in liver reserves, even if breast feeding is discontinued. Giving it to the mother at the time of delivery ensures that these reserves will continue to be augmented, if the infant is breast-fed, for at least six months.*

Fortification

Fortification offers an alternative method of delivering vitamin A to target children, more regularly and without seeking them out. It has the added advantage of increasing vitamin A intake of pregnant and lactating mothers and thereby neonates and breast-fed infants, without risk of teratogenicity (a potential but unproven hazard of massive dosing during early pregnancy). Fortification is commonly practiced in developed countries; it was fortification of margarine that eventually stopped the xerophthalmia epidemic in Denmark.

A wide variety of items can be fortified with vitamin A [495]. But to be effective the vehicle must reach a significant proportion of the target population, and for practical reasons, must be processed at a limited number

*This conclusion is reflected in the 1981 revision of the WHO recommendations for prophylactic use of massive dose vitamin A.

of central sites where the fortification can be carefully monitored and controlled. These considerations alone place heavy constraints on the eventual choice of vehicle, especially since rural impoverished families, from which most xerophthalmia cases arise, consume few centrally processed items. Carefully conducted dietary studies are required to identify items meeting these minimal criteria.

Baseline surveys in Guatemala [297] indicated that 80% of rural children consumed processed sugar. Pilot studies demonstrated that a vitamin A "premix" could successfully be added to the sugar during the refining process; that little settled out or was lost in storage; and that the color and taste of the final product was acceptable to the population. Even though the investigators did not know ahead of time the proportion of vitamin-A-deficient children that would be included within the 80% reached, nationwide fortification of sugar raised mean serum vitamin A levels and, more significantly, reduced the prevalence of low and deficient levels [297,496].

Over 90% of children surveyed in Cebu, the Philippines, consumed table salt, wheat products, and monosodium glutamate (MSG) on a regular basis [497]. Only the latter, however, was centrally processed. Fortification of MSG with 6250 IU vitamin A per gram was estimated to provide 75% of the consuming children with at least 25% of their RDA [498]. When MSG fortified with vitamin A was provided free to families in a pilot study, there was a pronounced rise in serum vitamin A levels and fall in the prevalence of xerophthalmia [483].

Study IV identified three centrally processed items consumed by a majority of Indonesian children, and, more to the point, a majority of those with xerophthalmia: MSG, wheat, and refined sugar (Tables 14-3 and 14-4). Roughly 70% of subjects with Bitot's spots consumed MSG, a higher rate than for either of the other items. The rate was lowest among children under a year of age, but increased dramatically by the second year of life ($p < .001$ among the larger group of normals). Consumption among subjects with active *corneal* disease in Study IV was lower: 46% consumed MSG, 27% sugar, and 23% wheat on a regular basis ($\geq$ 1/week).

In addition to being more widely consumed by the target population, MSG offers another significant advantage: the difference in per capita consumption between target children (and their mothers) and wealthier segments of society that consume maximum amounts of MSG was far narrower than for either of the other items. MSG can therefore be fortified to a higher level, delivering a potentially protective amount of vitamin A to a large proportion of minimally consuming members of the target population, without risking toxicity among maximum consumers. Also, a larger propor-

Table 14–3. Prevalence of regular consumption[1] of potentially fortifiable agents (random sample, Study IX)

Age (years)	Total n	Percent consuming regularly[1] MSG	Wheat	Sugar
0	1031	13	39	20
1	1102	63	58	56
2	1031	81	58	63
3	1079	80	56	66
4	961	83	58	70
5	1024	81	57	64
Total[2]	6333	67	54	56
$CI_{95\%}$		66–68	53–55	55–57

1. ≥ once per week.
2. Includes children of unknown age.

Table 14–4. Prevalence of regular consumption[1] of potentially fortifiable agents (cases of Bitot's spots, Study IV)

Age (years)	Total n	Percent consuming regularly[1] MSG	Wheat	Sugar
0	1	0	0	0
1	25	52	52	56
2	70	69	54	63
3	94	77	54	56
4	70	70	53	71
5	92	71	47	45
Total[2]	358	70	51	56
$CI_{95\%}$		68–72	48–54	53–59

1. ≥ 1 week
2. Includes children of unknown age.

tion of the added vitamin A will find its way to the target population, reducing the waste, hence the cost of the program.

Identifying a preferred vehicle does not guarantee fortification will prove practical. Innumerable political, commercial, and technical obstacles need be surmounted [499].

Increasing natural dietary intake

Capsule distribution and fortification are artificial means of compensating for inappropriate dietary practices. In most communities changing those

dietary practices should be the least expensive, most widely effective long term solution to the problem. The first step is identifying which they are.

The most critical dietary factors in Indonesia were early discontinuation of breast feeding and inadequate consumption of carotene-rich fruits and dark green leafy vegetables (Chap. 9). These are likely to be major factors in other communities as well. Prolongation of breast feeding and early introduction of readily digestible beta-carotene-rich fruits should have a significant impact on the problem, especially during the first two years of life. In general, however, the least expensive, most widely and consistently available source of "vitamin A" is dark green leafy vegetables.

Dark green leafy vegetables are a potent source of provitamin A carotenoids [29]. Due to inefficiencies in absorption and conversion, oily preparations of beta-carotene, the most significant of the provitamin A substances, yield half the vitamin A activity of the preformed vitamin [90,91,478,500]. Activity of beta-carotene supplied as vegetables is slightly lower [48, 478,479,501,502]. But cooking, which breaks down otherwise indigestible cellulose constituents of the vegetables, and addition of oil, increases absorption significantly [417,418]. It may reach 70%, even in undernourished children [318].

Despite its lower activity, the carotene concentration in dglv (dark green leafy vegetables) is so high that ingestion of 68 g of spinach (estimated, for comparison, to contain 1 RDA equivalent to 7500 IU carotene or 2500 IU of the preformed vitamin) is equivalent to 63 g of calf liver, 227 g of hens egg, 1.7 liters of whole milk, or 6 kg of beef or mutton [48]. In addition, sources of provitamin A, especially dglv, are far less expensive than sources of the preformed vitamin. This largely accounts for the fact provitamin A carotenoids provide most of the vitamin A activity in the diets of depressed communities in which xerophthalmia occurs [273,413,415,416,483,503,504]. Solon [273] calculated that in Cebu 1 dollar would buy 200,000 IU of vitamin A activity from vegetable sources, but only 4333 IU from fruits (which are often sold as cash crops) and 1556 IU from other sources.

Roughly 900 μg of beta-carotene per day, as dglv, are required to maintain serum vitamin A levels of otherwise healthy young children [481,503]. Thirty to forty grams of cooked dglv (less than a handful [504]) raises their serum vitamin A levels [318,418]. After being fed 30 g of cooked dglv per day for three months, children on a markedly deficient (300 IU carotene/day) diet maintained adequate levels for at least four to five months [481,505,506]. Dark green leafy vegetables alone can cure xerophthalmia [255], even though systemic infections, common in these children, cut carotene absorption in half [300].

Although the carotene content of gly varies with the species and age of the plant, and methods of cultivation and preparation [47,273,504], 30–50 g a day will generally supply the daily requirements of young children. Oomen [504] recommends that the leaves be cut up before cooking, and then mixed in with the staple food (e.g. rice) to encourage consumption. In the case of young infants it may be mashed or sieved. Several grams of oil should be added to promote absorption. This is unnecessary if it is cooked in oil, although cooking in large amounts of oil will leach much of the carotene out, and be lost if the oil is discarded. Moderate boiling has little effect on the carotene content of the leaves, and will destroy or remove potentially hazardous substances (e.g. cyanates and oxalates) found in some [504,507]. It is probably wise to throw the residual water away [434].

Having discovered that xerophthalmic children do not consume adequate quantities of gly, it is then necessary to discover why [152]. It makes little sense to extoll the virtues of green leafy vegetables if they are not locally available. It makes equally little sense to encourage home gardening if they are.

The Indonesian countrywide survey (Study IV) revealed that gly were consumed one or more times a day by 80% of the families of xerophthalmic children, and at least once a week by 99%, exactly the same as for families of normal children (Table 14-5). Reduced gly consumption of xerophthalmic children can only be explained by their failure to partake, as often as their normal peers, of foods already available in the household. A similar conclusion has been reached by others [105,149,354].

If availability is not a problem, why don't they eat more greens? Mothers who claimed that their children never ate greens were asked why. Responses for normal (Table 14-6) and xerophthalmic (Table 14-7) children were roughly similar. The larger number of normals permits more precise analysis. Excluding "other" (primarily children who had not yet been

Table 14-5. Family consumption of green leafy vegetables (Study IV)

Clinical status	Total n[1]	% Distribution by frequency of consumption				
		$\geq 1d$	$\geq 1w$	$\geq 1m$	$< 1m$	never
XIB	358	79.1	19.8	0.8	0.0	0.3
MC	340	81.5	17.4	1.2	0.0	0.0
N	34576	81.9	16.8	1.0	0.1	0.2

[1] Family data for each child in study; some families are therefore included more than once.

Table 14–6. Reasons for children never eating green leafy vegetables (random sample[1], Study IV)

Age (years)	Total[2] (n)	% Distribution by reason					
		Not bought	Not available	Too strong	Child dislikes	Can't cook	Other[3]
0	773	0.1	0.0	23.4	7.1	14.6	54.7
1	274	0.7	1.8	14.2	39.8	17.9	25.5
2	78	2.6	1.3	2.6	70.5	7.7	15.4
3	40	2.5	7.5	0.0	67.5	12.5	10.0
4	47	0.0	4.3	0.0	78.7	8.5	8.5
5	53	1.9	3.8	0.0	88.7	3.8	1.9

1 Entire random sample, including normals, abnormals, and matched controls.
2 Children who never consume glv.
3 Vast majority of those under 2 years not yet weaned.

weaned), mothers often thought green leafy vegetables were unhealthy ("too strong"), or, much the same thing, did not know how to prepare them, for very young children. The reason most frequently cited for older children was their dislike of glv. The relative importance of these factors varied from one culture to another.

Knowing that green leafy vegetables are readily at hand, and the reasons they are not being consumed, provides a solid basis for designing intervention strategies. But these need to be carefully formulated and tested. Nutrition education programs have been notoriously ineffective at altering dietary practices [508], though 30% of mothers who had stayed with their children at a nutrition rehabilitation center claimed, on follow-up, to have continued feeding them green vegetables every day [447]. Perhaps a finely

Table 14–7. Reasons for children never eating green leafy vegetables (cases of Batot's spots, Study IV)

Age (years)	Total[1] (n)	% Distribution by reason					
		Not bought	Not available	Too strong	Child dislikes	Can't cook	Other
0	0	–	–	–	–	–	–
1	6	0.0	0.0	0.0	66.7	16.7	16.7
2	10	0.0	10.0	0.0	60.0	10.0	20.0
3	13	0.0	7.7	0.0	69.2	7.7	15.4
4	9	0.0	11.1	0.0	88.9	0.0	0.0
5	13	0.0	15.4	0.0	69.2	7.7	7.7

1 Children who never consume glv.

focused approach, taking into account local cultural proclivities, will have greater success. For example, child-rearing in Indonesia is "peace-oriented" [258]. Advising mothers on ways to increase the palatability of green leafy vegetables (e.g., chopping up the leaves and mixing them into the child's rice) are likely to prove more productive than simply exhorting her to force her child to eat them. A program for feeding Indonesian children a spoonful of red palm oil everyday [509] failed because they objected to the taste of the "medicine."

In areas where green leafy vegetables are relatively scarce or expensive, home gardening or other horticultural activities may need to be promoted. Piric [507] calculated that less than 2 square meters of garden in the Philippines could supply the daily vitamin A requirements of a young child. This approach has only just begun pilot testing [183, 497].

Appendix I: The Indonesian nutritional blindness prevention project

Background and methods

Nutritional blindness has long been recognized as a serious problem in Indonesia. In 1972 the government initiated a limited program for distribution of high-dose vitamin A capsules as an emergency measure in 20 districts (kabupatens) where the problem was considered severe. In the same year collaborative arrangements were made with Helen Keller International (then called the American Foundation for Overseas Blind) to evaluate the efficacy, cost and efficiency of this pilot program. Results indicated that regular administration of capsules reduced the occurrence of mild forms of xerophthalmia, but the incidence of xerophthalmia in the untreated group pointed to a problem of enormous proportions and the cost of expanding the specialized capsule distribution system nationwide was prohibitive.

A steering committee was established in June 1975 to explore, along with representatives of Helen Keller International, the possibility of carrying out a project aimed at answering major, practical questions that remained obstacles to the development of a national nutritional blindness prevention program.

These included:

1. The underlying cause of the conjunctival and corneal changes traditionally ascribed to xerophthalmia, and the relative contributions of vitamin A deficiency, protein deficiency, diarrhea, measles, local ocular infections, and other systemic diseases in their etiology.
2. Epidemiologic determinants of vitamin A deficiency, xerophthalmia, and nutritional blindness (age, sex, seasonality, clustering, feeding practices, socioeconomic status, general nutritional status, intercurrent infections, demographic characteristics, etc.) which might identify variables amenable to intervention.

Appendix I reprinted, with modification, from the project's "Final Report" [510].

3. The natural history of nightblindness, Bitot's spots, and conjunctival xerosis; their relationship to corneal pathology, the validity of the concept of sequential stages of xerophthalmia; and the potential value of using these milder signs to identify children at increased risk of nutritional blindness.
4. The most practical form of effective vitamin A therapy for xerophthalmia.
5. The potential value of periodic administration of a massive dose of vitamin A for prevention of nutritional blindness.
6. The incidence and prevalence of xerophthalmia and nutritional blindness, and the magnitude of the problem.
7. The relationship between the prevalence of various clinical manifestations of xerophthalmia in a community and its risk of nutritional blindness.

Four basic studies were planned and carried out.

General methods

Project headquarters were located at the Cicendo Eye Hospital, Bandung, which has the highest xerophthalmia caseload in the country. Except for detailed clinical charts compiled in Studies II-III, all forms were precoded for direct transfer to 80-column IBM cards. These were reviewed and edited by the project's statistics section before punching. The statistics section also compiled simple, hand-tabulated analyses on a sample of the incoming data as a means of monitoring performance and progress of the many study teams, and of identifying critical and unexpected results requiring further investigation.

In large part the studies were interrelated, the results of one being used to confirm or expand those of another. Active cases of corneal xerophthalmia identified in Study I were hospitalized and studied as part of Study II, while patients in Studies II and III were used to train and standardize the teams that carried out Study IV.

All study teams were trained for at least two to three months, standardized, and field tested.

Statistical tests employed use of the normal deviate (z) corrected for continuity, chi square (χ^2) with the Yates's correction, Fisher's exact test, Student's t test for paired and unpaired samples, tests for linear trend, and correlation and regression analyses [511–513].

Serum vitamin A levels were determined by the micromethod of Neeld and Pearson [57], holo-retinol binding protein (holo-RBP) by that of Glover et al. [65], and total-RBP and transferrin by that of Mancini [63].

Study I

This was a longitudinal, prospective study of 4600 preschool-age rural children reexamined every three to four months. The study was carried out in six villages of Kabupaten Purwakarta, West Java, a two hours' drive from Jakarta, the capital city, to the north, and Bandung to the southwest. They were chosen on the basis of local clinical records and exploratory "mini surveys" which demonstrated a high incidence of xerophthalmia.

Mapping, census, and survey

As a preliminary step, the six study villages were completely mapped and all houses numbered. During the next phase all houses were visited by members of the field team and those families containing children less than six years of age were enrolled in the study and assigned a study number, which was then affixed to the house. Vital statistics and socioeconomic data were collected on the family and each of its members (forms 103 A and B). Name, age, sex, and study number of each member was transferred to a registration card that remained with the family (form 104) and census book (form 106). The team's supervisors revisited 10–20% of all houses and checked the accuracy with which the forms had been completed.

Clinical rounds

Seven regular clinical rounds were carried out between March 1977 and December 1978. Midway through the seventh round a special validation study was instituted: all children with xerophthalmia (night blindness, Bitot's spots, or conjunctival xerosis) were randomly assigned to receive one of two identical appearing capsules: 200,000[a] or 700 IU vitamin A (retinyl palmitate) in oil. Assignment and administration of the capsules were carried out by a supervisor. The physicians were purposely kept unaware of which capsule each child received. These children were reexamined in

[a] Contained UNICEF supplied capsule containing 200,000 IU retinyl palmitate and 40 IU [illegible] (had its nipple cut off and the contents expressed into the child's mouth).

double-masked fashion three weeks after treatment, and each received an additional high-dose capsule at that time. These post-treatment reexaminations constitute a special eighth "validation" round to document the vitamin A responsiveness of the clinical diagnoses.

All examinations were carried out by a single team composed of an ophthalmologist, pediatrician, two supervisory nurses, and eight enumerators. The enumerators went house-to-house, updating basic demographic data and identifying all study children with the help of the field census book and family-retained registration card. All available children were brought to a central point where the ophthalmologist examined their eyes with a handlight, the pediatrician carried out a general physical examination, and their height and weight were measured with a calibrated "dacin" or bar balance and "microtoise".

The nutritionist collected dietary histories (forms 108A, B, and C) in masked fashion on all children with active xerophthalmia (XN, XI, X2, X3), their matched controls (the next child of the same age and sex in the RT "neighborhood"), and a preselected subsample of the study population as a whole. During the first clinical round fingertip blood samples were obtained from these same children; during the first round the subsample comprised 10% of all study children and bloods were taken on every other member; during the second round the subsample was composed of 5% of all children.

Any child with corneal involvement (or, after the second clinical round, 180 degrees or more of conjunctival xerosis) was immediately offered hospitalization and treated. Children without severe xerophthalmia but with severe malnutrition or life-threatening illness were advised to go to the local Puskesmas (health clinic) or hospital, and if willing, transportation was provided where necessary. Children with moderate cough or diarrhea received symptomatic therapy (decongestants and oralyte respectively).

The subsample was preselected at project headquarters. Banding. For the first round, all study families were serially arranged, beginning with family number 1, RT 1, village Cilegong. After a random start between 1 and 10, every tenth family was systematically included. Blood samples were drawn on all preschool-age children residing in every other family in the subsample. At each subsequent round the original start was advanced one number, the process repeated, and every twentieth family included.

Interviews were carried out in both Sundanese and Indonesian, the enumerators being fluent in both.

Special xerophthalmia recording procedures were established in the four rural health clinics servicing the study area so that final analyses could be corrected for participants who received vitamin A therapy.

Eligible children born or migrating into study households were added to the study. Families which lacked preschoolers at the time of the census/survey, and were therefore not enrolled in the study, were never added to it, even if they eventually acquired suitably aged children.

Diagnostic definitions

1. *Conjunctival dryness* was defined as one or more granular nonwettable patches. Numerous examples of this type of lesion were encountered among hospital patients and their recognition was easily and repeatedly standardized with the ophthalmologists of Studies I through IV.
2. *Conjunctival foam or bubbles* (Bitot's spots) is even more obvious and easily recognized than (1) above. When present, the "foam" was removed with a cotton-tipped applicator to demonstrate the xerosis, if any, below.
3. *Conjunctival pigmentation and thickening* were difficult to standardize and their definition left to the experience of the ophthalmologist.
4. *Corneal involvement*, like conjunctival lesions, was readily encountered among clinic and hospital patients, and the reproducibility of diagnosis high. All cases were referred to Study II where they underwent careful, detailed examination and classification as described elsewhere.
5. *History of nightblindness* was obtained from the parent or guardian by inquiring as to whether the child suffered from "buta ayam" or "kotokeun" (chicken eyes). In the rare instances that these terms were not recognized, the symptoms, such as inability to locate food or toys after dusk, were described. A positive history was accepted only when the respondent was certain of its presence and the age of onset, and indicated that the child's behavior was clearly different from that of his peers. In some instances, also considered positive, the child was said to be nightblind only after a photic stress, such as flying a kite on a sunny day.

Early in the first round, objective assessment of scotopic vision among children with a history of nightblindness was added to the examination. Usually the ophthalmologist or a carefully trained field worker returned after dusk and compared the child's ability to locate a piece of candy or a

toy to that of his normal by history peers. On subsequent rounds the child was allowed to dark adapt for 15 min in a darkened room and his ability to locate his mother, 6–10 feet away, similarly tested.

Analyses

Cooperation remained high in all villages throughout the course of the study, except in the conservative village of Citeko (where 25–50% of study children often refused examination).

In order to increase the efficiency of the field work and shorten the interval between examinations, at the end of the first clinical round the study population was reduced from roughly 5000 to 4000 preschool-age children. This was accomplished by excluding several areas (contiguous RTs) in which Bitot's spots had not been found. All analyses of incidence, and of the relationship between incidence and prevalence, are limited to the non-excluded RTs. Four RTs mistakenly dropped during the second clinical round were reentered into the study during the third. These four RTs are included in the analyses.

Blood specimens

400–600 μl of blood were collected in unheparinized capillary tubes at the central point and sealed with molten wax. These were then placed in a sealed test tube and stored in an ice-filled, covered chest. They were spun the same evening at field headquarters, the clear serum separated by snapping the capillary tubes above the level of the packed cells, resealed, and shipped to the biochemistry laboratories at the Nutrition Research Institute in Bogor in reed, sealed containers at the end of each week.

One capillary tube of blood was analyzed for hemoglobin (spectrophotometrically with Drabkin reagent) at field headquarters the same day the blood was obtained.

Market patterns

One warung (a small, local store) from each RK (a collection of RTs) was visited during every clinical round and the availability and cost of an itemized list of food items recorded.

Studies II/III

These were prospective, detailed, clinical, biochemical, bacteriologic, and histopathologic studies of children with corneal (Study II) and noncorneal (Study III) xerophthalmia. In addition, these patients were enrolled in a variety of therapeutic and diagnostic trials. All corneal cases were stratified by the severity of their involvement and a subsample systematically selected for epidemiologic field studies which yielded matched controls for comparison.

Source of patients

All patients, regardless of age, presenting to the Cicendo Eye Hospital between June of 1977 and June of 1978 with signs or symptoms of xerophthalmia were automatically enrolled in the study. Additional patients with corneal involvement were recruited from the Cikampek Eye Clinic, a 2½-hour drive away, and from Study I.

Study II included 162 consecutive patients having active corneal xerophthalmia. An additional four cases had already received both antibiotics and vitamin A and their lesions had begun to resolve, and two cases with active measles had stromal lesions atypical for pure xerophthalmia. The only other children with active corneal disease excluded from the series were those in whom the etiology was clearly not xerophthalmia: neonatal ophthalmia (four cases), all less than three weeks of age with grossly purulent eyes and positive smears and cultures for *Neisseria* gonococcus; phlyctenulosis (three cases); classical epidemic keratoconjunctivitis (two cases); mild measles keratoconjuntivitis (one case); and one case of "classical" multiple peripheral ulcers of staphylococcal hypersensitivity which cleared on steroids and topical antibiotic treatment.

Study III involved 83 consecutive cases of conjunctival xeroses/Bitot's spots, as well as 21 cases of isolated nightblindness.

Age/sex/neighborhood-matched controls of corneal cases identified in the course of the field investigations were encouraged to come to Cicendo for similar examination and treatment.

Clinical evaluation

Complete ophthalmologic and pediatric evaluations (including anthropometric measurements) were carried out on all children. Ocular examina-

tions were carried out in the following order: handlight, slit-lamp (with and without sterile fluorescein), swabbing and scrapings of corneal ulcers (for bacteria and fungi), Lissamine green staining, Schirmer test after administering topical anesthesia and blotting the inferior cul de sac dry [514-515], application of dilating drops, dark adaption (30 min), examination for nightblindness, and indirect ophthalmoscopy.

Nightblindness was assessed by evaluating the individual's dark-adapted ability to locate a parent or guardian 8 feet away in a room darkened to a level that the normal observer could read headlines but not ordinary newsprint after 10 min of adaptation.

All lesions were carefully drawn and all eyes photographed.

Dietary and socioeconomic data

Dietary histories were collected by a nutritionist and socioeconomic data by a specially trained enumerator on forms similar to those employed in Study I.

Follow-up examinations

In general, all cases with corneal involvement (Study II) were offered hospitalization, those without corneal involvement (Study III and controls) were not. Hospitalized patients were examined daily, and all others according to the schedule in Table A-1 (day 0 being the initial examination).

Every reasonable attempt was made to follow all patients at regular intervals. Unfortunately, once the patients began to improve, parents saw little reason to return. When they failed to appear for two successive visits, a letter was sent to the home urging their return. In the case of severely ill corneal cases, a member of the staff visited the home if they failed to respond to the letter. At the completion of the study a personal visit was made to the homes of every subject not examined during the final two

Table A–1

Study II	Study III
Daily for 1 week	Day 1
	Day 3
Weekly for 4 weeks	Week 1
	Week 2
Monthly thereafter	Monthly thereafter

months. If available, the patient was transported back to the hospital for examination. If not available, the reason was sought from relatives and neighbors; if he had moved to a new address in West Java and this was known, it was visited; if the child had died the date and apparent cause of death were recorded.

Biochemical studies

Three cubic centimeters of venous blood were collected, transferred to capillary tubes, spun, and the clear supernatant stored at −20°C. Vitamin A determinations were usually carried out within one week, and never more than two weeks following collection; holo-retinol-binding protein (holo-RBP) determinations were usually carried out within two months, and never more than eight months after collection. Samples were analyzed at the laboratories in Bogor in masked fashion, for vitamin A, holo-RBP, prealbumin, total RBP, and transferrin.

Blood samples were collected from all patients and controls at the initial examination (zero hours), and thereafter as in Table A-2:

Table A–2

Study II	Study III
(patients and controls)	
1 hour	1 hour
4 hours	
1 day	1 day
2 days (initially only)	
3 days	3 days
1 week	1 week
2 weeks	
3 weeks	
4 weeks	
monthly	monthly

Because of equipment failure, vitamin A determinations are not available for the period July 16, 1977 through January 14, 1978, and holo-RBP determinations for the period after May 15, 1978.

Microbial studies

Swabs and scrapings were smeared for immediate evaluation and directly plated or inoculated onto the following media for bacterial and fungal cul-

tine, blood agar, chocolate agar, Sabouraud's (x2), and bouillion. All analyses were carried out by the Bio Farma laboratories in Bandung in masked fashion.

Stool specimens, when available, were examined at the Department of Public Health, University of Padjadjaran, for ova and parasites.

Histopathologic studies

In selected cases, small (2 × 1 mm) conjunctival biopsies were taken from either the temporal or nasal quadrant, and from the inferonasal quadrant, under topical proparacaine or subconjunctival xylocaine anesthesia at completion of the examination. Topical antibiotic ointment was applied to the biopsied areas and the eye patched and examined daily until healing was complete (usually two to four days). In some instances conjunctiva of the fellow eye was biopsied at a preselected interval following treatment to study the resolution of the lesions.

Light, transmission, and scanning electron microscopy of biopsy specimens were carried out at the eye pathology laboratories of Johns Hopkins and Harvard Medical Schools.

Treatment and diagnostic/therapeutic trials

Study III. Unless severely ill, patients with isolated nightblindness or conjunctival lesions were generally treated as outpatients.

At the start of the study, those with an "odd" number received a coded (UNICEF) capsule containing 200,000 IU vitamin A; those with an "even" number an identical appearing capsule containing 700 IU. The exceptions to this rule were children eight years or older. It was suspected that a significant proportion of these rare cases contained nonresponsive Bitot's spots. Rather than risk losing them, undiagnosed, during prolonged follow-up, they all received the high dose capsule. All patients received a high-dose capsule at three months or sooner if their condition deteriorated. Because a sizable proportion of low-dose recipients did deteriorate clinically, the use of low dose capsules was discontinued early in the study. Thereafter, all patients received 200,000 IU vitamin A at their initial examination.

Study II, general care: all patients with corneal involvement were encouraged to enter the special study ward established at Cicendo for com-

plete and often urgently needed, systemic therapy (rehydration, feeding, antibiotics, etc.). They had chest X-rays, stool examinations for ova and parasites, TB skin tests, and additional tests required for management of their systemic illnesses.

All hospitalized patients received a high-protein diet (at least 15 g/day, if possible by nasogastric tube, if required) and some form of systemic vitamin A therapy. Those with corneal perforation received 50,000 IU penicillin G/kg or cloxacillin equivalent) daily for at least seven days.

Dietary intake of all ward residents was recorded by the nutritionist. Every attempt was made to keep the children in the ward for at least two weeks; some parents, however, insisted on leaving earlier, while others refused to allow their child to be hospitalized at all.

Systemic vitamin A. Several regimens were employed:

a. Initially children received either the contents of a standard UNICEF capsule (200,000 IU retinyl palmitate plus 40 IU vitamin E in oil) orally (odd numbered) or 100,000 IU water-miscible vitamin A (Aquasol A Parenteral) intramuscularly (even numbered).
b. Because a number of severely malnourished children responded poorly or relapsed soon after receiving a single dose, subsequent patients received one of these same regimens plus an additional 200,000 IU oil-miscible vitamin A orally the day following initial treatment.
c. As the supply of water-miscible injectable vitamin A eventually ran out, each of the last 50 patients received either the double dose oral regimen or 200,000 IU oil-miscible vitamin A intramuscularly (in two divided doses) on admission to the study.

Children who seemed to respond poorly received one or more additional doses after two to three weeks. Those who were gravely ill were transferred to the pediatric ward of the general hospital (Hasan Sadikin) but retained in the study.

Topical therapy

1. One eye of 27 consecutively hospitalized patients with corneal ulceration received topical antibiotic ointment (mycetracin plus garamycin) five times a day to their right eye, none to their left (to determine the possible role of bacterial infections in the genesis of these lesions and the need for antibiotic therapy). One case with obviously infected le-

sions was excluded from this trial and automatically received antibiotic treatment. The trial was discontinued when a single nonrecipient eye fared substantially worse that its perfectly matched recipient. All subsequent patients with corneal ulceration received both topical and systemic antibiotics.

2. One eye of 50 consecutive patients received three topical applications of 0.25 cc sterile retinoic acid 0.1% in arachis oil kindly supplied by Roche Pharmaceutical, Basle for seven consecutive days. The other eye received sterile arachis oil. Where the two eyes were equally affected the drug was placed in the right eye in half the patients, in the left eye in the other half. When involvement was unequal, the drug was placed in the more severely affected eye. Patients with "open" eyes (perforations through the cornea) were excluded from this trial.

Epidemiologic investigations (Study II)

Using forms and procedures similar to those employed in Study I, the Study II team visited the neighborhoods of a subsample of corneal cases representative of the spectrum of clinical severity encountered. Beginning at the house of the active corneal case, approximately 15 neighboring houses were visited and 25 preschool-age children examined and their socioeconomic status evaluated. Blood sample and dietary histories were collected on all children the same age in years as the index case, all children discovered to have active xerophthalmia, and all children in five randomly chosen families.

Children of the same age and sex as the index (Study II corneal) case were designated matched controls. All were encouraged to return to Cicendo for examination. Of the 60 that did, 9 proved, on careful examination, to have xerophthalmia. The 51 clinically normal controls belonged to 33 corneal cases. Where more than one control was available for an index case, their average was used in the paired comparison; for measurement data the mean was employed; for attribute data fractional rates of positivity were calculated.

Study IV

This was the national xerophthalmia/nutritional blindness prevalence survey carried out in 23 of the 27 provinces of Indonesia.

Sample size

The goal of the sampling procedure was to provide a sufficiently large and representative sample of preschool-age children for each major population area to be reasonably certain of detecting active conjunctival lesions (XIB) and old healed corneal disease (XS) at the minimal prevalence deemed a significant public health problem by WHO and major differences that might exist between high prevalence and low prevalence areas. These populous areas were divided into six zones thought to best segregate cultural-administrative differences in the country. Rather than choose a sample with a probability proportional to size for the country as a whole, equal-sized samples were chosen for each of these zones, so as to provide the minimal necessary sample for statistically valid estimates of corneal disease rates within each. Overall country rates are calculated by applying weighting factors (proportional to population size) to the zonal rates.

A choice of 7500 children per zone was felt to best satisfy the competing priorities of practical constraints (time, money, and personnel) and statistical need.

Choice of zones

Since it was impossible, from a practical standpoint, to examine all areas of Indonesia, the country was divided into six zones covering the vast majority (96%) of the population. Five zones were represented in their entirety: East Java, Central Java (including Jogyakarta), West Java (including Djakarta), Sumatra, Sulawesi.

The remaining zone was composed of a representative sample, of more limited size, of several islands: Kalimantan, Lombok, Bali, Ambon.

Basic sampling structure

A stratified, multistage, cluster sampling scheme was chosen.

1. The country was stratified into these six zones (and their component islands).
2. Each stratum was restratified into urban and rural.
3. A team could examine roughly 120 rural children and 250 urban children per day. Each rural cluster was designed to yield 120 children, and each urban, given the far fewer sites available, 500. Sufficient clus-

ters were then assigned to each zone to yield the desired number of children.

4. To increase efficiency, urban samples were not chosen to be representative of the urban areas as a whole, but only of their slums, from which experience indicates the vast majority of urban cases arise. Urban results, therefore, indicate areas of obvious risk, not true prevalence. If necessary, urban prevalence can be approximated by adjusting the observed prevalence for the proportion of urban dwellers who live in the slums.

Selection of sample sites (clusters): use of intercensal survey as sampling frame

A well-designed population survey was carried out by the Central Bureau of Statistics (CBS) in 1976. A review of their sampling procedures indicated that with modification their sample would serve as an excellent basis for the sampling frame. In addition to the excellence of the sample, the CBS could also supply maps defining each cluster and lists of their inhabitants (useful for further defining the cluster).

Selection of sample clusters from sampling frame

The clusters of the CBS SUPAS II subsample of the Intercensal Population Survey served as the sampling frame for the project survey. The frame was first separated into zones (province, and island, and each then stratified into rural (nonmunicipality) and urban (municipality).

Rural sample sites within each zone were already chosen, for SUPAS II, with a probability proportional to size (PPS). For each rural zone roughly 36 clusters were required. The total number of clusters in each zone in the SUPAS II frame was divided by 36, yielding the required sampling ratio. After a random number start between site 1 and the sampling interval (e.g., 54 for Cebu), every site falling at the required interval was chosen. This systematic sampling technique preserved the randomness and PPS of the original SUPAS II selection. The teams were required to visit all families within the cluster. If this yielded less than the required 120 children, the boundaries of the cluster were enlarged to adjacent areas of similar socioeconomic composition to make up the difference.

The urban sample was composed of the slum areas of major municipalities. The slums were identified by local census and health authorities.

For Zone 6, composed of a variety of islands, a larger number of rural sites were included to provide a sample size sufficient for estimating rates in each, though not with as much precision as for zonal rates. The number of sites in these islands (Zone 6) were as follows: (1) Bali = 11 rural, 1 urban, (2) Lombok = 20, all rural, (3) Kalimantan = 19 rural, 4 urban (1 per province). All but Ambon were chosen in the systematic manner indicated above. A representative rural sampling of Ambon was not included in the Intercensal Survey.

Sampling of Ambon:

Stage I—9RK were chosen from a list of all RKs ordered by population at a systematic sampling ratio of 20,000 people per site.

Stage II—1 RT was randomly selected from among all RTs in each selected RK.

Stage III—within each RT, a census block was randomly chosen.

Four selected sites in West Java and two in East Java were found to be already a part of the capsule distribution scheme. Since they were no longer representative of the area they were dropped, and adjacent villages in the SUPAS II frame substituted.

Sampling sites eventually excluded

Only 5 preselected sites were eventually dropped from the survey because of inaccessibility. One each was from East Java, Central Sulawesi, North Sulawesi, South Sulawesi, and Aceh.

Modifications from original protocol

The number of sites indicated above, hence children in the survey, was less than projected in the original protocol. This reduction was required when more realistic estimates of travel time and accessibility during the survey period (wet season, October through April) indicated that it was impossible to cover the original sample with the amount of time, money, and personnel available. This season was chosen to avoid both the election period, and Lebaran and Ramadan (when dietary intake was likely to be altered). For the same reason the survey began in Bali, a Hindu area, to minimize the impact of the Lebaran celebrations.

Preliminary visits to sample areas

Written communication and visits to appropriate provincial government authorities were made by project staff in May and June 1977 to obtain official permits and local support. During these visits local census officials were contacted to locate sample villages and obtain the detailed sample cluster maps. Provincial and local counterparts appointed by the health inspector were contacted to help detail survey procedures and determine time schedules, travel routes, local transport requirements, lodging, and financial channels for use by the survey teams, as well as the best means of returning completed forms to Bandung.

Composition and training of survey teams

Three survey teams were recruited in June 1977, each composed of one ophthalmologist, one nutritionist, one nurse, and five enumerators.

The teams were given three weeks of intensive training, including standardization, before any sample sites were visited. Thre three ophthalmologists spent one week at the Cicendo Eye Hospital to become better acquainted with the signs of xerophthalmia and survey forms to be used.

Lectures and discussions on survey procedures, interview techniques, anthropometric measurements, and use of the survey forms were given to all team members during one week of classes held at project headquarters. This was followed by practical field training in rural villages of West Java and Bali, during which continuous supervision and standardization were carried out.

Survey forms and data collected

Simple self-coding forms, pretested in the field, were used to record basic socioeconomic data of every family, and the health, dietary history, height, weight, and results of the eye examination on each child.

The forms were designed so that a strip containing all the results could be torn off and mailed separately from the completed form. This enabled immediate hand tabulation and reduced the risk of losing all the data during shipment to Bandung. A detailed survey manual was provided to every team member.

Activities

Prior to the team's visit, the local counterpart contacted and informed each village authority about the survey operation, and requested that they ensure that families in the sample site remained at home during the day of the survey. Upon arrival at a sample site the clinical team (the opthalmologist, the nutritionist, the nurse, and an enumerator) established one or more central examination points while the enumerators, accompanied by local guides, visited every house, where they compiled socioeconomic data and collected the preschool-age children (below age six) for their examination. Because of cultural taboos, children less than two months of age were generally not examined.

The ophthalmologist examined the anterior segment of every child's eyes with a handlight, noted obvious abnormalities, and estimated the potential visual acuity as better or worse than 20/200. Special attention was paid to those lesions potentially related to active xerophthalmia (conjunctival xerosis, Bitot's spots, corneal xerosis, ulceration, and keratomalacia) and its healed sequelae. The ophthalmologist attempted to assign an etiology to all healed corneal abnormalities with the help of historical data provided by an older family member. Major categories included:

Congenital: noted at or shortly after birth in an otherwise white and quiet eye.

Trauma: clear-cut history of injury at the time of onset or corneal damage.

Infection: gross purulence, especially in children below 2 months of age at onset.

Xerophthalmia: none of the above, in children at least 2 months of age, usually ill or malnourished at the time of onset.

The enumerator at the central examination point measured the height and weight of every study child. Standing height was determined with a microtoise measuring tape while the length of babies was measured in a specially constructed sliding frame. The weight was measured with a Dacin bar scale.

The nurse assisted the ophthalmologist in the eye examination and selection of random children and normal matched controls.

The nutritionist completed the diet interview for all random children, abnormals, and matched controls in masked fashion. The record emphasized the frequency of consumption of relevant foods and estimated the

quantities of potentially fortifiable food items that were consumed. The reasons foods rich in vitamin A and carotene were not used was determined. In addition, the nutritionist assisted the team leader (ophthalmologist) in checking the completeness and standardization of survey forms. This encouraged immediate detection and correction of errors and inconsistencies on a running basis, before the team departed for the next sample site.

Problems in data analysis and coverage

To expedite data analysis, forms 40 and 41 were first cleaned, edited, and matched. According to family data (form 40) 21,391 families contained 36,701 children eligible for inclusion in the study. 36,060 children (98% of the total) in 21,349 families (99% of the total) were examined (form 41). All 36,060 children examined were included in the calculation of prevalence rates.

Correlations, including dietary and anthropometric data required, in addition, use of form 42. When these were matched with forms 40 and 41, only a total of 35,274 children (98% of those examined) were found to have a complete record. The remaining 700 children were identified, and it was discovered that their cards ("42") were never punched. Except for 230, all of whom came from three villages (two in Central Java, one in West Java), the rest were evenly distributed among the other sample sites. Age and sex distribution of the total (36,060) and reduced (35,274) samples were identical. None of the missing children were abnormals, matched controls, or part of the random sample.

Clinical definitions

XIB. The definition of (active) Bitot's spots is the same used in the WHO Criteria for a Public Health Problem: foam overlying an area of conjunctival xerosis (XIB). Although the WHO criterion was used, it should be noted that areas of true conjunctival xerosis (but without foam), some almost frankly skinlike, were present in large numbers of children. If they had been included in this analysis the rates of conjunctival disease would have been approximately one third higher.

Of the 72,120 eyes examined, 649 were diagnosed as having Bitot's spots (XIB). Diagnosis was cross-checked against the presence of dryness and foam. In 14 (an insignificant .02%) the description was incompatible with

the diagnosis: about half were overdiagnoses (7/649, 1% of all Bitot's spots) and half underdiagnoses (.01% of all normals). A total of 358 cases of Bitot's spots (X1B) were identified in the survey. Because an age/sex-matched control was not always available at the sample site, the number of matched controls (340) was slightly smaller than the number of cases of Bitot's spots.

X2/X3: Active corneal disease was diagnosed using standard WHO criteria. All had frank corneal involvement obvious on handlight examination and all but one had severe accompanying conjunctival disease. (The single exception had X3B and recently received vitamin A.)

XS: The most difficult and subjective assessment is in determining the likelihood that old corneal scarring was due to xerophthalmic corneal involvement. Without examining the eye at the time of its active disease, we can only surmise from available data (clinical findings; age of onset; and history of concomitant malnutrition, worms, cough, fever, measles, trauma, and purulent discharge) what that original process was. Although we can never be absolutely certain of the cause of scarring in any *individual* case, we can, by employing reasonably strict, conservative criteria, feel certain that most children in a particular *group did or did not have true XS.*

All cases of corneal scarring were classified on a scale of 0 to 4 according to the degree to which available data supported a diagnosis of XS. This does not necessarily mean that those in the lower rankings did not suffer xerophthalmic damage, only that the history and clinical findings suggested that another etiology was likely. Each case was classified on the basis of all contributory data. Parameters that strongly suggested a xerophthalmic origin included: (a) age over 1 year; (b) bilateral involvement; (c) severe scarring, especially with evidence of perforation (adherent leukoma, phthisis, descemetocele, or staphyloma); (d) absence of a reasonably certain history of trauma or purulent discharge (although appropriately aged children with bilateral perforation and a history of purulence were considered xerophthalmic since such perforations rarely occur from infection alone and "apparently purulent" discharge has been observed among Study II patients with classical xerophthalmia); and (e) the presence of severe malnutrition, diarrhea, fever, or worms at the time of active corneal disease.

A total of 151 children had some degree of corneal scarring, including one case that had active disease as well. Of these, 60 (Group 0) were almost certainly due to other causes (primarily congenital origin, trauma, or neonatal ophthalmia). An additional 37 (Group 1) could have been due to xerophthalmia, but were more likely the result of other diseases. The seven cases in Group 2 most often had a classical clinical picture for xerophthal-

mia but a history suggesting that another etiology *might* have been present or a history of measles with *mild* corneal maculae that could conceivably have resulted without implicating the xerophthalmic process. Groups 3 (48 cases) and 4 (29 cases) were likely to have suffered xerophthalmic corneal destruction and serve as the basis for our *minimal, conservative* estimate of XS.

Appendix II: 1981 revision of WHO recommendations

The World Health Organization published a report of an international meeting on vitamin A deficiency held in 1974 [47]. This included recommendations for the treatment and classification of clinical xerophthalmia, and established prevalence criteria to define when xerophthalmia constituted a problem of public health magnitude. These recommendations have been widely adopted.

A second international meeting was held in October 1980, at which it was decided to modify existing recommendations in light of new data, particularly those available from the Indonesian Nutritional Blindness Prevention Project (detailed in this monograph). A report of that meeting, and these revisions (given below), are to be published in the Technical Report Series of WHO, likely by late 1981.

Clinical classification of xerophthalmia (WHO, 1981 revision)

Night blindness (XN)
Conjunctival xerosis (X1A)
Bitot's spot (X1B)
Corneal xerosis (X2)
Corneal ulceration keratomalacia < ⅓ corneal surface (X3A)
Corneal ulceration/keratomalacia ≥ ⅓ corneal surface (X3B)
Corneal scar (XS)
Xerophthalmia fundus (XF)

Prevalence criteria for a xerophthalmia problem of public health significance (WHO, 1981 revision)

Nightblindness (XN)	1.0%
Bitot's spots (XIB)	0.5%
Corneal xerosis corneal ulceration/keratomalacia (X2 X3A X3B)	0.01%
Corneal scar (XS)	0.05%
Plasma vitamin A < 10 μg/dl	5.0%

Treatment of xerophthalmia (WHO, 1981 revision)

Immediately on diagnosis	200,000 IU by mouth
Second day	200,000 IU by mouth
Prior to discharge, or if clinical deterioration occurs, or 2–4 weeks later	200,000 IU by mouth

1. Oral doses consist of an oil solution of retinyl palmitate or acetate.
2. In the presence of repeated vomiting or severe diarrhea 100,000 IU water miscible retinyl palmitate by the intramuscular route is preferred.

Appendix III: Detailed descriptions of selected corneal cases (Study II)

In a number of cases, the clinical course provides clues to the pathophysiology of xerophthalmic corneal destruction. Some of these cases have already been described in detail in the body of the text. Others are presented here.

A. Cases of corneal ulceration (category 4) presenting with potential precursor lesions (treebark cornification and/or bullae).

Case 200/108: The entire left cornea was covered by a treebark, cornified layer, within which was one classically punched-out ulcer as well as three tiny, pinpoint fluorescein-positive superficial lesions, one of which was infiltrated and two of which were not. A 25% hypopyon and endothelial folds were also present.

Case 200/011: This patient presented with an inferior xerotic plaque in the right eye and a fluorescein-positive superficial ulcer in the center of a similar plaque in the left eye. The ulcer healed, by day 4, as a faint macula.

Case 200/188: Perhaps demonstrating initiation of the stromal baring process, this case presented with two superficial stromal bullae. The anterior walls of both stained with fluorescein, suggesting that loss of epithelial lining had already ensued.

Case 200/050: The right cornea contained a thick, elevated xerotic plaque in the inferonasal quadrant. The same area of the left eye was occupied by an ulcer. Adjacent, superotemporally to the ulcer were three stromal vesicles, with thick anterior walls and optically empty centers. Their surface stained brightly. One day following the first dose of vitamin A the stromal vesicles were gone, and what had been their surface stained faintly if at all. The ulcer had already improved.

B. Cases in category 5 (penetrating ulcers) potentially transitional between categories 4 (ulcers) and 6 (focal, deep stromal necrosis).

Case 200/129: A two-year-old boy presented with a two-month history of nightblindness and one-week history of a white spot on the left cornea. Vitamin A on admission was 5 μg/dl, albumin 2.6 g/dl, and edema was present. The right eye displayed a central but otherwise classical (category 4) sharp, punched-out, densely white ulcer of one-third depth without swollen margins. White, flocculent, hypopyon type material was adherent to the back of the cornea deep to the ulcer. The left cornea contained a large central/superior-temporal necrotic punched-out perforation through which Descemet's membrane, with some overlying necrotic material, bulged, the anterior chamber being flat. Under routine therapy both corneas healed, the right as a leukoma, the left as a larger, adherent leukoma.

Case 200/157: A two-year-old boy with marasmic-kwashiorkor had a serum vita-

mm. A of 2 μg/dl, albumin of 2.6 g/dl, and transferrin of 20 mg/dl. The entire bulbar conjunctiva was xerotic and without injection or. Both corneas were heavily xerotic and twice normal thickness. A perfectly round 1–2 mm. staining, yellowish infiltrate was present superior nasally in the right cornea. A punched-out perforation containing a knuckle of iris occupied the identical position in the other eye. The anterior chamber in the left eye was shallow. Despite routine therapy, by day 1 the shallow, infiltrated lesion in the right eye had become a densely staining, sharp margined, punched-out ulcer of one third corneal depth, with only a tiny rim of infiltrate about it. By day 2 the ulcers in both eyes had begun to heal.

C. Cases in category 6 demonstrating potential mechanisms by which focal necrosis forms, extends, and heals

Case 200 151. A two year old boy was admitted with marasmic-kwashiorkor and a serum vitamin A of 3 μg/dl, albumin of 2.8 g/dl, and transferrin of 18 mg/dl. The entire bulbar conjunctiva of both eyes was severely xerotic. The surface of both corneas was also xerotic, and had a marked, ground-glass appearance on retroillumination. Both corneas contained yellowish, bulging lesions, inferior-nasally. On slit lamp examination, the corneas were edematous, 2–3 times normal thickness throughout; the bulging lesions consisted of loose, cystic, extremely edematous tissue sharply separated from adjacent cornea by a narrow, shallow excavation, and the anterior chamber of both eyes was very shallow. In addition, the left cornea contained a more densely yellow, moderately staining (2+) nonbulging lesion superior central to the inferonasal one. The patient received 200,000 IU oil-miscible vitamin A intramuscularly (with, we were to learn, predictably poor response), cloxacillin and gentamycin systemically, topical antibiotics, and thrice daily topical retinoic acid in the left eye. By day 2 (two days later), the inferior bulging necrotic mass in the left eye had incorporated the superior-central area that was originally flat and separated from it, and the necrotic bulge in the right eye was now surrounded by a zone of haziness and limited infiltration. The yellowish, bulging lesions in both eyes were extremely edematous from the surface back to Descemet's membrane. By day 5 the right eye was much worse, new areas of necrosis (not yet bulging) extending from the original lesion in the area where limited infiltrate was noted the day before. In the left eye the originally flat, densely yellow area, subsequently incorporated into the bulging mass, was flat once again. By day 7 much of the necrotic tissue in the center of the lesion in the right eye had disappeared, producing a descemetocele. By 2 weeks, both lesions had healed as adherent leukomas, in the right eye larger than the original area of necrosis, in the left eye the same size. The flat area of infiltration transiently incorporated into the bulging mass had returned to normal. The clinical course demonstrates both the reversible nature of some of the lesions and at least one manner by which necrosis can occur and lesions enlarge.

Case 200 090. A 3-year-old girl with serum vitamin A of 6 μg/dl, holo-RBP of 2 μg/ml, albumin of 2.8 g/dl, and transferrin of 20 mg/dl presented with a swollen, opaque, necrotic-looking, sharp-margined central lesion in the right cornea. By day 2 the lesion was greyish-white, flat, and firm (if still edematous) looking, rather than jellylike, necrotic, and sloughing. By day 15 it had healed as a much smaller, dense leukoma. Even peripheral, nonnecrotic-looking cornea was opaque and

edematous on admission, but, like much of the area included in the originally swollen mass, eventually returned to normal.

Case 200/163. A four-month-old, seemingly well nourished infant, with weight for height greater than 90% of standard, albumin 3.7 g/dl, and transferrin 183 mg/dl but vitamin A of only 5 μg/dl presented with temporal Bitot's spots and superior-nasal round, sharp-margined, staining, edematously cystic, opaque, bulging lesions in each eye. Stroma immediately about the lesions was 4 times normal thickness, and elsewhere, 3 times. The anterior chamber was slightly shallow on. Iris was not in contact with either lesion. The child received 200,000 IU vitamin A orally on admission and again the following day. The right eye received retinoic acid topically 5 times a day, the left placebo. By day 1 (the day following admission) the right eye was obviously better, the cornea generally clearer, and the lesion unchanged. On gently opening the lids of the left eye a "pop" was felt, presumably perforation of Descemet's membrane, and iris found to be filling the wound. By two weeks the right lesion had been replaced by a leukoma. The left lesion still presented a descemetocele, which eventually healed, by one month, as an adherent leukoma.

References

1. Wolf, G., A historical note on the mode of administration of vitamin A for the cure of night blindness, *Am. J. Clin. Nutr.* *31*, 290–292 (1978).
2. Duddell, B., *Treatise of the Diseases of the Horny Coat of the Eye*, pp. 32, 56, 57–58, John Clark, London (1729).
3. Magendie, *Memoire sur les proprietes nutritives des substances qui ne contiennent pas d'Azote*, p. 7, Paris (1816).
4. Mackenzie, W., *A Practical Treatise on Diseases of the Eye*, pp. 88–199, Longman, London (1830).
5. Arlt, C.F., In *Die Krankheiten des Auges*, pp. 211–215, Prague (1851).
6. Hubbenet, M., Observations sur l'hemeralopie, *Ann. Oculist. (Paris)* *44*, 293 (1860).
7. Bitot, C., Sur une lesion conjunctivale non encore decrite, coincidant avec l'hemeralopie, *Gazette Hebdomadaire de Medecine et de Chirurgie* *10*, 284–28 (1863).
8. Blessig (1866) cited in Blegvad, O. [39].
9. Graefe, A., Hornhautverschwarung bei infantiler encephalitis, *Graefe's Arch. Ophthalmol.* *12*, 250–256 (1866).
10. Hirschberg, J., Ueber die durch Encephalitis bedingte Hornhautverschwarung bei kleinen Kindern, *Klin. Wochenschr.* *5*, 324–326 (1868).
11. Hildreth, J.S., Anasthesie der Cornea mit gleichzeitig verminderter Wirkung des Atropins auf die Iris, und deren einfluss auf ulcerative hornhautentzundung, *Arch. f. Augenh. u. Ohrenh.* *1*, 200–202 (1870).
12. Leber, T., Ueber die Xerosis der Bindehaut und die infantile Hornhautverschwarung nebst Bemerkungen uber die Entstehung des Xerophthalmus., *Graefe's Arch. Ophthalmol.* *29*, 225–290 (1883).
13. Arlt, C.F., *Clinical studies on diseases of the eye, including those of the conjunctiva, cornea, sclerotic, iris, and ciliary body*, pp. 110; 138–139, Y.J. Pentland, Edinburgh (1885).
14. Gama Lobo, Ophthalmia brasiliana, *Klin. Mbl. Augenheilk.* *4*, 65 (1866).
15. Leuscher, B., *Jenaische Zeitschr. f. Med. U. Naturwissenschaft.* *3*, 103 (1867).
16. Weeks, J.E., Xerosis conjunctivae bei Sauglingen und Kindern, *Archiv. fur Augenheilkunde* *17*, 193–202 (1887).
17. Herbert, H., Epithelial xerosis in natives of India, *Trans. Ophthalmol. Soc. U.K.* *18*, 103–104 (1896).
18. Mori, M., Uber den sog Hikan, Xerosis conjunctivae infantum ev. Keratomalacie, *Jahrb. Kinderheilk.* *59*, 175–194 (1904).
19. Snell, S., On nyctalopia with peculiar appearances on the conjunctiva, *Trans. Ophthalmol. Soc. U.K.* *1*, 207–215 (1880-81).
20. Spicer, H., Ophthalmological Society, *Lancet* *2*, 1387 (1892).
21. Falta, W. and Noeggerath, C.T., Futterungsversuche mit künstlicher Nahrung, *Beitr. Chem. Physiol. Path.* *7*, 313–322 (1906).

22. Knapp, P., Experimenteller Beitrag zur Ernährung von Ratten mit künstlicher nahrung und zum Zusammenhang von Ernährungsstörungen mit Erkrankungen der Conjunctiva. *Zeitschrift für Experimentelle Pathologie und Therapie* 5, 147–169 (1909).
23. Hopkins, F.G., Feeding experiments illustrating the importance of accessory factors in normal dietaries. *J. Physiol. Lond.* 49, 425–460 (1912).
24. McCollum, E.V., and Davis, M., The necessity of certain lipins in the diet during growth. *J. Biol. Chem.* 15, 167–175 (1913).
25. Osborne, T.B., and Mendel, L.B., The influence of butter fat on growth. *J. Biol. Chem.* 16, 423–437 (1913).
26. Osborne, T.B., and Mendel, L.B., The influence of cod liver oil and some other fats on growth. *J. Biol. Chem.* 16, 423–437 (1914).
27. Goldschmidt, M., Experimenteller Beitrag zur Aetiologie der Keratomalacie. *Graefe's Arch. Ophthalmol.* 90, 354–366 (1915).
28. McCollum, E.V., and Davis, M., The essential factors in the diet during growth. *J. Biol. Chem.* 23, 231–254 (1915).
29. McCollum, E.V., and Simmonds, N., A biological analysis of pellagra-producing diets. II. The minimum requirements of the two unidentified dietary factors for maintenance as contrasted with growth. *J. Biol. Chem.* 32, 181–191 (1917).
30. McCollum, E.V., and Simmonds, N., A biological analysis of pellagra-producing diets. I. The dietary properties of mixtures of maize kernel and bean. *J. Biol. Chem.* 32, 29–61 (1917).
31. Bloch, C.E., Fat deficiency disturbances in infants. *JAMA* 68, 1516 (1917).
32. Bloch, C.E., Clinical investigation of xerophthalmia and dystrophy in infants and young children (Xerophthalmia et dystrophia alipogenetica). *J. Hygiene (Cambridge)* 19, 283–301 (1921).
33. Holmes, H.N., and Corbett, R.E., The isolation of crystalline vitamin A. *J. Amer. Chem. Soc.* 59, 2042–2047 (1937).
34. DeHaas, J.H., and Meulemans, P., Vitamin A and carotinoids in blood deficiencies in children suffering from xerophthalmia. *Lancet I*, 1110–1111 (1938).
35. Oomen, H.A.P.C., An outline of xerophthalmia, in *Int. Review of Tropical Med.*, pp. 131–213. Academic Press, New York/London (1961).
36. Dujardin, D., Une epidemie de xerosis hemeralopique. *J. des Sciences Médicales de Lille*, 16, 361–369 (1895).
37. International Agency for the prevention of blindness, *World blindness and its prevention*," pp. 3–5. Oxford Univ. Press, New York, Toronto (1980).
38. Bloch, C.E., Further clinical investigations into the diseases arising in consequence of a deficiency in the fat-soluble A factor. *Am. J. Dis. Child.* 28, 659–667 (1924).
39. Blegvad, O., Xerophthalmia, keratomalacia and xerosis conjunctivae. *Am. J. Ophthalmol.* 7, 89–117 (1924).
40. Blackfan, K.D., and Wolbach, S.B., Vitamin A deficiency in infants. A clinical and pathological study. *J. Pediatr.* 3, 679–706 (1933).
41. Williamson, A.D., and Leong, P.C., Keratomalacia in Singapore and its relation to vitamin A in milk. *Med. J. Malaya* 4, 83–87 (1949).
42. Yap, K.T., Protein deficiency in keratomalacia. *Br. J. Ophthalmol.* 40, 502–503 (1956).

43. McLaren, D.S., *Malnutrition and the Eye*, pp. 29–60, 162–232, 299–303. Academic Press, New York, 1963.

44. Rodger, F.C., Saiduzzafar, H., Grover, A.D., and Fazal, A., Nutritional lesions of the external eye and their relationship to plasma levels of vitamin A and the light thresholds. *Acta Ophthalmol.* 42, 1–24 (1964).

45. Sauter, J.J.M., *Xerophthalmia and Measles in Kenya*. Drukkerij Van Denderen, B.V., Groningen, 1976.

46. McLaren, D.S., Oomen, H.A.P.C., and Escapini, H., Ocular manifestations of vitamin-A deficiency in man. Bull WHO 34, 357–361 (1966).

47. Report of a joint WHO-USAID Meeting, *Vitamin A deficiency and Xerophthalmia*. Tech. Rep. Ser. No. 590, WHO, Geneva, 1976.

48. Moore, T., *Vitamin A*. Elsevier, Amsterdam (1957).

49. DeLuca, L.M., "Vitamin A" in *Handbook of Lipid Research*, Vol. 2, *The Fat Soluble Vitamins*, ed. H.F. DeLuca, pp. 1–67, Plenum Press, New York (1978).

50. Symposium, Vitamin A and retinoids, recent advances, *Fed. Proc.* 38, 2501–2513 (1979).

51. DeLuca, L.M., Glover, J., Heller, J., Olson, J.A., and Underwood, B., Recent advances in the metabolism and function of vitamin A and their relationship to applied nutrition, in *Guidelines for the Eradication of Vitamin A Deficiency and Xerophthalmia*. The Nutrition Foundation, New York (1977).

52. Olson, J.A., Gunning, D., and Tilton, R., The distribution of vitamin A in human liver. *Am. J. Clin. Nutr.* 32, 2500–2507 (1979).

53. Olson, J.A., The prevention of childhood blindness by the administration of massive doses of vitamin A. *Isr. J. Med. Sci.* 8, 1199–1206 (1972).

54. Suthutvoravoot, S., and Olson, J.A., Plasma and liver concentrations of vitamin A in a normal population of urban Thai. *Am. J. Clin. Nutr.* 27, 883–891 (1974).

55. Underwood, B.A., Siegel, H., Weisell, R.C., and Dolinski, M., Liver stores of vitamin A in a normal population dying suddenly or rapidly from unnatural causes in New York City. *Am. J. Clin. Nutr.* 23, 1037–1042 (1970).

56. Zaklama, M.S., Gabr, M.K., Maraghy, S.E., and Patwardhan, V.N., Liver vitamin A in protein-calorie malnutrition. *Am. J. Clin. Nutr.* 25, 412–418 (1972).

57. Neeld, J.B., and Pearson, W.N., Macro and micromethods for the determination of serum vitamin A using trifluoroacetic acid. *J. Nutr.* 97, 454–462 (1963).

58. Bessey, O.A., Lowry, O.H., Brock, M.J., and Lopez, J.A., The determination of vitamin A and carotene in small quantities of blood serum. *J. Biol. Chem.* 166, 177–188 (1946).

59. Sommer, A., McLaren, D.S., and Olson, J.A., Assessment of vitamin A status, in *Guidelines for the Eradication of Vitamin A Deficiency and Xerophthalmia*. The Nutrition Foundation, New York (1977).

60. Reddy, V., Mohanram, M., and Raghuramulu, N., Serum retinol binding protein and vitamin A levels in malnourished children. *Acta Paediatr. Scand.* 68, 65–69 (1979).

61. Pure, V., and Anbumathan, P., Early serum changes in severely malnourished children with corneal xerophthalmia after injection of water miscible vitamin A. *Am. J. Clin. Nutr.*, 34, 34–40 (1981).

62. Bieri, J.G., Tolliver, T.J., and Catignani, G.L., Simultaneous determination of

alpha-tocopherol and retinol in plasma or red cells by high pressure liquid chromatography. *Am. J. Clin. Nutr.*, 32: 2143–2149 (1979).

63. Mancini, G., Carbonara, A.O., and Heremans, J.F., Immunochemical quantitation of antigens by single radial immunodiffusion. *Immunochemistry*, 2: 235–254 (1965).

64. Smith, F.R. and Goodman, D.S., The effects of diseases of the liver, thyroid and kidneys on the transport of vitamin A in human plasma. *J. Clin. Invest.* 50: 2426–2436 (1971).

65. Glover, J., Morley, D., Muhilal, H., and Weston, S., Micro-method for fluorimetric assay of retinol-binding protein in blood plasma. *Clin. Chim. Acta* 30: 371–380 (1971).

66. Large, S., Neal, G., Glover, J., Thanangkul, O., and Olson, R.E., The early changes in retinol binding protein and prealbumin concentrations in plasma of protein-energy malnourished children after treatment with retinol and an improved diet. *Br. J. Nutr.* 43: 393–402 (1980).

67. Tarwotjo, I., Sommer, A., Soegiharto, T., Susanto, D., Muhilal, H., Dietary practices and xerophthalmia among Indonesian children. *Am. J. Clin. Nutr.* (1982) (in press).

68. Westhoff, C.H.A., Enige opmerkingen omtrent oogziekten op Java. *Geneesk. Tijdschr. Ned. Indie*, p. 141 (1911).

69. Tarwotjo, I., ten Doesschate, J., Gunawan, S., Reedy, S., and Sullivan, E.H., An evaluation of the vitamin A deficiency prevention pilot project in Indonesia. The Ministry of Health, Government of Indonesia and The American Foundation for Overseas Blind, New York (1976).

70. Oomen, H.A.P.C. and ten Doesschate, J., The periodicity of xerophthalmia in South and East Asia. *Ecology of Food and Nutrition* 2: 207–217 (1973).

71. ten Doesschate, J., Causes of blindness in and around Surabaja, East Java, Indonesia, pp. 159–241. Thesis, Univ. of Indonesia, Jakarta (1968).

72. Fritz, C., *Combating Nutritional Blindness in Children. A Case Study of Technical Assistance in Indonesia*. Pergamon Press, New York (1980).

73. Lilienfeld, A.M., *Foundations of Epidemiology*. Oxford University Press, New York (1976).

74. Sommer, A., *Epidemiology and Statistics for the Ophthalmologist*. Oxford University Press, New York and Oxford (1980).

75. Rumphield, R.W., A practical essay on Hemeralopia or nightblindness. *Medico-Chirurgical Transactions* 5: 52–66 (1814).

76. DeGouvea, H., Beiträge zur Kenntnis der Hemeralopie und Xerophthalmie aus Ernährungsstörungen. *Grae. f. s. Arch. Ophthalmol.* 29: 167–200 (1883).

77. Elliot, R.H., in *Tropical Ophthalmology*, pp. 75–86, Henry Frowde, Hodder and Stoughton, London (1920).

78. Ballhe, H., Observations on hemeralopia or nightblindness. *Medico-Chirurgical J. and Review*, 2: 179–182 (1816).

79. Stephenson, S., On epithelial xerosis of the conjunctiva. *Trans. Ophthalmol. Soc. U. K.* 15: 55–102 (1896).

80. Kuhli, T., Zur Lehre von der epidemischen Hemeralopie. *Archiv. fur Augenh.* 17: 409–411 (1887).

81. Friderica, L.S. and Holm, E., Experimental contribution to the study of the

relation between night blindness and malnutrition. Influence of deficiency of fat soluble A vitamin in the diet on the visual purple in the eyes of rats. *Am. J. Physiol.* 73, 63–78 (1925).

82. Wald, G. The photoreceptor process in vision. *Am. J. Ophthalmol.* 40, 18–41 (1955).

83. Dowling, J.E., and Wald, G., Vitamin A deficiency and night blindness. *Proc. Natl. Acad. Sci.* 44, 648–661 (1958).

84. Lewis, J.M., Bodansky, O., Falk, K.G., and McGuire, G., Vitamin A requirements in rat. The relation of vitamin A in blood plasma, liver and retina. *J. Nutr.* 23, 351–363 (1942).

85. Bridges, C.D.B., Vitamin A and the role of the pigment epithelium during bleaching and regeneration of rhodopsin in the frog eye. *Exp. Eye Res.* 22, 435–455 (1976).

86. Robison, W.G., and Kuwabara, T., Vitamin A storage and peroxisomes in retinal pigment epithelium and liver. *Invest. Ophthalmol. Vis. Sci.* 16, 1110–1117 (1977).

87. Saari, J.C., Bunt, A.H., Futterman, S., and Berman, E.R., Localization of cellular retinol-binding protein in bovine retina and retinal pigment epithelium with a consideration of the pigment epithelium isolation technique. *Invest. Ophthalmol. Vis. Sci.* 16, 797–806 (1977).

88. Holm, E., Demonstration of hemeralopia in rats nourished on food devoid of fat soluble A vitamin. *Am. J. Physiol.* 73, 79–84 (1925).

89. Brenner, S., and Roberts, L.J., Effects of vitamin A depletion in young adults. *Arch. Intern. Med.* 71, 474–482 (1943).

90. Hume, E.M., and Krebs, H.A., Vitamin A requirement of human adults. An experimental study of vitamin A deprivation in man. Vitamin A Sub-Committee of the Accessory Food Factors Committee, Medical Research Council, Special Report Series No. 264, 7–145 (1949).

91. Sauberlich, H.E., Hodges, R.E., Wallace, D.L., Kolder, H., Canham, J.E., Hood, J., Raica, N., and Lowry, L.K., Vitamin A metabolism and requirements in the human studied with the use of labeled retinol. *Vitam. Horm.* 32, 251–275 (1974).

92. Russell, R.M., Morrison, S.A., Smith, F.R., Oaks, E.V., and Carney, E.A., Vitamin A reversal of abnormal dark adaptation in cirrhosis. Study of effects on the plasma retinol transport system. *Ann. Intern. Med.* 88, 622–626 (1978).

93. Partaman, I., Sidrys, L., and Tripathi, R., Iatrogenic night blindness and keratoconjunctival xerosis. *N. Engl. J. Med. Corres.* 301, 943–944 (1979).

94. Russell, R.M., Multack, R., Rosenberg, I.H., Smith, A.C., and Krill, A.E., Dark adaptation testing for diagnosis of subclinical vitamin-A deficiency and evaluation of therapy. *Lancet* 2, 1161–1163 (1973).

95. Vahlquist, A., Sjölund, K., Norden, A., Peterson, P.A., Stigmar, G., and Johansson, B., Plasma vitamin A transport and visual dark adaptation in diseases of intestine and liver. *Scand. J. Clin. Lab. Invest.* 38, 301–308 (1978).

96. Petersen, R.A., Petersen, A.S., and Robb, R.M., Vitamin A deficiency with xerophthalmia and night blindness in cystic fibrosis. *Am. J. Dis. Child.* 116, 662–665 (1968).

97. Weinstein, A., *Ueber Nacht- und Tag-blindheit*, Würzburg (1858).

98. Fleury, et al. 1842. Cited in Stephenson [79].
99. Dixit, D.T., Night blindness in third trimester of pregnancy, *Indian J. Med. Res.* 54, 791–795 (1966).
100. Sommer, A., Hussaini, G., Muhilal, Tarwotjo, L., Susanto, D., and Saroso, J.S., History of nightblindness: a simple tool for xerophthalmia screening, *Am. J. Clin. Nutr.* 33, 887–891 (1980).
101. Sommer, A., Emran, N., and Tjakrasudjatma, S., Clinical characteristics of vitamin A responsive and nonresponsive Bitot's spots, *Am. J. Ophthalmol.* 90, 160–174 (1980).
102. Chou, C.H., Effect of vitamin deficiency on light sense in cases of xerosis and pigmentation of the conjunctiva, *Chin. Med. J.* 16, 365–369 (1930).
103. Dowling, J.E., and Wald, G., The biological function of vitamin A acid, *Proc. Natl. Acad. Sci.* 46, 587–608 (1960).
104. Sommer, A., Tjakrasudjatma, S., Djunaedi, E., and Green, W.R., Vitamin A responsive panocular xerophthalmia in a healthy adult, *Arch. Ophthalmol.* 96, 1630–1634 (1978).
105. Blankhart, D.M., Individual intake of food in young children in relation to malnutrition and night blindness, *Trop. Geogr. Med.* 19, 144–153 (1967).
106. Brockman, H., Commenting on Stephenson's paper, *Trans. Ophthalmol. Soc. U.K.* 18, 400–401 (1896).
107. Purtscher, O., Beitrag zur Kenntnis der Ophthalmia hepatica (hepatica-Baas), *Graefe's Arch. Ophthalmol.* 50, 83–122 (1900).
108. Mikamo (1915), cited in Elliot, R.H. [77].
109. Wright, R.E., Keratomalacia in Southern India, *Br. J. Ophthalmol.* 6, 164–175 (1922).
110. Uyemura, M., Ueber ein merkwurdige Augenhintergrundveranderung bei zwei Fallen von idiopathischer Hemeralopie, *Klin. Monatsbl. Augenheilkd.* 81, 171–173 (1928).
111. Fuchs, A., White spots of the fundus combined with night blindness and xerosis (Uyemura's Syndrome), *Am. J. Ophthalmol.* 48, 401–403 (1959).
112. Fuchs, A., Ein Fall von weisspunktierten Fundus bei hemeralopie mit xerose, *Klin. Monatsbl. Augenh.* 81, 849–850 (1928).
113. Teng-Khoen-Hing, Fundus changes in Hypovitaminosis A, *Ophthalmologica Basel* 137, 81–85 (1959).
114. Bors, F. and Fells, P., Reversal of the complications of self-induced vitamin A deficiency, *Br. J. Ophthalmol.* 55, 210–214 (1971).
115. Fells, P. and Bors, F., Ocular complications of self-induced vitamin A deficiency, *Trans. Ophthalmol. Soc. U.K.* 89, 221–228 (1969).
116. Teng, K.H., Further contributions to the fundus xerophthalmicus, *Ophthalmologica* 150, 219–238 (1965).
117. Herron, W.L. and Riegel, B.W., Production rate and removal of rod outer segment material in vitamin A deficiency, *Invest. Ophthalmol. Vis. Sci.* 13, 46–53 (1974).
118. Carter-Dawson, L., Kuwabara, T., O'Brien, P.J., and Bieri, J.G., Structural and biochemical changes in vitamin A-deficient rat retinas, *Invest. Ophthalmol. Vis. Sci.* 18, 437–446 (1979).

119. Tansley, K.: Factors affecting the development and regeneration of visual purple in the mammalian retina. *Proc. R. Soc. London 114*, 79–103 (1933).
120. Johnson, M.L.: Degeneration and repair of the rat retina in avitaminosis A. *Arch. Ophthalmol. 29*, 793–810 (1943).
121. Ramalingaswami, V., Leach, E.H., and Srinamachari, S.: Ocular structure in vitamin A deficiency in the monkey. *Q. J. Exp. Physiol. 40*, 337–347 (1955).
122. Hayes, K.C.: Retinal degeneration in monkeys induced by deficiencies of vitamin E or A. *Invest. Ophthalmol. 13*, 499–510 (1974).
123. Pillat, A.: Die klassischen symptome der vitamin A mangels und der vitamin A mangel als gesamterkrankung des körpers. *Klin. Wochenschr. 55*, 779–783 (1940).
124. Sipperley, J.O., Quigley, H.A., and Gass, J.D.M.: Traumatic retinopathy in primates: the explanation of Commotio Retinae. *Arch. Ophthalmol. 96*, 2267–2273 (1978).
125. Sloan, L.L.: Rate of dark adaptation and regional threshold gradient of the dark adapted eye: Physiologic and clinical studies. *Am. J. Ophthalmol. 30*, 705–720 (1947).
126. Baas, K.L.: Ueber eine Ophthalmia hepatica. *Graefe's Arch. Ophthalmol. 40*, 212–246 (1894).
127. Netter, C.: Bull. Soc. Acad. Sci., Paris 70, 577 (1870).
128. Nelson, A.F., Lamb, A.R., and Heller, V.G.: The vitamin requirement of various species of animals. III. The production and cure of xerophthalmia in the suckling. *Am. J. Dis. Child. 23*, 518–520 (1922).
129. Kollock, C.W.: A form of xerosis. *Ophthalmic Review 9*, 249–251 (1890).
130. Mayou, M.S.: II. Diseases of the conjunctiva. 4. The pathological anatomy of the plaques in epithelial xerosis. *Trans. Ophthalmol. Soc. U.K. 24*, 9–16 (1904).
131. Yassur, Y., Yassur, S., Zaltzani, S., Zachs, U., and Ben-Sira, I.: Keratomalacia. *Isr. J. Med. Sci. 8*, 1192–1194 (1972).
132. Sie Boen Liam: Over vlekken van Bitot niet behorend tot het Ziektebeeld der xerophthalmie. *Geneesk. Tijdschr. Ned. Indie. 78*, 665–670 (1938).
133. Daga, S., Agarwal, K.N., and Bhatt, L.: Serum vitamin A levels in childhood xerophthalmia. *Indian J. Med. Res. 57*, 755–757 (1969).
134. Gopalan, C., Venkatachalam, P.S., and Bhavani, B.: Studies of vitamin A deficiency in children. *Am. J. Clin. Nutr. 8*, 833–840 (1960).
135. Bagchi, K., Halder, K., and Chowdhury, S.R.: Study of Bitot's spot with special reference to protein malnutrition. *J. Indian Med. Assoc. 33*, 401–407 (1959).
136. Kuming, B.S., and Politzer, W.M.: Xerophthalmia and protein malnutrition in Bantu children. *Br. J. Ophthalmol. 51*, 649–665 (1967).
137. Bodger, F.C.: The ocular effects of vitamin A deficiency in man in the tropics. *Exp. Eye Res. 3*, 367–372 (1964).
138. Darby, W.J., McGanity, W.J., McLaren, D.S., Paton, D., Alemu, A.Z., and Medhin, A.M.G.: Bitot's spots and vitamin A deficiency. *Public Health Reports 75*, 738–743 (1960).

139. Mehrjee, V.M., Bitot's spots in Trinidad. *Am. J. Ophthalmol.* 24, 1029–1034 (1941).

140. Rodger, F.C., Sanduzzaha, H., Grover, A.D., and Fazal, A., A reappraisal of the ocular lesion known as Bitot's spots. *Br. J. Nutr.* 17, 475–485 (1963).

141. Sinha, D.P., and Bang, F.B., The effect of massive doses of vitamin A on the signs of vitamin A deficiency in preschool children. *Am. J. Clin. Nutr.* 29, 110–115 (1976).

142. Reddy, P.S., Bitot's spots and vitamin A deficiencies. *Trans. Ophthalmol. Soc. New Zealand* 17, 90–93 (1965).

143. Paton, D., and McLaren, D.S., Bitot's spots. *Am. J. Ophthalmol.* 50, 568–574 (1960).

144. Boohier, L.E., Callison, E.C., and Hewston, E.M., Experimental determination of minimum vitamin A requirements of normal adults. *J. Nutr.* 17, 317–331 (1939).

145. Emirii, A.P., The cornea in kwashiorkor. *J. Trop. Pediatr.* 17, 117–134 (1971).

146. John, L., The disturbances of sensibility of the cornea and conjunctiva in xerosis and keratomalacia of adults with a contribution to the explanation of the genesis of these diseases. *Arch. Ophthalmol.* 5, 374–391 (1931).

147. Sullivan, W.R., McCulley, J.P., and Dohlman, C.H., Return of goblet cells after vitamin A therapy in xerosis of the conjunctiva. *Am. J. Ophthalmol.* 75, 720–725 (1973).

148. Gombos, G.M., Hornblass, A., and Vendeland, J., Ocular manifestations of vitamin A deficiency. *Ann. of Ophthalmol.* 2, 680–684 (1970).

149. Hypovitaminosis A. Round table discussion. *Fed. Proc.* 17, 103–143 (1958).

150. McLaren, D.S., A study of the factors underlying the special incidence of keratomalacia in Oriya children in the Phulbani and Ganjam districts of Orissa, India. *J. Trop. Pediatr.* 2, 135–140 (1956).

151. Basu, D.C., Dutta, L.C., Goswami, P., and Saha, S.K., Role of serum protein in the ocular manifestations of vitamin A deficiency. *Br. J. Ophthalmol.* 55, 700–703 (1971).

152. Sommer, A., *Field Guide to the Detection and Control of Xerophthalmia*, WHO, Geneva, 1978.

153. Nicholls, E., and Nimalasuriya, A., Bitot's spots in Ceylon. *Lancet I*, 1432–1434 (1939).

154. Sommer, A., Green, W.R., and Kenyon, K.R., Clinical-histopathologic correlations of vitamin A responsive and nonresponsive Bitot's spots. *Arch. Ophthalmol.* 99, 2014–2027 (1981).

155. Sweet, L.K., and Kang, H.L., Clinical and anatomic study of avitaminosis A among the Chinese. *Am. J. Dis. Child.* 50, 699–734 (1935).

156. Pillat, A., Does keratomalacia exist in adults? *Arch. Ophthalmol.* 2, 256–287 (1929).

157. Smith, R.S., Farrell, L., and Bailey, T., Keratomalacia. *Surv. Ophthalmol.* 20, 213–219 (1975).

158. Herbert, H., Comments on paper of Mayou. *Trans. Ophthalmol. Soc. U.K.* 21, 15–16 (1901).

159. Damican-Gillet, M., Conjunctival lesions in avitaminosis A. A histopathological study, *Trop. Geogr. Med. 10*, 233–238 (1958).
160. Kirwan, E.O., Sen, K., and Bose, N., Nutrition and its bearing on preventable blindness and eye diseases in Bengal, *Indian J. Med. Res. 31*, 49–62 (1943).
161. Escapini, H., Vitamin A deficiency, its ocular stigmata, Proceedings, Western Hemisphere Nutrition Congress II, pp. 1–7, (1968).
162. Kessing, S.V., Mucous gland system of the conjunctiva, *Acta Ophthalmol. (Suppl.) 95*, 9–133 (1968).
163. Fell, H.B. and Mellanby, E., Metaplasia produced in tissue cultures of chick ectoderm by high vitamin A, *J. Physiol. 119*, 470–488 (1953).
164. Wolbach, S.B. and Howe, P.R., Tissue changes following deprivation of fat-soluble A vitamin, *J. Exp. Med. 42*, 753–777 (1925).
165. Mori, S., Primary changes in eyes of rats which result from deficiency of fat-soluble A in diet, *J.A.M.A. 79*, 197–200 (1922).
166. Mori, S., The changes in the para-ocular glands which follow the administration of diets low in fat-soluble A, with notes of the effect of the same diets on the salivary glands and the mucosa of the larynx and trachea, *John Hopkins Hospital Bulletin*, 33, 357–359 (1922).
167. Wilson, J.R. and DuBois, R.O., Keratomalacia in infants, with postmortem examination, *Am. J. Dis. Child. 26*, 431–436 (1923).
168. Vaughan, D.G., Xerophthalmia, *Arch. Ophthalmol. 51*, 789–798 (1954).
169. Vijayaraghavan, K., Sarma, K.V.R., Reddy, V., and Bhaskaram, P., Rose Bengal staining for detection of conjunctival xerosis in nutrition surveys, *Am. J. Clin. Nutr. 31*, 892–894 (1978).
170. Mackenzie, A., Bitot's spots, *Lancet 2*, 341 (1939).
171. Sommer, A., Emran, N., and Tamba, T., Vitamin A-responsive punctate keratopathy in xerophthalmia, *Am. J. Ophthalmol.* 87, 330–333 (1979).
172. Appelmans, M., Lebas, P., and Missotten, L., A propos de l'avitaminose A et ses manifestations oculaires, *Scalpel 110*, 217–234 (1957).
173. Duke-Elder, S. and Leigh, A.G., "Diseases of the outer eye," in *System of Ophthalmology*, ed. S. Duke-Elder, p. 1122, Kimpton, London (1965).
174. Jellife, D.B., *The Assessment of the Nutritional Status of the Community*, pp. 221–241, WHO, Geneva (1966).
175. Stephenson, S., On sloughing corneae in infants; an account based upon the records of thirty-one cases, *Ophthalmoscope* 8, 782–818 (1910).
176. Bloch, C.E., Blindness and other diseases in children arising from deficient nutrition (lack of fat-soluble A factor), *Am. J. Dis. Child. 27*, 139–148 (1924).
177. Wille, W.A., Xerophthalmia, a deficiency disease, *Trans. Far Eastern Assoc. Trop. Med. 4th Congr. 1*, 245–254 (1921).
178. Walien, C.I., A study of the effect of vitamin A supplementation in Egyptian children, *Vitamin A Deficiency and Blindness Prevention*, p. 13, American Foundation Overseas Blind, New York, (1974).
179. Kuming, B., The evolution of keratomalacia, *Trans. Ophthalmol. Soc. U.K.* 87, 305–315 (1967).

180. Schoeler, E., Beitrag zu den xerotischen Hornhautleiden unter Anführung einer neuen, bisher von mir nicht beobachteten form dieses Leidens nach vorausgegangener Entziehungskur, *Klin. Wochenschr.* 24, 979–982 (1887).

181. Kruse, H.D., The ocular manifestations of avitaminosis A, with especial consideration of the detection of early changes by biomicroscopy, *Milbank Mem. Fund Q.* 19, 207–240 (1941).

182. Berliner, M.L., Regarding the early detection of avitaminosis A by gross or biomicroscopic examination of the conjunctiva, *Am. J. Ophthalmol.* 25, 302–308 (1942).

183. Tandon, B.N., Ramachandran, K., Nath, I.M., Sood, N.N., Gahlot, D.K., Gupta, M.C., Wah, J.P., Sinha, S.N., Hasteer, P.C., and Kutty, P.R., Vitamin A nutritional status of rural community of Khol block in Haryana, North India, *Am. J. Clin. Nutr.* 28, 1436–1442 (1975).

184. Sauter, J.J.M., Diagnosis of xerophthalmia by vital staining, *Trop. Doctor* 6, 91–93 (1976).

185. Kusin, J.A., Sinaga, H.S.R.P., and Marpaung, A.M., Xerophthalmia in North Sumatra, *Trop. Geog. Med.* 29, 41–46 (1977).

186. Kusin, J.A., Soewonto, W., and Sinaga, H.S.R.P., Rose Bengal and lissamine green vital stains, useful diagnostic aids for early stages of xerophthalmia? *Am. J. Clin. Nutr.* 32, 1539 (1979).

187. Emran, N., and Sommer, A., Lissamine green staining in the clinical diagnosis of xerophthalmia, *Arch. Ophthalmol.* 97, 2333–2335 (1979).

188. Sommer, A., Conjunctival xerosis, *Am. J. Clin. Nutr.* (corrs.) 33, 1313–1314 (1980).

189. Pillat, A., Bacteriological findings in praexerosis cornea, *Arch. Ophthalmol.* 125, 173–206 (1930).

190. Mann, I., Pirie, A., Tansley, K., and Wood, C., Some effects of vitamin-A deficiency on the eye of the rabbit, *Am. J. Ophthalmol.* 29, 801–815 (1946).

191. Pillat, A., Production of pigment in the conjunctiva in nightblindness, prexerosis, xerosis and keratomalacia of adults, *Arch. Ophthalmol* 9, 25–47 (1933).

192. Brown, J., Case of ulcerated cornea from inanition, *Edinburgh J. Med. Sci.* (Corrs.) 3, 218–1827.

193. Fischer, J.N., Keratomalacie nach Masern, *Lehrbuch degesamt Entzündungen*, p. 275–1843.

194. Biswas, R.B., Ocular manifestations due to lack of vitamin A in the system, *Indian Med. Gaz.* 76, 747–750 (1941).

195. Owen, H.B., and Hennessey, R.S.F., Keratomalacia in liver disease, *Trans. R. Soc. Trop. Med. Hyg.* 25, 367–375 (1932).

196. Sommer, A., The xerophthalmic cornea, in, *The Cornea in Health and Disease*, ed. P. Trevor-Roper, 1107–1121, Roy. Soc. Med., London (1981).

197. Sommer, A., and Sugana, T., Corneal xerophthalmia and keratomalacia, *Arch. Ophthalmol.* (1982). In Press.

198. Dohlman, C.H., Lemp, M.A., and English, F.D., Dry eye syndromes, *Int. Ophthalmol. Clin.* 10, 215–251 (1970).

199. Baum, J.L., Mishima, S., and Boruchoff, S.A., On the nature of dellen, *Arch. Ophthalmol.* 79, 657–662 (1968).

200. Pfister, R. and Renner, M., The histopathology of experimental dry spots and defleu in the rabbit cornea: a light microscopy and scanning and transmission electron microscopy study. *Invest. Ophthalmol. Vis. Sci. 16*, 1025–1038 (1977).

201. Wason, I.M., Ophthalmia associated with a dietary deficiency in fat-soluble vitamin (A): study of the pathology. *JAMA 76*, 908–912 (1921).

202. Van Horn, D.L., Schutten, W.H., Hyndink, R.A., and Kurz, P., Xerophthalmia in vitamin A-deficient rabbits. Clinical and ultrastructural alterations in the cornea. *Invest. Ophthalmol. Vis. Sci. 19*, 1067–1079 (1980).

203. Dohlman, C.H. and Kalevar, V., Cornea in hypovitaminosis A and protein deficiency. *Isr. J. Med. Sci. 8*, 1179–1183 (1972).

204. Pirie, A., Effect of vitamin A deficiency on the cornea. *Trans. Ophthalmol. Soc. U.K. 98*, 357–360 (1978).

205. Slansky, H.H., Freeman, M.I., and Itoi, M., Collagenolytic activity in bovine corneal epithelium. *Arch. Ophthalmol. 80*, 496–498 (1968).

206. Itoi, M., Gnadinger, M.C., Slansky, H.H., Freeman, M.I., and Dohlman, C.H., Collagenases in the cornea. *Exp. Eye. Res. 8*, 369–373 (1969).

207. Slansky, H.H., Gnadinger, M.C., Itoi, M., and Dohlman, C.H., Collagenase in corneal ulcerations. *Arch. Ophthalmol. 82*, 108–111 (1969).

208. Brown, S.I., Weller, C.A., and Wasserman, H.E., Collagenolytic activity of alkali-burned corneas. *Arch. Ophthalmol. 81*, 370–373 (1969).

209. Pirie, A., Werb, Z., and Burleigh, M.C., Collagenase and other proteinases in the cornea of the retinol-deficient rat. *Br. J. Nutr. 34*, 297–311 (1975).

210. Kenyon, K.R., Berman, M., Rose, J., and Gage, J., Prevention of stromal ulceration in the alkali-burned rabbit cornea by glued-on contact lens. Evidence for the role of polymorphonuclear leukocytes in collagen degradation. *Invest. Ophthalmol. Vis. Sci. 18*, 570–587 (1979).

211. Johnson-Muller, B. and Gross, J., Regulation of corneal collagenase production: epithelial-stromal cell interaction. *Proc. Nat'l. Acad. Sci. U.S.A. 75*, 4417–4421 (1978).

212. Hook, R.N., Hook, C.W., and Brown, S.I., Fibroblast collagenase, partial purification and characterization. *Invest. Ophthalmol. Vis. Sci. 12*, 771–776 (1973).

213. BenEzra, D. and Tanishima, T., Possible regulatory mechanisms of the cornea. I. Epithelial-stromal interaction in vitro. *Arch. Ophthalmol. 96*, 1891–1896 (1978).

214. Gordon, J.M., Bauer, E.A., and Eisen, A.Z., Collagenase in human cornea. *Arch. Ophthalmol. 98*, 341–345 (1980).

215. Stephenson, M. and Clark, A.B., A contribution to the study of keratomalacia among rats. *Biochem. J. 14*, 502–521 (1920).

216. Seng, W.L., Glogowski, J.A., Wolf G., Berman, M.B., Kenyon, K.R., and Kiorpes, T.C., The effect of thermal burns on the release of collagenase from corneas of vitamin A-deficient and control rats. *Invest. Ophthalmol. Vis. Sci. 19*, 1461–1470 (1980).

217. Wiggert, B., Bergsma, D.R., Helmsen, R.J., Alligood, J., Lewis, M., and Chader, G.J., Retinol receptors in corneal epithelium, stroma and endothelium. *Biochim. et Biophys. Acta 491*, 104–113 (1977).

218. Kim, Y.C., and Wolf, G., Vitamin A deficiency and the glycoproteins of rat corneal epithelium. *J. Nutr. 104*, 710–718 (1974).

219. Lexmson, R.A., Paterson, C.A., and Pfister, R.R., Ascorbic acid prevents corneal ulceration and perforation following experimental alkali burns. *Invest. Ophthalmol. Vis. Sci. 15*, 986–993 (1976).

220. Pfister, R.R., and Paterson, C.A., Additional clinical and morphological observations on the favorable effect of ascorbate in experimental ocular alkali burns. *Invest. Ophthalmol. Vis. Sci. 16*, 478–487 (1977).

221. Mori, S., The pathological anatomy of ophthalmia produced by diets containing fat-soluble A, but unfavorable contents of certain inorganic elements. *Am. J. Hyg. 3*, 99–102 (1923).

222. Wright, J.C., and Meger, G.E., A review of the Schirmer test for tear production. *Arch. Ophthalmol. 67*, 564–565 (1962).

223. Lamberts, D.W., Foster, C.S., and Perry, H.D., Schirmer test after topical anesthesia and the tear meniscus height in normal eyes. *Arch. Ophthalmol. 97*, 1082–1085 (1979).

224. Lemp, M.A., Holly, F.J., Iwata, S., and Dohlman, C.H., The precorneal tear film. I. Factors in spreading and maintaining a continuous tear film over the corneal surface. *Arch. Ophthalmol. 83*, 89–94 (1970).

225. Mishima, S., Some physiological aspects of the precorneal tear film. *Arch. Ophthalmol. 73*, 233–241 (1965).

226. Holly, F.J., and Lemp, M.A., Surface chemistry of the tear film, implications for dry eye syndromes, contact lenses, and ophthalmic polymers. *J. Contact Lens Soc. Am. 5*, 12 (1971).

227. Lemp, M.A., Dohlman, C.H., Kuwabara, T., Holly, F.J., Carroll, J.Ni., Dry eye secondary to mucus deficiency. *Tr. Am. Acad. Ophthalmol. Otolaryngol. 75*, 1223–1227 (1971).

228. Beaver, D.L., Vitamin A deficiency in the germ-free rat. *Am. J. Pathol. 38*, 335–349 (1961).

229. Pfister, R.R., and Renner, M.E., The corneal and conjunctival surface in vitamin A deficiency. A scanning electron microscope study. *Invest. Ophthalmol. Vis. Sci. 17*, 874–883 (1978).

230. Sjogren, H., Zur Kenntnis der Kerato-conjunctivitis sicca (Keratitis filiformis bei hypofunktion der Tranendrusen). *Acta Ophthalmol. 11*, 1–151 (1933).

231. Sjogren, H., and Bloch, K.J., Keratoconjunctivitis sicca and the Sjögren syndrome. *Surv. Ophthalmol. 16*, 145–159 (1971).

232. Brown, S.I., and Frayson, M., Marginal furrows. A characteristic corneal lesion of rheumatoid arthritis. *Arch. Ophthalmol. 79*, 563–567 (1968).

233. Gudas, P.P., Altman, B., Nicholson, D.H., and Green, W.R., Corneal perforations in Sjogrens syndrome. *Arch. Ophthalmol. 90*, 470–472 (1973).

234. Radtke, N., Meyers, S., and Kaufman, H.E., Sterile corneal ulcers after cataract surgery in keratoconjunctivitis sicca. *Arch. Ophthalmol. 96*, 51–56 (1978).

235. Ralph, R.A., Conjunctival goblet cell density in normal subjects and in dry eye syndromes. *Invest. Ophthalmol. Vis. Sci. 14*, 299–302 (1975).

236. Abdel-Khalek, L.M.R., Williamson, J., and Lee, W.R., Morphological changes in the human conjunctival epithelium. II. In keratoconjunctivitis sicca. *Br. J. Ophthalmol. 62*, 800–806 (1978).

237. Jones, D.B., Prospects in the management of tear-deficiency states. *Tr. Am. Acad. Ophthalmol. Otolaryngol. 83*, 693–700 (1977).

238. Allen, M., Wright, P., and Reid, L., The human lacrimal gland. A histochemical and organ culture study of the secretory cells. *Arch. Ophthalmol. 88*, 493–497 (1972).

239. Beitch, L., The induction of keratinization in the corneal epithelium. A comparison of the "dry" and Vitamin A-deficient eyes. *Invest. Ophthalmol. Vis. Sci. 9*, 527–543 (1970).

240. Pfister, R.R. and Murphy, G.E., Corneal ulceration and perforation associated with Sjogren's syndrome. Arch. Ophthalmol. 98, 89–94 (1980).

241. Strauss, J.S., Vitale, J.J., Downing, D.T., and Franco, D., Surface lipid composition in children with protein calorie malnutrition. *Am. J. Clin. Nutr. 31*, 237–240 (1978).

242. Katz, J. and Kaufman, H.E., Corneal exposure during sleep (nocturnal lagophthalmos). *Arch. Ophthalmol. 95*, 449–453 (1977).

243. Valenton, M.J. and Tan, R.V., Secondary ocular bacterial infection in hypovitaminosis A xerophthalmia. *Am. J. Ophthalmol. 80*, 673–677 (1975).

244. Pranhus, C., Runyan, T.E., and Lindberg, R.B., Ocular flora in the severely burned patient. *Arch. Ophthalmol. 96*, 1421–1424 (1978).

245. Smolin, G. and Okumoto, M., Staphylococcal blepharitis. *Arch. Ophthalmol. 95*, 812–816 (1977).

246. Sommer, A., Muhilal, H., Tarwotjo, I., Djunaedi, E., and Glover, J., Oral versus intramuscular vitamin A in the treatment of xerophthalmia. *Lancet I*, 557–559 (1980).

247. Sommer, A. and Emran, N., Topical retinoic acid in the treatment of corneal xerophthalmia. *Am. J. Ophthalmol. 86*, 615–617 (1978).

248. McLaren, D.S., Shirajian, E., Tchalian, M., and Khoury, G., Xerophthalmia in Jordan. *Am. J. Clin. Nutr. 17*, 417–430 (1965).

249. Fisher, E. and Allen, J.H., Mechanism of corneal destruction by Pseudomonas proteases. *Am. J. Ophthalmol. 46*, 249–255 (1958).

250. Iglewski, B.H., Burns, R.P. and Gipson, I.K., Pathogenesis of corneal damage from Pseudomonas exotoxin A. *Invest. Ophthalmol. Vis. Sci. 16*, 73–76 (1977).

251. Kessler, E., Mondino, B.J., and Brown, S.I., The corneal response to Pseudomonas aeruginosa: histopathological and enzymatic characterization. *Invest. Ophthalmol. Vis. Sci. 16*, 116–125 (1977).

252. Eiferman, R.A., Cryotherapy of Pseudomonas keratitis and scleritis. *Arch. Ophthalmol. 97*, 1637–1639 (1979).

253. Reddy, V. and Srikantia, S.G., Serum vitamin A in kwashiorkor. *Am. J. Clin. Nutr. 18*, 405–409 (1966).

254. Pereira, S.M., Begum, A., and Dunn, M.E., Vitamin A deficiency in kwashiorkor. *Am. J. Clin. Nutr. 19*, 482–486 (1966).

255 Venkataswamy, G., Krishnamurthy, K.A., Chandra, P., Kabir, S.A., and Pyne, A., A nutrition rehabilitation centre for children with xerophthalmia. *Lancet 1*, 1120–1122 (1976).

256 Tijssen, J., Effect of keratophthalmia and other frequent ocular diseases on increase of blindness in the Netherlands. *Nederl.Tijdschr. v. Geneesk.* 78, 5452–5458 (1934).

257 Oomen, H.A.P.C., Clinical epidemiology of xerophthalmia in man. *Am. J. Clin. Nutr.* 22, 1098–1105 (1969).

258 ten Doesschate, J., Clinical aspects of keratomalacia. *Isr. J. Med. Sci.* 8, 1184–1189 (1972).

259 Sommer, A. and Mululal, Nutritional factors in corneal xerophthalmia and keratomalacia. *Arch. Ophthalmol.* (1982). In Press.

260 Beckin, W.L., Volwiler, W., Goldsworthy, P.D., Garby, L.E., Reynolds, W.F., Stogsdill, R., and Stender, R.S., Studies of I-131 albumin catabolism and distribution in normal young male adults. *J. Clin. Invest. 41*, 1312–1333 (1962).

261 Shetty, P.S., Watrasiewicz, K.E., Jung, R.T., and James, W.P.T., Rapid-turnover transport proteins: an index of subclinical protein-energy malnutrition. *Lancet 2*, 230–232 (1979).

262 Schwandt, P., Fatch Moghadam, A., Richter, W., and Sandel, P., Retinol-binding protein in malnutrition. *Lancet 2* (corres.) 794 (1979).

263 Ingenbleek, Y., Van den Schrieck, H., De Nayer, P., and De Visscher, M., Albumin, transferrin and the thyroxine-binding prealbumin/retinol-binding protein (TBPA/RBP) complex in assessment of malnutrition. *Clin. Chim. Acta 63*, 61–67 (1975).

264 Ingenbleek, Y., De Visscher, M., and De Nayer, P., Measurement of prealbumin as index of protein-calorie malnutrition. *Lancet 2*, 106–109 (1972).

265 Vahlquist, A., Peterson, P.A., and Wibell, L., Metabolism of the vitamin A transporting protein complex. I. Turnover studies in normal persons and in patients with chronic renal failure. *Eur. J. Clin. Invest. 3*, 352–362 (1973).

266 Socolow, E.L., Wolber, K.A., Purdy, R.H., Holloway, M.T., and Ingbar, S.H., Preparation of I-131 labeled human serum prealbumin and its metabolism in normal and sick patients. *J. Clin. Invest. 44*, 1600–1609 (1965).

267 Smith, F.R. and Goodman, D.S., Metabolism of plasma retinol-binding protein in man. *J. Clin. Invest. 49*, 1754–1761 (1970).

268 Vahlquist, A., Metabolism of the vitamin-A transporting protein complex: Turnover of retinol-binding protein, prealbumin, and vitamin A in a primate (Macaca mulatta). *Scand. J. Clin. Lab. Invest. 30*, 349–360 (1972).

269 Meyer, K.A., Popper, H., Steigman, F., Walters, W.H., and Zevin, S., Comparison of vitamin A of liver biopsy specimens with plasma vitamin A in man. *Proc. Soc. Exp. Biol. Med. 49*, 589–591 (1942).

270 Popper, H., Steigman, F., Meyer, K.A., and Zevin, S.S., Relation between hepatic and plasma concentrations of vitamin A in human beings. *Arch. Int. Med. 72*, 439–460 (1943).

271. Hoppner, K., Phillips, W.E.J., Murray, T.K., and Campbell, J.S., Survey of liver vitamin A stores of Canadians, *Canad. Med. Assn. J.* 99, 983–986 (1968).
272. May, C.D., Blacktan, K.D., McCreary, J.F., and Allen, F.H., Clinical studies of vitamin A in infants and in children, *Am. J. Dis. Child.* 59, 1167–1184 (1940).
273. Solon, F.S., Popkin, B.M., Fernandez, T.L., and Latham, M.C., Vitamin A deficiency in the Philippines: A study of xerophthalmia in Cebu, *Am. J. Clin. Nutr.* 31, 360–368 (1978).
274. Brink, E.W., Perera, W.D.A., Broske, S.P., Cash, R.A., Smith, J.L., Sauberlich, H.E., and Bashor, M.M., Vitamin A status of children in Sri Lanka, *Am. J. Clin. Nutr.* 32, 84–91 (1979).
275. Brown, K.H., Gallan, A., and Alangir, S.M., Xerophthalmia, protein-calorie malnutrition, and infections in children, *J. Pediatr.* 95, 651–656 (1979).
276. McCollum, E.V., and Simmonds, N., *The Newer Knowledge of Nutrition*, 3rd Ed. p. 289, Macmillan, New York (1925).
277. Klerks, J.A., The assessment of the nutritional status of Indonesian schoolchildren, *Berita Kementrian Kesehatan Republik Indonesia*, 11–41 (1956).
278. Arroyave, G., Wilson, D., Mendez, J., Behar, M., and Scrimshaw, N.S., Serum and liver vitamin A and lipids in children with severe protein malnutrition, *Am. J. Clin. Nutr.* 9, 180–185 (1961).
279. Smith, F.R., Goodman, D.S., Zaklama, M., Gabr, M.K., Maraghy, S.E., and Patwardhan, V.N., Serum vitamin A, retinol binding protein, and prealbumin concentrations in protein-calorie malnutrition. I. A functional defect in hepatic retinol release, *Am. J. Clin. Nutr.* 26, 973–981 (1973).
280. Moore, T., Vitamin A and proteins, *Vitam. Horm.* 18, 431–437 (1960).
281. Baumann, C.A., Foster, E.G., and Moore, P.R., Effect of dibenzanthracene, of alcohol, and of other agents on vitamin A in rat, *Biol. Chem.* 142, 597–608 (1942).
282. Basu, N.M. and De, N.K., Storage of vitamin A in liver under different conditions of protein and carbohydrate intake, *Sci. and Culture (Calcutta)* 6, 672 (1941).
283. Muto, Y., Smith, J.E., Milch, P.O., and Goodman, D.S., Regulation of retinol-binding protein metabolism by vitamin A status in the rat, *J. Biol. Chem.* 247, 2542–2550 (1972).
284. Smith, F.R., and Goodman, D.S., The effects of diseases of the liver, thyroid and kidneys on the transport of vitamin A in human plasma, *J. Clin. Invest.* 50, 2426–2436 (1971).
285. Graham, G.G., Creed, H.M., Phul, M., MacLean, W.C., Jr., Rabold, J., Kallman, C.H., and Mellits, E.D., Determinants of growth among poor children: relation of nutrient intakes to expenditure for food, *Am. J. Clin. Nutr.* 34, 555–561 (1981).
286. Sinha, B.N., The influence of protein on keratomalacia. II. Experimental observations in albino rats, *J. Indian Med. Assoc.* 47, 213–223 (1966).
287. Annual Report, National Institute of Nutrition, Hyderabad, India (1981).
288. Saari, J.C., Bredberg, L., and Futterman, S., Esterification of retinol by

retinoblastoma cell lines WERI Rb1 and Y79. *Invest. Ophthalmol. Vis. Sci.* *19*, 1301–1308 (1980).

289. Scragg, J. and Rubidge, C., Kwashiorkor in African children in Durban, *Br. Med. J.* *2*, 1759–1766 (1960).

290. Sommer, A., Sugana, T., Hussaini, G., Emran, N., and Tarwotjo, I., Xerophthalmia: Determinants and control. Proceedings. Intern'l Cong. Series No. 450. XXIII Concilium Ophthalmol., Excerpta Medica, pp. 1615–1618, Amsterdam–Oxford, 1978.

291. Rao, K.S.J. and Khan, I., Basal energy metabolism in protein calorie malnutrition and vitamin A deficiency. *Am. J. Clin. Nutr.* *27*, 892–896 (1974).

292. McLaren, D.S., Influence of protein deficiency and sex on the development of ocular lesions and survival time of the vitamin A deficient rat. *Br. J. Ophthalmol.* *43*, 234–241 (1959).

293. Peterson, P.A., Nilsson, S.F., Ostberg, L., Rask, L., and Vahlquist, A., Aspects of the metabolism of retinol-binding protein and retinol, *Vitam. Horm.* *32*, 181–214 (1974).

294. Mululal, H. and Glover, J., Effects of dietary deficiencies of protein and retinol on the plasma level of retinol-binding protein in the rat, *Br. J. Nutr.* *32*, 549–558 (1974).

295. Vitamin A enrichment of donated foods (with special reference to dry skim milk powder), *Bulletin, Protein Advisory Group*, VI, No. 4 (1976).

296. Patwardhan, V.N., Hypovitaminosis A and epidemiology of xerophthalmia, *Am. J. Clin. Nutr.* *22*, 1106–1118 (1969).

297. Arroyave, G., Aguilar, J.R., Flores, M., and Guzman, M.A., Evaluation of sugar fortification with vitamin A at the national level. Scientific Publication No. 384. Pan American Health Organization, Washington D.C. (1979).

298. Graham, G.G., Creed, H.M., Phil. N., MacLean, W.C., Jr., Kallman, C.H., Rabold, J., and Mellits, E.D., Determinants of growth among poor children, nutrient intake achieved growth relationships, *Am. J. Clin. Nutr.* *34*, 539–554 (1981).

299. Clausen, S.W. and McCoord, A.B., The carotinoids and vitamin A of the blood. *J. Pediatr.* *13*, 635–650 (1938).

300. Heymann, W., Absorption of carotene, *Am. J. Dis. Child.* *51*, 273–283 (1936).

301. Uhlhoff, W., Untersuchungen uber den Einfluss des chronischen Alkoholismus auf das menschliche Sehorgan, *Klin. Wochenschr.* *24*, 227, 716–717 (1887).

302. Fuchs, A., The influence of general metabolic and nutritional disturbances upon the resistance of the cornea, *Am. J. Ophthalmol.* *30*, 721–727 (1947).

303. Bernhard, Hemeralopie und Xerosis conjunctivae bei Potatoren, Thesis, Tubingen Univ. (1902).

304. Higgins, H.L., Some physiological and clinical effects of high fat feeding, *N. Engl. J. Med.* *203*, 145–150 (1930).

305. Boller, R., Brunner, O., Uber die Ausscheidung von vitamin A im Harn, *Klin. Wochenschr.* *16*, 861–862 (1937).

306. Ralli, E.P., Papper, E., Paley, K., and Bauman, E., Vitamin A and carotene

content of human liver in normal and in diseased subjects. *Arch. Intern. Med.* 68, 102–111 (1941).

307. DeHaas, J.H., Posthuma, J.H., and Meulemans, O., Xerophthalmia in children in Batavia. *Indian J. Pediatr.* 8, 139–157 (1941).

308. Reddy, V., Vitamin A deficiency and blindness in Indian children. *Indian J. Med. Res.* (*Suppl.*), 26–37 (1978).

309. Nguyen Dinh Cat, La kerato-malacie infantile au Viet Nam, pp. 1127–1135, XVIII Cong. Ophthalmol., Belgium (1958).

310. Santer, J.J., Causes of blindness detected in 19 schools for the blind in Tanzania. Final Report, September 1978.

311. Trantus (1900), Baer (1901). Cited in Gronouw, A., *Graefe's Saemisch Handbuch*, 3rd Ed., pp. 624–628, Verlag Von Julius Springer, Berlin (1920).

312. Bezold, F., Keratomalacie nach morbillen. *Klin. Wochenschr. 11*, 408–411 (1874).

313. Hiro, Y., and Yamada, M., Die Masern und die Keratomalacie. *Monatsschr. Kinderheilk. 65*, 438–445 (1936).

314. Arlt, A., Some remarks on post-typhoid eye affections. *Am. J. Ophthalmol. 9*, 341–344 (1892).

315. Arroyave, G., and Calcano, M., Depression of serum levels of retinol and of retinol-binding protein (RBP) during infections. *Arch. Latinoamer. Nutr. 29*, 233–260 (1979).

316. Mendez, J., Scrimshaw, N.S., Salvado, C., and Lopez, S.M., Effects of artificially induced fever on serum proteins, vitamin levels and hematological values in human subjects. *J. Appl. Physiol. 14*, 768–770 (1959).

317. Jacobs, A.L., Leitner, Z.A., Moore, T., and Sharman, I.M., Vitamin A in rheumatic fever. *J. Clin. Nutr. 2*, 155–161 (1954).

318. Lala, V.R., and Reddy, V., Absorption of B-carotene from green leafy vegetables in undernourished children. *Am. J. Clin. Nutr. 23*, 110–113 (1970).

319. Lindquist, T., Untersuchungen uber das vitamin A bei Pneumonie. *Klin. Wochenschr. 16*, 1345–1348 (1937).

320. Lawrie, N.R., Moore, T., and Rajagopal, K.R., The excretion of vitamin A in urine. *Biochem. J. 35*, 825–836 (1941).

321. Sivakumar, B., and Reddy, V., Absorption of labelled vitamin A in children during infection. *Br. J. Nutr. 27*, 299–304 (1972).

322. Breese, B.B., Watkins, E., and McCoord, A.B., The absorption of vitamin A in tuberculosis. *J.A.M.A. 119*, 3–4 (1942).

323. May, C.D., and Lowe, C.U., Absorption of orally administered emulsified lipid in normal children and in children with steatorrhea. *J. Clin. Invest. 27*, 226–230 (1948).

324. Mansour, M.M., Mikhail, M.M., Farid, Z., and Bassily, S., Chronic salmonella septicemia and malabsorption of vitamin A. *Am. J. Clin. Nutr. 32*, 319–321 (1979).

325. Nalin, D.R., Russel, R., Greenberg, H., and Levine, M.M., Reduced vitamin A absorption after enteric infections, in *Current Chemotherapy and Infectious Disease*, eds. Nelson, J.D., Grassi, C., Proc. 11th International Congress

of Chemotherapy and 19th Interscience Conference on Antimicrobial Agents and Chemotherapy, II, 947–948 (1980).

326. Rogers, W.E., Bieri, J.G., and McDaniel, E.G., Vitamin A deficiency in the germfree state, *Fed. Proc.* 30, 1773–1778 (1971).

327. Bieri, J.G., McDaniel, E.G., and Rogers, W.E., Survival of germfree rats without vitamin A, *Science* 163, 574–575 (1969).

328. Dossetor, J., The pattern of malnutrition in Zaria, *J. Trop. Pediatr.* 21, 16–19 (1975).

329. Fosterman, G.B., and Wilson, D.L., Clinical features of vitamin A deficiency, *J. A.M.A.*, 98, 2054–2060 (1932).

330. Paton, D., Keratomalacia: A review of its relationship to xerophthalmia and its response to treatment, *The Eye, Ear, Nose and Throat Monthly* 46, 186–188 (1967).

331. Williams, P.H., and Tsvetkov, V.L., Bilateral spontaneous expulsion of the lens in a case of kwashiorkor, *J. Trop. Med. Hyg.* 72, 47–48 (1969).

332. Franken, S., Measles and xerophthalmia in East Africa, *Trop. Geogr. Med.* 26, 39–44 (1974).

333. Oomen, J.M.V., Xerophthalmia in Northern Nigeria, *Trop. Geogr. Med.*, 246–249 (1974).

334. Voorhoeve, H.W.V., Xerophthalmia in the presence of kwashiorkor in Nigeria, *Trop. Geogr. Med.* 18, 15–19 (1966).

335. Awdry, P.N., Cobb, B., and Adams, P.C.G., Blindness in the Luapula Valley, *Cent. Afr. J. Med.* 13, 197–201 (1967).

336. Sommer, A., Quesada, J., Doty, M., and Faich, G., Xerophthalmia and anterior segment blindness among preschool-age children in El Salvador, *Am. J. Ophthalmol.* 80, 1066–1072 (1975).

337. Sommer, A., Tourcau, S., Cornet, P., Midy, C., and Pettiss, S.T., Xerophthalmia and anterior segment blindness, *Am. J. Ophthalmol.* 82, 439–446 (1976).

338. Sommer, A., Faich, G., and Quesada, J., Mass distribution of vitamin A and the prevention of keratomalacia, *Am. J. Ophthalmol.* 80, 1073–1080 (1975).

339. Trantas, M., Complications oculaires rares de la rougeole, *Ann. Oculist.* 124, 390 (1900).

340. Sandford-Smith, J.H., and Whittle, H.C., Corneal ulceration following measles in Nigerian children, *Br. J. Ophthalmol.* 63, 720–724 (1979).

341. Gaflick, P., McNurlan, M., Fern, E., Tomkins, A., and Waterlow, J.C., Protein synthesis and breakdown after vaccination, *Br. Med. J.* 281, 1215–1216 (1980).

342. Dossetor, J., and Whittle, H.C., Protein losing enteropathy and malabsorption in acute measles enteritis, *Br. Med. J.* 2, 592–593 (1975).

343. Quere, M.A., Les complications oculaires de la rougeole, cause majeure de cecite chez l'enfant en pays tropical, *Opthalmologica* 148, 107–120 (1964).

344. Morley, D., Severe measles in the tropics, Part I, *Br. Med. J.* 1, 297–300 (1969).

345. Whittle, H.C., Sandford-Smith, J., Koghe, O.L., Dossetor, J., and Duggan, M., Severe ulcerative herpes of mouth and eye following measles, *Trans. R. Soc. Trop. Med. Hyg.* 73, 66–69 (1979).

346. Rodger, F.C., *Blindness in West Africa*, H.K. Lewis and Co. Ltd. London (1959).

347. Chirambo, M.C. and Ben-Ezra, D., Causes of blindness among students in blind school institutions in a developing country, *Br. J. Ophthalmol. 60*, 665-668 (1976).

348. van de Walle, L.J. Cited in Kunning (358).

349. Ammashaun, A., Measles and blindness in Nigerian children, *Niger. J. Ped. 1*, 10 (1977).

350. Ben-Sira, I., "Ticho, U., and Yassur, Y., Surgical treatment of active keratomalacia by "covering graft", *Isr. J. Med. Sci.* 8, 1209-1211 (1972).

351. Olumu, O., Etiology of blindness in Nigerian children, *Am. J. Ophthalmol. 70*, 533-540 (1970).

352. Phillips, C.M., Blindness in Africans in Northern Rhodesia, *Cent. Afr. J. Med. 7*, 153-158 (1961).

353. Castillo, J.M.D., The causes of blindness in the population of Sahara, 1st Gen. Assembly, International Agency for the Prevention of Blindness, Oxford, July, 1978.

354. Cobb, B. and Awdry, P.N., Xerophthalmia, *Trans. Ophthalmol. Soc. U.K.* 88, 579-585 (1968).

355. Byabo, N.O., Measles in Uganda, *Trop. Geogr. Med. 22*, 167-171 (1970).

356. McGlashan, N.D., Measles, malnutrition and blindness in Luapula Province, Zambia, *Trop. Geogr. Med. 21*, 157-162 (1969).

357. Dekkers, N.W.H.M., The cornea in tropical measles. A study in Western Kenya, First General Assembly, International Agency for Prevention of Blindness, Oxford, England, 1978.

358. Kunnes, B., Reply to McLaren, *Br. J. Ophthalmol.* (*Corres.*) 52, 645 (1968).

359. MacManus, E.P., Xerophthalmia in Matabeleland, *Cent. Afr. J. Med. 14*, 166-170 (1968).

360. Frederique, G., Howard, R., and Bonink, V., Corneal ulcers in rubeola, *Am. J. Ophthalmol. 68*, 996-1003 (1969).

361. McLaren, D.S., Nutrition and eye disease in East Africa: Experience in Lake and Central Provinces, Tanganyika, *J. Trop. Med. Hyg. 63*, 101-122 (1960).

362. Budden, F.H., Blindness in Northern Nigeria, WHO Vir PBL 75.4, 2-35 (November-December 1974).

363. McKenzie, A., An examination of vitamin A deficiency among African natives by the dysadaptation test, *Trans. Roy. Soc. Trop. Med. Hyg. 32*, 717-728 (1939).

364. Thomson, I.G., Eye diseases and blindness in relation to vitamin A deficiency in northern Nigeria, *J. Trop. Med. Hyg. 59*, 155-161 (1956).

365. Awdry, P.N. and Cobb, B., Vitamin A deficiency and blindness in the Luapula Valley of Northern Rhodesia, *Exp. Eye Res. 3*, 373 (1964).

366. Rodger, F.C. and Sinclair, H.M., *Metabolic and Nutritional Eye Diseases*, Charles C. Thomas, Springfield, Ill. (1969).

367. Kietzman, B., Endophthalmitis in Nigerian children, *Am. J. Ophthalmol. 65*, 211-220 (1968).

368 Benezra, D., and Chirambo, M.C., Incidence and causes of blindness among the under 5 age group in Malawi. *Br. J. Ophthalmol.* 61, 154–157, 1977.

369 Reddy, V., Jagadeesan, V., Raghuramulu, N., Bhaskaram, C., and Srikantia, S.G., Functional significance of growth retardation in malnutrition. *Am. J. Clin. Nutr.* 29, 3–7, 1976.

370 Hekwungwe, A.E., Grasset, N., Glass, R., and Foster, S., Immune response to measles and smallpox vaccinations in malnourished children. *Am. J. Clin. Nutr.* 33, 621–624, 1980.

371 Smythe, P.M., Schonland, M., Brereton-Stiles, G.G., Coovadia, H.M., Grace, H.J., Loening, W.E.K., Malovane, V., Parent, M.A., and Vos, G.H., Thymolymphatic deficiency and depression of cell-mediated immunity in protein-calorie malnutrition. *Lancet* 2, 939–945, 1971.

372 McMurray, D.N., Loomis, S.A., Casazza, L.J., Rex, H., and Miranda, R., Development of impaired cell-mediated immunity in mild and moderate malnutrition. *Am. J. Clin. Nutr.* 34, 68–77, 1981.

373 Dossetor, J., Whittle, H.C., and Greenwood, B.M., Persistent measles infection in malnourished children. *Brit. Med. J.* 1, 1633–1635 (1977).

374 Whittle, N.C., Bradley-Moore, A., Fleming, A., and Greenwood, B.M., Effects of measles on the immune response of Nigerian children. *Arch. Dis. Child.* 48, 753–756, 1973.

375 McKenzie, D., Hansen, J.D.L., and Becker, W., Herpes simplex versus infection. Dissemination in association with malnutrition. *Arch. Dis. Child.* 34, 250–256, 1959.

376 Kipps, A., and Kaschula, R.O.C., Virus pneumonia following measles. *S. African Med. J.* 50, 1083–1088, 1976.

377 Scrimshaw, N.S., Synergistic and antagonistic interactions of nutrition and infection. *Fed. Proc.* 25, 1679–1681 (1966).

378 Venkataswamy, G., Glover, J., Cobby, M., and Price, A., Retinol-binding protein in serum of xerophthalmic malnourished children before and after treatment at a nutrition center. *Am. J. Clin. Nutr.* 30, 1968–1973 (1977).

379 Blatz, G., Hornhautentschmelzung nach Masern. *Klin. Monatsbl. Augenh.* 129, 763–772, 1956.

380 Mahalanabis, D., Simpson, T.W., Chakraborty, M.L., Ganguli, C., Bhattacharjee, A.K., and Mukherjee, K.L., Malabsorption of water miscible vitamin A in children with giardiasis and ascariasis. *Am. J. Nutr.* 32, 313–318 (1979).

381 Sivakumar, B., and Reddy, V., Absorption of vitamin A in children with ascariasis. *J. Trop. Med. Hyg.* 78, 111–115, 1975.

382 Mahalanabis, D., Jalan, K.N., Mattra, T.K., and Agarwal, S.K., Vitamin A absorption in ascariasis. *Am. J. Clin. Nutr.* 29, 1372–1375 (1976).

383 Oey, D.H., Het voor kunnen van xerophthalmie in eenige desa's van het Regentschap Kebumen. *Geneesk. Tijdschr. Ned. Indie.* 76, 1101–1110 (1936).

384 Sivakumar, B., and Reddy, V., Absorption of vitamin A in children with ascariasis. *Am. J. Trop. Med. Hyg.* 78, 111–115 (1975).

385 Gupta, M.C., Mithal, S., Arora, K.L., and Tandon, B.N., Effect of periodic deworming on nutritional status of Ascaris-infested preschool children receiving supplementary food. Int. Cong. Nutr., Rio de Janeiro, Brazil (1978).

386. Lewis, J.M., Bodansky, O., Lallienfeld, M.C.C., and Schneider, H., Supplements of vitamin A and of carotene during pregnancy. *Am. J. Dis. Child.* 73, 143–150 (1947).

387. Lund, C.J. and Kimble, M.S., Plasma vitamin A and carotene of the newborn infant with consideration of fetal-maternal relationships. *Am. J. Obstet. Gynecol.* 46, 207–221 (1943).

388. Byrn, J.N. and Easterman, N.J., Vitamin A levels in maternal and fetal blood plasma. *Bull. Johns Hopkins Hospital* 73, 132–137 (1943).

389. Thanangkul, O., Promkutkaew, C., Wanyapong, T., and Damrongsak, D., Comparison of the effects of a single high dose of vitamin A given to mother and infant upon plasma levels of vitamin A in the infant. Joint WHO/USAID Meeting on the control of vitamin A deficiency: Priorities for research and action programmes. Jakarta, Indonesia (November 25–29, 1974).

390. Young, D.L. and Chan, P.L., Effects of a progestogen and a sequential type oral contraceptive on plasma vitamin A, vitamin E, cholesterol and triglycerides. *Am. J. Clin. Nutr.* 28, 686–691 (1975).

391. Vahlquist, A., Johnsson, A., and Nygren, K., Vitamin A transporting plasma proteins and female sex hormones. *Am. J. Clin. Nutr.* 32, 1433–1438 (1979).

392. Venkatachalam, P.S., Belavady, B., and Gopalan, C., Studies on vitamin A nutritional status of mothers and infants in poor communities of India. *J. Pediatr.* 61, 262–268 (1962).

393. Bodansky, O., Lewis, J.M., and Lallienfeld, M.C.C., The concentration of vitamin A in the blood plasma during pregnancy. *J. Clin. Invest.* 22, 643–647 (1943).

394. Maxwell, J.P., Vitamin deficiency in the antenatal period, its effects on the mother and the infant. *J. Obstet. Gynaecol. Brit. Emp.* 39, 764–776 (1932).

395. Iyengar, L. and Apte, S.V., Nutrient stores in human foetal livers. *Am. J. Clin. Nutr.* 27, 313–317 (1972).

396. Smith, B.M. and Malthus, E.M., Vitamin A content of human liver from autopsies in New Zealand. *Br. J. Nutr.* 16, 213–218 (1962).

397. Lewis, J.M., Bodansky, O., and Shapiro, L.M., Regulation of level of vitamin A in blood of newborn infants. *Am. J. Dis. Child.* 66, 503–510 (1943).

398. De Haas, J.H. and Meulemans, O., Vitamin A and carotenoids in blood of pregnant and lactating native and Chinese women of Batavia. *Geneesk. Tijdschr. Ned. Indie* 78, 847–855 (1938).

399. De Haas, J.H., Posthuma, J.H., and Meulemans, O., Xerophthalmie bij kinderen in Batavia. *Geneesk. Tijdschr. Ned. Indie* 80, 928–950 (1940).

400. Stolte, K., Ueber Keratomalazie. *Klin. Monatsbl. Augenheilkd.* 68, 739–743 (1922).

401. Smith, P., Comments on presentation by Spicer (20).

402. Hadberg, J., Zur Casuistik des durch Inanitionszustande bedingten hornhautgangran. *Archive fur Augenheilkunde.* 12, 315–332 (1883).

403. Schiele, A. (1907). Cited in Elliot (77).

404. Meulemans, O. and DeHaas, J.H., Over het gehalte aan carotine en vitamine A van moedermilk in Batavia. *Geneesk. Tijdschr. Ned. Indie* 76, 1538–1571 (1936).

405. Belavady, B. and Gopalan, C., Chemical composition of human milk in poor Indian women. *Indian J. Med. Res.* 47, 234–245 (1959).

406. Kon, S.K. and Mawson, E.H., Human milk. Med. Res. Council Spec. Rep. Series No. 269, p. 32, (1950).

407. Rasanen, L., Nutrition survey of Finnish rural children. VI. Methodological study comparing the 24-hour recall and the dietary history interview. *Am. J. Clin. Nutr.* 32, 2560–2567, (1979).

408. Beaton, G.H., Milner, J., Corey, P., McGuire, V., Cousins, M., Stewart, E., de Ramos, M., Hewitt, D., Grambsch, P.V., Kassim, N., and Little, J.A., Sources of variance in 24-hour dietary recall data: implications for nutrition study design and interpretation. *Am. J. Clin. Nutr.* 32, 2546–2559, (1979).

409. Garn, S.M., Larkin, F.A., and Cole, P.E., The real problem with 1-day diet records. *Am. J. Clin. Nutr. (Corres.)* 31, 1114–1116, (1978).

410. Graham, G.G., Validity of 24-hr dietary recall. *Am. J. Clin. Nutr. (Corres.)*, 1939–1941, (1977).

411. Santa Cruz Guéllar, M.A. and Flores, H., Alimentary surveys: The use of food composition tables. XI Int. Cong. of Nutr., Rio de Janeiro, Brasil (September 1978).

412. Aykroyd, W.R. and Rajagopal, R., The state of nutrition of school children in South India. *Indian J. Med. Res.* 24, 419–437 (1936).

413. Roels, O.A., Debien, O., and Trout, M., Vitamin A deficiency in Ruanda-Urundi. *Trop. Geogr. Med.* 10, 77–92 (1958).

414. Rao, K.S., De, N.K., and Rao, D.S., Investigation of an outbreak of night-blindness in a village near Madras. *Indian J. Med. Res.* 41, 339–357 (1953).

415. Yap, K.T., A comparative study of the diets, and results of some blood analyses, of children living in different environments in Jogjakarta (Central Java). *Br. J. Nutr.* 11, 158–161 (1957).

416. Pereira, S.M. and Begum, A., Prevention of Vitamin A deficiency. *Am. J. Clin. Nutr.* 22, 858–862 (1969).

417. Roels, O.A., Trout, M., and Dujacquier, R., Carotene balances on boys in Ruanda where vitamin A deficiency is prevalent. *J. Nutr.* 65, 115–127 (1958).

418. Jayarajan, P., Reddy, V., and Mohanram, M., Absorption of B-carotene from green leafy vegetables. XI Int. Cong. of Nutr., Rio de Janeiro, Brazil (September 1978).

419. Hamburger, R., Ueber Keratomalacie bei Kindern. *Deut. med. Wochschr.* 49, 1301–1303 (1923).

420. Parnell, J.P., Sherman, B.S., Effect of vitamin A on keratinization in the A deficient rat. In: *Fundamentals of Keratinization*, American Association for the Advancement of Science, Washington, D.C., 113–129 (1962).

421. Oomen, H.A.P.C., The incidence of xerophthalmia in Java in relation to age and sex. *Docum. de Med. Geogr. Trop.* 9, 357–368 (1957).

422. Vijayaraghavan, K., Naidu, A.N., Rao, N.P., and Srikantia, S.G., A simple method to evaluate the massive dose vitamin A prophylaxis program in pre-school children. *Am. J. Clin. Nutr.* 28, 1189–1193 (1975).

423. Sabis, R., Ophthalmology in a concentration camp. *Am. J. Ophthalmol.* 44, 12–17 (1957).

424. Swaminathan, M.C., Susheela, T.P., and Thimmayamma, B.V.S., Field prophylactic trial with a single annual oral massive dose of vitamin A. *Am. J. Clin. Nutr.* 23, 119–122 (1970).

425. Gebre-Medhin, M., Vahlquist, A., Hofvander, Y., Uppsall, L., and Vahlquist, B., Breast milk composition in Ethiopian and Swedish mothers. I. Vitamin A and B-carotene. *Am. J. Clin. Nutr.* 29, 441–451 (1976).

426. Sinha, D.P. and Bang, F.B., Seasonal variation in signs of vitamin-A deficiency in rural West Bengal children. *Lancet* 2, 228–231 (1973).

427. Oomen, H.A.P.C., McLaren, D.S., and Escapini, H., Epidemiology and public health aspects of hypovitaminosis A. A global survey of xerophthalmia. *Trop. Geogr. Med.* 16, 271–315 (1964).

428. McLaren, D.S., "Discussion summary," International Symposium on the Metabolic Function of Vitamin A, Nov. 25–27, 1968. *Am. J. Clin. Nutr.* 22, 1135–1138 (1969).

429. Sommer, A., Epidemiology in the design and evaluation of blindness control programs. *Tr. Am. Acad. Ophthalmol. Otolaryngol.* 79, 447–452 (1975).

430. Sommer, A., Tarwotjo, I., Hussaini, G., Susanto, D., and Soegiharto, T., Incidence, prevalance and scale of blinding malnutrition. *Lancet* 1, 1407–1408 (1981).

431. A proposal for the characterization of vitamin A deficiency and xerophthalmia in Indonesia: A basis for the design of effective intervention programmes. Ministry of Health, Government of Indonesia and the American Foundation for Overseas Blind, New York, N.Y. (revised April, 1976).

432. Franken, S., Blindness prevention programme in Bangladesh. Assignment Report. WHO SEA Ophthalmol. Vol. 4. (March 31, 1975).

433. Gopalan, C. and Vijayaraghavan, K., Nutrition Atlas of India, pp. 67; 159. Indian Council of Medical Research, New Delhi, (1971).

434. Shah, P.M., Strategies for prevention of malnutritional blindness in India, operational methodology—management, monitoring and cost/benefit, Royal Commonwealth Society for the Blind, (July, 1978).

435. Sivasubramaniam, P., Keratomalacia. *Trans. Ophthalmol. Soc. (Ceylon)* 1, 21–27 (1958).

436. Chang, S.P., Causes of blindness among the Chinese. *National Medical Journal of China* 16, 370–378 (1930).

437. Hsu, P.L., Prevention and treatment of trachoma and blindness in Heilungkiang rural areas. WHO Meeting on Programs for the Prevention of Blindness, Asilomar, Calif. (October, 1978).

438. Pizzarello, L., Visual status of children of Indochinese refugees currently residing in Thailand. Final Report. Helen Keller International, pp. 1–20 (1979).

439. Lechat, M.F., Bouche, R., de Goyet, C., and Bouequey, C., Epidemiologie de l'avitaminose A au Niger. *Ann. Soc. Belg. Med. Trop.* 56, 333–342 (1976).

440. Simmons, W.K., Xerophthalmia and blindness in Northeast Brazil. *Am. J. Clin. Nutr.* 29, 416–422 (1976).

441. McLaren, D.S., Read, W.W.C., and Tchalian, M., Extent of human vitamin A deficiency. *Proceed. Nutr. Soc. U.K.* 25, p. XXVIII (1966).

442. Sommer, A., Renewed interest in the ancient scourge, xerophthalmia. *Am. J. Ophthalmol.* (*Editorial*) 86, 284–285 (1978).
443. Abdullah, M., Abedin, Z., Ahmad, K., Chowdhury, [illegible] Hassan, N., Hussain, M., Huda, N., and Saber, A., Nutrition survey of rural Bangladesh. Int. Cong. Nutr., Rio De Janeiro, Brazil (August, 1978).
444. Menon, K. and Vijayaraghavan, K., Sequelae of severe xerophthalmia: a follow-up study. *Am. J. Clin. Nutr.* 33, 218–220 (1980).
445. Sommer, A. and Loewenstein, M.S., Nutritional status and mortality: a prospective validation of the QUAC stick. *Am. J. Clin. Nutr.* 18, 287–292 (1975).
446. Kielmann, A.A. and McCord, C., Weight-for-age as an index of risk of death in children. *Lancet I*, 1247–1250 (1978).
447. Venkataswamy, G., Cobby, M., and Pirie, A., Rehabilitation of xerophthalmic children. *Trop. Geogr. Med.* 31, 149–154 (1979).
448. Stranski, E., Klinische Beitrage zur Frage der Aetiologie der Keratomalacie. *Jahrbuch fur Kinderheilkunde 104*, 183–194 (1924).
449. Fritz, T., Final Report on Blind Babies Project, Cicendo Eye Hospital, Bandung, Indonesia, pp. 1–12. Helen Keller International (1979).
450. Holcomb, R.C., Nightblindness. *JAMA 102*, 786–787 (1934).
451. Husaini, G., Tarwotjo, I., and Sommer, A., Cure for night blindness. *Am. J. Clin. Nutr. 31*, 1489–1978.
452. Banister, R. *A treatise of one hundred and thirteen diseases of the eyes and eye lids*, Thomas Mann (2nd Edition), London (1622).
453. Romary, A propos de l'hemeralopie essentielle. *Le Caducée 3*, 50 (1903).
454. Chu, F.T. and Lin, C.K., Efficacy of parenteral vitamin A administration in vitamin A deficiency: clinical study of 9 cases. *Chin. Med. J.* 53, 413–426 (1938).
455. Pereira, S.M., Begum, A., Isaac, T., and Dunn, M.E., Vitamin A therapy in children with kwashiorkor. *Am. J. Clin. Nutr. 20*, 297–304 (1967).
456. Somerset, E.J. Cited in D.G. Vaughn [168].
457. Srikantia, S.G. and Reddy, V., Effect of a single massive dose of vitamin A on serum and liver levels of the vitamin. *Am. J. Clin. Nutr.* 23, 114–118 (1970).
458. Arroyave, G., Viteri, F., Behar, M., and Scrimshaw, N.S., Impairment of intestinal absorption of vitamin A palmitate in severe protein malnutrition (kwashiorkor). *Am. J. Clin. Nutr.* 7, 185–190 (1959).
459. Osborne, T.B. and Mendel, L.B., Ophthalmia and diet. *JAMA* 76, 905–908 (1921).
460. Sommer, A., Muhilal, H., and Tarwotjo, I., Protein deficiency and treatment of xerophthalmia. *Arch. Ophthalmol.* (1982). In Press.
461. Smith, J.E., Muto, Y., Milch, P.O., and Goodman, D.S., The effects of chylomicron vitamin A on the metabolism of retinol-binding protein in the rat. *J. Biol. Chem 248*, 1544–1549 (1973).
462. Smith, F.R., Suskind, R., Thanangkul, O., Leitzmann, C., Goodman, D.S., and Olson, R.E., Plasma vitamin A, retinol-binding protein and prealbumin concentration in protein-calorie malnutrition. III. Response to varying dietary treatments. *Am. J. Clin. Nutr.* 28, 732–738 (1975).

463. Ingenbleek, Y., van der Schriek, H.G., De Nayer, P., and De Visscher, M., The role of retinol-binding protein in protein-calorie malnutrition, *Metabolism 24*, 633–641 (1975).

464. Kusin, J.A., Reddy, V., and Sivakumar, B., Vitamin E supplements and the absorption of a massive dose of vitamin A, *Am. J. Clin. Nutr. 27*, 774–776 (1974).

465. Sivakumar, B. and Reddy, V., Absorption of orally administered labelled vitamin A in apparently normal children, SEANUT Xeroph.Meet/6 (March 17, 1972).

466. Reddy, V., Vitamin A deficiency, Decade report of the National Institute of Nutrition, Hyderabad, India p. 63 (1970).

467. May, O.E. and Wolfe, E., Case of xerophthalmia, *Lancet 2*, 252–253 (1938).

468. Pirie, A., Effects of locally applied retinoic acid on corneal xerophthalmia in rat, *Exp. Eye Res. 25*, 297–302 (1977).

469. Smith, J.E., Milch, P.O., Muto, Y., and Goodman, D.W.S., The plasma transport and metabolism of retinoic acid in the rat, *Biochem. J. 132*, 821–827 (1973).

470. Ott, D.B. and Lachance, P.A., Retinoic acid: A review, *Am. J. Clin. Nutr. 32*, 2522–2531 (1979).

471. Van Horn, D.L., DeCarlo, J.D., Schutten, W.H., and Hyndiuk, R.A., Topical retinoic acid in the treatment of experimental xerophthalmia in the rabbit, *Arch. Opthalmol.* In Press.

472. Wiggert, B., Bergsma, D.R., Helmsen, R., and Chader, G.J., Vitamin A receptors: Retinoic acid binding in ocular tissues, *Biochem. J., 169*, 87–94, (1978).

473. Smolin, G., Okumoto, M., and Friedlaender, M., Tretinoin and corneal epithelial wound healing, *Arch. Ophthalmol. 97*, 545–546 (1979).

474. Arroyave, G., Bauernfeind, J.C., Olson, J.A., and Underwood, B.A., "Selection of intervention strategies" in *Guidelines for the Eradication of Vitamin A Deficiency and Xerophthalmia*. Report of the International Vitamin A Consultative Group, pp.III-1–III-10 The Nutrition Foundation, New York (1978).

475. Bauernfeind, J.C., The Safe Use of Vitamin A, Report of the International Vitamin A Consultative Group, The Nutrition Foundation, New York (1980).

476. Davis, D.R., Using vitamin A safely, *Osteopathic Medicine 3*, 31–43 (1978).

477. Rodriguez, M.S. and Irwin, M.I., A conspectus of research on vitamin A requirements of man, *J. Nutr. 102*, 909–968 (1972).

478. Report of a Joint FAO/WHO Expert Group on Requirements of Vitamin A, Thiamine, Riboflavine, and Niacin, WHO Tech. Report Ser. No. 362 WHO, Geneva (1967).

479. Passmore, R., Nicol, B.M., Rao, M.N., Beaton, G.H., and DeMayer, E.M., *Handbook on Human Nutritional Requirements, pp. 25–28, WHO Monograph Series (FAO Nutritional Studies No. 28)*, Rome (1974).

480. Patwardhan, V.N., Kamel, W.W., and Pharaon, H., Studies on vitamin A deficiency in infants and young children in Jordan. II. A pilot trial of vitamin A prophylaxis in Jordanian infants, pp. 103–137, Project Report, World Health Organization, (1966).

181. Pereira, S.M. and Begum, A., Failure of a massive single oral dose of vitamin A to prevent deficiency. *Arch. Dis. Child.* 46, 525–527 (1971).
182. Araujo, R.L., Borges, E.F., Silva, J.D., Costa Val, A.P. and Vieira, E.C., Failure of massive oral doses of vitamin A to prevent hypovitaminosis A. XI Int. Cong. of Nutr., Rio de Janeiro, Brazil, September 1978.
183. Solon, F., Fernandez, T.L., Latham, M.C., and Popkin, B.M., An evaluation of strategies to control vitamin A deficiency in the Philippines. *Am. J. Clin. Nutr.* 32, 1445–1453 (1979).
184. Nair, N.A., Report on vitamin A prophylaxis programme in Kerala State. WHO Meeting of Nutrition Experts for Consultation on Prevention of Xerophthalmia, SEA/NUT/Xeroph. Meeting/5, March 17, 1972.
185. Gadkar, M.A., Report on vitamin A prophylaxis programme in Mysore State. WHO Meeting of Nutrition Experts for Consultation on Prevention of Xerophthalmia, SEA/NUT/Xeroph. Meeting/4, March 17, 1972.
186. Lusvotpo, I., Hoorse, L., Tjakrasupatma, R.S., Ginawan, S., Basuki, M. and Santoso, S., Large-scale distribution of massive dose vitamin A in Indonesia: A study of the operational aspects. *Bull. Penelitian Kesehatan, Health Studies in Indonesia, III*, 27–31, 1975.
187. Assessment of vitamin A distribution in Bangladesh. Smallpox Eradication Programme, Ministry of Health, Population Control and Family Planning, People's Republic of Bangladesh, October, 1975.
188. Swaminathan, M.C., A programme for the prophylaxis against blindness in children caused by vitamin A deficiency in India: An appraisal. Joint WHO/USAID Meeting on Vitamin A deficiency and xerophthalmia, Jakarta, Indonesia, November 25–29, 1974.
189. Azurin, J.C. and Alvero, M., Cholera incidence in a population offered cholera vaccination: Comparison of cooperative and uncooperative groups. *Bull. WHO 44*, 845–849, 1971.
190. Karnad, R., Vitamin A deficiency: Prevalence in India and prophylaxis against blindness caused by it in children. WHO Meeting of Nutrition Experts for Consultation on Prevention of Xerophthalmia, SEA/NUT/Xeroph. Meeting/10, March 22, 1972.
191. Friderichsen, C. and Edmund, C., Studies of hypovitaminosis A. II. A new method for testing the resorption of vitamin A from medicaments. *Am. J. Dis. Child.* 53, 99–109, 1937.
192. Chakhalkar, P. and Magar, N.G., Dark adaptation test as related to the clinical symptoms of vitamin A deficiency and the serum level of carotene and vitamin A. *Ind. J. Med. Res.* 50, 253–258 (1962).
193. Sugana, T. and Sommer, A., Prevention of neonatal blindness. *Lancet* 2, 1101–1978.
194. Sobel, A.E., Besman, L., and Kramer, B., Vitamin A absorption in the newborn. *Am. J. Dis. Child.* 77, 576–591 (1949).
195. Bauernfeind, J.C. and Cort, W.M., Nutrification of foods with added vitamin A. *CRC Crit. Rev. Food Technol.* 4, 337–375 (1973).
196. Arroyave, G., Mejia, L.A., and Aguilar, J.R., The effect of vitamin A fortifi-

cation of sugar on the serum vitamin A levels of preschool Guatemalan children: a longitudinal evaluation, *Am. J. Clin. Nutr.* 34, 41–49 (1981).

497. Solon, F.S., Fernandez, T.L., Latham, M.C., and Popkin, B.M., Planning, implementation, and evaluation of a fortification program, *J. Am. Diet. Assoc.* 74, 112–118 (1979).

498. Williamson, D.F. and Latham, M.C., Mono-sodium-glutamate (MSG) consumption and its potential effectiveness as a fortification vehicle for vitamin A in the Philippines, *Int. Cong. Nutr.*, Brazil (September, 1978).

499. Florentino, R., Report of the Philippines Vitamin A Fortification Program, Meeting of the International Vitamin A Consultative Group, Cebu, Philippines (November 27–29, 1979).

500. Bauernfeind, J.C., Carotenoid vitamin A precursors and analogs in foods and feeds, *Agricultural and Food Chemistry*, 20, 456–473 (1972).

501. Muhilal, and Karyadi, D., A study on the bioavailability of vegetable carotenes and preformed vitamin A in preschool children, Presented at the International Vitamin A Consultative Group, Geneva (May 18–20, 1977).

502. Bawa, S., Malek, M.A., and Ahmad, K., Studies on dark green leafy vegetables, Part III, Availability of Carotene as a source of vitamin A, *Bangladesh J. Agriculture 1*, 33–37 (1976).

503. Pereira, S.M., Vitamin A deficiency in preschool children in North Arcot district, Tamil Nadu, India, WHO Meeting of Nutrition Experts for Consultation on Prevention of Xerophthalmia, SEA/NUT/Xeroph., Meeting 9 (March 20, 1972).

504. Oomen, H.A.P.C. and Grubben, G.J.H., *Tropical Leaf Vegetables in Human Nutrition*, Orphan Publishing Co., Willimstad, Curacao (1978).

505. Cited in Pereira, S.M. [506].

506. Pereira, S.M. and Begum, A., Studies in the prevention of vitamin A deficiency, *Indian J. Med. Res.* 56, 362–369 (1968).

507. Pirie, N.W., Restoring esteem for leafy vegetables, *Appropriate Technology*, 3, 24–25 (1976).

508. Orraca-Tetteh, R., The impact of nutrition education of mothers on the nutrition of their children, XI Int. Cong. Nutr., Rio de Janeiro, Brazil (September 1978).

509. Lian, O.K., Tie, L.T., Bose, C.S., Prawiranegara, D.D., and György, P., Red palm oil in the prevention of vitamin A deficiency. A trial on preschool children in Indonesia, *Am. J. Clin. Nutr.* 20, 1267–1274 (1967).

510. *Characterization of Vitamin A Deficiency and Xerophthalmia and the Design of Effective Intervention Programs*, Final Report, Nutritional Blindness Prevention Project, Helen Keller International, New York (1980).

511. Snedecor, G.W. and Cochran, W.G., *Statistical Methods*, State University Press, Ames, Iowa (1967).

512. Armitage, P., *Statistical Methods in Medical Research*, Blackwell Scientific Publications, Oxford (1971).

513. Swinscow, T.D.V., *Statistics at Square One*, British Medical Association, London (1978).

514. Jones, L.T., The lacrimal secretory system and its treatment. *Am. J. Ophthalmol.* 62: 47–60 (1966).
515. de Roetth, A., Lacrimation in normal eyes. *Arch. Ophthalmol.* 49: 185–189 (1953).
516. Sommer, A., Vitamin A, xerophthalmia and diarrhea. *Lancet I*: 1411–1412 (1980).
517. Sommer, A., Conjunctival appearance in corneal xerophthalmia. *Arch. Ophthalmol.* (1982) (in press).
518. Laditan, A.A.O. and Fafunso, M., Serum levels of vitamin A, beta-carotene and albumin in children with measles. *E. Afr. Med. J.* 58: 51–55 (1981).
519. Sachs, U. and Marcus, M., Bilateral herpetic keratitis during measles. *Am. J. Ophthalmol.* 91: 796–797 (1981).
520. Sommer, A., Green, W.R., and Kenyon, K.R., Clinical-histopathologic correlations in xerophthalmic ulceration and necrosis. *Arch. Ophthalmol.* (1982) (in press).
521. Sommer, A. and Emran, N., Tear production in vitamin A-responsive xerophthalmia. *Am. J. Ophthalmol.* (1982). (In Press).

Index

Absorption of vitamin and provitamin A, effect of infections on, 124
Age
  corneal xerophthalmia, relation to, 100–101, Table 6-10, Fig. 6-2
  and risk of xerophthalmia, 153–55, Figs. 3-5, 10-1
  See also Bitot's spot, Conjunctival xerosis
Albumin, serum
  interpretation, 98–99
  levels in corneal xeropthalmia, 99–100, Table 6-8
  See also Protein status
Anthropometric status. *See* Nutritional status, general

Background, Indonesian Project, 8–9
Bacteria
  in Bitot's spot and conjunctival xerosis, 34–36, 48, Tables 3-3, 3-4
  isolation from xerophthalmic eyes, 94–95, Table 6-5
  keratin, as culture medium for, 94
  presence in corneal ulceration necrosis, 77, 80–83, Figs. 5-1, 5-2, 5-3
  role in corneal ulceration, 94–96
Bitot's spot
  background, 28–29
  nightblindness and, 29
  as sequelae of past deficiency, 47–48
  sex, relation to responsive nonresponsive lesions, 155–56
  See also Conjunctival xerosis
Blindness, sequelae of xerophthalmia, 176–79, Table 12-1
Breast feeding
  discontinued, reasons for, 143, Table 9-2
  frequency, 144
  and vitamin A, 140–41
  and xerophthalmia, 141–44, Table 9-4, fig. 9-1

Carotene
  metabolism, 6
  serum levels in keratomalacia, 114
  See also Diet, Dietary intake, Dietary sources
Clinical classification. *See* Xerophthalmia, classification
Clustering, cases by location, 157–59, Table 10-3
Cod-liver oil, effect on xerophthalmia, 187–88
Collagenase. *See* Proteases
Conjuctiva, appearance in corneal xerophthalmia, 48–51, Plates 12, 14, 16, 21–25, 29. *See also* Conjunctival xerosis
Conjunctival wrinkling and thickening, 52
Conjunctival xerosis
  absence in adult volunteers, 53–54
  and age, 42–44, 48, 154–55, Figs. 3-5, 3-6, 10-1
  background, 28–29
  binocularity, Table 3-5
  classification, 51
  clinical appearance, 29–30, 49, 51–52, Plates 3–10, 17–19, 28, 31
  distinguishing responsive from nonresponsive, 36–38
  evolution and diagnosis, 51–54
  and general nutritional status, 48
  healing, partial or transient, 38–39, 42
  histopathology, 30–36, 38, 51–52, Figs. 3-1 to 3-4, Tables 3-3, 3-4, 3-8, 3-9
  inflammation, effect of, 49–51, 53, Table 3-14
  Kajal, use in diagnosis of, 53
  location and extent, 36–38, 47–49, Tables 3-5, 3-6, 3-7, 3-13
  nonresponsive lesions, origin, 47–48, 52
  past xerophthalmic episode, 48
  pigmentation in, 53
  and presence of nightblindness, 45
  and protein status, 48
  rapid deterioration vitamin A status, effect on, 49–51
  and recognition of active vitamin A deficiency, 46–47
  response to therapy, 29, 38–43, Table 1-3, 3-1, 3-9 to 3-11, Fig. 3-1
  serum vitamin A, by response, Table 3-12
  severity, 36–38, 48–49, Table 3-13
  vital stains in diagnosis, 52–53, Table 3-15
  See also Bitot's spot
Contributory systemic diseases
  infections, 123–37, Table 8-1
  mechanisms, 124–26
  noninfections, 123
Corneal cases, comparability with and without controls, Table 1-2

Corneal destruction
background, 55–57
historical notes, 3–4
Corneal ulceration necrosis
binocularity, 65–67, 70–73, 75, Table 4-3
categories, 65
clinical appearance: necrosis, 71–75, Fig. 4-4, Plates 12–14, 22, 27–29, 31
clinical appearance: ulceration, 65–67, 70, Plates 16, 21–27
clinical-histopathologic correlation, 76–88, Figs. 5-1, 5-2, 5-3
healing, 70–75, plates 29–30, 31–32
and inflammation, 67
measles, precipitation by, 74, 80
mechanisms of formation, 67–69, 86–88, Plates 17–18, 25, 26
necrosis: apparent reversibility, 73–74, 87–88
selected cases: additional, Appendix III
ulceration, factors associated with severity, 70–71, Table 4-8
Corneal xerophthalmia
causation, role of local ocular factors, 89–96
causation, role of systemic factors, 96–104
definitions, diverse, 56–57
pattern of progression, 83, 86–88
study categories, 57–58, Table 4-1
See also Corneal ulceration necrosis
Corneal xerosis
and age, 64
clinical appearance, 60–63, Plates 9, 10, 13, 15, 17–20
cornified epithelium, 63
and epithelial microcysts, 61
and general health and nutritional status, 64
histopathology, 76
and mortality, 64, Table 4-7
presenting complaint, 63
prevalence, 60
and protein status, 64, Table 4-6
and punctate keratopathy, 61–62, Tables 4-3, 4-4
and stromal edema, 61, 63, Table 4-5
See also Corneal xerophthalmia

Dark adaptation, impaired, as earliest clinical alteration, 20. *See also* Nightblindness
Dellen: role in ulceration, 68–69, 86
Diarrhea
and corneal xerophthalmia, 104
relation to risk of xerophthalmia, 126–28, Table 8-2
See also gastroenteritis
Dietary intake, and risk of xerophthalmia, 139–50
carotene content, 148–49
carrots, 148, Table 9-6
edible oils, 150, Table 9-7
eggs, 146–48, Tables 9-5, 9-6
fish, 147–48, Table 9-6
fruits, 144–46, 148, Tables 9-3, 9-6
green leafy vegetables, 144–46, 148, Tables 9-4, 9-6
meat, 146–47
red palm oil, 150
vitamin and provitamin A, 149–50
See also Breast feeding, Green leafy vegetables, Vitamin A intake
Dietary sources of vitamin A
neonatal period, 140–44
prenatal period, 139–40
weaning and early childhood, 144–50

Edema, pedal
and corneal xerophthalmia, 103, Fig. 6-3
and risk of xerophthalmia, 110
See also Protein status
Exposure, corneal, 93–94

Fat-soluble A, 4
Fever, effect on vitamin A levels, 124
Fortification. *See* Prevention
Fundus: xerophthalmic, 24–27, Fig. 2-2, Plates 1, 2
Fungi and corneal ulceration, 95

Gastroenteritis
and risk of xerophthalmia, 126–27
and severity of corneal xerophthalmia, 104
See also Diarrhea
Goblet cells
loss in xerosis, 34–36
return with therapy, 42, Table 3-9
Green leafy vegetables
amount to satisfy vitamin A requirements, 219–20
availability, 220–222, Table 14-5
preparation of, 220
reason not consumed, 220–22, Tables 14-6, 14-7
as source of vitamin A, 219–20
See also Dietary intake, Prevention, Vitamin A intake
Growth
demands on vitamin A, 116
effect of vitamin A, 116–17

Health status, general
and risk of xerophthalmia, 138, Table 8-6
and severity of corneal xerophthalmia, 104

Height for age
in relation to xerophthalmia, 120–22, Table 7-6, Fig. 7-4
interpretation, 120
See also Nutritional status, general
Hemeralopia, terminology, 4
Histopathology
corneal ulceration/necrosis, 77–83, Figs. 5-1, 5-2, 5-3
corneal xerosis, 76
See also Conjunctival xerosis
Home gardening, 220, 222

Incidence
active corneal xerophthalmia, 163–68, Tables 11-1, 11-5
noncorneal xerophthalmia, 164–68, Table 11-2
problems in measurement, 162–63
xerophthalmia, Indonesia estimate, 165–68, Table 11-5
Indonesian project. *See* Methods
Infections
relation to risk of xerophthalmia, 126–37
systemic, effect on vitamin A status, 124–25
Inflammation, effect on conjunctival xerosis, 49–51, Table 3-14
Inflammatory cells, role in corneal ulceration/necrosis, 77, 80, 83, 86–88, Figs. 5-1, 5-2, 5-3

Keratin, as culture medium, 94
Keratinization, conjunctival, 30–36, 47–48, 51–52, Figs. 3-1 to 3-4, Table 3-3
persistent, and chronicity, 48
Keratinization, corneal, 83, Fig. 5-1
mechanism, 92–94
Keratomalacia
terminology, 5
treatment, 4
See also Corneal ulceration/necrosis

Laboratory assessment
holo-RBP, 8
liver vitamin A, 7
serum vitamin A, 7
total-RBP, 7–8
Lissamine Green. *See* Vital staining
Liver
storage, vitamin A, 7
stores, and diet, 139

Massive vitamin A dose
distribution of, 212–13, 216
duration of effect, 211–13, Table 14-1
frequency of administration, 209–11
for infants and mothers, 216
and maintenance of vitamin A levels, 210–11
and protection from xerophthalmia, 210–12
size of dose, 209–11
targeting, 213
Measles
and blindness in Africa, 134–36
and corneal scars, 132
herpes infection in, 135–36
and mortality, 132
and nutritional status, 132–33
postmeasles syndrome, 133
precipitation of corneal ulceration/necrosis, 74, 80, 129–32
precipitation of corneal ulceration/necrosis, 74, 80, 129–32
and protein metabolism, 133
relation to risk of xerophthalmia, 129–36, Tables 8-3, 8-4
Methods, Indonesian Project
detailed, 223–42
summary, 9–15
Monosodium glutamate. *See* Prevention, by fortification
Mortality, 179–84, Tables 12-1, 12-3
blindness and, 183
nutritional status and, 179–82, Table 12-2
vitamin A deficiency and, 182–83
Mucus component of tear film
goblet cells, significance, 91–92. *See also* Goblet cells
role, 92

Nightblindness
in ancient history, 3–4, 19
response to therapy, 24
and photic stress, 19, 23
terminology, 4
See also Rhodopsin; Visual cycle
Nightblindness, by history
in conjunctival xerosis, 21–24, 45, Fig. 2-1
in corneal xerophthalmia, 23–24, Table 2-3
isolated finding, 22–23
prevalence, compared with Bitot's spots, 20, Table 2-1
as screening tool, 213–15, Table 14-2
serum vitamin A, compared with conjunctival xerosis, 20–21, Tables 2-1, 2-2
validation by examination, 21
Nutrition education, 221–22. *See also* Green leafy vegetables, Prevention, dietary

Nutritional status, general, 101–103, 116–22. *See also* Height, Height for age, Weight for height
Nyctalopia, terminology, 4

Oral vitamin A. *See* Treatment, Treatment trials

Photoreceptors, in vitamin A deficiency, 26–27
Pregnancy, effect on vitamin A status, 140
Prevalence, xerophthalmia in Indonesia, 165–68, Tables 11-2 to 11-4, 11-6
Prevalence criteria
  validity, 168–72, Table 11-8
  WHO (1976), Table 11-7
  WHO (1981), Appendix II
Prevention, 209–222
  background, 209
  dietary, 218–22, Tables 14-5 to 14-7
  by fortification, 216–18, Tables 14-3, 14-4
  by periodic dosing, 209–16, Table 14-1
  role of measles immunization, 209
  See also Massive vitamin A dose
Proteases, role in ulceration, 86–88
Protein status
  effect on RBP response, 201–204, Table 13-11
  effect on RBP synthesis, 110, 115
  effect on vitamin A storage, 111
  paradoxical effects on vitamin A status, 116
  and response to therapy. *See* Treatment, Treatment trials
  and risk of xerophthalmia, 109–10, 115–16
  and severity of corneal xerophthalmia, 98–100
  See also Albumin, serum, Edema, pedal, Transferrin, serum, Vitamin A–protein interaction
Punctate keratopathy
  clinical appearance, 58, Fig. 4-1, Plate 11
  and conjunctival xerosis, 45–46, Table 3-12
  and corneal xerosis, 61–62, Tables 4-3, 4-4
  origin, 83
  prevalence and severity, 58–60, Table 4-2
  response to therapy, 60, Table 4-2

RBP, apo-, metabolism, 7–8
  See also Retinol-binding protein
RBP, holo-
  in corneal xerophthalmia, 98, Table 9-9
  critical levels for corneal xerophthalmia, 198, Fig. 13-1
  effect of protein status on response, 201–204, Table 13-11
  metabolism, 7–8
  See also Retinol-binding protein, Treatment trials
Relapse. *See* Massive vitamin A dose, Treatment trials
Respiratory infection
  and absorption, 124
  and corneal xerophthalmia, 104
  relation to risk of xerophthalmia, 128–29, Fig. 8-1
  urinary vitamin A loss, 124
Response to therapy. *See* Treatment trials
Retinol, metabolism, 6–7
Retinol-binding protein
  apo. *See* RBP, apo-
  holo. *See* RBP, holo-
  laboratory techniques, 7–8
  metabolism, 7–8
Retinyl ester, metabolism, 6
Rhodopsin, 19–20
Rod thresholds, elevated. *See* Dark adaptation, impaired
Rose Bengal. *See* Vital staining

Screening for vitamin A deficiency
  Bitot's spots, 213
  history of nightblindness, 213–15, Table 14-2
  value, 216
  See also Nightblindness, by history
Seasonal variation in xerophthalmia, 161
Sex, and risk of xerophthalmia, 155–57, Table 10-2, Fig. 10-1
Size of xerophthalmia problem
  Indonesia, 165–68, Table 11-5
  worldwide, 174–75
Skimmed milk
  fortification, 116
  use as cause of xerophthalmia, 139–141
  vitamin A content, 140
Socioeconomic status, and risk of xerophthalmia, 147, 159–61
Spontaneous cure rate, noncorneal xerophthalmia, 164–65, Table 11-2
Squamous metaplasia. *See* Keratinization, conjunctival
Stromal cysts, role in ulceration, 86
Stromal edema, 83, 86
  in corneal necrosis, 73
  in corneal xerosis, 61–62, Table 4-5
Stromal exposure, role in ulceration, 86
Stromal loss, corneal. *See* Corneal ulceration necrosis
Study methods
  countrywide survey (IV), 13–14, 234–42
  hospital-based study (HHI), 9–13, 229–34

interpretation of data, 15
longitudinal field study (I), 9, 225–28
Stunting. *See* Height for age

Targeting distribution. *See* Massive vitamin A dose; Screening
Tear film
as factor in corneal involvement, 89–94
significance of alterations in, 92
See also Mucus; Tearing
Tearing
decreased, and severity of xerophthalmia, 89–90, Tables 6-1, 6-3, Fig. 6-1
functional dehydration, effect of, 90, 103
protein status, effect of, 89–90, Table 6-2
vitamin A status, effect of, 90, 91, Tables 6-3, 6-4
Terminology, clinical, 4–5
Transferrin, serum
interpretation, 98–99
levels in corneal xerophthalmia, 99–100, Table 6-9
See also Protein status
Treatment, xerophthalmia, 187–208
food, 205–207
historical background, 187–88
and nightblindness, 187
oral vitamin A, effectiveness, 204–205
recommendations, WHO (1976), 188
recommendations, WHO (1981), Appendix II
surgery, role, 208
systemic vitamin A, 188–205
topical vitamin A, 207–208
toxicity from, 204–205
use of cod liver oil, 187
use of topical liver juices, 187
Treatment trials, systemic vitamin A
biochemical response, 195–204
clinical response, 188–95, Tables 13-1, 13-2, 13-4 to 13-8
comparability of study participants, 191–92, Table 13-4
holo-RBP response, 198–204, Tables 13-9, 13-11, 13-12, Figs. 13-1, 13-2
influence of diarrhea, Table 13-6
influence of protein status, 191–92, 201–07, Tables 13-3, 13-7, 13-11, 13-13
relapse, early, 189–95, 205–207, Tables 13-3, 13-13
serum vitamin A response, 196–98, Tables 13-9, 13-10

Ulceration
effect on conjunctival xerosis, 49–51, Table 3-14
terminology, 5

Urinary tract infection, relation to xerophthalmia, 137

Visual cycle, 19–20
Visual field changes, xerophthalmic, 25, 27, Fig. 2-3
Visual outcome, active xerophthalmia, 176–79, Table 12-1
Visual purple. *See* Rhodopsin
Vital staining, diagnosis conjunctival xerosis, 52–53, Table 3-15
Vitamin A
absorption, 6
biochemistry and metabolism, 6–8
food sources, 6, 7, 219
liver stores, 7, 139
requirements, 210
serum level, critical values, 108–109
Vitamin A deficiency
historical developments, 4
RBP synthesis, effect on, 110
Vitamin A intake
neonatal, and adequacy of maternal stores, 141–42
prenatal, and adequacy of maternal stores, 139–40
seasonality, 139
weaning and early childhood, 144–50
See also Breast feeding; Dietary intake
Vitamin A–protein interaction, 100, 110–16
diet-induced association, 110
model, relative vitamin A adequacy, 111–13, Figs. 7-1, 7-2, 7-3
and RBP synthesis, 110
regression analysis, 113–14, Table 7-3
Vitamin A response to therapy. *See* Treatment trials
Vitamin A status
albumin-standardized, 113, Table 7-2
and Bitot's spots, 97, Table 2-2
collapsed, in keratomalacia, 113–14, Table 7-3
effect on growth, 116–22
interpretation of serum levels, 107
pregnancy, effect on, 140
of randomly sampled children, 97, Table 2-2
and risk of xerophthalmia, 107–109, Table 7-1
serum levels, critical values, 108–109
and severity of corneal change, 97–98, Table 6-6
See also RBP, holo; Vitamin A–protein interaction
Vitamin A status, rapid deterioration
conjunctival response, 49–51, Table 3-14
corneal response, 50–51

Weight for height
in corneal xerophthalmia, 101–103, 117, Table 6-11
interpretation, 101
relation to xerophthalmia, 117–19, 121–22, Tables 6-11, 7-4, 7-5
See also Nutritional status, general
World Health Organization, recommendations, 243–44
Worldwide distribution of xerophthalmia, 172–74
Worldwide magnitude of xerophthalmia, 174–75
Worms, passed
and corneal xerophthalmia, 104
relation to risk of xerophthalmia, 136–37, Table 8-5

Xerophthalmia
historical notes, 3–4
magnitude and distribution of problem, 162–75. *See also* Incidence; Prevalence; Size of problem; Spontaneous cure rate
terminology, 5

Xerophthalmia, classification
suggested alterations in, conjunctival, 51
WHO (1976), 57, Table 1-1
WHO (1981), Appendix II
Xerosis, terminology, 1

Other Books of Interest

EPIDEMIOLOGY AND STATISTICS FOR THE OPHTHALMOLOGIST
Alfred Sommer
1980 paper

WORLD BLINDNESS AND ITS PREVENTION
Sir John Wilson, Ed.
1980

A HANDBOOK OF OPHTHALMOLOGY FOR DEVELOPING COUNTRIES
Second Edition
Geoffrey G. Bisley
1980 paper

AN INTRODUCTION TO OPHTHALMOLOGY
Second Edition
John Parr
1982 paper

OPTIC NEURITIS AND ITS DIFFERENTIAL DIAGNOSIS
G. D. Perkin and F. Clifford Rose
1979

WORLD NUTRITION AND NUTRITION EDUCATION
H. M. Sinclair and G. R. Howat, Eds.
1980

FOUNDATIONS OF EPIDEMIOLOGY
Second Edition
Abraham M. Lilienfeld and David E. Lilienfeld
1980 cloth and paper

INTERNATIONAL HEALTH
Paul F. Basch
1978 cloth and paper

PAEDIATRICS IN THE TROPICS
Current Review
R. G. Hendrickse
1981

BLINDNESS AND VISUAL HANDICAP: THE FACTS
J. H. Dobree and R. Bolton
1982

Oxford University Press, New York