PN-AAK-894
ISN 2092

Reprinted from the Archives of Ophthalmology
March 1982, Volume 100
Copyright 1982, American Medical Association

Corneal Xerophthalmia and Keratomalacia

Alfred Sommer, MD, Tjakrasudjatma Sugana, MD

• Detailed examinations were conducted on 162 consecutive children with nutritional keratopathy. Surface changes ranged from mild haziness through generalized xerosis and formation of thickened keratinized plaques. Diffuse stromal edema occurred early in the disease. Stromal loss took two forms: relatively small, sharply demarcated, eccentric, noninfiltrated cylindrical ulcers of varying depth; and localized or generalized, usually full-thickness necrosis. All forms of involvement were sometimes present in the same individual or even the same eye. Traumatic separation of a keratinized plaque, or decompensation of a dellen, accounted for some instances of stromal baring. In other cases, stromal melting appeared to progress below an intact epithelium. Focal areas of necrosis healed rapidly, as adherent leukomas; larger lesions sloughed, forming extensive descemetoceles. With therapy, the vast majority of children retained central corneal clarity.

(*Arch Ophthalmol* 1982;100:404-411)

Xerophthalmia probably affects 5 million Asian children every year.[1] In half a million, substantial corneal involvement develops, a quarter of a million going blind. Corneal manifestations, recognized for hundreds of years,[2-8] were recently classified as follows.

With a classification of X2 the sign was corneal xerosis, with X3A, corneal ulceration with xerosis; with X3B, keratomalacia; and with XS, corneal scars.

Precise descriptions of these changes, their cause and pathogenesis, have been limited by the absence of carefully correlated clinical, bacteriologic, histopathologic, and biochemical studies on large numbers of very young children. Such studies, recently carried out in Indonesia, resulted in the recognition of punctate keratopathy as an early manifestation of vitamin A deficiency.[9,10] In the present report we describe more severe forms of corneal involvement.

SUBJECTS AND METHODS

A detailed description of subjects and methods appears elsewhere.[1] In brief, all individuals with active corneal disease who came to the Cicendo Eye Hospital, Bandung, Indonesia, between June 1977 and September 1978, underwent detailed ophthalmic and pediatric examinations. The ocular examination was carried out in the following order: the eye was examined with a hand light and a slitlamp, first without and then with sterile fluorescein; the cornea and conjunctiva were swabbed, and, if an ulcer was present, scraped for bacterial and fungal studies; sterile lissamine green was placed in the cul de sac and the degree of staining was assessed[11]; a Schirmer test was carried out in both eyes after topical application of proparacaine hydrochloride and drying of the conjunctiva and inferior cul de sac; 1% tropicamide and 10% phenylephrine hydrochloride were placed in both eyes, and scotopic vision was tested after 30 minutes dark adaptation[10,12]; finally, the fundus was examined by indirect ophthalmoscopy, and, when abnormalities were noted and the cornea was sufficiently clear and intact, with the slitlamp and contact lens.[13] All lesions were drawn and photographed.

Three milliliters of venous blood was collected and immediately spun. The clear supernatant was separated and stored at −20 °C. Vitamin A determinations were carried out by the method of Neeld and Pearson,[14] usually within one week but never more than two weeks after collection The serum holoretinol-binding protein (HRBP) level was determined by the method of Glover et al,[15] usually within two months and never more than eight months after collection. Transferrin levels were determined by the technique of Mancini et al.[16] All laboratory investigations were carried out in masked fashion. Because of equipment failure, vitamin A determinations were not available from July 16, 1977, through Jan 14, 1978, and HRBP after May 15, 1978

After receipt of informed consent from an accompanying parent or guardian, subjects with abnormal conditions (and matched control subjects) were enrolled in one of several treatment trials. All received one or more massive doses of vitamin A[1,17] and were offered free hospitalization. Those accepting hospitalization received a high-protein diet, and appro-

Accepted for publication April 1, 1981.
From the International Center for Epidemiologic and Preventive Ophthalmology, Wilmer Ophthalmological Institute, The Johns Hopkins Medical Institutions, Baltimore, and Helen Keller International, New York (Dr Sommer); and the Nutritional Blindness Prevention Project, Bandung, Indonesia (Drs Sommer and Sugana)
Read in part before the Sixth European Congress of Ophthalmology, Brighton, England, April 25, 1980.
Reprint requests to Wilmer Ophthalmological Institute, 600 N Wolfe St, Baltimore, MD 21205 (Dr Sommer)

priate therapy for any systemic illnesses present (respiratory tract infection, gastroenteritis, etc). Every attempt was made to reexamine the children daily until healing of their lesions, and monthly thereafter. Corneal material was available for histopathologic examination in a limited number of cases where the patients either died or required enucleation.

Fifteen cases of corneal disease were excluded from the series: four with bacteriologically confirmed gonococcal ophthalmia (all under 3 weeks of age with grossly purulent eyes); three with phlyctenulosis; two with epidemic keratoconjunctivitis; one mild case of measles keratoconjunctivitis; one case of multiple small peripheral ulcers of classic staphylococcal hypersensitivity that cleared with topical steroids and antibiotics; four with presumed xerophthalmia who had already received antibiotics and vitamin A before the first observation by us; and two with active measles and atypical stromal lesions who, in retrospect, probably represented xerophthalmic corneal involvement modified by the viral illness [1]

Statistical analyses included χ^2 with the Yates' correction and tests for linear trend in proportions.[18,19]

RESULTS

One hundred sixty-two consecutive cases of presumed corneal xerophthalmia were classified by the clinical severity of the worst affected eye into one of eight files, grouped into three categories (Table 1). Fifty-three percent of cases were male, 47% female, the distribution being independent of the severity of disease. Subjects ranged in age from 1 month (an infant with severe bilateral xerosis and unilateral limbal-limbal necrosis, said to have been born with Bitot's spots) to 12 years (median, 3 years) (Table 2). The severity of disease was inversely related to age (Table 3).

Table 1 —Clinical Classification of Corneal Cases in Study*

Class	File	Clinical Description	Cases (No.)
X2	1*	Mild xerosis haziness and loss of luster	24
	2	Moderate xerosis surface has dry, peau d'orange appearance	24
	3	Severe xerosis: presence of keratinized plaques	5
X3A	4	Small ulcer(s) sharply demarcated, 1-3 mm in diameter, superficial or deep	45
	5	Large ulcer usually full-thickness, may be variant of file 4 or 6 lesion	5
X3B	6	Localized stromal necrosis	34
	7	Complete corneal necrosis: unilateral	13
	8	Complete corneal necrosis. bilateral	12

*Classified by most severe lesion in worst eye

Table 2.—Age Distribution of Corneal Cases

File	Total (No.)	Age, yr* 0	1	2	3	4	5	≥ 6
1	24	0	8	21	33	21	8	8
2	24	0	13	42	17	17	8	4
3	5	0	0	60	20	20	0	0
4	45	4	11	42	16	13	9	4
5	5	0	0	60	40	0	0	0
6	34	15	24	29	15	15	3	0
7	13	23	31	23	8	15	0	0
8	12	17	25	8	17	8	8	17
Total	162	7	15	33	19	15	6	4

*Percent of total in row

Table 3 —Proportion of Subjects Less Than 2 Years of Age

Severity of Corneal Lesion (File)	% of Total in File (Age, yr) 0	1	Total < 2*
1-3	0	9	9
4-5	4	10	14
6	15	24	38
7-8	20	28	48

*$P < .001$ by linear trend for proportions

Clinical Appearance

X2 (Corneal Xerosis).—The mildest clinical change apparent by hand light was a slight haziness, or loss of luster, adjacent to the inferior limbus, representing numerous fluorescein-positive punctate lesions and mild, localized stromal edema. With more severe involvement, more or all of the corneal surface was hazy, representing increased density and extent of the punctate lesions and severity and extent of accompanying stromal edema (Fig 1 and 2). Dense accumulation of healed, residually pigmented intraepithelial and subepithelial specks accounted for persistence of inferior haziness in treated cases. In an occasional case, nonstaining, fine epithelial microcysts were initially present. These were often extremely water repellent and appeared less fluorescent than the background tear film. They usually disappeared within one to two days of vitamin A therapy, sometimes being replaced by typically staining punctate lesions.

With more severe involvement, the corneal surface assumed a dry, granular peau d'orange appearance, most prominent inferiorly adjacent to the limbus, or as a horizontally oval area 2 to 3 mm above it (file 2) (Fig 3). The frankly xerotic nature of these changes was often apparent, even on hand-light examination. In some, fluorescein stained or pooled in "cracks" in the cornified surface, forming a tree-bark appearance. Following therapy, the cornified layer eventually peeled off (Fig 4).

The most severe surface change was a thick, heavily xerotic plaque, generally located in the interpalpebral zone (file 3) (Fig 5). These were foamy or amorphous in nature, suggesting that they are composed of bacterial and keratin debris as observed in thick Bitot's spots.[1,20]

Several distinctive forms of stromal loss were observed, although one small group of patients (file 5) was difficult to categorize.

X3A (Ulceration).—Classic, uncomplicated ulceration (file 4) consisted of one (91% of cases) or more sharply demarcated ulcers of varying depth (Fig 6 through 8). In more than 70% of affected eyes, the ulcers had a punched-out, smooth-walled, cylindrical appearance, as if a trephine had been applied to the eye. The margins were usually regular, and in only a small minority, swollen. Infiltration, present in a minority of cases, was usually slight and confined to the

Figure 1.

Figure 2.

Figure 3.

Figure 4.

Figure 5.

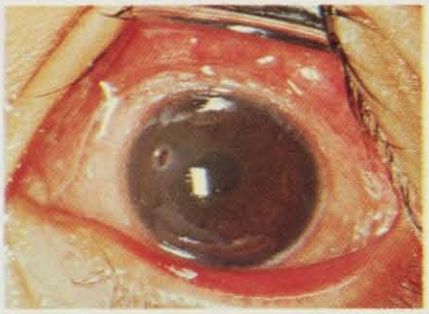

Figure 6.

Figure 7.

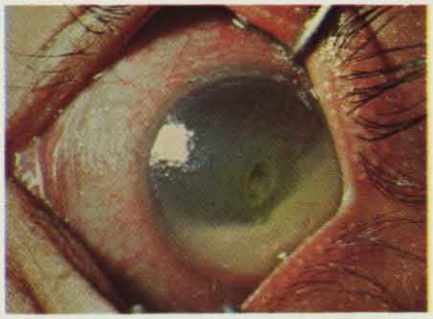

Figure 8.

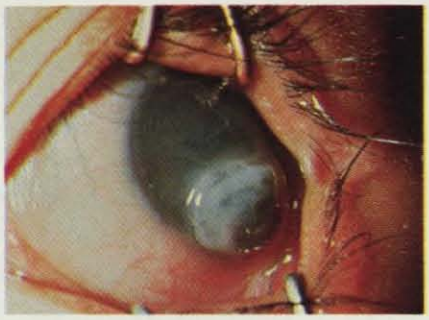

Figure 9.

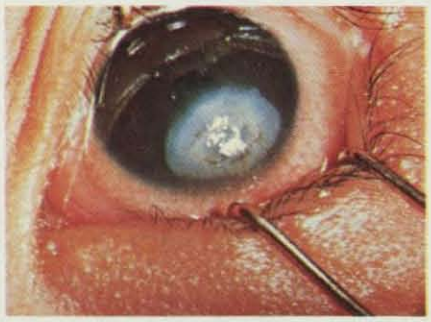

Figure 10.

Figure 11.

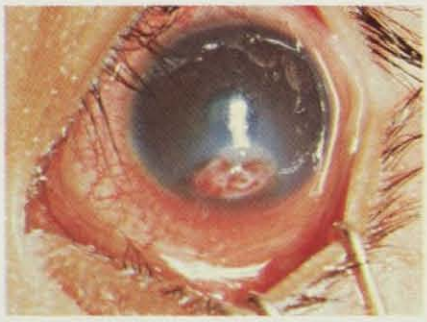

Figure 12.

3

Fig 1.—Corneal xerosis (files 1 and 2 severity). Bilateral inferior corneal haze in 4-year-old girl. Serum vitamin A level, 4 μg/dL; holoretinal-binding protein, 0 μg/mL.

Fig 2.—Corneal xerosis (file 2 severity). Punctate keratopathy, densest inferiorly, in xerotic right eye of 2-year-old girl. Left eye contained inferior ulcer. Serum vitamin A level, 13 μg/dL; holoretinol-binding protein, 0 μg/mL.

Fig 3.—Corneal xerosis (files 2 and 3 severity). Peau d'orange (file 2) and xerotic plaque (file 3) bilaterally in 3-year-old boy. Holoretinol-binding protein, 1 μg/mL.

Fig 4.—Peeling of keratinized surface. Two days following systemic vitamin A therapy, patch of xerotic surface of eye in Fig 2 peeled inferiorly, forming scroll below, and leaving xerosis-free island of clear cornea.

Fig 5.—Corneal xerosis (file 3). Thick amorphous plaque, resembling Bitot's spot, adherent to cornea of severely malnourished 2½-year-old girl.

Fig 6.—Xerophthalmic ulcer (file 4 type). Typical "punched-out" ulcer, three fourths of corneal depth, in left eye of 4-year-old boy. Other eye contained area of localized necrosis. Serum vitamin A level, 4 μg/dL; holoretinol-binding protein, 1 μg/mL.

Fig 7.—Xerophthalmic ulcer (file 4 type). Typical "punched-out" ulcer, one fourth corneal depth, in right eye of 3-year-old girl. Although anterior chamber was formed, pigment was present on posterior surface of cornea, left behind by iris torn free during dilation. Other eye contained descemetocele (Fig 19). Serum vitamin A level, 4 μg/dL.

Fig 8.—Xerophthalmic ulcer (file 4 type). Unusually central ulcer in left eye of 2-year-old boy. Dense inferior hypopyon present. Right cornea xerotic. Serum vitamin A level, 5 μg/dL.

Fig 9.—Localized necrosis (file 6 type). Typical focal necrosis in 2-year-old severely malnourished boy. Other eye severely xerotic. Corneal problem first noted three weeks after measles.

Fig 10.—Healed necrosis. Same eye as Fig 9, one month after isolated vitamin A therapy (parents refused to permit hospitalization). Note clear pupillary zone.

Fig 11.—Localized necrosis (file 6 type). Typical localized necrosis in otherwise healthy, well-nourished 2-year-old boy. Temporal and nasal conjunctival xerosis/Bitot's spots in both eyes. Corneal abnormality in other eye limited to dense punctate keratopathy. Serum holoretinol-binding protein, 1 μg/mL.

Fig 12.—Healing necrosis. Same eye as Fig 11 two weeks after single oral dose of 200,000 IU of vitamin A.

base, inner wall, or a thin rim about the surface of the ulcer. In a small percentage of cases, ulcers were smooth, saucer-shaped depressions, otherwise identical in appearance to those above. In 9% of affected eyes, the worst lesion was a mild, seemingly transitional stage, in which a large subepithelial bulla, sometimes encountered in cases of X2 (files 1 through 3), had ruptured, resulting in a densely staining erosion or superficial ulcer.

More than three fourths of all ulcers were located in the inferior and/or nasal quadrants. The vast majority were round and 1 to 2 mm in diameter. Those in the inferior quadrant were more often horizontally oval, 1 to 3 mm in length and at least 1 to 2 mm above the limbus. Most ulcers were one-fourth to one-half corneal thickness in depth. When ulcers were present bilaterally, their location, size, shape, and depth were extraordinarily symmetrical. Conjunctival injection (of varying severity) was present in 79% of ulcerated eyes, and a hypopyon, in 32%.

File 5 consisted of five cases of large, full-thickness stromal ulceration (reaching to or beyond Descemet's membrane), similarly localized and sharp margined. They probably represent a modification or advanced stage of surface ulceration (file 4), or full-thickness stromal necrosis (file 6).

X3B (Necrosis).—Except for the size of the area of involvement, lesions in files 6 to 8 were similar in appearance and readily distinguishable from those in file 4.

Patients in file 6 had localized, opaque, gray to yellow, deep stromal necrosis, ranging in size from 3 mm to involvement of almost the entire cornea (Fig 9 through 13) (by definition the cutoff for files 7 and 8). Grayish lesions were generally edematous and cystic. Often level with, or protruding above, the corneal surface, they collapsed with treatment, assuming the appearance of sharply demarcated stromal defects. These were often considerably smaller than expected from their initial appearance, as if reversible changes had originally surrounded the central area of dissolution. Occasionally the edematous tissue sloughed. Deep stromal loss was sometimes followed by descemetoceles, rupture, perforation, and iris prolapse.

Yellowish lesions suggested heavy, focal inflammatory infiltration. In a number of instances these formed protuberant, dome-shaped lesions, sometimes with smooth, glistening surfaces that failed to stain with fluorescein. Staining usually appeared, however, within one to three days of vitamin A therapy. Small descemetoceles (less than one fourth of the corneal surface) reepithelialized rapidly (two to five days) and scarred quickly. Larger descemetoceles scarred extremely slowly, those covering three fourths or more of the corneal surface commonly eventuating in anterior staphylomas and ultimately phthisical globes.

Generalized stromal edema was extremely common. Corneal thickness sometimes reached three to four times normal with marked shallowing of the anterior chamber in the absence of demonstrable perforation.

In the most severe form of disease, all but a thin rim of limbal tissue was destroyed in one (file 7) or both (file 8) eyes (Fig 14 through 18). In some the cornea initially appeared firm, yellowish-white, but intact, while in others it was clear and gelatinous. In all instances the stroma sloughed within one to three days, leaving a total descemetocele (Fig 19 through 21). The peripheral 1- to 2-mm corneal-limbal zone, usually opaque and edematous on admission, remained vital.

The prevalence of binocular stromal loss (files 4 through 8) increased with the severity of loss in the worst affected eye (Table 4, $P < .001$ by linear trend).

Intermediate and Transitional Lesions

A variety of intermediate, potentially transitional lesions were observed. These are described in greater detail elsewhere.[1]

1. As already indicated, xerotic corneas occasionally contained nonstaining, water-repellent intraepithelial microcysts. These disappeared within a few days of vitamin A therapy, often being replaced by fluorescein-positive punctate epithelial defects.

2. Some xerotic (X2) corneas contained multiple small bubble-like

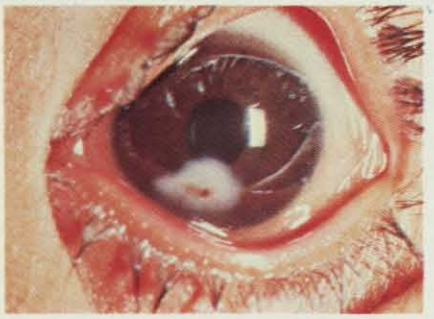

Figure 13.

Figure 14.

Figure 15.

Figure 16.

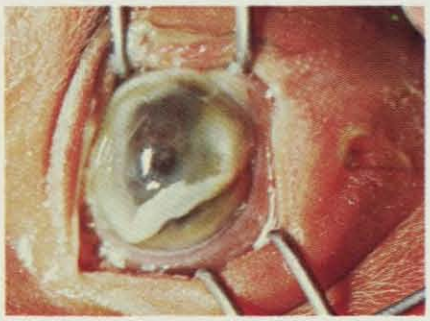

Figure 17.

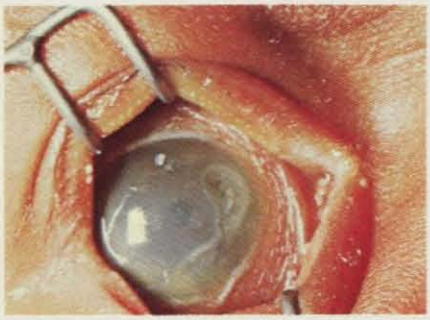

Figure 18.

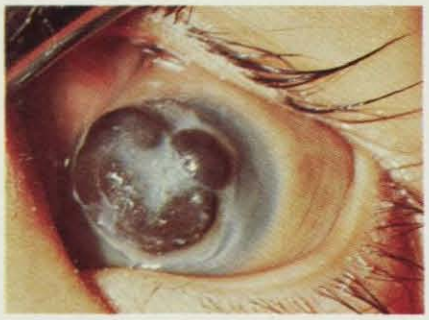

Figure 19.

Figure 20.

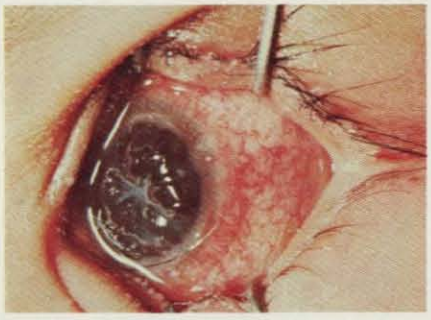

Figure 21.

Figure 22.

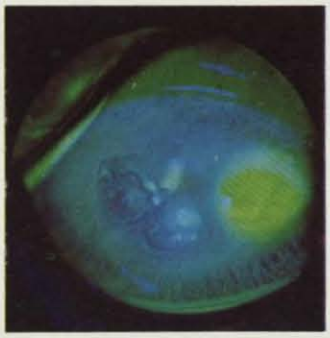

Figure 23.

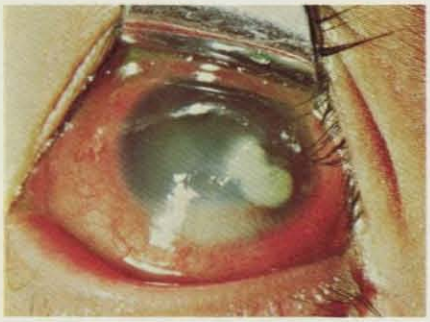

Figure 24.

Fig 13.—Healed necroses. Residual adherent leukoma in same eye as Fig 11 and 12, one month after single oral dose of vitamin A. Note clear pupillary zone.

Fig 14.—Complete corneal necrosis (files 7 and 8 type). Complete corneal necrosis in right eye of 10-month-old severely malnourished boy. Other cornea xerotic. Serum vitamin A level, 6 μg/dL; holoretinol-binding protein, 1 μg/mL.

Fig 15.—Phthisical globe. Eye in Fig 14, three months after presentation.

Fig 16.—Complete corneal necrosis (files 7 and 8 type). Complete necrosis of left cornea of malnourished 2-year-old boy. Other eye contained inferior area of focal necrosis. Serum holoretinol-binding protein, 1 μg/mL.

Fig 17.—Complete corneal necrosis (files 7 and 8 type). Complete necrosis of left cornea in youngest child in series: 1-month-old boy allegedly born with Bitot's spots. Conjunctiva of both eyes severely xerotic. Serum vitamin A level, 6 μg/dL; holoretinol-binding protein, 2 μg/mL. Mother's serum vitamin A level, 13 μg/dL.

Fig 18.—Right eye of child whose left eye is shown in Fig 17.

Fig 19.—Descemetocele (files 7 and 8). Sloughing of necrotic stroma results in total descemetocele of left cornea of child whose right eye is shown in Fig 7.

Fig 20.—Descemetocele (files 7 and 8). Total descemetocele in severely malnourished 4-year-old girl. Conjunctivae of both eyes were severely xerotic (not well appreciated in photographs because of tearing). Serum holoretinol-binding protein, 2 μg/mL.

Fig 21.—Descemetocele (files 7 and 8). Other eye of subject shown in Fig 20.

Fig 22.—Transitional lesions. Reasonably well-nourished 1-year-old boy, with serum vitamin A level of 4 μg/dL. Right eye (not shown) contained punctate keratopathy and conjunctival xerosis. Left eye had two infiltrated, saucer-shaped depressions (one inferiorly, the other inferotemporally). Staining was limited to cancer of each depression, where it was deep and cylindrical. Nasally there was a large, focal area of surface irregularity, composed of superficial stromal blisters, each surrounded by a depression, but in the area was zero. Entire stroma was edematous, being three times normal thickness.

Fig 23.—Same eye as Fig 22, two days after 200,000 IU of oil-miscible vitamin A intramuscularly, but still zero in nasal area of irregularity; inferior depression (with central ulceration) is unchanged; ulceration in temporal lesion is enlarged.

Fig 24.—Same eye as fig 22 and 23, five days after initial therapy. Nasal irregularities gone; inferior ulcer healed as clear, saucer-shaped depression considerably larger than original area of frank ulceration; temporal lesion now localized area of necrosis.

Table 4.—Active Binocular Stromal Loss* in Corneal Cases

Severity of Worst Lesion in Worst Eye (File)	Total Cases, No.	Bilateral Stromal Loss†	
		No.	%
4	44‡	8	18
5	5	4	80
6	34	15	44
7-8	25	23	92

*Ulceration or necrosis.

†Difference in prevalence, files (4 and 5):6, and 6:(7 and 8), $P < .01$.

‡Omits one case with healed staphyloma in the fellow eye.

mounds: sharply demarcated, clear, cystic swellings within the superficial stroma. In some instances, but not all, their surface stained with fluorescein. Within a few (one to five) days, these were often replaced by classic, sharply demarcated, noninfiltrated, intensely fluorescein-positive ulcers. In other cases they simply disappeared.

3. One case (200/160) was particularly revealing and will be described in detail. A 1½-year-old male infant had a serum vitamin A level of 4 μg/dL, but was otherwise reasonably well nourished (albumin level, 3.2 g/dL; weight for height, 90% of Harvard standard). The right eye was white and quiet, with conjunctival xerosis inferiorly for 180°. The cornea was clear by hand-light examination but covered by dense punctate keratopathy. The conjunctiva of the left eye was injected, not xerotic. Its central corneal surface was sharply irregular, with alternating mounds (clear epithelial or thin-walled superficial stromal vesicles) and depressions, none of which stained, sitting atop deep stromal edema (two to three times normal corneal thickness) (Fig 22 and 23). Inferior to this irregular patch were two saucer-shaped ulcers of peculiar appearance; for half their depth (the superficial one fourth of the corneal thickness), the walls were gently sloping and failed to stain with fluorescein; this was followed by an abrupt transition, the deeper half having a classic, cylindrical-shaped, punched-out, intensely staining ulcerated appearance. After the patient received vitamin A therapy, one of these ulcers healed uneventfully, becoming a clear, saucer-shaped corneal depression. The other did not fare as well: by day 2 it had become a deeper, V-shaped gutter depression, the entire depth staining from edge to edge. By day 5 the area was opaque, its surface a fluorescein-positive, bulging mass, like an abscess typical of file 6 (Fig 24). It eventually healed as a dense leukoma. This poor response may have been related to the use of a massive, but oil-miscible injection of vitamin A (serum vitamin A level still only 4 μg/dL the day following therapy).[1] This eye, therefore, contained a continuous and potentially related spectrum of changes from dellen-like depressions containing central subepithelial clefts and erosions-ulcerations through classic, deep, sharp-margined stromal loss.

4. Focal infiltration was occasionally present early in the course of stromal involvement. Both corneas of one subject were heavily xerotic and twice normal thickness. A perfectly round, 1- to 2-mm, superficially fluorescein-positive, yellowish infiltrate was present superonasally in the right cornea. A classic punched-out perforation occupied the identical position in the other eye. Despite routine therapy, by the next day, the shallow infiltrated lesion of the right eye had become a densely staining, sharp-margined, punched-out ulcer (one third of the corneal depth), surrounded by only a tiny rim of infiltrate.

5. Two forms of corneal erosion-ulceration were observed in association with surface cornification. As the cornified layer lost its attachment to deeper, normal epithelium following vitamin A therapy, abrasive lid action caused premature, traumatic separation. Sudden, complete sloughing sometimes left a focal area of erosion-superficial ulceration at the firmest point of attachment. Typical ulcers were also observed within, and often at, the receding edge of thick keratinized corneal plaques.

Final Vision

The prospects for a clear, central cornea zone in one or both eyes were good in all cases except those with total bilateral necrosis (file 8). De-

Table 5 —Central Corneal Clarity

Original Classification (File)	No. of Cases†	Final Visual Acuity* No. of Cases 6/6 OU	6/6 Better Eye	< 6/60 OU	% of Cases ≥ 6/6 One or Both Eyes
X2 (1-3)‡	51	50	1	..	100
X3A (4-5)	46	36	10	.	100
X3A/B (6)	27	13	12	2	93
X3B (7)	11	.	9	2	82
X3B (8)	12	...	...	12	0
Total	147	99	32	16	89

* As estimated from central corneal clarity No cases resulted in central opacification compatible with acuity of the better eye between < 6/6 and ≥ 6/60

†Of all subjects in the 162 cases, seven did not have a follow-up examination, of those that did, nine died within one month, leaving 147 (91%) potential survivors in whom final corneal clarity was assessed

‡One patient, listed as 6/6 OU, initially had clearing but bilateral ulceration developed between days 15 and 25 and death occurred after one month The single case with less than 6/6 in one eye contained a staphyloma from old, healed keratomalacia

spite bilateral stromal loss in 18% to 92% of the cases of ulceration-necrosis (files 4 through 8), between 82% (file 7) and 100% (files 4 and 5) of the patients with stromal loss who survived at least one month retained a clear pupillary zone in at least one eye (Table 5).

COMMENT

Confusion over the classification, cause, and pathogenesis of corneal abnormalities in malnourished, sickly, and xerophthalmic children largely stems from the absence of standardized, detailed, clinical descriptions and correlative studies covering the full spectrum of disease. The present study provides such data on changes ranging from mild epithelial haze through frank limbal-limbal dissolution of the stroma.

Disturbed vitamin A metabolism appears to lie at the heart of the problem. In the accompanying article (see p 399) it is demonstrated that severity of corneal involvement in these children is directly related to vitamin A status, and that the adequacy of vitamin A metabolism is influenced by protein status. Vitamin A alone,[1] or in combination with supportive therapy,[17] almost invariably results in healing of viable corneal tissue.

The corneal changes appeared to represent a continuum, with all forms frequently present in the same individual and occasionally in the same eye. The mildest alterations are primarily epithelial: punctate erosions through frank keratinization of the entire surface, usually accompanied by diffuse stromal edema. Several mechanisms may be responsible for epithelial loss and stromal baring. Traumatic sloughing of cornified epithelium at a site of firm adhesion appears capable of removing a deep epithelial plug. The same mechanism may account for erosions or ulcers located within, or at the edge, of thick keratinized plaques. Alternatively, these may be decompensated dellen, caused by their proximity to steep-margined plaques[21,22] and exacerbated by the already reduced wettability of the xerotic corneal surface and decreased tearing consequent to vitamin A deficiency, protein deficiency, and dehydration.[1] The case reported in detail, with an irregular, intact corneal surface, was especially informative. Stromal vesicles were interspersed among areas clearly depressed below the level of the surrounding, normal surface. If the depressions indeed represent areas of stromal desiccation,[23] they are of a most unusual sort, sitting atop deeper stromal edema that increased corneal thickness to twice normal. This suspicion was heightened by the presence of peculiar ulcers in the adjacent (inferior) area: saucer-shaped, sloping, epithelialized depressions with central cylindrical ulceration, as if a stromal vesicle within a dellen had ruptured.

Typical xerophthalmic corneal ulcerations had a characteristic appearance: sharp-margined, cylindrical-shaped ulceration of varying depth without thickened or undermined margins and little if any evidence of infiltration. In one instance, however, the ulceration clearly began as a yellowish, staining, heavily infiltrated lesion that soon sloughed, leaving a classic, noninfiltrated ulcer behind. Superficial, shallow ulcers healed rapidly by reepithelialization. These could easily be missed at follow-up examination. Careful slitlamp examination, however, revealed a persistent superficial depression.

In at least one instance, a typical, noninfiltrated ulcer progressed to a heavily infiltrated, yellowish, opaque bulging mass typical of severe, full-thickness corneal necrosis seen in more advanced disease. It is unlikely, however, that all forms of xerophthalmic necrosis proceed in this fashion. In many instances, these bulging necrotic masses had smooth, glistening surfaces that failed to stain with fluorescein, suggesting that the epithelium was still intact. In one case,[1] a deep, clear, wide stromal cleft was present below an obviously intact epithelial surface, as if dissolution began deep to the epithelial surface. Histopathologic material from another case,[1,24] to be reported in greater detail, demonstrated fragmentation and collagen loss deep to an intact epithelium, in the absence of substantial numbers of inflammatory cells. Deep epithelial or superficial stromal bullae have been observed in vitamin A-deficient rabbits.[25]

Collagenases and other proteases[26,27] known to be released by regenerating epithelium,[28-30] keratocytes,[31,32] and infiltrating leukocytes,[33-35] and controlled by epithelial changes,[3] might account for cylindrical anteroposterior ulcers and sharply demarcated (localized) full-thickness necrosis. However, these mechanisms fail to explain rapid stromal necrosis deep to an intact epithelium, observed in several of our cases, those reported previously,[7,8,36] and occasionally observed in the vitamin A-deficient rat.[37] They also fail to explain the absence of substantial numbers of inflammatory cells in histopathologic material from one of our cases of advanced collagen fragmentation and dissolution.[24]

It would appear that unique mechanisms, in addition to the more obvious surface changes, account for some of the corneal alterations observed in vitamin A-deficient children. Despite reports to the contrary,[38] primary or secondary infection appears to play little role in the course of events.[1]

With appropriate therapy, visual outcome appears to be reasonably good. The vast majority of subjects retained at least one structurally intact globe containing a clear pupillary zone. This favorable course is largely related to the focal, eccentric nature of early stromal loss. Full-thickness defects were rapidly plugged with iris, preserving the

anterior chamber. Administration of vitamin A then results in rapid reepithelialization and peripheral scarring.[1,17] In many cases the area of irreversible stromal destruction is often more limited than suggested by initial appearance. Among subjects who have complete, bilateral corneal necrosis (file 8), of course, the outlook is dismal. The anterior chamber is invariably lost and scarring proceeds extremely slowly. Loss of intraocular contents frequently supervenes.

The Nutritional Blindness Prevention Project is a joint undertaking of the Ministry of Health, Government of Indonesia, and Helen Keller International, with substantial funding from the Office of Nutrition, US Agency for International Development (USAID).

This investigation was supported by Cooperative Agreement AID/DSAN-CA-0267-931-0045 between the Office of Nutrition, USAID, and the International Center for Epidemiologic and Preventive Ophthalmology

References

1. Sommer A: *Nutritional Blindness. Xerophthalmia and Keratomalacia.* New York, Oxford University Press, 1981

2 Duddell B: *Treatise of the Diseases of the Horny-Coat of the Eye* London, John Clark, 1729, pp 57-58

3. Brown J Case of ulcerated cornea from inanition. *Edin J Med Sci* 1827,3 218.

4 Mackenzie W: *A Practical Treatise on Diseases of the Eye,* ed 2 London, Longman Rees Orme Brown & Green, 1834, pp 577-578

5 Hubbenet M· Observations sur l'hemeralopie. *Ann Oculist* 1860,44 293.

6 Mori S Ueber den sogenannten Hikan (xerosis conjunctivae infantum bzw keratomalacie). *Jahrb Kinderheilk* 1904;59·175-194.

7 Bloch CE· Clinical investigation of xerophthalmia and dystrophy in infants and young children (xerophthalmia et dystrophia alipogenetica). *J Hygiene* 1921,19 283-307.

8. Pillat A Does keratomalacia exist in adults? *Arch Ophthalmol* 1929,2.256-286

9. Sommer A, Emran N, Tamba T: Vitamin A responsive punctate keratopathy in xerophthalmia *Am J Ophthalmol* 1979,87 330-333

10 Sommer A, Emran N, Sugana T: Characteristics of vitamin A responsive and nonresponsive Bitot's spots *Am J Ophthalmol* 1980,90.160-171.

11. Emran N, Sommer A· Lissamine green staining in the clinical diagnosis of xerophthalmia. *Arch Ophthalmol* 1979,97 2333-2335

12 Sommer A, Hussaini G, Muhilal, et al: History of nightblindness A simple tool for xerophthalmia screening. *Am J Clin Nutr* 1980,33 887-891.

13 Sommer A, Sugana T, Djunaedi E, et al Vitamin A responsive pan-ocular xerophthalmia in a healthy adult *Arch Ophthalmol* 1978,96:1630-1634.

14 Neeld JR, Pearson WN Macro- and micromethods for the determination of serum vitamin A using trifluoroacetic acid. *J Nutr* 1963,97:454-462

15 Glover J, Moxley L, Muhilal H, et al: Micromethod for fluorometric assay of retinol-binding protein in blood plasma *Clin Chim Acta* 1974,50 371-380

16 Mancini G, Carbonara AD, Heremans JF: Immunochemical quantitation of antigens by single radial immunodiffusion *Immunochemistry* 1965,2 235-254.

17 Sommer A, Tarwotjo I, Djunaedi E, et al· Oral versus intramuscular vitamin A in the treatment of xerophthalmia. *Lancet* 1980,1 557-559

18 Snedecor GW, Cochran WG *Statistical Methods,* ed 6 Ames, Iowa, Iowa University Press, 1967.

19 Swinscow TDV *Statistics at Square One.* London, British Medical Association, 1978.

20 Sommer A, Green WR, Kenyon KR· Bitot's spots responsive and nonresponsive to vitamin A. *Arch Ophthalmol* 1981,99 2014-2027.

21. Baum JL, Mishima S, Boruchoff SA: On the nature of dellen. *Arch Ophthalmol* 1968;79 657-662

22 Pfister R, Renner M The histopathology of experimental dry spots and dellen in the rabbit cornea A light microscopy and scanning and transmission electron microscopy study. *Invest Ophthalmol* 1977,16 1025-1038

23. Dohlman CH, Lemp MA, English FP. Dry eye syndromes *Int Ophthalmol Clin* 1970,10.215-251

24. Sommer A The xerophthalmic cornea, in Trevor-Roper P (ed): *The Cornea in Health and Disease.* Royal Society of Medicine International Congress and Symposium, series 40. London, Academic Press Inc, 1981, pp 1108-1112.

25 Van Horn DL, Schutten WH, Hyndiuk RA, et al. Xerophthalmia in vitamin A-deficient rabbits Clinical and ultrastructural alterations in the cornea *Invest Ophthalmol Vis Sci* 1980, 19 1067-1079.

26 Dohlman CH, Kalevar V: Cornea in hypovitaminosis A and protein deficiency. *Isr J Med Sci* 1972,8 1179-1183

27. Pirie A Effect of vitamin A deficiency on the cornea *Trans Ophthalmol Soc UK* 1978,98·357-360.

28 Slansky HH, Gnädinger MC, Itoi M, et al Collagenase in corneal ulcerations *Arch Ophthalmol* 1969,82·108-111.

29. Itoi M, Gnadinger MC, Slansky HH, et al Collagenases in the cornea *Exp Eye Res* 1969,8 369-373.

30. Brown SI, Weller CA, Wasserman HE. Collagenolytic activity of alkali-burned corneas *Arch Ophthalmol* 1969,81 370-373

31. Hook RM, Hook CW, Brown SI: Fibroblast collagenase partial purification and characterization *Invest Ophthalmol Vis Sci* 1973,12 771-776.

32. BenEzra D, Tanishima T: Possible regulatory mechanisms of the cornea: I. Epithelial-stromal interaction in vitro *Arch Ophthalmol* 1978,96 1891-1896.

33. Pirie A, Werb Z, Burleigh MC Collagenase and other proteinases in the cornea of the retinol-deficient rat *Br J Nutr* 1975;34:297-311

34 Kenyon KR, Berman M, Rose J, et al: Prevention of stromal ulceration in the alkali-burned rabbit cornea by glued-on contact lens: Evidence for the role of polymorphonuclear leukocytes in collagen degradation *Invest Ophthalmol Vis Sci* 1979,18 570-587

35 Johnson-Muller B, Cross J Regulation of corneal collagenase production· Epithelial-stromal cell interactions *Proc Natl Acad Sci USA* 1978,75:4417-4421.

36 Sweet LK, K'ang HJ· Clinical and anatomic study of avitaminosis A among the Chinese *Am J Dis Child* 1935,50.699-734

37 Wason IM· Ophthalmia associated with a dietary deficiency in fat-soluble vitamin (A): A study of the pathology. *JAMA* 1921,76 908-912

38. Valenton MJ, Rosalita VT: Secondary ocular bacterial infection in hypovitaminosis A xerophthalmia *Am J Ophthalmol* 1975,80 673-677

PROJECT NUMBER:
PROCESS: ACTION: DATES: INITIALS:
CATALOGUE 1656 US
ABSTRACT ARDA
FICHE RANDD
COMMENTS:

Printed and Published in the United States of America