Reprinted from the Archives of Ophthalmology
November 1981, Volume 99
Copyright 1981, American Medical Association

PN-AAK-132
duyel.

Bitot's Spots Responsive and Nonresponsive to Vitamin A

Clinicopathologic Correlations

Alfred Sommer, MD; W. Richard Green, MD; Kenneth R. Kenyon, MD

• Conjunctival biopsy specimens from patients with Bitot's spots responsive and nonresponsive to vitamin A were studied by light and electron microscopy. In both types, the lesions demonstrated keratinization with granular cells, irregular maturation, inflammatory infiltration of the conjunctival substantia propria, and loss of goblet cells. Only in the responsive cases were these changes generalized. Prominent Bitot's spots represented massive accumulations of Gram-positive bacilli and keratin debris. Responsive cases improved histologically within seven days of treatment, and goblet cells began to return within two weeks. These results support our previous suggestions that there is little basis for attempting to differentiate, clinically, between the two types of lesions and that at least some nonresponsive lesions represent a persistent metaplastic change induced during a prior episode of vitamin A deficiency.

(*Arch Ophthalmol* 1981;99:2014-2027)

Accepted for publication Dec 26, 1980.

From the International Center for Epidemiologic and Preventive Ophthalmology, and the Eye Pathology Laboratory, Wilmer Institute, The Johns Hopkins Medical Institutions, Baltimore (Drs Sommer and Green); Helen Keller International, New York, and the Nutritional Blindness Prevention Program, Bandung, Indonesia (Dr Sommer); and the Department of Ophthalmology, Harvard Medical School, the Cornea Service, Massachusetts Eye and Ear Infirmary, and the Cornea Research Department and Morphology Unit, Eye Research Institute of Retina Foundation, Boston (Dr Kenyon).

Read in part before the annual scientific meeting of the Wilmer Residents Association, Baltimore, April 26, 1979.

Reprint requests to Wilmer Institute, The Johns Hopkins Hospital, 600 N Wolfe St, Baltimore, MD 21205 (Dr Sommer).

The cause and importance of Bitot's spots have been a major source of controversy, impeding development of comprehensive xerophthalmia assessment and screening programs.[1-6] Recently published clinical data help reconcile earlier observations by suggesting that typically dry, nonwettable conjunctival xerosis and Bitot's spots of all varieties represent one and the same process. Most of these lesions, especially those in preschool-age children, those located on both sides of the cornea, and those accompanied by night blindness, are associated with an active vitamin A deficiency and respond to its administration. Vitamin-A-nonresponsive lesions probably are sequelae of past xerophthalmia.[7,8]

The last, and potentially most important, inference was based, in large part, on three sets of observations: the identical clinical appearance of responsive and nonresponsive lesions, their joint predilection for the temporal quadrant, and the observation of classic lesions that were rapidly, but only partially, responsive to vitamin A therapy. Further confirmation of this hypothesis awaits careful clinicopathologic correlation of responsive and nonresponsive lesions in otherwise normal eyes. We report such data herein.

PATIENTS AND METHODS

As previously described,[7,8] 83 consecutive cases of conjunctival xerosis and Bitot's spots with clear corneas on hand-light examination were studied. Medical, socioeconomic, and dietary histories were collected from the accompanying parent or guardian. Each patient underwent a careful ophthalmologic and pediatric examination and had blood drawn for biochemical analysis, and height and weight were recorded.

Conjunctival biopsy specimens were collected on a subsample of patients representing the different clinical conditions. After receiving informed consent from their parent or guardian, 1 drop of proparacaine hydrochloride was applied to the inferior cul-de-sac (children younger than 6 years) or 0.5 mL of lidocaine hydrochloride (2%) was injected subconjunctivally for local anesthesia. Using strict, sterile techniques, 4 × 3-mm conjunctival biopsy specimens were taken from the involved area adjacent to the temporal (and occasionally nasal) limbus and, in many instances, the seemingly normal inferonasal quadrant also. Excised conjunctiva was gently spread by its edges, epithelial surface up, on a firm piece of paper and immersed in Karnovsky's 4% formaldehyde-1% glutaraldehyde fixative.

The eye was dressed with gentamicin sulfate, bacitracin and polymixin B sulfate ointments, patched, and examined on successive days until healing was complete (usually within two to three days). In one instance, a small temporal abscess formed, which responded to intensive topical and systemic antibiotic treatment. In some cases, additional biopsy specimens were obtained, usually from the opposite equally involved eye at varying intervals after vitamin A therapy.

All children received an oral dose of 200,000 IU of vitamin A in oil and were requested to return on three successive days, then weekly for the first month and monthly thereafter. If their lesions failed to respond by one month, they received at least one additional dose. Those lesions still failing to respond by the end of the third month were considered "nonresponsive." "Responsive" cases included all patients whose lesions either cleared completely ("cured") or regressed dramatically ("improved") within two months (in most instances within one to two weeks).[8] All

Table 1.—Histopathologic Findings* From Pretreatment Conjunctival Biopsy Specimens From Responsive Cases and Controls

Case and Eye	Clinical Lesion†	Keratin‡	Granular Layer	Surface Bacteria	Goblet Cells	Subepithelial Inflammatory Infiltrate	Organization of Basal Layer	Epithelial Thickness	Cell Size	Prominence of Nucleoli
					Temporal					
1	B	2	1.5	0	0	0	2.5	34	1	1
2	B	2	3	1.5	0	0	3	24	0.5	0.5
3	A	3	1.5	0	0	0	3	23	0.5	0.5
4	B	0	0	0	0	0.5	2.5	15	0.5	0.5
5	B	2	3	0	0	1	4	18	0	0
6	B	3	3	3.5	0	0.5	3.5	25	0.5	0.5
7	B	2	3	1.5	0	0	4	33	0.5	0.5
8	B	2	3	1.5	0	0	3	25	1.5	1.5
9	+/−	0	0	0	0	0	4	25	0	0
10	0	0	0	0	0	0	4	16	0	0
					Nasal					
5	B	3	3	0	0	1	4	24	0	0
9	0	0	0	0	0	0	4	12	0	0
					Inferonasal					
2	0	0.5	0	0	0	0	4	15	0	0
3	0	0.5	0	0	0	0	3	17	0.5	0.5
5	0	0	0	0	0	0	4	24	0	0
6	0	0.5	0	0	0	0.5	3	13	0.5	0.5
7	B	2	2.5	1.5	0	1.5	4	25	0.5	0.5
8	0	0	0	0	0	1	3.5	23	0.5	0.5
10	0	0	0	0	15/5§	0	4	13	0	0

*See text for scoring.
†A indicates pure conjunctival xerosis; B, "foamy" Bitot's spot; and + /−, a few tiny isolated epithelial "bubbles."
‡Temporal lesion, case 4, and inferonasal biopsy, case 8, lacked keratin but had a thickened layer of flattened cells at the surface.
§The numerator is the total number of goblot cells observed. The denominator is the number of high-power fields surveyed.

clinical examinations were carried out by the same ophthalmologist and pediatrician.

Biopsy specimens were maintained in fixative and refrigerated until arrival at the pathology laboratory, where each specimen was divided for light and electron microscopy. Those for light microscopy were routinely processed and the following staining techniques employed: hematoxylin-eosin stain for overall structure and architecture, Dane's stain for keratin and goblet cells, PAS stain for goblet cells, and Brown and Hobbs stain for bacteria. Nine factors were assessed: degree of keratinization, graded 0 to 4; number of granular cell layers; presence of intrakeratin bacteria, graded 0 to 4; number of goblet cells per high-power field; presence of inflammatory infiltrate in the conjunctival substantia propria, graded 0 to 4; delineation of the basal layers (4, indicating normal architecture; 1, complete disorganization); increase in size of the cells, graded 0 to 2; increased prominence of their nucleoli, graded 0 to 2; and relative thickness of the epithelium, from the surface to the base of the basal layer, measured with an eyepiece reticule under a 40-power lens (where keratinization was extremely thick, the keratin and remaining fractions were measured separately). All histologic sections were reviewed by one of us (W.R.G.). Statistical analyses used the Student's *t* test.

Specimens designated for ultrastructural examination were additionally divided. For transmission electron microscopy, osmium tetroxide postfixation, dehydration in graded alcohols, and embedding in an epoxy resin were followed by semithin sectioning and paraphenylenediamine staining for orientation and phase-contrast photomicrography. Thin sections of representative areas were doubly stained and examined on transmission electron microscopes. For scanning electron microscopy, osmication and dehydration were followed by critical-point drying and gold-platinum sputter coating. The epithelial surfaces of these specimens were examined, using a scanning electron microscope.

RESULTS

Pretreatment Responsive Cases and Controls

Pretreatment temporal biopsy specimens were available from eight subjects (cases 1 through 8) who eventually responded to therapy (Table 1). Patients 1 and 2 eventually improved, and patients 3 through 8 were cured. A biopsy of nasal lesion in case 5 also was done.

Two additional cases are listed. The first (case 9) was of questionable diagnosis and indeterminate response. There were only two to four small, superficial "bubbles" temporally and normal-appearing conjunctiva nasally on presentation. Response to therapy was equivocal, but both eyes had classic Bitot's spots develop ten months later. Presumably, this pretreatment biopsy specimen represents a high-risk case, with either mild early involvement or old healed disease, and biopsies were done on both the temporal and nasal areas. The other patient (10) was seen initially with normal conjunctiva and night blindness. He was treated with 200,000 IU of vitamin A, and a biopsy of his eye was done two months later. Definitive examination eventually disclosed retinitis pigmentosa. The serum vitamin A level, even on admission, was 28 μg/dL (normal). His specimens are therefore included as normal controls.

All pretreatment responsive lesions had notable pathologic changes, especially when compared with the equivocal and control cases (Fig 1). Keratinization was seen in every lesion but one (Fig 2 through 5). Loss of microvillus projections from the plasma membrane of superficial epithelial cells was especially evident by electron microscopy (Fig 2). In the one exception (case 4, Fig 6), there was the same thickened superficial layer of flattened cells as in the keratinized cases. This was also the only lesion lacking a granular cell layer, composed of basophilically stippled cells located between the keratin and wing-cell layers, which was prominent in all the others (Fig 2 through 5).

Surface and intrakeratin bacteria, almost always Gram-positive bacilli, were present in four of the eight temporal lesions, usually as a light scattering, but occasionally in focal clumps (Fig 2).

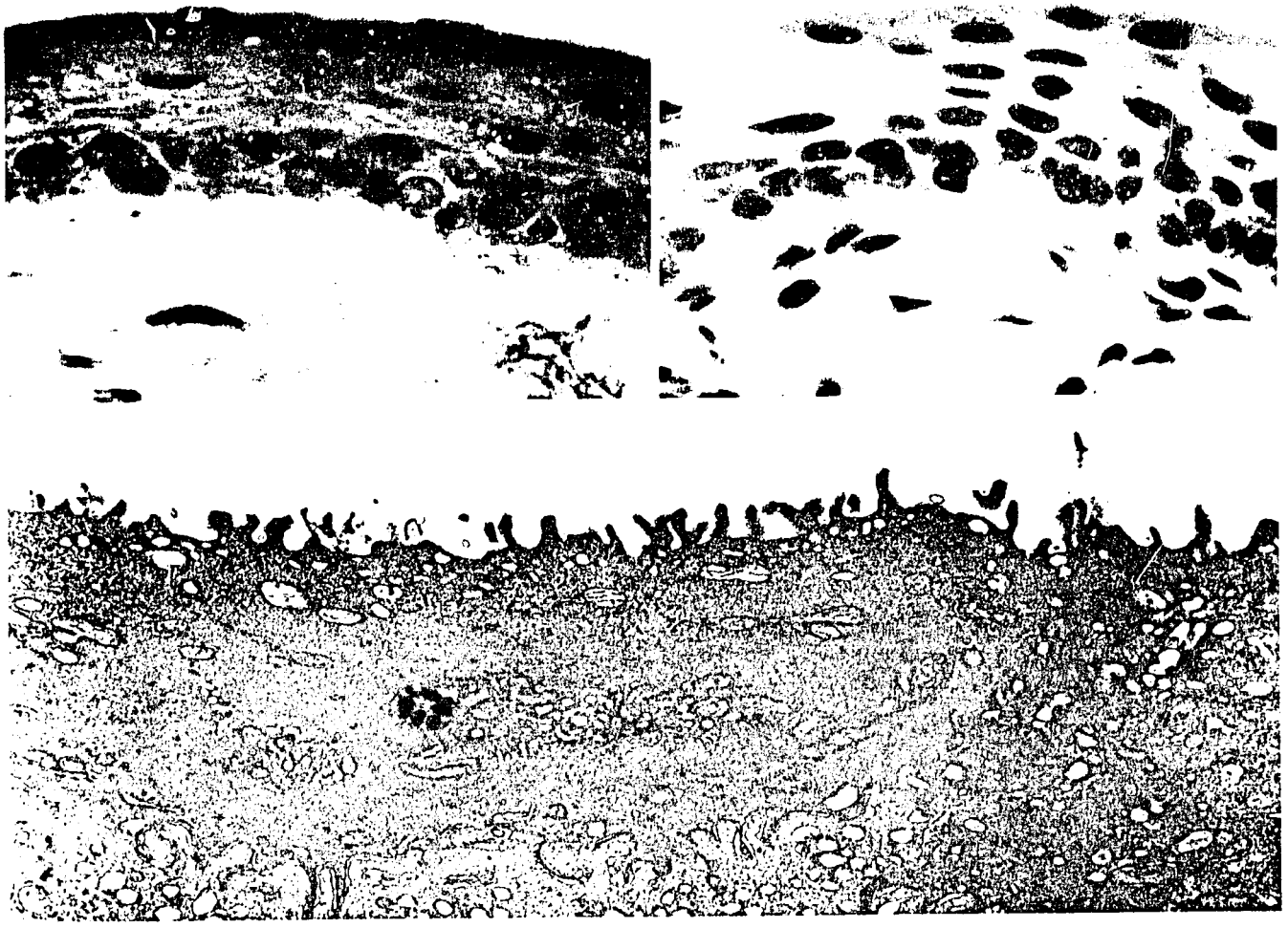

Fig 1.—Case 10. Eleven-year-old boy with clinically normal conjunctiva and normal serum vitamin A levels. Top left, Light microscopy of conjunctiva from area adjacent to temporal limbus is normal with respect to nonkeratinizing stratified squamous epithelium of five to eight cell layers and underlying stroma without inflammatory cell infiltrate (Brown and Hobbs stain, magnification ×825). Top right, Light microscopy of conjunctiva from inferonasal quadrant shows normal complement of goblet cells (at extreme left and right; hematoxylin-eosin, magnification ×825). Bottom, Transmission electron microscopy of inferonasal bulbar conjunctiva shows epithelial cell-free surface to have numerous microvillus projections of plasma membrane and cytoplasm devoid of keratohyaline granules (×16,700).

Parakeratosis was not conspicuous, although acanthotic thickening of the epithelial layers was common. This was accompanied by a somewhat irregular maturational sequence, with mild to moderate disorganization of the basal layer in six cases and larger cells and nuclei with prominent nucleoli in seven cases (Fig 2 through 6).

A mild chronic inflammatory cell infiltrate was present in the substantia propria of three cases (Fig 6).

Goblet cells were not detected in any of the sections, including those from the equivocal and control cases.

Pretreatment biopsy specimens from the inferonasal quadrant, the area said to contain the greatest concentration of goblet cells in the normal eye,[7] were available from six responsive patients and the normal control. While the area adjacent to the nasal limbus was clinically abnormal in four cases, the inferonasal quadrant itself had appeared normal in all but one (case 7). In the latter instance, the whole of the conjunctiva was xerotic. Except for that single advanced case (Fig 4), changes in the inferonasal areas were milder than their temporal counterparts, with only minimal keratinization, thinner epithelium, and absence of granular cells and intrakeratin bacteria (compare Fig 2 and 5). However, goblet cells, abundant in the normal control (Fig 1), were absent.

Posttreatment Responsive Cases

Temporal biopsy specimens were obtained from the opposite eye of three responsive patients seven days after treatment (Table 2). Before therapy, two patients (cases 1 and 4) had had foamy Bitot's spots in that location, and the other (case 3) had a large xerotic patch. At the time of the posttreatment biopsy, all had improved clinically: case 1 had only a small patch of xerosis, case 3 had a few isolated superficial bubbles, and case 4 looked entirely normal. In comparison with the pretreatment biopsy specimen of the other eye, the keratin and granular cell layers had disappeared in two cases, with return of surface microvilli (Fig 3 and 7), whereas in the other (case 4), a thin keratin and granular cell layer appeared, possibly reflecting a difference in sampling or initial histopathologic changes in the two eyes (Fig 6). The basal layers were better organized, the size of the cells and prominence of their nucleoli were reduced, and the epithelium thinner in

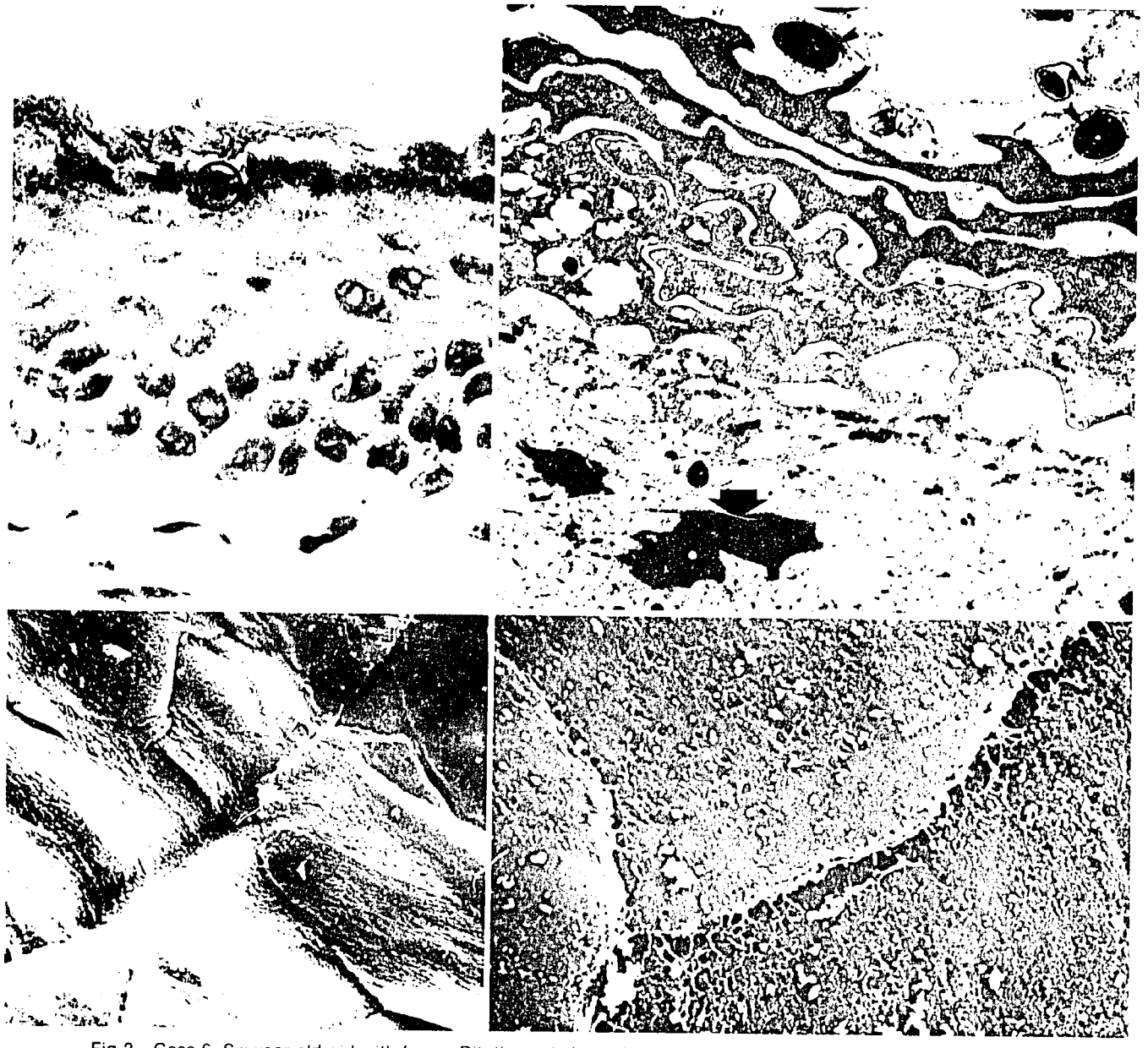

Fig 2.—Case 6. Six-year-old girl with foamy Bitot's spots in each eye. Pretreatment biopsy specimen of temporal conjunctiva (right eye). Top left, By light microscopy, heavily keratinized surface overlies prominent granular cell layer. Keratohyaline granules (circled) are most numerous in superficial cells. There is moderate disorganization of basal layer with irregular maturational sequence of enlarged cells with prominent nuclei (hematoxylin-eosin, magnification ×825). Top right, Transmission electron microscopy resolves bacterial forms (small arrowheads) adherent to notably keratinized superficial cells with underlying cells containing large keratohyaline granules (large arrow) (×16,700). Bottom left, Scanning electron microscopy of conjunctival surface showed several desquamating keratinized epithelial cells (×2,000). Bottom right, Higher-magnification scanning electron microscopy of three adjacent superficial cells resolves adherent debris (possibly bacterial) with absence of surface microvilli (×5,500).

two cases. Later temporal biopsy specimens, obtained 14 days to four months after treatment (three from patients with and two from cases without pretreatment specimens), were all normal (Fig 2 and 6). Goblet cells were present in only a single specimen, obtained at two months.

Inferonasal biopsy specimens were obtained seven days to three months after treatment from two patients with and three without pretreatment specimens. Only the specimen from day 7 was still abnormal, with a thin keratinized layer and minimal disorganization of the basal layer. Goblet cells, abundant in three specimens, first appeared at 14 days (Fig 5).

Nonresponsive Cases

To ensure that these were completely nonresponsive, biopsy specimens were taken only after repeated treatment had failed to have any effect during a two- to seven-month period. Temporal specimens were obtained from eight eyes (cases 13 through 20) of five patients, and a nasal specimen was obtained from a large inferonasal biopsy that extended to the limbus in one (Table 3).

Eye 19, the fellow eye of a patient with a unilateral Bitot's spot, was clinically and histologically normal.

In three eyes (cases 13, 17, and 18), a thick, frayed mass of keratin, intermixed with bacteria, overlay the epithelial surface. In two of these (cases 17 and 18), both with thick "cheesy"

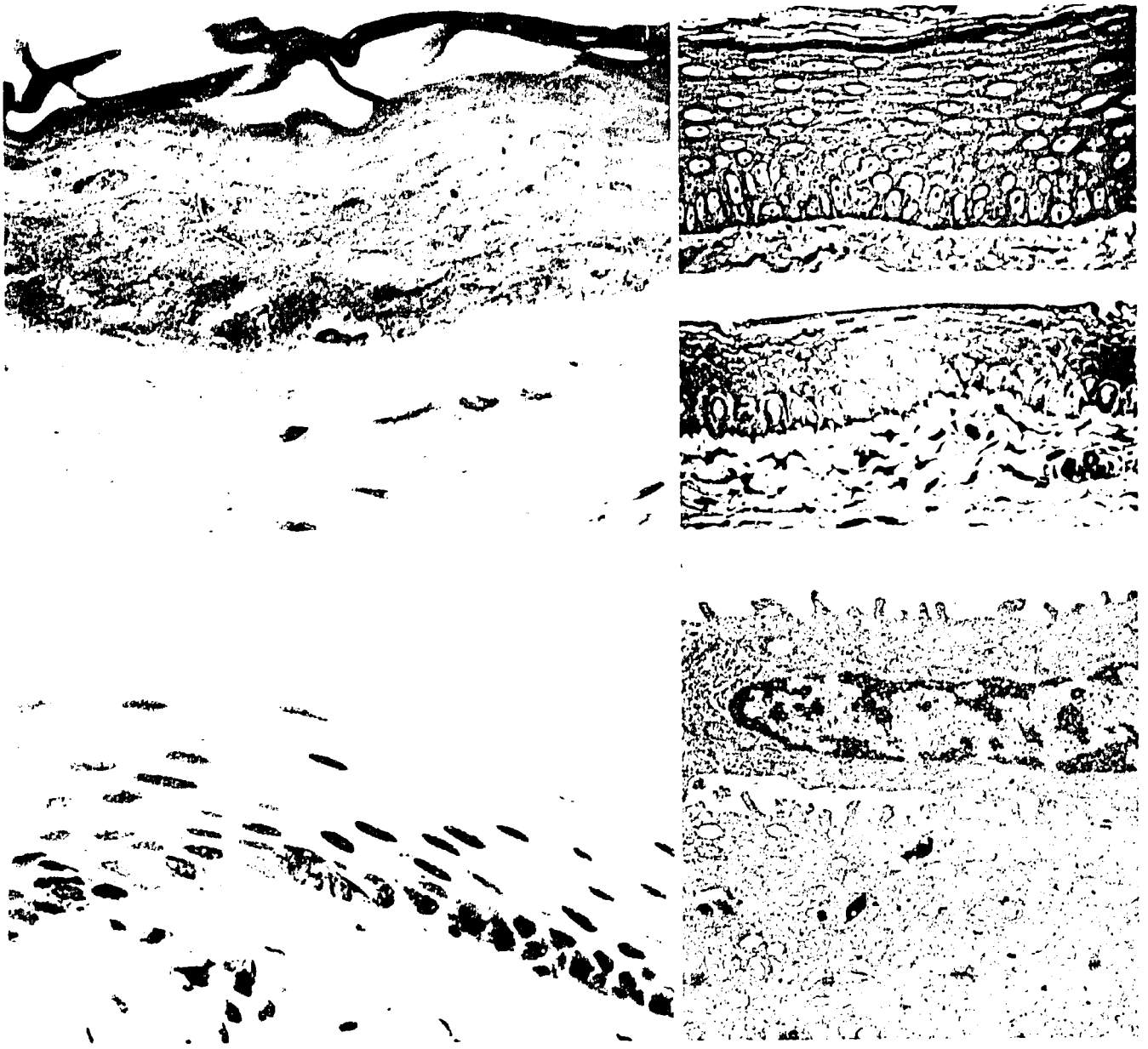

Fig 3 —Case 3 Seven-year-old boy with temporal areas of conjunctival xerosis in both eyes Top left By light microscopy pretreatment temporal biopsy specimen (right eye) has prominently keratinized surface (Dane's stain, magnification ×825) Top right Phase-contrast microscopy of same area resolves surface keratinization, keratohyaline granules acanthosis and dyskeratosis (paraphenylenediamine magnification ×750) Bottom left Biopsy specimen of temporal conjunctiva (left eye) seven days after vitamin A therapy appears normal by light microscopy (hematoxylin-eosin magnification ×825) Center right Phase-contrast photomicrograph of same area is confirmatory and additionally shows decrease in epithelial thickness (compare with top right paraphenylenediamine magnification ×750) Bottom right Transmission electron microscopy of same area illustrates partial return of surface membrane infoldings and microvillae (×16,700)

Fig 4 —Case 7 One-year-old boy with severe conjunctival xerosis involving all of conjunctiva for 360 Foamy Bitot's spots were present temporally in both eyes Left Pretreatment temporal conjunctival biopsy specimen (right eye) examined by light microscopy shows prominent keratin and granular cell layers (hematoxylin-eosin, magnification ×825) Right Phase-contrast microscopy of inferonasal conjunctiva from same eye shows keratin and granular cell layers to be as prominent as those of temporal quadrant with absence of goblet cells (paraphenylenediamine, magnification ×500)

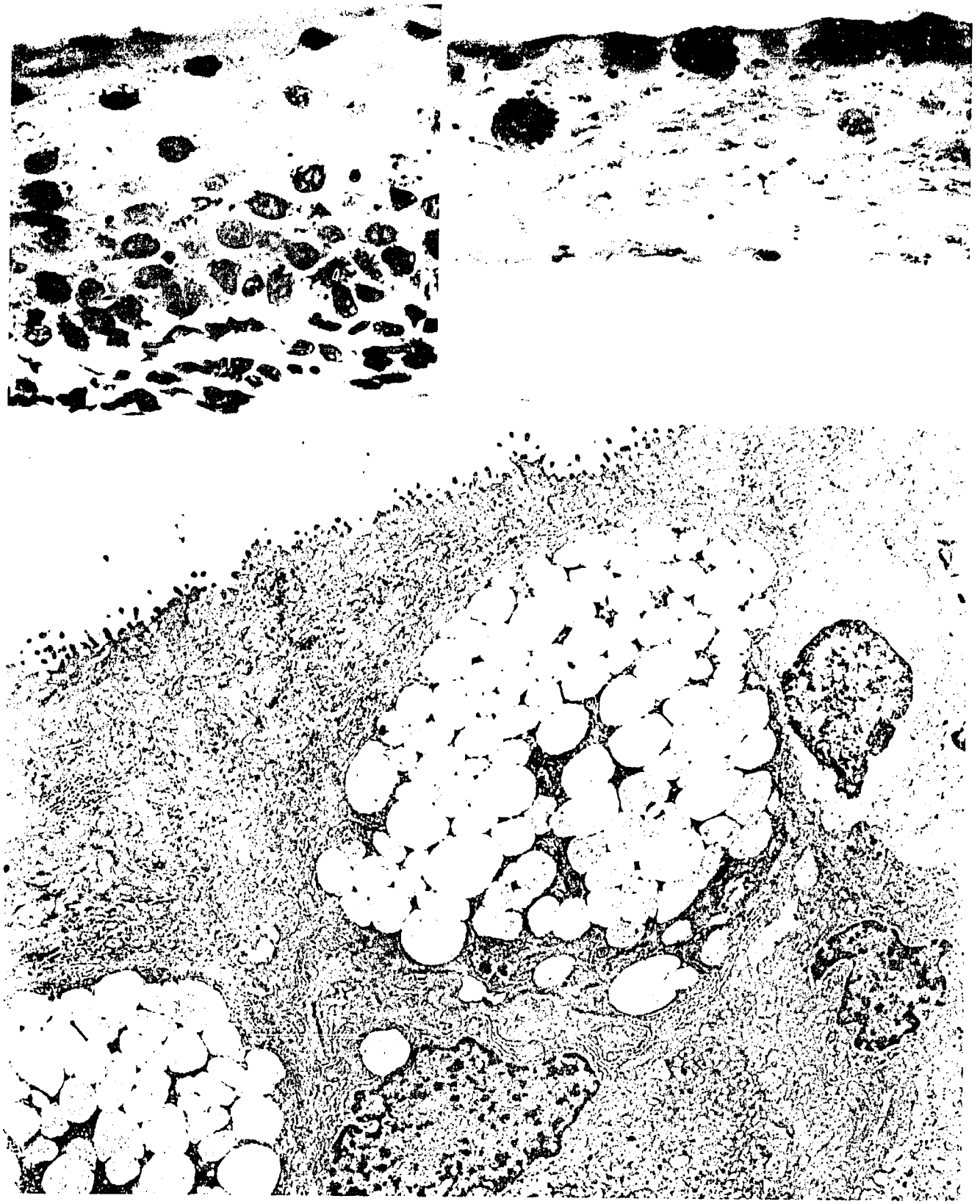

Fig 5.—Case 6. Six-year-old girl with foamy Bitot's spots temporally and xerosis nasally in each eye. Top left, Pretreatment conjunctival biopsy specimen from inferonasal quadrant (right eye) has light microscopic features of typical keratinizing metaplasia: keratinized surface, disorganization of basal layer, and irregular maturational sequence (Brown and Hobbs stain, magnification ×825). Compare with more severe changes evident in temporal quadrant of same eye (Fig 2, top left). Top right, Light micrograph of inferonasal conjunctiva (left eye), on which biopsy was done 14 days after vitamin A therapy, includes numerous goblet cells (Dane's stain, magnification ×825). Note that goblet cells were not apparent in temporal conjunctival biopsy specimen obtained at same time (compare with Fig 2, top left). Bottom, Transmission electron microscopy of same specimen confirms presence of several ultrastructurally normal goblet cells and usual complement of surface microvilli (×8,000).

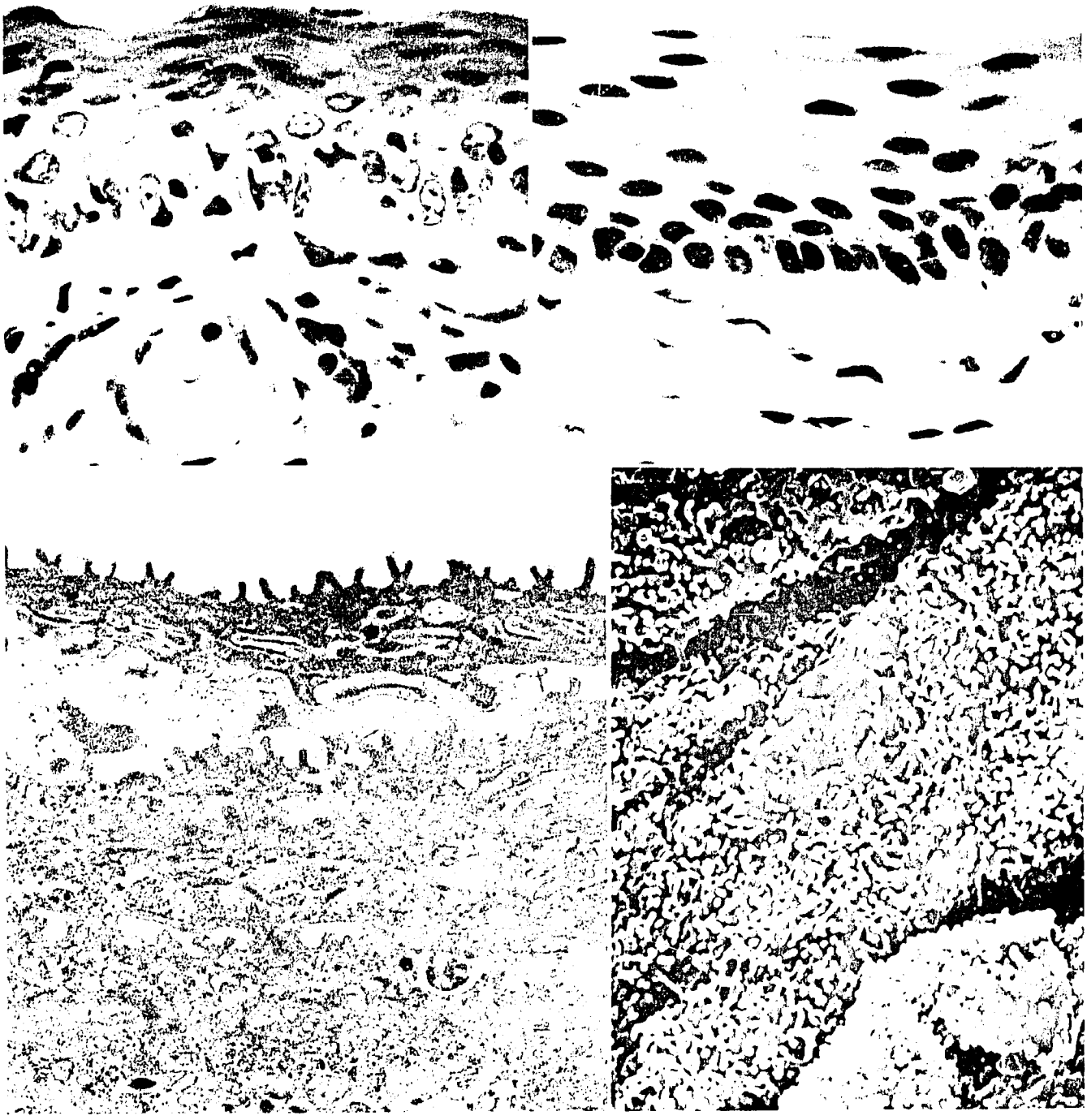

Fig 6.—Case 4. Two-year-old girl with foamy Bitot's spots in temporal quadrant of each eye. Top left, Pretreatment temporal conjunctival biopsy specimen (left eye) shows, by light microscopy, thickened superficial layer of flattened cells in absence of frank keratinization or granular cell layer. Stri.ing disruption of basal layer and mild chronic inflammatory infiltration of stroma are present (hematoxylin-eosin [HE], magnification ×825). Top right, Light microscopy of temporal conjunctival biopsy specimen (right eye) four months after vitamin A therapy appears entirely normal (HE, magnification ×825). Bottom left, Transmission electron microscopy of same specimen (four months after therapy) illustrates normal cell membrane surface specializations and absence of intracytoplasmic keratohyaline material (×16,700). Bottom right, Scanning electron microscopy of same specimen exhibits innumerable cell surface microvilli (×10,000).

lesions, this reached large proportions, with bacteria preponderating (Fig 8 and 9). Gram-positive bacilli were present in both. The specimen from eye 17 contained Gram-negative cocci also. Budding yeast forms were present in eye 13.

Differences in the histologic appearance of nonresponsive and pretreatment responsive lesions were minor: the magnitude of the subepithelial inflammatory infiltrate and concentration of surface bacteria was greater in the former, whereas nucleoli were more prominent and cells larger in the latter ($P < .05$, Table 4).

Nonresponsive and pretreatment responsive lesions differed in one other respect. Pathologic changes in pretreatment responsive lesions tapered

Table 2.—Histopathologic Findings* From Posttreatment Conjunctival Biopsy Specimens From Responsive Cases

Case and Eye†	Clinical Lesion‡	Interval Since Therapy	Keratin	Granular Layer	Surface Bacteria	Goblet Cells§	Subepithelial Inflammatory Infiltrate	Organization of Basal Layer	Epithelial Thickness	Cell Size	Prominence of Nucleoli
						Temporal					
1	B/A	7 days	(0)	(0)	0	0	0	(3.5)	(24)	(0.5)	(0.5)
3	A/+/−	7 days	(0)	(0)	0	0	0	3.0	(18)	0.5	0.5
4	B/0	7 days	0.5	0.5	0	0	(0)	(4)	17	(0)	(0)
	B/0	2 mo	(0)	0	0	(3/5)	(0)	(4)	23	(0)	(0)
	B/0	4 mo	(0)	0	0	0	(0)	(4)	17	(0)	(0)
6	B/+/−	14 days	(0)	(0)	(0)	0	(0)	3.5	(17)	(0)	(0)
11	B/0	1 mo	0	0	0	0	0	4	16	0	0
12	B/0	3 mo	0	0	0	0	0.5	4	15	0	0
						Inferonasal					
3	0/0	7 days	0.5	0	0	0	0	3.5	18	0.5	0.5
4	0/0	2 mo	0	0	0	2/5	0	4	16	0	0
6	0/0	14 days	(0)	0	0	(4/1)	0	(4)	14	(0)	(0)
11	0/0	1 mo	0	0	0	0	0	4	13	0	0
12	0/0	3 mo	0	0	0	35/7	1.5	4	16	0	0

*See text for scoring. Parentheses indicate improvement over pretreatment biopsy, where available.
†All posttreatment biopsy specimens are from the opposite eye that underwent biopsy before treatment.
‡Pretreatment appearance of lesion/appearance at time of posttreatment biopsy. A indicates conjunctival xerosis; B, "foamy" Bitot's spot; and +/−, a few tiny isolated epithelial "bubbles."
§The numerator is the total number of goblet cells observed. The denominator is the number of high-power fields surveyed.

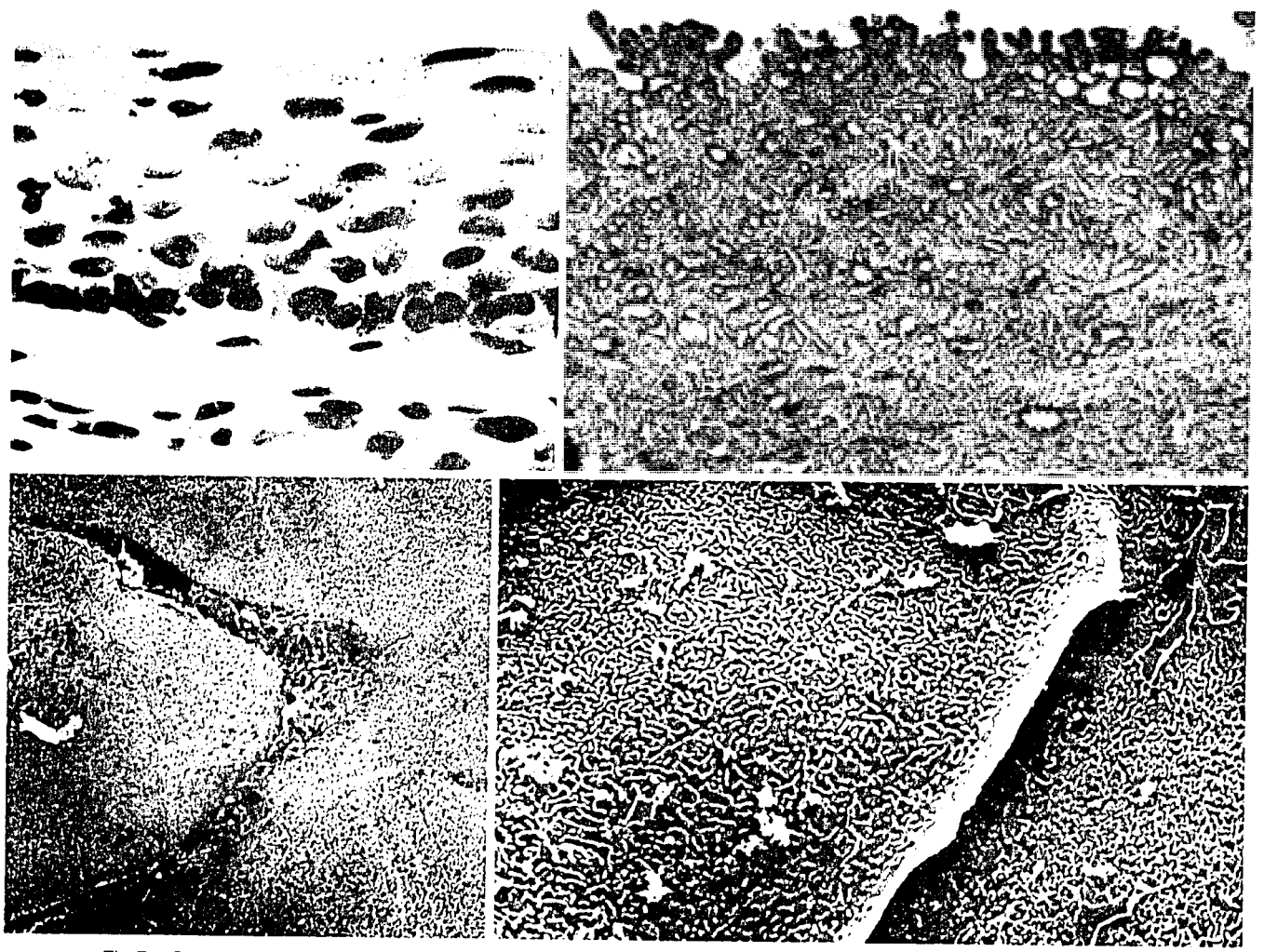

Fig 7.—Case 6. Six-year-old girl with foamy Bitot's spots in each eye. Biopsy of temporal conjunctiva (left eye) was done 14 days after vitamin A therapy. Top left, Light microscopic appearance of conjunctival epithelium and stroma is normal (hematoxylin-eosin, original magnification ×825). Top right, Transmission electron microscopy of corresponding area shows return of extensive surface microvilli (×16,700). Bottom left and right, Scanning electron microscopy of surface confirms presence of normal-appearing microvilli and microplicae (left, ×2,000; right, ×5,000).

Table 3.—Histopathologic Findings* From Conjunctival Biopsy Specimens From Nonresponsive Cases

Case/Eye	Clinical Lesion†	Keratin‡	Granular Layer	Surface Bacteria‡	Goblet Cells§	Subepithelial Inflammatory Infiltrate	Organization of Basal Layer	Epithelial Thickness‡	Cell Size	Prominence of Nucleoli
					Temporal					
13/13	B	4	2	4.	0	1.5	3	20	0	0
14/14	B	1	2	1.5	0	0	3.5	22	0.5	0.5
15	B	2	0.5	1.5	0	0.5	3	40	0.5	0.5
15/16	C	2	3	2.5	0	0.5	3	25	0	0
17	C	4	3	4	0	1.5	3	35	0	0
16/18	C	4	3	4	0	1.5	3	30	0	0
19	0	0	0	0	0	0	4	25	0	0
17/20	B	2.5	2.5	1.0	0	2	3	30	0.5	0.5
					Nasal					
15/16	B	1	3	3	0	0.5	4	27	0	0
					Inferonasal					
13/13	0	0	0	0	46/5	0	4	20	0	0
14/14	0	0	0	0	15/5	0	4	15	0	0
15	0	0	0	0	4/4	0	4	12	0	0
15/16	B	0	0	0	22/7	0	4	26	0	0
17	0	0	0	0	7/3	0.5	4	21	0	0
17/20	0	0	0	0	20/5	0.5	4	18	0	0

*See text for scoring.
†B indicates "foamy" Bitot's spot; and C, "cheesy" Bitot's spot.
‡Eyes 13, 17, and 18 contained a thick, frayed mass of keratin and bacteria on the surface. Epithelial thickness was measured from the intact keratin surface to the base of the basal layer.
§The numerator is the total number of goblet cells observed. The denominator is the number of high-power fields.

off gradually, merging imperceptibly with less abnormal, surrounding conjunctiva. In nonresponsive lesions, the transition between abnormal and surrounding normal conjunctiva was strikingly abrupt (Fig 10).

Inferonasal biopsy specimens were available from six of the nonresponsive eyes (Table 3). In contrast with their pretreatment responsive counterparts, they were normal in every regard. Most notably, surface microvilli and goblet cells were abundant in all (Fig 11). In only two cases was a mild chronic inflammatory infiltrate present (Fig 10).

COMMENT

The histopathology of true vitamin-A-related conjunctival xerosis was described in rats more than 50 years ago. Mori[10] characterized the early changes as cornification of the surface, formation of keratohyaline granules in cells below the cornified layer, and thickening of the epithelium. He also noted that these changes began near the limbus, spreading from there to the rest of the conjunctiva and that, in the absence of ulceration, bacteria did not penetrate below the surface of the conjunctiva or cornea.

Wolbach and Howe[11] were the first to call attention to the widespread nature of the keratinizing metaplasia induced by vitamin A deficiency. Using the respiratory tract of the rat as a model, they demonstrated that the process was multifocal, with new islands of stratified epithelium undermining adjacent areas of otherwise viable columnar epithelium and separating them from their original mesenchymal support. Those investigators agreed with Mori that the primary change, in both conjunctiva and cornea, was keratinization, with goblet cells persisting for a time after this first occurs. In late states they noted a slow, slight, irregular downgrowth of the basal cells and the accumulation of mononuclear cells and lymphocytes in the conjunctival substantia propria.

In a recent report, Pfister and Renner[12] confirmed those observations in the guinea pig. Using light and scanning electron microscopy, they demonstrated complete absence of goblet cells and presence of many surface spherules and rods, presumed to be bacteria. In one animal, the earliest killed, scanning electron microscopic changes consistent with corneal keratinization were already apparent in the presence of a normal complement of goblet cells.

Understandably, conjunctival histopathologic studies in human xerophthalmia have been much more limited, only occasionally including eyes without severe corneal involvement. The first detailed description of pure conjunctival xerosis in the presence of night blindness was provided by Leber[13] almost 100 years ago, long before vitamin A was discovered. He described hyperplasia of the conjunctiva and notable flattening and keratinization of the superficial layers. He also noted large numbers of bacilli, which later elicited much interest as the "xerosis bacillus."[14] Mayou,[15] studying six cases of what must have been true vitamin-A-responsive Bitot's spots, noted that xerosis bacilli, and other organisms, adhered in large quantities to the surface but were not found in or between epithelial cells or deeper tissues. The epithelium itself was thickened, keratinized, and lacked goblet cells, but it did contain a well-marked layer of granular cells. Inflammatory cells were present in the conjunctival substantia propria.

Less detailed reports described keratinization in 14 of 15 cases of Bitot's spot[16] and keratinization with loss of goblet cells in 16 of 17 severely affected eyes with corneal involvement.[17]

Histopathologic changes observed in pretreatment biopsy specimens from our responsive cases conform perfectly to those earlier reports and our previous description of a case of extensive conjunctival and corneal xerosis.[18] Keratinization, flattening of the surface cells, formation of a granular cell layer, the presence of surface bacteria (mainly classic xerosis bacilli) without deeper penetration, thickening of the epithelium, inflammatory infiltration of the substantia propria, and complete absence of goblet cells all have been noted previously. A finding to which we perhaps bring added attention is the loss of definition of the basal layer, accompanied by enlarged cells and nuclei with promi-

9

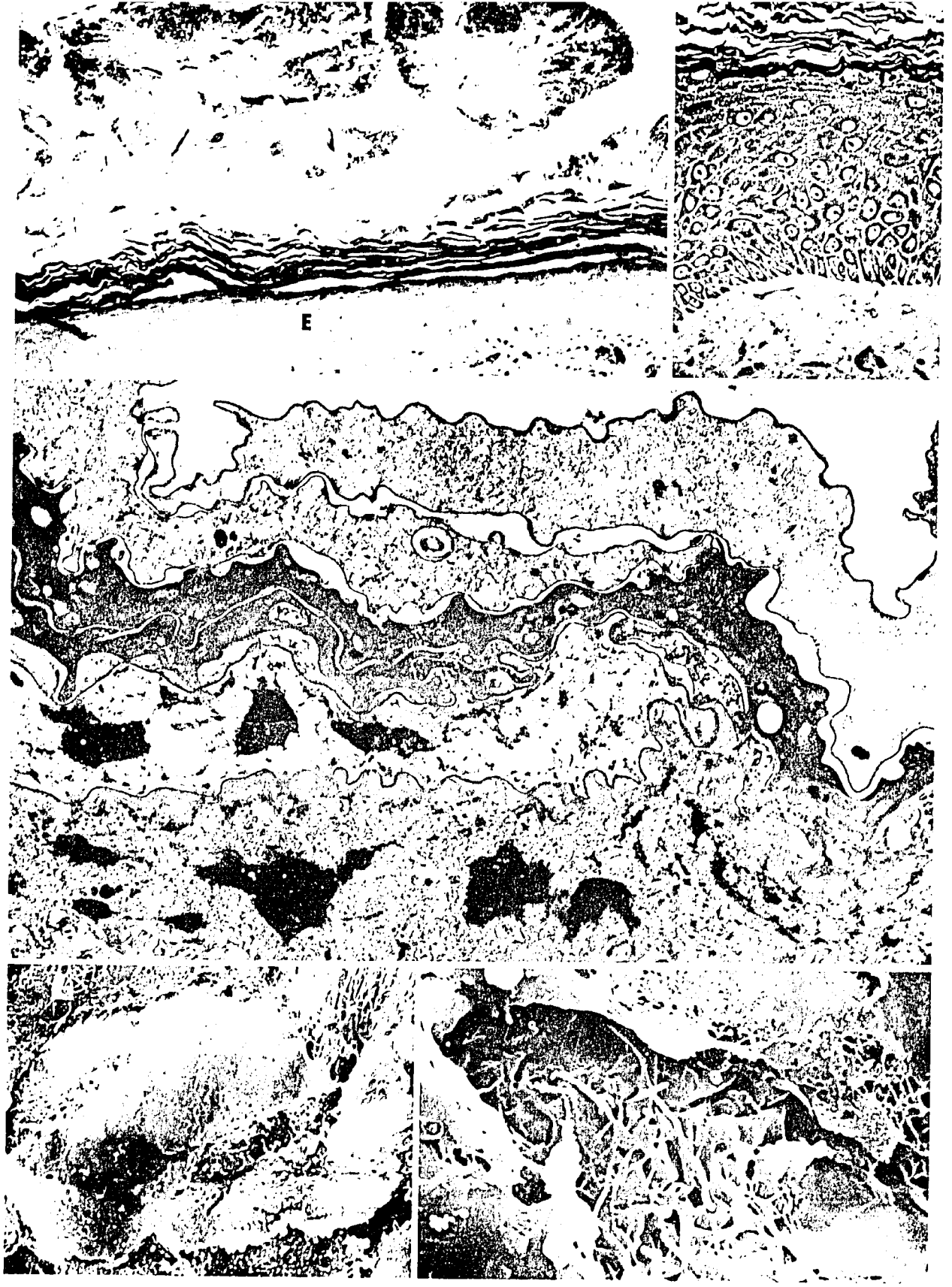

Fig 8.—Case 15. Twenty-year-old man with prominent "cheesy" Bitot's spots that were nonresponsive to vitamin A therapy. Top left, Temporal conjunctiva (left eye) by light microscopy shows large plaque of material overlying the keratinized surface (Dane's stain, magnification ×125). Top right, By phase-contrast microscopy, extensive surface keratinization, keratohyaline granule formation, and acanthosis are seen in same specimen (paraphenylenediamine, magnification ×750). Center, Transmission electron microscopy of this biopsy specimen confirms presence of extensively keratinized superficial cells containing large keratohyaline granules (×13,500). Bottom left, Low-magnification scanning electron microscopy of adherent keratinized debris in this specimen shows multiple laminations of devitalized cellular remnants (×2,000). Bottom right, At higher magnification, scanning electron microscopy resolves amorphous cellular material and coarse fibrillary substance (×10,000).

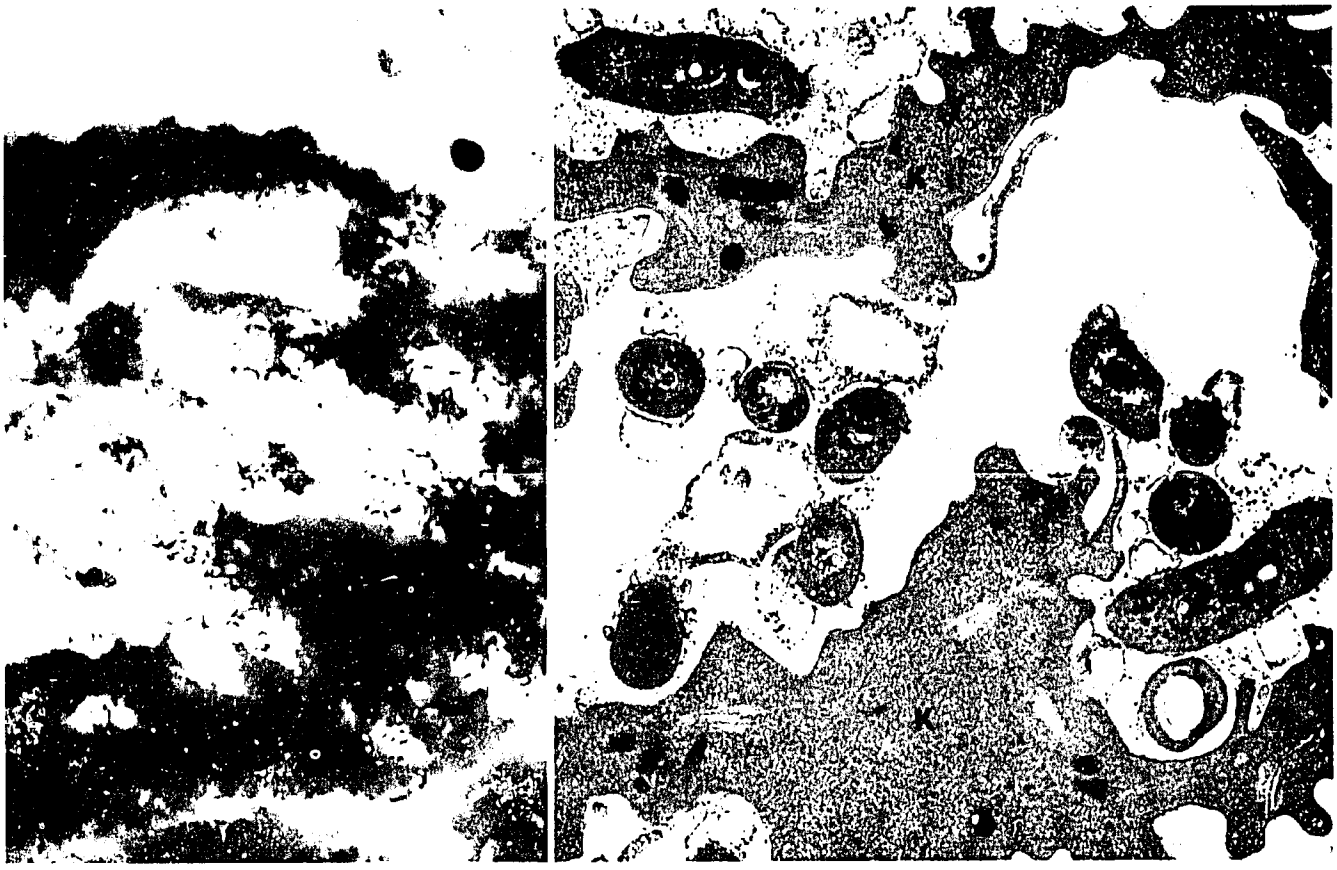

Fig 9.—Case 15. Twenty-year-old man with prominent "cheesy" Bitot's spots that were nonresponsive to vitamin A therapy. Left, Higher-magnification light microscopy of temporal conjunctiva shown in Fig 8 resolves composition of adherent superficial material to be, in large part, massive accumulation of Gram-positive bacilli (Brown and Hobbs stain, magnification ×1,300). Right, Transmission electron microscopy of this tissue shows numerous bacterial profiles interspersed among keratinized squames (K) (×24,000).

nent nucleoli in a somewhat irregular maturational sequence. In no cases did we note formation of rete pegs, as described in the guinea pig[12] and in a single human case of keratomalacia.[19]

Corresponding pretreatment biopsy specimens from patients with clinically normal inferonasal quadrants showed the same changes as the lesions themselves, although to a milder degree. Especially interesting was the complete absence of goblet cells, since this is an area of the conjunctiva in which these cells usually are found in abundance.[9] This same observation was made by Sullivan et al[20] about two alcoholic patients with corneal ulcers and in our earlier report[15] of isolated vitamin A deficiency in an otherwise healthy 22-year-old woman.

Sauter[21] reported that goblet cells also are rare or absent in African children with conjunctival xerosis. However, unlike our patients, their epithelium was extremely thin and atrophic, a change that was said to persist after treatment and clinical cure.

More enlightening were the findings in our nonresponsive cases. The histopathologic changes in the lesions themselves were essentially identical to those of the active vitamin-A-responsive variety. Minor differences, eg, the greater degree of subepithelial inflammatory infiltration and higher concentration of surface bacteria (including budding yeast forms in one case), among nonresponsive lesions may simply reflect their great chronicity. One other difference was probably of greater importance. Among nonresponsive cases, the pathologic process was sharply limited to the area of the lesion itself; the transition between abnormal and surrounding normal conjunctiva was abrupt, and biopsy specimens of the inferonasal quadrant disclosed perfectly normal epithelium with abundant goblet cells. The lesions were just as localized, clinically, in responsive eyes. However, the histopathologic changes were generalized, apparently affecting all of the conjunctiva; notably keratinized

Table 4.—Mean Histopathologic Alterations in Conjunctival Biopsy Specimens of Responsive and Nonresponsive Temporal Lesions

	Responsive (n = 8)		Nonresponsive (n = 7)	
	Mean*	SE	Mean*	SE
Keratinization	2.0	0.33	2.8	0.46
Granular layer	2.3	0.40	2.3	0.34
Surface bacteria†	1.0	0.44	2.6	0.51
Subepithelial inflammatory infiltrate†	0.3	0.13	1.1	0.28
Organization of basal layer	3.2	0.21	3.1	0.07
Cell size†	0.6	0.16	0.2	0.10
Prominence of nucleoli†	0.6	0.16	0.2	0.10

*Rounded to nearest tenth.
†Difference statistically significant at $P < .05$.

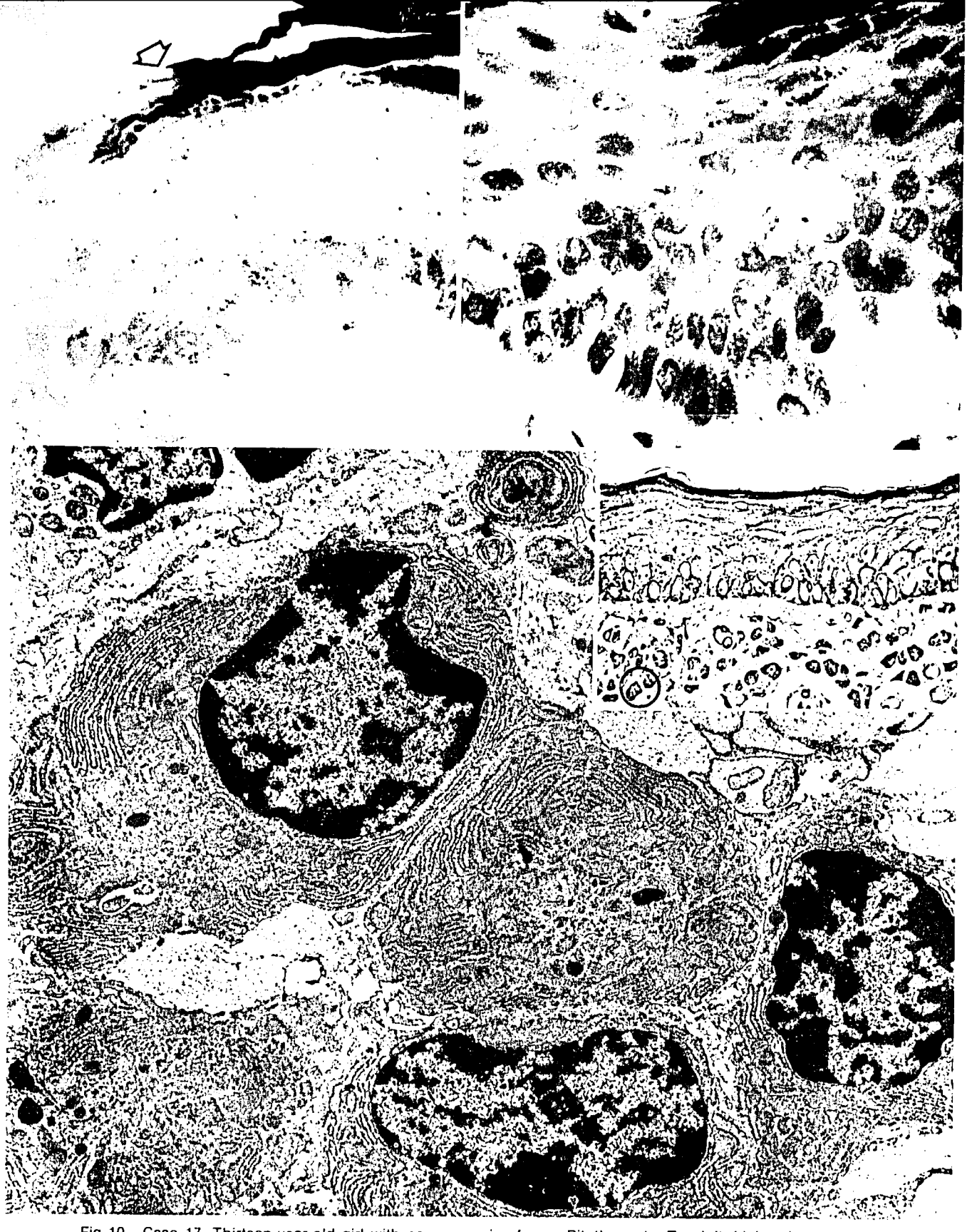

Fig 10.—Case 17. Thirteen-year-old girl with nonresponsive foamy Bitot's spots. Top left, Light microscopy of temporal conjunctival biopsy specimen (right eye) exhibits abrupt transition (arrowhead) between abnormal heavily keratinized surface (right) and more normal adjacent conjunctiva (left) (Dane's stain, magnification ×825). Top right, Another section from same specimen similarly demonstrates by light microscopy abrupt transition between normal epithelium (left) and abnormal epithelium (right) with keratin, granular cell layer, and irregular maturational sequence (PAS, magnification ×825). Bottom inset, Phase-contrast photomicrograph of inferonasal conjunctiva illustrates similar epithelial features, plus chronic inflammatory infiltrate of the stroma, preponderantly composed of plasma cells (circled) (paraphenylenediamine, magnification ×750). Bottom, Transmission electron microscopy of area circled in inset shows clustered plasma cells with typical nuclear and cytoplasmic features (×9,500).

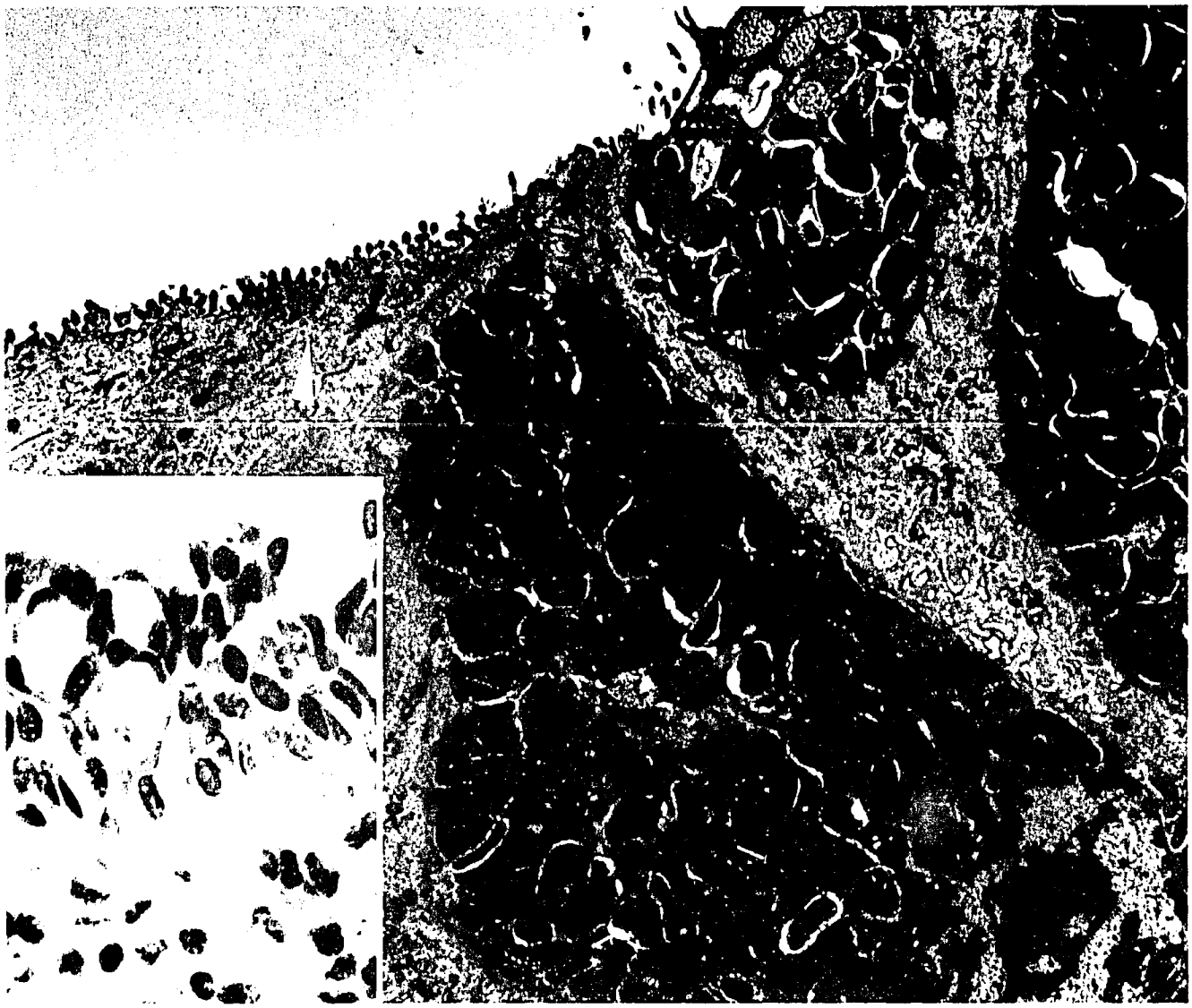

Fig 11.—Case 17. Thirteen-year-old girl with nonresponsive foamy Bitot's spots. Inset, Inferonasal conjunctiva (left eye) by light microscopy appears normal regarding absence of surface keratinization and presence of numerous goblet cells (hematoxylin-eosin, magnification ×825). Main figure, Transmission electron microscopy of area illustrated in inset discloses epithelial cells with usual surface membrane projections and devoid of keratohyaline material. Three goblet cells shown are similarly unremarkable, with secretory granules of various electron density and reticulation (×9,500).

epithelium of the lesions merged gradually with less severely affected surrounding conjunctiva, while milder but definite keratinizing metaplasia with loss of goblet cells was noted in the inferonasal quadrants.

In the only other histopathologic study of nonresponsive Bitot's spots of which we are aware,[4] the findings were similar; the lesions themselves varied from simple hyperplasia to fully developed, stratified squamous metaplasia with total loss of goblet cells, while the goblet cell population of the upper fornix was said to be normal in appearance and number. The authors concluded that Bitot's spots were not caused by vitamin A deficiency and that one must look elsewhere for their origin.

Our interpretation is different. Cases of conjunctival xerosis and Bitot's spots in the absence of vitamin A deficiency and failing to respond to vitamin A therapy are well documented.[1,3,4] However, vitamin A deficiency is the only well-established cause of conjunctival xerosis and Bitot's spots in otherwise normal eyes.[1,7] The cause of presumed nonvitamin-A-related lesions has never been elucidated. We recently described responsive and nonresponsive cases in the same general population.[7,8] Of these two groups, the nonresponders were significantly older, claimed to have had their lesions longer, and were more likely to recall a previous xerophthalmic episode, all of which suggested that their lesions could represent sequelae of past xerophthalmia. In addition, almost all (16/17) nonresponsive lesions were located in the temporal quadrant, the single eye with a nasal lesion containing a temporal one also. This predilection for the temporal site was shared by responsive lesions. Temporal lesions were present in every responsive abnormal eye, nasal lesions in only two thirds; temporal lesions often were more conspicuous, never less so than their nasal counterparts; and the temporal lesion often was the slower, never the quicker, to heal. In fact, in five responsive cases, there was rapid disappearance of all nasal lesions and improvement in the temporal ones, although the latter persisted to some degree for at least three to five

months. In one instance the temporal lesions eventually disappeared entirely, only to reappear several months later while serum vitamin A levels remained well within the normal range. Similar instances of waxing and waning of temporal spots were noted by Sinha and Bang[22] in a vitamin-A-supplemented population. Importantly, Bitot's spots in previously normal children continued to arise among placebo recipients but not among vitamin A recipients. In this instance at least, vitamin A supplementation prevented the development of seemingly non-vitamin-A-related Bitot's spots. It seems in some persons, because of age, chronicity, exposure, or other (as yet undetermined) factors, keratinizing metaplasia induced by vitamin A deficiency in the temporal (and rarely nasal) quadrant persists long after the initial stimulus has been removed.

Partly on the basis of their similar appearance on slitlamp examination, we suggested that there was little reason for differentiating between conjunctival xerosis and Bitot's spots, the two representing variations of the same basic process.[7,8] Our clinicopathologic correlations support this conclusion. Only a single case of conjunctival xerosis was studied, but its histologic appearance and that of the one previously reported[18] were indistinguishable from the vast majority of Bitot's spots. The surface of two of three cheesy Bitot's spots, however, was composed of massive, compact congregations of xerosis bacilli and frayed keratin. It is likely that the bacilli find dead keratinized cells to be an excellent culture medium. We applied gentamicin-bacitracin-polymyxin B ointment six times daily to one eye of a patient with bilateral nonresponsive cheesy spots for two weeks, with only slight reduction in the thickness and extent of the surface material (unpublished data).

Finally, we have documented the rapid histologic resolution that follows administration of vitamin A. Definite improvement was noted in responsive lesions within seven days of treatment, all subsequent specimens being normal. Goblet cells, however, were slow to return, first appearing in an inferonasal specimen at two weeks and in temporal specimens at two months, confirming our earlier observations[18] and those of Sullivan et al.[20] Since vitamin-A-responsive punctate keratopathy, the earliest known corneal manifestation of vitamin A deficiency in humans, resolves before this time,[23] it supports animal data[11,12] that suggest keratinization is a primary process and not dependent on the loss of goblet cells.[24] Only the brief comments by Herbert[25] on Mayou's 1903 presentation are at variance with this interpretation. He described advanced lesions involving the whole of the conjunctiva among severely malnourished persons in India in which keratinization was said to be absent while goblet cells were already lost.

Preparation of this report was carried out under Cooperative Agreement AID/DSAN-CA-0267 (931-0045) between the Office of Nutrition, US Agency for International Development (USAID), and the International Center for Epidemiologic and Preventive Ophthalmology. Work was supported in part by Academic Investigator Award EY00156 from the National Eye Institute, National Institutes of Health (NIH); the William F. Milton Fund of Harvard University; a grant-in-aid from Fight for Sight, Inc, New York City; the Research to Prevent Blindness James L. Adams Award; Biomedical Research Support grant RR05527 from the National Eye Institute, NIH; and the Massachusetts Lions Eye Research Fund, Inc (Dr Kenyon).

The Nutritional Blindness Prevention Program is a joint undertaking of the Ministry of Health, Government of Indonesia, and Helen Keller International, with substantial funding from the Office of Nutrition, USAID.

References

1. Snell S: On nyctalopia with peculiar appearances on the conjunctiva. *Trans Ophthalmol Soc UK* 1881;1:207-215.
2. Oomen HAPC: An outline of xerophthalmia. *Int Rev Trop Med* 1961;1:131-215.
3. Rodger FC, Saiduzzafar H, Grover AD, et al: A reappraisal of the ocular lesion known as Bitot's spot. *Br J Nutr* 1963;17:475-485.
4. Darby WJ, McGanity WJ, McLaren DS, et al: Bitot's spots and vitamin A deficiency. *Public Health Rep* 1960;75:738-743.
5. Kuming BS, Politzer WM: Xerophthalmia and protein malnutrition in Bantu children. *Br J Ophthalmol* 1967;51:649-665.
6. *Vitamin A Deficiency and Xerophthalmia*, report of a joint WHO/USAID (World Health Organization/US Agency for International Development) meeting. Geneva, World Health Organization, 1976, pp 18-21.
7. Sommer A: *Nutritional Blindness: Xerophthalmia and Keratomalacia*. Oxford, England, Oxford University Press, to be published.
8. Sommer A, Emran N, Tjakrasudjatma S: Clinical characteristics of vitamin A responsive and nonresponsive Bitot's spots. *Am J Ophthalmol* 1980;90:160-171.
9. Kessing SV: Mucus gland system of the conjunctiva: A quantitative normal anatomical study. *Acta Ophthalmol Suppl* 1968;95:9-13.
10. Mori S: Primary changes in eyes of rats which result from deficiency of fat-soluble A in diet. *JAMA* 1922;79:197-200.
11. Wolbach SB, Howe PR: Tissue changes following deprivation of fat-soluble A vitamin. *J Exp Med* 1925;42:753-777.
12. Pfister RR, Renner ME: The corneal and conjunctival surface in vitamin A deficiency: A scanning electron microscope study. *Invest Ophthalmol Vis Sci* 1978;17:874-883.
13. Leber T: Ueber die Xerosis der Bindehaut und die infantile Hornhautverschwärung, nebst bemerkungen ueber die Entstehung des Xerophthalmus. *Albrecht Von Graefes Arch Klin Exp Ophthalmol* 1883;29:225-290.
14. Stephenson S: On epithelial xerosis of the conjunctiva. *Trans Ophthalmol Soc UK* 1896; 18:55-102.
15. Mayou MS: The pathological anatomy of the plaques in epithelial xerosis. *Trans Ophthalmol Soc UK* 1904;24:9-16.
16. Reddy PS: Bitot's spots and vitamin A deficiencies. *Trans Ophthalmol Soc NZ* 1965; 17:90-93.
17. Sweet LK, K'ang HJ: Clinical and anatomic study of avitaminosis A among the Chinese. *Am J Dis Child* 1935;50:699-734.
18. Sommer A, Tjakrasudjatma S, Djunaedi E, et al: Vitamin A-responsive panocular xerophthalmia in a healthy adult. *Arch Ophthalmol* 1978;96:1630-1634.
19. Smith RS, Farrel T, Bailey T: Keratomalacia. *Surv Ophthalmol* 1975;20:213-219.
20. Sullivan WR, McCulley JP, Dohlman CH: Return of goblet cells after vitamin A therapy in xerosis of the conjunctiva. *Am J Ophthalmol* 1973;75:720-725.
21. Sauter JJM: *Xerophthalmia and Measles in Kenya*. Groningen, the Netherlands, Drukkerij van Denderen, 1976, pp 139-140.
22. Sinha DP, Bang FB: The effect of massive doses of vitamin A on the signs of vitamin A deficiency in preschool children. *Am J Clin Nutr* 1976;29:110-115.
23. Sommer A, Emran N, Tamba T: Vitamin A responsive punctate keratopathy in xerophthalmia. *Am J Ophthalmol* 1979;87:330-333.
24. Dohlman CH, Kalevar V: Cornea in hypovitaminosis A and protein deficiency. *Isr J Med Sci* 1972,8:1179-1183.
25. Herbert H: Comments on presentation by M. S. Mayou. *Trans Ophthalmol Soc UK* 1904; 24:15-16.

Printed and Published in the United States of America