AGENCY FOR INTERNATIONAL DEVELOPMENT
WASHINGTON, D. C. 20523

BIBLIOGRAPHIC INPUT SHEET

FOR AID USE ONLY

1. SUBJECT CLASSIFICATION

A. PRIMARY: Population — PC00-0000-0000

B. SECONDARY: Family planning

2. TITLE AND SUBTITLE

Surgical and engineering research on means of fertility control; Project III: New and improved approaches to reversible sterilization of the male. Final report

3. AUTHOR(S)

(100) Free, M. J.; (101) Battelle Memorial Inst., Columbus, Ohio

4. DOCUMENT DATE	5. NUMBER OF PAGES	6. ARC NUMBER
1979	265p.	ARC 613.942.F853

7. REFERENCE ORGANIZATION NAME AND ADDRESS

Battelle

8. SUPPLEMENTARY NOTES *(Sponsoring Organization, Publishers, Availability)*

9. ABSTRACT

10. CONTROL NUMBER

PN-AAG-705

11. PRICE OF DOCUMENT

12. DESCRIPTORS

Sterilization
Birth control
Surgical instruments
Vasectomy

13. PROJECT NUMBER

932170530

14. CONTRACT NUMBER

AID/csd-3152

15. TYPE OF DOCUMENT

AID 590-1 (4-74)

613.942
F853

PN-AAG-905

FINAL REPORT

Surgical and Engineering Research on Means of Fertility Control

Project III:

New and Improved Approaches to Reversible Sterilization of the Male

January 1979

Prepared for AID
through
Battelle Population Study Programs
Human Affairs Research Center
Pacific Northwest Division
Battelle Memorial Institute
under Contract AID/csd-3152

Battelle
Pacific Northwest Laboratories

LEGAL NOTICE

This report was prepared by Battelle as an account of sponsored research activities. Neither Sponsor nor Battelle nor any person acting on behalf of either:

MAKES ANY WARRANTY OR REPRESENTATION, EXPRESS OR IMPLIED with respect to the accuracy, completeness, or usefulness of the information contained in this report, or that the use of any information, apparatus, process, or composition disclosed in this report may not infringe privately owned rights; or

Assumes any liabilities with respect to the use of, or for damages resulting from the use of, any information, apparatus, process, or composition disclosed in this report.

FINAL REPORT

SURGICAL AND ENGINEERING RESEARCH ON MEANS OF FERTILITY CONTROL

PROJECT III:

NEW AND IMPROVED APPROACHES TO REVERSIBLE STERILIZATION OF THE MALE

M. J. Free, Ph.D., Project Director

January 1979

Prepared for AID through
Battelle Population Study Programs
Human Affairs Research Center
Pacific Northwest Division
Battelle Memorial Institute
under Contract AID/csd-3152

Battelle
Pacific Northwest Laboratories
Richland, Washington 99352

BACKGROUND

The principal objectives of this project at its inception were to research and develop simplified and reversible methods of male sterilization. Beginning July 1, 1971, literature reviews, site visits, an international workshop (Appendix 1) and a Medical Advisory Committee (Appendix 1) were employed to focus on significant gaps in knowledge, definitive areas of human need, and ways to meet those needs. The state of knowledge and assessment of goals, based on these inputs, is summarized as follows:

Research on the Reproductive System and its Response to Vas Occlusion

The general conclusion was that there are large gaps in our knowledge of both normal male reproductive physiology and the consequences of vasectomy. A number of areas needing extensive study were identified and discussed:

Granuloma Formation. Varying opinions have been expressed regarding the formation of granulomas, both symptomatic and asymptomatic. These differences need to be resolved.

Effects of Denervation. It is not known whether vas dilation following vasectomy is due to hydrostatic pressure, denervation or both. Neither is it known whether the contractility and tonus of the vas are restored after reanastomosis. (Peristaltic contraction does return to normal in the urethra and bowel after resection.)

Sperm Production and Disposal. A systematic determination of sperm counts before vasectomy and after reanastomosis is needed. Baseline data are required in order to evaluate later results. Spermatogenesis requires further study to determine if there is impairment in a given percentage of vasectomized men. The question of what happens to sperm after vasectomy if they are not reabsorbed might be answered by the finding of decreased or absent sperm production. This needs further study. Most patients show only temporary engorgement of the epididymis after vasectomy.

Hormonal Changes. Hormonal patterns could conceivably be altered by vasectomy. It is possible that changes in the pattern of androgen secreted by the testes could induce changes in target tissues.

Uric Acid Metabolism. Substantiation is needed for a report that vasectomized men, and individuals who are azoospermic due to vas blockage for other reasons, have very high blood levels of uric acid.

Immunology. It was generally agreed that much more data on the immunological consequences of vasectomy are required.

Ligation versus Cautery. It was generally agreed that cautery or electrocoagulation may be a more effective procedure than ligation, with fewer complications due to granuloma and hematoma formation. Complications appear to be further reduced by the interposition of fascia between the cut ends, although this needs further study. Further comparative studies of various procedures are needed, and simple instruments should be developed for electrocoagulation.

External Approaches to Vas Blockade. The feasibility of burning or denaturing the vasal mucosa without making an incision was suggested.

Reversible Techniques

During the late 1960s and early 1970s vasectomy emerged as an important method of fertility control technique in the developed and less-developed world alike. This proved widely acceptable as a method of family limitation, became deliverable on a large scale and had withstood, to that date, the intense scrutiny for side effects made possible by the enormous growth in the population of vasectomized males. The success of the method prompted inquiry by clinical researchers and research planners into the possibility of increasing the acceptability of male sterilization still further by devising reversible methods of vasal contraception. Such methods were presumed to be attractive to individuals considering vasectomy but harboring doubts about the finality of the method, fearing changes in future plans or circumstances, catastrophic loss of family, or loss of sexual identity.

Following the rapid rise in popularity of vasectomy, increasing numbers of candidates for vasovasostomy, combined with the dismal record of failure with vasovasostomy techniques then available (less than 30% restoration of fertility), further emphasized the need for more effective methods of vasectomy reversal. Since implantable devices and prostheses were becoming more common in other areas of human health care, the stage was set for the development of reversible intravasal devices.

A principal assumption behind intravasal occlusive device development was that the root of the difficulty in vasectomy reversal by surgical means lay in the vasovasostomy and vasectomy operations per se, rather than in the consequences of vas occlusion. It was generally supposed that devices could eliminate these difficulties and, at the very least, by virtue of being easy to install and reverse, permit the general practitioner to achieve the success rate of the experienced specialist, thus substantially reducing the cost of the procedure. At best, it was thought, intravasal devices might improve the prospects for restored fertility following vas occlusion beyond the best means available and, perhaps, even facilitate multiple reversals.

In general, the vas deferens was assumed to be a relatively simple conduit for sperm and, therefore, a passive receptacle for plugs or valves. Furthermore, the ease with which 90% sterility could be achieved in man with a simple nylon thread in the vasal lumen, and the dramatic decrease in sperm counts that resulted from numerous preliminary trials with simple plugs and clips, provided sufficient support for the assumption that successful devices could be developed by trial and error, at reasonable cost of time and money, using existing knowledge of the male reproductive system.

A complete block to sperm passage has been the aim for most occlusive devices in the "closed" mode. Because the vas behaves like a viscous tube, shrinking in response to outside compression and dilating when stretched from the inside, measures were deemed necessary to develop an interlocking tissue-device interface in order to anchor

the device in place and prevent sperm migration. Obviously, the materials used for intravasal devices had to be biocompatible, and the device had to be easily reversible. Other than these criteria, there were no critical guidelines for intravasal device development.

PROJECT OBJECTIVE

After the initial period of problem definition and exploration, the following objectives were outlined for the project:

(1) to develop a new and improved device for reversible sterilization of the male

(2) to develop and refine safe electrocoagulation equipment for improved simple vasectomy

(3) to determine the physiologic effects of vas occlusion as they affect potential reversibility.

These three basic objectives remain unchanged, although approaches have altered in some cases due to new developments, which occurred during the course of the program, and as a result of continued input from the Medical Advisory Committee.

REVERSIBLE INTRAVASAL OCCLUSIVE DECIVE (RIOD)

Details of development of the device known as the RIOD are documented in papers published during the past five years (Appendix 2). These developments led up to the issuance of U.S. Patent No. 3,990,434. The RIOD had several advantages over other devices being developed elsewhere:

1. It was installed in the intact (untransected) vas, thus maintaining muscle, nerve and vessel continuity.
2. The poly(ether)urethane material used to fabricate the RIOD permitted sufficiently thin walls that the lumen diameter of the device could approach that of a normal undilated vas.
3. The device had a compliance similar to that of the vas wall itself, and required no clips or ligatures to hold it in place.
4. The RIOD was inherently cheap to fabricate in large numbers, being devoid of sophisticated stopcock arrangements or expensive material.

The RIOD was designed primarily as an occlusive device with potential for one Off-On-Off cycle during the user's lifetime.

Status

Though animal models were invaluable in developing the RIOD concept and refining the insertion procedures, they seemed inadequate

for testing the long-term reversibility of the device. Even the rhesus monkey responded differently from man to vasectomy and vas manipulative procedures (Appendix 2, paper 7). Attempts to improve the rhesus model were not very successful (Appendix 2, paper 7). Nevertheless, it was evident that the RIOD, in its most advanced form, had several promising qualities:

1. It was easily inserted without transecting the vas and would stay in place without clips or ligatures.
2. It was biocompatible and compliant, so that it did not erode adjacent tissues.
3. In the closed mode, it was effective in occluding the vas.
4. In the open mode, the lumen was large enough to permit normal sperm counts in the ejaculate.

RIOD technology has been successfully transferred to private industry for further research and testing. Since January 1978, experimental RIODs have been prepared by Medical Dynamics, Inc., Englewood, CO, 80112. Devices from this source were installed by Julian Frick, M.D., Salzburg, Austria, in three volunteers, 65-75 years of age, during surgery for benign prostatic hypertrophy. The vasa containing these devices were removed 3-6 months after installation. The devices were well tolerated. While they were in place no discomfort was reported. At removal there were no apparent reactions resulting from the device. Histologically, there were no inflammatory areas other than the lumen of the bypassed segment; however, there was little evidence of fibrous tissue ingrowth into the devices.

RIODs were installed bilaterally in a 37-year-old volunteer candidate for elective sterilization by Edwin L. Adair, M.D., Denver, CO. As with the Austrian cases, no installation problems were encountered, even though adhesions, vascularity and vasal stricture (suggesting a previous injury) were present on the left side. Vas occlusion was successful and no problems have been reported with this case to date.

Both Drs. Frick and Adair plan to continue limited clinical tests, including installation of the device in the open mode to determine if sperm can pass through the device without impediment.

Prospects for a Practical Reversible Intravasal Device

Research activity on intravasal device technology has dwindled to a low level. Since prospects for vasectomy reversal (using micro-surgical techniques) have improved considerably over the past 3 years, and clear evidence of long-term efficacy of reversible devices has not emerged, the likelihood of a revival of interest in such devices in the near future seems slight. However, the possibility that most of the problems associated with devices may be animal model problems should be borne in mind. The ease with which more than 90% sterility can be achieved in man using the simplest of devices, a nylon thread, in addition to the several known limitations of animal models (Appendix 2, paper 7), gives support to this contention. Furthermore, reflection on the consequences of vasectomy in even the best-regarded animal models

leads to the conclusion that vasectomy itself would not be considered suitable for human trials on the basis of animal studies alone.

Reversible sterilization by means of an intravasal device must still be considered technically feasible and, with sufficient effort, could be realized. However, the cost-benefit assessment has changed. The development of promising microsurgical methods of vasovasostomy, enacting of the Medical Device Act Amendment of 1971 by the U.S. Congress, and the increasing availability of simplified procedures for female sterilization have all altered the cost/benefit equation for intravasal device development. Furthermore, device development has proved more difficult than envisaged, reversibility after long-term installation in man will be difficult to prove within a reasonable time period, and 70% reversibility may be the best that can be expected, based on microsurgical vasovasostomy results. There remains the possibility that animal model problems are obscuring a useful method for human fertility planning and that some existing advanced device designs, such as the RIOD, will eventually prove sufficiently effective in man without additional development costs. Furthermore, if recent reports on circulating antisperm antibodies and immune-complex deposition in the rabbit glomerulus and in atherosclerotic plaques of rhesus monkeys presage vasectomy complications yet to be uncovered, nonocclusive or partially occlusive intravasal devices may offer an alternative approach to intravasal contraception, since extravasation of sperm and antisperm antibody formation are much less likely if sperm passage is not impeded. The RIOD concept can be easily adapted to a nonocclusive approach by

introducing micro channel, and/or spermicidal inserts, into the device. These approaches are currently under investigation by Medical Dynamics, Inc.

BIPOLAR ELECTROCOAGULATOR FOR VASECTOMY WITHOUT LIGATION OR RESECTION

The background of the vasectomy method known as the Schmidt Technique, and details of development of the Bipolar Vas Electrocoagulator are documented in papers published during the last 5 years (Appendix 3). This instrument was refined in conjunction with clinical tests by Stanwood S. Schmidt, M.D. Eureka, CA.

The technology was transfered to Electro Medical Systems, Inc., Denver, CO, who conducted, in conjunction with the BNW inventor, a program of industrial refinement prior to producing 60 units for testing by the International Fertility Research Program (IFRP). The instrument was also made commercially available soon afterward under the EMS Trademark, VASEAL.

During IFRP tests some failures were encountered in the hands of two clinicians with limited experience in the Schmidt Technique. An extensive investigation was undertaken by BNW and these failures were traced to intermittent failure of the electrode, probably due to insufficient crimping pressure on the amphenol plug during fabrication.

During the 1 1/2 years of delay between receipt of test units and start of the IFRP tests, EMS underwent a period of upheaval, resulting in the loss or dismissal of most employees associated with the VASEAL, including the Vice President responsible for initiating and directing the project. The VASEAL project was essentially shelved by EMS, and no further development or effective communication took place. As a result,

potential problems related to crimping pressure were not recognized or, if they were, were not relayed to the BNW Project Director. Later, telephone interviews with EMS engineers indicated an early quality control problem with crimping, a type of problem that was not unusual on first-run, prototypical equipment. Increased quality control of crimping appeared to have post-dated delivery of at least some of the test electrodes.

However, out of the investigation on VASEAL electrode failures several useful findings arose. Some of these, including the finding that avoidance of heat could double the life of the electrode, pertained to more effective use and care of the instrument and were incorporated into a revised handbook (Appendix 3, paper 6). Another significant finding was that fascial separation of the vas ends did not offer indemnity against failure of vasal occlusion, since the fascial tissues were rapidly destroyed by inflammatory processes associated with sperm granuloma (Appendix 3, paper 7).

Prospects for a Bipolar Vas Electrocoagulator

Electro Medical Systems has recently been taken over by Davol, Inc., and the VASEAL project is apparently being revived. Meanwhile, other companies (Medical Dynamics, Inc.; Codman and Shurtleff) are taking advantage of the public domain information published from this project (Appendix 3) to develop other versions of the bipolar vas electrocoagulator. Dr. Schmidt has completed 2000 cases, without a failure, using the bipolar instrument and is using it for routine practice. Dr. Juan Giner Velázquez

(Head of Family Planning Services, Instituto Mexicano de Seguro Social, Mexico City), who purchased a VASEAL privately from EMS, has completed several hundred cases without failure and is also using the instrument routinely. Over the past 5 years the Schmidt technique has become firmly established and was acknowledged by international vasovasostomy experts attending the PARFR workshop on Reversal of Sterilization (1978), as the best method of vasectomy with respect to subequent vasovasostomy. Since the safety and control advantages of the bipolar approach to electrocoagulation are considerable, it seems very likely that the instrument will become widely used in one form or another within the next 5 years. Its advantages for public programs in less technologically developed countries still remain to be tested.

Trials in small laboratory animals have not given cause to hope that electrocoagulation of the vasal lumen without transection can lead to reliable vas occlusion. The power of vasal mucosa to regenerate and form lumina even after destruction of almost all of the muscle layers in these animals is remarkable. Since occlusion without transection is necessary for successful transcutaneous electrosurgical sterilization, the prospects of success for this technique are small, unless the human vas responds in a different manner, or to a radically different degree.

THE PHYSIOLOGIC EFFECTS OF VAS OCCLUSION

Follow-up studies in men after vasectomy are detailed in papers prepared or published over the past three years (Appendix 4). The findings are as follows:

Human lymphocyte antibodies are not formed as a results of standard vasectomy procedures (Appendix 4, papers 1 and 2).

2. Electrocoagulation of the vas does not result in a higher incidence of antisperm antibody formation when compared with vasoligation, and may possibly result in a lower incidence of sperm-immobilizing antibodies.
3. No substantive changes in the gonad-pituitary axis or in blood chemistry occurs up to 44 months after vasectomy.
4. Antisperm antibodies appeared in 30-50% of vasectomized men.
5. Men who develop antisperm antibodies after vasectomy tend to have lower serum FSH levels both <u>before</u> and <u>after</u> vasectomy than those who do not develop these antibodies.

INTERIM AND SPECIAL REPORTS ON CONTRACT AID/csd-3152 PROJECT III

Interim Reports

First Progress Report	January 15, 1972
Second Progress Report	July 15, 1972
Third Progress Report	January 15, 1973
Fourth Progress Report	July 15, 1973
Fifth Progress Report	January 31, 1974
Sixth Progress Report	September, 1974
Seventh Progress Report	March, 1975
Eighth Progress Report	December, 1975
Ninth Progress Report	January, 1978

Special Reports

Fertility Control in India: Personal Observations	November, 1976
State of the Art of the Vas Deferens Electrocoagulator	April, 1977
The Reversible Intravasal Occlusive Device (RIOD)	May 1, 1977
Vasovasostomy: An Assessment of the State of the Art	July 13, 1977
The RIOD: Preliminary Clinical Trials	March, 1978

Committee Members

Rudi Ansbacher, M.D.
Department of Obstetrics and Gynecology
Brooke General Hospital
P.O. Box 103
Fort Sam Houston, Texas 78234
Phone - (512) 221-3046

Donald S. Coffey, Ph.D.
Laboratory of Reproductive Biology
The Johns Hopkins University Hospital
Brady Hall, Room 504
Baltimore, Maryland 21205
Phone - (301) 955-5000

Joseph E. Davis, M.D.
New York Medical College
Flower and Fifth Avenue Hospitals
Fifth Avenue at One Hundred and Sixth Street
New York, New York 10029
Phone - (212) TR6-5500

Seymour Katsh, Ph.D.
Professor of Pharmacology
University of Colorado
Medical Center
4200 East Ninth Avenue
Denver, Colorado 80220
Phone - (303) 394-7564

Stanwood S. Schmidt, M.D.
707 K Street
Eureka, California 95501
Phone - (707) 443-2259

Emil Steinberger, M.D.
Professor and Director
Program in Reproductive Biology
and Endocrinology
University of Texas Medical School
102 Jesse H. Jones Library Bldg.
Houston, Texas 77025
Phone - (713) 526-8501

Subcontractors

Alvin Paulsen, M.D.
U.S. Public Health Service Hospital
P.O. Box 3145
Seattle, Washington 98114
Phone - (206) 325-8000 Ext. 345

Nancy J. Alexander, Ph.D.
505 NW 185th
Beaverton, Oregon 97005
Phone - (503) 645-1141

Larry L. Ewing, Ph.D.
Department of Population Dynamics
The Johns Hopkins School of Hygiene
615 N Wolfe Street
Baltimore, Maryland 21205
Phone - (301) 955-3106

Consultants

Stanwood S. Schmidt, M.D.
707 K Street
Eureka, California 95501

Edwin L. Adair, M.D.
3535 S Lafayette Street
Englewood, Colorado 80110

References, Appendix 1

1. Reversible male sterilization: Current status and future directions. A workshop held December 13 and 14, 1971 at Battelle Seattle Research Center, Seattle, WA.

2. Johnson, D. S. 1972. Reversible male sterilization: Current status and future directions. Contraception 5:327-328.

REVERSIBLE MALE STERILIZATION: CURRENT STATUS AND FUTURE DIRECTIONS

A Workshop

December 13 and 14, 1971
Battelle Seattle Research Center
Seattle, Washington

Chairmen

C. Alvin Paulsen, M.D.
University of Washington
School of Medicine

William J. Clarke, D.V.M., Ph.D.
Battelle-Northwest

Organized by
The Battelle Population Study Center

Sponsored by
The Agency for International Development

OBJECTIVE AND SCOPE

The objective of this working conference is to establish a rational basis for future research and development efforts devoted to reversible male sterilization.

Through discussions of specific topics germaine to the attainment of this objective, the workshop will:

- review the current state-of-the art of male sterilization procedures and their reversal;
- identify the gaps in our knowledge of:
  - male reproductive processes as they affect or are affected by sterilization procedures;
  - the structure and function of the vas deferens in relation to the types of occlusive measures that can be tolerated;
  - the long-term effects of vas occlusion on spermatogenesis and steroidogenesis;
  - the immunological sequelae of vas occlusion;
- suggest appropriate animal models for investigations designed to fill-in these gaps in our knowledge;
- establish performance criteria against which reversible male sterilization techniques can be compared (e.g., efficacy, safety, complications, reversibility, etc.);
- develop guidelines and protocols for the clinical evaluation of experimental procedures;
- explore the various approaches to reversible male sterilization, identifying in each case the advantages, disadvantages, and limitations of the approach and the potential contributions to its success of the latest materials and engineering technology;
- identify the most promising approaches to reversible male sterilization and develop research and evaluation protocols.

PROGRAM

Monday, December 13

Morning

Introduction and Conference Objectives . . . . . D. J. Prager

Male Sterilization: The AID Perspective . . . . . J. J. Speidel

Session I. Sterilization Procedures: Current Status . . C. A. Paulsen

A. Surgical Vas Ligation

B. Vas Occlusion and Obstruction

Afternoon

Session II. Reversibility: The Long-Term Effects of Vas Occlusion . . . . . C. A. Paulsen

A. Vas Structure and Function: Reanastomosis

B. Epididymal Physiology

C. Testicular Physiology

- spermatogenic
- steroidogenic
- immunologic

Evening

Session III. Materials Technology: Current Status . . . A. S. Hoffman

Tuesday, December 14

Morning/Afternoon

Session IV. Research and Development: Future Directions. . W. J. Clarke

A. Fundamental Research: What We Need to Know

B. Identification of Suitable Animal Models

C. Clinical Evaluation: Need for Uniformity

- meaningful protocols
- criteria for success of reversibility

D. Complications: Physiological and Psychological Sequelae

E. Reversible Techniques: The Most Promising Approaches

Workshop Conclusion . . . . . D. J. Prager

PARTICIPANTS LIST
MALE STERILIZATION MEETING
December 13 and 14, 1971

Dr. Rudi Ansbacher
Department of Obstetrics
and Gynecology
P. O. Box 103
Brooke General Hospital
Fort Sam Houston, Texas 78234

Dr. J. Michael Bedford
Assistant Professor of Anatomy
International Institute for the
Study of Reproduction
Columbia University
630 West 168th Street
New York, New York 10032

Dr. Gabriel Bialy
Contraceptive Development Branch
Center for Population Research
Building 31, Room 2A50
National Institutes of Health
Bethesda, Maryland 20014

Dr. Erich E. Brueschke, Director
Medical Engineering Center
I.I.T. Research Institute
10 West 35th Street
Chicago, Illinois 60616

Dr. W. J. Clarke
Battelle Northwest
Building 331
Richland, Washington 99352

Dr. Donald S. Coffey
Laboratory of Reproductive Biology
Brady Hall, Room 504
Johns Hopkins University Hospital
Baltimore, Maryland 21205

Miss Ruth Crozier
Fertility Regulation Methods
Evaluation Branch
Center for Population Research
Building 31, Room 2A24
National Institutes of Health
Bethesda, Maryland 20014

Dr. Pramila David
Rural Family Planning Project
Allahabad Agricultural Institute
P. O. Agricultural Institute
Allahabad, India

Dr. Joseph E. Davis
320 West End Avenue
New York, New York 10023

Dr. George Denniston
Population Dynamics
3829 Aurora Avenue North
Seattle, Washington 98103

Dr. G. W. Duncan
Battelle Population Study Center
4000 N. E. 41st Street
Seattle, Washington 98105

Dr. Richard D. Falb
Battelle Columbus Laboratories
505 King Avenue
Columbus, Ohio 43201

Dr. Marv Frazier
Battelle Northwest
Building 331
Richland, Washington 99352

Dr. Hugh Fudenberg
Department of Hematology
University of California
Medical Center
San Francisco, California 94122

Dr. M. F. Gillis
Battelle Northwest
Building 331
Richland, Washington 99352

Dr. Patricia Hackett
Battelle Northwest
Building 331
Richland, Washington 99352

Dr. Carl Heller
Pacific Northwest Research Foundation
1102 Columbia Avenue
Seattle, Washington

Dr. Walter Herrmann
Chairman
Department of Obstetrics and
Gynecology
University of Washington Medical
School
Seattle, Washington 98105

Dr. Alan S. Hoffman
Research Professor
Chemical Engineering and Bioengineering
University of Washington
Seattle, Washington

Dr. Robert S. Hotchkiss
Professor and Chairman
Department of Urology
New York University Medical Center
566 1st Avenue
New York, New York 10016

Dr. Jaroslav Hulka
Associate Professor
Department of Obstetrics and Gynecology
University of North Carolina
Chapel Hill, North Carolina

Dr. Diana Johnson
Department of Physiology
Medical College of Virginia
Health Sciences Division
Virginia Commonwealth University
Richmond, Virginia 23219

Dr. M. Karagianes
Battelle Northwest
Building 331
Richland, Washington 99352

Dr. Seymour Katsh
University of Colorado Medical School
4200 East 9th Avenue
Denver, Colorado 80220

Dr. Hee Yong Lee
Department of Urology
College of Medicine
Seoul National University
Seoul, Korea

Dr. J. William McRoberts
Department of Urology
University of Washington School of Medicine
Seattle, Washington 98195

Dr. C. A. Paulsen
U. S. Public Health Service Hospital
P. O. Box 3145
Seattle, Washington 98114

Mrs. Mary Perry
Office of Population
Technical Assistance Bureau
Department of State
Washington, D. C. 20025

Dr. Malcolm Potts
Medical Director
International Planned Parenthood Federation
18-20 Lower Regent Street
London, SW1, England

Dr. Denis J. Prager
Battelle Population Study Center
Human Affairs Research Centers
4000 N. E. 41st Street
Seattle, Washington 98105

Dr. P. Rumke
Antoni Van Leeuwenhoek Huis
The Netherlands Cancer Institute
Amsterdam, Holland

Dr. Stanwood S. Schmidt
707 K Street
Eureka, California

Dr. J. Joseph Speidel
Chief, Research Division
Office of Population
Agency for International Development
Washington, D. C. 20025

Dr. H. Fred Stegall
Assistant Director
Center for Bioengineering
G 213 Health Sciences
University of Washington
Seattle, Washington 98195

Dr. Emil Steinberger
Director, Program in Reproductive Biology and Endocrinology
University of Texas Medical School at Houston
102 Jesse H. Jones Library Building
Houston, Texas 77025

Mr. Robert G. Wheeler
Battelle Northwest
RO Building
Battelle Boulevard
Richland, Washington 99352

Dr. Julius H. Winer
9915 Santa Monica Boulevard
Beverely Hills, California

REVERSIBLE MALE STERILIZATION: CURRENT STATUS AND FUTURE DIRECTIONS

Diana Schneider Johnson, Ph.D.

Department of Physiology
Medical College of Virginia
Richmond, Virginia 23219

INTRODUCTION

A workshop on reversible male sterilization was held at the Battelle Seattle Research Center on December 13-14, 1971, under the sponsorship of the Agency for International Development (AID). The workshop was organized by Dr. Denis J. Prager of the Battelle Population Study Center; co-chairmen were Drs. W. J. Clarke of Battelle and C. Alvin Paulsen of the University of Washington. The objective of this conference was to establish a rational basis for future research and development on reversible male sterilization.

Participants were asked to: 1) review the current state of the art of male sterilization procedures and their reversal; 2) identify the gaps in our understanding of a) male reproductive processes as they affect or are affected by sterilization procedures, b) the structure and function of the vas deferens in relation to the types of occlusive measures that can be tolerated, c) the long-term effects of vas occlusion on spermatogenesis and steroidogenesis, and d) the immunological sequelae of vas occlusion; 3) suggest appropriate animal models for investigations designed to fill in these gaps; 4) establish performance criteria against which reversible male sterilization techniques can be compared (efficacy, safety, complications, reversibility, etc.); 5) develop guidelines and protocols for the clinical evaluation of experimental procedures; 6) explore the various approaches to reversible male sterilization, identifying the advantages, disadvantages and limitations to each approach and the potential contributions to its success of the latest materials and engineering technology; and 7) identify the most promising approaches to reversible male sterilization and develop research and evaluation protocols.

STERILIZATION PROCEDURES: CURRENT STATUS

Chairman: C. Alvin Paulsen

Surgical Vas Ligation

Vasectomy is an outpatient procedure that generally requires approximately 20 minutes. The skin of the scrotum is cleansed and a local anesthetic administered. The vas deferens is isolated and cut, after which the cut ends are

Accepted for publication April 3, 1972

ligated or fulgurized, then replaced in the scrotal sac and the incision closed. The details of the procedure vary from surgeon to surgeon. It is important to emphasize to the patient that he is not sterile until the ejaculate has been found to be sperm-free. The participants were generally agreed that the vas should always be cut high in the scrotum where it is straight, rather than in the convoluted portion, because subsequent reanastomosis is simpler and more likely to be successful.

A frequent complication (up to 5%) of the vasectomy procedure is hematoma formation. Joseph Davis (New York City) felt that the main cause of hematoma is failure to take sufficient care of the underlying small vessels in the scrotal wall, rather than bleeding from major vessels, since the latter are generally tied off when bleeding occurs during the procedure. The small blood vessels may not bleed until the effects of the local anesthesia wear off. Fulguration of the cut ends of the vas may avoid this problem.

The importance of maintaining the circulation and nerve supply of the vas for the success of later reanastomosis was suggested by several of the participants. Michael Bedford (Columbia University) suggested that failure of the nerve supply to regenerate after reanastomosis may result in semi-functional muscle tissue. Approximately 70% of the sperm in a normal individual come from the region proximal to the point where vasectomy is performed, and movement of sperm during ejaculation requires a powerful series of coordinated movements. Sperm counts after reanastomosis tend to be low, and it may be that sperm are simply pushed out under pressure rather than as a result of contraction. Division of the inferior spermatic nerve should be followed by re-innervation, but removal of the nerve stump and the presence of scar tissue may make this impossible when a length of the vas is removed. A major question that must be answered is whether normal function can return without this nerve supply. Julius Winer (Beverly Hills, California) felt that the high success rate that can be obtained when both the original vasectomy and the reanastomosis are carefully performed indicates that impairment of the blood and nerve supply can be avoided.

A major complication following vasectomy is the occurrence of sperm granulomas, inflammatory responses to sperm leakage from the reproductive tract into surrounding tissue. Many granulomas represent simply a local foreign body reaction, although others may result in a major abscess. Scar tissue formation following a granulomatous reaction may make subsequent reanastomosis impossible. It is difficult to find an animal model in which to study granuloma formation, because of marked species differences in immune systems. Emil Steinberger (University of Texas Medical School, Houston) has found that many sperm are required to induce an immune response in the rat, whereas the presence of only a few sperm are required in the human. The absolute amount of sperm required to induce granuloma formation in the human needs to be determined.

The incidence of spontaneous reanastomosis is generally low, and tends to occur within a short time after the procedure, although some cases have been seen up to 5-7 years later. Stanwood Schmidt (Eureka, California) noted that such spontaneous reanastomosis may be associated with a sperm granuloma.

There was extensive discussion of whether ligation or fulguration produces a better obstruction with fewer complications. Dr. Schmidt emphasized the superiority of fulguration or cauterization. He has found that the incidence of sperm granuloma is far lower with fulguration. Dr. Schmidt has also successfully utilized cautery with a hot platinum wire for the end of the vas proximal to the epididymus. The cautery procedure destroys the muscosa and submucosa. The tissue appearance of the cauterized vas is neat and regular compared to the abnormal tissue seen following ligation. William McRoberts (University of Washington School of Medicine) has also found that fulguration is preferable to ligation. He has had virtually no granuloma complications following fulguration, versus 10% following ligation.

It was generally agreed that vasectomy could be readily taught to paramedical personnel. However, techniques to be used by paramedical personnel should be made as simple and mistake-proof as possible.

Vas Occlusion and Obstruction

Dr. Davis has attempted to develop an intervasal device (IVD) that would be a permanent implant, but that could pass through a series of on-off phases to provide true reversibility. The device, made of gold with a stainless steel stem, is covered with a mesh designed to induce tissue ingrowth in order to form a permanent attachment to the vas. The vas is transected high in the straight portion, the muscosa cored out, and the device inserted 1 cm into each side. The valve stem is placed perpendicular to the vas, in the "off" position. In preliminary clinical tests, nine of 10 volunteer subjects became azoospermic and resembled normal vasectomized patients. In the 10th patient, the valve was found to be improperly positioned; he became azoospermic when the valve was correctly placed in the "off" position. In future studies, the valves will be turned to the "on" position to see whether sperm counts and motility return to normal.

Hee Yong Lee (Seoul National University) described the use of an intervasal thread for vas occlusion. Local anesthesia is used for the procedure. The IVD is 3 cm long, and is made of non-absorbable nylon and silicone that is flocculated to permit tissue ingrowth. It is held in place by a filiform thread tied around the vas. The IVD has a diameter of 0.8 mm (the average vas diameter of Korean men is 0.3 mm). Sperm content dropped below 7 million (2/3 of these to zero) in 408 cases, but increased later in 30. In the latter, the IVD had been extruded from the vas due to its stiffness. A local foreign body reaction has been found in the region of the IVD. Only 1-2 pregnancies have resulted in patients having a sperm count below 7 million with this IVD in place. The procedure requires 15-20 minutes, compared to 5-10 minutes for the standard ligation procedure. Complications are minimal, with only minor inguinal discomfort and some tissue firmness.

Dr. Lee considers a sperm count below 7 million to be adequate for sterilization; however, others have found that pregnancies can occur even with counts below 5 million. Dr. Davis noted that there is no hard data available from normal men for adequate comparison; quite low counts have been found even in fertile men, and there is no adequate standard of "normalcy". Carl Heller (Pacific Northwest Research Foundation) noted that one must also consider the

fertility of the female partner. Pregnancy may not occur in couples where the male has a relatively high sperm count but the female has a low potential fertility; such a woman may require a partner with an extremely high sperm count in order to become pregnant. Conversely, semen with a low sperm count may be quite adequate for induction of pregnancy in a highly fertile woman.

Malcolm Potts (International Planned Parenthood Federation) felt that many people involved with vasectomy have an obsession with failure, and suggested that a technique for male sterilization that was totally reversible but had a small failure rate would still be extremely valuable. A concern with reversibility implies use of the method for spacing; thus, it should be feasible to use pregnancy termination as a back-up technique, just as it is used for failures in female contraception. Such an approach would be similar to all methods of contraception currently in use; i.e. the patient would be informed that there was a slight risk of pregnancy. There is an intermediate ground of good versus perfect that should be considered when talking about reversibility. The occurrence of a few pregnancies with the diaphragm or IUD has never been cause for alarm, and there is no reason that the same approach cannot apply to male methods.

REVERSIBILITY: THE LONG-TERM EFFECTS OF VAS OCCLUSION

Chairman: C. Alvin Paulsen

Dr. Winer described the procedure that he uses for vas reanastomosis. The scrotal area is exposed, and the vasectomy site is located, dissected out and transected distally. The vas is injected with dye to insure that it is patent through the ejaculatory duct. The proximal end is then transected, and the milky secretion from the epididymus diluted with saline and examined. The two ends are approximated under an operating microscope. A nylon splint is placed in the lumen, and 3 or 4 sutures placed through the muscularis and adventitia, without touching the mucosal layer; any opening in the mucosa permits sperm egress, and closure of the vas due to swelling and fibrosis may then occur. Tissue reactions are markedly reduced by meticulous avoidance of sperm spillage and constant irrigation with saline to remove spermatozoa. After reanastomosis, 2-3 supporting sutures of 0000 nylon or #2-3 silk are used to remove tension from the operative site. The skin is sutured with 000 or 0000 plain catgut or 0000 nylon. The splint is left in place, an elastic jock strap is used as a pressure dressing, and the testes are packed with gauze. The patient is kept relatively inactive for 4 days, at which time the splint is removed and he is sent home. The skin sutures are removed in one week. Far better results, as measured by subsequent pregnancies, were obtained in those patients whose original vasectomy permitted reanastomosis by a vasovasotomy rather than a vasoepididymostomy.

Dr. Lee has found that only 1 in 1000 Korean patients request reversal of vasectomy. Of 120 patients on whom reanastomosis was performed, the semen of 108 was examined. Of these, 97 showed sperm and 25 were able to induce pregnancy. Twelve of these patients showed psychological complications after vasectomy, which disappeared after the reversal procedure. A two day hospitalization was generally required. The "success rate" was much higher (92 vs 67%) when reanastomosis was

done via a bilateral vasovasotomy than when epididymal reanastomosis was required. Both Drs. Winer and Lee noted that many abnormal sperm are seen initially, but these are gradually replaced by sperm with normal morphology and motility.

The actual extent of reversibility (as measured by subsequent pregnancy) would appear to be quite low for surgical vasectomy. Donald Coffey (Johns Hopkins University Hospital) noted that a comparison of data from many sources indicates an average reversibility of only 50%, when success is defined in this way. This low rate occurs despite the fact that sperm showing a relatively normal appearance are frequently found in more than 90% of the patients.

The demand for reversal would appear to vary extensively. Dr. Lee's observation of a 0.1% request rate, as well as data from other countries, would indicate that reversibility is not of particular importance in many areas. However, the availability of a reversible method might induce more men to consider sterilization at a younger age and after fewer children, in which case it would be used essentially as a contraceptive. In the United States, the number of requests for reversal range between 6-10%. The vast majority of requests in this country are due to divorce and remarriage.

Dr. Potts suggested that the available data indicate that vasectomy and reanastomosis must be considered quite separately. The original procedure is simple and can be done skillfully even by well-trained paramedical personnel. In contrast, reanastomosis is a difficult procedure that should be attempted only by highly skilled physicians.

Epididymal and Testicular Physiology

It is important to consider the possibility that the high failure rates associated with reanastomosis are related to an impairment of reproductive physiology. Dr. Bedford has studied the long-term effects of vasectomy in the rabbit, hamster, rat and Rhesus monkey. Six months following bilateral vasectomy in the rabbit, there was enormous distention of the vas, although the distention had not backed up into the corpus region. Testicular tissue was histologically normal, but examination of the enlarged cauda epididymidis showed masses of solid sperm and a flattened epithelium. No infiltration by any type of leukocyte was ever observed unless rupture of the duct had occurred. Most of the sperm had lost their acrosomes, and there was some separation of heads and tails, but no phagocytosis or leukocytic invasion was evident. Involvement of the corpus generally occurred by 8 months, at which time a series of lesions, ruptures and scars could be seen in the caput and/or cauda. Depression of the germinal epithelium had occurred in those in which "abscesses" were present in the caput, with only a few scattered remnants remaining.

In the rat, epididymal lesions and spermatocoeles were observed in at least 50% of the animals after 8-9 months. The tubules were full of sperm but, as in the rabbit, leukocytic infiltration was seen only when granulomata were present.

In the hamster, granuloma formation in either the caput or cauda, massive lesions and distention of the cauda were observed 3-4 months following ligation.

Involvement of the caput resulted in a depression of testicular activity. As in the other species, infiltration of leukocytes was apparent only in the regions of granuloma formation.

A far less marked response to vasectomy has been observed in the Rhesus monkey, although experiments have not yet been continued for long time periods. Some epididymal turgidity was found 3-4 weeks after the operation, but this tended to decrease by 6 weeks. Discrete lesions of the cauda and vas deferens could be demonstrated histologically 6 weeks after vasectomy, but they were too small for visual identification. The lesioned areas did show leukocytic invasion, as well as degenerating sperm, and active phagocytosis of sperm by monocytes and polymorphs was underway. EM studies of the cauda showed sperm heads and tails within macrophages. Distension is much less pronounced in this species, partly due to the presence of a large amount of interstitial tissue.

These data indicate that sperm are continually produced after vasectomy, but that no reabsorption occurs until the epithelium ruptures, at which time leukocytic infiltration and invasion occurs. A significant effect on the testes appeared only in those cases in which duct distention by sperm reached the corpus. The situation in the human may be similar to that of the Rhesus, whose epididymal architecture is somewhat similar. There are many reports of the presence of antibodies to sperm in vasectomized men. These might be induced as a consequence of rupture of the duct with exposure of large numbers of sperm to immunologically competent cells. Other workers have also been unable to confirm the occurrence of reabsorption. Dr. Bedford suggested that spermatogenic arrest or interstitial hyperplasia might be responsible for the lack of a major pressure buildup.

Dr. Heller has recently studied a series of 58 men in whom sperm egress was blocked. Testicular biopsies were found to be normal up to 17 years after vasectomy. All patients tested before vasectomy showed counts that were within the normal range. More work is needed on non-human primates, since the human and (probably) other primates appear to respond to vasectomy in a markedly different way than many other species.

Immunology

The immunological consequences of vasectomy were discussed by P. Rümke (The Netherlands Cancer Institute) and Rudi Ansbacher (Fort Sam Houston, Texas). Dr. Rümke has been able to induce a spermagglutinin response in male rats by injecting autologous epididymal spermatozoa subcutaneously. Tolerance was never observed. All animals were fertile immediately after unilateral vasectomy, but some were rendered infertile after the development of spermagglutinins. This was not related to the titer.

A comparison of 2000 infertile males with 416 fertile individuals showed that 3.3% of the infertile individuals had high serum titers of spermagglutinins, whereas such high titers were never found in fertile men. The semen of men showing positive spermagglutinin responses often showed auto-agglutination. However, about 1/3 of these were azoospermic, almost always due to ductal obstruction rather than to impaired spermatogenesis.

In most individuals there was a positive correlation between serum and seminal plasma antibody titers, with the serum levels much higher. Sperm-agglutinins are probably produced locally in the genital tract in those cases with relatively high seminal plasma titers, whereas the antibodies may diffuse into the seminal fluid from the blood in other cases. Seminal plasma generally contains only low amounts of IgG and IgA, and no IgM. IgG levels in different semen fractions were correlated with acid phosphatase levels, and there was no correlation with fructose or spermatozoa, suggesting that IgG enters the seminal plasma via the prostate.

A retrospective study showed an inverse correlation between fertility and spermagglutinin titer. However, fertility can occur in spite of the presence of serum antibodies. It is not yet known whether those who became fertile had low titers, as might be expected.

Dr. Ansbacher described immunological studies on infertile couples, utilizing semen analyses, a macroscopic gelatin spermagglutination test, and a complement-specific sperm immobilization test. Of 228 infertile couples, 18 female and 17 male serum samples showed either positive spermagglutinin or immobilization tests. There were no correlation between the semen analyses and those men with sperm autoantibodies.

Similar immunological studies were performed on 55 patients prior to, and at 6 months and 1 year following vasectomy. One man had a circulating sperm-agglutinin prior to vasectomy, whereas 54.2% had such antibodies 6 months later. None gave a positive response on the sperm immobilization test prior to vasectomy, but 31.3% had a positive reaction 6 months later. One year after vasectomy, the incidence of sperm agglutinating and sperm immobilizing antibodies was unchanged, but definite serum sperm antibody titer increases were noted. The consequences of these observations are not yet understood.

There are preliminary data which suggest that those patients who develop sperm antibodies after vasectomy have a higher incidence of previous multiple allergies than patients who do not develop sperm antibodies. To clarify this interelationship, careful follow-up studies are clearly indicated to determine whether alterations in the reproductive immune response mechanism may be related to systemic immunologic responses.

Sperm Banks

The availability of a method for sperm storage that would insure the availability of healthy sperm to a vasectomized man who wished to induce pregnancy would be a major advance, since the demand for reversibility should no longer be a problem. Sperm samples could be taken from each patient prior to vasectomy, and would be available when desired. However, the techniques of sperm storage are presently not developed to the extent that this is feasible.

Pregnancy rates in the human after freeze-thawing can be quite high. However, following prolonged storage, there are not sufficient data to support statements which have suggested that there is no major loss of fertilizability. The major problem in this approach involves individual differences in response to the freezing and thawing procedure. Sperm samples from an individual considering vasectomy should first be tested by freeze-thawing for a few weeks to determine viability.

Dr. Steinberger found a difference in the sperm count of the semen required to induce pregnancy when frozen and fresh material was used; the mean sperm count of fresh semen that successfully induced pregnancy was 101 million, while that for frozen material was 148 million. The mean initial motility also needed to be higher for frozen material. The motility after storage was 50-90% below that of the original material; this drop was immediate, and was related to the freeze-thaw process rather than being a function of time in storage. Some samples were highly resistant to such changes, while others were quite sensitive and showed large decreases in motility and ability to induce pregnancy. The mean of pooled samples showed a definite decrease in motility with prolonged storage. It must be remembered that pregnancy, not motility, is the final test of any method.

It was agreed that, while it is as yet too early to draw any precise conclusions, the availability of sperm storage will probably increase the desirability of vasectomy. Even if there is very little chance that a given individual will want to utilize the stored sperm, their availability is reassuring, and may help to decrease the psychological problems associated with the procedure.

Dr. Steinberger emphasized the point that the use of sperm banks should not be used as an enticement for vasectomy until techniques have developed to the point where it is possible to guarantee future sperm normality without reservation.

RESEARCH AND DEVELOPMENT: FUTURE DIRECTIONS

Chairman: W. J. Clarke

Fundamental Research

The general conclusion drawn from this and previous sessions was that there are large gaps in our knowledge of both normal male reproductive physiology and the consequences of vasectomy. A number of areas needing extensive study were identified and discussed.

Granuloma Formation. Varying opinions were expressed regarding the formation of granulomas, both symptomatic and asymptomatic. These differences need to be resolved. An experimental model is needed in which set numbers of sperm can be added and the resulting tissue changes studied.

Effects of Denervation. It is not known whether vas dilation following vasectomy is due to hydrostatic pressure, denervation or both. It is also not known whether the contractility and tonus of the vas are restored after reanastomosis. Peristaltic contraction does return to normal in the urethra and bowel after resection; whether restoration occurs in the vas could be studied using an animal model that could be electrically ejaculated. A systematic determination of sperm counts in human ejaculates following reanastomosis is also required. There is some evidence that they do tend to be low.

Sperm Production. A systematic determination of sperm counts before vasectomy and after reanastomosis is needed. Baseline data are required in order to evaluate later results. Spermatogenesis requires further study to determine if there is impairment in a given percentage of vasectomized men. Dr. Heller's study, described earlier, would indicate that this is not a problem; however, only a small number of subjects were involved. Dr. Coffey has found no difference in the production rate of sperm in rats following vasectomy, and is now studiying the effects of vasectomy before puberty.

Spermatogenic Arrest. The question of what happens to sperm after vasectomy if they are not reabsorbed might be answered by the finding of decreased or absent sperm production. This needs further study. Most patients show only temporary engorgement of the epididymus after vasectomy.

Hormonal Changes. Hormonal patterns could conceivably be altered by vasectomy. Dr. Steinberger noted that the testes produce several different androgens in varying amounts, and that different target tissues are susceptible to different androgens. It is conceivable that changes in the pattern of androgen secretion could induce differential changes in target tissues. Dr. Coffey has looked for such changes in the rat, and has found no differences that are functionally expressed. Dr. Steinberger suggested that basic studies are needed to determine testicular biosynthetic activity. One approach would be to determine the steroid composition of blood entering and leaving the testes.

Uric Acid Metabolism. Dr. Winer has found that vasectomized men and individuals who are azoospermic due to vas blockage for other reasons have very high blood levels of uric acid. The uric acid levels drop following reanastomosis. Studies are needed to determine the uric acid metabolism of normal and vasectomized men, and to investigate whether high levels of uric acid are present. This observation, which has not been reported previously, is the first indication that there may be a systemic metabolic consequence of vasectomy. Clearly, definitive studies are required to determine the extent and seriousness of these findings.

Immunology. It was generally agreed that much more data on the immunological consequences of vasectomy are required. Studies are also needed to determine whether immunological responses may be related to the development of small lesions of the type described by Dr. Bedford in the Rhesus.

Ligation versus Cautery. It was generally agreed that cautery or fulguration may be a more effective procedure than ligation, with fewer complications due to granuloma and hematoma formation. Complications appear to be further reduced by the interposition of fascia between the cut ends. Further comparative studies of various procedure are needed, and simple instruments should be developed for cautery.

External Approaches to Vas Blockade. Dr. Schmidt suggested that it might be feasible to burn the vasal mucosa without making an incision, using a diathermy

field to make the needle white-hot. This should be effective even if the needle were not quite in the muscosa. This approach has been successfully used in dogs. The skin over the vas is stretched and xylocaine is injected. The needle is then inserted using resistance to determine when the lumen is reached. The result would be similar to the vasal block induced by gonorrhea.

Dr. Coffey suggested that a similar approach could be used for the injection of a substance such as absolute ethanol to denature the tissue. Damage would be local because the ethanol would lose its ability to denature as it was diluted. Dr. Schmidt's technique for localization of the lumen could be used for the introduction of many types of substances.

Reversible Techniques: The Most Promising Approaches

Valves. The major problem associated with the reversibility of valves is the buildup of tissue debris so that sperm cannot pass even when the valve is open. Erich Brueschke (M.I.T. Research Institute) has recently been working to design a non-fouling valve, which should eliminate this problem. Dr. Schmidt suggested that tissue abrasion and bleeding will be a problem with any rigid device, and that puncture through the lumen would be possible if the scrotal area were subject to pressure. Even placement in the inguinal area would not be completely safe.

The successful use of a valvular IVD requires tissue ingrowth to insure that sperm cannot pass around the device. Various approaches to the induction of ingrowth should be pursued.

Complications: Physiological and Psychological Sequelae

Dr. Davis noted that the uric acid abnormality found in vasectomized men by Dr. Winer is the first demonstration of what may be a serious complication of vasectomy. He felt that the suggested problems of autoimmunity, thrombophlebitis and other complications have until now remained largely anecdotal. Subsequent discussion was directed toward designing a program for the detection of adverse side effects.

Dr. Coffey noted that suddenly, after assuming for so many years that vasectomy was essentially a harmless technique, observations such as the increased uric acid levels and possibility of lesions are now being made. We don't want to believe that vasectomy has side effects, but new data may not support this conclusion. For example, even large scale studies did not find any serious problem with the use of birth control pills, until the reports of thrombophlebitis became available.

Dr. Paulsen suggested that organized studies could be most easily done if vasectomies were performed in clinics, and these clinics, as well as individual physicians, kept adequate records from the start. He noted that the Veterans Administration accomplished this quite satisfactorily with their cooperative studies involving treatment of prostatic carcinoma with diethylstilbestrol as well as treatment of mild hypertension with various appropriate therapeutic agents.

Identification of Suitable Animal Models

There was extensive discussion of the utility of animal studies at several points during the meeting, generally during the discussion of the use of reversible valves. The major drawback to the use of animals for testing new approaches is the marked species differences that make it difficult to transpose data to the human. However, there are many studies which should be done initially in other species. The concern for animal testing varied extensively among the participants. Several felt that no new drug or device should ever be used in humans without prior testing in suitable animal models, while others expressed the viewpoint that so little animal data can be transferred to the human that such testing is almost useless.

Dr. Coffey strongly objected to the use of rigid IVDs in human volunteers before any animal studies were made. In contrast, Dr. Davis felt that more data is provided by a few human volunteers than by a multitude of animal studies. He has not found that the animal data is transferable to the human, because the tissue composition of the vas differs significantly. Others felt that a balance is needed between the two types of studies, and suggested that animal models are suitable for studies such as biocompatibility. Dr. Brueschke noted that , while a great deal of information is not transferable to the human, such processes as optimization of surface treatment to induce ingrowth can be studied much faster and more easily in animals, with subsequent transfer to human subjects.

Dr. Coffey felt that preliminary safety and materials testing should always be done in animals before human studies are begun. However, there is probably no good animal model for physiological studies. Many surgical procedures have been developed in animals. At the present time, even though there are a huge number of vasectomized men, there are many unknowns about the consequences of this procedure. It is possible that extensive animal studies may begin to provide needed information.

MATERIALS TECHNOLOGY: CURRENT STATUS

Chairman: Allan S. Hoffman

Allan Hoffman (University of Washington) discussed the materials available for use in prosthetic devices with regard to their structure, biological compatibility and potential usefulness. Polymers used for artificial tissues fall into two categories, the soft materials used in artificial organs, valves, ducts, tendons, breast enhancement, facial prostheses and artificial corneas, and the hard materials used for articial joints and teeth and bone substitutes. Unfortunately, many physicians are ignorant of the properties of the materials used for these functions.

The criteria used for the selection of biomaterials include: 1) they must have the required physical properties, 2) they must be easy to purify, fabricate and sterilize, 3) they must maintain their physical properties and function over the desired time period, and 4) they must not produce any undesirable side

reactions. Biomaterials may be plastics, metals or ceramics, and are used in the form of fibers, films, foams, tubes, rods, etc.

The interconversions between physical states varies for different types of substances and in part determines the functions for which they can be used at room or body temperature. The average molecular weights of biologically useful polymers are generally in the range of 25,000 - 300,000. Smaller molecules generally have poor physical properties, e.g. they melt at low temperatures, have low viscosity, etc. and larger molcules are generally too hard to process. The same molecular weight range is generally seen for biologically important proteins, such as albumin, and very large complex molecules tend to utilize subunits whose individual molecular weights are below 300,000.

A major problem with the use of plastics in the body is that most commercial products contain additives such as plasticizers, antioxidants and u.v. stabilizers, as well as catalyst fragments and polymeric material of low molecular weight. Many of these substances can be released from the prosthesis over a period of time. For example, the use of vinyl material may soon be prohibited for use in blood bags because released plasticizer material has been found in the blood and liver. It is also important to remember that if chemical agents are used for sterilization, problems may result from remaining traces of these chemicals after a device is implanted.

Materials which show potential for use as prostheses have been screened in one test using a pseudo-extracellular fluid whose composition is similar to physiological conditions.

It was suggested earlier that any substance used to block the vas deferens should adhere well to, and therefore probably require ingrowth from, the wall of the vas, in order to insure permanence and total impenetrability to sperm. The degree of tissue adhesion to different materials could be studied by implanting sutures subcutaneously for varying lengths of time, followed by measurement of the force required to remove them. In order to provide reversible sterilization, adhesion should be great enough to prevent sperm passage, but should not be so great that removal causes extensive tissue damage.

Possibilities for prosthetic devices designed to block the vas deferens include: 1) porous core materials, 2) a porous core filled and coated with a hydrogel, 3) a hollow fiber with the proper negative charge, possibly coated with hydrogel, and 4) a solid or porous core coated with flocculated fibrils.

References, Appendix 2

1. Free, M. J. 1975. Development of a reversible intravasal occlusive device (RIOD), pp. 124-139. In: Control of Male Fertility, J. J. Sciarra, C. Markland, and J. J. Speidel (eds.). Harper & Row, Inc., MD.

2. Free, M. J., R. E. Filipy, R. R. Adee, and T. M. Fish. 1976. Technology for mechanical fallopian tube-blocking devices, pp. 239-252. In: Advances in Female Sterilization Techniques, J. J. Sciarra, W. Droegmueller, and J. J. Speidel (eds.). Harper & Row, Inc., MD.

3. Free, M. J. 1974. Animal experiments with a reversible intravasal occlusive device (RIOD). (Abstract) Proc. Int. Congress of Physiological Sciences, New Delhi, India, October, 1974.

4. Brueschke, E. E., L. J. D. Zaneveld, M . J. Free, and J. R. Wingfield. 1976. Vas deferens contraceptive methodology, pp. 543-555. In: Human Semen and Fertility Regulation in Men, E. S. E. Hafez, (ed.). C. V. Mosby Co., MO.

5. Free, M. J. 1976. Reversible Intravasal Occlusive Device. U.S. Patent 3,990,434.

6. Free, M. J. 1979. Reversible Intravasal Devices: State of the Art. An invited contribution to a Workshop on Reversal of Sterilization, sponsored by PARFR, December 4-6, 1977, San Francisco, CA.

7. Adams, R. J. 1978. Report on the effect of a reversible intravasal occlusive device (RIOD) in subhuman primates. The Johns Hopkins University, School of Medicine, MD.

Development of a Reversible Intravasal Occlusive Device

(1)

MICHAEL J. FREE, Ph.D.

RATIONALE FOR A REVERSIBLE INTRAVASAL OCCLUSIVE DEVICE

The question of reversibility is causing some divergence in the objectives of medical scientists and clinicians working in the area of surgical sterilization of the male. From a behavioral point of view, the question is whether more people would accept vas occlusion if it were a reversible procedure. From a technical point of view, the question concerns the ease and consistency with which sperm can be returned to the ejaculate by whatever means and whether these sperm are quantitatively adequate to fertilize. From a clinical standpoint, the question includes concern for the ease and safety of the procedure, as well as its efficacy, and whether implanted reversible devices would constitute a significant improvement over surgical reanastomosis when the total welfare of the patient is considered.

The behavioral question is likely to remain academic unless surgical approaches to sterilization become truly reversible. It should be debated, however, with reference to specific populations, customs and economic situations. We have based our efforts on the particular needs and problems of developing countries where, in the words of Pai (1), ". . . one of the barriers to the acceptance of sterilization is the fear of death of children or spouse, as sterilization is considered as a drastic, irreversible method. The greater challenge, therefore, in the mass movement for voluntary sterilization is the mobilization of total resources to make recanalization a greater reality. Of the 203,363 sterilized individuals in Greater Bombay, only 291 individuals sought recanalization. The need is not great but the confidence reversibility generates will accelerate the pace of acceptance."

On a technical level, reversibility of vas occlusion would be simpler and may be more successful if it involved manipulating an implanted occlusive

Michael J. Free, Ph.D., Medical Sciences Section, Biology Department, Battelle Pacific Northwest Laboratories, Richland, Washington.

This work would not have been possible without the multidisciplinary cooperation available at the Battelle Pacific Northwest Laboratories. I am particularly appreciative of the contributions made by Tom Fish of the Battelle Polymer Engineering Laboratory.

device rather than surgically reanastomosing the transected vas. With our objectives we do not see the need for sophisticated valve devices with limitless on-off cycles. Rather we aim at a reliable combination of surgical technique and implantable device that will markedly improve the success rate of sperm restoration through one off-on-off cycle when contrasted to general clinical experience with surgical reanastomosis (2). To achieve this goal with overall clinical acceptability in mind, we have established the following criteria:

1. Installation in the vas deferens will produce minimal disturbance to blood, nerve, lymph and muscle continuity.
2. The device will bind to the vas by allowing and encouraging tissue ingrowth.
3. The device will respond to tissue deformation and muscle compression without damage or irritation.
4. The closed mode will completely block sperm passage.
5. The device will be easily reversible through surgical intervention.
6. Sperm passage will not be impeded nor will sperm be altered in the open mode.
7. The devices will be inexpensive to manufacture.

We do not know at this time if there are inherent limitations to successful restoration of fertility after long-term vas occlusion. We are aware of the probability of autoimmunity that may prevent restoration of fertility even though sperm are restored to the ejaculate (3) and of the possibility of changes in the epididymis that may impair sperm transport in the lower tract (4). Nevertheless, judging by the fertility rates reported for more successful individual series of surgical reanastomoses [55%, (5)] compared with general clinical experience [20%, (2)], inherent limitations to restoration of fertility after vas occlusion leave much room for improvement. Additionally, questions concerning the fertility of sperm after vas occlusion will resolve quite quickly when vas patency can be easily restored. In the following pages our concept for a reversible intravasal occlusive device (RIOD) is outlined, our progress in small animal models is described and our major problems and responses to them are discussed.

CONCEPT FOR A RIOD

Our concept is illustrated in Fig. 1, which shows a longitudinal drawing (Fig. 1A) of the first prototype ($RIOD_1$) and a graphic representation of the device installed in the vas deferens (Fig. 1B). The essential features are as follows: 1) three simple components are molded from a single polymeric material; 2) a porous structure is on the outside of the end piece tubes to permit tissue ingrowth; 3) no transection or ligation of the vas deferens and

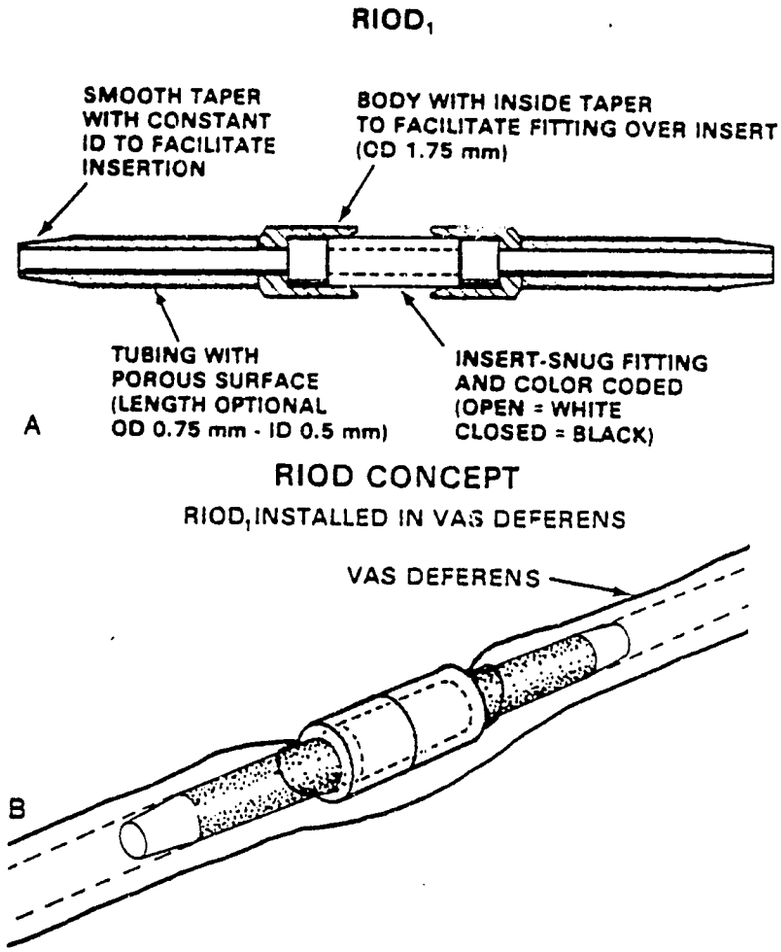

FIG. 1. The RIOD concept. *A*. Longitudinal section of $RIOD_1$. *B*. $RIOD_1$ installed in the vas deferens.

associated nerves and vessels is necessary; and 4) reversal is accomplished by interchanging the color-coded connecting piece (black plug, white tube).

Installation procedures are illustrated in Fig. 2, which shows the four stages of installation of a $RIOD_2$ into a rabbit vas. The initial puncture of the vas is made with a tapered microsurgical tool and enlarged with a blunted 19 g hypodermic needle. Steps are taken at the time of installation to remove the vas lumen epithelium at the vas–RIOD interface. These steps and various features of RIOD design and installation, including the dimensions, component materials and surface pore shape and size, have been varied in the

FIG. 2. Installation of the RIOD$_2$ (open mode) in vas deferens of rabbit. *A*. Proximal end piece installed. *B*. Both end pieces installed. *C*. Interconnecting tube inserted into proximal end piece. *D*. Installation complete.

course of development and are still evolving at this time. They will be discussed further in the sections on RIOD problems and solutions.

PROGRESS WITH THE RIOD

Details of two types of surface porosity for tissue ingrowth are shown in the scanning electron photomicrographs (Fig. 3). Parts of A and B show two different magnifications of a surface treatment used on ethylene vinyl acetate tubing in which surface bubbles are generated in the molding process, then broken open with abrasives. Pore sizes range from 20 to 50 μm. Parts C and D

B
B

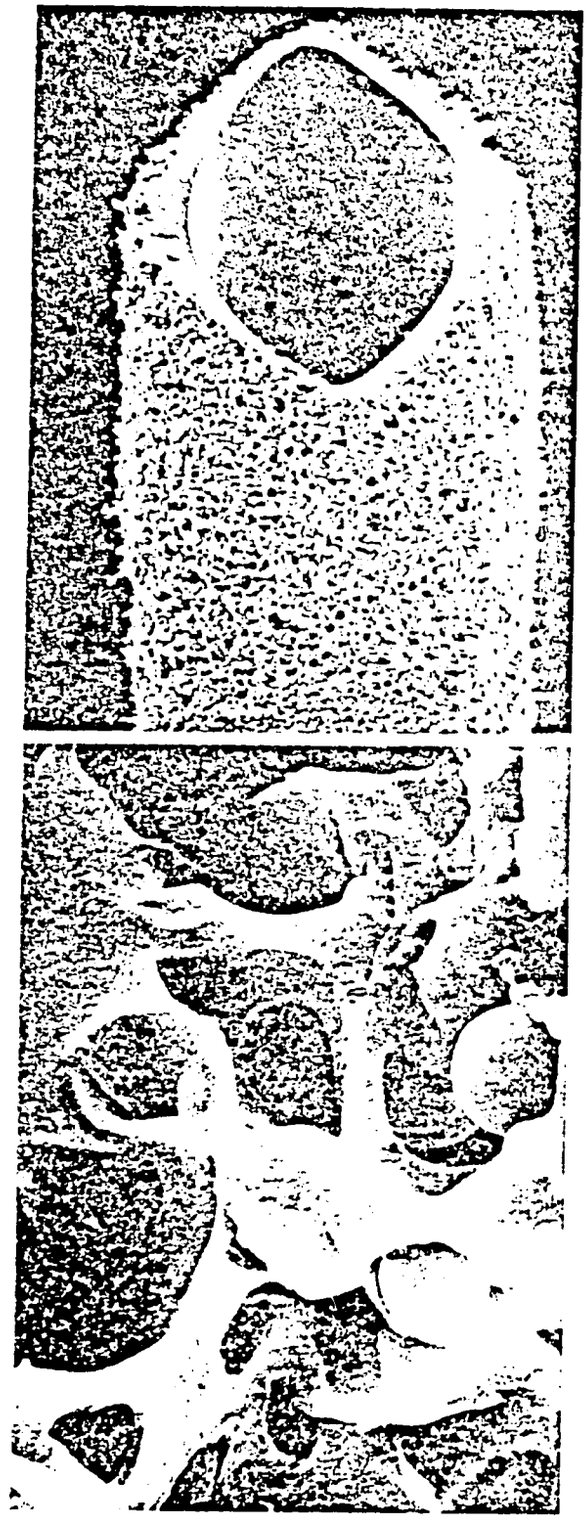

FIG. 3. Scanning electron photomicrographs of porous surfaces for the RIOD-vas interface. *A*. Abraded surface on ethylene vinyl acetate tubing. ×100. *B*. Same as A. ×1000. *C*. Dip-coated surface on polyurethane tubing. ×40. *D*. Same as C. ×3000.

FIG. 4. Morphology of the RIOD-implanted vas. *A*. Right vas of guinea pig 51 at 5 months following $RIOD_2$ installation in the open mode. *B*. Same as A, with serosal connective tissue incised. *C*. Reproductive tract of rabbit 10, 1 months following $RIOD_2$ installation in the closed mode.

TABLE 1. Results of Mating Guinea Pigs after $RIOD_1$ Installation

Guinea Pig Identification	RIOD Mode	Births		Time from Introduction of Female	
		Total	Live	To Removal of Female (days)	To Birth of Litter (days)
46	Closed	0	0	99	–
48	Closed	0	0	99	–
50	Closed	0	0	99	–
47	Open	0	0	39*	–
49	Open	3	3	88	147
51	Open	5	2	99	122

* Both male and female died of acute bacterial infection.

show a treatment used on polyurethane involving dip-coating and subsequent removal of particles layered on the surface of the tube. In this example pore sizes range from 10 to 20 μm but can be varied in size and shape.

Figure 4 shows the morphology of the vas after RIOD implantation for 5 months (open mode) in a guinea pig (Fig. 4A, B) and for 1 month (closed mode) in a rabbit (Fig. 4C). The RIOD body, which lies outside of the vas, is characteristically overgrown with thin connective tissue (Fig. 4A). In Fig. 4B this tissue has been cut to expose the RIOD body containing the white connecting tube. The typical response to vas occlusion in the rabbit is seen in Fig. 4C. The cauda epididymidis and proximal vas are swollen and engorged with sperm.

Histologic cross-sections of the RIOD–vas interface in the guinea pig after 5 months of implantation (Fig. 5A, B) show connective tissue ingrowth into the surface pores. In these examples the RIOD surface texture was as in Fig. 3A and B, and the epithelium was destroyed at the time of installation using a battery-driven cautery and bipolar electrode specially designed for use in the vas deferens (6).

Breeding trials with six guinea pigs implanted bilaterally with $RIOD_1$ are shown in Table 1. These data from the first prototype demonstrated the feasibility of the RIOD concept. Sperm counts from four rabbits implanted bilaterally with $RIOD_2$ in the open mode are shown in Fig. 6. After a brief postsurgical drop subsequent sperm counts and percent motility were generally in the normal range. Sperm counts in rabbits after bilateral installation of $RIOD_2$ in the closed mode (Fig. 7) fell to zero after the first ejaculate and remained at zero for the 2-month trial period.

RIOD PROBLEMS AND SOLUTIONS

First prototypes (Fig. 1) were fabricated from ethylene vinyl acetate tubing with an internal diameter (ID) of 0.5 mm. Although considerably more com-



FIG. 5. Histology of the RIOD–vas interface. *A*. Section through the right vas and indwelling $RIOD_1$ of guinea pig 51, 5 months after installation. ×350. *B*. Section through the right vas and indwelling $RIOD_1$ of guinea pig 46, 5 months after installation. ×350.

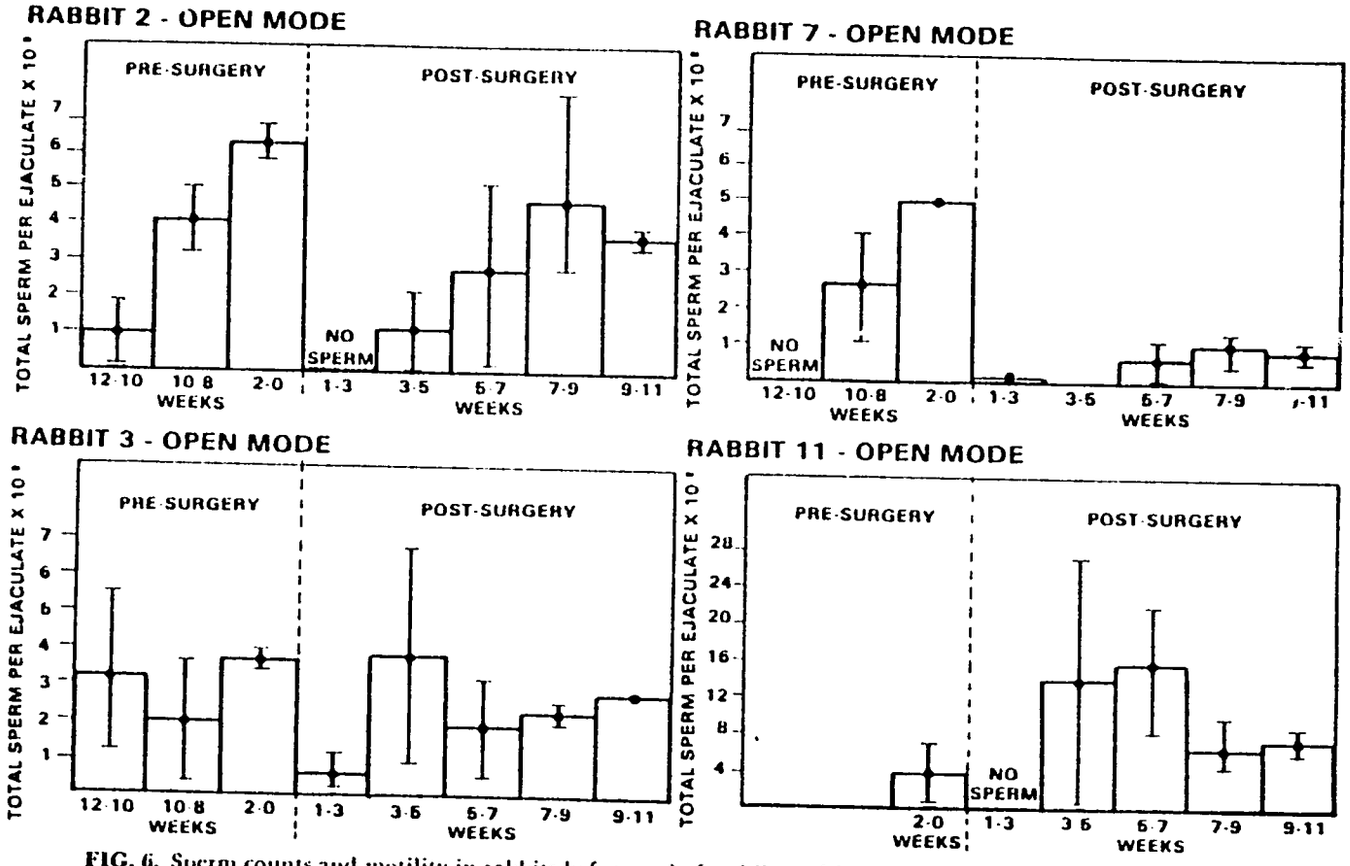

FIG. 6. Sperm counts and motility in rabbits before and after bilateral installation of $RIOD_2$ in the open mode.

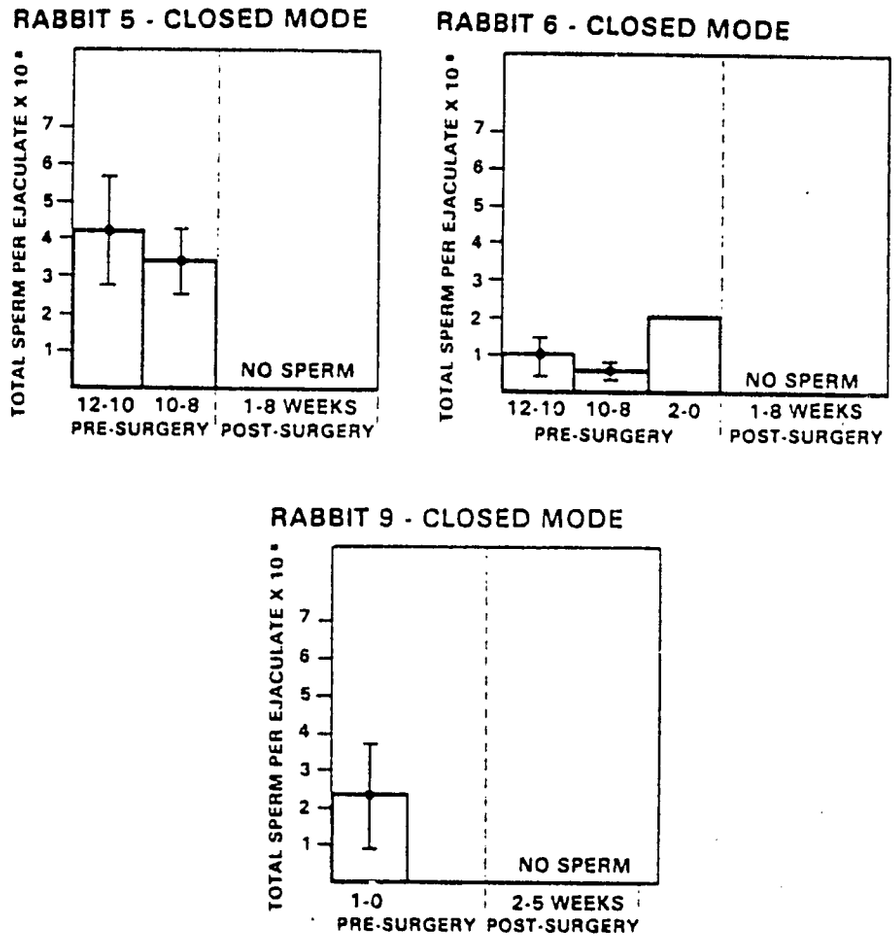

FIG. 7. Sperm counts and motility in rabbits before and after bilateral installation of $RIOD_2$ in closed mode.

pliant than polyethylene, it was stiff enough to erode through the vas wall in some cases (Fig. 8). This erosion usually occurred on the distal end of the RIOD leaving the vas occluded by the ingrown proximal end and interconnecting plug. The ID of $RIOD_1$ (0.5 mm) also appeared inadequate for the normal passage of sperm in the rabbit (Table 2).

$RIOD_2$ (Fig. 9) was developed in response to these specific problems. It was fabricated from soft polyurethane with an ID of 0.75 mm. No erosion problems were encountered with this prototype, and sperm passage was normal in the open mode (Fig. 6). However, in a few animals the flexible tubing tended to kink at the tube–body junction (Fig. 10) and some wrinkling of

FIG. 8. Left vas of guinea pig 49. 5 months following installation of $RIOD_1$ in the open mode. The distal stem has eroded through the vas.

TABLE 2. Sperm Counts and Sperm Antibody Titers after $RIOD_1$ Installation in Rabbits

Rabbit Identification	RIOD Mode	Sperm Count (millions/ml) Before RIOD	After RIOD	Reversed	Antibody Titers (K/SIV)* Before RIOD	After RIOD	Reversed
31	Closed	150	0	1 (not motile)	0/2	0/2	0/1.5§
45	Closed	—	—	—	10/2.1	10/2.1	—
34	Open	175	40† (not motile)	—	0/2	0/2‡	—
49	Open	—	—	—	0/1.7	0/1.7	—

* K = Kibrick macroscopic sperm agglutination; SIV = sperm immobilization values.

† After surgical flush to remove debris.

‡ SIV rose to high levels between 55 and 77 days after installation. Autopsy revealed that distal RIOD stem had broken through vas on right side.

§ Between 13 and 23 days postreversal SIV rose to 4.5.

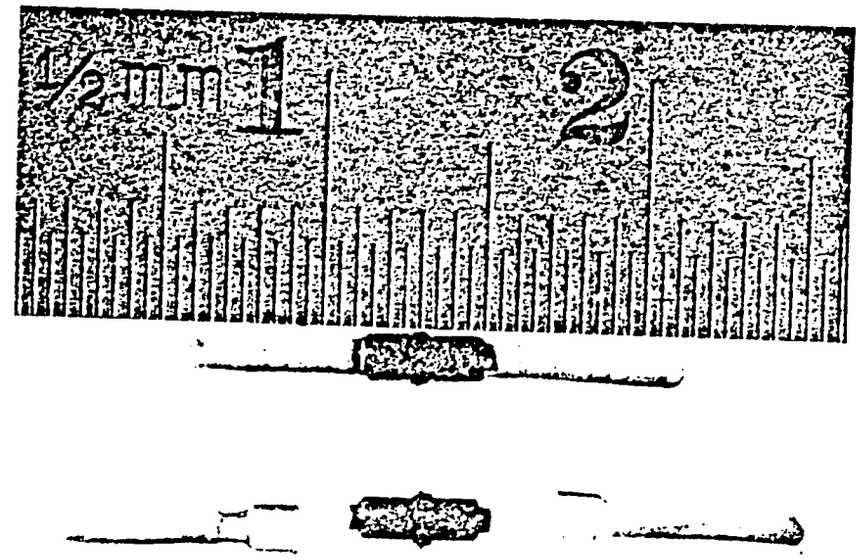

FIG. 9. $RIOD_2$ assembled and disassembled.

the tubing wall close to the tube–body junction was evident in most installations. In addition, the increase in the outer diameter (OD) of the stem from 0.75 to 1 mm necessitated by the increase in ID caused the body–stem junction to be less abrupt and more streamlined, so that in a few instances prior to being anchored by ingrowth and overgrowth the RIOD was propelled into the proximal vas by the peristaltic action of the vas musculature. The most recent prototype (Fig. 11) is designed to solve these problems. The compliance of the tubes becomes progressively from the tip to the tube–body junction to prevent kinking and wrinkling. The rims of the body tubes are extended outward to prevent migration.

In ensuring and maximizing connective tissue ingrowth it seems necessary to destroy the epithelium in the vicinity of the tubing pores. Failure to do this resulted in a layer of atypical, hyperplastic epithelium in guinea pigs that did not grow down into the pores (Fig. 12). A clean cut through the inner muscle layers would seem to be the best way of preparing the vas for ingrowth as the pores are then adjacent to fresh, uninjured cells that can serve as a source of new fibrous tissue. However, the RIOD installation procedure does not lend itself easily to endarterial type stripping techniques. Special stripping tools are being developed at the present time. Meanwhile, techniques that destroy the epithelium in situ are being employed. The vas cautery (6) with bipolar circumferential electrodes has proved useful, but in the rabbit it can leave pockets of epithelium and encourage an influx of

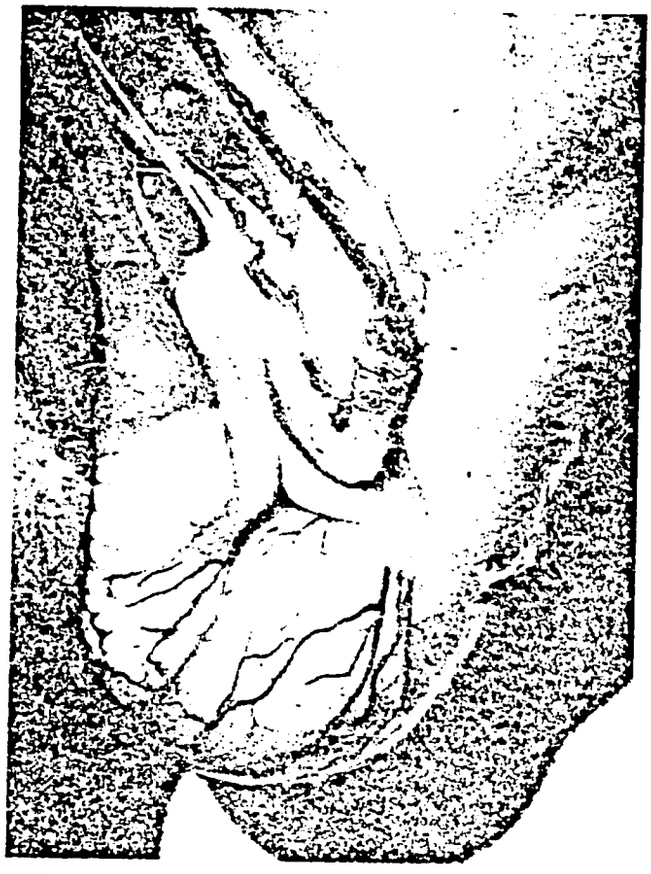

FIG. 10. Left vas of rabbit 5, 2 months following installation of $RIOD_2$ in the closed mode. The soft $RIOD_2$ has kinked at the body–stem junction causing distortion of the vas and adhesions.

FIG. 11. Drawing of $RIOD_3$. See text for details.

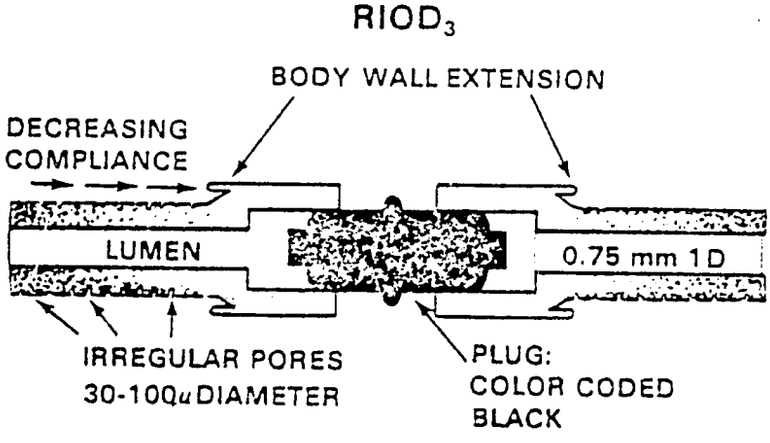

FIG. 12. Section through the right vas of guinea pig 49 and indwelling $RIOD_1$, 5 months following installation. The epithelium has not been destroyed and has become atypical and hyperplastic. Phagocytic cells are present in the RIOD pores. ×350.

phagocytic cells. Ethanol (95%) was not adequate to destroy the epithelium when administered by putting it on and in the pores of the RIOD tubing.

Pore size is also important in promoting good tissue ingrowth. Pore diameters smaller than 25 μm appear inadequate. Good ingrowth is less important for sperm blockage than for mechanical bonding to withstand the traction and manipulation involved during the reversal procedure.

Extrapolation from animal models is a particular problem with procedures involving the vas deferens. Procedural surgical problems arise from the deeply lying vas with relatively little connective tissue in guinea pigs. Evaluation of reversibility is difficult with the rabbit due to the extraordinary buildup and subsequent slow dispersal of sperm and sperm remnants proxi-

mal to the site of occlusion. In some cases, however, we feel that we are observing important problems in animal models that could occur at a much lower and less noticeable frequency in man. In this sense the small animal models may be serving well. Early trials of a more advanced model system in the rhesus monkey are planned for the near future.

REFERENCES

1. PAI DN: Keynote Address of the 2nd International Conference of the Association for Voluntary Sterilization. Geneva, Feb. 1973

2. DERRICK F: Survey on reanastomosis. Reported at the 29th Annual Meeting, American Fertility Society, San Francisco, 1973 and summarized in Family Plan Dig 2:7, 1973

3. FREE MJ, DUNCAN GW: New technology for voluntary sterilization, *in* Population and the New Biology, A Eugenics Society Symposium. New York, Academic Press, 1974. In press

4. SCHMIDT SS: Personal communication

5. PHADKE GM, PHADKE AG: Experiences in the reanastomosis of the vas deferens. J Urol 97:388, 1967

6. DECKER J, CARMICHAEL R: An electrocautery instrument for the fulguration of the vas deferens during vasectomy for sterilization, *in* Proceedings of the 10th Annual Rocky Mountain Bioengineering Symposium. Edited by D Dick. Pittsburgh, Instrument Society of America, 1973

Technology for Mechanical Fallopian Tube-Blocking Devices

MICHAEL J. FREE, Ph.D.

RONALD E. FILIPY, M.S.

ROY R. ADEE, B.S.

TOM M. FISH

Based on what is known of oviduct physiology, the clinical literature on tubal occlusion and the few available preliminary trials of intratubal occlusive devices, we have attempted to list the imperatives for successful mechanical tube-blocking devices. From our own experience of bioimplants, particularly in the vas deferens, we have attempted to lay some ground rules, point out some possible pitfalls and suggest some approaches for design and application of intratubal occlusive devices. These remarks are offered as a basis for considering the feasibility, acceptability and cost benefit of this approach to female sterilization.

ACCESS TO THE FALLOPIAN TUBES

Access to the tubes can be through the uterus and uterotubal junction, through the wall of the isthmus or ampulla or through the fimbria and infundibulum.

TRANSUTERINE APPROACH

The uterotubal route has a clear advantage over the other approaches because hysteroscopy or other transuterine techniques may be used to avoid major surgery. A highly efficacious, transuterine method of tubal closure is therefore an attractive research objective even without considering the possible reversibility.

Several features enhance the advantages of this method: the interstitial portion of the fallopian tube is mechanically well supported and therefore not

Michael J. Free, Ph.D., Ronald E. Filipy, M.S., Roy R. Adee, B.S., and Tom M. Fish, Biology Department, Battelle, Pacific Northwest Laboratories, Richland, Washington 99352, Fuels and Materials Department

easily eroded; it has a narrow lumen; and it is less secretory than other portions of the tube. Additionally, muscular activities at this site can be controlled to some extent with exogenous hormones, a feature that may aid in retaining devices prior to permanent binding through ingrowth or tissue adhesives. The problem of locating the uterotubal junction and delivering the device may be eased by current research and development on instrumentation for hysteroscopy. A number of ingenious solutions have already been devised in association with specific tube-blocking concepts (1, 2).

Promising devices and procedures for installing them through the uterus include cured-in-place silicone rubber intrusions (1, 3) and an annular device that constricts the separated periluminal tissue layers (2). Other concepts for transuterine approaches include preformed plugs with potential for tissue ingrowth; threaded screw devices; microporous plugs for filtering out sperm; and plastic foams, highly compressed for insertion, which expand to fill and grip the tube.

ABDOMINAL APPROACH

Although generally less desirable than the transuterine approach, the abdominal approach may be practical if it involves a similar low failure rate (less than 1%) with no more risk than the present sterilization procedures and, in addition, offers substantial improvement in reversibility. However, the reversal procedure is likely to involve a second major operation with consequent additional risks.

Using this approach, it may be possible to interpose valve devices between the cut end of the transected tube or install bypass devices through the wall of the intact tube as has been done experimentally in the vasa deferentia of various animal species (4, 5). The isthmus offers the best site for implantation. Although the larger lumen of the ampulla offers the device fabricator an easier target, the apparent secretory nature and higher compliance of the segment, together with the persistent muscular activity of the tube, may conjoin against permanent intratubular blockage. Some pattern of tissue ingrowth into the device would almost certainly be required for preformed devices installed in the transected or punctured isthmus.

A few experimental devices have also been installed through or around the fimbria. Fimbriotexy has received only scant attention, but it may be feasible (6).

On the other hand, maintenance of preformed devices in the tubal infundibulum is fraught with potential problems. Since most tubal secretions flow out through the infundibulum, blockage at this point can result in hydrosalpinx. Reversible devices inserted in or through the infundibulum would probably have to be removable plugs in order to restore the area to its normal ovum-collecting function. This precludes tissue ingrowth for anchoring the device, even if such ingrowth could be achieved in this highly secretory segment of the tube. Despite these poor indications, preliminary studies have shown that smooth or notched devices installed through the infundibulum and anchored with ligatures or clips can be made to stay in place in animals (7) and humans (8). It is possible that these devices permit the passage of fluids

(and sperm) between the device and tubal wall but preclude the passage of ova.

COMPATIBILITY BETWEEN DEVICE AND TUBAL TISSUES

COMPLIANCE MATCHING

One clear finding from intravasal device development has been the need for compliance matching between the device and the vas deferens, and should therefore be considered in any implanted tube-blocking device. Metal, ceramic and other rigid structures, semiflexible plastics such as polyethylene, and even flexible types of ethylene vinyl acetate have frequently eroded through the muscle of the vas wall in guinea pigs, rabbits, dogs and monkeys. Only soft devices of polyurethane (5) and silicone rubber (4) have proved sufficiently flexible in the vas deferens. The tissue erosion arising from compliance mismatch may be due to mechanical stresses on the superficial vas deferens resulting from movements of the scrotum. If this is the case, the fallopian tube may withstand stiffer devices than the vas. On the other hand, if the tissue erosion in the male tract results from the muscular activity of the hollow vas deferens itself, acting against the stiffer indwelling device, then a similar result is likely to occur in the female tube. Therefore, compliance matching may be an important consideration for indwelling tubal devices. Preliminary trials to clarify this point should be carried out prior to expensive development of rigid intratubal devices.

CHRONIC IRRITABILITY

Although irritability may be a desired feature of devices into which tissue ingrowth is required, the irritating substances should ideally be an adjunct to the fabric of the device. The device itself, destined for long-term residence in the body, should be a well defined inert material and in a pure state, free of plasticizers and impurities that may be chemically toxic or potentially carcinogenic. From our experience in the vas deferens, subacute inflammatory response at the device-vas wall interface (Fig. 1A) is, unfortunately, a common response to devices that have no such effect on tissues outside the vas deferens (Fig. 1B). This response, characteristically neutrophil and macrophage infiltration (Fig. 2), may be due to low level mechanical irritation or to disturbance of the immunologic barriers, allowing antigenic sperm to come in contact with immunologically reactive tissues. The inflammatory response of the vasal lumen tissues to an indwelling device occurs in the untreated vas as well as in the vas which has been electrocoagulated, reamed or treated with cytotoxic substances to remove the mucosa (with the intention of promoting fibrous ingrowth). The fallopian tube may respond in a similar fashion, since it is similar to the vas in many structural respects, is subject to mechanical irritation and has an immunologic barrier protecting the submucosal tissues from the more or less antigenic semen, sperm and ova.

We do not know how to avoid this inflammation at present, nor whether it disappears completely in time. It does not appear to be specific to any particular material used in device fabrication and is still present in the vasa of guinea

FIG. 1. Photomicrograph of a vas-device interface in rabbit, 71 days after installation. *A*. Inside the lumen, showing subacute inflammation typical of this site. Sperm can be seen in one area of the interface. (X350) *B*. Outside the vas, showing the absence of inflammation in the vas muscle tissues associated with extra-luminal portions of the device. (X100)

pigs, rabbits and rhesus monkeys after 5, 2.5 and 2 months, respectively. However, the clear signs of irritation evident at these earlier stages were less evident after 12 months in guinea pigs and, furthermore, neutrophil infiltration appeared to be associated with the presence of sperm in each species. Since accumulated sperm masses do not occur in the female tract it is possible that irritation due to intratubular devices may be absent or less severe than in the male counterpart.

FORMATION OF A PERMANENTLY BOUND TUBE-DEVICE INTERFACE

Tubal occluding substances that are placed into the tubes in a fluid state, thereby conforming to the invaginations and contortions of the tubal lumen and extending throughout most of the isthmus, appear to remain in place in animal species (1). Shorter preformed devices may need some type of tissue ingrowth to bind them permanently to the tubal lumen tissues.

B

TEXTURED SURFACES FOR TISSUE INGROWTH

Surfaces suitable for ingrowth may take the form of meshes or flocking bound onto the outside of suitable tubing. However, when installing devices in the vas deferens with a view toward reversibility, we have found it essential to create the largest possible internal diameter through the device to minimize blocking by cell debris and to facilitate the eventual free flow of sperm. In order to minimize wall thickness in our device conduits, and also to avoid any additional problems created by bonding different materials, we have developed methods of preparing plastic tubes or plugs with integrally textured outer surfaces (Fig. 3). These surfaces are prepared by coating the tube or plug with particles graded in size according to the desired size of the pores (we normally use 30–120 μ pore diameters for the purpose of tissue ingrowth). The particles can be plastic powders, metal particles or crystalline substances; the surface shown in Fig. 3 was formed with graded sucrose crystals. The coated tubes or plugs are brought into contact with a solvent which dissolves the polymer surface and causes it to flow over the adhering particles. When the



FIG. 2. Photomicrograph of a vas lumen-device interface in guinea pig, 94 days after installation. n, neutrophilis: m, macrophage: g c., giant cells. (X350)

particles are removed mechanically or with a suitable solvent (e.g., sucrose is removed with water) the cellular type of structure shown in Fig. 3 results.

These and other types of integral surface texture were adequate for tissue ingrowth as indicated by the response to the devices obtained in areolar connective tissue (Fig. 4) and in the muscle wall of the rabbit isthmus (Fig. 5). In the latter device (Fig. 5), carbon particles were incorporated into the plastic tube to enhance visibility.

FIBROUS INGROWTH IN TUBULAR STRUCTURES

In the vas deferens, active contractions, secretions and accumulating sperm combine to keep the vas separate from the device, with the result that reepithelization can occur in a few days, even after quite severe destruction of the mucosa prior to device installation. The new epithelium is invariably atypical and hyperplastic (Fig. 6). Except at the cut ends of the transected vas, or where the walls of the vas are held in apposition, fibrous scar tissue resulting from preinstallation destruction of the mucosa is often prevented from pene-

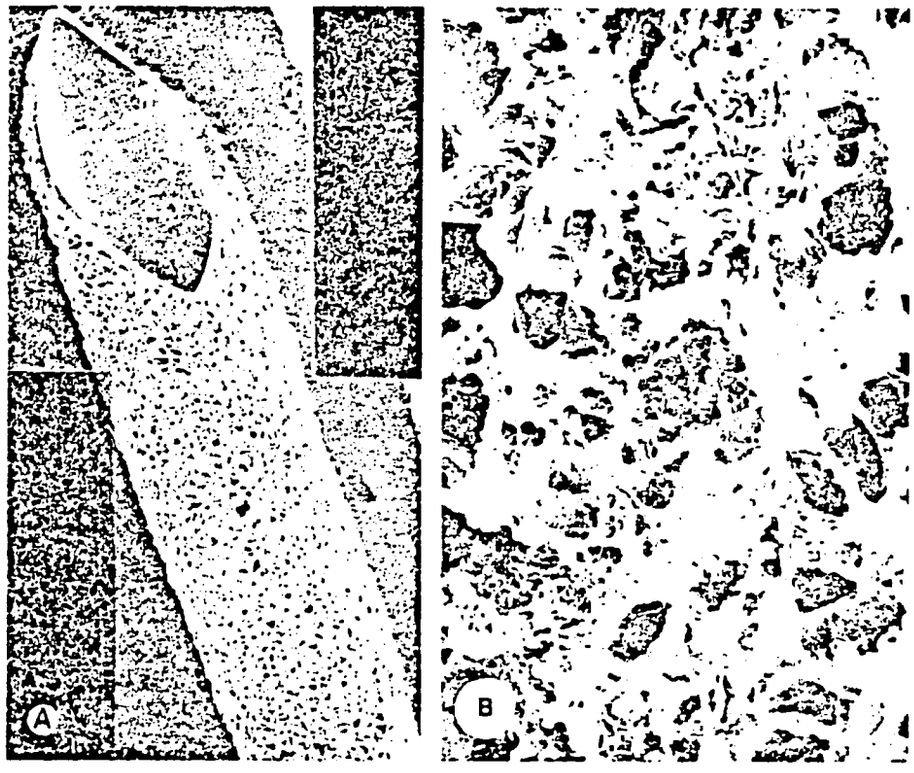

FIG. 3. Scanning election micrograph of polyurethane tubing with integrally textured surface. (*A*, X45, *B*, X300)

trating the device by this regenerated epithelium. Nevertheless, patches of fibrous ingrowth do occur (Fig. 7).

Similar problems seem likely to arise with attempts to induce fibrous ingrowth in the fallopian tubes. Our response to this problem has been to combine initial destruction of the mucosa by electrocoagulation with a sustained irritation brought about by a sclerosing agent coated on the device at the time of installation. Vigorous fibrous ingrowth (Fig. 8) has been much more prevalent in these preparations. A specially designed bipolar electrocautery can be used to destroy the tubal epithelium (Fig. 9) with minimal damage to the underlying muscle layers (9). Reaming devices have also been used successfully for removing vasal mucosa prior to device installation, but these may be less adaptable to the more tortuous and often remote fallopian tube. We have used 70% ethanol, 1% formaldehyde and paraformaldehyde powder as sustained irritants in an attempt to prevent epithelial regrowth and to enhance fibrosis. Other agents such as quinacrine and silver nitrate also lend themselves to this procedure. A more controlled release of irritant may be achieved by incorporating the agent into the surface of the device in a

FIG. 4. Photomicrograph of fibrous tissue ingrowth from areolar connective tissue into integral pores on ethylene vinyl acetate tubing. (X175)

diffusible form. For example, plastic microspheres may lend themselves to this purpose (10).

To facilitate ingrowth in the early stages following device installation, it may be useful to minimize muscle activity of the tubal wall. The action of the female sex steroids might be useful in this respect, although dose levels would have to be carefully regulated to bring about the desired effect (11).

HISTOLOGIC EVALUATION OF EXPERIMENTAL DEVICES

Plastic devices inside biologic tissues cannot be dealt with easily using conventional histologic techniques due to the effect of solvents on the polymer materials, the differential effect of heat on tissue and polymer and distortions arising from sectioning heterogeneous materials. The following procedure has worked well for installing plastic devices in the vas deferens.

Tissues, with device in situ, fixed and stored in 10% neutral buffered formalin were removed from the fixative and washed overnight in 0.2 M

FIG. 5. Photomicrograph of fibrous tissue ingrowth from the muscle of the wall of rabbit isthmus into integral pores on polyurethane tubing. Carbon particles have been incorporated into the polyurethane to increase visibility. (X100)

cacodylate buffer, pH 7.4. They were then dehydrated through 50, 70, 95 and 100% ethanol with a minimum of 30 min at each concentration. After three changes (of 30 min each) in 100% ethanol, Freon T.F. was substituted for ethanol through a graded series (alcohol: Freon 1:1, 1:3, and pure Freon T.F.) with a minimum of 1 hour at each concentration. The tissues were held overnight in pure Freon T.F. and then subjected to critical point drying using Freon 13 as the transitional fluid. After drying, the tissues were placed in JB-4 water soluble embedding medium (Polyscience) with a gentle vacuum until they remained submerged.

The next day the specimens were polymerized in the JB-4 embedding medium (excluding the solution B component) using a cobalt 60 source. Sections of about 3.5μ in thickness were obtained, using a Sorvall JB-4 microtome with glass knives, and were stained with hematoxylin and eosin.

Staining was accomplished with a minimum of wrinkling. A freshly cut section was floated on a drop of water on a microscope slide and transferred onto the surface of warm (65°C) Delafield's hematoxylin for one minute. Using a camel hair brush, the section was transferred and submerged in tap

FIG. 6. Photomicrograph of a vas lumen-device interface in guinea pig, 94 days after installation. The vas is dilated and hyperplastic epithelium has replaced the original mucosa destroyed by electrocoagulation. (X175)

water for rinsing, tranferred to ammoniated water for blueing and then rinsed again in tap water. Counterstaining was accomplished by submerging the section held on the brush in room temperature eosin for 15–30 sec. After rinsing in tap water, the section was mounted on a glass slide.

PROBLEMS ASSOCIATED WITH VISCOELASTICITY

The walls of both the vas and fallopian tubes are viscoelastic and will accommodate to an increased tension. From this property there arise several consequences for indwelling devices: the elastic component of the wall cannot necessarily be relied upon to hold a device in place nor to form a seal between the tube and device. Fluid or cells forced between the device and the muscular wall can dilate the tube beyond the diameter of the device, allowing passage of materials past the device and facilitating movement of the device within the tube. It may be useful to design devices with diameters larger than the normal nondistended tubal lumen diameter so that the tube, upon dilatation,

FIG. 7. Photomicrograph of a vas lumen-device interface in rabbit, 78 days after installation. The mucosa was destroyed by electrocoagulation prior to installation of the device. Substantial fibrous ingrowth has occurred in this area. Areas of fibrous ingrowth occur sporadically in most cases where the vasal mucosa has been adequately destroyed. (X350)

stretches up to its maximum. Difficulties of installation can be overcome by dilating the lumen with successively larger probes prior to inserting the device, although care must be exercised. Too large a device may increase the incidence of tearing and tissue erosion. The ideal size range is usually a matter of trial and error.

SUMMARY: OUTLOOK FOR REVERSIBLE INTRATUBAL DEVICES

The advantages of the transuterine approach compared with other approaches for mechanical occlusion of the fallopian tubes appear overwhelming. In addition, reversibility, which seems no less feasible with transuterine than with abdominal approaches, would be a minor procedure with the transuterine approach and a major operation with other approaches.

Liquid polymers injected and cured in situ show promise as tubular plugs,

FIG. 8. Photomicrograph of a vas lumen-device interface in rabbit, 63 days after installation. The mucosa was destroyed by electrocoagulation prior to installation and the device was coated with 1% formalin in ethanol. Fibrous ingrowth was common throughout the vas-device interface. (X350)

because they can conform to the shape of tubal lumen, extend over a large segment of the tube and make contact with a large area of tubal luminal wall. There remains the problem of damage to the tubal wall when the plug is removed and the consequences on reversibility.

On the other hand, shorter, preformed plugs probably would require tissue ingrowth to secure them in place. To achieve this, the surface of the device must be suitably textured and the tubal epithelium must be removed in the area of device installation and prevented from regenerating. Since epithelium regenerates easily in these tubal structures and since the device may act like a splint to hold the tube open, it may be necessary to extend the irritation at the device-tissue interface over a period of days or weeks. For the device to stay in place over this ingrowth period the diameter should be larger than the normal tubal lumen, the tube should be immobilized if possible and temporary ties, clips or tissue adhesive may be necessary. These ingrown devices may be made reversible by means of a removable plug within a hollow tube. Alternatively, a thin septum within the tube can be pierced to allow passage of sperm and ovum.

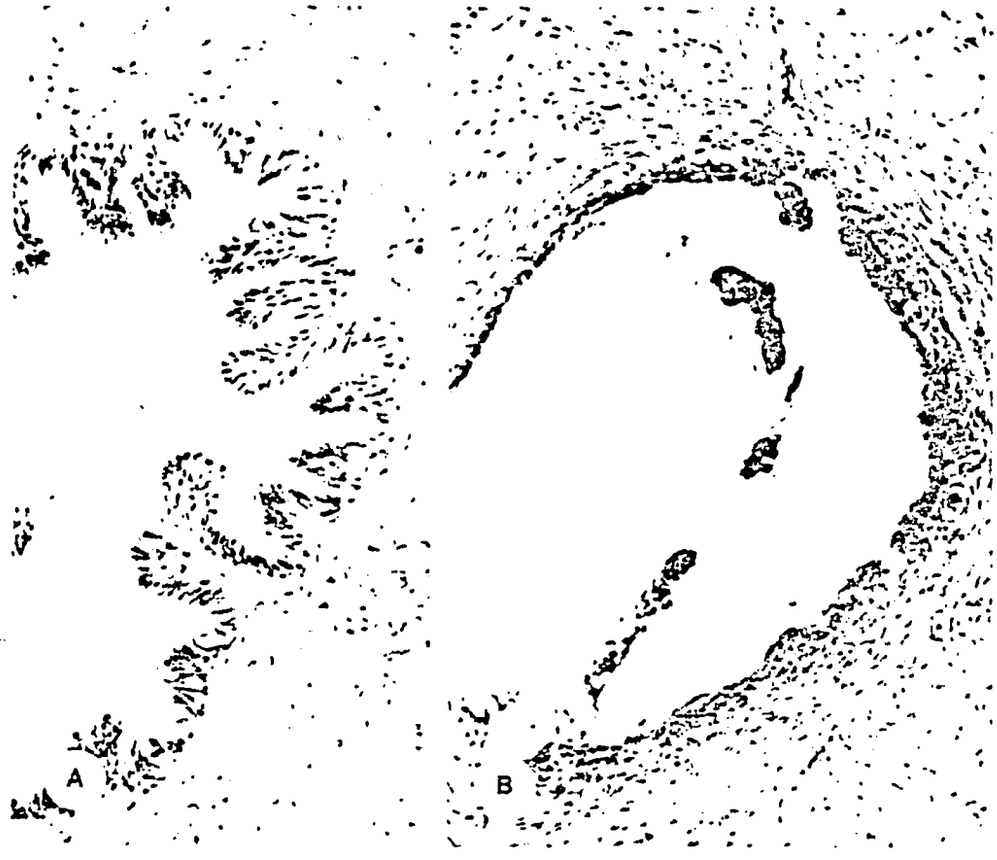

FIG. 9. Destruction of vasal epithelium in human resulting from electrocoagulation with a specially designed bipolar electrocautery. *A*. Normal human vas deferens. (X175) *B*. Human vas deferens after electrocoagulation. (X175)

REFERENCES

1. ERB RA, BALIN H, DAVIS RH, KYRIAZIS GA: System and technique for blocking the fallopian tubes. Advances in Planned Parenthood 9:42, 1974
2. BOLDUC LR: Contraceptive apparatus and procedure. US Patent 3,855,296, 1973
3. RAKSHIT B: The scope of liquid plastics and other chemicals for blocking the fallopian tube. In Richart RH, Prage DJ (eds): Human Sterilization. Springfield, Charles C Thomas, 1972, p 213
4. BREUSCHKE LE, ZANEVELD LJD: Development and evaluation of reversible vas occlusive devices. In Sciarra JJ, Markland C, Speidel JJ (eds): Control of Male Fertility. Hagerstown, Harper & Row, 1975, p 112
5. FREE MJ: Development of a reversible intravasal occlusive device. In Sciarra JJ, Markland C, Speidel JJ (eds): Control of Male Fertility. Hagerstown, Harper & Row, 1975, p 124
6. LAUFE LE, HASSLER C, LOWER BR: Laporatory prototype for reversible female sterilization. In Duncan GW, Fajb RD, Speidel JJ (eds): Female Sterilization: Prognosis for Simplified Outpatient Procedures. New York, Academic Press, 1972, p 65

7. MEEKER CI: Cited in Sciarra JJ: Sterilization of women: a review of new and potentially reversible techniques. In Schima ME, Lubell I, Davis JE, Connell E (eds): Advances in Voluntary Sterilization. Amsterdam, Excerpta Medica, 1974, p 63

8. STEPTOE PC, cited in Tatus H, Ansbacher R: Female sterilization–basic science aspects. In Schima ME, Lubell I, Davis JE, Connell E (eds): Advances in Voluntary Sterilization. Amsterdam, Excerpta Medica, 1974, p 262

9. DECKER J, CARMICHAEL R: An electrocautery instrument for the fulguration of the vas deferens during vasectomy for sterilization. In Dick D (ed): Proceedings of the 10th Annual Rocky Mountain Bioengineering Symposium, Pittsburgh, Instrument Society of America, 1973, p 5

10. HASSLER CR, GARDNER DL, EMMERLING DC, BAYTOS WC, WILLIAMSON K: The study of intrauterine microcapsules as a prolonged drug release form. Proceedings of the San Diego Biomedical Symposium, 13:1, 1974

11. DUKELOW WR, RIEGLE GD: Transport of gametes and survival of the ovum as functions of the oviduct. In Johnson AD, Foley CW (eds): The Oviduct and Its Functions. New York, Academic Press, 1974, p 193

PROCEEDINGS

OF THE INTERNATIONAL UNION OF PHYSIOLOGICAL SCIENCES

VOLUME XI

XXVI INTERNATIONAL CONGRESS

NEW DELHI, 1974

ABSTRACTS OF VOLUNTEER PAPERS

976 ANIMAL EXPERIMENTS WITH A REVERSIBLE INTRAVASAL OCCLUSIVE DEVICE (RIOD).

M.J. Free, Ph.D.
Biology Department, Battelle, Pacific Northwest Laboratories, Richland, WA, U.S.A.

A RIOD consists of three components, two identical endpieces and a central connecting plug (closed mode) or tube (open mode). Each endpiece is 5 mm long, 3.5 mm being 1.0 mm OD X 0.75 mm ID and the remaining 1.5 mm being 1.50 mm OD X 1.25 mm ID. The plug is 1.25 mm OD X 3.5 mm long; the tube is 1.25 mm OD X 0.75 mm ID X 3.5 mm long; each fits snugly into the large portion of the endpieces. Materials used in RIOD fabrication are ethylene vinyl acetate and polyurethane, the outer 60 μm of the small portion of the endpieces textured into a porous structure to permit tissue ingrowth. The endpieces are inserted into the vas lumen through needle punctures in the vas wall and connected to each other outside the vas with the plug or tube. No ligatures are used. RIODs have been implanted in 14 rabbits and 16 guinea pigs in which the vas epithelium had been fulgurated, treated with a sclerosing agent or left intact. Epithelial and/or connective tissue ingrowth occurred in all cases and was usually sufficient to form an apparently compatible and permanent tissue-device union. In fertility tests to date, no pregnancies have occurred in the closed mode and pregnancies have occurred in 75% of the matings in the open mode. RIOD lumen size and compliancy are critically important in minimizing local tissue reaction and maximizing seminal sperm count and motility.

53 vas deferens contraceptive methodology

E. E. Brueschke
L. J. D. Zaneveld
M. J. Free
J. R. Wingfield

There is an increasing tendency for young people to accept voluntary sterilization as a commitment to limiting their families (Bumpass and Presser, 1972) and as a means of avoiding the problems inherent in pills and paraphernalia (Presser and Bumpass, 1972). Unlike vasectomy, which was salvaged from the arsenal of the physician's prophylactic procedures (its original purpose was to prevent retrograde infection in patients undergoing prostatectomy) to become the most widely used method for effecting permanent sterilization in the male, newer vas occlusive techniques are being developed for the specific purpose of sterilization. Unquestionably a major drawback of vasectomy is its relative irreversibility. The surgical technique for vasectomy reversal (vasovasostomy) is relatively complex, and its prospect for success is limited, especially if the original vasectomy was done in such a way as to prevent spontaneous vasovascanastomosis by removing large segments of the vas deferens. The relative permanence of the results of the surgery as currently performed necessitates careful counseling of those who elect to undergo the procedure. Of 1363 physicians responding to a questionnaire, 351 had never attempted vasovasostomy and 542 had performed the operation one or more times (Derrick et al., 1973). In this same study, spermatozoa returned in 38% of the men and the average pregnancy rate was 20%.

Research supported by the Contraceptive Development Branch, Center for Population Research, National Institute of Child Health and Human Development (contract No. NIH NICHD-71-2229) and the Agency for International Development (contract No. AID/csd-3152).

Some see the need for technological innovation only in terms of new surgical tools for carrying out vasovasostomy. These include tissue adhesives (Bornemisza and Furka, 1970; Gursel et al., 1971) or various splints (Steinhardt, 1969). Others believe that reversibility and acceptance of vasectomy would be facilitated by the development of a valvelike device that could be implanted in the vas deferens in lieu of vasectomy and would allow the passage of spermatozoa at the wish of the individual under the control of the physician. The availability of an effective contraceptive device for men, particularly if such a device were truly reversible, would offer significant advantages over other techniques currently available and could be expected to gain wide acceptance and utilization.

In contrast to the typical surgical vasectomy, the development of a reversible occlusive device will provide the medical community with additional options in approaching male sterilization. For example, devices that would allow cycling of the occlusive device from an occluded to a nonoccluded state may minimize some of the immunological side effects (Ansbacher et al., 1972; Alexander, 1972) and may enhance the reestablishment of fertility. Optimally the device should be externally controlled (e.g., by electrical or magnetic means). Surgical manipulation would not decrease the effectiveness of the device as a contraceptive method, however, since most men would meet the requirements for fathering children by having the device in the "on" position only once or twice in their lifetime. External control (by the physician) may make the device especially useful, since the side effects caused by sperm accumulation could be minimized by opening

the valve at infrequent, selected intervals. Engineering problems related to external control need only be solved after the true practicality of such devices is demonstrated.

In developing a vas deferens contraceptive method, a number of complex questions arise relating to the dimensional properties and morphology of the vas, the mechanism of sperm transport and storage, the ability of the vas deferens to grow into a porous surface material, the effect of various substances on sperm motility, the length and diameter of tubes through which spermatozoa can pass, the best types of material to use, methods of vas deferens occlusion, etc. The desired information will depend on the technique to be used, e.g., chemical occlusion, noningrowth devices, or devices that will adhere to the vas by tissue ingrowth into the device. These concepts will also vary if the technique is to be reversible.

THE VAS DEFERENS

Anatomy

The vas deferens is an extremely muscular, tubular structure connecting the epididymis to the urethra. Starting at the epididymis, the scrotal portion of the vas ascends into the

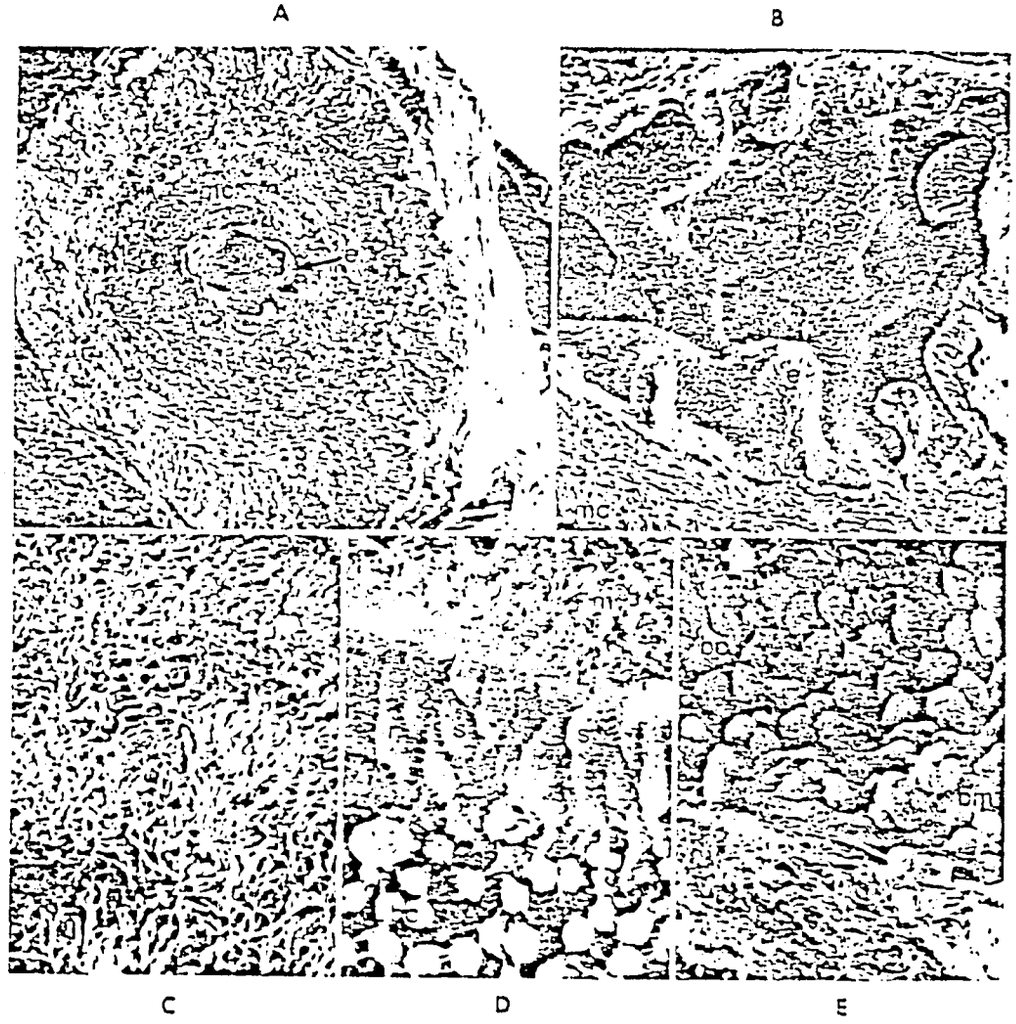

Fig. 53-1. A, Cross section of human vas deferens. Note relative thickness of luminal epithelium *(e)* and muscle and connective tissue layers *(mc)*. B, Longitudinal section of dog vas deferens showing extreme convolutions of luminal surface, luminal epithelium *(e)*, and muscle and connective tissue *(mc)*. C, Microvilli of human vas. D, Human vas deferens showing columnar cell layer partially lifted off underlying basal cells *(bc)* and basement membrane. Note microvillus surface *(m)*. Columnar cells appear to be attached by connective material. Two types of columnar cells are present, "rectangular" cells *(r)* and "stalked" cells *(s)*. E, Human vas deferens connective tissue layer *(ct)*, basement membrane *(bm)*, and basal cells *(bc)*. (A ×40, B ×125, C ×5000, D ×1000, E ×1000.) (From Brueschke et al., 1974b.)

inguinal canal (inguinal portion) and runs for some distance in the pelvic cavity. At this terminal portion it is frequently surrounded by glandular enlargements, which are termed the ampulla. Just before entering the urethera, the vas fuses with the excretory ducts of the seminal vesicles and forms the ejaculatory duct. The scrotal vas is part of the spermatic cord, which also contains several other structures, including the lymphatics, the spermatic artery and veins that form the pampiniform plexus around the artery, sympathetic nerves, and the internal cremaster muscle. The spermatic cord is surrounded by the tunica vaginalis.

The vas deferens receives its motor innervation from the lumbar sympathetic outflow. The sympathetic fibers reach the pelvis via the hypogastric nerve. The musculature of the vas itself possesses a very dense adrenergic innervation of short neurons; the cell bodies of these neurons are located close to the target organs. They possess large amounts of catecholamines, chiefly norepinephrine. The vas receives its blood supply from the deferential artery, a branch of the inferior vesicle artery (Sjöstrand, 1965).

Structure

The lumen of the vas deferens consists of pseudostratified epithelium that is made up of columnar and basal (cuboidal) cells (Fig. 53-1) (Brueschke et al., 1974b). The columnar cell layer is very easily removed. Manipulation of the vas during surgical procedures should be minimal and delicate if the integrity of the columnar cells is to be maintained. The internal surface of the vas is covered with microvilli (stereocilia) and is usually extremely convoluted. The vas possesses a thick muscular coat that consists of an inner and outer longitudinal muscle layer and an interposed circular muscular layer. The epithelium of the vas is surrounded by a basement membrane and, toward the exterior, by a lamina propria of connective tissue consisting chiefly of collagen fibers but also composed of capillaries, fibrocytes, and occasionally a muscle cell (Nicander and Schantz, 1961; Fährmann and Schuchardt, 1965; Niemi, 1965; Wendlar, 1968).

Precise techniques have been developed for measuring the lumen of the vas (Brueschke et al., 1974c). Because the vas has invaginations and stretch, it is necessary to distinguish between "no resistance" (normal vas lumen) and "significant resistance" (the largest diameter to which the vas can be stretched) luminal sizes. Based on a study of 25 human vas specimens, the mean diameter of the largest gauge that could be entered into the vas with no resistance was 0.85 ± 0.07 mm, and the mean diameter of the probes that met with significant resistance was 1.06 ± 0.12 mm. Analysis of the data suggests normal distribution (Fig. 53-2). The no-resistance population has a smaller variance than the significant-resistance population. As several investigators were involved in the research, the results suggest that it is easier to obtain general agreement as to what "no resistance" feels like rather than to obtain consensus on the feel of "significant resistance." Identical results are normally obtained whether the measurements are performed in situ or after excision. The lumen of the vas varies from patient to patient and from one vas to the other in the same patient. The external mean diameter of 23 human specimens was 2.85 ± 0.43 mm.

The dog has a vas that is similar to but slightly smaller than that of the human. The mean no-resistance luminal diameter is 0.77 ± 0.07 mm, and the mean significant-resistance diameter is 0.98 ± 0.08 mm (Fig. 53-2). These dog vas mean values differ from the mean size of the human vas by 0.086 mm (no resistance) and 0.084 mm (significant resistance).

Physiology

The majority of spermatozoa are stored in the epididymis and are transported through the vas at the time of ejaculation by a series of coordinated contractions that are controlled by the release of norepinephrine from the nerve endings. Approximately 100 to 500 million spermatozoa pass through the vas at one time, a fact that explains the necessity for the heavy musculature that surrounds the vas deferens. Approximately 30% of the ejaculated spermatozoa originate from the ampullary portion of the vas. They are either transported there between ejaculatory periods by the spontaneous motility of the human vas or are placed there as a residue from the previous ejaculation. Due to this storage phenomenon, 10 or more ejaculates or a period of 5 to 6 months after vasectomy are frequently required before all spermatozoa disappear from the ejaculate (Freund and Davis, 1969). On the other hand, bilateral vasectomy of the dog results in immediate absence of spermatozoa from the ejaculate (Brueschke et al., 1974a), probably because of the absence of sperm storage outside the epididymis.

Knowledge of the functional anatomy of the vas deferens is obviously important in vas contraceptive methodology. The mucosa is im-

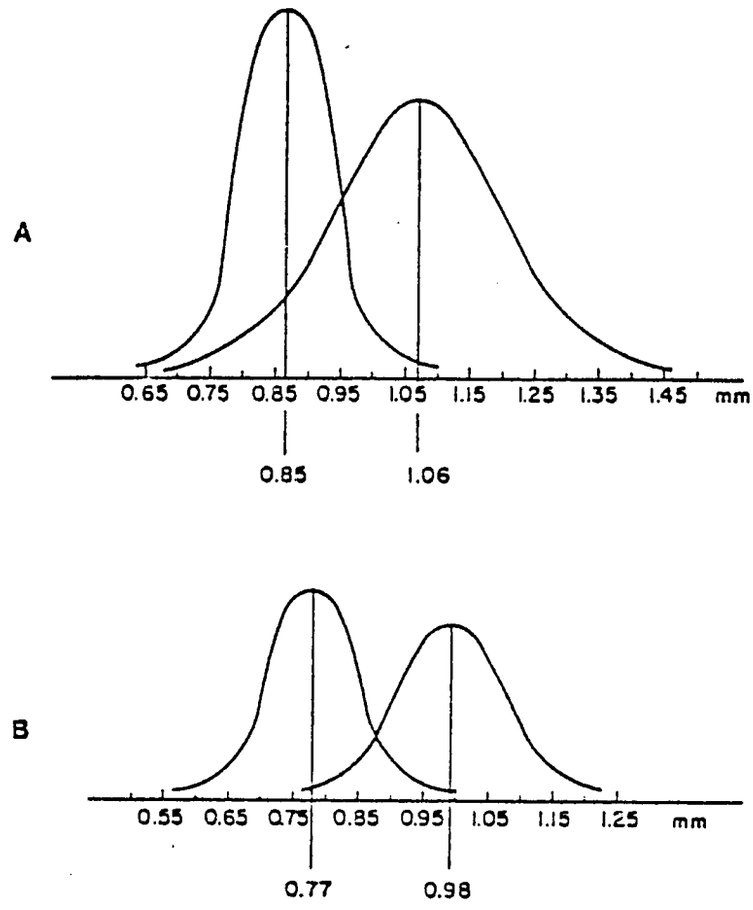

Fig. 53-2. A, Relative size distribution between "no resistance" and "significant resistance" luminal sizes in men. Central values indicate mean for each population. B, Relative size distribution between "no resistance" and "significant resistance" luminal sizes in dogs. (From Brueschke et al., 1974c.)

portant in techniques involving its removal or obliteration. The extent of muscular mass (vas wall thickness, relative muscle mass vs vas epithelium) is important in device design and in devices depending on ingrowth. Such ingrowth depends on fibroblasts rather than epithelial cells, due to their natural tendency to regenerate. In those cases in which device implantation into the vas is contemplated, knowledge of the size of lumen of the human vas deferens and any animal model is essential.

NONDEVICE-RELATED PROCEDURES

Surgical vasectomy

Surgical vasectomy is a simple procedure. It requires only a local anesthetic and can be performed with a minimum of medical formality. While certain small variations in technique do exist, the operation is fairly standardized. The vas deferens is exteriorized through a small incision in the scrotal sac, and a section 0.5 to 1.0 cm in length is removed. The cut ends of the vas are then treated in a variety of ways to ensure that spermatozoa are permanently sealed into the proximal vas and that both ends are physically prevented from rejoining. Despite these precautions, some instances of sperm granuloma have been noted, and recanalization of the sperm path between segments of the transected vas has occurred in a small number of cases. Some means of obliterating the vas lumen is helpful before sutures or clips are applied to close the vas ends. Curettage and electrocautery are probably the most effective methods currently available to accomplish this.

While it is important to ensure that the vas ends are permanently sealed and restrained from rejoining, there is an increasing awareness that some opportunity for future vas rejoining (vasovasostomy) should be built into the vasectomy procedure by removing only a small portion of the vas and making the procedure as atraumatic as possible. Success re-

ported in performing vasovasoanastomosis (Phadke and Phadke, 1967; Schmidt, 1975) underscores the feasibility of reversing surgical sterilization and the need to plan for this possibility while performing the vasectomy operation. Surgical vasectomy and surgical vasovasostomy are discussed in Chapter 47. A starch stent has been used to facilitate vasovasostomy. An artificial vas deferens (anastomosing device) for restoring spermatozoa production when even large segments of the vas have been removed has been successfully tested in dogs (Brueschke et al., 1974d).

Electrocautery

Electrocautery is finding increasing acceptance in the United States as a tool for improving simple surgical vasectomy. A series of 1000 vasectomies has been reported in which no segment of the vas was removed and no ligatures were tied on the vas (Schmidt, 1973). Instead, the lumen of the proximal end was cauterized for 4 mm in such a way that the electrocautery lesion was confined to the epithelium, lamina propria, and part of the muscle wall. The distal end was cauterized on the cut surface only. The sheath of the vas was closed over the distal end using a single ligature. The number of patients in this series now stands at 1500, with no failures and an occurrence of sperm granulomas or other complications in less than 1% of cases (Schmidt, 1975). This compares with failure rates of 0.5% to 3% and a rate of complications as great as 10% following vasectomy by ligation (Gursel et al., 1971; Steinhardt, 1969). A significant advantage is that reanastomosis is technically easier following vasectomy by this procedure because none of the vas has been removed. Transcutaneous electrocautery has been proposed, but the feasibility of this procedure has not yet been demonstrated.

Chemical and ultrasound approaches

Recently the injection of substances that induce scar tissue plugs in the vas has been investigated. Injection of ethanol into the rat vas results in irreversible occlusion and a halt in sperm transport (Freeman and Coffey, 1973; Coffey and Freeman, 1975). Similar results have been reported in men (Freeman, 1975). It has also been shown that quinacrine dihydrochloride has some occlusive effects in the rat vas deferens (Setty et al., 1972). The use of focused ultrasound for transcutaneous vasal cauterization has also been proposed, but this approach is still in the preliminary stage.

DEVICE-RELATED PROCEDURES

Extravasal occlusion

One means of blocking the flow of spermatozoa involves the application of a concentrated force sufficient to collapse the lumen at some point along the vas deferens. If this force can be controlled to the point where it can occlude the lumen without inducing too much trauma, the potential exists for restoration of sperm transport when the pressure is released.

One such technique involves the closure of a V-shaped clip around the vas deferens (Fig. 53-3). This applies a fairly atraumatic, parallel crushing force that closes the luminal area and blocks sperm transport (Jhaver et al., 1971). Since the integrity of the vas remains intact for the most part, removal of the clip allows repair of any induced damage and hence the passage of spermatozoa. Unlike blood vessels, which are highly susceptible to permanent damage and disintegration, the vas deferens is a tough, thick-walled muscular structure that tends to retain healthy tissue even after surgical vasectomy. The clips can also be used in conjunction with surgical vasectomy to occlude the transected ends of the vas and prevent recanalization from occurring. It is then not necessary for the applied crushing force to be atraumatic, since any possibility of reversibility must depend on surgical vasovasoanastomosis. Tantalum clips are currently be-

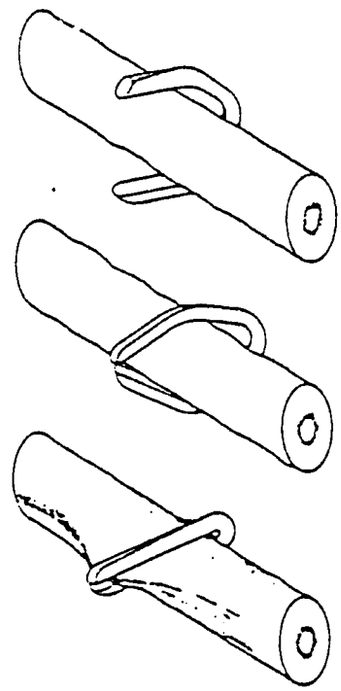

Fig. 53-3. Weck surgical occluding devices showing stages from application through occlusion using Hemoclip.

ing used instead of ligatures in at least one clinic (Moss, 1972) and are being promoted for vas and oviduct occlusion by the manufacturer of Hemoclips.*

The externally applied clip does not fully meet the objectives of a truly reversible device, however. The major reason is the lack of reliability either in the occlusion of the vas or the restoration of function when the clip is removed. Generally, if the clip is applied tightly enough to occlude the vas, trauma occurs and sperm transport cannot be restored. To prevent such trauma, the clip must be applied so loosely that the passage of spermatozoa is not completely halted. In sum, the placement of the clip is really the only part of the system that is under the complete control of the surgeon. The actual reversibility of the procedure is dependent on inherent biological forces.

Intravasal occlusion

One method that suggests itself because of the nature and objectives of the problem consists in placing an object into the luminal area of the vas deferens to interrupt the flow of spermatozoa. The objects and methods of placement are generally limited only by the imagination and creative ability to devise and apply occlusive systems. Two types of occluding methodology may be applied. In one case the device is entirely or almost entirely within the lumen of the vas (intraluminal device). In the other a significant portion of the device protrudes outside the vas (extraluminal device).

Intraluminal devices

The intraluminal devices are placed into the vas either through a small incision, which requires one or two sutures for closure, or a puncture using a suture or hypodermic needle. The blocking device is implanted either with or without a cannula. Devices include cylindrical plugs, spherical beads, or threads of suture material (Lee, 1969; Klapproth and Young, 1973). Reversibility is achieved in these cases by removing the object. Some thought has also been given to intraluminal devices that can be externally actuated by magnetic or other means. A long, balloon-type device that can be inflated to obstruct the lumen has been proposed. Although such ideas may ultimately prove to be impractical, there is great merit in the novelty of their conception.

The disadvantages in this approach are several, however. The invasive procedure can result in scarring at the incision site, which may obliterate the lumen with fibrous tissue and result in permanent blockage. The device may migrate within the lumen, and therefore it must be radiopaque so that it can be located unless some means of anchoring the device is available. Removing the device doubles the surgery on the vas and increases the same risks that are present during insertion.

A typical example is the Brodie reversible intravas device (RIVD) that is composed of polypropylene and consists of a series of connected, progressively smaller spheres. This device is inserted into the vas and removed later when reversibility is desired. In a study of 13 men who volunteered to have the device inserted for periods of from 5 to 15 months, 3 of the patients never became azoospermic because the device eroded through the vas. Of the 10 azoospermic patients, 9 had their devices removed but in none of these men was sperm transport restored (Derrick and Frensilli, 1974).

In order for the blocking device to be effective, it must be matched to the diameter of the vas lumen. Obviously, an incompletely obstructed lumen continues to present an opportunity for sperm to pass around the device. Ideally the device size should be slightly greater than the lumen size, so that the elastic property of the vas may be used to advantage in forming a tight seal around the device. At the time of device placement attempts should probably be made to stretch the vas up to 70% or 80% because a time-related relaxation of the vas around the device will probably occur as the system gradually adjusts and accommodates itself to the presence of the foreign body. Size selection therefore becomes an important problem. The choice of device size will depend on accurate measurement of the luminal diameter, since a statistical distribution of both the luminal diameters and vas elasticity exists among individuals (Brueschke et al., 1974c). Device diameters must be available to provide the best fit for the particular vas.

Even with such precautions, luminal blockage causes a swelling of the vas testicular to the site of occlusion. This is apparently the result of pressure by the accumulated spermatozoa. Such swelling would encourage the transport of spermatozoa around the device. A comparative study was done between sections from testicular and prostatic vas stumps in previously vasectomized dogs (Brueschke, 1975). Increases in luminal diameter testicular to blockage averaged 97% of normal, while the

*Edward Weck & Co., Inc., New York, N.Y.

corresponding increase in the outside diameter was only about 20%, indicating that the luminal increase is partially due to a loss in wall thickness. The vas deferens distal to the side of blockage did not show any significant changes from the normal. Blocking sperm transport by the insertion of a device within the vas lumen is therefore a technique complicated by many other nonobvious biological effects.

Extraluminal devices

Concepts. Devices that can fulfill the requirement of being implantable and fully reversible through some mechanical means also imply a high degree of engineering sophistication in the design of such a mechanism. This sophistication takes two forms. One is the design of the actuating mechanism, the other is miniaturization of the mechanism so that the device can be dimensionally compatible with the vas deferens. The most desirable features of such a device combination would include noninvasive actuation that cannot be deliberately or accidentally controlled by the patient. Actuation by scrotal palpation reduces the degree of sophistication but increases the chance of an unscheduled actuation. The cost/benefit ratio must also be considered in the development of these devices. It is unlikely, for example, that the frequency of reversal will be very high, occurring perhaps no more than several times in the life of a small number of patients. The necessity of minor surgery to actuate the device, provided that the integrity of the vas deferens and device are undisturbed, may not therefore be a deterrent.

The feasibility of devices with simple mechanisms to interrupt sperm flow is well established. Several types of devices and methods of implantation have been evaluated through animal studies and are described by a number of investigators. Two principal methods of implantation are used. One technique requires a longitudinal incision that is several millimeters shorter than the device along the principal axis of the vas. The device is implanted through the incision and held in position by several simple interrupted sutures. An advantage of this technique is that the neuromuscular continuity of the vas is preserved, and peristalsis or other contractile forces necessary for sperm transport are interfered with to a lesser degree. The other technique involves transecting the vas and connecting the two ends by a device, which would contain a valve to either permit or prevent sperm transport. This technique is advantageous in that sperm transport can be stopped very effectively.

In both cases it is helpful to incorporate a system for tissue ingrowth into the device. This is particularly important in the longitudinally implanted devices, since the continuity of the vas is uninterrupted and sperm passage around the device may occur. Tissue ingrowth into a device placed in the transected vas deferens is important to prevent sperm leakage and hence granuloma formation with the attendant possibility of recanalization around the device. To encourage tissue ingrowth, the vas epithelium must be removed along the device, since ingrowth depends on the activity of the connective tissue fibroblasts (Maness et al., 1973; Brueschke and Zaneveld, 1975; Brueschke et al., 1975a). Care must be taken to avoid destruction of the epithelium beyond the ends of the device inlet and outlet tubes, however, since this may cause scar formation.

Two types of tissue ingrowth systems may be designed for a device: (1) material such as Dacron velour, a type of material consisting of many small fibers, is added to its surface, or (2) the surface of the device is made porous, allowing the ingrowth of tissue. Porosity can be achieved with either rigid or flexible (plastic) devices, although the porosity of the surface is more easily controlled in the rigid devices.

Rigid devices. The devices that can be used as extraluminal vas deferens blocking mechanisms may be divided into two classes: (1) all flexible devices that are almost solely composed of some type of soft plastic, with the usual exception of the valving mechanisms, and (2) rigid devices that are to a large extent made of metal. Rigid devices do not readily bend; this is a significant drawback in that they cannot accommodate lateral movement of the vas deferens, i.e., excessive motion of the scrotal area may result in the perforation of such devices through the vas. This was shown by experiments in dogs where devices with rigid inflow and outflow tubes invariably perforated the vas deferens (Brueschke et al., 1975a). Such rigid devices therefore were not considered satisfactory for practical purposes and their use was abandoned.

The rigid inflow and outflow tubes originally seemed practical, since the stainless steel and ceramic used for them are easily made porous. Ceramic materials impregnated with copper particles are flame sprayed onto the stainless steel tubes to the desired thickness. The copper is then leached from the opposite tube, leaving a porous surface that hopefully

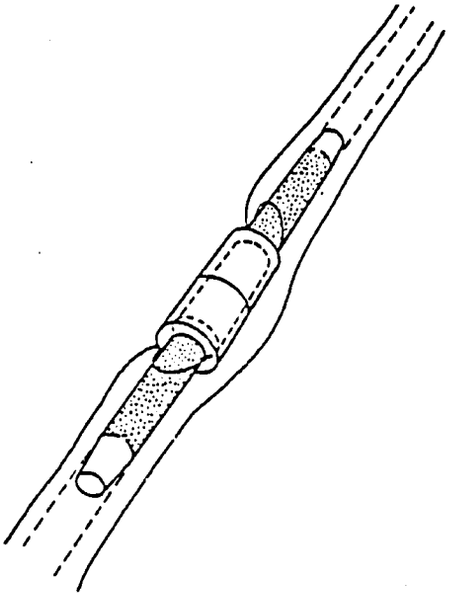

Fig. 53-4. Battelle-Northwest-AID reversible intravasal occlusive device (RIOD) concept.



Fig. 53-5. Textured surface of polyurethane RIOD.

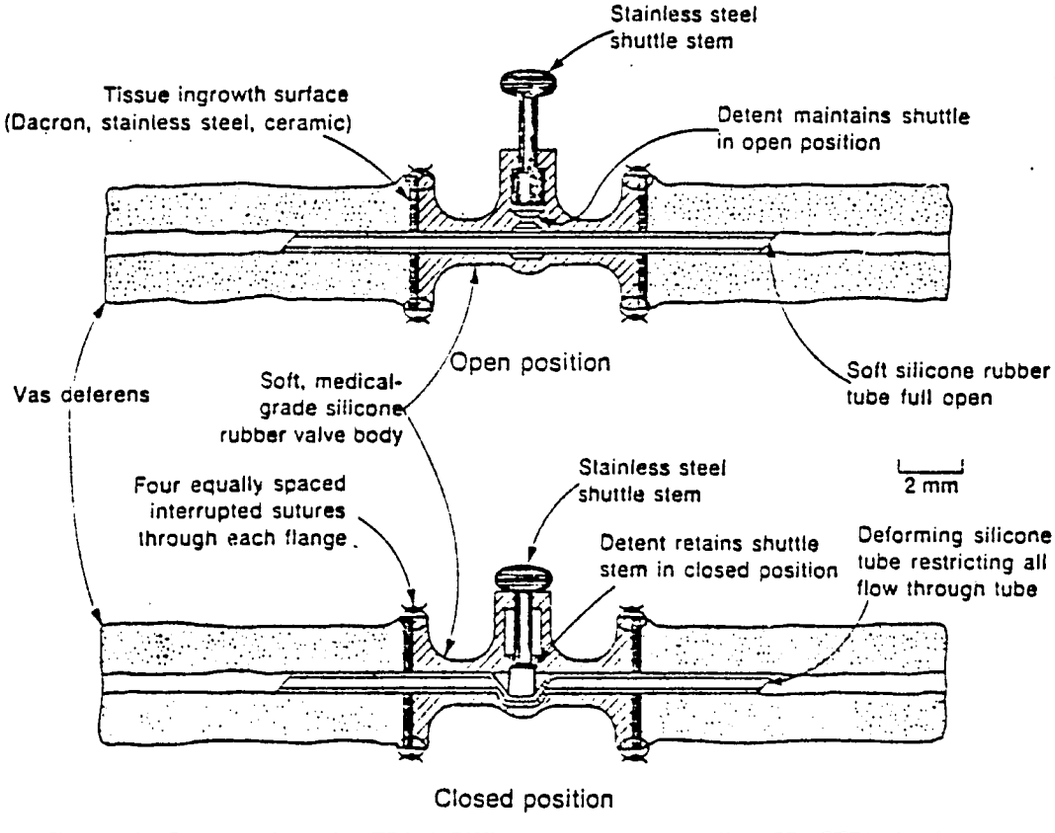

Fig. 53-6. Cross section of IITRI-NICHD spermatozoa controller (SPACER) shuttle stem reversible occlusive device, indicating one closure mechanism. Silicone rubber tube extends through valve body, with constant uniform diameter in spermatozoa passage channel. Tube also serves as vas deferens pilot tube. (From Brueschke et al., 1975b.)

permits ingrowth of connective tissue. A clear-cut evaluation of whether effective tissue ingrowth occurred in such tubes was never obtained because it was difficult to section such tubes and because the use of such devices was abandoned when it was shown that they invariably perforated the dog vas deferens. Additionally, the Dacron velour method of tissue ingrowth was so successful that the porous surface studies were abandoned (Brueschke et al., 1975a).

The use of a rigid valve with gold mesh ingrowth has been studied in guinea pigs (Davis, 1975). A longitudinal incision was used for implantation; in 6 of 18 experiments sperm passed around the device when no perforations were reported. This result may be attributed to the anatomical differences between the scrotal area of the guinea pig on the one hand and that of men and dogs on the other. Also the vas deferens of the guinea pig is much less muscular.

Flexible devices. A plastic device combining the surface porosity and texture required for tissue attachment with flexible end tubes has been tested in guinea pigs (Free and Duncan, 1975). This device, called a reversible intravasal occlusive device (RIOD) (Fig. 53-4), is easily and cheaply fabricated. It can be installed in the vas with a minimum of disturbance to blood, nerve, lymph, and muscle continuity, it permits tissue ingrowth, and it

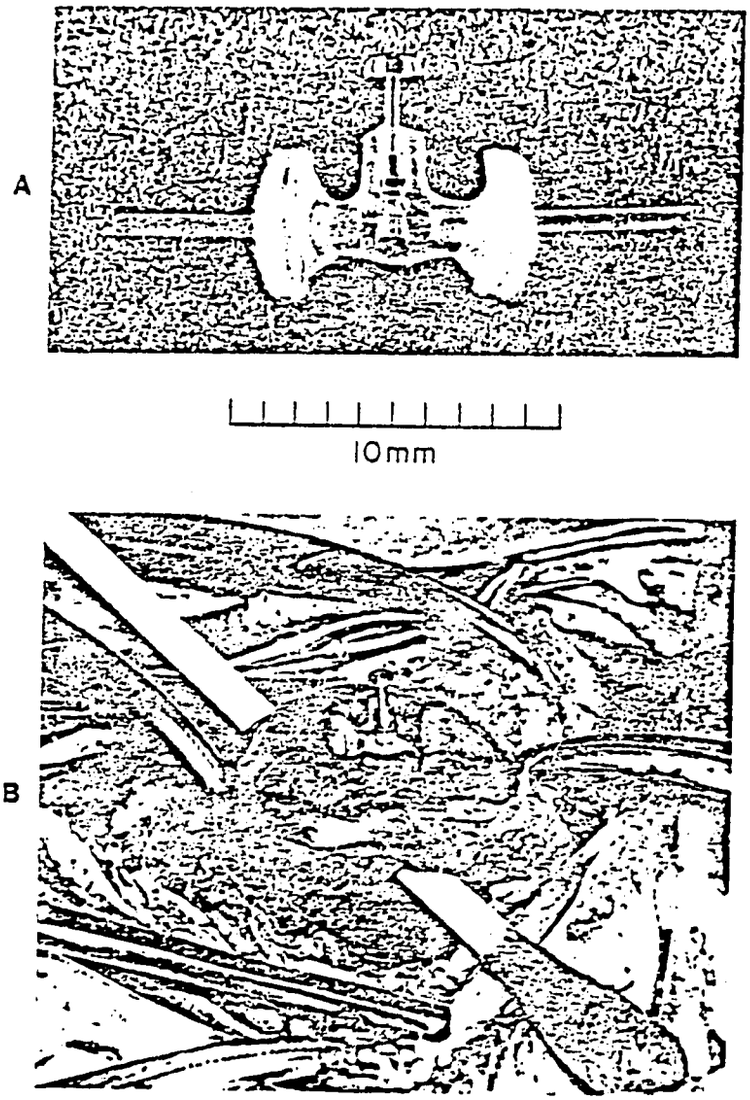

Fig. 53-7. A, Shuttle stem reversible occlusive SPACER with Dacron velour ingrowth surface and Silicone rubber flexible pilot tubes. B, Typical surgical implantation of IITRI-NICHD SPACER in transected vas deferens. Distance between cut ends of vas when sutured to device is about 7 mm. (From Brueschke et al., 1975b.)

is compliant. Pore sizes ranging from 20 to 150 μ are obtained in the surface of ethylene vinyl acetate tubing by generating bubbles in the molding process that are subsequently broken open by means of abrasives. More recent versions of the RIOD have utilized polyurethane in place of ethylene vinyl acetate; these have an outside diameter of 0.8 to 1.0 mm and an inside diameter of 0.5 to 0.7 mm (Fig. 53-5). Normal sperm counts have been achieved in rabbits when this device is installed in the open mode. The RIOD is reversed through surgical intervention by replacing a blocking plug with a patent insert (Free, 1975).

Other flexible device systems developed to date require transection of the vas deferens. Although the objections to interrupting the neuromuscular integrity of the vas deferens are still valid, one procedure that has consistently yielded favorable results uses an all-soft Silicone device called the spermatozoa controller (SPACER) (Brueschke et al., 1975b). The device body is fabricated entirely of medical grade Silicone rubber and is specially molded to incorporate a mechanism for reversibly occluding the transport path of spermatozoa (Fig. 53-6). The valving mechanism consists of a stainless steel shuttle stem that occludes the lumen of the device when it is depressed into the valve body. Two flanges are attached at each end of the device body and are reinforced with Dacron mesh to act as suture rings. Material for tissue ingrowth (Dacron velour) is also applied to these rings and makes direct contact with the cross-sectional area of the transected vas. The ingrowth surface thus provided has proved to be highly effective, and sperm leakage has never been observed. Flexible pilot tubes (0.6 mm outside diameter, 0.3 mm inside diameter) of silicone rubber extend 4 mm beyond the flanges (Fig. 53-7, *A*) and are inserted into the exposed lumen at the transected end of the vas without removal of the epithelium. Four simple interrupted sutures are used to attach the vas end to the suture ring (Figs. 53-6 and 53-7, *B*). Sutureless implant techniques have been studied, and one method employing a barbed clamp has been used successfully to attach the device to the vas end.

The SPACER has been implanted in dogs that are ejaculated weekly, using an artificial vagina (Brueschke et al., 1975b). Typical sperm counts as a function of sample number for an animal implanted with this type of device are shown in Fig. 53-8. An average drop in sperm count of 80% after implant is characteristic. Increasing or decreasing the length or luminal diameter of the device did not increase these sperm counts to preimplant levels. Even so, four separate breeding trials were suc-

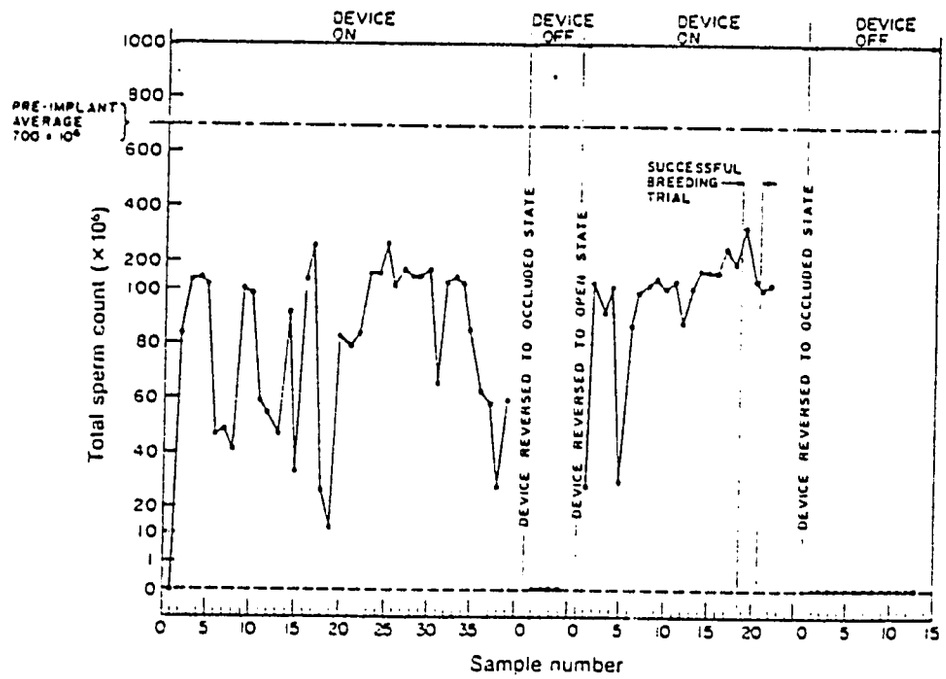

Fig. 53-8. Typical variations in total sperm count in dog associated with SPACER device implant and reversals.

cessful, as each resulted in the production of offspring. The devices had been closed for a period of time prior to two of these trials, halting the flow of spermatozoa (Fig. 53-8). Prior to breeding, the devices were returned to the "on" position, restoring sperm transport. The SPACER has been implanted in the transected vasa of 60 dogs and more than 40 of these are currently under evaluation in long-term experiments to determine the effects of extended periods of implantation in both the open and closed positions. To date the trials have had a high degree of success.

The important features of the SPACER are the soft pilot (inflow and outflow) tubes, the combined suture rings and ingrowth material, and the method of implant. Various mechanisms of occlusion can be adapted to the device as long as these important design features are retained. The total concept may in fact be described as an artificial vas deferens with material properties that permit the incorporation of valve mechanisms. These mechanisms may be as simple or complex as the design constraints and ingenuity of the designer will permit.

A modified version of the SPACER has also been used for implantation into an intact vas by insertion through two longitudinal incisions similar to those used for insertion of the RIOD. Only the valve body protrudes above the vas. To prevent sperm transport through the vas, the section between the flexible tubes is occluded with a clip or by electrocautery.

Nonocclusive devices

It is natural to consider how a similar means of contraception might be obtained without preventing the normal transport of spermatozoa through the vas deferens. This reasoning leads to the concept of another class of devices that function in a manner entirely different from those previously considered. Specifically, a nonocclusive device would not interfere with spermatozoa transport by blocking the path but by redirecting the spermatozoa so that they may be harmlessly exhausted or voided before becoming part of the ejaculate. Operating in this manner, a sperm shunt implant might, for example, redirect the sperm component (usually about 0.5 ml in volume) to the bladder, from which it could be expelled during micturition. Restoration of fertility would involve simply a return of the flow of sperm to the distal portion of the vas deferens. A Y shunt to divert the spermatozoa over a longer path has also been tried (Swartwout and Zaneveld, 1974).

Implants that release spermicidal reagents are also a possibility. A system of this type would not interrupt the flow of spermatozoa and would be less likely to impair spermatogenesis. In addition, the physical response of a system that must undergo long periods of occlusion with a variable degree of confidence in restoring fertility is eliminated. Replacing these problems are, of course, others that involve the pharmacology of the agent to be released, the determination of releasing rates, replacement techniques, and a system of delivery. Even these new considerations do not appear as formidable as they might have prior to the successful testing of devices implanted in the transected vas deferens. With the means to implant sections of artificial vas deferens available, any number of spermicide-releasing systems might be integrated into this design (Brueschke et al., 1974a-c).

VAS DEFERENS CONTRACEPTION AND FAMILY PLANNING

Although male sterilization requires medical skill, an important fact that must be carefully considered is that surgical techniques, whether they are reversible or irreversible, are one of the more effective methods of dealing with population expansion. Male contraception that would not require the application of a high level of knowledge on the part of the patient, as do birth control pills for women, would have an enormous advantage. This is because contraceptives currently in use frequently require a level of education on the part of the patient that is beyond what is implied by the simple prescription. Complications arise in that prescriptions must be refilled or active preventive measures must be taken prior to intercourse. IUDs, for example, have a discontinuance rate of about 50% over a 2-year period. There is in essence no "discontinuance" among people who have undergone sterilization, and this concept may well be of particular benefit in sterilization for men. Thus although the implementation of vas deferens contraceptive methodology requires special medical skills, it is a potent tool for family planning and consequently for population control.

The vasectomy procedures currently available are essentially irreversible because vasovasoanastomosis requires a very high degree of surgical skill and the percentage of patients in whom fertility is restored is not great. A truly reversible method would be attractive to a large number of men who may not wish to permanently interfere with their fertility and want to reserve the option of restoring their fertility at some later date. For most men who

have completed their families, this option would be more a psychological than a practical benefit. However, for younger men who wish to postpone reproduction until they are socially and economically better prepared, a truly reversible procedure would hold greater attraction than other methods. One can only speculate on the impact of a reversible method of male contraception on population growth, since there is little doubt that such a development would be highly beneficial in controlling many of the problems secondary to overpopulation that plague the world today.

REFERENCES

Alexander, N. J. 1972. Vasectomy: long-term effects in the rhesus monkey. J. Reprod. Fertil. 31:399.

Ansbacher, R., Keung-Yeung, K., and Wurster, J. C. 1972. Sperm antibodies in vasectomized men. Fertil. Steril. 23:640.

Bornemisza, G., and Furka, I. 1970. Restoration of the divided ductus deferens by adhesive material. Acta Chir. Acad. Sci. Hung. 11:335.

Brueschke, E. E. 1975. Unpublished data.

Brueschke, E. E., and Zaneveld, L. J. D. 1975. Development and evaluation of reversible vas occlusive devices. In Sciarra, J. J., Markland, C., and Speidel, J. J., editors: Control of male fertility. New York, Harper & Row, Publishers.

Brueschke, E. E., Wingfield, J. R., Burns, M., and Zaneveld, L. J. D. 1974a. Development of a reversible vas deferens occlusive device. II. Effect of bilateral and unilateral vasectomy on semen characteristics in the dog. Fertil. Steril. 25:673.

Brueschke, E. E., Zaneveld, L. J. D., Rodzen, R., and Berns, D. 1974b. Development of a reversible vas deferens occlusive device. III. Morphology of the human and dog vas deferens: a study with the scanning electron microscope. Fertil. Steril. 25:687.

Brueschke, E. E., Burns, M., Maness, J. H., Wingfield, J. R., Mayerhofer, K., and Zaneveld, L. J. D. 1974c. Development of a reversible vas deferens occlusive device. I. Anatomical size of the human and dog vas deferens. Fertil. Steril. 25:659.

Brueschke, E. E., Maness, J. H., Zaneveld, L. J. D., Burns, M., Rodzen, R., and Wingfield, J. 1974d. An artificial vas deferens. Trans. Am. Soc. Artif. Intern. Organs 22:108.

Brueschke, E. E., Zaneveld, L. J. D., Burns, M., Rodzen, R., Wingfield, J. R., and Maness, J. H. 1975a. Development of a reversible vas deferens occlusive device. IV. Rigid prosthetic devices. Fertil. Steril. 26:29.

Brueschke, E. E., Zaneveld, L. J. D., Rodzen, R., Mayerhofer, K., Burns, M., Maness, J. H. and Wingfield, J. R. 1975b. Development of a reversible vas deferens occlusive device. V. Flexible prosthetic devices. Fertil. Steril. 26:40.

Bumpass, L. L., and Presser, H. B. 1972. Contraceptive sterilization in the U.S.: 1965 and 1970. Demography 9:531.

Coffey, D. S., and Freeman, C. 1975. Vas injection: A new surgical procedure to induce sterility in human males. In Sciarra, J. J., Markland, C., and Speidel, J. J., editors: Control of male fertility. New York, Harper & Row Publishers.

Davis, J. E. 1975. Unpublished data.

Derrick, F. C., and Frensilli, F. J. 1974. Experience with a reversible vas device. J. Urol. 111:523.

Derrick, F. C., Yarbrough, W., and D'Agostino, J. 1973. Vasovasostomy results of questionnaire of members of the American Urological Association. J. Urol. 110:556.

Führmann, W., and Schuchardt, E. 1965. Electronmikroskopische befunde am Epithel des Nebenhodenganges und des Samenleiters von normalen, hypophysektomierten und androgenbehandelten Ratten. Naturwissenschaften 9:212.

Free, M. J. 1975. Development of a reversible intravasal occlusive device (RIOD). In Sciarra, J. J., Markland, C., and Speidel, J. J., editors: Control of male fertility. New York, Harper & Row, Publishers.

Free, M. J., and Duncan, G. W. 1975. New technology for voluntary sterilization. In Benjamin, B., Cox, T. R., and Peel, J., editors: Population and the new biology. New York, Academic Press, Inc.

Freeman, C. 1975. Preliminary human trial of a new male sterilization procedure: vas sclerosing. Fertil. Steril. 26:162.

Freeman, C., and Coffey, D. S. 1973. Chemical induction of male sterility by injection of vasosclerosing agents. Fed. Proc. 32:310.

Freund, M., and Davis, J. E. 1969. Disappearance rate of spermatozoa from the ejaculate following vasectomy. Fertile. Steril. 20:163.

Gursel, E., Zinsser, H. H., and Hrdlicka, G. 1971. Nonsutured, nonsplinted anastomosis of the vas deferens. A preliminary report. Invest. Urol. 8:417.

Hulka, J. F., and Davis, J. E. 1973. Sterilization of men. In Hafez, E. S. E., and Evans, T. N., editors: Human reproduction: conception and contraception. New York, Harper & Row, Publishers.

Jhaver, P. S., Davis, J. E., Lee, H., Hulka, J. E., and Leight, G. 1971. Reversibility of sterilization produced by vas occlusion clip, Fertil. Steril. 22: 263.

Klapproth, H. J., and Young, I. S. 1973. Vasectomy, vas ligation and vas occlusion, Urology 1:292.

Lee, H. Y. 1969. Experimental studies on reversible vas occlusion by intravasal thread, Fertil. Steril. 20:735.

Maness, J. H., Brueschke, E. E., Burns, M., Rodzen, R., and Wingfield, J. 1973. Biomaterials requirements for reversible male contraceptive devices, Med. Biol. 15:204.

Moss, W. M. 1972. A sutureless technic for bilateral partial vasectomy, Fertil. Steril. 23:33.

Niesnder, L., and Schantz, B. 1961. On the ultrastructure of the glandular epithelium of the ampulla ductus deferentis in rabbits, Acta Morphol. Neerl. Scand. 4:172.

Niemi, M. 1965. The fine structure and histochemistry of the epithelial cells of the rat deferens, Acta Anat. 60:207.

Phadke, G. M., and Phadke, A. G. 1967. Experiences in the reanastomosis of the vas deferens, J. Urol. 97:888.

Pretser, H. B., and Bumpass, L. L. 1972. The acceptability of contraceptive sterilization among U.S. couples: 1970. Fam. Plann. Perspect. 4:18.

Schmidt, S. S. 1975. Complications of vas surgery. In Sciarra, J. J., Markland, C., and Speidel, J. J., editors: Control of male fertility. New York, Harper & Row, Publishers.

Schmidt, S. S. 1975. Personal communication.

Schmidt, S. S. 1974. Prevention of failure in vasectomy, J. Urol. 109:296.

Setty, B. S., Das Gupta, P. K., and Kar, A. B. 1972. Chemical occlusion of the vas in rats. Contraception 6:149.

Sjöstrand, N. O. 1953. The adrenergic innervation of the vas deferens and the accessory male genital glands, Acta Physiol. Scand. 29:1.

Stolberg, B. S. 1969. Vasectomy—a simplified technique, Urology (Cleveland) 1:17.

Swerdloff, R. S., and Zinneman, L. J. D. 1973. Report on a 2 years nonoclusive intravasal device. In Sciarra, J. J., Markland, C., and Speidel, J. J., editors: Control of male fertility. New York, Harper & Row, Publishers.

Weissler, D. 1966. Histochemistry of the epithelial cells of the epididymis, vas deferens and seminal vesicle of the rat. Z. Zellforsch. Mikrosk. Anat. 71:1.

United States Patent [19]

Free

[11] **3,990,434**

[45] **Nov. 9, 1976**

[54] **REVERSIBLE INTRAVASAL OCCLUSIVE DEVICE**

[75] Inventor: **Michael J. Free**, Pasco, Wash.

[73] Assignee: **The United States of America as represented by the Department of Health, Education and Welfare**, Washington, D.C.

[22] Filed: **Feb. 18, 1975**

[21] Appl. No.: **550,708**

[52] **U.S. Cl.** ..... **128/1 R**; 128/334 C

[51] **Int. Cl.**[2] **A61B 19/00**

[58] **Field of Search** ..... 128/1 R, 334 C

[56] **References Cited**

UNITED STATES PATENTS

3,699,957	10/1972	Robinson	128/1 R
3,704,704	12/1972	Gonzalez	128/1 R
3,820,528	6/1974	Rogers	128/1 R
3,833,384	8/1974	Bucalo	128/334 C X
3,877,435	4/1975	Bucalo	128/334 C

Primary Examiner—Dalton L. Truluck
Attorney, Agent, or Firm—Browdy and Neimark

[57] **ABSTRACT**

A reversible occlusive device for regulating the flow of the fluid through a body passage and having particular utility in the vas deferens for reversible male sterilization is surgically implanted. The vas is punctured by a micro tool such as a hypodermic needle and then a proximal tube having a shoulder portion and openings on either end is inserted. A second hole is punctured in this body passage at a distance approximately equal to twice that of the length of the shoulder portion of the proximal tube. A distal tube similar in construction to the proximal is then inserted into this puncture along with a closed plug for the prevention of the passage of body fluid. If the individual wants the body passage open, the closed plug is surgically removed and is replaced by an open plug.

8 Claims, 3 Drawing Figures

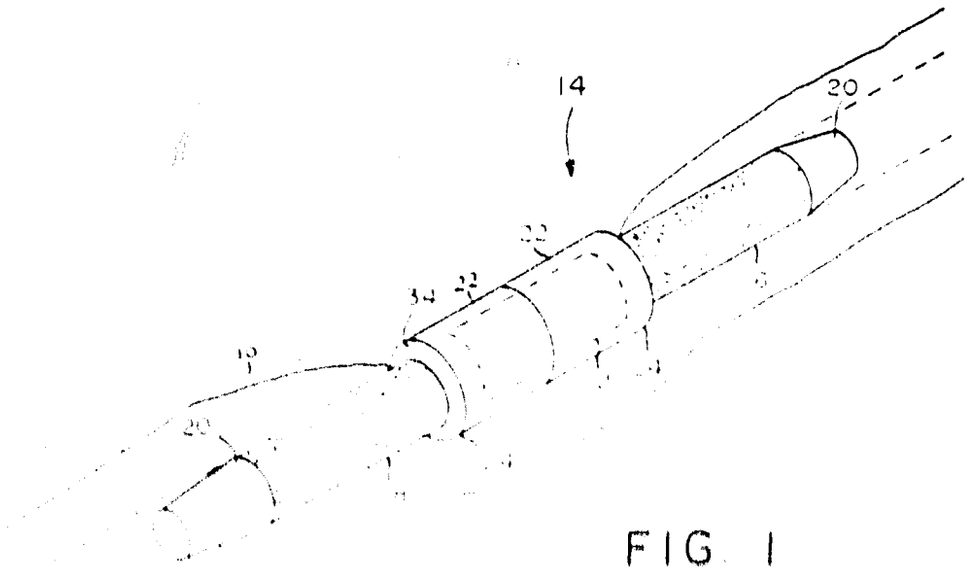

FIG. 1

FIG. 2

REVERSIBLE INTRAVASAL OCCLUSIVE DEVICE

FIELD OF THE INVENTION

This invention relates to a reversible occlusive device for use in the regulation of the flow of fluid in a body passage. This device is particularly adapted to be used in the vas deferens of the adult male as a means for male sterilization.

BACKGROUND OF THE INVENTION

In recent years, man has become increasingly aware that what was once thought to be a limitless supply of natural and man-made resources has now become alarmingly depleted. This depletion is due in great part to an unparalled increase in the world population. In the first three-quarters of this century, man's growth rate has reached the point whereby he is taking much more out of the world's resources than he has been replacing. If this rate continues, man will reach a point in the near future where he cannot clothe or feed himself properly. To counteract this depletion of resources and to ensure that the necessities of life will be available to everyone, increased encouragement and education has been directed to proper family planning. To accomplish this end, many different devices have been developed to prevent conception, so that the opportunity to make an intelligent decision as to whether two people want and can properly care for a child is available. These devices have been directed toward both the male and the female, but many of them contain serious drawbacks. Several female oral contraceptive devices have been found to cause harmful side effects, and some intra-uterine devices have been linked to cervical cancer.

Vasectomies have gained expanded acceptance in the last few years as a means for preventing pregnancy. However, this method exhibits the serious drawback of being non-reversible. One who has undergone a vasectomy cannot recant on his decision once the operation is completed. Several reversible male sterilization devices have been developed, but these devices have not been very reliable since their construction does not allow the vas to become permanently attached to the device so as to form an intrinsic part of the wall of the device.

SUMMARY OF THE INVENTION

According to the present invention, a plastic reversible intravasal occlusive device has now been developed which can be placed into the vas deferens of the adult male in such a manner that the vas becomes permanently attached to it. This device consists of two tubes and an insert and is used to regulate the passage of the spermatozoa through the vas. [illegible]

It is, accordingly, an object of the invention to overcome the defects of the prior art as described above.

Another object is to provide an improved manner for the control of conception and pregnancy.

Another object of this invention is to produce a reversible occlusive device which is to be inserted into a body passage.

One other object of this invention is to produce a reversible occlusive device which is inserted into the vas deferens.

Still another object of this invention is to produce a reversible occlusive device whose surface is porous, thereby enabling it to become firmly attached to the vas deferens.

Yet another object of the invention is to produce a reversible occlusive device which requires no ligatures to hold it in place prior to ingrowth.

A further object of the present invention is to produce a reversible occlusive device that does not require the transection of the vas deferens.

Still another object of the invention is to produce a reversible occlusive device which requires surgery to effect the reversal.

BRIEF DESCRIPTION OF THE DRAWING

The above and additional objects and advantages inherent in the present invention will become more apparent by reference to the description of an illustrated embodiment in a drawing thereof in which:

FIG. 1 is a perspective view of an embodiment of an occlusive device of the present invention;

FIG. 2 is a cross-sectional view taken through line 1—1 of FIG. 1 prior to pushing the tubes together; and

FIG. 3 is a longitudinal cross-section of another embodiment of a device of the present invention.

DETAILED DESCRIPTION OF PREFERRED EMBODIMENTS

FIG. 1 shows an occlusive device 14 inserted into a body passage 10 such as the vas deferens. The device 14 is composed of a proximal tube 16, a distal tube 18 and one of either of two inserts 13, one of which is hollow and the other of which is solid. To facilitate the insertion of the two tubes into the vas deferens, the ends of each of the tubes are tapered at 20.

The prevention of migration of the reversible occlusive device 14 after it has been inserted into the vas deferens 10, which is of prime importance, is accomplished by providing shoulders 22 on the untapered ends of the tubes 16 and 18. [illegible]

exposing a portion of said duct by making an incision;

puncturing said portion of said duct without severing same to provide a first puncture;

inserting a proximal tube having a shoulder into said duct at said first puncture to a distance where said shoulder abuts said duct;

puncturing said duct at a distance from said first puncture approximately equal to twice the length of said shoulder without severing said duct to provide a second puncture;

inserting a distal tube having a shoulder into said duct at said second puncture to a distance where its shoulder abuts said duct;

inserting one end of a closed regulating plug into said proximal tube;

pushing said distal tube over the second end of said regulating plug; and

closing said incision without first clamping the duct to either of the tubes.

8. A method according to claim **7**, further including the steps of:

removing said closed regulating plug; and

inserting an open regulating plug in its place.

* * * * *

REVERSIBLE INTRAVASAL DEVICES:

State of the Art

by

MICHAEL J. FREE, Ph.D.

Experimental Pathology Section

Biology Department

Battelle

Pacific Northwest Laboratories

Richland, WA 99352

January 1979

REVERSIBLE INTRAVASAL DEVICES:

State of the Art

by

MICHAEL J. FREE, Ph.D.

Experimental Pathology Section

Biology Department

Battelle

Pacific Northwest Laboratories

Richland, WA 99352

WHERE DID ALL THE VAS PLUGS GO?

During the late 1960s and early 1970s vasectomy emerged as an important method of fertility control in the developed and less-developed world alike. It proved widely acceptable as a method of family limitation, became deliverable on a large scale and has withstood, to date, the intense scrutiny for side effects made possible by the enormous growth in the population of vasectomized males. The success of the method prompted inquiry by clinical researchers and research planners into the possibility of increasing the acceptability of male sterilization still further by devising reversible methods of vasal contraception. Such methods were presumed to be attractive to individuals considering vasectomy but harboring doubts about the finality of the method, fearing changes in plans or circumstances, catastrophic loss of family or loss of sexual identity.

Following the rapid rise in popularity of vasectomy, increasing numbers of candidates for vasovasostomy, combined with the dismal record of failure with vasovasostomy techniques then available, further emphasized the need for more effective methods of vasectomy reversal. Since implantable valves and prostheses were appearing more common in other areas of human medicine, the stage was set for the development of reversible intravas devices. Which leads us, at this, beginning in the late 1980s, to the question of what happened to the vas plugs.

Now, just 2-3 years since the zenith of vas device research and development, only two or three projects remain active to any degree. The development of promising microsurgical methods of vasovasostomy, enacting of the Medical Device Act Amendment of 1971 by the US Congress, and the increasing availability of simplified procedures for female sterilization have all undoubtedly altered the cost/benefit equation for intravasal device development. However, the primary obstacle has been the vas deferens itself. Formerly regarded as little more than a conduit for sperm, the vas did not turn out to be the passive receptacle for plug or valve that device developers hoped for. Rather, it has become obvious that the vas is a more complex organ, unique in many respects, both morphologically and physiologically.

In the following paper we discuss the current state of intravasal device technology with emphasis on the major obstacles that remain to be surmounted. In doing so we (understandably) draw most heavily upon our own experience with the 1100, a device presently being tested in an "improved" subhuman primate model.

RATIONALES AND ASSUMPTIONS BEHIND INTRAVASAL DEVICE DEVELOPMENT

A principal assumption behind intravasal occlusive device development was that the root of the difficulty in vasectomy reversal by surgical means lay in the vasovasostomy and vasectomy operations per se rather than in the consequences of vas occlusion. It was generally supposed that devices could eliminate these difficulties and, at the very least, by virtue of being easy to install and reverse, permit the general practitioner to achieve the success rate of the experienced specialist, substantially reducing the cost of the procedure. At best, it was thought, intravasal devices might improve the prospects for restored fertility following vas occlusion beyond the best means available and, perhaps, even facilitate multiple reversals.

Various device development efforts were directed toward different levels in this progression of possibilities (Table 1). At the simplest level, devices were designed merely to substitute for vasectomy, with a view toward increasing the chances for successful reversal. Such devices were aimed at individuals planning or desiring no more children but wanting to keep all options open, for one reason or another. At the other extreme, devices with nonsurgical or superficial surgical reversal procedures were aimed at possible on-again/off-again contraceptive [illegible] Problems [illegible]

each off-on cycle, all of which would certainly extend the interval of infertility, did not appear to disturb protagonists of these devices.

In general, the vas deferens was assumed to be a relatively simple conduit for sperm and, therefore, a passive receptacle for plugs or valves. Nevertheless, minimal disturbance to blood vessels, nerve and muscle continuity was considered an important goal, since prolonged discontinuity was considered to be one possible reason for low success rates following vasovasostomy. Furthermore, the mechanism concerned with depositing the contents of the vas deferens into the urethra was known to be controlled by a unique, localized sympathetic nerve supply operating through the hypogastric nerve, peripheral ganglion and associated short adrenergic neurones (Owman and Sjöberg, 1972). Cutting this nerve supply at any point resulted in denervation of those parts of the seminal emission mechanism peripheral to the cut. If the vas deferens is cut, therefore, the segment on the testicular side of the cut will lose its adrenergic nerve supply (Norberg et al., 1967; Poliakova et al., 1976). The denervated vas deferens can still transport sperm by augmented contractions but at a rate so reduced that the lumen becomes distended and engorged with sperm (Owman and Sjöberg, 1972). More recently, the major vas deferens blood vessels have been implicated in the autonomic control of accessory gland functions indirectly by acting as a local pathway for steroid hormones from the epididymis (Ewerdwalbesloer et al., 1973). Further, the vas deferens appears to be the site of origin of seminal secretory stimuli, at least in some species (Gair, 1973; Mills and Kaufman, 1975; Mercer and Ellis, 1977).

It is clear from the earlier observations on vasal form and function that assumptions of a passive vas deferens were hardly warranted at the outset of vas-device development. However, the ease with which 90% sterility could be achieved in man with a simple nylon thread in the vasal lumen (Lee, 1972; 1973; 1975) and the dramatic decrease in sperm counts that resulted from numerous preliminary trials with simple plugs and clips provided sufficient support for the assumption that successful devices could be developed by trial and error, at reasonable cost of time and money, using existing knowledge of the male reproductive system.

A complete block to sperm passage has been the aim for most occlusive devices in the "closed" mode. Because the vas behaves like a viscous tube, shrinking in response to outside compression and dilating when stretched from the inside, measures were deemed necessary to develop an interlocking tissue-device interface in order to anchor the device in place and prevent sperm migration. Obviously, the materials used for intravasal devices had to be biocompatible and the device easily removable. Other than these criteria and the maintenance of an intact vas demanding disguised caution, there were no critical principles for intravasal device development. Thus diversity flourished

STUMBLING BLOCKS IN THE FIELD OF INTRAVASAL DEVICE DEVELOPMENT

Recent successes (Silber, 1977) in improving surgical reanastomosis using microsurgical techniques suggest that periods of vas occlusion do not influence subsequent restoration of fertility sufficiently to preclude reversal in at least 70% of cases. This gives some validity to the original assumption behind intravasal device development that limitations of the surgical methods were the reason for poor success in restoration of fertility in vasectomized men. Less valid, however, was the assumption that devices could be easily designed to overcome the limitation of surgical technique.

Three characteristics of the vas deferens, underestimated at the outset, proved to be major obstacles to device development. These are: 1) the extraordinary capacity for epithelial regeneration; 2) the strong and persistent mobility of the organ; 3) the irritability of sperm to extramucosal tissues. These three stumbling blocks mitigated against achieving in an entirely satisfactory fashion the major technical objectives generally recognized as guidelines for intravasal device development.

One criterion for vas device development discussed in the previous section, that of minimizing the intact vas deferens, is viewed as a [illegible] for reversibility, especially in view of the loss of [illegible] tissue [illegible] the [illegible] of the vas lumen. At the same time, the [illegible] vas deferens [illegible] for an [illegible] device that [illegible] the vas lumen [illegible] expand

of exerting a full range of forces upon the vas contents, thereby disturbing the vas-device interface during the ingrowth phase, driving the accumulating sperm into the implant segment, buckling and kinking soft devices and pushing more rigid devices through the vas wall. What is good for the long-term goal of reversibility is, in this respect, bad for the short-term goal of occlusion. Many device developers abandoned early attempts at maintaining an intact vas deferens and instead took to installing devices between the free ends of the transected vas. However, reversal of such devices is unlikely to be accompanied by regeneration of the proximal nerve net. In one respect this is worse than surgical vasovasostomy, since careful apposition of the freshly cut free ends of the vas may permit nerve regeneration. Maintenance of vas muscle, nerve and vessel continuity may be a worthy goal for intravasal device development but it presents a much greater challenge than was foreseen to retaining indwelling devices, preventing tissue erosion and developing strong sperm-proof vas-device interfaces.

The objective of achieving an interlocking tissue-device interface to anchor the device and prevent sperm stagnation demands a specialized device surface consisting of interconnecting pores or anti vasal tissues to grow into the device. Since tough, nonexpanding fibrous tissue is a tissue that epithelial ingrowth is desired, the vas must be treated in such way to ensure the maximal contribution to the healing process of fibroblasts and tissue macrophages (the mononuclear phagocytes) and of the vas wall, to maintain the integrity of the vas tissue.

be disturbed by intense vasal contractions. Additionally, the porous surface can be confined to that part of the device adjacent to the cut end and no further destruction of the vasal mucosa may be necessary. On the other hand, when the device is placed in the intact vas, porosity and mucosal destruction must extend over the entire implant segment. Not only is the device subjected to the full force of vasal contractions, but if mucosal destruction is not complete or sufficiently extensive, the epithelium will rapidly grow back and leave a loose layer of cells, easily penetrated by sperm, adjacent to the device. However, an even more pervasive problem arises when, as a result of mucosal destruction, spermatozoa are permitted to come into contact with the submucosal layers of the vas wall. In animal trials the sperm irritates vasal smooth muscle, causing an accumulation of inflammatory cells. Since the keratinoid elements of spermatozoa are not easily broken down and removed (Bedford, 1976), the inflammation can persist in the vas wall for months or years. Sometimes this low-grade inflammation will surround the device, but often fibrous ingrowth will enter the device pores while pockets of inflammation persist in the vas musculature. These conditions may facilitate recanalization around the closed device or mechanical erosion of the weakened vas wall by muscle movement acting on the device.

Choice of suitable materials for intravasal devices was not easy because the variety of known biocompatible materials turned out to be either too rigid or too fragile. A common finding in early device

studies was the need to avoid materials that are substantially less compliant than the vas itself. This precluded all the metals, ceramic, nylon, polyethylene and fluorinated polyolefines. The compliancy range that could be tolerated in the mobile vas deferens was apparently quite small, since too much flexibility resulted in buckling and kinking of the device. The primary candidate material for device fabrication, silicone rubber, required minimum wall thicknesses that imposed a severe limit upon maximum lumen diameter obtainable through the device.

When most intravasal devices are in the open position, sperm pass through an artificial conduit on their way to the ampulla. The size of that conduit is important in determining the resistance of the device to sperm flow. For example, a lumen size of 0.5 mm was found to seriously impede the egress of sperm through the rabbit duct, whereas 0.75 mm gave normal sperm counts (Free, 1975; Kraft, 1975). A general objective is to maximize the internal diameter of the device while maintaining the external diameter within the constraints set by the maximum distensibility of the vas wall. Measurement of the lumen diameter in freshly excised segments of human vas yielded a mean and standard deviation of 0.85 $\pm$ 0.07 mm; maximally distended, the lumen reached 1.06 $\pm$ 0.12 mm (Brueschke et al., 1974). In 22 men undergoing vasovasotomy the lumen diameter on the ampullary side of the vasectomy site was 1.03 $\pm$ 0.2 mm (Schmidt and Brueschke, 1976). Since the maximum possible outside diameter is in the region of 1 mm, a wall thickness of no more than 0.10 mm is required to maintain a normal lumen diameter. This thin wall is very difficult to

achieve especially since many device designs require an additional layer of porous material over the surface of the device. The result is that most intravasal devices will impose a significant resistance to sperm egress which, even assuming no other problems, may seriously affect reversibility of the device.

Most device development has been carried out using animal models, yet in areas where comparison is possible between these species and man some significant differences have come to light. It is possible, therefore, that some of the problems discussed here are peculiar to, or aggravated by, the particular animal species used.

LIMITATIONS OF ANIMAL MODELS FOR INTRAVASAL DEVICE DEVELOPMENT

Several observations point to limitations in animal models for research on the vas deferens. For example, both nerves supplying the epididymis course along the vas deferens in most species, but in man one nerve is remote from the vas (Hodson, 1970). Thus, vasectomy is more likely to denervate the epididymis in animal models than in man. Additionally, most small laboratory species have much more elastic vasa deferentia with little connective tissue when compared with man. Extreme enlargement of vasa and epididymides takes place following vas occlusion in these species, generally resulting in irreversible changes.

Rhesus monkeys exhibit several vasal characteristics and responses that differ from the human vas. About 60% of sperm in the human ejaculate appears to be transported directly from the proximal vasa deferentia and caudae epididymides during ejaculations as judged by sperm depletion following vasectomy (Freund and Davis, 1969). On the other hand, direct observation of the vas deferens in conscious and anesthetized rhesus monkeys suggests that only the ampullary end contracts during ejaculation and that transport through the vas is a continuous process (Guha et al., 1977). Furthermore, vasectomy by electrocoagulation without ligatures has worked well in men over the past 10 years (Schmidt, 1973), while in rhesus monkeys vasectomized by this technique the scarred ends of the proximal vasa invariably blow open within six months (Alexander, 1975).

2-62

Most animal species so far examined exhibit some degree of inflammatory reaction when their sperm are permitted to come into contact with submucosal tissues. In rhesus monkeys, however, this reaction seems particularly extreme, leading to fistula formation in more than 40% of monkeys following simple vasectomy (Alexander, 1977). Possibly for the same reason, extensive adhesions are common between the vas, tunica vaginalis and scrotal wall after any surgical manipulation of rhesus monkey vas deferens. In contrast, extensive adhesions are not commonly observed during vasovasostomy in man.

These limitations of animal models for intravasal device development can lead to a "Catch 22" situation in which human trials are needed to resolve the model differences, while convincing animal trials are required to justify clinical testing. In an attempt to resolve this problem we have attempted to create an "improved" rhesus model by installing devices in monkeys rendered aspermatogenic by implantation of subcutaneous steroid capsules. Steroids are withdrawn at the time of device installation, and in the interim before recovery of spermatogenesis the device-vas interface can develop in a sperm-free environment.

RIOD TRIALS IN RHESUS MONKEYS

Details of early development and laboratory animal trials of a reversible intravasal occlusive device (RIOD) have been reported in earlier workshops (Free, 1975; Free et al., 1976). Some of the discussion on stumbling blocks to vas device development covered in previous paragraphs will be amplified by a summary of our experience with the RIOD in rhesus monkey.

Preliminary trials were carried out on six intact adult rhesus monkeys. These monkeys were not subjected to supression of spermatogenesis prior to installation as occurred in more recent trials. The RIODs were inserted in the vas deferens according to procedures shown in Figure 1.

The incidence of immunological and pathological events following RIOD installation is compared in Table 2 with those following vasectomy. Disappearance of sperm from the ejaculate took up to 3 months in these animals, although a similar result was also apparent in vasectomized rhesus. The incidence of palpable granulomas and fistulas after RIOD installation compared favorably to those following vasectomy. The extraordinarily high incidence of fistulas following vasectomy in rhesus monkeys suggests that rhesus sperm are particularly irritating to extravasal tissues and that rhesus may therefore have severe limitations as a model for human intravasal contraceptive technology. The incidence of circulating sperm antibodies and macrophages in the ejaculate following RIOD installation were higher and more persistent than after vasectomy. This result was, perhaps, a reflection of destruction of the vasal

mucosa during the installation procedure, allowing the sperm to come into contact with layers of vasal muscle unprotected by the immunological barrier of the mucosa. The sperm were apparently retained within the vas, since the incidence of palpable granuloma was low.

Histopathology of the vas deferens from the RIOD-implanted rhesus monkey revealed that wperm were generally present in the musculature of the vasa and were associated with areas of apparent irritation (Figure 2). This irritation was not sufficient to be observable by external examination of the exposed vas deferens. Sometimes fibrous tissue ingrowth into the RIOD was evident (Figure 3 and 4), but any beneficial mechanical binding by this ingrowth was negated by the persence within the vasal musculature (Figure 2) or at the vas-device interface (Figure 4) of areas of irritation, characterized by the presence of scattered spermatozoa and keratinoid sperm debris.

In at least five vasa deferentia the electrocoagulation in combination with 1% formalin had apparently destroyed too much of the vas wall and the distal end of the RIOD had sunk into the submucosal tissues. This did not change the effectiveness of occlusion but obviously impaired reversibility (Figure 5). Mild electrocoagulation, similar to that used for the Schmidt method of vasectomy, is probably sufficient to elicit fibrous tissue ingrowth. Limitations on effective ingrowth due to the irritability of sperm in the submucosal layers may be unavoidable in rhesus but may be much less of a problem in man, since the low incidence of fistulation and effective vasal blockage after electrocoagulation in man suggest that human sperm are much less irritable to somatic tissues.

Sperm counts in a monkey with RIODs in the open mode were within the normal range after a recovery period of 80-120 days. Similar periods of depressed sperm count are seen after sham vasectomy operations in rhesus monkeys (Alexander, 1977).

An advanced primate trial is now being conducted in collaboration with Dr. Larry Ewing at Johns Hopkins University School of Public Health. Ten rhesus monkeys have been rendered reversibly azoospermic by means of steroid-filled silastic capsule implants. RIODs have been installed under these sperm-free conditions to eliminate the problems associated with irritability of monkey spermatozoa during the ingrowth phase. Implanted steroid capsules were withdrawn at the time of RIOD installation to permit return of spermatozoa, and the efficacy of the RIODs is being assessed by electroejaculation and breeding trials. We are not implying in this trial that a similar regime will necessarily be required for RIOD installation in man. Rather, we are attempting to improve the rhesus monkey as a model for the human vas deferens. The steroid-filled capsules released 20 μg testosterone and 0.72 μg estradiol/kg/day; all monkeys became azoospermic within 1-2 months of implantation. In most cases, accessory gland secretions were eventually eliminated so that no emissions occurred at ejaculation, even though penile engorgement and rhythmic contractions of the ejaculatory muscle were evident. Spermatogenesis returned to normal following withdrawal of the capsule, as indicated by sperm counts in animals with open RIODs (Figure 6). Normal sperm counts through the open devices suggest no unusual resistance to sperm flow with these thin-walled (0.7-0.8 mm ID) poly(ether)urethane

RIODs. Eight animals with closed RIODs have remained azoospermic even though accessory gland secretions have returned in six of them, suggesting that the RIODs are effectively blocking sperm egress. Reversal of closed devices will be carried out in two monkeys at 3-month intervals.

PROSPECTS FOR A PRACTICAL REVERSIBLE INTRAVASAL DEVICE

Research activity on intravasal device technology has dwindled to a low level. Since prospects for improved vasectomy reversal (using microsurgical techniques) have improved considerably, and the major problems associated with device development have not been solved, the likelihood of a revival of interest in such devices in the near future seems slight. However, the possibility that most of the problems associated with devices may be animal model problems should be borne in mind. The ease with which more than 90% sterility can be achieved in man using the simplest of devices, a nylon thread (Lee, 1975), in addition to the several known limitations of animal models discussed earlier in this paper gives support to this contention. Furthermore, reflection on the consequences of vasectomy in even the best-regarded animal models leads to the conclusion that vasectomy itself would not be considered suitable for human trials on the basis of animal studies alone.

Reversible sterilization by means of an intravasal device must still be considered technically feasible and, with sufficient effort, could be realized. However, the cost-benefit assessment has changed. Development has proved more difficult than envisaged, reversibility after long-term installation in man will be difficult to prove within a reasonable time period, and 70% reversibility may be the best that can be expected based on microsurgical vasovasostomy results (Silber, 1977). There remains the possibility that animal model problems are

obscuring a useful method for human fertility planning and that some existing advanced device designs will eventually prove sufficiently effective in man without additional development costs. Furthermore, if recent research on circulating antisperm antibodies and immune-complex deposition in the rabbit glomerulus (Bigazzi et al., 1976; Alexander and Tung, 1977) gives a presage of vasectomy complications yet to be uncovered, nonocclusive intravasal devices may offer an alternative approach to intravasal contraception since extravasation of sperm and antisperm antibody formation are much less likely if sperm passage is not impeded.

TABLE 1. Current or Recent Research on Reversible Intravasal Devices

(Principal Investigators)	Funding Agency and Related References	Concept and Status
1. New York Medical College School of Medicine Bronx Co., New York, NY (M. Freund and J. Davis)	NIH (Davis, 1973)	Gold and stainless steel stopcock installed in the sectioned vas with gold mesh for ingrowth; works in "on" and "off" position in guinea pigs; human work initiated and terminated. (U.S. Patent 3,742,933 L. Bucalo). Further clinical studies reportedly underway in Florida.
2. Ortho Corp. Raritan, NJ (J. Loe)	Ortho (Polidoro et al., 1976)	Metal device with magnetic valve for nonsurgical reversal; discontinued research after 1 year; biologic studies in rabbit and dog. (U.S. Patent 3,731,670 J. M. Loe).
3. Illinois Institute of Tech. Research Chicago, IL (E. E. Brueschke and L. J. D. Zaneveld)	NIH (Brueschke et al., 1972, 1975a,b)	Porous ceramic and etched stainless steel device with valve; second generation device of silastic; dog experiments show tissue ingrowth and sperm passage. Device is 13-17 mm long with ID of 0.3-0.45 and OD of 0.7-0.9. NIH no longer funding.
4. Abcor, Inc. Cambridge, MA (E. W. Nuwayser)	NIH	Hollow fiber tube with bonded flock and removable center pin made of steel, vitallium of plastic; quinacrine used to promote tissue ingrowth. Status unknown.
5. Tecna Corp. Emeryville, CA (T. C. Robinson)	NIH	Plastic tubes with microporous polyurethane surface for tissue ingrowth; rabbit experiments show good tissue ingrowth and near-normal sperm passage. (U.S. Patent 3,699,957 T. C. Robinson). Status unknown.
6. University of Missouri Columbia, MO (E. C. Mather)	NIH	Reversible vasectomy prosthesis of silastic with dacron sheath; tissue ingrowth achieved on transected bull vas; work discontinued.

TABLE 1 (Continued)

(Principal Investigators)	Funding Agency and Related References	Concept and Status
7. Medical Engineering Foundation, Inc. Little Rock, AR (J. T. Turley)	?	Ball-valve device made of fluoro-plastic material; flexible stems install through a slit in the unsectioned vas by means of a special inverted V clamp; valve kept in place by rolled plastic clip; ball valve has slotted head. Present status unknown. (U.S. Patent 3,820,528 W. P. Rogers)
8. Battelle-Pacific Northwest Laboratories Richland, WA (M. J. Free)	AID (Free and Duncan, 1974; Free, 1975)	Flexible plastic device [Poly(ether) Urethane] with textured surface installed in the unsectioned vas in two halves; halves are joined around a plastic plug and uncoupled and rejoined around open tube for reversal. Device is 16-20 mm long with ID of 0.6-0.75 mm and OD of 0.8-1 mm. Tested in guinea pigs, rabbits and rhesus monkeys. (U.S. Patent 3,990,434 M. J. Free/U.S. Dept. HEW)
9. Southwest Foundation for Research & Development San Antonio, TX (D. C. Kraemer)	NIH	Nonocclusive device with copper coils inside a tube for spermicidal action; copper caused semen coagulation and occlusion; now seeking new spermicides.
10. Massachusetts General Hospital Boston, MA	The Population Council	Removable silastic obturator. Status unknown.
11. Carolina Population Center U. of North Carolina Chapel Hill, NC (J. Hulka)	AID	Polypropylene tube with Teflon velour, also a proplast sponge; work discontinued.
12. Department of Urology University of Iowa Iowa City, IA (K. H. Moon and R. G. Bunge)	(Moon and Bunge, 1972)	Tapered polyethylene tubing installed in unsectioned vas with ends protruding; ends are anchored with silver clips; work discontinued because of pain and leakage in human trials.

TABLE 1 (Continued)

(Principal Investigators)	Funding Agency and Related References	Concept and Status
13. New York Medical College New York, NY (M. Freund)	AID (Pathfinder)	Intravasal silastic balls used successfully in guinea pigs. Status unknown.
14. Korea (H. Y. Lee)	(Johnson, 1972; Lee 1972; Lee, 1973; Lee 1975)	Intravasal nylon or silastic thread caused infertility in dogs and man but 6% failures over time. Reportedly in clinical use in Korea.
15. University of Chicago Chicago, IL (J. R. Swartwout)	AID (PARFR) (Swartwout and Zaneveld, 1975)	Animal experiments with "Y-valve" show transit through long leg of device resulted in sperm damage and infertility; only slight impairment of semen quality through short leg. Project status unknown.
16. N. S. Shah 1414 E. 59th St. Chicago, IL	?	Plastic and metal device inserted into the transected vas and opened and closed by means of a metal clamp manipulated through the skin. Present status unknown. (U.S. Patent 3,613,661 N. S. Shah)
17. T. Read Route 1, Box 470 Tempe, AZ	?	A by-pass device for diverting sperm into the scrotal tissues. Present status unknown. (U.S. Patent 3,042,021 T. Read)
18. Dow Corning Midland, MI (S. A. Braley)	Dow Corning	Liquid, self-curing silastic injected into the vas. Reversal is effected by surgically removing the plug. Present status unknown. (U.S. Patent 3,422,813 S. A. Braley, Jr. and J. D. Delmer)
19. Biomedical Engineering Division Indian Institute of Tech. New Delhi, India (S. K. Guha)	(Guha et al. 1975)	Device tubes made of stainless steel with spiral of silver wire held on with enamel. Body of device contains a Teflon plunger that can occlude or join up the two end tubes. Opening the device automatically flushes the tubes. Testing in rhesus monkeys.

TABLE 1 (Continued)

(Principal Investigators)	Funding Agency and Related References	Concept and Status
20. The Rockefeller Univ. New York, NY (K. A. Laurence)	(Laurence, 1972)	Liquid silastic mixed with catalyst just prior to injection of 0.05-0.08 ml into the vas deferens. Trials in rats, guinea pigs and rabbits.
21. Nathan Brodie, M.D. 1103 Albemarle Rd. Brooklyn, NY	(Brodie, 1975)	Polypropylene device, beaded and tapered. The device is fitted through a horizontal incision in the intact vas and ligated in place with 6-0 stainless steel. 80% of 60 insertions became azoospermic.

TABLE 2. Incidence of Events Following Vasectomy (Vas Section and Vasoligation), RIOD Installation (Closed Mode) and Sham Vas Occlusion.

	Days Postoperation 0 - 14				14 - 30			30 - 120			120 - 180		
	Preoperation	Vasectomy[b]	RIOD[c]	Sham[d]	Vasectomy	RIOD	Sham	Vasectomy	RIOD	Sham	Vasectomy	RIOD	Sham
Incidence of Sperm Immobilizing Antibodies (%)	0	100	-	0	73	100	0	27	66	0	27	50	20
Incidence of Sperm Agglutinating Antibodies (%)	0	93	-	0	47	66	0	0	33	0	0	50	0
Incidence of Macrophage in Ejaculate (%)	10[a]	0	-	0	7	50	0	27	50	0	7	-	0
Incidence of Fistulas (%)	0	33	-	0	47	0	0	27	0	0	20	16	0
Incidence of Granulomas (%)	0	0	-	0	0	0	0	0	0	0	53	0	0
Incidence of Sperm Free Ejaculate (%)	0	-	-	0	-	50	0	66	50	0	-	100	0

All procedures were carried out at the Oregon Regional Primate Research Center under Dr. Nancy J. Alexander. Vasectomy and sham trials were part of a PARFR-funded project under Dr. Alexander.

[a] % of vasectomized group: [b] n = 15: [c] n = 6: [d] n = 5

REFERENCES

Alexander, N. J. Immunologic and Morphologic Effects of Vasectomy in the Rhesus Monkey, Fed. Proc. 34: 1962, 1975.

Alexander, N. J. Vasectomy and Vasovasostomy in Rhesus Monkeys: The Effect of Circulating Antisperm Antibodies on Fertility, Fertil. Steril. 28: 562, 1977.

Alexander, N. J., Tung, K. S. K. Immunological and Morphological Effects of Vasectomy in the Rabbit, Anat. Rec. 188: 339, 1977.

Badr, F. M. Prostaglandin Levels in Tissues of the Male Reproductive System in Six Strains of Mice, Endocrinology 96: 2, 1975.

Bartke, A., Koerner, S. Androgenic Regulation of the Concentration of Prostaglandin F in the Male Reproductive System of Rats and Mice, Endocrinology, 95: 1739, 1974.

Bedford, J. M. Adaptations of the Male Reproductive Tract and the Fate of the Spermatozoa Following Vasectomy in the Rabbit, Rhesus Monkey, Hamster and Rat, Biol. Reprod. 14: 219, 1976.

Bigazzi, P. E., Kosuda, L. L., Harnick, L. L., Brown, R. C., Rose, N. R. Antibodies to Testicular Antigens in Vasectomized Rabbits, Clin. Immunol. Immunopathol. 5: 182, 1976.

2-75

Brodie, N. Male Sterilization Employing an Intra-Vas Device, Int. J. Fertil. 20: 197, 1975.

Brueschke, E. E., Burns, M., Maness, J. H., Wingfield, J. R., Mayerhofer, K., Zaneveld, L. J. D. Development of a Reversible Vas Deferens Occlusive Device: I. Anatomical Size of the Human and Dog Vas Deferens, Fertil. Steril. 25: 659, 1974.

Brueschke, E. E., Burns, M., Rodzen, R., Wingfield, J. and Maness, J. Development of Implantable Reversible Contraceptive Devices for Use in the Male, Proc. 25 Ann. Conf. Eng. Med. Biol. 14: 337, 1972.

Brueschke, E. E., Zaneveld, L. J. D., Burns, M., Rodzen, R., Wingfield, J. R. and Maness, J. H. Development of a Reversible Vas Deferens Occlusive Device: IV. Rigid Prosthetic Devices, Fertil. Steril. 26: 29, 1975a.

Brueschke, E. E., Zaneveld, L. J. D., Rodzen R., and Berns, D. Development of a Reversible Vas Deferens Occlusive Device. III. Morphology of the Human and Dog Vas Deferens: A Study with the Scanning Electron Microscope, Fertil. Steril. 25: 687, 1974.

Brueschke, E. E., Zaneveld, L. J. D., Rodzen, R., Mayerhofer, K., Burns, M., Maness, J. H. and Wingfield, J. R. Development of a Reversible Vas Deferens Occlusive Device: V. Flexible Prosthetic Devices, Fertil. Steril. 26: 40, 1975b.

Davis, J. E. Results with the Use of Intra-Vasal Valve. Presented at 29th Annual Meeting, American Fertility Society, San Francisco, 1973.

Free, M. J. Development of a Reversible Intravasal Occlusive Device, in, Control of Male Fertility, J. J. Sciarra, C. Markland and J. J. Speidel (eds.), p 124. Harper and Row, Inc., MD, 1975.

Free, M. J. and Duncan, G. W. New Technology for Sterilization, in, Population and the New Biology, B. Benjamin, P. R. Cox and J. Peel, (eds.), p 65 Academic Press, New York, 1974.

Free, M. J., Filipy, R. E., Adee, R. R. and Fish, T. M. Technology for Mechanical Fallopian Tube-Blocking Devices, in, Advances in Female Sterilization Techniques, J. J. Sciarra, W. Droegemueller and J. J. Speidel, (eds.), p 239. Harper and Row, Inc., MD, 1976.

Freund, M., Davis, J. E. Disappearance Rate of Spermatozoa from the Ejaculate Following Vasectomy, Fertil. Steril. 20: 163, 1969.

Guha, S. K., Ahmed, A. M. and Kaur, H. Feasibility Study of the Reversible Occlusion Device for the Vas Deferens, Med Biol Eng 14: 15, 1976.

Guha, S. K., Kaur, H., and Ahmed, A. M., Mechanics of Spermatic Fluid Transport in the Vas Deferens, Med. and Biol. Engineering. 1977. In press.

Hodson, N. The Nerves of the Testis Epididymis, and Scrotum, in, The Testis, I, Johnson, A. D. Gomes, W. R., Vandemark, N. L., (eds.), p 47. Academic Press, New York, 1970.

Johnson, D. S. Reversible Male Sterilization: Current Status and Future Directions, Contraception 5: 327, 1972.

Kraft, L. A., Effect of Intravas Devices on Rabbit Fertility, Society for the Study of Reproduction, 8th Annual Meeting, 1975.

Laurence, K. A. Occlusion of the vas deferens with silastic, in, Human Sterilization, R. M. Richart, D. J. Prager, (eds.). Charles C. Thomas, Springfield, IL, 1972, p. 222-228.

Lee, H. Y. Reversible vas occlusion by intravasal thread, in, Human Sterilization, R. M. Richart, D. J. Prager (eds.), p 193. Charles C. Thomas, Springfield, IL, 1972.

Lee, H. Y. Clinical studies on reversible occlusion by intravasal thread, in, Fertility and Sterility, T. Hasegawa, M. Hayashi, F. J. G. Ebling and I. W. Henderson (eds.), p 280. Excerpta Medica, Amsterdam, 1973.

Lee, H. Y. Studies on Male Sterilization Techniques, J. Korean Med. Assoc. 18(4): 1, 1975.

Marley, P. B., Smith, C. C. The Source and a Possible Function in Fertility of Seminal Prostaglandin-Like Material in the Mouse, Br. J. Pharmacol. 52: 114 p, 1974.

Moon, K. H. and Bunge, R. G. Temporary occlusion of the ductus deferens, in, Human Sterilization, R. M. Richart, D. J. Prager (eds.), p 204. Charles C. Thomas, Springfield, IL, 1972.

Norberg, K. A., Risley, P. L., and Ungerstedt, U. Adrenergic Innervation of the Male Reproductive Ducts in Some Mammals. II. Effects of Vasectomy and Castration, Experientia 23: 392, 1967.

Owman, C. H. Sjöberg, N. O. The Importance of Short Adrenergic Neurons in the Seminal Emission Mechanism of Rat, Guinea Pig and Man, J. Reprod. Fertil. 28: 379, 1972.

Pierrepoint, C. G., Davies, P., Lewis, M. H., and Moffat, D. B. Examination of the hypothesis that a direct contact switch exists for the prostate and seminal vesicles, J. Reprod. Fertil. 44: 395, 1975.

Polidoro, J. P., Kraft, L. A. and Culver, R. M. Intra-Vas Device Studies in Rabbits: I. Effect of Surgical Procedures on Adrenergic Innervation of the Vas Deferens, Contraception 14: 383, 1976.

Schmidt, S. S., and Bruescke, E. E., Anatomical Sizes of the Human Vas Deferens after Vasectomy, Fertil. Steril., 27(3): p. 271, 1976.

Schmidt, S. S. Prevention of Failure in Vasectomy, J. Urol. 109: 296, 1973.

Silber, S. J. Microscopic vasectomy reversal: The first 308 cases. Fertil. Steril., 1977. In press.

Swartwout, J. R., Zaneveld, L. J. D. Research on Nonocclusive Devices. In: Control of Male Fertility, J. J. Sciarra, C. Markland and J. J. Speidel (eds.), p 140. Harper and Row, Inc., MD, 1975.

A

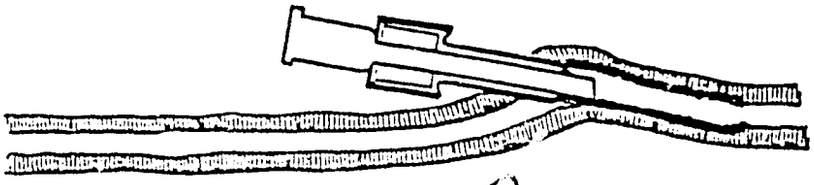

B

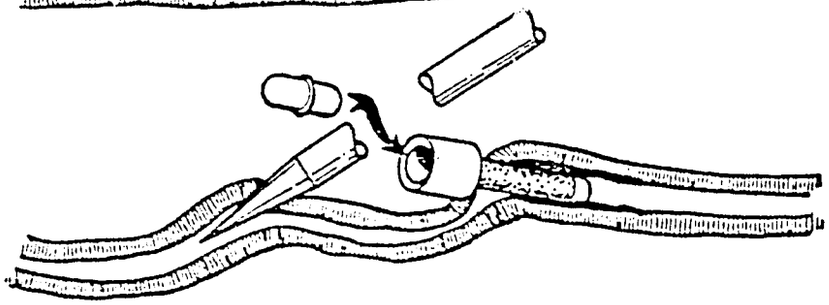

C

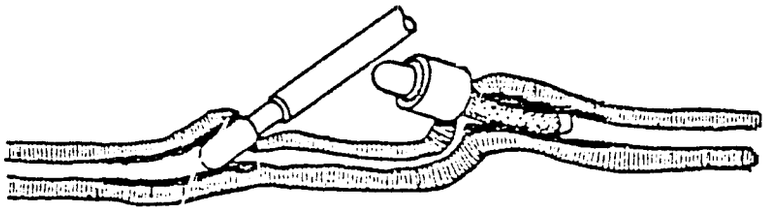

D

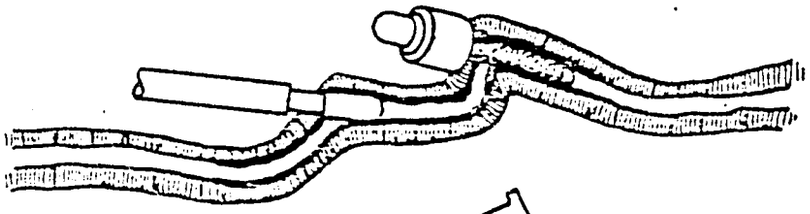

E

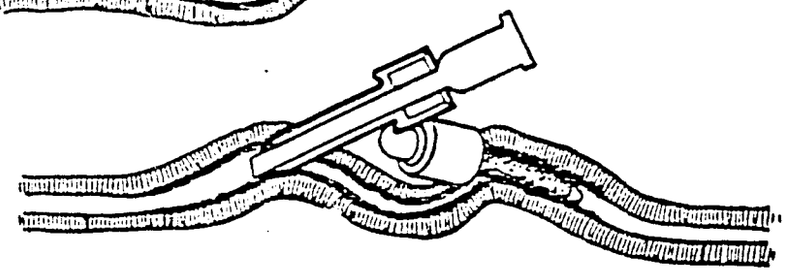

F

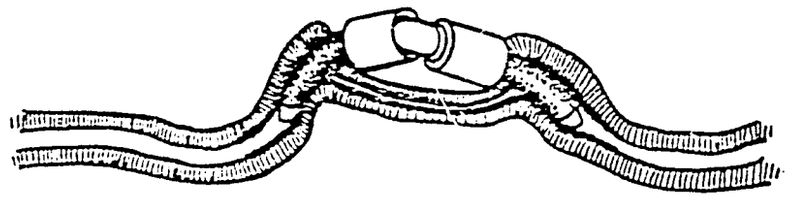

G

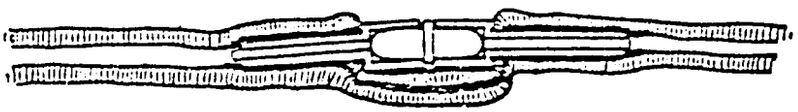

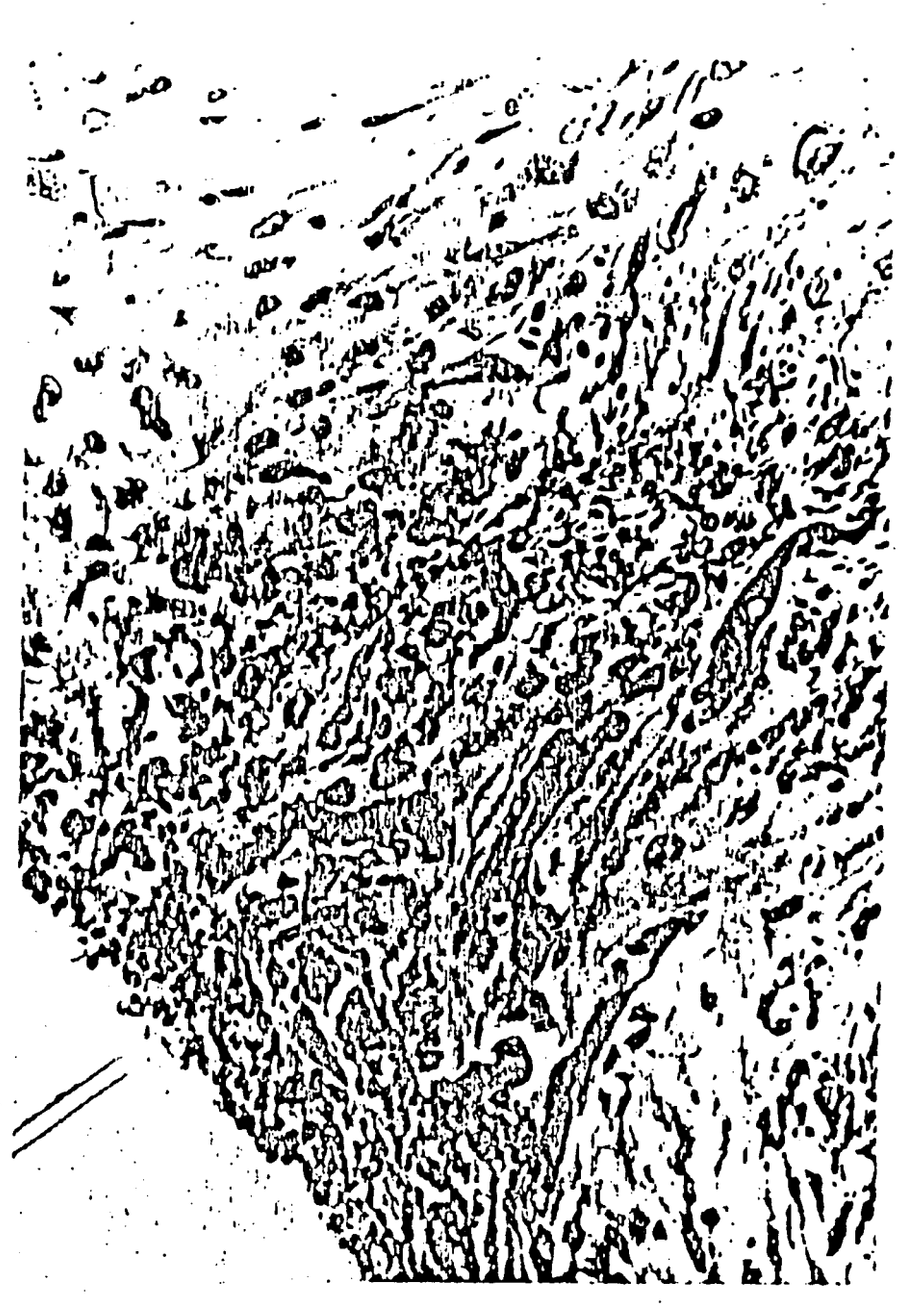

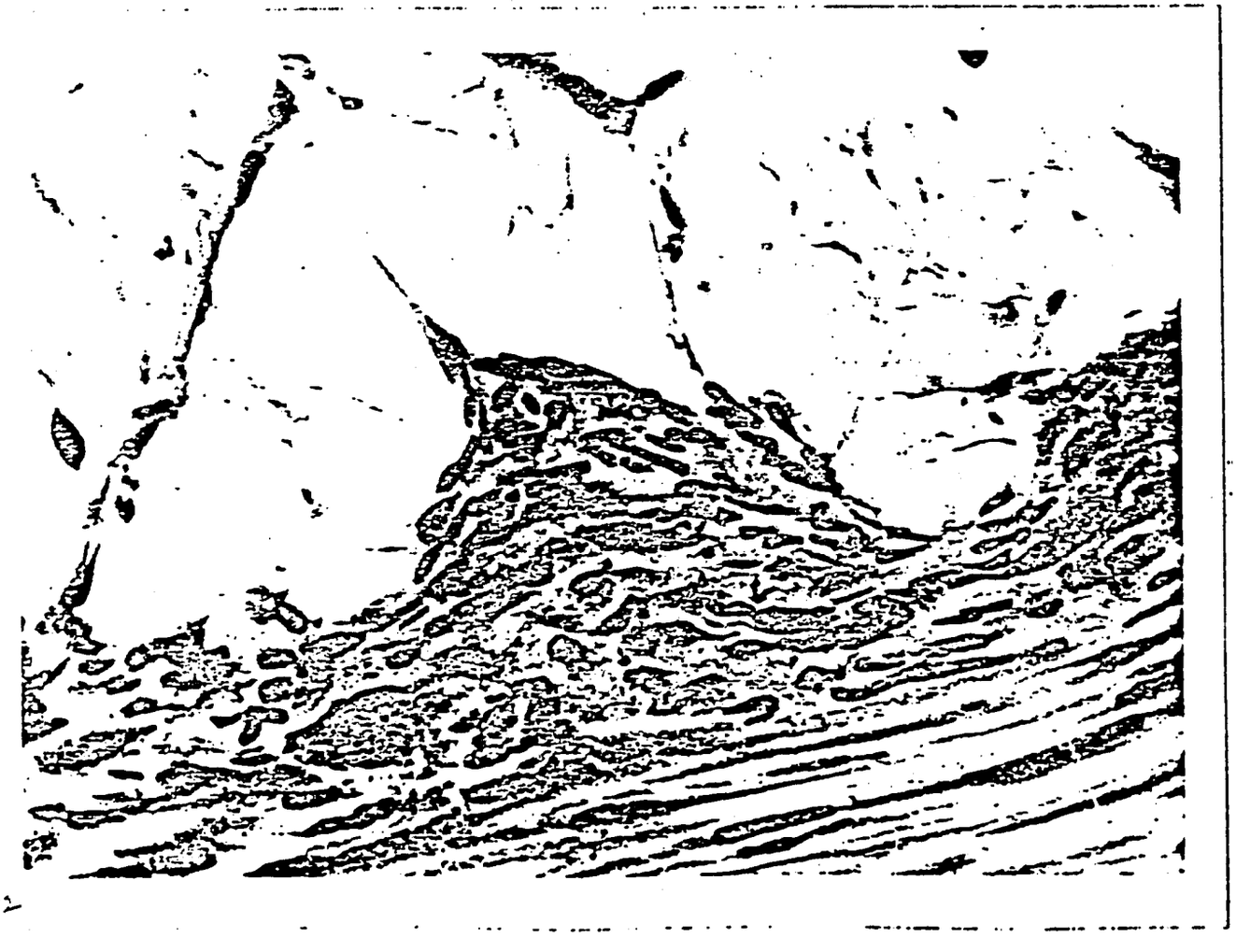

2-82

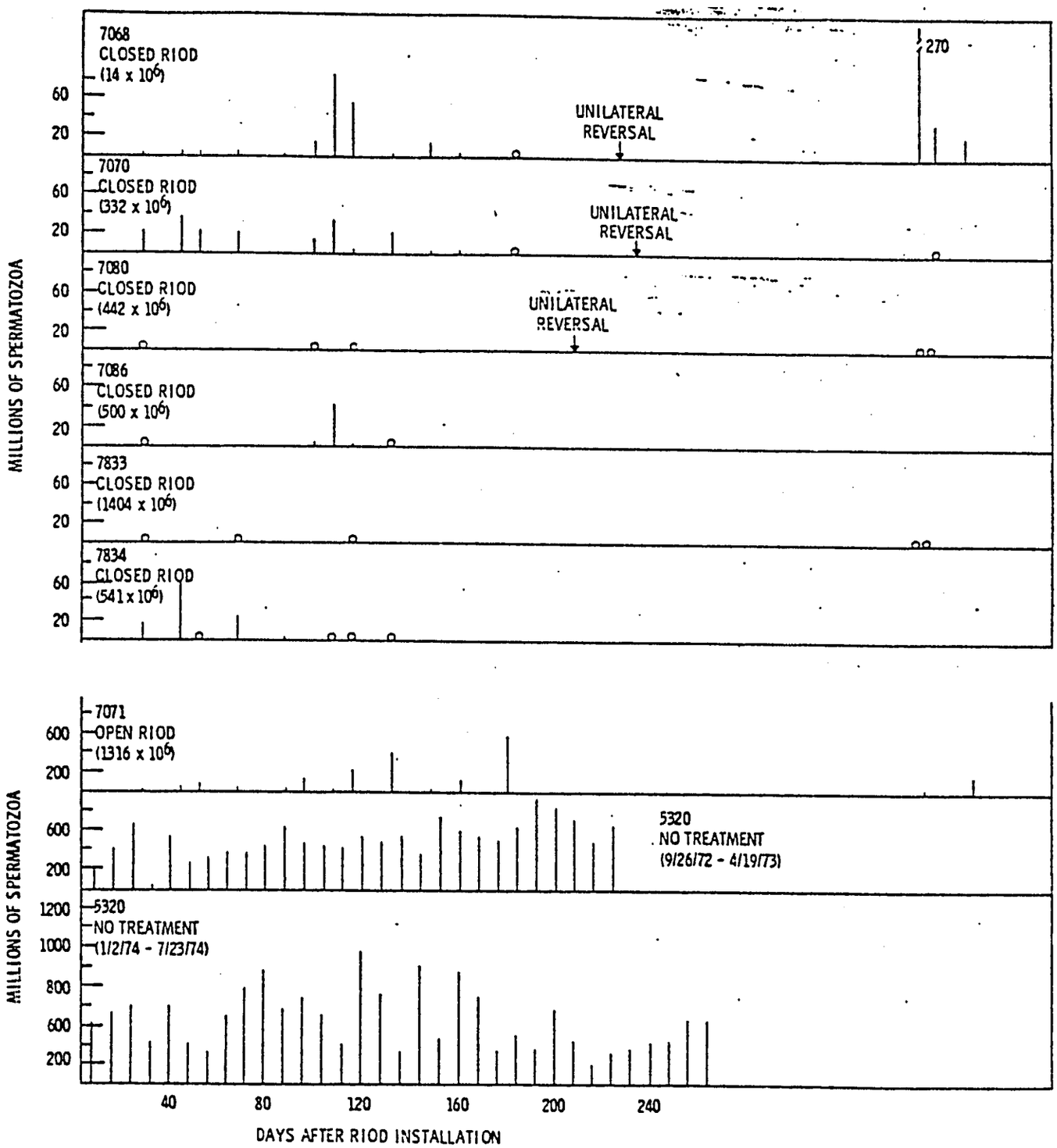
7068
CLOSED RIOD
(14 x 10^6)
270
UNILATERAL
REVERSAL
7070
CLOSED RIOD
(332 x 10^6)
UNILATERAL
REVERSAL
7080
CLOSED RIOD
(442 x 10^6)
UNILATERAL
REVERSAL
7086
CLOSED RIOD
(500 x 10^6)
7833
CLOSED RIOD
(1404 x 10^6)
7834
CLOSED RIOD
(541 x 10^6)
MILLIONS OF SPERMATOZOA
60
20
7071
OPEN RIOD
(1316 x 10^6)
600
200
5320
NO TREATMENT
(9/26/72 - 4/19/73)
5320
NO TREATMENT
(1/2/74 - 7/23/74)
1200
1000
800
40
80
120
160
200
240
DAYS AFTER RIOD INSTALLATION

2-83

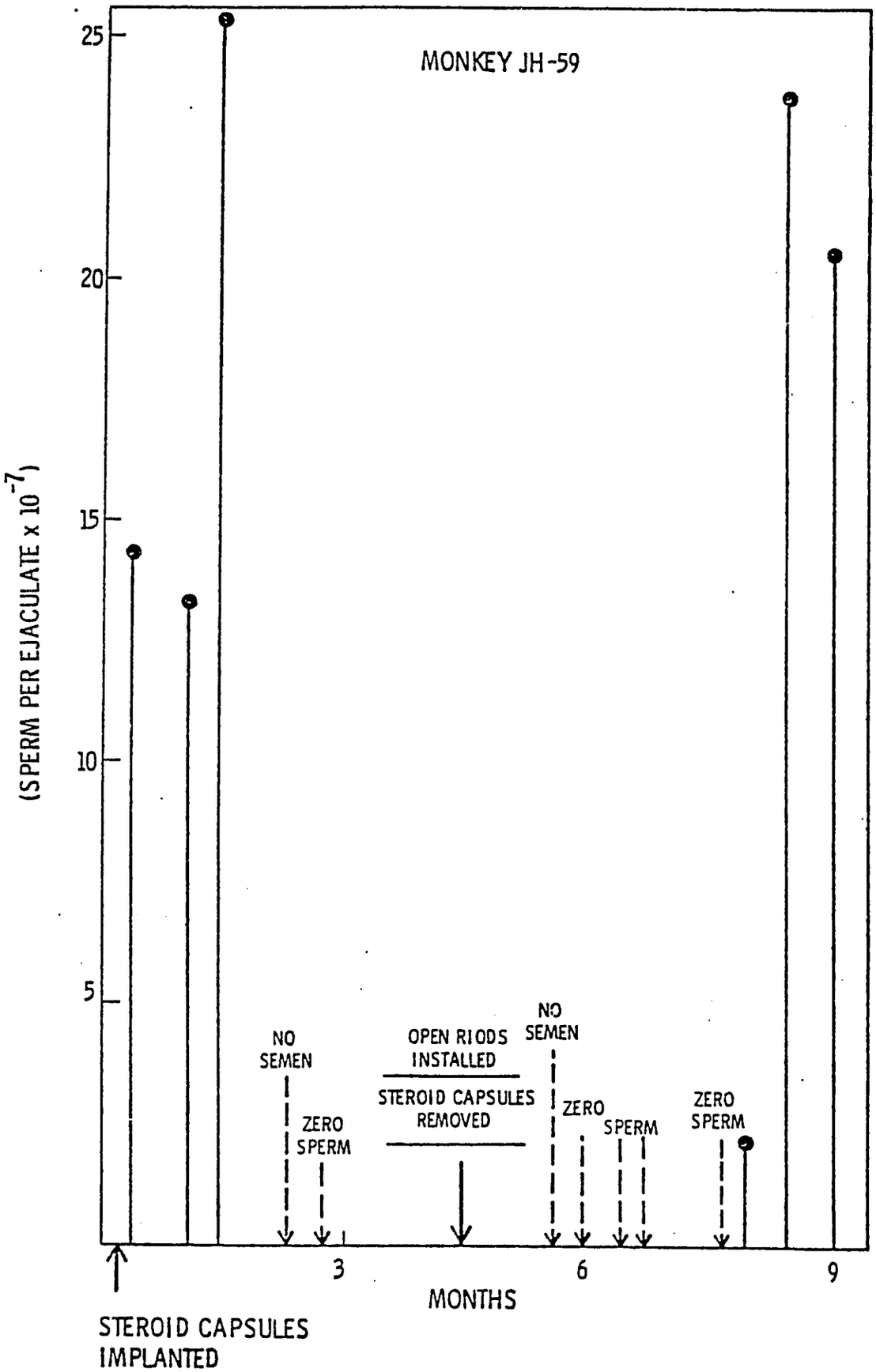
MONKEY JH-59
(SPERM PER EJACULATE x 10^-7)
25
20
15
10
5
NO SEMEN
ZERO SPERM
OPEN RIODS INSTALLED
STEROID CAPSULES REMOVED
NO SEMEN
ZERO SPERM
ZERO SPERM
3
6
9
MONTHS
STEROID CAPSULES IMPLANTED

2-84

FIGURE LEGENDS

Figure 1. Installation of the Reversible Intravasal Occlusive Device (RIOD) in the vas deferens.

A. The vas has been punctured with a fine pointed microtool, dilated with a series of probes (0.86-1.24 mm) and the mucosa electrocoagulated with an EMS VASeal (ElectroMedical Systems, Denver, CO). One half of the RIOD mounted on a 23 ga catheter stub is inserted into the vas in the direction of the epididymis. The catheter stub is then withdrawn.

B. The RIOD insert (black = closed; white = open) is inserted into the body of the first RIOD half. A second puncture is made approximately 1 mm from the free tip of the RIOD insert.

C. The bipolar electrocoagulator electrode is introduced in the direction of the ampulla and the mucosa electrocoagulated.

D. The intermediate segment of vas is electrocoagulated through the same hole.

E. The second RIOD half mounted on a catheter stub is inserted in the direction of the ampulla.

F. The body of the second RIOD stub is pushed on to the free end of the RIOD insert.

G. A completed installation. The intermediate segment scars shut while tissue grows into the pores on the narrow portions of the device. Reversal consists of exposing the vas, slipping out the closed insert and substituting the open one.

Figure 2. Response of sub-mucosal tissues to spermatozoa in RIOD-implanted rhesus monkey vas deferens.

A. Spermatozoa at the tissue-RIOD interface and within the adjacent muscularis. Elements of a chronic inflammatory process are present. Monkey 7086-R. H&E, 500X.

B. Chronic inflammatory response to spermatozoa within the musculature. The response is characterized by mononuclear phagocytic cells. Monkey 7086-R. H&E, 1750X.

Figure 3. Fibrous ingrowth into the porous surface of the RIOD. Monkey 7080-R. H&E, 250X.

Figure 4. Spermatozoa and associated inflammatory response at the tissue-RIOD interface. Ingrowth of a fibrous element into the porous RIOD surface has occurred. Monkey 7086-R. H&E, 1750X.

Figure 5. Sperm counts in rhesus monkeys following RIOD installation in the closed and open mode. Sperm counts from an untreated monkey (5320) are shown to illustrate normal variability of this parameter.

Figure 6. Sperm counts in a rhesus monkey following subcutaneous implantation of a steroid-containing capsule, and subsequent installation of RIODs in the open mode. Silastic capsules released 20 μg testosterone and 0.72 μg estradiol/kg body weight/day. Sperm counts returned to normal levels following withdrawal of the steroids, demonstrating adequate potency of the open RIOD.

Report on the effect of a reversible intravasal occlusive device (Riod) in subhuman primates

Sub-contract B-35835-B-L (A.I.D. 1420-23C)

Battelle Pacific Northwest Laboratories

Robert J. Adams D.V.M.

Division of Comparative Medicine

The Johns Hopkins University, School of Medicine

Baltimore, Maryland

June 15, 1978

Rhesus Q-59

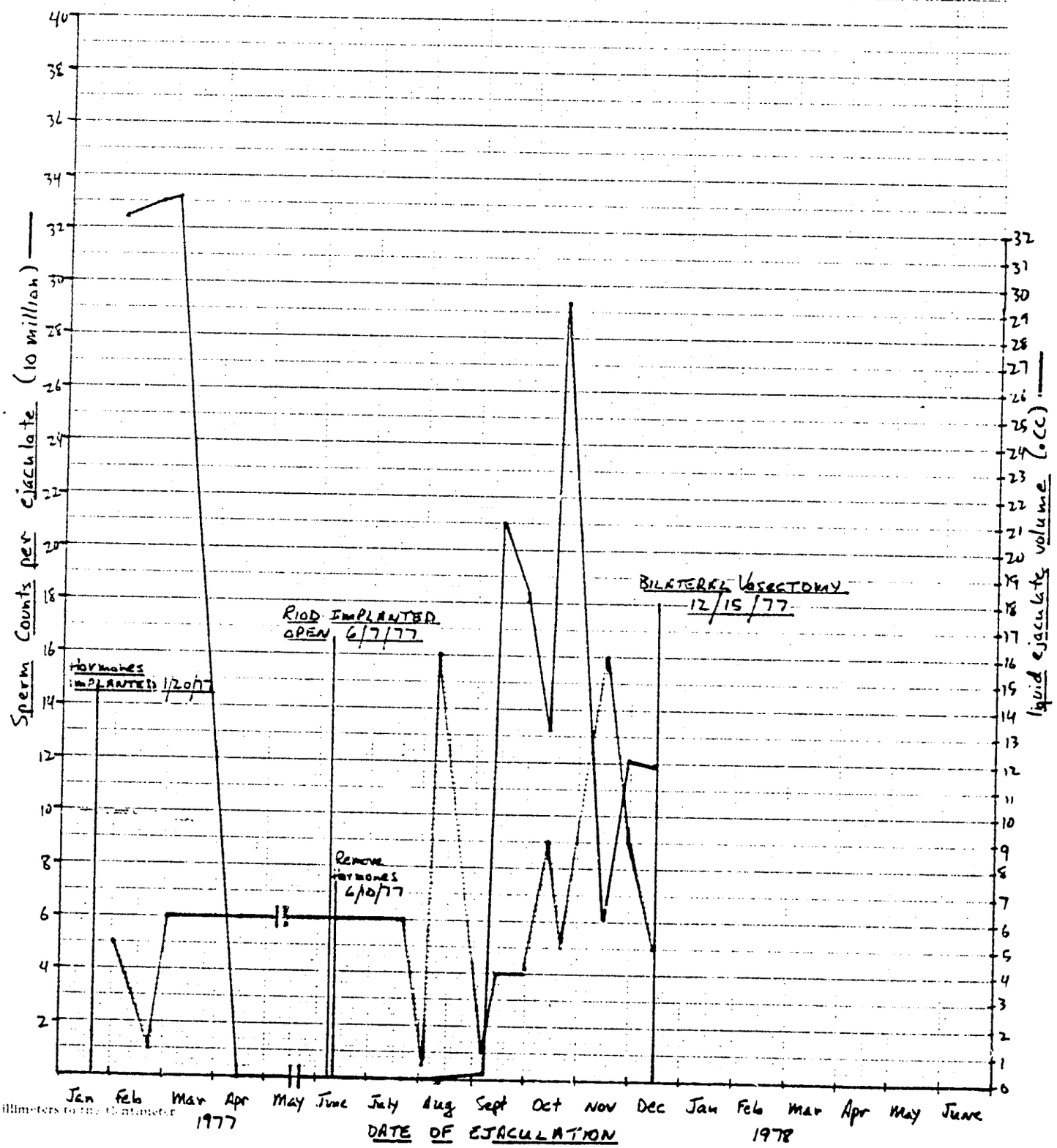

2-88

© Millimeters to the Centimeter

Rhesus Q-59

RIOD placement: 6/7/77 --OPEN MODE
0.9mm O.D. used is both vas deferens

left side-did not cut vas sheath prior to making entry hole. tunics were sutured with 4-0 prolene, simple interrupted 3-0 Dexon used to close subcutis and skin closed with 3-0 prolene

right side-vas sheath incised prior to making entry hole. Following placement 6-0 prolene used to close sheath, simple continuous pattern. 4-0 prolene used to close both tunics. 3-0 Dexon to close subcutis, 3-0 prolene to close skin.

6/10 some swelling of left side; remove hormone implants from back

6/20 slight perisuture reaction.

7/5 attempt first ejaculation--slight amount of fluid produced; penis engorged but no sperm found microscopically.

RIOD REVERSAL: 12/15/77 --bilateral excision of vas

Left side-no adhesions on outer layer. Sheath adhered to vas. Riod appeared in place but difficult to visualize body portion. Cut down made over distal Riod stem. Riod stem was in lumen, did not appear to be firmly bound into vas wall. Vas wall sutured over stem before entire segment containing Riod was excised. Excised vas pinned out and immersed in 10% BF. Vas ends ligated and transfixed ligated with 5-0 prolene prior to excision. Tunics sutured with 3-0 Dexon, simple continuous. Skin closed with 3-0 prolene, simple interrupted.

Right side- more adhesions evident. Sm all yellow cyst evident over RIOD implant. Implant segment of vas dissected out and excised after ligation and transfixation with 3-0 prolene. Closure similar to left side.

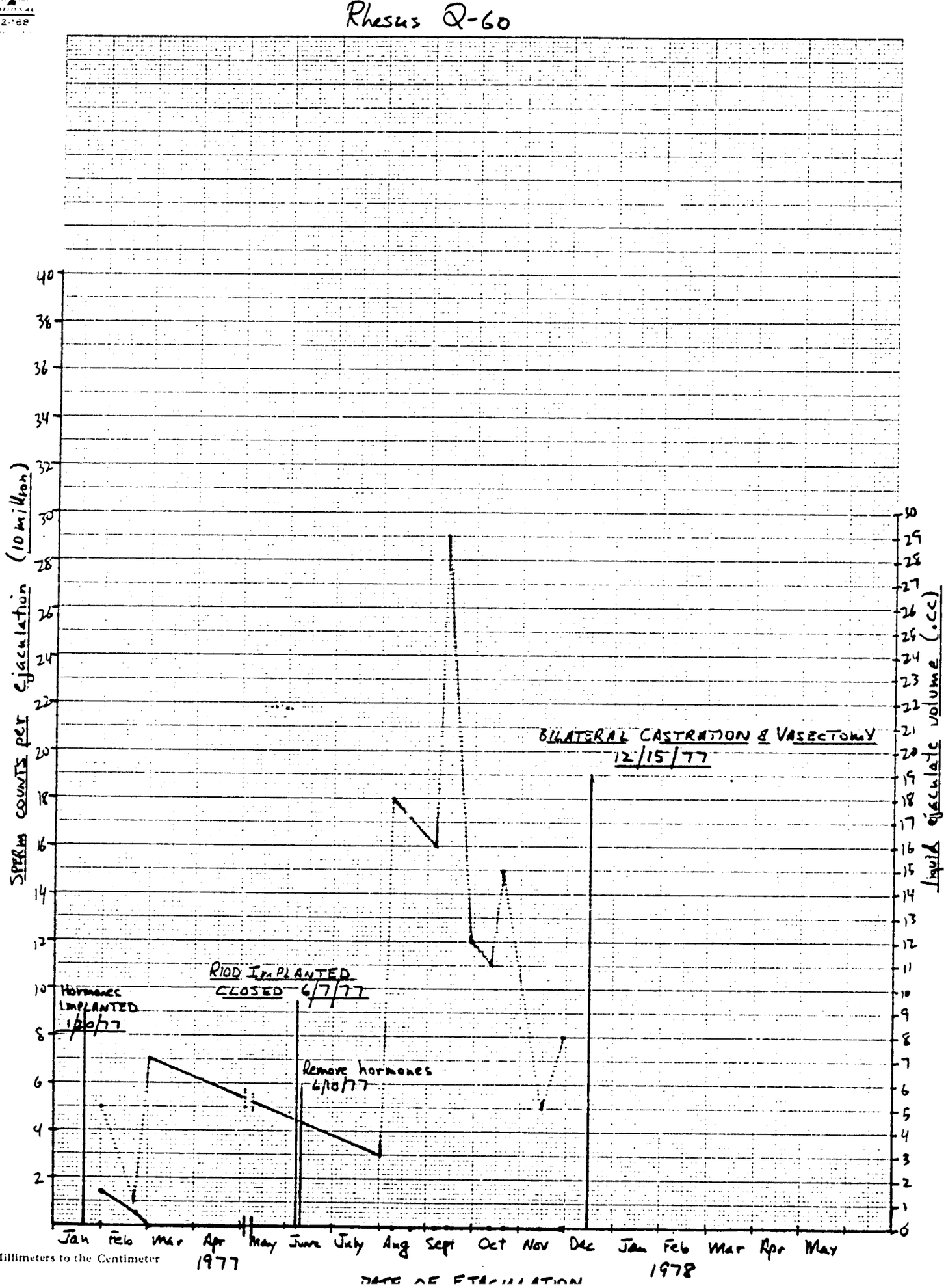

10 Millimeters to the Centimeter

Rhesus Q-60

RIOD placement: 6/7/77--CLOSED MODE

0.9mm O.D. used in both vas deferens

left side- vasal sheath incised. Some difficulty experienced in Riod placement. Sheath sutured with 6-0 prolene. Both tunics closed with 4-0 prolene. Subcutis with 3-0 Dexon and skin with 3-0 prolene.

right side-sheath cut, some difficulty in insertind stem into proximal (epididymal end). May have gone through vasal wall on initial insertion. Suture sheath with 6-0 prolene, simple continuous, tunics with continuous 4-0 prolene, subcutis with 3-0 Dexon skin 3-0 prolene.

6/10 some slight swelling of left side. Remove T implant, unable to locate E implants.

6/20 some scrotal swelling and preputial edema. No evidence of hernia development. Sutures removed, skin healed

ATTEMPTED RIOD REVERSAL 12/15/77 bilateral castration

left side-large granulomatous mass, many adhesions around Riod. Testis excised with epididymis and vas. Fixed in Bouin's. Riod buried in granuloma, fixed in NBF.

right side-As above. Riod appeared inplace. Testis and vas fixed as above.

Rhesus Q-69

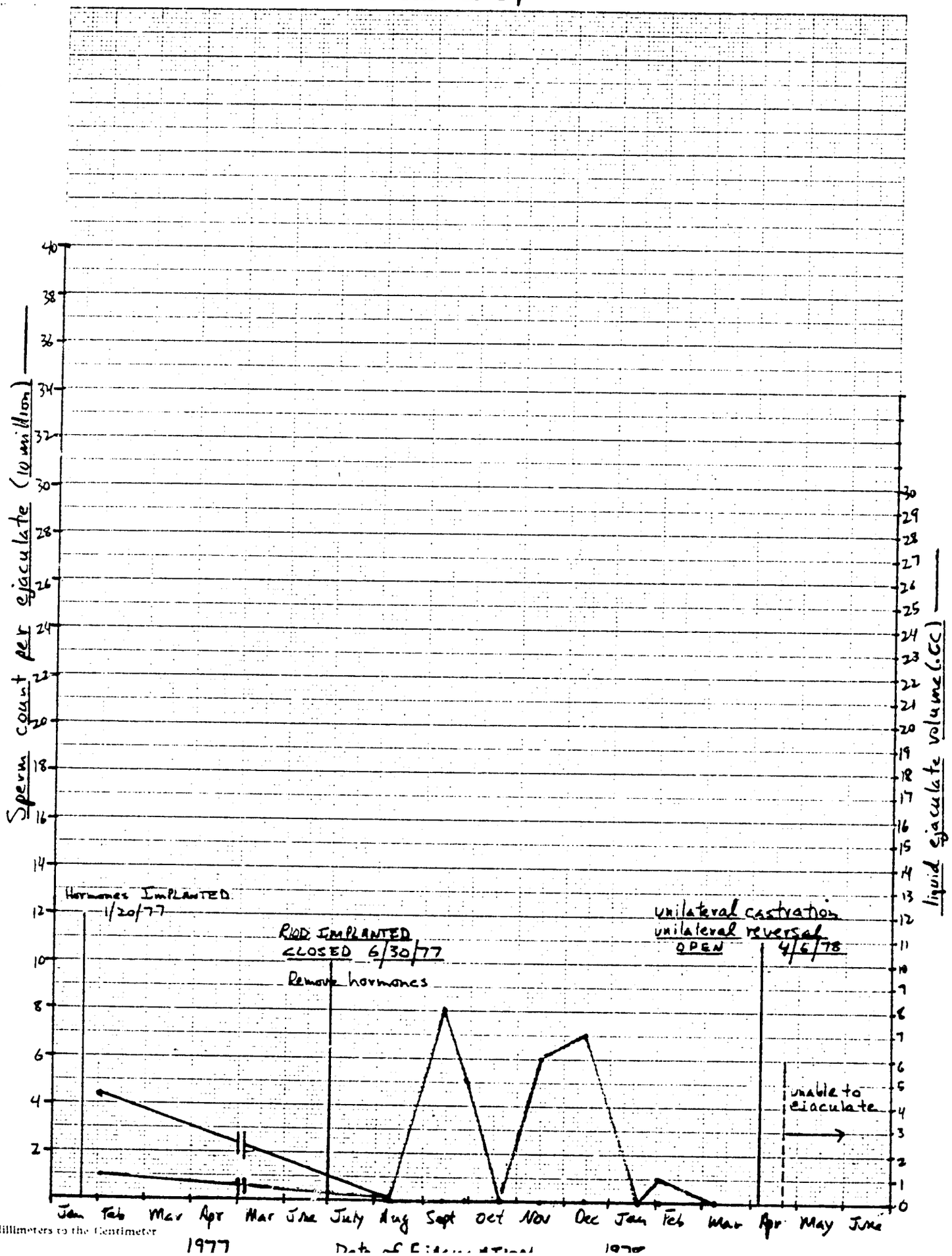

-92

10 Millimeters to the Centimeter

Rhesus Q-69

RIOD placement: 6/30/77--CLOSED MODE

left side- proximal portion of vas tore numerous times. 18.5 probe stretched vas considerable. unable to cauterize the small portion distal to the second hole (between the holes). Proper Riod placement questionable. Sheath sutured over Riod. 6-0 silk sutured over both stem portions. Tunics closed with 3-0 Dexon, simple continuous. Skin closed with 3-0 prolene.

right side- omentum herniated through inguinal ring. Placement good. 6-0 silk sutured over both stem portions of Riod. Routine closure as above. No procedure done to close external ring.

hormonal implants removed following above surgery.

RIOD Reversal: 4/6/78

left side- difficult to locate Riod. Eventually found in region of epididymal head. Possibly had migrated proximally secondary to the poor placement. Elected to remove the left testicle, epididymis and vas. No adhesions external to the spermatic cord.

right side-adhesions of vas to tunic. Large amount of blood oozing when Riod finally dissected free. Whitish-yellow material escaped from area adjacent to Riod (granuloma). Able to reverse. Vasal sheath sutured over Riod with 3-0 Dexon. Routine closure as above.

Rhesus Q-58

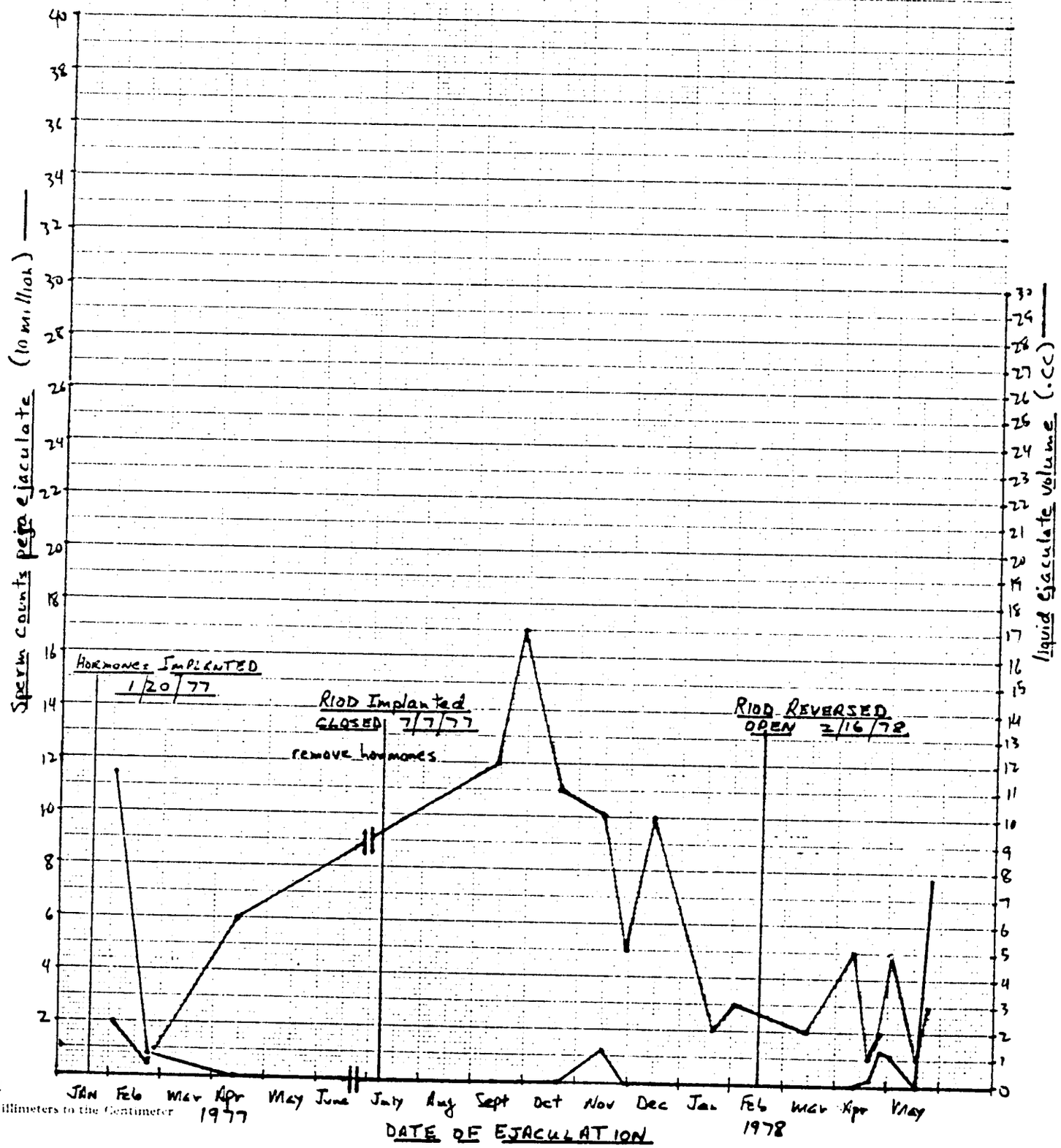

2·94 Millimeters to the Centimeter

Rhesus Q-58

RIOD placement: 7/7/77--CLOSED MODE

0.85mm O.D. used both sides

left side-placement good, distal stem portion slightly harder to insert. Sheath sutured over stem ends with 6-0 silk. Closure of tunics,subcutis, and skin routine as described in previous cases.

right side-unable to insert proximal stem end all the way into the vas, otherwise no problems encountered. Routine closure as above.

hormonal implants removed at time of surgery

RIOD reversal: 2/16/78 unilateral vasectomy, unilateral reversal

left side-granuloma palpated in tail of epididymis. Difficult to locate Riod. No adhesions outside tunics. Adhesions of vas to pampiniform plexus moderate. Only able to find distal stem segment with closed body segment intact. Appears as though proximal segment is encapsulated in a portion of the vas. Distal piece slipped out easily as vas was manipulated. Vasectomy performed. Closure routine.

right side-no adhesions outside tunics. Minimal adhesions between vas and pampiniform plexus. Some yellow fliud filled the proximal segment and escaped when the body was removed. Reversal performed. Sheath sutured with 5-0 prolene. Routine closure as described.

Rhesus Q-64

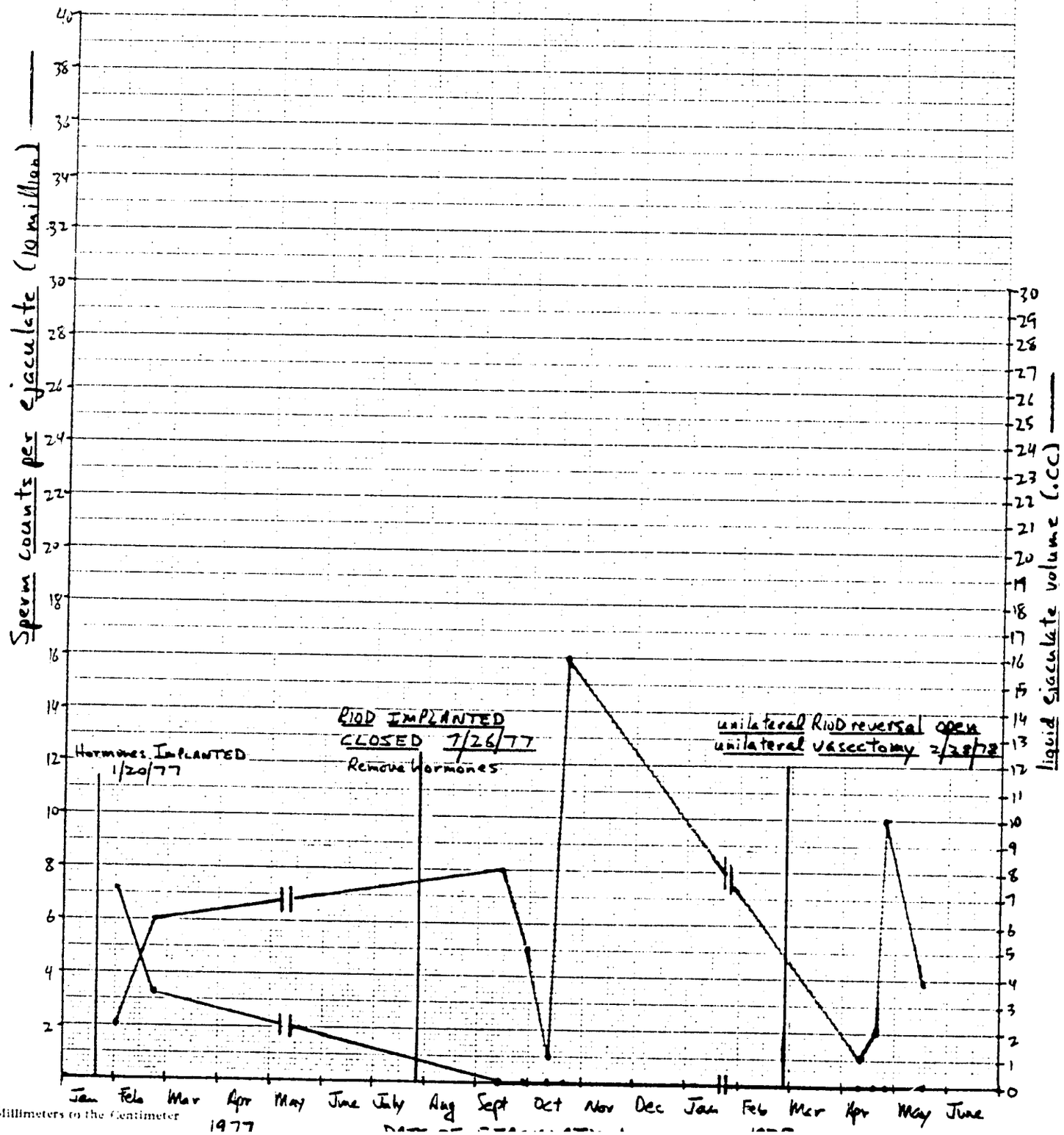

2-96 Millimeters to the Centimeter

Rhesus Q-64

RIOD placement: 7/26/77--CLOSED MODE

0.85mm O.D. used both sides

left side-placement went smoothly. Unneccessary to suture over the sheath. Small amount of omentum herniated through the external inguinal ring, but this was easily pushed back into the abdominal cavity.

right side-proximal portion experienced some difficulty inserting the probes into the lumen. Riod may have been slightly wrinkled during placement.

routine closure of incision as described.

hormonal implants removed at time of surgery

RIOD reversal: 2/28/78 unilateral reversal, unilateral vasectomy

left side-small amount of omentum still in spermatic cord. No adhesions between spermatic cord and skin. Moderate amount of adhesions between the vasa and the external tunic and adjacent pampiniform plexus. A small amount of yellow,pasty material is in the adhesions between the vasa and pampiniform. The Riod is easily visualized and the body is easily removed. Slight amount of movement of stem from the distal portion, but this was easily corrected. Closed body replaced with open body. No granulomas in the testis or epididymis.

right side-No granulomas can be palpated in either the testis or epididymis. There are no adhesions between the tunic and skin. The vasa is firmly adhered to the tunic in the region of the Riod. The distal segment of the Riod lay outside of the vasa. The entire Riod and vas deferens was excised and put in neutral buffered formalin.

Routine closure performed

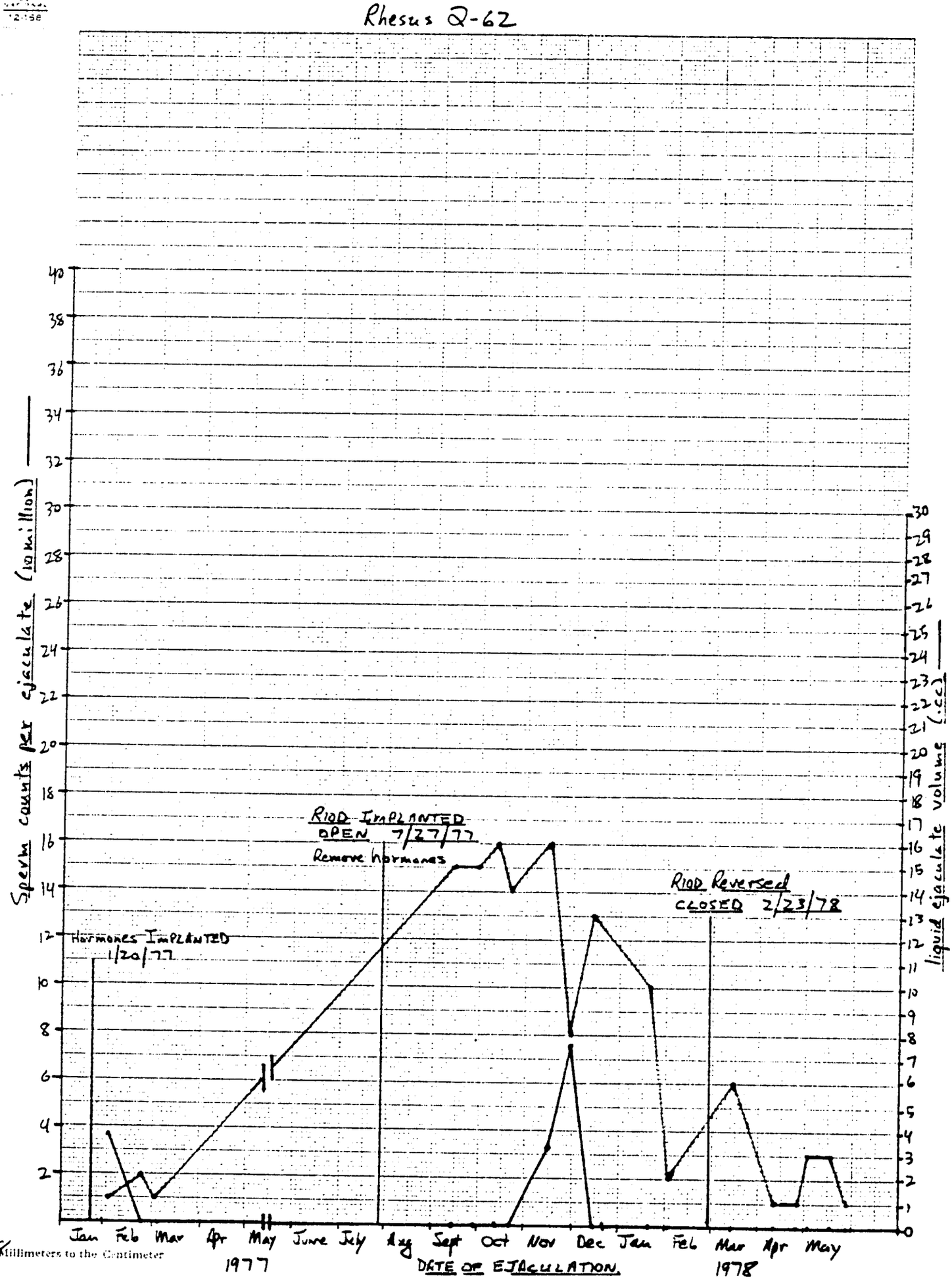

-98 Millimeters to the Centimeter

Rhesus Q-62

RIOD placement: 7/27/77--OPEN MODE

0.85mm O.D. used both sides

left side-placement went well with no difficulty.

right side-proximal portion of the vas tore and difficulty was experienced in placing the Riod properly. The distal portion went smoothly. This size Riod fit tightly.

routine closure as described

hormonal implants removed at time of surgery.

The testes and vas of this animal are smaller than any of the other animals done to this time.

RIOD reversal: 2/23/78 bilateral reversal

left side-no adhesions of the tunic to the skin. Moderate amount of adhesion of the vas to the pampiniform plexus. Able to isolate Riod and change body from open to closed.

right side-palpable granuloma in epididymis. No adhesions of tunic to skin. Minimal amount of adhesion of vas to adjacent tissue. Able to isolate and reverse body of Riod from open to closed. Unnecessary to suture sheath over Riod

routine closure as described

Rhesus Q-68

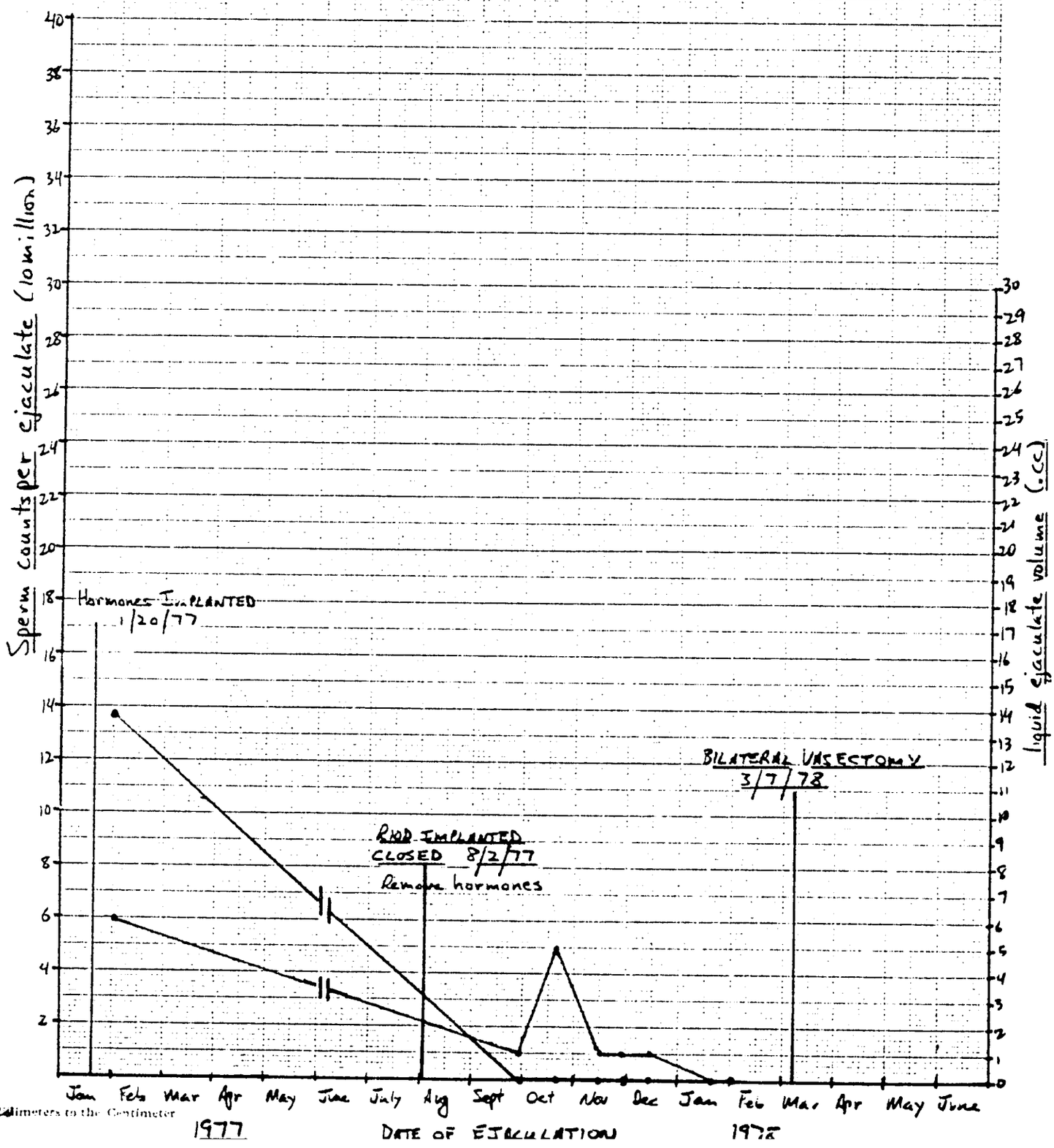

Millimeters to the Centimeter

Rhesus Q-68

RIOD placement: 8/2/77--CLOSED MODE

0.90mm O.D. used both sides

left side-placement of Riod went well with no difficulty.

right side-vas tore after cautery of the distal segment. Both edges of the tear could be utilized and the Riod was inserted. Also some difficulty inserting proximal segment. 6-0 silk suture over Riod in sheath.

hormonal implants removed at time of surgery

8/3/77 monkey removed last 2 skin sutures on right side. replaced under ketaset restraint

8/5/77 monkey picking at sutures on right side

8/8/77 some induration of wound edges where animal picking and chewing at suture

RIOD reversal: 3/7/78--bilateral vasectomy

left side-no granulomas palpated in testis or epididymis. Large amount of fat in the spermatic cord. No external adhesions of the tunic to the skin. There were a minimal amount of adhesion of the vas to the adjacent tissue. I was unable to locate the Riod. Tracing the vas to the tail of the epididymis I was able to locate two enlargements in the vas approximately one centimeter apart in the region where the Riod should have been. I assumed the Riod migrated out of the vas and these two enlargements were where the vas was entered. The intervening area between these two enlargements appeared somewhat thinner than the rest of the vas. The entire vas including these segments was excised and fixed in neutral buffered formalin.

right side-abundant fat around the spermatic cord. Minimal adhesions between the vas the the tunic. Proximal segment of the Riod was lying totally out of the vas. Entire segment excised and fixed in N.B.F.

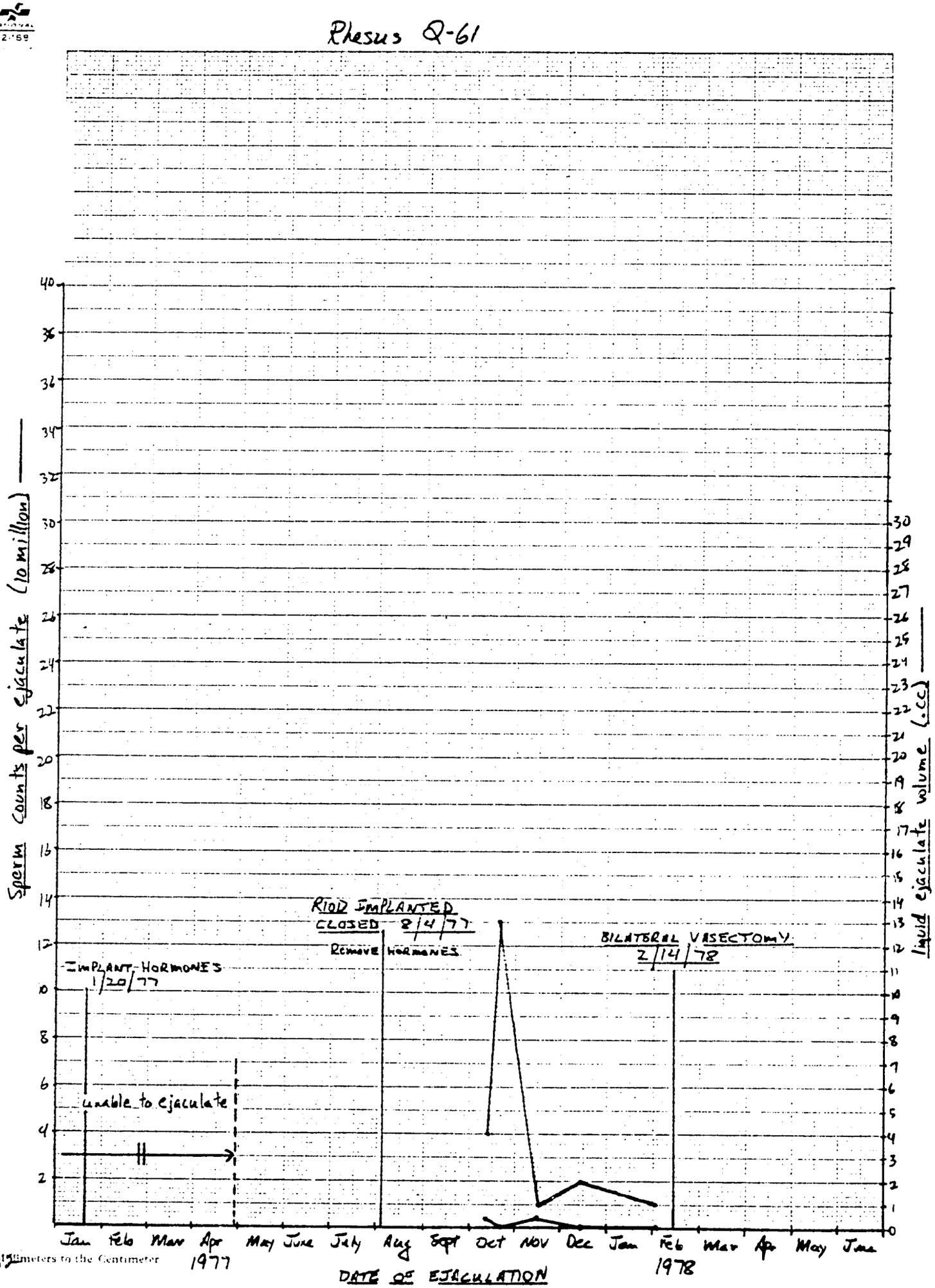

2-410 Millimeters to the Centimeter

Rhesus Q-61

RIOD placement: 8/4/77--CLOSED MODE

0.85mm O.D. used both sides

left side-placement of Riod went well with no difficulty. It was necessary to immerse the Riod in 70% alcohol because a 0.9mm Riod would not fit and no 0.85mm were ready to use.

right side-no difficulty in Riod placement. Also had to immerse in 70% alcohol.

routine closure as described. Unnecessary to place any sutures over the Riod.

RIOD reversal: 2/14/78--bilateral vasectomy

left side-No adhesions external to the spermatic cord. Unable to visualize the Riod when tunic opened. Many adhesions in area, bleeding continual. Granulomatous inflammation around the pampiniform and the vas. The Riod was finally found lying outside the vas, with the proximal segment bent at an angle. Distal to the Riod these was yellow fluid in the vas. Entire segment of vas excised and fixed in N.B.F.

right side-No adhesions external to the spermatic cord. Adhesions of vas to pampiniform plexus in area of Riod insertion. Riod was exposed and closed plug removed. Upon attempting to replace with an open body, the entire device slid out of the vas. No ingrowth of the tissus into the Riod stem had apparently taken place. This portion of the vas was excised and fixed in N.B.F.

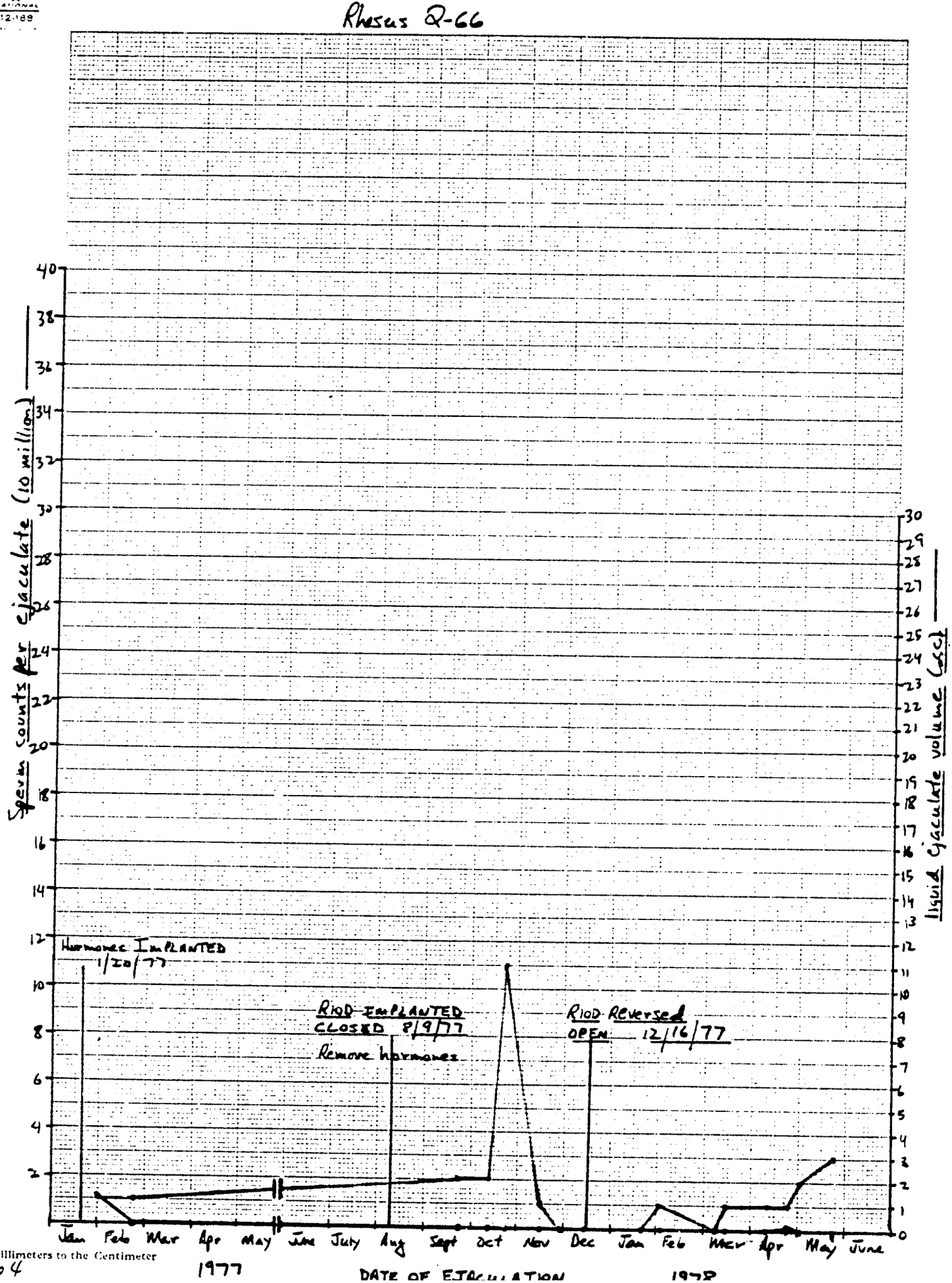

10 Millimeters to the Centimeter

-104

Rhesus Q-66

RIOD placement: 8/9/77--CLOSED MODE

0.85mm O.D. used both sides

left side-while cauterizing the vas the cautery grabbed. Some tearing of the vas occurred. Able to insert Riod. Routine closure.

right side-initially had same problem with cautery. Changed electrode which stopped any grabbing. Proximal segment inserted a bit too far away from the distal segment. When body inserted both stems had to be retracted from the hole slightly. Sheath sutured over proximal segment with 6-0 silk.

hormonal implants removed at time of surgery

RIOD reversal: 12/16/77--bilateral reversal

left side-minimal adhesions. No sirn of ingrowth into RIOD. Some sperm Riod reversed. Sheath repaired with 5-0 prolene.

right side-no adhesions. Cauda palpated--vas engorged. No sign of sperm. Riod reversed.

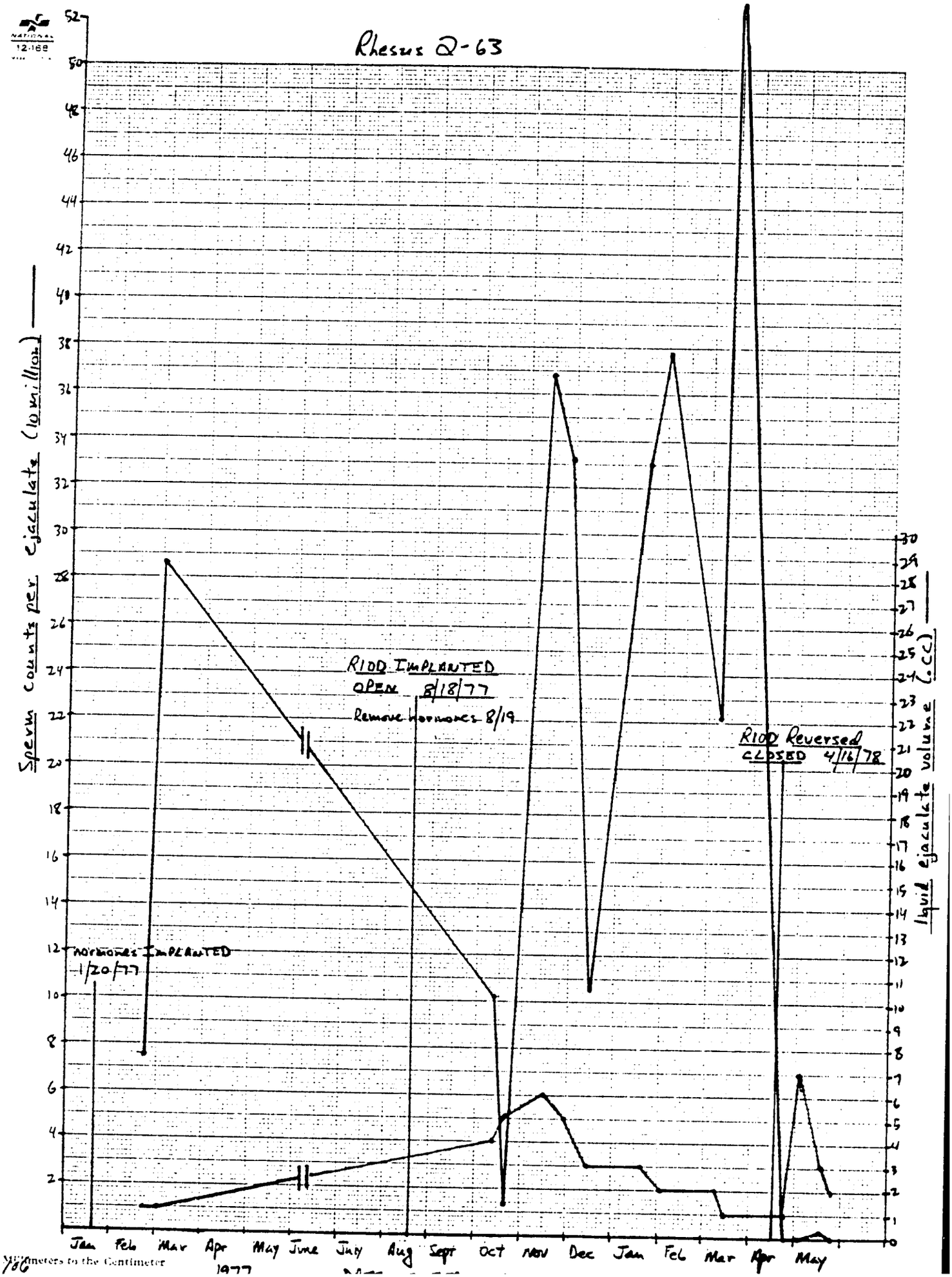

NATIONAL 12-188
50 Millimeters to the Centimeter
12/86

Rhesus Q-63

RIOD placement: 8/18/77--OPEN MODE

used 0.85mm O.D. both sides

left side- placement accomplished with minimal difficulty

right side-some tearing of vas while inserting proximal segment. Sheath closed over proximal segment with 5-0 silk.

closure routine as described

hormonal implants removed 8/19/77

RIOD reversal: 4/18/78

left side-minimal adhesions of vasa to adjacent tissue in region of Riod. Able to reverse from open to closed. 5-0 prolene used to suture sheath over device. Routine closure

right side-more adhesions in region of Riod. Difficult to expose Riod, because it was adherent beneath the vas and adjacent tissue. Reversal accomplished with some difficulty. Unable to suture sheath over the device.

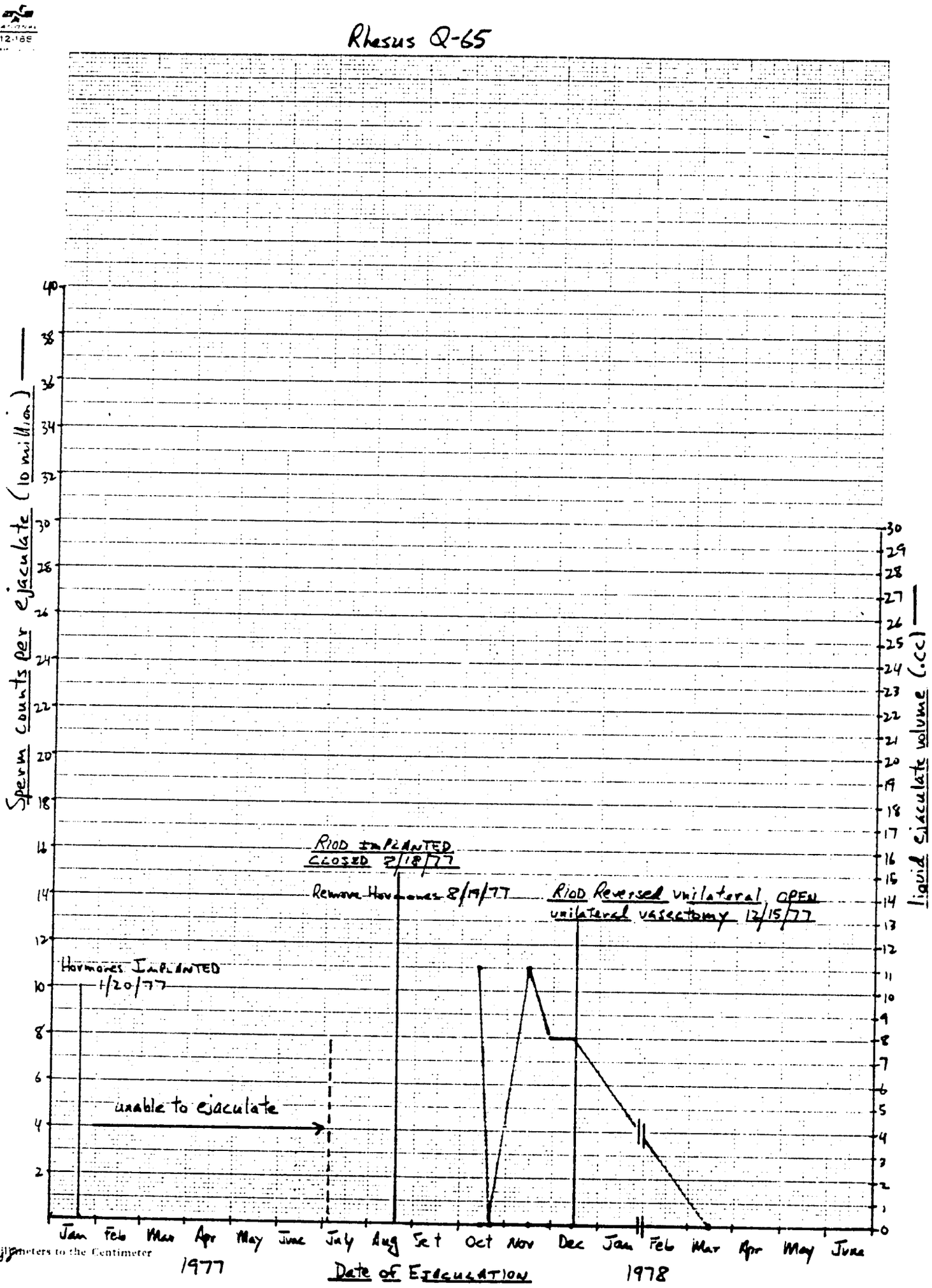

10 Millimeters to the Centimeter

Rhesus Q-65

RIOD placement: 8/18/77--CLOSED MODE

left side-some tearing of vas when proximal segment inserted.

right side-minimal difficulty, Riod inserted. Small amount of bleeding from pampiniform plexus.

Closure routine as described

hormonal implants removed 8/19/77

RIOD reversal: 12/15/77--unilateral reversal, unilateral vasectomy

left side-some adhesions. Granuloma at proximal end. Distal end appeared to be out of vas. Vas ligated and transfixed ligated. Implant segment excised with Riod in place. Fixed in 10% N.B.F. Routine closure

right side-minimal adhesions. Riod in place, no granulomas. Proximal Riod tube slipped out of vas as plug was removed. No sign of ingrowth. No sperm evident at proximal end. Riod tube reinserted, open body inserted between stems. Sheath closed over Riod with 5-0prolene. Pampiniform plexus nicked during surgery, bleeder ligated with 3-0 dexon. Routine closure. Small nodule palpated in right epididymis.

EJACULATION HISTORY POST RIOD IMPLANTATION

Animal No.	Date RIOD Inserted	RIOD Mode*	7/5/77	7/19/77	8/2/77	8/9/77	9/6/77	9/13/77	9/26/77	10/11/77	10/20/77	11/15/77	11/29/77	12/12/77	1/19/78	2/1/78	3/7/78	3/14/78	4/11/78	4/19/78	4/25/78	5/2/78	5/16/78	5/23/78
59	6/7	O	+/-	+/-	+/-	+/-	+/+	+/+	+/+	+/+	+/+	+/+	+/+	+/+	12/15/77 bilateral vasectomy									
60	6/7	C	ND→		+/-	+/-	+/-	+/-	+/-	+/-	+/-	+/-	+/-	-/-	12/15/77 bilateral castration									
69	6/30	C	ND→			+/-	ND	+/-	+/-	-/-	+/-	+/-	-/-	+/-	+/-	+/-	-/-	-/-	ND	-/-	-/-	-/-	-/-	ND
58	7/7	C	ND→					+/-	+/-	+/-	+/-	+/+	+/-	+/-	+/-	+/-	ND	+/-	+/+	+/+	+/+	+/+	+/-	+/+
64	7/26	C	ND→					+/-	+/-	+/-	+/-	-/-	-/-	-/-	-/-	-/-	ND	ND	+/-	+/-	+/-	+/-	+/-	+/-
62	7/27	O	ND→					+/-	+/-	+/-	+/-	+/+	+/+	+/-	+/-	+/-	ND	+/-	+/-	+/-	+/-	+/-	+/-	+/-
68	8/2	C	ND→						+/-	+/-	+/-	+/-	+/-	+/-	+/-	+/-	3/7/78 bilateral vasectomy							
61	8/4	C	ND→						-/-	+/+	+/-	+/+	-/-	+/-	-/-	+/-	2/14/78 bilateral vasectomy							
66	8/9	C	ND→						+/-	+/-	+/-	+/-	+/-	+/-	+/-	+/-	-/-	+/-	+/-	+/-	+/-	+/-	-/-	+/-
63	8/18	O	ND→						+/-	+/+	+/+	+/+	+/+	+/+	+/+	+/+	+/+	+/+	ND	ND	+/-	+/-	+/+	+/-
65	8/18	C	ND→						-/-	+/-	+/-	+/-	+/-	+/-	-/-	-/-	-/-	+/-	-/-	-/-	-/-	-/-	ND	ND

RIOD mode O=open
C=closed

ejaculation (+,-) → / ← sperm present microscopically (+,-)

69 4/6/78 unilateral castration, unilateral reversal to open
58 2/16/78 unilateral vasectomy, unilateral reversal to open
64 2/28/78 unilateral vasectomy, unilateral reversal to open
62 2/23/78 bilateral reversal to closed
66 12/16/77 bilateral reversal to open
63 4/16/78 bilateral reversal to open
65 12/15/77 unilateral vasectomy, unilateral reversal to open

References, Appendix 3

1. Decker, J. and R. Carmichael. 1973. An electrocautery instrument for the fulguration of the vas deferens during vasectomy for sterilization. Presented at the Tenth Annual Rocky Mountain Bioengineering Symposium, May 7-9, 1973. Boulder, CO. Instrument Society of America, Pittsburgh, PA.

2. Schmidt, S. S., R. Carmichael, J. R. Decker, and M. J. Free. 1974. Vas cautery: battery-powered instrument for vasectomy. Urology III:604-605.

3. Free, M. J. and G. W. Duncan. 1974. New technology for voluntary sterilization, pp. 65-82. In: Population and the New Biology. Bernard Benjamin, Peter R. Cox, and John Peel (eds.). Academic Press, NY.

4. Alexander, N. J., S. S. Schmidt, M. J. Free, M. V. Danilchick, and W. T. Hill. 1976. Sperm antibodies after vasectomy with fulguration. J. Urol. 115:77-78.

5. Schmidt, S. S. and M. J. Free. 1978. The Bipolar Needle for Vasectomy. I. Experience with the First 1000 Cases. Fertil. Steril. 29:676-679.

6. Operation and Maintenance Manual for the Vas Deferens Electrocoagulator System.

7. Vasectomy: Efficacy of placing the two cut ends of the vas deferens in different fascial planes. (Draft; not for distribution)

AN ELECTROCAUTERY INSTRUMENT FOR THE FULGURATION OF THE VAS DEFERENS DURING VASECTOMY FOR STERILIZATION

JOHN DECKER
ROBERT CARMICHAEL
Battelle Pacific Northwest Laboratories

Presented at the
Tenth Annual
Rocky Mountain Bioengineering Symposium

May 7 - 9, 1973

Boulder, Colorado

ISA PREPRINT

Copyright 1973

Instrument Society of America
Instrumentation • Systems • Automation
400 Stanwix Street
Pittsburgh, Pa. 15222

© 1973, ISA BM 73302 (5-10)

AN ELECTROCAUTERY INSTRUMENT FOR THE FULGURATION OF THE VAS DEFERENS DURING VASECTOMY FOR STERILIZATION

John Decker, Scientist
Robert Carmichael, Senior Technician
Battelle Pacific Northwest Laboratories
Richland, WA 99352
United States of America

INTRODUCTION

Vasectomy has rapidly become an acceptable, common means of sterilization of adult men in many countries throughout the world. This operation is simple yet is beset by a failure rate in the U.S. as high as 2 to 6%.[1] This failure may be due to several causes, ranging from spontaneous reanastomosis to spermatic granuloma. Stanwood S. Schmidt, M.D., has developed a vasectomy technique which virtually eliminates failure and complication. This technique, tested in more than 1,375 vasectomies, relies on fulguration of the lumen of the transected vas.

The first widely accepted electrocautery instrument was the spark-gap diathermy introduced by Cushing and Bovie in 1928. For many years the technical advancement of electrocautery instruments has been limited to refinements of the original Bovie units. Since the report of a solid state electrocautery instrument in 1968 by Petty, Lim and Stahl[2] many modern solid state instruments have become available. Although these solid state instruments are smaller than the older spark-gap instruments, they are not fully portable; and all require a 110-volt AC power source. The versatility of these instruments, necessary for a surgical electrocautery, adds an expense and complexity both unnecessary and undesirable in an electrocautery unit limited to vasectomies. Based on this report and medical and technical advice from Schmidt, we have developed a solid state electrocautery instrument designed specifically for fulguration of the vas during vasectomy. The requirement of a battery-powered, portable instrument necessitated the reduction of power consumption to an absolute minimum. The development of a concentric bipolar needle electrode reduced the coagulating power by concentrating the current in the immediate area of the mucosa of the vas. The extent of the lesion formed by this unique electrode arrangement is self-limiting due to the concentration of power in a small area. The more typical arrangement in electrosurgical instruments is a monopolar electrode with a diffuse ground. These instruments require a very subjective control of the lesion by adjusting the withdrawal rate of the electrode from the vas lumen. Patient safety is assured by the transformer-isolated, low-power output and by localization of current to the immediate vicinity of the bipolar electrode tip. The instrument is inexpensive, simple to use, and battery-powered, therefore, ideal for use in extensive male sterilization programs in lesser developed countries. In its final form it will weigh approximately two pounds. Testing on guinea pigs and freshly excised human vas has been successfully completed.

INSTRUMENT DESCRIPTION

The instrument was designed to deliver low duty cycle, high-voltage, square-wave pulses. A laboratory instrument, designated the C.D.S. Cautery, Mark II, was designed so that the variables, pulse rate, pulse width, and peak pulse voltage, could be independently adjusted. The versatility of the Mark II allowed for optimization of these variables. This optimization is necessary in order to produce lesions in the vas consistent with lesions produced by the Schmidt technique.

The instrument consists of several basic circuits as depicted in the block diagram of Figure 1. Figure 2 is a complete electrical schematic. The Pulse Rate Generator is comprised of a unijunction relaxation oscillator with adjustable frequency. The rate of the pulse train can be varied from 150 to 1,500 pulses per sec. The output of this generator drives the Pulse Width Controller, a monostable multivibrator with adjustable time constant. The duration of the pulses emitted from the Pulse Width Controller can be varied from 10 to 100 μsec. The Output Amplifier increases the pulse train power level to that necessary to coagulate tissue. To maintain a low battery drain, the output amplifier was designed so that the power transistors draw current only during the short time that a pulse is present. The output of the amplifier is coupled to the cautery electrode through a step-up pulse transformer which provides the necessary high voltage. This transformer also electrically isolates the output from the rest of the circuit which assures patient safety.

A combination of high pulse rates and wide pulse widths causes a degradation of the square-wave shape of the pulse due to the limitations of the

Superior numbers refer to similarly numbered references at the end of this paper.

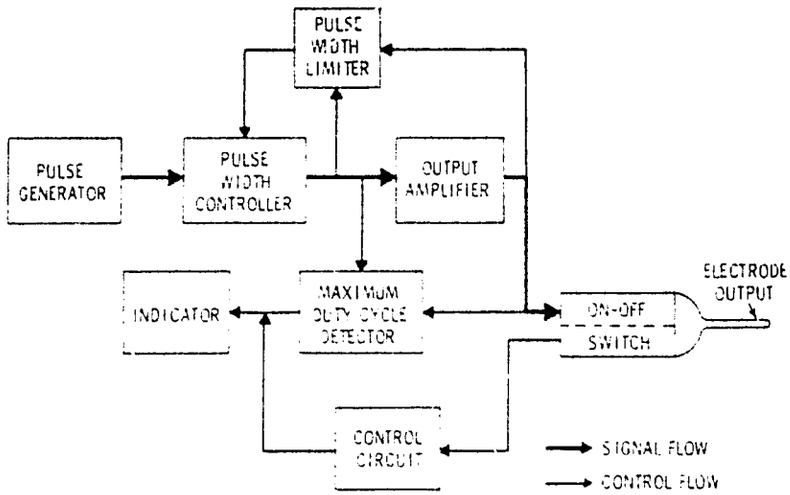

FIGURE 1. Block Diagram of the C.D.S. Cautery, Mark II

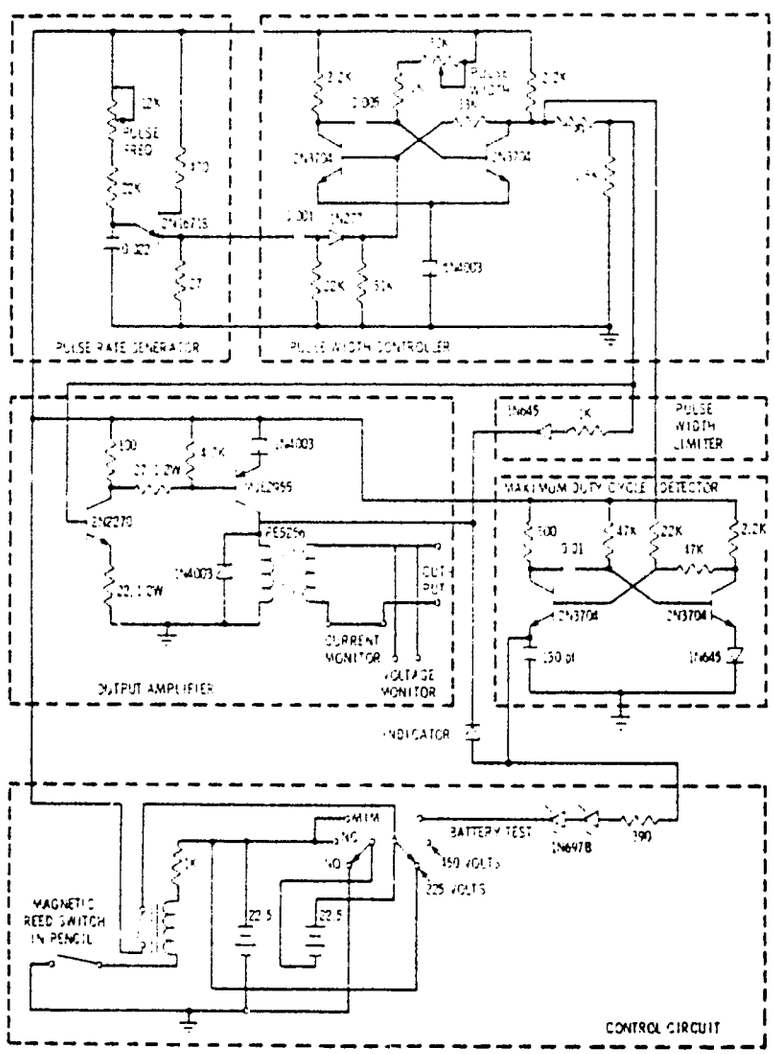

FIGURE 2. Electrical Schematic of C.D.S. Cautery, Mark II

output transformer. When the pulse degrades, the output transistor must dissipate a self-destructive amount of power. The Pulse Width Limiter protects the output transistor under these conditions by forcing the output of the Pulse Width Controller to zero if the voltage across the primary winding of the transformer begins to diminish. This action terminates the pulse and assures a fast fall time.

The Maximum Duty Cycle Detector energizes a light-emitting diode indicator under the identical conditions that operate the Pulse Width Limiter. The detector consists of a monostable multivibrator which, similar to the Pulse Width Limiter, monitors the voltage between the output of the Pulse Width Controller and the primary of the pulse transformer. If the output of the controller remains high as the voltage across the transformer falls to zero, the monostable will trigger on and light the light-emitting diode (LED) indicator for approximately 100 μsec during each cycle.

The control portion of the circuit includes two pairs of parallel-connected 22.5 volt, B-type batteries;* the on-off switching circuit described in greater detail below; and a "hi-lo" voltage selection switch with a momentary battery test position. When the 225-volt "lo" voltage output is selected, the three-position switch connects the two pairs of batteries in parallel, supplying 22.5 volts to the circuits. When the 450-volt "hi" voltage output is selected, the two pairs of batteries are connected in series, supplying 45 volts to the circuits. When the switch is in the momentary battery test position, the 45 volts are connected through two-series, back-biased, 18-volt zener diodes to the LED indicator. Thus, as long as the total supply voltage exceeds about 40 volts, the LED will light brightly indicating that the batteries are good.

In order to eliminate the necessity of a foot switch, a finger-controlled switch was included in the electrode pencil. The switch is comprised of a magnetic reed switch operated by a sliding magnet (Figure 3). The reed switch and all wiring in the pencil are completely embedded in the epoxy of which the handle is constructed. This embedment allows the handle to be heat-sterilized.

The needle is a concentric bipolar electrode originally intended for deep brain encephalographic recording (Figure 4a). Approximately half of the needle is embedded in an epoxy base along with a connector, allowing the base to be plugged into the pencil (Figure 3). The electrode also can be heat-sterilized.

A photograph of the completed instrument is shown in Figure 5.

RESULTS

Evaluation of C.D.S. Cautery, Mark II instrument is based on visual examination of vasectomies performed on guinea pigs. Also, lesions formed in human vas by a Birtcher electrocautery (Schmidt technique) were compared with lesions formed in freshly excised human vas by the Mark II.

Animal Trials

Bilateral vasectomy was attempted in two guinea pigs using the Mark II unit. Additionally, the unit has been used prior to the insertion of vas valve and tubing in three additional guinea pigs. In all cases, the degree of blanching resulting from the electrode could be clearly followed and controlled by withdrawing the needle or switching off the current.

One animal was vasectomized according to the method of Schmidt and autopsied 16 days later. The right vas, fulgurated with a pulse width of 80 μsec (450 volts, 300 Hz), exhibited a satisfactory blockage in both cut ends that withstood the additional pressure of syringe insufflation. In the left vas, fulgurated with a pulse width of 60 μsec (450 volts, 300 Hz), the central cut end was satisfactorily blocked; but the peripheral end gave the impression of blockage followed by burst. Sperm appeared to have accumulated in a large mass in the connective tissue surrounding the cord. The current necessary to produce the lesions in this animal was less than 60 milliamps. In a second guinea pig the intact vasa were fulgurated by insertion of the probe through the vas sheath and wall. Autopsy 17 days later revealed plugs of scar tissue in both vasa although they did not appear to be forming a complete block as vasal fluid content could be expressed through the plug. Complete vasal plug formation in the guinea pig following fulguration of the vasal mucosa may be impaired by the high pressure (up to 80 mm Hg) generated in the vas lumen following vas occulsion.

The evaluation of the use of the Mark II on human vas was conducted in the following manner. During a routine vasectomy performed by Schmidt, the proximal end of the transected vas was fulgurized by a Birtcher electrocautery using the standard Schmidt technique. A 2-mm segment of the vas, containing the lesion, was then excised and identified for later histological evaluation. A 2-mm segment of the distal vas was excised, fulgurized by the Mark II electrocautery and identified for later histological evaluation. The standard Schmidt vasectomy procedure then followed so as not to jeopardize the success of the operation. The results of the histological evaluation are given in Table I. The aim of fulguration of the vas is to destroy the epithelial lining without disrupting the surrounding vas musculature. The coagulated epithelial cells slough off, and the muscle tissue gives rise to scar tissue which permanently blocks the lumen of the vas. It appears that the Mark II cautery accomplishes this aim quite well when set at 225-volt pulse magnitude, 300-sec pulse rate and 88-μsec pulse width. At this setting the entire luminal epithelium is destroyed, but less destruction of the musculature occurs than when the Birtcher electrocautery is used.

The evaluation procedure was to be conducted on 10 sections of vas; however, failure of the needle electrode limited the number to 2 sections. The

*Burgess No. 4156 or Eveready No. 763

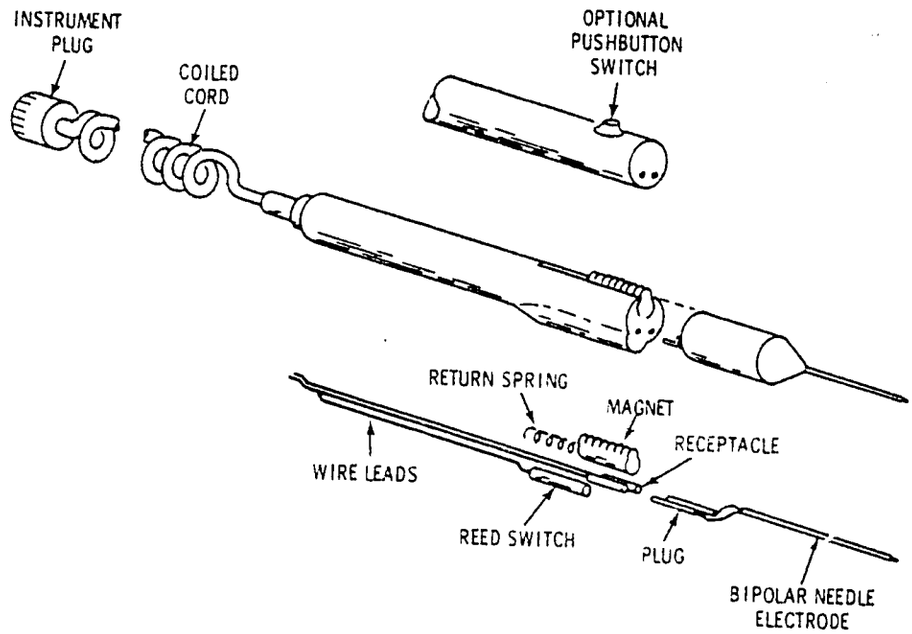

FIGURE 3. Electrode Pencil Showing Sliding Magnet Finger-Operated Switch and Optional Pushbutton Switch

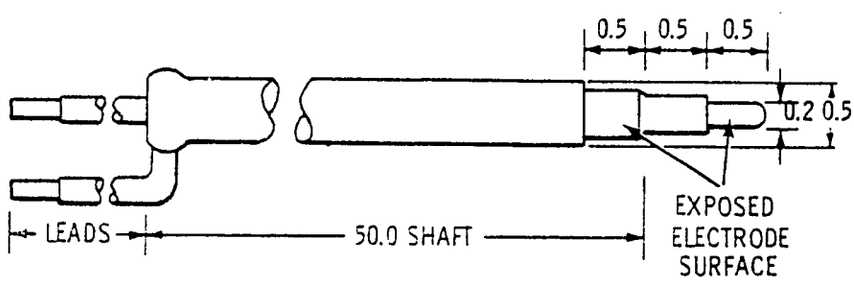

FIGURE 4a. Bipolar Needle Electrode (All measurements are in millimeters)

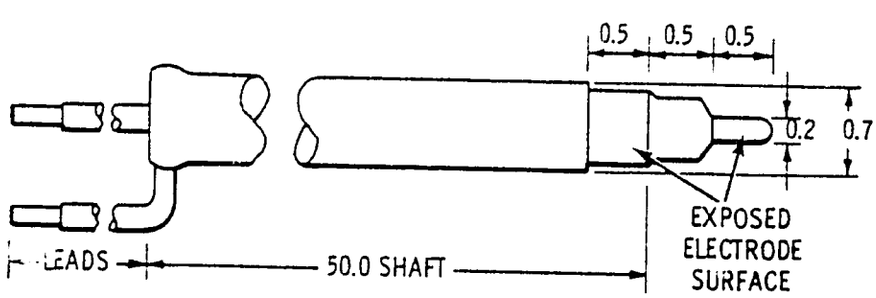

FIGURE 4b. Proposed Modification of Bipolar Needle Electrode (All measurements are in millimeters)



FIGURE 5. C.D.S. Cautery, Mark II

TABLE I. Histological Comparison of Fulguration by Birtcher and C.D.S. Electrocautery Instruments

Electrocautery Instrument Used	Instrument Settings	Microscopic, Histological Examination Results
Birtcher	Schmidt Standard	Considerable electrical heat destruction of the luminal epithelium, mild coagulation necrosis of the tissues of the muscularis a few cells in thickness
C.D.S., Mark II	225 volts (pulse magnitude) 300 Hz (pulse rate) 88 μsec (pulse width)	Electrical heat destruction of the luminal epithelium, little coagulation necrosis of the muscle coat immediately adjacent to the luminal epithelium
C.D.S., Mark II	225 volts 400 Hz 88 μsec	Complete electrical heat destruction of the luminal epithelium, coagulation of the muscular coat for a depth of about 10 to 12 cells around the periphery of the lining

insulation between the bipolar electrode elements broke down as the unit was tested at the 450-volt setting. This fault was not detected during bench testing and may have been aggravated by repeated autoclaving of the electrode. The thickness of insulation will be increased to assure that the problem does not reoccur.

DISCUSSION

The bipolar concentric electrode which is characteristic of the C.D.S. Cautery may possibly simplify vasectomy to a nonsurgical, "transdermal" procedure. The vas deferens can be easily palpated, beneath the skin, high in the scrotum. After local anesthesia a length of vas would be pushed into a small fold of the scrotal dermis. A towel-clamp would then be inserted through the skin of the fold beneath the vas to hold the vas securely in this position just below the skin. The bipolar needle would then be inserted through the skin into the lumen of the vas, and the current would be applied to fulgurate a small section. This transdermal technique relies on the theory that sufficient scar tissue would be formed in the intact vas to permanently block sperm flow. This theory has been tested successfully by Schmidt in one dog. A similar test was performed in a guinea pig at our laboratory. The result was not so encouraging as the scar tissue block was easily broken by the pressure of syringe inflation of the vas.

Several major shortcomings of the C.D.S. Cautery became apparent during evaluation. All of these problems concerned the needle electrode or the electrode pencil. Testing on the human vas showed that better electrical contact would be made between the luminal epithelium and the two electrode elements if the needle were slightly larger in diameter. The proposed electrode is depicted in Figure 4b. This electrode will be stiffer and, therefore, more suitable for the transdermal technique of vasectomy described above.

Repeated autoclaving appears to slightly degrade the insulation between the concentric elements of the bipolar needle electrode. When used with a coagulating pulse magnitude of 450 volts, arcing occurred which shorted the two elements. Increasing the thickness of insulation between the two elements will solve this problem and result in the desired increased electrode diameter.

Through test and evaluation of the Mark II cautery the values of the parameters (i.e., pulse magnitude, pulse rate and pulse width) have been defined. An acceptable fulguration is produced by a square pulse of 225-volt magnitude and 80-usec width, occurring at a rate of 300 pulses per sec. Eliminating the variable controls of these parameters will yield a smaller, lighter instrument which will be easier to operate, as it will have only one switch. Eliminating the excess circuitry will reduce the current drain from the batteries, thus eliminating the need for large batteries. A new model, designated the C.D.S. Cautery, Mark III, incorporates these simplifications (Figure 6). The latest in integrated circuit design has been used to reduce the fabrication costs. Bench testing of this model has been completed, and a completely packaged unit as shown in Figure 7 is presently being field tested.

REFERENCES

1. Schmidt, S. S., 1973. Prevention of Failure in Vasectomy. J. Urol. Feb. (In Press)

2. Petty, P. G., A. J. Lim and R. Stahl, 1968. A Solid State Pulsed Coagulating Diathermy Instrument: Preliminary Report, Aust. N.A. J. Surg., Vol 38, 172-176.

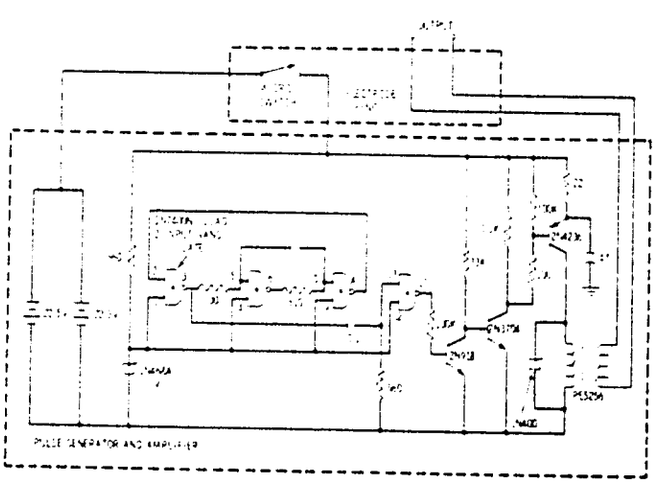

FIGURE 6. Electrical Schematic of C.D.S. Cautery, Mark III



FIGURE 7. C.D.S. Cautery, Mark III

VAS CAUTERY: BATTERY-POWERED INSTRUMENT FOR VASECTOMY

STANWOOD S. SCHMIDT, M.D.
ROBERT CARMICHAEL
JOHN DECKER
MICHAEL J. FREE, PH.D.

From the Division of Urology, University of California School of Medicine, San Francisco, California

ABSTRACT—Fulguration is the best means of sealing the cut ends of the vas at vasectomy, but the classic electrosurgical units can destroy the muscular wall of the vas and create complications. The cautery described herein, designed expressly for vasectomy, effects epithelial but no muscular destruction sufficient to produce hazardous side effects.

Fulguration of the lumen is now recognized as the optimal method of sealing the cut ends of the vas at vasectomy. Spermatic granuloma of the vas and its sequela, spontaneous reanastomosis, are significantly less likely to occur when this technique is used. In 1973, Schmidt[1] reported a series of 1,000 consecutive cases wherein this method, combined with closure of the fascial sheath of the vas, was used. This series now numbers more than 1,600 cases, without failures and with minimum spermatic granulomas of the vas.

One disadvantage is the use of standard types of electrosurgical units (Bovie, Birtcher, and others). Here, experience and judgment are critical. The ideal current application should result in destruction of the epithelium of the vas only and in preservation of the muscular wall, which would then serve as a source of fibrous tissue to seal off the end of the vas. Even when a "light touch" is used, tissue sections show significant muscular destruction. Because of the vast reserve of power in these electrosurgical units, additional fulgurizing current will destroy the full thickness of the vas wall. Necrosis, sloughing, and sperm leakage soon follow.

Moreover, another disadvantage is that the standard unit requires a 110-volt current. In some areas of the world this may be difficult to secure.

Carmichael and Decker,[2] of the Battelle Memorial Institute, have produced a cautery* which has been expressly designed for vasectomies (Fig. 1A). Its power source is one 22.5-volt dry battery. Since it employs a bipolar needle, grounding of the patient is unnecessary (Fig. 1B). The cautery draws a minimum of current so that several hundred vasectomies can be performed with one battery. The entire unit weighs about 2 pounds.

Tissue sections show that this method produces complete epithelial destruction, with muscular destruction limited to only a few layers of cells. Since the purpose of fulguration is to destroy the epithelium, the use of this cautery is a marked improvement over that of customary electrosurgical unit (Fig. 2). The tissue destruction is self-limiting, thus excessive necrosis will not occur.

This instrument has been employed in a series of more than 100 vasectomies in the senior author's practice. To date, no spermatic granu-

*Cautery development supported by Agency for International Development, Contract AID/csd-3152.



FIGURE 1. *(A) Vas cautery and bipolar needle, and (B) diagram of bipolar needle.*

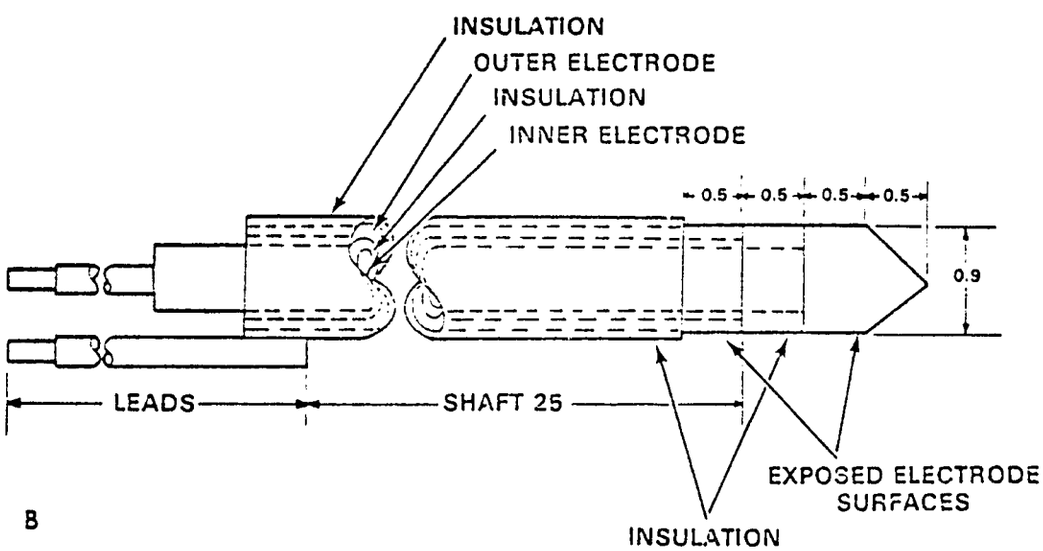

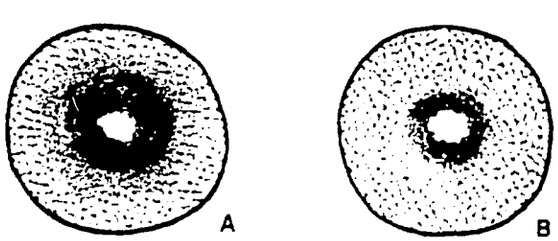

FIGURE 2. *Tissue destruction in vas: (A) electrosurgical unit, and (B) vas cautery.*

lomas have resulted, and there have been no surgical failures. The cautery is simple to utilize and is superior to the usual electrosurgical unit in performing vasectomies.

M-478, University of California
San Francisco, California 94143
(DR. SCHMIDT)

References

1. SCHMIDT, S. S., Prevention of failure in vasectomy, J. Urol. 109: 296 (1973).
2. DECKER, J., and CARMICHAEL, R., An electrocautery instrument for the fulguration of the vas deferens during vasectomy for sterilization, Proc. 10th Annual Rocky Mountain Bioengineering Symposium, 1973, p. 5–10.

New Technology for Voluntary Sterilization

M. J. FREE and G. W. DUNCAN

Battelle
Pacific Northwest Laboratories, Richland, Washington, U.S.A.
and
Population Study Center, Seattle, Washington, U.S.A.

The technologically-developed world has begun to see, feel, touch, smell and choke on the manifestations of over-consumption and over-population. The pioneer proponents of fertility control in the lesser developed countries are seeing their efforts outstripped by more easily practised and readily accepted death-control measures and impeded by cultural practices and religious dogma. Out of this growing awareness we see emerging the phenomenon of mass voluntary sterilization.

In the lesser-developed countries where the follow-up of individual patients is an impossible task and where repetitive procedures are easily forsaken or forgotten, the advantages of a contraceptive method requiring only one brief encounter between physician and individual to deliver nearly 100 per cent lifetime efficacy are overwhelming from a demographic and individual standpoint. Public health officials in some countries are realizing this and responding with vasectomy clinics in railway stations, country buses and camps. India has more than 19·3 sterilizations per 1,000 population (Pai, 1973). Eleven million sterilizations were recorded in that country by the end of May 1972. Only Bangladesh approached this rate of sterilization in the Eastern world although several other countries are on the way (Fig. 1).

In the Western world, and particularly in the USA, there is an increasing tendency for young people to accept sterilization as an irreversible commitment to limiting their families (Bumpass and Presser, 1972) and, apparently, as a way to get out from under the barrage of pills and paraphernalia (Presser and Bumpass, 1972a).

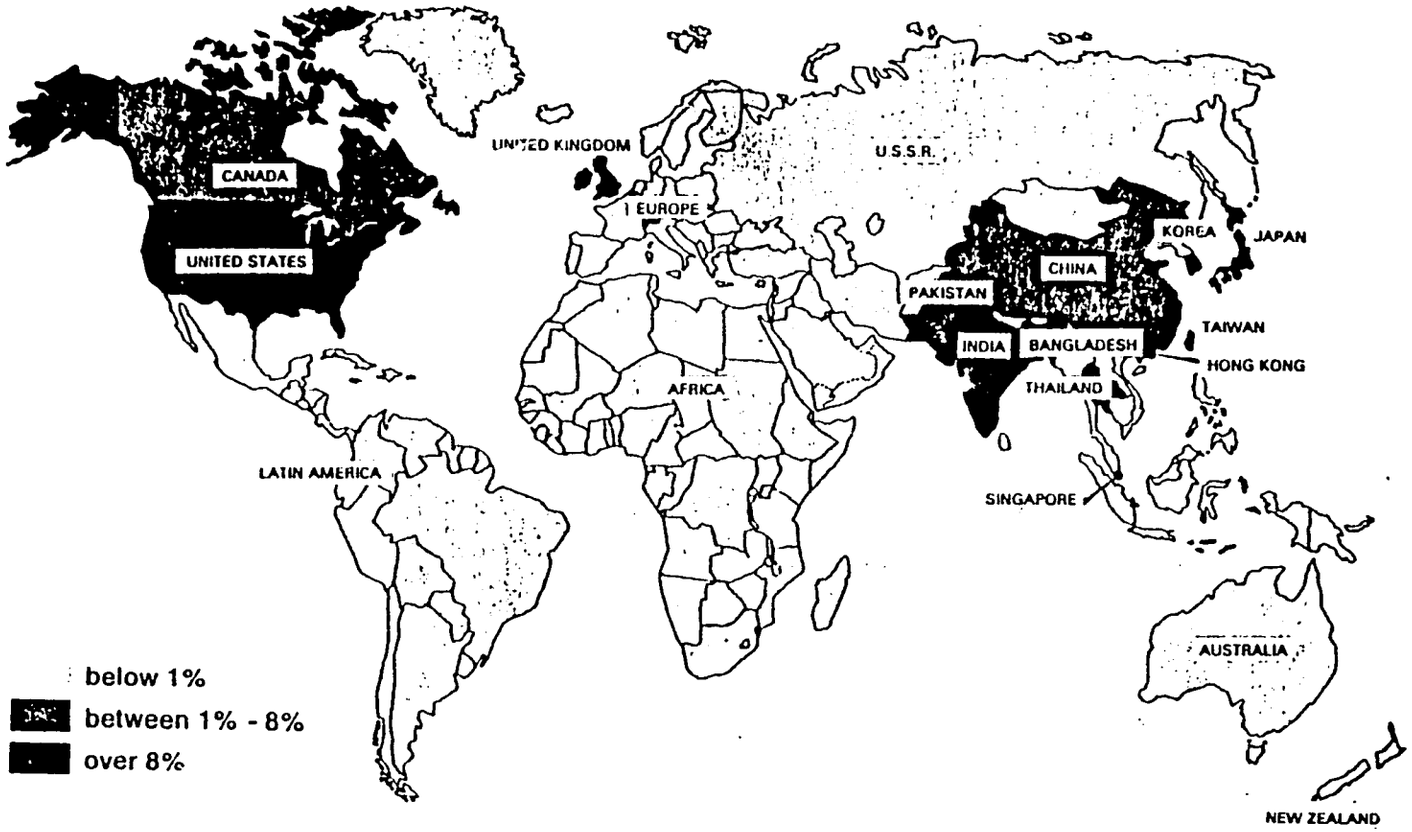

FIG. 1. Estimated world prevalence of voluntary sterilization 1972. Percentages are calculated on the basis of number of sterilized persons of reproductive age, male and female, per 100 women aged 15-44, in order to arrive at a figure indicating what percentage of fertile married couples are currently protected against unwanted pregnancy by this method. Source: Population Reports (1973).

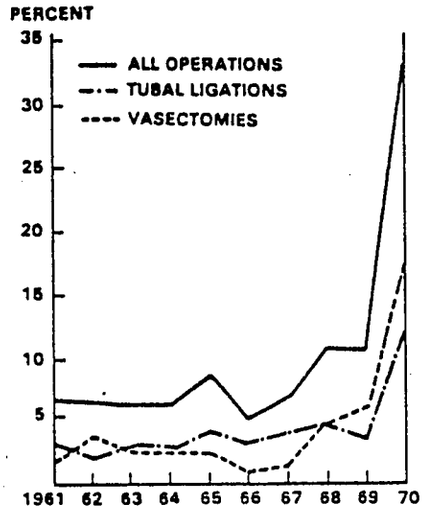

FIG. 2. Percentage of all sterile for contraceptive purposes in 1970 who were sterilized in each year: 1961–70. Source: Presser and Bumpass (1972b).

Figure 2 shows the trend in US vasectomies since 1961 (Presser and Bumpass, 1972b). One third of all people sterilized up to 1970 were sterilized in that year. Since that time the rate has doubled but is probably levelling off at the present time.

Male Sterilization

Male sterilization, or vasectomy, is a relatively simple doctor's office procedure (Fig. 3) salvaged from the arsenal of urological prophylactic procedures. It was formerly used to prevent the spread of urinary infection and made somewhat obsolete by antibiotics. In the 1920s, vasectomy was thought to increase sexual vigour (Steinach, 1920) and at the present time more than 13 million men are vasectomized throughout the world. Yet if vasectomy were a brand new procedure that had to be approved for human testing on the basis of animal experiments, it would have little chance of approval. The startling rise in popularity of the procedure, the dearth of organizable retrospective clinical information or controlled-perspective clinical studies and a spate of anecdotal clinical reports have stimulated a lot of laboratory activity in recent months. From these and earlier published studies we have learned of the spermatocoeles, adhesions and scrotal inflammation in rat (Smith, 1962; Flickinger, 1972; Alexander, 1973a; Sackler *et al.*, 1973), the antibody-induced degeneration of germinal cells in guinea pig (Alexander, 1973b), the apparently pressure-

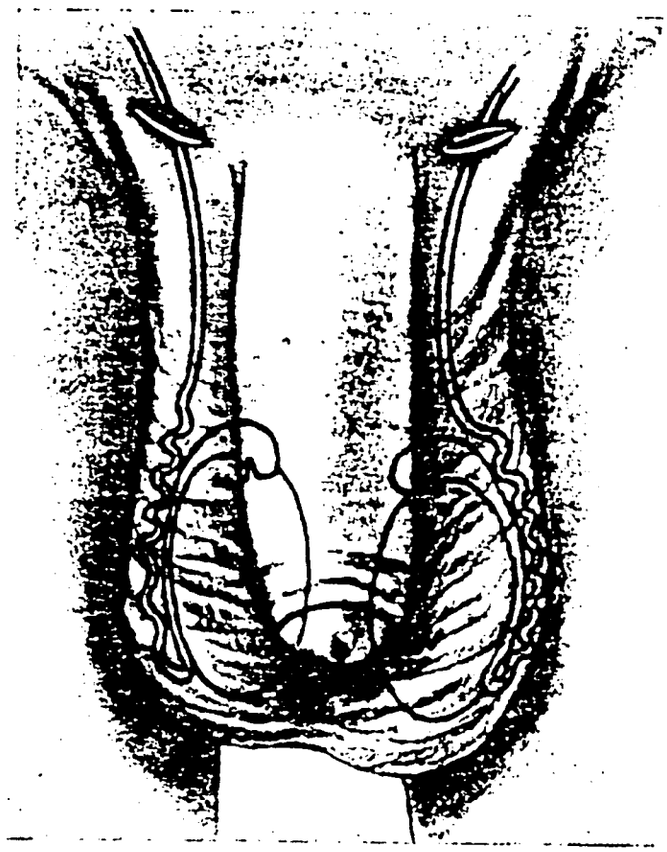

FIG. 3. Diagram showing optimum location for vasectomy. An outline of the testes, epididymides, and vasa deferentia is superimposed on the front view of the scrotum. Surgical incisions are shown over the straight portion of the vasa. Through these small incisions the vasa can be exteriorized and closed off by several alternative methods (see Fig. 6). Source: Schmidt (1972).

mediated necrosis of the testis in rabbit (Bedford, 1972), the epididymal and vasal granulomas in goat (unpublished data), all following occlusion of the vas deferens. All these changes are extensive and readily apparent to the trained observer and, to the degree that they occur in these animals, would not be tolerated in man.

Meanwhile, studies have been proceeding in a somewhat more dogged fashion on primates, including the human species itself. So far, while certainly revealing the room and need for improvement in traditional "cut and tie" methods of male sterilization, these studies are generally supporting the historical attitude of urologists who view

vasectomy in man as a relatively innocuous procedure: as safe, certainly, as most alternative forms of pregnancy prevention and other everyday probabilities. For example, testosterone levels remained unchanged over a four-week study following vasectomy in fifty men (Bunge, 1972). Gonadotrophins and hematologic and blood-chemistry parameters remain unchanged over 0–12 months of a continuing study following vasectomy in ninety-five men (unpublished data). Of particular interest, serum uric acid and cholesterol remained unchanged over this time period. Normal spermatogenesis has been observed in testicular biopsies up to seventeen years after vasectomy (Johnson, 1972), although some transient changes may occur immediately following the operation (Derrick *et al.*, 1973) and sperm granulomas occur in up to ten per cent of cases depending on the method of vas occlusion employed (Schmidt and Morris, 1973). Evidence that many reported effects in man are psychological is suggested by the unaltered sexual activity of Rhesus monkey following vasectomy (Phoenix, 1973). The one clear-cut change that does occur following vasectomy in a significant percentage of men is the build up of sperm antibody titers (Phadke and Padukone, 1966; Ansbacher *et al.*, 1972; Shulman *et al.*, 1972). This will be discussed later in the context of reversibility of vasectomy.

At least ten additional studies are presently being conducted in U.S. clinics and laboratories on vasectomized human volunteers or subhuman primates. Thus much more information on the sequelae of vasectomy in these key species will become available in the next one or two years and will hopefully make unnecessary any further extrapolation of experimental data from unsatisfactory animal models. One reason for the differences in response to vasectomy between man and lower mammals may well have to do with the innervation of the epididymis. The middle spermatic nerve courses safely along the spermatic artery in man, whereas in lower mammals its equivalent accompanies, and probably suffers the same fate as, the vas deferens.

There is now the debatable question that is causing some divergence in the objectives of medical scientists and clinicians working in this field: Would significantly more people accept vasectomy if it were a reversible procedure? In some of the lesser-developed countries, where the dependence on children for support in old age and concomitant fear of child mortality is a major factor for birth control acceptability (Pai, 1973), the answer to the question is most likely to be "yes". In the technologically developed countries, where the motives for voluntary sterilization may perhaps have a higher ideological or philosophical content, the answer to the question is less certain.

Within the ranks of those who view vasectomy as a reversible or potentially reversible procedure, there is another divergence of opinion. Firstly, there are those who view the reanastomosis of the vas deferens by surgical means as a practical and potentially generally applicable procedure and see a need for technological innovation only in the surgical tools for carrying out this procedure. These tools may include tissue adhesives (Bornemisza and Furka, 1970; Gursel *et al.*, 1971) or various types of splints (Steinhardt, 1969). On the other hand, there are those who believe that reversibility of vasectomy would be facilitated by the development of a valve-like device which could be implanted into the vas deferens in lieu of vasectomy and would allow sperm to stop or go at the will of the individual and the hand of the surgeon. Several laboratories and clinics are pursuing the idea of a reversible intravasal occlusive device (Table I). These devices range from the well publicized gold and stainless steel Bionyx "Phaser" currently being tested in human volunteers at New York Medical College (Fig. 4) to various plastic, ceramic and metal devices. Details of some of these devices including the gold Phaser are not public information at the present time. Our own model (Fig. 5), as an example of the plastic genre of devices, incorporates much of the current thinking on optimizing anatomic and physiologic conditions for reversal of vas occlusion. It is easily and cheaply fabricated, can be installed in the vas with a minimum of disturbance to blood, nerve, lymph and muscle continuity, will bind to the vas by allowing and promoting tissue ingrowth, is sufficiently compliant to respond to tissue deformation and muscular compression, will totally block the passage of sperm through the vas, is easily reversible by surgical intervention and permits verification of potency at the time of reversal. It is currently being tested in animals.

Common to both objectives, the intravasal device or surgical reanastomosis, is a need for improved methods of simple vasectomy that would facilitate restoration of fertility if that need arose in the individual. A large number of variations of the basic procedure of vasectomy are utilized on a routine basis around the world (Klapproth and Young, 1973). In the near future there will undoubtedly be some extensive comparative studies of these methods. There is now a growing awareness of the need to maintain nerve, blood vessel, lymphatic and even muscle continuity in the vas deferens if reversibility is to be optimized. It seems likely that the current practice of removing segments of varying lengths from the vas deferens will be found to be unnecessary providing the mucosal lining of the vas is interrupted and effectively prevented from regenerating.

TABLE I

Current or recent research in the U.S.A. on reversible intravasal devices

Institution (Principal investigators)	Funding agency	Concept
New York Medical College, School of Medicine (M. Freund and J. Davis)	NIH (NICHHD)	Gold and stainless steel stopcock installed in the sectioned vas with gold mesh for ingrowth.
Ortho Pharmaceutical Corporation, Baritan, New Jersey.	Ortho	Metal device with magnetic valve for nonsurgical reversal.
Illinois Institute of Technology Research Institute Chicago, Ill., (E. E. Brueschke)	NIH (NICHHD)	Porous ceramic and etched stainless steel operated through a small opening in scrotal sac or by palpating scrotum. I sections conduits used.
Abcor Inc. Cambridge, Mass. (E. W. Nuwayser)	NIH (NICHHD)	Hollow fibre tube with bonded flock. Centre pin made of steel, vitallium or plastic.
Tecna Corp. Emeryville, California.	NIH	Plastic tubes with microporous surface for tissue ingrowth.
Illinois Institute of Technology Research Institute Chicago, Ill. (M. Burns and E. E. Brueschke)	AID (?)	Ferivasal occlusive device—occludes by external compression.
University of Missouri Columbia, Mo. (E. C. Mather)	NIH (NICHHD)	Reversible vasectomy prosthesis.
Medical Engineering Foundation Inc. Little Rock, Ark. (J. T. Turley)	?	Ball valve device made of fluoroplastic material. Flexible stems installed through a slit in the unsectioned vas by means of a special inverted V clamp. Valve kept in place by rolled plastic clip. Ball valve has slotted head.
Battelle Northwest Laboratories, Richland, Wash. (M. J. Free)	AID	Flexible plastic device with textured surface installed into the unsectioned vas in two halves. Halves are joined around a plastic plug and uncoupled and rejoined around open tube for reversal.

TABLE I (continued)

Institution Principal investigators	Funding agency	Concept
Southwest Foundation for Res. and Dev. San Antonio, Tex. D. C. Kraemer	NIH (NICHHD)	Nonocclusive device with copper or iron coils or threads inside a tube—spermicidal action.
Massachusetts General Hospital, Boston, Mass.	Population Council Inc.	Removable silastic obturator.
Carolina Population Center, U. North Carolina, Chapel Hill, N.C. J. Hulka	AID	Polypropylene tube with teflon velour. Also a proplast sponge.
Dept. of Urology Univ. of Iowa, Iowa City, Ia. (K. H. Moon and R. G. Bunge	?	Tapered polyethylene tubing installed in unsectioned vas with ends protruding. Ends are anchored with silver clips.

The electrocautery is finding increasing acceptance in the United States as a tool for improving simple vasectomy. Schmidt recently reported a series of 1,000 vasectomies in which no segment of the vas was removed and no ligatures were tied on the vas (Fig. 6) (Schmidt, 1973). Rather, the lumen of the proximal end was cauterized for 4 mm in such a way that the lesion was confined to the epithelium, lamina propria and part of the muscle wall. The distal end was cauterized on the cut surface only and the sheath of the vas was closed over it with a single ligature. This series now stands at 1,500 with no failures and less than one per cent of sperm granulomas or other complications (Schmidt, S. S. personal communication). This compares with around 0·5–3 per cent failures and up to 10 per cent of complications following vasectomy by ligation (Fig. 5) (Klapproth and Young, 1973); Schmidt, 1973). An additional advantage is that reanastomosis is technically easier following vasectomy by this procedure.

A bipolar electrocautery specifically designed for vas occlusion has been developed in our laboratory under the sponsorship of AID (Fig. 7). This small solid-state instrument is completely self-contained and draws very little power from its 22½ volt battery. The probe is sterilizable and the needle electrode interchangeable. Current flow is confined to the area between the two bands around the tip of the needle (Fig. 8) and is thus self-limiting. This device is currently under clinical evaluation and shows promise for improving simple vasectomies under field, railway station, bus or clinic conditions.

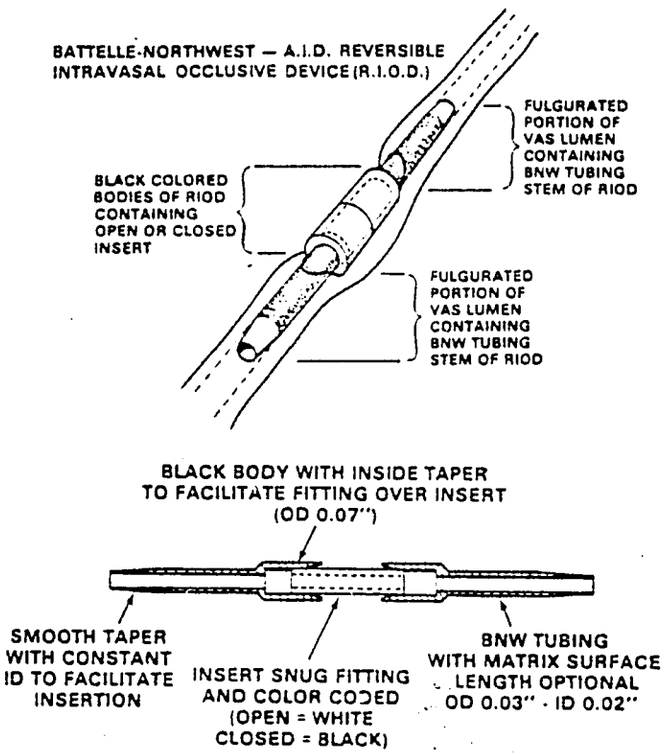

FIG. 5. The plastic "RIOD" device for reversible occlusion of the vas. See text for details. (Upper) Cross section. (Lower) The RIOD installed in the vas deferens.

An incisionless approach to vas occlusion has already been made by Sekhon in India using transcutaneous diathermy to transect the vas in one or two places (Sekhon, 1970). Other approaches to simple vas occlusion include the insertion of silicone plugs, thread and tubes that simply fill up the vas lumen (Lee, 1969; Klapproth and Young, 1973). It seems unlikely that these indwelling plugs will stand up to extensive testing without some form of adhesion or ingrowth with the wall of the vas. Tantalum clips are currently being used instead of ligatures in at least one clinic (Moss, 1972) and are being promoted for the purpose of vas and tubal occlusion by the manufacturer of hemoclips (Edward Weck and Co. Inc., New York). Looking further into the future, the use of injectable substances that induce scar tissue plugs in the vas remains a possibility. Amongst the latter studies, the recent report of Freeman and Coffey, (1973) using ethanol injection into the rat

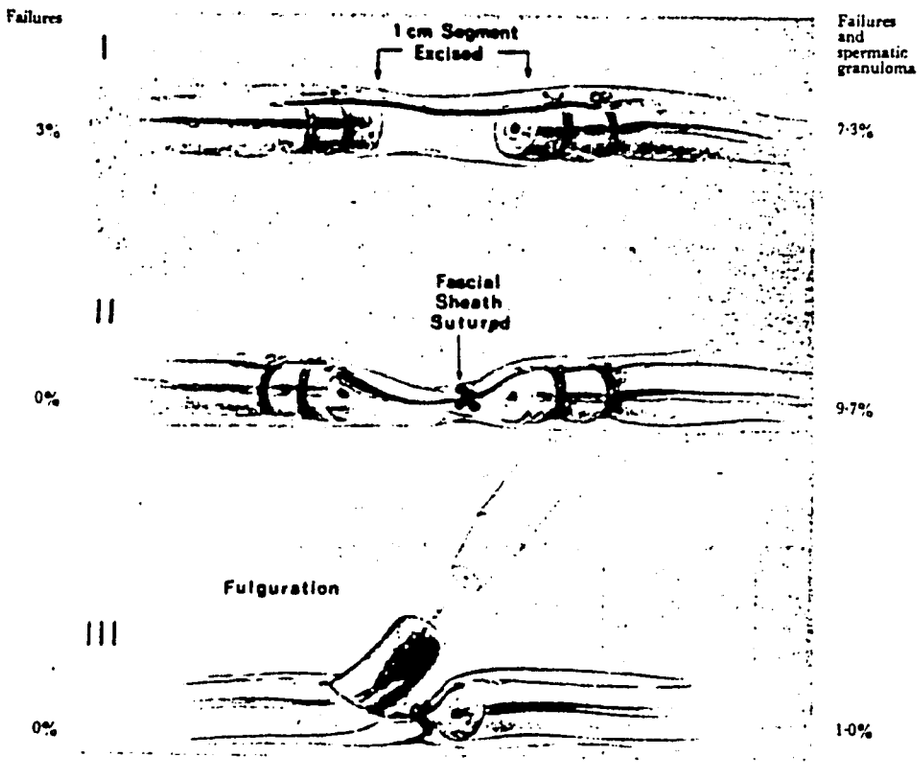

FIG. 6. Results of different methods of vasectomy. I, vas cut, doubly ligated and 1 cm segment excised. II, vas cut, doubly ligated, 1 cm segment excised and distal end covered over with fascial sheath. III, vas cut, proximal lumen fulgurated, distal end covered over with fascial sheath. Source: Schmidt (1973).

vas is of notable interest. In addition, quinacrine dihydrochloride has shown some vas occlusive effects in the rat vas (Setty *et al.*, 1972). The use of focused ultrasound for transcutaneous vasal cauterization has also been proposed by our laboratory and is in the preliminary design state at the present time.

Assuming that sperm can be returned to the ejaculate in sufficiently large numbers, will that achieve the objective of restored fertility? The currently available figures (Derrick, 1973) for surgical reanastomosis show a large discrepancy between success in restoring sperm levels and restoration of fertility (Table II). A more successful individual series yielded 55 per cent pregnancy with 83 per cent return of sperm in 76 patients (Phadke and Phadke, 1967). Indications are that these observations are linked with others showing an increase in

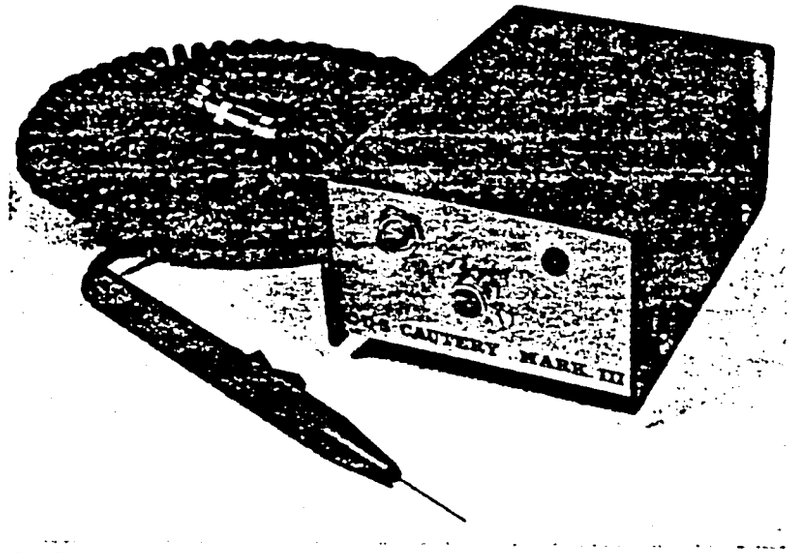

FIG. 7. A miniature, battery-powered bipolar cautery unit for use in the vas deferens. Source: Decker and Carmichael (1973.)

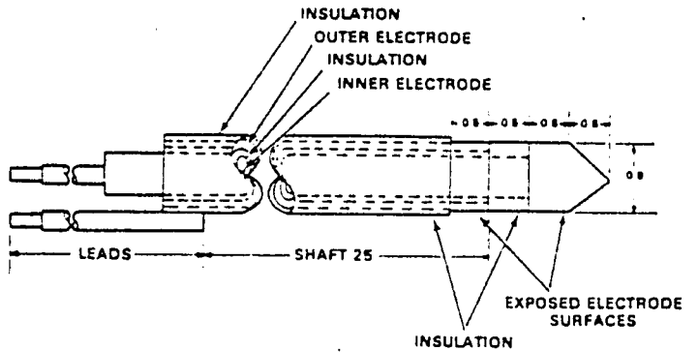

FIG. 8. Detail of the bipolar needle electrode for vas cautery unit. Source: Decker and Carmichael (1973).

antibody titers in 50–60 per cent of men following vasectomy (Phadke and Padukone, 1966; Ansbacher *et al.*, 1972; Shulman *et al.*, 1972). If these antibodies are found to impair epididymal function or spermatogenesis it may well be that all methods of vasectomy reversal will have only limited success unless some more sophisticated immunological precautions are taken. Additionally, the long-term pathological consequences, if any, of autoimmunity to sperm are unknown and are the subject of considerable research activity at the present time.

TABLE II

Survey of vasovasostomy

No. of physicians	Technique	No. of cases	% pregnancy
103	No splint	388	10·9
281	Wire splint	804	19·9
98	Cannulae splint	242	20·9
60	Nylon splint	196	26·0
542			19·3
	Return of normal sperm in 38 %		

Female Sterilization

Occlusion of the fallopian tubes in the human female presents many of the same ponderables as vas occlusion: to section or not to section; to remove a segment or not; to use clips or ligatures; to cauterize or not, to determine the optimum site of occlusion. In addition, female sterilization poses other sets of alternatives and attendant problems concerned with preoperative treatment, timing of the procedure and approach to the site of occlusion. Many of these alternatives are falling into line behind a few key technological innovations. The most profound of these innovations has been the development of fibre optics and the evolution of the endoscope to the status of an everyday surgical instrument. This instrument in the form of a laparoscope has turned female sterilization into an outpatient procedure in some clinics (Wheeless, 1972a, b; Wortman and Piotrow, 1973a), eliminating the risks associated with general anaesthesia, the expense associated with inpatient care, and the scar associated with the traditional laparotomy approach. Although most laparoscopists use general anaesthesia and two punctures to accommodate laparoscope and occlusioning tools (Neuwirth, 1972; Wortman and Piotrow, 1973a), the instrumentation and techniques have been developed for viewing and doing through a single abdominal puncture (Wortman and Piotrow, 1973b). Lower surgical risk, less scarring and greater acceptability of local anaesthesia are likely to make single puncture laparoscopy a major method in the future.

Another endoscopic technique, culdoscopy, approaches the occluding site through the vagina rather than abdomen (Fig. 9). It has all the advantages of laparoscopy. Additionally, it does not require insufflation of the abdominal cavity, leaves no external scarring and avoids the psychological trauma associated with abdominal surgery

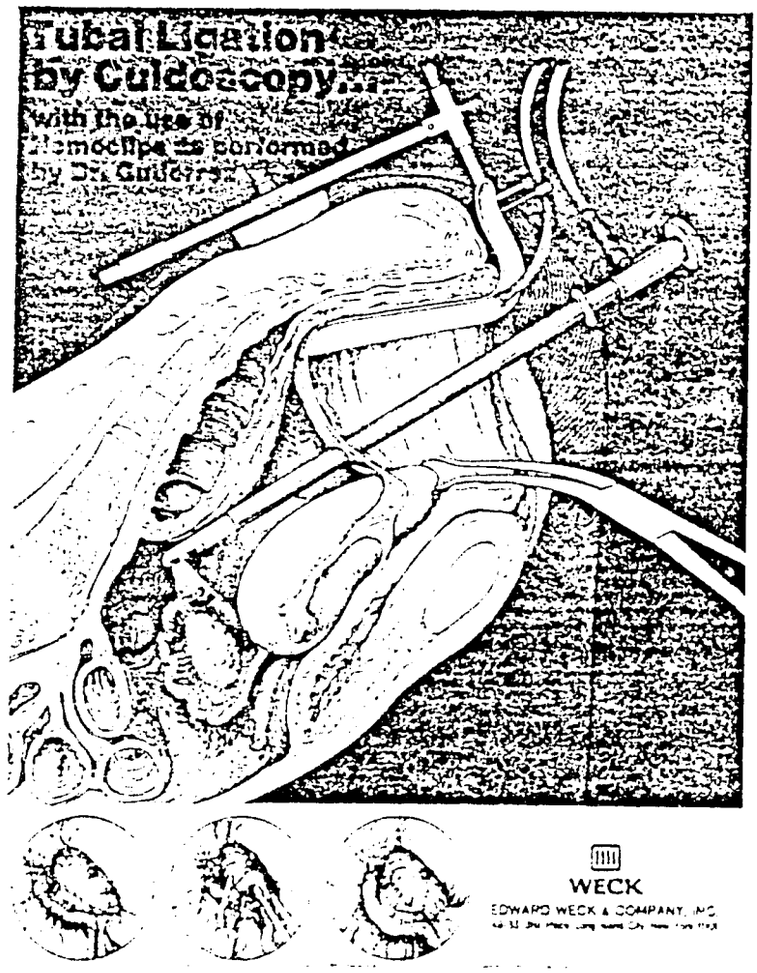

FIG. 3. Tubal Ligation by Culdoscopy. Source: Advertising brochure, Edward Weck and Company, Inc. 44-13 Pine Place, Long Island City, New York 11101.

(Clyman, 1972; Gutierrez-Najar, 1972). However, it apparently requires more skill and therefore, more training and experience. Consequently, extensive future use of this method may be primarily centred around large clinics.

All of these endoscopy methods suffer from the disadvantage of instrument cost, higher for laparascopy because of the equipment needed to pump CO_2/N_2O or, rarely, air into the body cavity. Because of this and also because some endoscopic techniques are not

suited to post-partum or post-abortion sterilization, it is unlikely that the traditional methods will die out completely. In particular, the non-endoscopic transcervical procedure, colpotomy, requires the minimum of surgical equipment, can be done under local anaesthesia and is probably adaptable to outpatient procedure, making it ideal for widespread application in developing countries (Wortman and Piotrow, 1973c).

Methods of actually occluding the fallopian tubes have included ligatures usually accompanied by sectioning, cautery with or without sectioning, tantalum hemoclips (Gutierrez-Najar, 1972; Hayashi, 1972) and more recently plastic and metal spring loaded clips which maintain constant tension on the tubes, thereby preventing necrosis and recanalization (Hulka and Omran, 1972a). Refinement of the surgical tools for applying these latter clips in conjunction with culdoscopy or colpotomy may significantly simplify the overall procedure and further increase its practicability and acceptability in the next few years.

For the longer term, it seems certain that non-surgical procedures of sterilization will become practical. These will utilize the transcervical approach and need, therefore, no more skill than that required to install an intrauterine contraceptive device. Use of the hysteroscope will allow direct visualization of the uterotubal junction if necessary. The methods of occlusion may be by chemical or inert liquids in the form of adhesives (Grode *et al.*, 1971; Falb *et al.*, 1972), barriers (Rakshit, 1968 and 1972; Omran and Hulka, 1970), sclerosing agents (Richarrt *et al.*, 1971; Zipper and Insunza, 1972; Zipper *et al.*, 1970) or combinations of these, or may involve electrocautery (Hulka and Omran, 1972b) or, more remotely, cryocoagulation (Droegemueller *et al.*, 1971), laser beams (Halbrecht, in press) and ultrasonic cautery.

Quinacrine has proved to be the most effective chemical tubal occlusion agent to date (Zipper and Insunza, 1972), although it requires two applications to achieve effective tubal obstruction in 90 per cent of cases. Among the adhesive agents, gelatin-resorcinol-formaldehyde (GRF.) has shown promise (Grode *et al.*, 1971).

Devices are being developed to deliver chemical occlusive agents precisely to the fallopian tubes without endoscopic visualization (Thompson *et al.*, 1972). They would act to seek out the uterotubal junction and form a gasket around it to prevent the back flow of injected chemicals. The chemicals may then be injected into the tubes from an external syringe. Such devices are the key to making female sterilization a paramedical procedure, thereby increasing its availability in more remote and sparsely-doctored areas of developing countries or regions.

Summary of Future Trends

Although a temporary slowing of the current rate of voluntary vasectomy in the technologically-developed countries seems inevitable as the once-only demands of motivated individuals are satisfied and the procedure undergoes close scientific scrutiny, the demands for female sterilization may continue to grow unabated as procedures become simpler, safer, and cheaper. In the developing countries, delivery of the means rather than acceptability of family limitation is the limiting factor. While instrument costs and maintenance problems may hobble the increase of female sterilization procedures until transcervical methods become practical, it seems likely that female sterilization will play a steadily increasing rôle in the birth control programmes of the developing world. More reversible methods of vas occlusion, feasible within the next five years, should boost the acceptability of this procedure in a younger and therefore more demographically-significant segment of the developing world population.

References

Alexander, N. J. (1973a). Ultrastructural changes in rat epididymis after vasectomy. *Z. Zellforsch*, **136**, 177.

Alexander, N. J. (1973b). Vasectomy and autoimmune aspermatogenesis in the guinea pig. *6th Annual Meeting, Society for Study of Reproduction*, Athens, Georgia.

Ansbacher, R., Keung-Yeung, K. and Wurster, J. C. (1972). Sperm antibodies in vasectomised men. *Fertil. Steril.*, **23**, 640.

Bedford, J. M. (1972). The consequences of vasectomy for the vas deferens and epididymis in the rat, hamster, rabbit and rhesus monkey. Presented at *Annual Conference, Society for Study of Fertility*. Reading, England.

Bornemisza, G. and Furka, I. (1970). Restoration of the divided ductus deferens by adhesive material. *Acta Chir. Acad. Sci. Hung.*, **11**, 335.

Bumpass, L. L. and Presser, H. B. (1972). Contraceptive sterilization in the U.S.: 1965 and 1970. *Demography*, **9**, 531.

Bunge, R. G. (1972). Plasma testosterone levels in man before and after vasectomy. *Invest. Urol.*, **10**, 9.

Clyman, M. J. (1972). Tubal sterilization by operative culdoscopy. In *Female Sterilization*. Edited by G. W. Duncan, R. D. Falb and J. J. Speidel. New York: Academic Press.

Decker, J. and Carmichael, R. (1973). An elecrocautery instrument for the fulguration of the vas deferens during vasectomy for sterilization. (Presented at the Tenth Annual Rocky Mountain Bioengineering Symposium). Pittsburgh, Pennsylvania: Instrument Society of America.

Derrick, F. C. (1973). Survey on reanastomosis. Reported at *29th Annual Meeting, American Fertility Society*, San Francisco, and summarized in *Family Planning Digest*, **2**, 7.

Derrick, F. C., Glover, W. L., Kanjuburumbam, Z., and Jacobson, C. (1973). Histopathological changes in spermatogenesis following vas deferens occlusion. *29th Annual Meeting, American Fertility Society*, San Francisco.

Droegemueller, W., Makowski, E. and Macsalka, R. (1971). Destruction of the endometrium by cryosurgery. *Amer. J. Obstet. Gynecol.*, **110**, 467.

Falb, R. D., Grode, G. A. and Pavkov, K. L. (1972). Adhesive blockage of the fallopian tube. In *Female Sterilization*. Edited by G. W. Duncan, R. D. Falb and J. J. Speidel. New York: Academic Press.

Flickinger, C. J. (1972). Alterations in the fine structure of the rat epididymis after vasectomy. *Anat. Rec.*, **173**, 277.

Freeman, C. and Coffey, D. S. (1973). Chemical induction of male sterility by injection of vaso-sclerosing agents. *Fed. Proc.*, **32**, 310 Abs.

Grode, G. A., Pavkov, K. L. and Falb, R. D. (1971). Feasibility study on the use of a tissue adhesive for the nonsurgical blocking of fallopian tubes. Phase I: Evaluation of a tissue adhesive. *Fertil. Steril.*, **22**, 522.

Gursel, E., Zinsser, H. H. and Hrdlicka, G. (1971). Nonsutured, nonsplinted anastomosis of the vas deferens: A preliminary report. *Invest. Urol.*, **8**, 417.

Gutierrez-Najar, A. J. (1972). Culdoscopy as an aid to family planning. In *Female Sterilization*. Edited by G. W. Duncan, R. D. Falb and J. J. Speidel. New York: Academic Press.

Halbrecht, I. In Proceedings of the 2nd International Conference on Voluntary Sterilization, February 25–March 1, 1973, Geneva, Switzerland. *Excerpta Medica* (in press).

Hayashi, M. (1972). Tubal sterilization with clips. In *Human Sterilization*. Edited by R. M. Richart and D. J. Prager. Springfield, Illinois: C. C. Thomas Co.

Hulka, J. F. and Omran, K. F. (1972a). Comparative tubal occlusion: Rigid and spring-loaded clips. *Fertil. Steril.* **23**, 633.

Hulka, J. F. and Omran, K. F. (1972b). Cauterization for tubal sterilization. In *Human Sterilization*. Edited by R. M. Richart and D. J. Prager. Springfield, Illinois: C. C. Thomas Co.

Johnson, D. S. (1972). Reversible male sterilization: Current status and future directions. *Contraception*, **5**, 327.

Klapproth, H. J. and Young, I. S. (1973). Vasectomy, vas ligation and vas occlusion. *Urology*, **1**, 292.

Lee, H. Y. (1969). Experimental studies on reversible vas occlusion by intravasal thread. *Fertil. Steril.*, **20**, 735.

Moss, W. M. (1972). A sutureless technic for bilateral partial vasectomy. *Fertil. Steril.*, **23**, 33.

Neuwirth, R. S. (1972). Nonpuerperal sterilization by laparoscopy. In *Human Sterilization*. Edited by R. M. Richart and D. J. Prager. Springfield, Illinois: C. C. Thomas Co.

Omran, K. K. and Hulka, J. F. (1970). Tubal occlusion: A comparative study. *Int. J. Fertil.*, **15**, 226.

Pai, D. N. (1973). *Keynote Address of the 2nd Int. Conference of the Assoc. Volunt. Steri.* Geneva.

Phadke, A. M. and Padukone, K. (1966). Presence and significance of autoantibodies against spermatozoa in the blood of men with obstructed vas deferens. *J. Reprod. Fertil.*, **7**, 163.

Phadke, G. M. and Phadke, A. G. (1967). Experiences in the reanastomosis of the vas deferens. *J. Urol.*, **97**, 888.

Population Reports, Series C-D, (Feb. 1973). Population Information Program, Dept. of Medical and Public Affairs of the George Washington University, Medical Center, 2001 S St., N. W., Washington D.C. 20009, U.S.A.

Phoenix, C. H. (1973). Sexual behaviour in rhesus monkeys after vasectomy. *Science*, **179**, 493.

Presser, H. B. and Bumpass, L. L. (1972a). The acceptability of contraceptive sterilization among U.S. couples: 1970. *Family Planning Perspectives*, **4**, 18.

Presser, H. B., and Bumpass, L. L. (1972b). "Demographic and Social Aspects of Contraceptive Sterilization in the United States. 1965–70." Report to the Commission on Population Growth and the American Future, In *Demographic and Social Aspects of Population Growth*. Edited by C. F. Westoff and R. Parke, Jnr. U. S. Government Printing Office, Washington, D. C. February.

Rakshit, B. (1968). Experiments on tubal blocking for sterilization without laparotomy. *J. Obstet. Gynecol., India*, **18**, 282.

Rakshit, B. (1972). Scope of liquid plastics and other chemicals for blocking the fallopian tube. In *Human Sterilization*. Edited by R. M. Richart and D. J. Prager. Springfield, Illinois: C. C. Thomas Co.

Richarrt, R. M., Gutierrez-Najar, A. J. and Neuwirth, R. S. (1971). Transvaginal human sterilization: A preliminary report. *Amer. J. Obstet. Gynecol.*, **111**, 108.

Sackler, A. M., Weltman, A. S., Pandhi, V. and Schwartz, R. (1973). Gonadal effects of vasectomy and vasoligation. *Science*, **179**, 293.

Schmidt, S. S. (1972). Vas reanastomosis procedures. In *Human Sterilization*. Edited by R. M. Richarrt and D. J. Prager. Illinois: C. C. Thomas.

Schmidt, S. S. (1973). Prevention of failure in vasectomy. *J. Urtol.*, **109**, 296.

Schmidt, S. S. and Morris, R. R. (1973). Spermatic granuloma: The complication of vasectomy. *Fertil. Steril.* (In press).

Sekhon, G. S. (1970). Percutaneous vasectomy, a comparative study using a new instrument and technique. *Indian J. Med. Res.*, **58**, 1433.

Setty, B. S., Dasgupta, P. R. and Kar, A. B. (1972). Chemical occlusion of the vas in rats. *Contraception*, **6**, 329.

Shulman, S., Zappi, E., Ahmed, U. and Davis, J. E. (1972). Immunologic consequences of vasectomy. *Contraception*, **5**, 269.

Smith, G. (1962). The effects of ligation of the vasa efferentia and vasectomy on testicular function in the adult rat. *J. Endocrinol.*, **23**, 385.

Steinach, E. (1920). Verjuengung durch experimentelle neubelebung des altenden pubertaetsdruese. *Arch. Entwiklungsmech. Organismen*, **46**, 557.

Steinhardt, E. E. (1969). Vasovasostomy—a simplified technique. *Henry Ford Hosp. Med. J.*, **17**, 67.

Thompson, H., Dafoe, C. A., Moulding, T. S. and Seitz, L. E. (1972). Evaluation of experimental methods of occluding the utero tubal junction. In *Female Sterilization*. Edited by G. W. Duncan, R. D. Falb and J. J. Speidel. New York: Academic Press.

Wheeless, C. R. (1972)a. The status of outpatient tubal sterilization by laparoscopy: Improved techniques and review of 1,000 cases. *Obstet. Gynecol.*, **39**, 635.

Wheeless, C. R. (1972b). Outpatient sterilization by laparoscopy under local anaesthesia in less developed countries. In *Female Sterilization*. Edited by G. W. Duncan, R. D. Falb and J. J. Speidel. New York: Academic Press.

Wortman, J. and Piotrow, P. T. (1973a). Laparoscopic sterilization, a new technique. *Sterilization, Population Report*, Series C, No. 1, January.

Wortman, J. and Piotrow, P. T. (1973b). Laparoscopic sterilization II. What are the Problems? *Sterilization, Population Report*, Series C, No. 2, March.

Wortman, J. and Piotrow, P. T. (1973c). Colpotomy—the vaginal approach. *Sterilization, Population Report*, Series C, No. 3, June.

Zipper, J. and Insunza, S. (1972). Pharmacological agents that potentiate or inhibit the occlusive action of quinacrine in the rabbit tube and rat uterus. In *Female Sterilization*. Edited by G. W. Duncan, R. D. Falb and J. J. Speidel. New York: Academic Press.

Zipper, J., Stachetti, E. and Medel, M. (1970). Human fertility control by transvaginal application of quinacrine on the fallopian tube. *Fertil. Steril.*, **21**, 581.

THE JOURNAL OF UROLOGY
Copyright © 1976 by The Williams & Wilkins Co.

Vol. 115, January
Printed in U.S.A.

SPERM ANTIBODIES AFTER VASECTOMY WITH FULGURATION

N. J. ALEXANDER,* S. S. SCHMIDT, M. J. FREE, M. V. DANILCHIK AND W. T. HILL

From the Oregon Regional Primate Research Center, Beaverton and the Division of Urology, University of Oregon Health Sciences Center, Portland, Oregon; the Division of Urology, University of California School of Medicine, San Francisco and The General Hospital, Eureka, California, and the Battelle Pacific Northwest Laboratories, Richland, Washington

ABSTRACT

Whether antisperm antibodies develop after vasectomy probably depends on several variables, 1 of which may be the surgical technique. The levels of serum antisperm antibodies were compared in men vasectomized by 2 techniques: vasoligation and fulguration. No difference in the incidence of spermagglutinating antibody was found in the 2 groups. However, immobilizing antibodies were observed in 43 per cent of the men undergoing vasoligation but in only 29 per cent of the men vasectomized by fulguration.

Antisperm antibodies develop in about half of the vasectomized men.[1-3] However, why they develop in some and not in others is not well understood. The explanation involves several variables, including not only the basic immunocompetence of the individual but probably also such factors as the rate of sperm output, the sites of sperm resorption and extravasation, and the possibility of adjuvant inflammatory effects at the time of sperm extravasation. Moreover, different surgical procedures may lead to the formation of different kinds of vas blockage, which may or may not accentuate sperm extravasation. Therefore, antibody formation may be related to the surgical method. The fulguration method developed by Schmidt involves sectioning and fulguration of the vas without the conventional vasoligation.[4] It is suggested that the firm scar that forms on the cut and fulgurated ends of the vas is effective against granuloma formation.[5-7] On the other hand, there may be a short interval before scar formation during which time sperm have access to the scrotal tissues; if so, either tolerance or rapid sensitization and immunization may result. The reported low incidence of sperm granulomas associated with the fulguration technique prompted a retrospective study of 94 patients vasectomized by Schmidt during the last 11 years to compare them with an unmatched group of men vasectomized by ligation for a comparable period.

METHODS

Single 2 ml. blood samples were taken from 94 men vasectomized between January 1963 and December 1974 by the fulguration method described by Schmidt.[4] These samples were compared with sera from 87 men vasectomized by the conventional vas ligation technique by several different physicians. Thirteen additional samples taken from these men at different intervals are included in the comparison of time intervals but not in the comparison of the totals. Antibodies to spermatozoa were assayed by the macroscopic spermagglutination technique[10] and the sperm immobilization procedure.[11] The spermagglutinin titer was reported as the reciprocal of the last positive dilution. Spermagglutinating antibodies equal to or more than 20 were considered positive. Sera were considered positive for sperm immobilizing antibodies if the ratio of control percentages to test motility percentages was equal to or more than 2.0. The incidence and titers of sperm antibodies were examined for the following time intervals after vasectomy: 0 to 1/2, 1/2 to 1, 1 to 2, 2 to 3, 3 to 5 and more than 5 years.

RESULTS AND DISCUSSION

Of the 87 men vasectomized by means of vasoligation during the last 10 years 43 per cent exhibited sperm-immobilizing activity, while only 29 per cent of 94 men vasectomized with fulguration of the vasa had sperm-immobilizing antibodies (table 1). An X^2 analysis of these data shows the different frequencies to be significant only at p less than 0.10. When broken down into respective time periods this discrepancy diminishes. No differences in agglutination activity were observed between the 2 groups (table 2).

Testicular ends of the vas examined at the time of vasovasostomy reveal that about 20 per cent have had demonstrable spermatic granulomas. In addition, others have had epididymal obstruction which may be caused by spermatic granulomas. Schmidt and Morris report that fewer granulomas result from vasectomy by the fulguration technique than by vasoligation.[4, 5] They observed that the testicular end of the vas is capped by a firm scar without evidence of granuloma. The results of our study on antisperm antibodies reveal similar or slightly lower sperm immobilizing antibody levels in the fulguration group as compared to the vasoligation group. Alexander showed that sperm immobilizing antibody titers in vasectomized rhesus monkeys correlated with the incidence of sperm granulomas.[12] Her study involved vas fulguration similar to Schmidt's, yet exploratory operations showed that granulomas developed in 4 of the 6 monkeys. This high rate of granuloma formation after vasectomy may reflect a species difference between man and the rhesus monkey or a difference in surgical technique. Because human and rhesus sperm counts normally vary within the same order of magnitude per ejaculate, it is not expected that the rate of sperm output would account for the differences observed.

Brannen and associates have suggested that a low incidence of antisperm antibody levels may indicate cell-mediated immunity.[13] High antibody levels developed in rats with ligated vasa, whereas cell-mediated immunity developed exclusively in those with no ligation after vasectomy. However, granulomas developed in both groups. The type of immune response may well depend upon the rate and time of exposure to spermatozoa[13, 14] and the type of vasectomy performed may produce different immune responses. For at least a short while after vasectomy ligation completely prevents extravasation, and it is only after a certain lag that the combination of necrosis at the site of constriction and build-up of back pressure

Accepted for publication June 13, 1975.

Partial support for this study by Contract 70 from the Program for Applied Research on Fertility Regulation and Contract AID/CSD-3153 from the Agency for International Development.

Publication No. 813 from the Oregon Regional Primate Research Center.

* Requests for reprints: Oregon Regional Primate Research Center, 505 N.W. 185th Ave., Beaverton, Oregon 97005.

.26

FERTILITY AND STERILITY
Vol. 29, No. 6, June 1978
Printed in U.S.A.
Copyright © 1978 The American Fertility Society

THE BIPOLAR NEEDLE FOR VASECTOMY. I. EXPERIENCE WITH THE FIRST 1000 CASES*

STANWOOD S. SCHMIDT, M.D.†
MICHAEL J. FREE, PH.D.‡

Division of Urology, University of California School of Medicine, San Francisco, California 94143, and Battelle Northwest Laboratories, Richland, Washington 99352

A battery-powered, bipolar electrocoagulator has been specifically developed for sealing the cut ends of the divided vas at vasectomy. With a minimum of electric power, the electrocoagulator destorys only the mucosa and one or two muscle cell layers of the vas, which leads to optimal fibrosis of the cut ends.

This instrument has been used in more than 1000 vasectomies without a known failure and with a minimum of complications. An analysis of these cases is reported with emphasis upon the method's success in sealing the vas.

Vasectomy is the most popular means of sterilization for fertility control. Although many techniques exist for this operation, the electrocoagulation, fascial interposition technique "appears to have the best chance of preventing complications as well as permitting easier reversibility."[1] The senior author has performed more than 3000 consecutive vasectomies by this method—without a failure. In spite of this record, the operation can still be improved upon.

When a monopolar electrosurgical unit (Bovie or Birtcher type) is used for fulguration, experience and judgment are critical in determining the end-point. Tissue destruction may be inadequate; on the contrary, it may be so extensive that the end of the vas sloughs, leaving the lumen open, thus allowing leakage of sperm and the formation of a granuloma.[2] Furthermore, areas of the world exist where electric power is either unavailable or undependable. Transection of the vas, together with suturing its sheath, deprives the epididymis and proximal vas of innervation.[3] This lack of innervation could interfere with sperm transport after a future vasovasostomy.

All present techniques are those of open surgery, requiring skin incision by a surgeon. If a method for nondividing, percutaneous vas obstruction could be perfected, the operation would be performed faster and more simply; such an operation was attempted by the senior author some 20 years ago with the use of a monopolar needle. It failed—weak heat was created but electrocoagulation was not, owing to the relatively large surface area of the needle in contact with the tissue. Clearly, different electric circuitry was needed.

These problems were discussed in 1971 at a meeting sponsored by the Agency for International Development and held at the Battelle Population Study Center, Seattle, Wash.[4] In response to these proceedings, a battery-powered, bipolar electrocoagulator was developed for use in vasectomy.[5,6] This instrument has recently been refined and manufactured by Electro Medical Systems, Inc., Denver, Colo., under the trade name Vaseal (Figs. 1 to 3). In this model, current flows from the tip to the shaft of the needle electrode across a collar of insulation. Using a minimum of electric power, this electrocoagulator destroys only the mucosa and one or two muscle cell layers of the vas, leaving adequate live muscle to serve as a source of the fibroblasts which will seal off the vas lumen (Fig. 4).

Received January 17, 1978; accepted February 16, 1978.

*Presented at the Thirty-Fourth Annual Meeting of The American Fertility Society, March 29 to April 1, 1978, New Orleans, La.

†Reprint requests: Dr. Stanwood S. Schmidt, Urology, M-553, University of California School of Medicine, San Francisco, Calif. 94143.

‡Battelle Northwest Laboratories.



FIG. 1. Bipolar cautery system: power unit, hand control, and needle electrode.

Although not designed for this purpose, it is weakly effective in cauterizing small blood vessels. Since 1973, this unit has been used by the senior author in more than 1000 vasectomies—without a known failure and with a minimum of complications. An analysis of these cases is reported here with emphasis upon the method's success in sealing the vas.

SUBJECTS AND METHODS

Equipment. All vasa were electrocoagulated with the same basic equipment and circuitry.[6] The first unit, a handmade prototype electrocoagulator, was succeeded by a commercially made unit (the Vaseal) which incorporated refinements based on studies of the early prototype. Performance, except for needle life, was identical.

Because some components of the equipment used were withdrawn for study while they were still in working order, only a few were used until they ceased to function. Two batteries were used to failure. One lasted for 483 cases, the other for 264. The pencils, with switch and cord, were autoclaved between cases, and deterioration is ascribed to the autoclaving. One pencil lasted for 475 cases, another for 463.

Twenty needles were used to the point of failure (751 patients). All needles were autoclaved and were lightly cleaned between cases with a chlorine-containing pumice cleanser. Needle life varied from 9 to 88 procedures. The first 10 needles were used an average of 27 times per needle. The second 10 (manufactured after study of the earlier model and obviously improved) lasted an average of 48.1 times of use per needle. Recent studies suggest that needle life can be further prolonged if the needles are lightly cleaned with pumice without chlorine, and if they are cold-sterilized.

Patient Selection. Prospective patients were given a booklet which explained the procedure and its possible complications and which included

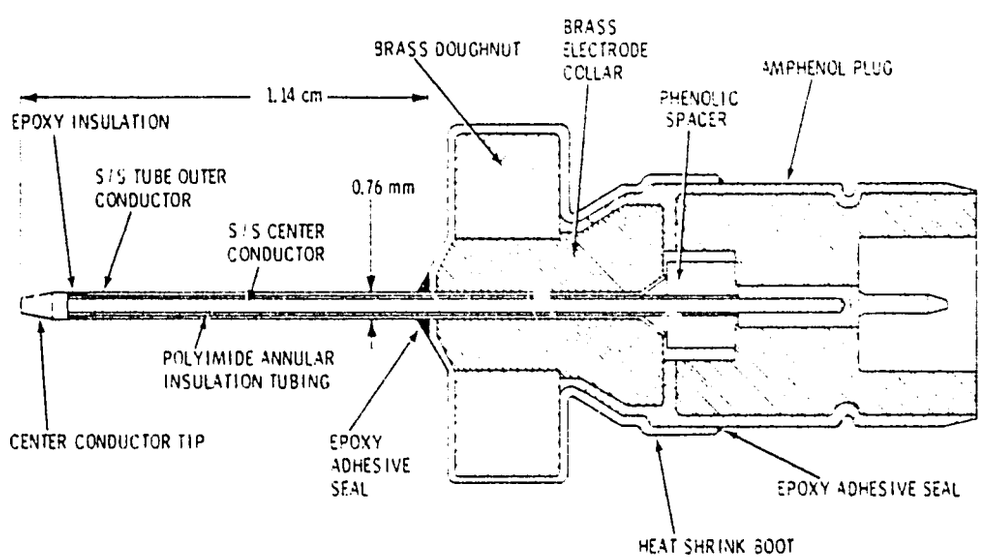

FIG. 2. Cross-section of bipolar electrode showing needle and connector assembly.



[illegible] Photomicrograph of an unused bipolar electrode [illegible]

[illegible] consent form. A personal interview was then held with each man and wife. Any uncertain patient was dissuaded from having the operation. When the wife was pregnant, it was suggested that the operation be delayed until after delivery, [illegible] the vas not dissected open. No requirements were [illegible] other than that the decision [illegible] and informed. In the very young couple, a waiting period was occasionally set, to confirm that the decision was correct. Single men and childless couples were accepted when their motivation was judged to be sincere and mature.

Technique. All operations were performed under local anesthesia in the office. The vas was exposed high in the scrotum and divided. Its sheath was held to prevent it from falling back into the scrotum. Its cut ends were then held with smooth forceps, exposing its lumina. The bipolar needle was inserted to a depth of 2 mm on the urethral side. The current was turned on and the needle was slowly withdrawn (1 to 2 seconds). After adequate electrocoagulation was shown by the development of bubbles around the needle (often accompanied by a wisp of steam), the needle was inserted to a depth of 4 to 5 mm on the testicular side and this side was similarly electrocoagulated [illegible] seconds. A buzzer in the [illegible] indicated that power was being delivered

but did not ensure proper needle function, which was demonstrated only by the bubbling. Since a greater degree of anesthesia is required against electrical stimuli than against cutting, additional anesthetic was always injected into the sheath of the vas, around the cut ends, before electrocoagulation. After electrocoagulation, the sheath of the vas was closed over the urethral end and the skin was then closed.

Patient Analysis. Members of our group of patients are considered fairly typical of American men who request a vasectomy. Their ages range from 20 to 68 years (85.2% were between the ages of 20 and 40 years and 14.8% were 40 years or older). The number of living children whom these men had fathered before their vasectomies ranged from 0 to 9 (11.2% had one child, 53.2% had two children, 17.4% had three children, and 9.4% had four or more); 8.2% of the men in this group had never fathered a child and, of this 8.2%, 3.1% were single and 5.1% were married.

The age of the youngest child ranged from 1 week to 30 years. In this series of 100 patients, 14.3% had a youngest child above 10 years of age and 1.9% had a youngest child older than 20 years.

Patients receiving Medicaid (6.8%) were accepted on an equal basis with others. At least 11.8% of all of our patients were educators, physicians, attorneys, and men in other professions.

RESULTS

Several previous series of vasectomy cases, also performed by the senior author, have been analysed and are compared with the present group. Series I comprises 288 cases wherein the vas was divided, a 1-cm segment was excised, and the vas ends were doubly ligated. No failure occurred for 138 of these cases in which fascia was interposed. Series II comprises 1600 patients in which the vas was divided, the vas ends were electrocoagulated with a monopolar electrode and fascia was interposed between the vas ends. Series III, the present one, comprises 1000 patients in whom the same technique was employed but in whom the bipolar needle was used to seal the ends of the vas (Table 1).

[illegible]

[illegible]

TABLE 1. *Comparison of Results*

	Series I (ligation) (288 patients)	Series II (monopolar) (1600 patients)	Series III (bipolar) (1000 patients)
Vasectomy failure (spontaneous anastomosis)	3.3%[a]	0.0%	0.0%
Spermatic granulomas of vas	4.2%[b]	0.4%	0.4%
Wound infection requiring antibiotics	4.2%	1.3%	1.3%
Hematomas (none required drainage)	1.4%	0.4%	0.2%
Suture extrusion	3.1%	0.3%	0.0%
Congestive epididymitis (reported to physician)	5.6%	2.8%	3.8%
Patients having undergone later vasovasostomy	No data	0.4%	0.2%

[a] Of the 150 cases in this series without fascial interposition.
[b] Additional cases were diagnosed but not operated upon.

author's hands. The figures cited for wound infection, hematomas, and congestive epididymitis are so similar that they bear out the fact that the only difference between series II (1600 patients) and series III (1000 patients) is in the type of cautery used.

The incidence of spermatic granuloma of the vas is the most significant means of determining whether the vas has been sealed properly. Series I, wherein the vas was ligated, contains a high incidence of such granulomas, some of which progressed to spontaneous vas anastomosis. The operative failure itself was prevented by interposition of fascia between the cut ends, but this interposition did not affect the occurrence of granulomas. Experience in vasovasostomy, usually following vas ligation, has shown such granulomas to be present in 15% to 40% of patients. Many are silent, while others are symptomatic [illegible]

[illegible]

the muscle between lumen and cut may be destroyed, leaving an area proximal to the cut end which is susceptible to blowout and leakage. Such an area, when recognized, should be excised, and electrocoagulation performed on the intact portion of the vas.

The low incidence of granulomas indicated that the bipolar needle is an effective instrument for sealing the cut vas without ligatures, clips, or other devices. A trial is planned to test a modified needle, with a sharpened tip, for sealing the undivided vas. Should this trial prove successful, we shall then have both the technique and the equipment for percutaneous vasectomy.

REFERENCES

1. Davis JE: Statement made at PARFR Workshop on Sterilization Reversal, San Francisco, December 4, 1977.
2. Schmidt SS, Morris RK: Spermatic granuloma and complications of vasectomy. Fertil Steril 24:941, 1973.
3. Alexander NJ: The biology of the ductus deferens. Paper read at PARFR Workshop on Sterilization Reversal, San Francisco, December 4, 1977.
4. Johnson DS: Reversible male sterilization: current status and future directions. Contraception 5:327, 1972.
5. Decker J, Carmichael R: An electro-cautery instrument for the fulguration of the vas deferens during vasectomy for sterilization. In Proceedings of the 10th Annual Rocky Mountain Bioengineering Symposium, 1973, p 5.
6. Schmidt SS, Carmichael R, Decker J, Free MJ: Vas cautery: battery-powered instrument for vasectomy. Urology 3:604, 1974.
7. Schmidt SS: Surgery and male infertility. In Male Infertility, Edited by ATK Cockett, RL Urry. New York, Grune and Stratton, 1977, p 45.
8. Schmidt SS: Technics and complications of elective vasectomy. The role of spermatic granuloma in spontaneous recanalization. Fertil Steril 17:467, 1966.
9. Schmidt SS: Prevention of failure in vasectomy. J Urol 109:296, 1973.
10. Schmidt SS: Complications of vas surgery. In Control of Male Fertility, Edited by JJ Sciarra, C Marshland, EJ Spendel. Hagerstown, Md: Harper and Row, 1975, p 29.
11. Silber SJ: Microscopic vasectomy reversal. Fertil Steril 28:1191, 1977.

The Vas Deferens Electrocoagulator System



Operation
and
Maintenance

Power Unit



The Vas Deferens Electrocoagulator System

The vas deferens electrocoagulator is a reliable, effective, durable, yet simple and inexpensive instrument for vasectomy. It provides bipolar electrocoagulation of the vas deferens lumen to achieve closed healing of the vas with minimal trauma, scar tissue or sperm antibody formation. It provides maximal effective male sterilization while maintaining the best possible conditions for surgical reversal. This manual provides instructions for operation, cleaning and maintenance of the unit; surgical protocol; and a review of relevant scientific literature.

Operating Instructions

The power unit should be positioned close enough to the operating table so that the hand control cable will allow the hand control and electrode to be manipulated within the surgical field. The power unit may be placed on a table, chair, shelf, etc. Since controls on the power unit are not used during the procedure, it may even be positioned beneath the table, out of sight.

For details regarding the surgical aspects of the procedure, please see the section titled "Surgical Protocol."

During the procedure, prior to actually electrocoagulating the lumen of the vas, it is suggested that the surgeon, while holding the hand control and electrode so that the patient may see it, press the button so that the patient may hear the buzzing noise accompanying electrocoagulation, simultaneously explaining to the patient that this is what he will hear.

Electrocoagulation takes place when the bipolar electrode is inserted within the lumen of the vas and activated. The tip of the bipolar electrode should be inserted approximately 6 mm into the lower (testicular) end of the cut vas. The surgeon should then press the button on the hand control with his thumb or forefinger for 4 to 5 seconds while slowly withdrawing the electrode. **Some blanching of the tissues will be evident upon close inspection.** In addition, **some bubbling, foaming and steaming of the vas contents can often be seen at the cut end.** This blanching of the tissue is visual evidence that electrocoagulation has taken place. Note that if coagulation is continued beyond the point of blanching, the coagulating current will continue to heat and char the tissue so that it turns brown. Coagulation to this extent is undesirable and unnecessary. Also note that **if no blanching is observed, coagulation may not have taken place.** In this event, the battery should immediately be tested for adequate power and the electrode inspected and changed if necessary.

The upper (ampullary) end of the cut vas is electrocoagulated in a similar fashion, with the needle electrode inserted into the lumen of the vas to a depth of approximately 2 mm before starting the coagulation and withdrawal sequence.

Checking the Electrocoagulator

To insure best results, the electrocoagulator, hand control and electrode should be routinely checked before each use. (Damage can occur when the unit is dropped; the hand control, electrode and battery can be expected to gradually degrade with use.)

Visual Examination

The bipolar electrode should be visually examined with a magnifier of at least 2 power. (A microscope eyepiece, inverted, is ideal to examine the electrode.) The connector on the end should appear to be in good working order, be of round geometry and the pin contained therein should be straight. The tip of the electrode should be in line with the shaft and the filler insulation should be present between tip and shaft, filling the gap. This insulation should contain no significant chips, voids or cracks. Should the electrode exhibit obvious wear or damage as noted above, it should be replaced. Discoloration of the electrode tip and shaft portions results from repeated use without proper cleaning (see section on Cleaning and Sterilization).

If each of the three parts of the system (power unit, hand control and electrode) appears to be in good working order, they should be assembled and tested.

Electrical Test

After assembling, the three units, proceed as follows:

1. Simultaneously press battery test button and hand control button and verify that red light comes on. If it does not, check to see that batteries correctly connected, polarities are correct and replace battery.

2. Press buttons on hand control [illegible] test will be heard. The [illegible] properly. If buzzer [illegible] instrument, replace battery.

Note:

Buzzer may be relied on to show when power unit is on. However, buzzer will operate at low battery voltages, when coagulation current is also low. Battery test light should be relied on as the only index of battery adequacy. Even when battery test light indicates adequate power, battery should be changed after every 200 procedures, or if buzzer sound changes during use of electrode.

3. Test for coagulating current at tip of bipolar electrode by laying tip of bipolar electrode on dry fingertip. Pressing hand control button should cause a slight tingling sensation to be felt in fingertip. This indicates that electrical energy is at tip of bipolar electrode when button is pressed. Since this electrical energy is quite mild, it may be present without producing tingling sensation. If tingling is not felt with dry fingertip, moisten fingertip with saline, tap water, or saliva to increase sensitivity.

An alternative method of testing for electrical energy at tip of bipolar electrode is to dip the tip into saline solution or salt water. When hand control button is pressed, film of small bubbles will immediately form on the electrode surfaces, indicating the presence of electrical energy.

4. If these checks indicate that the unit is working properly, it may be used with confidence in the vasectomy procedure. However, testing should always be examined for branching, bubbling and cleaning during actual use.

If these checks indicate that the system is not in good working order, the electrode and or hand control should be replaced (as appropriate) and or the power unit should be returned for repair or replacement.

Surgical Protocol

The following is the surgical protocol employed by Stanwood S. Schmidt, M.D.; other methods are discussed in the Review of the Literature.

Instruments

- Sterile gloves
- 20-cc Luer-Lok syringe with 25-ga, 5/8" needle
- Bard-Parker handle with #15 blade
- 2 curved mosquito clamps with sharp tips
- 2 straight Kelly or mosquito clamps
- 2 Allis clamps
- Electrocoagulator, hand control and needle electrode
- Needle holder and suture with needle (curved cutting edge, plain gut, cotton, silk, etc.)
- Mayo clamp
- Towel clip
- Gauze sponges
- Scissors

If available, magnifier of at least 2 power (Model [illegible] Optivisor, Donegan Optical Co., Inc. [illegible] Kansas [illegible]) is recommended. [illegible] power binocular magnifier with an [illegible] focal length.

Preparation

1. Patient lies supine on table, with fingers laced over chest.

2. Patient is cautioned to keep hands away from surgical field and instruments.

3. Genitalia are shaved.

4. Skin is washed with **warm** antiseptic soap and water solution, followed by an aqueous Zephiran-type antiseptic (**not** mercurials).

5. Scrotum is draped with an eyesheet, 24" x 30" or larger.

Procedure

1. Upper scrotum is palpated to locate vas, and to detect possible congenital absence or reduplication of vas.

2. Surgeon grasps vas in upper scrotum between thumb and index finger. The overlying skin is infiltrated for about 2 cm with 2% Lidocaine without epinephrine. Perivasal tissues are then infiltrated with the same solution.

3. Skin is incised, and curved mosquito clamp is used to spread the skin. Bleeders are clamped or fulgurated. If necessary, one or more layers of subcutaneous fascia are incised and spread open.

4. Vas is grasped—**cautiously**—with Allis clamp. If any pain occurs, additional anesthetic is injected into sheath of vas before locking clamp. If no pain occurs, additional anesthetic is injected into sheath after clamp is locked.

5. Sheath is incised longitudinally until vas muscle is exposed free of fascia. Care must be taken not to incise the vas. If this occurs, that segment is later discarded.

6. Curved mosquito clamp—or one point of a towel clip—is passed beneath vas to separate it from its sheath. Clamp is spread, and vas is grasped with smooth forceps. Allis clamp is removed and sheath is clamped with mosquito clamp to guard against it slipping away.

7. Vas is divided.

8. Holding vas with smooth forceps, electrocoagulator needle is inserted about 6 mm into the lumen of testicular side of vas and lumen is coagulated. Needle is then inserted 2 mm into lumen of upper end of vas and that lumen is also coagulated. If electrocoagulation is adequate, bubbles may appear around needle at cut end of vas, or center of vas will become opaque. **Note:** Care should be taken against excessive electrocoagulation, which may cause the entire vas to turn opaque, to "pop," or to turn black; the muscle must be left alive.

9. With the electrocoagulator, power is applied for approximately 4-5 seconds in the testicular end of the vas and for 2-4 seconds in the upper end.

10. Sheath is sutured over upper end of vas, using a single or figure-of-eight suture.

11. If bleeding occurs, especially from the vas or its sheath, it is controlled.

12. Vas is then released and skin is closed with one or more sutures.

13. Procedure is repeated on the other side.

14. Wound is bandaged, and a suspensory or similar support is applied.

15. Patient is discharged and advised to lie down for 2 hours.

16. Activity may then be resumed, as comfort permits. Bandages are removed after 2 days, when bathing and sex may be resumed. **Patient caution** - Contraceptives are necessary until testing shows the semen to be sperm free.

Semen Testing Procedure

1. Start testing after 10-15 ejaculations.

2. Inspect 10 or more high-power microscopic fields.

3. If no sperm are seen (including nonmotile), retest in 1 month.

4. If sperm are still absent, contraceptives may be discontinued.

Cleaning and Sterilization

The power unit itself requires only occasional cleaning with a mild detergent and damp cloth.

The electrode should be cleaned with household scouring powder: wet thumb and index finger, cover wetted area with scouring powder, place tip of electrode between thumb and index finger and, grasping the connector end of the needle in the other hand, move electrode back and forth. Rinse periodically and repeat as required until discoloration has been removed. Do not use stiff brush, abrasives (sandpaper) or steel wool to clean electrode since these methods can damage delicate electrode tip assembly.

Both hand control and electrode may be cold sterilized by gas or liquid sterilization (ethylene oxide). Do not use heat to sterilize the electrode.

Electrode and hand control may be sterilized separately (disconnected) or together (connected) by the most appropriate cold sterilization method. Care should be exercised in handling the electrode to avoid damage to the small tip.

When the electrocoagulator is used at frequent intervals, having two hand controls and two electrodes (with one cautery unit) will allow one set to be sterilized while the other is in use.

Battery Care

Testing the Battery

Pressing the battery test button should cause the red light above it to light. Simultaneously pressing hand control button and battery test button tests battery under load. This should indicate that sufficient battery voltage is present for vasectomy procedures. However, if the buzzer sound changes when the battery is under load (i.e. during use of the electrode), the battery should be replaced.

If the indicator does not light, the battery should be replaced at once.

Replacing the Battery

1. Remove the power unit cover by removing the four (4) screws on the sides of the unit.

2. Unscrew battery post caps and remove black (-) and red (+) wires from battery posts.

3. Remove old battery by slipping it out of case.

4. Insert new battery into case.

5. Connect black (-) and red (+) terminals to battery posts, making sure black (-) terminal is attached to - post and red (+) terminal to + post.

6. Press battery test button and confirm that indicator lights. (If battery is connected with polarity reversed, indicator will not light.)

7. Replace cover, making sure that sponge rubber liner is properly positioned over battery.

Replacement Batteries

The power unit is designed to accept inexpensive, commercially available batteries, generally available through radio repair shops and electronics parts dealers.

Acceptable batteries are:

Eveready #763 — 22 1/2-volt radio battery

Burgess #4156 — 22 1/2-volt radio battery

NEDA #710 — 22 1/2-volt radio battery

Battery Life

The battery can be expected to last for approximately two hundred (200) vasectomy procedures. It can be checked from time to time by pressing the battery test button and observing the red light that indicates a satisfactory battery condition. Since testing the battery in this fashion uses some of the battery energy, excessive testing of the battery will soon cause it to be depleted.

Battery Storage

Spare batteries can be stored with no difficulty for up to 1 year at room temperature (22°C). At elevated temperatures, expected shelf life (four months at 32°C) is reduced. It is therefore recommended that batteries be stored in a cool place, if possible. Batteries stored in a refrigerator will last almost indefinitely. If batteries are refrigerated, ample time (approximately

1 hour) should be allowed for them to reach room temperature (and full power) before using.

NOTE: Do not store the power unit with the battery in it for prolonged periods.

VII. Review of the Literature

The electrocoagulator is finding increased acceptance as a tool for improving simple vasectomy. In 1972, Schmidt[1] reported a series of 1,000 vasectomies in which no segment of the vas was removed and no ligatures were tied on the vas (Figure 1). Rather, the lumen of the proximal end was electrocoagulated for 4 mm in such a way that the lesion was confined to the epithelium, lamina propria and part of the muscle wall. The distal end was electrocoagulated on the cut surface only and the sheath of the vas was closed over it with a single ligature. This series now stands at over 2,000 with no failures and less than 1% of palpable sperm granuloma. This compares with approximately 0.5-3% failures and up to 10% of complications following vasectomy by ligation. An additional advantage is that reanastomosis following vasectomy is technically easier after this procedure since no segment of vas is removed and less than 1 cm of vas is affected by the coagulating current.

A number of other clinical investigators have also reported on the method. Peel and Potts[2] described the procedure briefly in their "Textbook of Contraceptive Practice", and the merits of electrocoagulation compared with ligation procedures were discussed in a 1971 workshop on male sterilization.[3] In a summary of the workshop,[4] Dr. William McRoberts is reported to have found electrocoagulation preferable to ligation and to have observed virtually no granuloma complications following electrocoagulation, versus 10% following ligation.

FAILURES			FAILURES AND SPERMATIC GRANULOMA
3%	A	*1-cm Segment Excised*	7.3%
0%	B	*Fascial Sheath Sutured*	9.7%
0%	C	*Fulguration*	1.0%

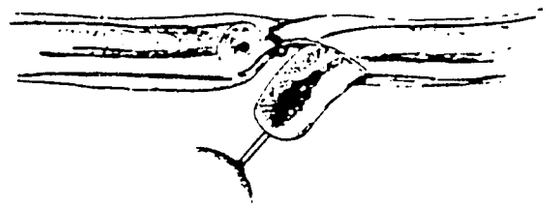

Figure 1. Results of different methods of vasectomy

A. Vas cut, doubly ligated and 1 cm segment excised
B. Vas cut, doubly ligated, 1 cm segment excised and distal end covered with fascial sheath
C. Vas cut, lumen electrocoagulated and distal end covered with fascial sheath

In a review of follow up after vasectomy, Edward's[5] commented that he had changed from the traditional procedure of excising 4 cm of vas and ligating, to electrocoagulation without resection in order to lessen the trauma of the operation, preserve more of the vas, and lessen postoperative disability. In an addendum to his review this clinical investigator reported on 200 sterilization procedures by electrocoagulation with no failures.

Klapproth and Young[6] reported on experience with four different vasectomy procedures, including excision of 1.5 cm of vas with ligation of the ends, side-by-side ligation, or double-back ligation. Compared with these techniques the electrocoagulation procedure was the preferred method and was said to be "closest to perfection" with respect to recanalization. A total of 8 recanalizations out of 800 vasoligations were reported by these clinical investigators as compared with no recanalizations out of 200 electrocoagulations.[6] A similar result was obtained by Esho, Ireland and Cass.[7,8] Six failures occurred in 487 vasoligation patients compared with no failures in 283 electrocoagulations. The incidence of "possible sperm granuloma" was also lower following electrocoagulation (0.7%) compared with vasoligation (2.2%), although in this series there were more wound infections (7.4% vs 4.9%) and greater discomfort with electrocoagulation.

In some of these series, electrocoagulation has been combined with removal of a small segment of vas for histological examination, although vasoligation was avoided and fascial separation of the cut ends was performed in all cases. In one additional series,[9] electrocoagulation was used in conjunction with tantalum clips.

Although sperm granuloma is often difficult to detect without histologic examination,[10] the incidence of verified sperm granuloma in monkeys has been correlated with sperm-immobilizing antibody titers.[11] In view of the lower incidence of sperm granulomas

following electrocoagulation compared with vasoligation, reported by Schmidt,[1] McRoberts,[4] and Esho, et al.,[7] it is pertinent to note that the incidence of sperm-immobilizing antibody activity tended to be lower following electrocoagulation compared with vasoligation, even though sperm-agglutinating antibodies were similar with each procedure.[12]

Traditionally, the monopolar surgical electrocautery with a diffuse ground plate has been used to perform these operations. These instruments are designed for powerful electrocoagulation or cutting procedures and are not ideal for electrocoagulation of the vasal mucosa. In vasectomy it is necessary to destroy the epithelium and lamina propria while preserving most of the muscle of the vas wall. It is believed that the immediate reaction is edema, and that later the muscle becomes the source of a fibrous tissue plug that forms at the cut end of the vas (Figure 2). The site of tissue destruction is cone-shaped, with the lesion becoming shallower further away from the cut end. This ensures against bursting of a weakened vas wall under the pressure of dammed-up sperm. In order to facilitate these objectives, eliminate the danger of stray current damage to surrounding tissues, minimize the possibility of user error, make the procedure independent of electricity supply, and eliminate the need for expensive equipment, a miniature, battery-driven bipolar electrocoagulator was designed specifically for electrocoagulation of the human vas deferens.[13,14] Numerous refinements and tests of these prototypes have culminated in the present vas deferens electrocoagulator. A follow-up survey of 1,000 cases performed with the bipolar electrocoagulator[15] is summarized in Table 1, comparing results with those from use of the monopolar cautery and standard resection and vasoligation techniques. These data indicate that the bipolar electrocoagulator can be effectively used in the Schmidt vasectomy procedure while retaining all of the safety, flexibility and utility of the bipolar system not found in monopolar electrocautery use.

A



Figure 2. Histology of the human vas deferens four years after transection and electrocoagulation

A. Transverse section through extreme tip of proximal end. Histopathology: Three layers of musculature visible. There is no lumen in the center of the vas, but the central area contains much fibrous connective tissue, indicative of a scar. There are no remnants of epithelium present.

B. Transverse section 1-2 mm from tip of proximal end. Histopathology: Three distinct layers of musculature, with the scar in the center. There appears to be a group of epithelial cell nuclei showing through at the center of the scar.

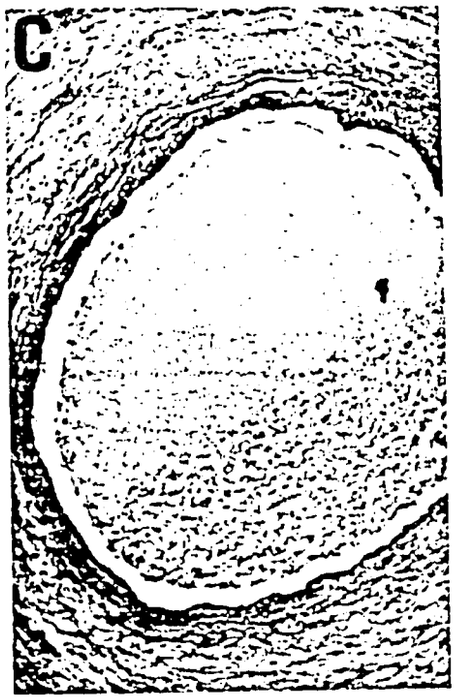

C. Transverse section 2-3 mm from tip of proximal end. Histopathology: An apparently normal epithelium is present in the central portion. Some subepithelial scar tissue is present, as well as some epithelial infiltration of eosinophils. The lumen is distended.

Table 1. Comparison of Results of Various Vasectomy Techniques[a]

	Ligation	Monopolar	Bipolar
No. of Patients	288	1600	1000
Vasectomy failure (spontaneous anastomosis)	3.3%[b]	0.0%	0.0%
Spermatic granulomas of vas	4.2%[c]	0.4%	0.4%
Wound infection requiring antibiotics	4.2%	1.3%	1.3%
Hematomas (none required drainage)	1.4%	0.4%	0.2%
Suture extrusion	3.1%	0.3%	0.0%
Congestive epididymitis (reported to physician)	5.6%	2.8%	3.8%
Patients having undergone later vasovasostomy	No data	0.4%	0.2%

(a) From Schmidt, S.S. and Free, M.J., Urology (in press), 1978
(b) Of the 150 cases in this series without fascial interposition
(c) Additional cases were diagnosed but not operated upon

References

1. **Schmidt, S. S.** Prevention of failure in vasectomy. *J. Urol. 109:*296, 1973.

2. **Peel, J and Potts, M.** *Textbook of Contraceptive Practice.* Cambridge, University Press, 1969.

3. Workshop on Reversible Male Sterilization. Sponsored by **The Agency for International Development.** Battelle Seattle Research Center, 1971.

4. **Johnson, D. S.** Reversible male sterilization: Current status and future directions. *Contraception 5:* 327, 1972.

5. **Edwards, I. S.** Follow-up after vasectomy. *Med. J. Aust. 2:* 132-135, 1973.

6. **Klapproth, H. J. and Young, I. S.** Vasectomy, vas ligation and vas occlusion. *Urology 1:* 292-300, 1973.

7. **Esho, J. O., Ireland, G. W. and Cass, A. S.** Vasectomy: Comparison of ligation and fulguration methods. *Urology 3:* 337-338, 1974.

8. **Esho, J. O., Ireland, G. W. and Cass, A. S.** Recanalization following vasectomy. *Urology 3:* 211-214, 1974.

9. **Tauber, A. S.** A long-term experience with vasectomy. *J. Reprod. Med. 10:* 147-149, 1973.

10. **Leader, A. J., Axelrad, S. D., Frankowski, R. and Mumford, S. D.** Complications of 2,711 vasectomies. *J. Urol. 111:* 365-369, 1974.

11. **Alexander, N. J.** Immunologic and morphologic effects of vasectomy in the rhesus monkey. *Fed. Proc., Fed. Am. Soc. Exp. Biol. 34:* 1692-1697, 1975.

12. **Alexander, N. J., Schmidt, S. S., Free, M. J., Danilchik, M. V. and Hill, W. T.** Sperm Antibodies after vasectomy with fulguration, *J. Urol. 115:* 77-78, 1976.

13. **Decker, J. and Carmichael, R.** An electrocautery instrument for the fulguration of the vas deferens during vasectomy for sterilization, pp. 5-10. *In: Proc. 10th Annual Rocky Mountain Bioengineering Symposium,* D. Dick (ed.), Instrument Society of America, Pittsburgh, PA.

14. **Schmidt, S. S., Carmichael, R., Decker, J. and Free, M. J.** Vas cautery: battery-powered instrument for vasectomy. *Urology 3:* 604-605, 1974.

15. **Schmidt, S. S. and Free, M. J.** The bipolar needle for vasectomy. I. Experience with the first 1,000 cases. *Urology* (in press), 1978.

VASECTOMY: EFFICACY OF PLACING THE TWO CUT ENDS OF THE VAS DEFERENS IN DIFFERENT FASCIAL PLANES

January 1979

This Study was performed in part under contract AID/csd-3152 from the Office of Population, U.S. Agency for International Development.

3-52

Vasectomy: Efficacy of Placing the Two Cut Ends of the Vas Deferens in Different Fascial Planes

ABSTRACT

A unique opportunity to study the efficacy of placing the two cut ends of the vas in different fascial planes as an integral part of the vasectomy procedure presented itself when surgical occlusion of the vasa was inadvertently not performed during vasectomy in a series of 40 men. Interposition of the fascia was performed in 12 cases and was not performed in 28 cases. Application of the Fisher's Exact Test showed that there was no significant difference in the failure rates of the two procedures. Histological examination revealed that sperm graulomata has the capability of eroding fascia and the wall of the vas.

Vasectomy: Efficacy of Placing the Two Cut Ends of the Vas Deferens in Different Fascial Planes

INTRODUCTION

Placing the two cut ends of the vas deferens in different fascial planes as an adjunct to the vasectomy procedure has been widely advocated for many years. This adjunct can be used with any method of vas occlusion that includes transection of the vas deferens. An opportunity to study the effectiveness of this adjunct procedure inadvertently presented itself and the results of this study are herein reported.

History

In 1923 Rolnick[1] reported on a study of 30 dogs. He concluded that recanalization is aided materially by the sheath of the vas deferens, the former acting as a splint promoting and directing the path for epithelization. It is most reasonable to assume that if the sheath of the vas were sealed over one end of the severed vas then recanalization could not occur. This adjunct procedure became widely adopted.[2-11]

The Procedure

After the vas ends are treated (ligated, clipped, coagulated) and the treated ends withdrawn into the sheath of the vas, the sheath (the internal spermatic fascia) is sutured over the end. Most surgeons suture the fascia over the distal end and most use a single suture.

Advocates of this procedure claim that an impenetrable wall of fascia is thus created, one which will prevent spontaneous anastomosis. In other words, it is believed that with the sheath blocked, regeneration cannot occur.

Study Background

A unique opportunity to study the effectiveness of this procedure presented itself when surgical occlusion of the vasa during vasectomy was inadvertently not performed in an undeterminable number of vasa within a series of 40 men. The procedure was performed through double vertical scrotal incisions. The vasa were separated from their sheath and transected, but no segment of vas was removed. The occlusion procedures were identical in all respect, except that in an undeterminable number of cases, vasal occlusion was not achieved. Interposition of the fascia was performed in 12 cases and not performed in 28 cases. Follow-up began after 15 ejaculations.

RESULTS

The results are summarized in Table I. Among the 28 cases where fascia was not interposed between the two cut ends of the vas, there were six (21.4%) failures. Of these, four of the patients had 98 or more sperm per high power field) HPF) after 35 to 54 ejaculations and in the sixth case, the number of sperm was 55 per HPF after 33 ejaculations.

Among the 12 cases where fascia was interposed, there were two (16.7%) failures. In one case, the number of sperm per HPF was 98 or over after 38 ejaculations and in the second case, the number

of sperm was 98 or over after 50 ejaculations. Another patient in this group where fascia was interposed was lost to subsequent follow-up and is considered a potential failure because the number of sperm was 98 or over per HPF after six ejaculations.

If the assumption is made that the proportion of non-occluded vasa was similar in each group, then application of the Fisher's Exact Test[12] indicates no significant difference in the failure rates of the two procedures ($p = 0.5485$). In other words, placing the two cut ends of the vasa in different fascial planes as a integral part of the vasectomy procedure does not reduce the incidence of failure. Even without the assumption of parity between the two groups with respect to unoccluded vasa it is apparent that fascial separation is no guarantee against failure of vasectomies.

In order to ascertain the fate of the fascial barrier, vasal tissues excised at the time of repeated vasectomy in two patients were obtained and fixed for histological examination. One set of tissues was from a patient whose vasectomy included the interposition of fascia between the cut ends of the vasa while the other set of tissues were from a patient whose vasectomy did not include this adjunct.

Patient 1 had a repeat vasectomy 23 weeks after the first procedure. This patient <u>did not</u> have fascia interposed between the cut ends. The histological examination revealed that the initial vasectomy had failed on the left side only. On this side, from the epididymal towards the ampullary end, the following sequence was noted. (Approximate distance is given proximal or distal to the site of transection).

1. (Proximal 4 mm) The transition from normal to abnormal vas occurred abruptly over the space of 0.5 mm. Epithelial lining cells were absent from the original lumen and two cavities appeared in the musculature, one contiguous with the original lumen and one deep in the longitudinal muscle layer. Scarring was evident in the musculature at this level (Fig. 1).

2. The muscle layer was fragmented into separate pieces with considerable scarring evident around the site of the original lumen.

3. (Proximal 1.5 mm) Progressing further towards the site of transection the vas became relatively normal (Fig. 2). No sperm were evident in the lumen.

4. (Proximal 0.7 mm) The vas remained relatively normal but some sperm nuclei appeared in the muscle layers and whole spermatozoa and mononuclear inflammatory cells were evident in the connective tissue <u>external</u> to the muscle (Fig. 3).

5. (Proximal 0.2 mm) The lumen was intact (Fig. 4). Sperm granulomas with epithelial lined channels appeared in the connective tissue external to the muscle layers (Fig. 5). A focus of mononuclear inflammatory cells with epithelial lined channels was present in the lamina propria (Fig. 6).

6. (Distal 0.2 mm) The original lumen appeared to divide into approximately ten very small lumena, each surrounded by a single layer of atypical epithelial cells (Fig. 7). The granulomas were more extensive.

7. (Distal 1.2 mm) A normal lumen appeared again at this level while the external granuloma became more extensive (Fig. 8).

8. The external granuloma extended for 14 mm toward the ampulla while becoming progressively less severe. The vas lumen remained normal throughout.

Comment

The proximal damage was probably due to handling during excision of the tissue. Since no fascial separation was used between distal and proximal vas segments the cut ends were probably lying in apposition. New lumena had formed through the inflammed areas within the lamina propria. These were probably sufficient to connect the proximal and distal lumens of the vas although additional epithelial lined lumena were present in the granulomatous tissue outside of the muscular layer.

Patient 2 had a repeat vasectomy after the first procedure. This patient did have fascia interposed between the cut ends. The histological examination revealed that the initial vasectomy had failed on the right side only. On this side, from the epididymal towards the ampullary end, the following sequence was noted.

1. The transition from normal to abnormal vas was characterized by an appearance and increase in the number of sperm and inflammatory cells in the connective tissue exterior to the muscle layer.

2. (Proximal 5.5 mm) A second channel became evident adjacent to the lumen. The inflammatory reaction subsided in the external connective tissue (Fig. 9) and the vas became essentially normal with a few spermatozoa in the lumen.

3. (Proximal 0.8-1 mm) Inflammatory reactions reappeared in the external connective tissue, characterized initially by the presence of sperm and mononuclear inflammatory cells and eventually by macrophage and foreign body giant cells. They gradually eroded the outer longitudinal muscle (Fig. 10) and foci of granulomatous reaction appeared in the lamina propria and junction of the longitudinal and circular muscle. The epithelial lining cells became atypical and hyperplastic (Fig. 11).

4. (Proximal 0.5 mm) The lumen disminished in size. The musculature was nearly obliterated by granuloma formation and scar tissue. Some epithelial lined channels were present (Fig. 12) at first followed by a large channel which appeared to run to the end of the proximal vas.

5. The region between the cut vas ends was made up entirely of granulomatous inflammatory cells although numerous epithelial lined channels containing sperm were present (Fig. 13).

6. (Distal 2 mm) The external granuloma diminished rapidly along the distal vas although the central granuloma persisted with sperm, lymphocytes, macrophage and numerous epithelial lines channels in evidence (Fig. 14). This central reaction diminished generally over the next 2 mm progressing toward a normal vas. A lumen appeared to be present throughout the distal vas.

Comment: The interposed fascia had apparently been eroded away by the granulomatous reaction. Although the cut ends of the vas where much further apart than was the case in the absence of fascial separation, large channels were present in the interposing granuloma through which sperm were apparently able to pass.

CONCLUSION

Sperm granuloma has the capability of eroding fascia and, from the outside in, the muscle wall of the intact vas. Interposition of fascia between the cut ends of the vas as an adjunct to vasectomy does not provide a guarantee against failure of vasectomy and may not improve the chances of success of the vasectomy. Furthermore, any circumstance or technique that results in an unoccluded proximal vas (tnereby permitting extensive granuloma to form) seems likely to be subject to a higher risk of failure even in the presence of a fascial barrier or an occluded distal vas end.

Table I

Summary of the Results of 40 Vasectomy Procedures
In An Examination of the Efficacy of Placing the Two
Cut Ends of the Vas Deferens in Different Fascial Planes

	No. of Patients	No. of Failures	% Failures
With interpostion of fascia	12	2	16.7
Withour interposition of fascia	28	6	21.4
Total	40	8	---

NOTE: Application of the Fisher Exact Probability Test showed that there was no significant difference in the failure rates of the two procedures ($p = 0.5485$).

3-61

FIGURE 1. Patient #1, 23 Weeks After Unsuccessful Vasectomy. Left Side 4 mm Proximal to Transection. (65X)



FIGURE 2. Patient #1, 23 Weeks After Vasectomy. Left Side 1.8 mm Proximal to Transection. (175X)

3·62

FIGURE 3. Patient #1, 23 Weeks After Unsuccessful Vasectomy. Site of Inflammation External to the Muscularis. Left Side 0.7 mm Proximal to Transection. (350X)



FIGURE 4. Patient #1, 23 Weeks After Unsuccessful Vasectomy. Left Side 0.2 mm Proximal to Transection.
a. The Vas Lumen. (65X)



FIGURE 5. Site of Granuloma and Epithelial Lined Channels External to the Muscularis. (325X)



FIGURE 6. Site of Inflammation and Epithelial Lined Channels in the Lamina Propria. (325X).



FIGURE 7. Patient #1, 23 Weeks After Unsuccessful Vasectomy. Left Side 0.2 mm Distal to Transection. Site of Divided Lumen. (175X)

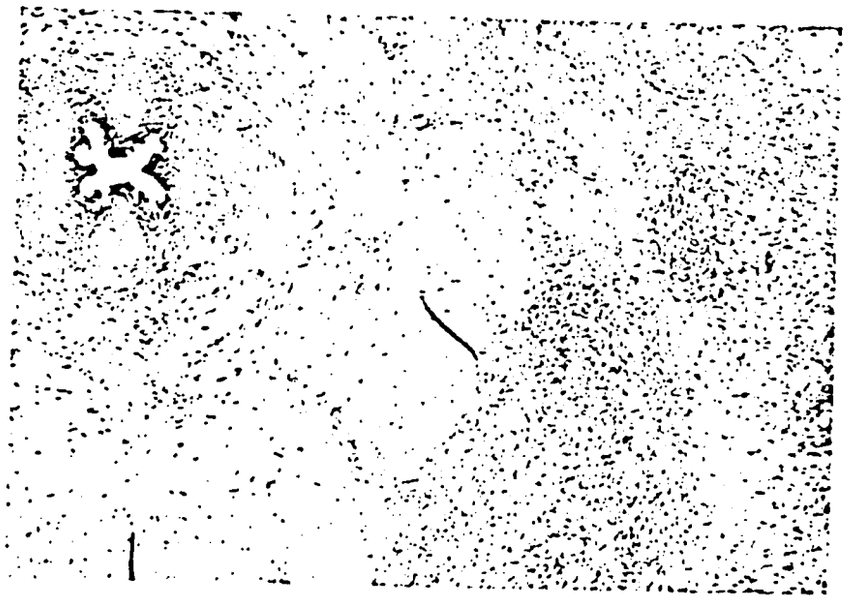

FIGURE 8. Patient #1, 23 Weeks After Unsuccessful Vasectomy. Left Side 1.2 mm Distal to Transection. (70X)

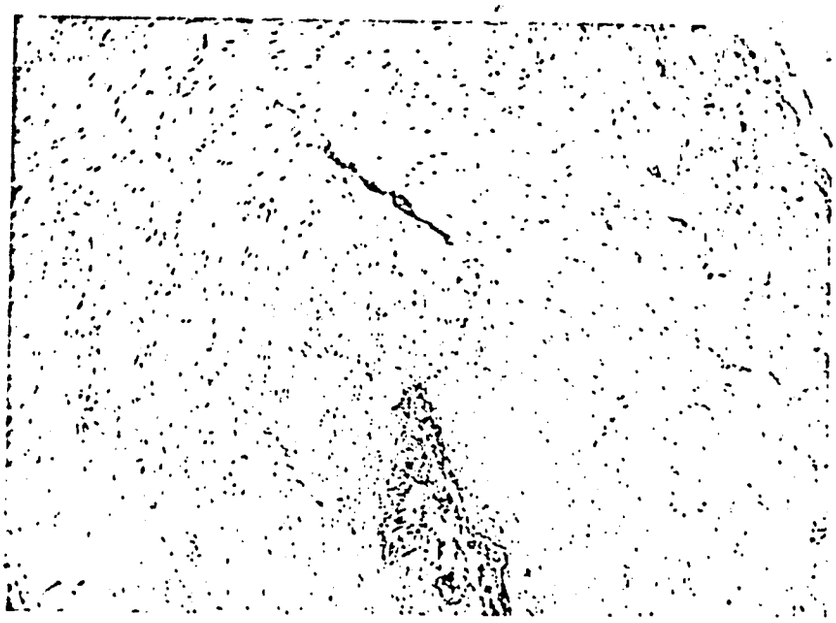

FIGURE 9. Patient #2, 16 Weeks After Unsuccessful Vasectomy. Right Side, 5.5 mm Proximal to Transection. (70X)



FIGURE 10. Patient #2, 16 Weeks After Unsuccessful Vasectomy. Right Side, 1 mm Proximal to Transection.
a. Site of Invasion of the Outer Longitudinal Muscle of the Vas by Inflammatory Cells. (175X)



FIGURE 11. Lumen with Hyperplastic Epithelium. (175X)



FIGURE 12. Patient #2, 16 Weeks After Unsuccessful Vasectomy. Right Side, 0.5 mm Proximal to Transection. (70X)

3-66



FIGURE 13. Patient #2, 16 Weeks After Unsuccessful Vasectomy. Right Side, at the Site of Transection. Epithelium-Lined Channels Through the Granuloma. (350X)



FIGURE 14. Patient #2, 16 Weeks After Unsuccessful Vasectomy. Right Side, 2 mm Distal to Transection. (170X)

REFERENCES

1. Rolnick, H. C., Regeneration of the vas deferens, Arch. Surg. 9:188, 1924.

2. Klapproth, H. J. and Young, I. S., Vasectomy, vas ligation and vas occlusion, Urology 1:292, 1973.

3. Schmidt, S. S., Prevention of failure in vasectomy, J. Urology Vol. 109, 1973, p. 296.

4. Moss, W. M., Sutureless vasectomy, an improved technique: 1300 cases performed without failure, Fertility and Sterility, Vol. 27, No. 9 September 1976. p. 1040.

5. Linnet, Lar, Control after vasectomy, Uzeski, Loef. 1977, 139, 1708

6. Esko, J. O., Ireland, G. W. and Cass, A. S., Vasectomy, Urology, Vol. 3, No. 3, March 1974.

7. Lehtonen, Timo, Vasectomy for voluntary male sterilization, Scand. J. Urol Nephrol 9:174, 1975.

8. Edwards, I. S., Vasectomy: A Single postoperative regimen, Med. J. Aust., 1977. 1:814.

9. Edwards, I. S., Vasectomy: Irrigation with euflavine, Med. J. Aust, 1977, 1:847.

10. Hanley, Howard, G., Vasectomy for voluntary male sterilazation, The Lancet, July 27, 1968. p. 207.

11. Mumford, Stephen, D., Vasectomy Counseling, San Francisco: San Francisco Press, 1977. p. 54.

12. Siegel, Sidney, Nonparametric Statistics, New York, McGraw-Hill, 1956. p. 96.

References, Appendix 4

1. Jennings, P. B., M. K. McCarthy, S. R. Plymate, and J. N. Wettlaufer. 1975. Fertil. Steril. 26:53-56.

2. Jennings, P. B., J. N. Wettlaufer, C. A. Paulsen. 1977. Fertil. Steril. 28:446-447.

3. Alexander, N. J., S. S. Schmidt, M. J. Free, M. V. Danilchik and W. T. Hill. 1975. Sperm Antibodies after vasectomy with fulguration. J. Urol. 115:77-78.

4. Alexander, N. A., M. J. Free, D. A. Paulson, R. Buschbom and D. Fulgham. 1979. Follow-up of blood chemistry, reproductive hormones and antisperm antibodies after vasectomy in 122 men. (in preparation)

FERTILITY AND STERILITY
Vol. 26, No. 1, January 1975
Printed in U.S.A.
Copyright © 1975 The American Fertility Society

PREVALENCE OF CIRCULATING HL-A LYMPHOCYTOTOXIC ANTIBODIES IN MEN AFTER VASECTOMY*

PAUL B. JENNINGS, V.M.D., M.Sc.,† MARY K. McCARTHY, M.Sc., STEPHEN R. PLYMATE, M.D.,‡ AND JOHN N. WETTLAUFER, M.D.

Clinical Research Service, Madigan Army Medical Center, Tacoma, Washington 98431

An increasing number of vasectomies are being performed in the United States for the purpose of birth control. It has been suggested that immunologic events occur following vasectomy; these may lead to systemic disease later in life, or may induce failure of a future reconstructive vasovasostomy.

Vasectomy has been reported to lead to the production of antibodies with HL-A specificity, or at least antibodies which cross-react with antigens of the HL-A system.[1] The HL-A site is the major histocompatibility locus in humans and affects the response to organ and tissue grafts.[2] It has also been suggested that it plays a role in the susceptibility of certain individuals to immunologic (autoimmune) disease.[3,4] A surgical procedure which might presensitize a patient to histocompatibility antigens could jeopardize future treatment of immunologically related conditions.

Men undergoing vasectomy at Madigan Army Medical Center (MAMC) were screened for circulating HL-A lymphocytotoxic antibodies before and at three-month intervals after surgery.

Received April 26, 1974.

*Presented at the Annual Meeting of the Pacific Coast Fertility Society, Scottsdale, Arizona, October, 1974.

Supported by Clinical Research Service, Madigan Army Medical Center

†Reprint requests: Dr. Paul B. Jennings, Box 99, Madigan Army Medical Center, Tacoma, Wash 98431

‡Present address: Endocrine Service, William Beaumont Army Medical Center, El Paso, Tex 79920

MATERIALS AND METHODS

Surgery was performed on 37 men by the Urology Service at this institution. Blood samples were taken before and 3, 6, 9, and 12 months after vasectomy.

Control and postvasectomy patient sera were screened for presence of HL-A reacting antibodies against the patient's own cells and against a random typed panel of 25 lymphocyte donors.

Heparinized blood samples (5 cc) and clotted blood for serum were collected from each patient, and pure suspensions of lymphocytes were prepared, using the ficoll-hypaque separation technique.[5] Each patient's lymphocytes were typed against a panel of human lymphocyte antisera, using the microdroplet lymphocyte cytotoxicity test.[6] A total of 115 human sera were utilized to identify 23 HL-A antigens: first sublocus: HL-A, 1, 2, 3, 9, 10, 11, W-19, W-28; and second sublocus: HL-A 5, 7, 8, 12, 13, W-5, W-10, W-14, W-15, W-17, W-18, W-22, W-27; 4a, 4b.

RESULTS

Thirty-seven men returned after vasectomy for at least two blood samples. Of these, 32 men remained in the study for a year (they missed only one or two blood samples). Eighteen of the 37 men

4-2

had preoperative and four postoperative blood samples drawn.

The results of testing the preoperative and postoperative sera from the 32 vasectomized men who remained in the study for one year against a panel of 25 typed lymphocyte donors are summarized in Table 1. The sera of two patients (10 and 14) showed a definite increase in positive reactions between six and 12 months after surgery. In patients 18 and 21, a slight increase in serum reactivity was noted at the 12-month sample; in patients 31 and 32 a slight increase was noted at three, six, and 12 months. The sera of two patients (17 and 30) showed a decrease in positive reactions postoperatively. Serum of only one of the 32 vasectomized patients (25) showed a weak positive reaction with the patient's own lymphocytes (at the three-month postsurgery sample). However, sera from this patient showed no positive reactions at any time with the 25-member lymphocyte panel.

TABLE 1. *Prevalence of Preoperative and Postoperative Lymphocytotoxic Antibodies in Vasectomized Men*

	No. of positive reactions/total (25)*				
		Postoperative			
Patient no.	Preoperative	3 months	6 months	9 months	12 months
1	0	2	1	0	0
2	0	0	0	0	0
3	0	0	1	0	0
4	0	0	1	0	0
5	0	0	0	1	0
6	0	0	0	0	0
7	0	0	0	0	0
8	0	0	0	2	1
9	0	1	0	1	0
10	1	4	6	10	4
11	1	1	0	0	1
12	0	0	0	0	0
13	0	0	1	0	1
14	3	2	3	3	6
15	1	1	0	1	1
16	1	1	0	2	0
17	3	2	0	1	0
18	0	0	1	1	3
19	0	1	2	...	2
20	0	...	0	0	0
21	0	1	0	...	3
22	1	0	0	...	0
23	0	0	0	...	1
24	0	...	0	0	0
25	0	0	0	...	0
26	0	0	0	...	0
27	0	0	...	0	0
28	0	0	1	...	1
29	2	1	...	...	1
30	4	4	0	...	0
31	0	4	...	1	3
32	1	2	3	...	3

*25-member HL-A-typed lymphocyte donor panel.

DISCUSSION

Widespread interest was generated by a preliminary report of a 75% incidence of cytotoxic antibodies to HL-A specific antigens, or cross reactive to HL-A antigens, after vasectomy in 12 men.[7,8] It implied that autoimmune disease might result from vasectomy.[1]

The sera of two of the vasectomized men in our study showed a definite increase in positive reactions in the lymphocytotoxicity test when measured against the lymphocyte donor panel. Neither of these men had any additional surgery during the study, nor did they have prior or subsequent blood transfusions. Preliminary analysis of the sera from these two patients suggested a general nonspecific hyperreactivity to many HL-A antigens. Weak, infrequent responses to certain antigens in the early postoperative period were magnified at six, nine, and 12 months in patient 10, and at 12 months in patient 14. Only one man once showed a weakly positive reaction against his own lymphocytes.

Of the noted positive reactions in these patients, 68% were weak (50% cytotoxicity—a 4+ reaction in the Terasaki scoring method); negative results were 1+ (same viability as the negative control); or, 2+ (10% to 19% cytotoxicity).[1]

It has been suggested that extravasation of spermatozoa into the tissues as a result of urogenital inflammation, or

4-3

trauma to the vas deferens, may provoke sperm antibody formation and explain infertility in men.[9] Sperm-agglutinating and sperm-immobilizing antibodies have been detected in men following vasectomy,[10] and some researchers feel accumulation of spermatozoa or their extravasation outside the normal epididymal channel after surgery may be the antibody stimulus.[7,9] The long-term postvasectomy effect of such sperm agglutinins or immobilizing antibodies is not clear at present, although one report stated an increased incidence of unexplained systemic disorders (thrombophlebitis, arthropathy, lymphadenopathy) in six patients, one to two years following elective vasectomy.[11-13]

HL-A antigens probably have a haploid expression on human spermatozoa.[14] Possibly, if vasectomy without simultaneous vasoligation were performed, a draining sperm fistula would be produced. Antibodies to the antigenic components of sperm (capsule, tail) then might well develop.[15] However, surgery at this institution involves division and ligation of the vas.[12] The antigens of the HL-A system are present on most cells of the body, including spermatozoa. Thus, it is conceivable that the host would recognize these as "self," even though in haploid expression, and not produce specific HL-A antibodies. This does not rule out some cross reactivity between antibodies produced to sperm structural components and the HL-A system.

We cannot explain the wide discrepancy between our results and those of Henry et al.[1] The surgical technique of vasectomy and the degree of sensitivity of the test systems involved may be factors. A long-term study is needed, which traces the activity of the HL-A system for several years in a large number of vasectomized men.

SUMMARY

Thirty-two men undergoing vasectomy were studied for one year to determine presence of HL-A antibodies after surgery. Blood samples were taken prior to vasectomy and at three, six, nine, and 12 months following surgery.

Twenty-six men showed no increase in antibody activity during the study when their sera were matched against a 25-member typed lymphocyte donor panel. Sera of two men showed a definite increase in positive reactions, six to 12 months after surgery. The sera of four men showed slight increases in reactivity between three and 12 months after vasectomy. The serum of one man showed a single positive reaction against his own lymphocytes three months after surgery, but no positive reactivity against the lymphocyte donor panel.

These studies suggest that HL-A antibodies are not regularly formed as a result of standard vasectomy procedures, but that further long-term evaluation of vasectomized patients may be needed to make definite conclusions.

Acknowledgments. The authors thank Laurie A. Sebring for technical assistance and Edith M. Hoyt for editorial assistance. Dr. Donald Kayhoe, Transplantation and Immunology Branch, National Institutes of Health, and Dr. E. Donnell Thomas, University of Washington, contributed human lymphocyte typing sera.

This study represents an immunologic portion of an extensive examination into the consequences of vasectomy, conducted by Dr. C. Alvin Paulsen, Department of Endocrinology, University of Washington, Seattle, Subcontract B-470, Battelle Pacific Northwest Laboratories, Seattle.

REFERENCES

1. Henry JB, Choi YJ, Sandler M, et al: Immunological consequences of vasectomy: cytotoxic antibodies in vasectomized men. Presented at the Transfusion Congress, American Association of Blood Banks and International Society of Blood Transfusion, Washington DC, August 29, 1972. (Unpublished data)

44

2. Falk JA, Falk RE: HL-A antigens in clinical transplantation. Med Clin North Am 56: 403, 1972
3. Naito S, Namerow H, Mickey MR, et al: Multiple sclerosis: association with HL-A 3. Tissue Antigens 2:1, 1972
4. Morris PJ, Forbes JF: HL-A and Hodgkins' disease. Transplant Proc 3:1275, 1971
5. Boyum A: Separation of leukocytes from blood and bone marrow. Scad J Clin Lab Invest 21: (Suppl 97) 77, 1968
6. Terasaki PI, McClelland J, McCurdy B: Manual of Tissue Typing Techniques. National Institues of Health, Bethesda, Maryland, 1973, p 54
7. Davis JE: Consequences of vasectomy. Urology 1:82, 1973
8. Henry JB: Immunological effects of vasectomy. JAMA 225:642, 1973
9. Rumke P, Hellinga G: Autoantibodies against spermatozoa in sterile men. Am J Clin Pathol 32:357, 1959
10. Ansbacher R: Sperm-agglutinating and sperm-immobilizing antibodies in vasectomized men. Fertil Steril 22:629, 1971
11. Roberts JH: Delayed thrombophlebitis and systemic complications after vasectomy: possible role of diabetogenic hyperinsulinism. J Am Geriat Soc 16:267, 1968
12. Hackett RE, Waterhouse K: Vasectomy-reviewed. Am J Obstet Gynecol 116:438, 1973
13. Derrick FC: Immunological effects of vasectomy. JAMA 225:642, 1973
14. Fellous M, Dausset J: Probable haploid expression of HL-A antigens on human spermatozoa. Nature [Lond] 225:191, 1907
15. Alexander NJ: Vasectomy: long-term effects. Science 182:946, 1973

4-5'

FERTILITY AND STERILITY
Vol 28, No. 4, April 1977
Printed in U.S.A.
Copyright © 1977 The American Fertility Society

ABSENCE OF CIRCULATING HL-A LYMPHOCYTOTOXIC ANTIBODIES IN MEN 21 TO 44 MONTHS AFTER VASECTOMY*

PAUL B. JENNINGS, V.M.D., M.Sc.†
JOHN N. WETTLAUFER, M.D.‡
C. ALVIN PAULSEN, M.D.§

Clinical Investigation Service and Urology Service, Madigan Army Medical Center, Takoma, Washington 98431, and Division of Endocrinology, University of Washington, Seattle, Washington 98114

Nineteen vasectomized men were followed for 21 to 42 months after surgery, and their sera were tested for the presence of HL-A lymphocytotoxic antibodies. In a previous study, the sera of two of these men had shown a definite increase in serum reactivity 6 to 12 months after surgery. Only one of the nineteen tested in the study demonstrated a single, weakly positive, reaction 24 months after surgery. It was considered that the initial stimulus for lymphocytotoxic antibody production was related to surgery. There was no evidence of antibody stimulation 21 to 44 months postoperatively.

In a previous report from this facility, 32 vasectomized men were tested for the presence of circulating HL-A lymphocytotoxic antibodies, before surgery and at 3-month intervals for 1 year postoperatively.[1] Only two patients in this study showed a definite increase in positive reactions between 6 and 12 months following surgery. The other patients showed minimal or no lymphocytotoxic response over the 1-year test period.

In the present study, certain numbers of the original group of 32 vasectomized men were tested for HL-A lymphocytotoxins, 21 to 44 months following the operative procedure.

MATERIALS AND METHODS

Nineteen of the original 32 vasectomized men volunteered to continue in the study for a total of 36 months. Postoperative blood samples for serum were collected at the time intervals listed in Table 1. The sera were frozen at −80° F until all samples were collected. Some samples were not available, since not all patients reported at the required time intervals. The numbers assigned to each patient in Table 1 are in the same numerical sequence as in the previous study.[1]

A panel of 29 random donors was HL-A-typed, using the microdroplet lymphocyte cytotoxicity test.[2] The panel used in the prior study was not available at this time. Consequently, a new 29-member panel was selected which would contain as many of the total antigens of the A and B loci as possible. A battery of 112 human typing sera was used to identify the following antigens: A locus—HLA-A1, 2, 3, 9, 10, 11, 28, 29, w19, w23, w24, w26, w30, w31, w33; B locus—HLA-B5, 7, 8, 12, 13, 14, 18, 27, w15, w17, w35, w40. The typed lymphocytes of each of the 29 donors were then used to screen the sera of the 19 post-vasectomy patients for presence of lymphocytotoxins, using the same microdroplet lymphocyte cytotoxicity test. Reactions were scored on the percentage of dead lymphocytes per field, according to the method of Terasaki et al.[2] Preoperative serum samples also were available from the previous study and were utilized as controls.

Accepted November 4, 1976.
*Supported by the Clinical Investigation Service, Madigan Army Medical Center, and Battelle Special Agreement B-470, Battelle Sponsor Agreement 2311100679, with the Agency for International Development.
†Clinical Investigation Service, Madigan Army Medical Center. Reprint requests: Dr. Paul B. Jennings, Box 99, Madigan Army Medical Center, Tacoma, Wash. 98431.
‡Urology Service, Madigan Army Medical Center.
§Division of Endocrinology, University of Washington.

4-6

TABLE 1. *Number of Months after Vasectomy Where Serum Samples Were Provided*

Patient	Sample 1	Sample 2	Sample 3
		mo	
2	28	31	38
4	27	30	39
5		34	42
6		34	43
7	32	36	44
9	30	34	42
10		27	35
11	26	29	36
12	31	34	42
13	24	28	34
14	24[a]	27	
15	24	26	34
20	26	29	36
22	26	32	
23	31	38	42
26	31	34	44
28	24	27	
30	21	29	33
32			34

[a]One positive reaction noted (+4) against 29-member lymphocyte donor panel.

RESULTS

All of the lymphocyte antigens present in the vasectomy patients, with the exception of HLA-Bw17, were represented in the 29-member donor panel (Table 2). Thus, it was possible not only to determine whether any of the postvasectomy patients' sera reacted against antigens present on the patients' own cells, but also against other HL-A configurations.

Patient 14, who demonstrated several positive reactions 6 to 12 months after surgery, demonstrated weak reactivity (+4) against one panel member 24 months postoperatively. This panel member contained one A-locus antigen (HLA-A2) in common with patient 14. Patient 10, the other patient who showed increased reactivity within the 1st year after surgery, did not react with any of the panel members 27 or 35 months after surgery. Sera from all of the other patients tested was unreactive.

TABLE 2. *Number of Times HL-A Antigens Were Represented*

A locus			B locus		
Antigen	29-Member donor panel	19-Member vasectomy group	Antigen	29-Member donor panel	19-Member vasectomy group
A1	6	3	B5	6	5
A2	16	12	B7	5	7
A3	6	4	B8	6	3
A9	6	5	B12	9	4
A10	1	3	B13	1	1
A11	8	0	B14	6	9
A28	3	12	B18	3	1
A29	1	0	B27	11	1
w19	1	1	w15	3	3
w23	2	0	w17	0	2
w24	3	0	w35	1	7
w26	1	0	w40	4	2
w30	4	0			
w31	1	0			
w33	5	0			

DISCUSSION

A continued absence of lymphocytotoxic activity was seen in all patients in the 3 years following surgery. Only patient 14 reacted positively on one occasion with donor cells. This patient's control serum was reactive as in the previous study, so some immunologic stimulus other than vasectomy might explain this hyper-reactivity.[1]

Perhaps our observations might be compared with those of Ansbacher,[3] who demonstrated a peak in activity of sperm-immobilizing antibody at 12 months after surgery, and almost complete disappearance of activity within 3 years.[3,4] The general reduction in such immunologic activity in time may reflect gradual reduction in the acute tissue reponse to surgery, i.e., urogenital inflammation or extravasation of sperm antigenic components.

Acknowledgments. We wish to thank Ms. Karil Kingbeil and Ms. Lucy Berliner, Department of Social Service, and Mrs. Marian Ursic, Department of Medicine, University of Washington, Seattle, Washington, for their assistance during this study. In addition, we thank Mr. James Graves, Mrs. Mina Garrison, and Mrs. Dolores LaBarge for their expert technical support. Mrs. Nancy Whitten provided editorial and clerical assistance, for which we are most grateful.

REFERENCES

1. Jennings PB, McCarthy MK, Plymate SR, Wettlaufer JN: Prevalence of circulating HL-A lymphocytotoxic antibodies in men after vasectomy. Fertil Steril 26:53, 1975
2. Terasaki PI, McClelland J, Park MS, McCurdy B: Microdroplet lymphocyte cytotoxicity test. In Manual of Tissue Typing Techniques, Department of Health, Education and Welfare Publication No. NIH 75-545. Bethesda Md, National Institutes of Health, 1974, p 67
3. Ansbacher R: Bilateral vas ligation: sperm antibodies. Contraception 9:227, 1974
4. Davis JE, Lubell I: Advances in understanding the effects of vasectomy. Mt Sinai J Med NY 42:391, 1975

4-7

THE JOURNAL OF UROLOGY
Vol. 115, January
Copyright © 1976 by The Williams & Wilkins Co.
Printed in U.S.A.

SPERM ANTIBODIES AFTER VASECTOMY WITH FULGURATION

N. J. ALEXANDER,* S. S. SCHMIDT, M. J. FREE, M. V. DANILCHIK AND W. T. HILL

From the Oregon Regional Primate Research Center, Beaverton and the Division of Urology, University of Oregon Health Sciences Center, Portland, Oregon; the Division of Urology, University of California School of Medicine, San Francisco and The General Hospital, Eureka, California, and the Battelle Pacific Northwest Laboratories, Richland, Washington

ABSTRACT

Whether antisperm antibodies develop after vasectomy probably depends on several variables, 1 of which may be the surgical technique. The levels of serum antisperm antibodies were compared in men vasectomized by 2 techniques: vasoligation and fulguration. No difference in the incidence of spermagglutinating antibody was found in the 2 groups. However, immobilizing antibodies were observed in 43 per cent of the men undergoing vasoligation but in only 29 per cent of the men vasectomized by fulguration.

Antisperm antibodies develop in about half of the vasectomized men.[1-3] However, why they develop in some and not in others is not well understood. The explanation involves several variables, including not only the basic immunocompetence of the individual but probably also such factors as the rate of sperm output, the sites of sperm resorption and extravasation, and the possibility of adjuvant inflammatory effects at the time of sperm extravasation. Moreover, different surgical procedures may lead to the formation of different kinds of vas blockage, which may or may not accentuate sperm extravasation. Therefore, antibody formation may be related to the surgical method. The fulguration method developed by Schmidt involves sectioning and fulguration of the vas without the conventional vasoligation.[4] It is suggested that the firm scar that forms on the cut and fulgurated ends of the vas is effective against granuloma formation.[5-9] On the other hand, there may be a short interval before scar formation during which time sperm have access to the scrotal tissues; if so, either tolerance or rapid sensitization and immunization may result. The reported low incidence of sperm granulomas associated with the fulguration technique prompted a retrospective study of 94 patients vasectomized by Schmidt during the last 11 years to compare them with an unmatched group of men vasectomized by ligation for a comparable period.

METHODS

Single 2 ml. blood samples were taken from 94 men vasectomized between January 1963 and December 1974 by the fulguration method described by Schmidt.[4] These samples were compared with sera from 87 men vasectomized by the conventional vas ligation technique by several different physicians. Thirteen additional samples taken from these men at different intervals are included in the comparison of time intervals but not in the comparison of the totals. Antibodies to spermatozoa were assayed by the macroscopic spermagglutination technique[10] and the sperm immobilization procedure.[11] The spermagglutinin titer was reported as the reciprocal of the last positive dilution. Spermagglutinating antibodies equal to or more than 20 were considered positive. Sera were considered positive for sperm immobilizing antibodies if the ratio of control percentages to test motility percentages was equal to or more than 2.0. The incidence and titers of sperm antibodies were examined for the following time intervals after vasectomy: 0 to ½, ½ to 1, 1 to 2, 2 to 3, 3 to 5 and more than 5 years.

RESULTS AND DISCUSSION

Of the 87 men vasectomized by means of vasoligation during the last 10 years 43 per cent exhibited sperm-immobilizing activity, while only 29 per cent of 94 men vasectomized with fulguration of the vasa had sperm-immobilizing antibodies (table 1). An X^2 analysis of these data shows the different frequencies to be significant only at p less than 0.10. When broken down into respective time periods this discrepancy diminishes. No differences in agglutination activity were observed between the 2 groups (table 2).

Testicular ends of the vas examined at the time of vasovasostomy reveal that about 20 per cent have had demonstrable spermatic granulomas. In addition, others have had epididymal obstruction which may be caused by spermatic granulomas. Schmidt and Morris report that fewer granulomas result from vasectomy by the fulguration technique than by vasoligation.[4, 5] They observed that the testicular end of the vas is capped by a firm scar without evidence of granuloma. The results of our study on antisperm antibodies reveal similar or slightly lower sperm immobilizing antibody levels in the fulguration group as compared to the vasoligation group. Alexander showed that sperm immobilizing antibody titers in vasectomized rhesus monkeys correlated with the incidence of sperm granulomas.[12] Her study involved vas fulguration similar to Schmidt's, yet exploratory operations showed that granulomas developed in 4 of the 6 monkeys. This high rate of granuloma formation after vasectomy may reflect a species difference between man and the rhesus monkey or a difference in surgical technique. Because human and rhesus sperm counts normally vary within the same order of magnitude per ejaculate, it is not expected that the rate of sperm output would account for the differences observed.

Brannen and associates have suggested that a low incidence of antisperm antibody levels may indicate cell-mediated immunity.[13] High antibody levels developed in rats with ligated vasa, whereas cell-mediated immunity developed exclusively in those with no ligation after vasectomy. However, granulomas developed in both groups. The type of immune response may well depend upon the rate and time of exposure to spermatozoa[13, 14] and the type of vasectomy performed may produce different immune responses. For at least a short while after vasectomy ligation completely prevents extravasation, and it is only after a certain lag that the combination of necrosis at the site of constriction and build-up of back pressure

Accepted for publication June 13, 1975.
Partial support for this study by Contract 70 from the Program for Applied Research on Fertility Regulation and Contract AID/CSD-3153 from the Agency for International Development.
Publication No. 813 from the Oregon Regional Primate Research Center.
* Requests for reprints: Oregon Regional Primate Research Center, 505 N.W. 185th Ave., Beaverton, Oregon 97005

4-8

FOLLOW-UP OF BLOOD CHEMISTRY, REPRODUCTIVE HORMONES AND ANTISPERM ANTIBODIES AFTER VASECTOMY IN 122 MEN

N. A. Alexander

M. J. Free

C. A Paulson

R. Buschbom

D. Fulgham

WORKING DRAFT - NOT FOR DISTRIBUTIC

This study was supported by the Office of Population U.S. Agency for International Development, Contract AID/CSD-3152 to Battelle-Northwest Laboratories.

At least 11 studies of pituitary-gonadal function after vasectomy have been reported (4,5,8,9,11,12,13,14,15,16,17) without evidence of change attributable to vasectomy. While these studies provide ample testimony for the absence of dramatic changes in sex hormones resulting from vasectomy they do not preclude the possibility of more subtle effects arising out of other endocrine, metabolic or immunologic responses to vasal occlusion.

In the present study 14 serum chemistry parameters were measured in combination with circulating levels of follicle stimulating hormone (FSH), luteinizing hormone (LH), testosterone (T), sperm immobilizing antibodies and sperm agglutinating antibodies prior to vasectomy and intermittently, up to 44 months following vasectomy in 122 men.

MATERIALS AND METHODS

The Study Population: Two groups of volunteers were drawn from patients requesting vasectomy for contraceptive purposes. One group of 73 men was from the Harborview (HV) hospital and another group of 49 men from Madigan Army Medical Center (MAMC), both in Seattle, Washington. The two groups were studied independently although hormone assays from both groups were performed in the same laboratories.

On the basis of blood chemistry prior to and following vasectomy, the two groups were distinctly different. All of the serum chemistry parameters with the exception of blood urea nitrogen and potassium

showed statistically significant differences between the two study groups (see Table 3).

This difference may be attributed in part to the significant age difference ($P < 0.001$) between the two groups. HV volunteers averaged $29.1 \pm 5.3\ S_x$ compared with $36.0 \pm 8.3\ S_x$ for the MAMC group.

Difficulties of follow-up resulted in less than 50% of patients being sampled at each of the time intervals during the first 12 months with the exception of zero time at which more than 90% of patients were sampled. Time intervals for sampling postvasectomy were 1.5 (HV only), 3, 6, 9, and 12 months. Thereafter, loss to follow-up increased markedly and less than 20% of patients became available at irregular intervals up to 44 months.

Surgical Protocol:

Analytical Methods:

Statistical Methods: Raw data were analyzed initially by comparing means between study populations and between time intervals within each population and the combined population.

Patients from each of the HV and MAMC studies were then divided into a nonresponder group and a responder group. A patient was classified as a responder if his sperm agglutination measurement was equal to or greater than 40, or if his sperm immobilization measurement was equal to or greater than 500 for any sperm antibody measurement made after vasectomy but not before vasectomy. All other patients were classified as nonresponders providing antibody data was available before vasectomy and at 9 or 12 months after vasectomy.

Means for each variable for nonresponders and responders were compared at each time, to see if there were any significant differences. Since the number of men sampled varied considerably between sampling times a fairly large amount of variation is to be expected from one measurement time to the next. The two tailed t test was used to test the hypothesis that the means for responders and nonresponders are equal.

The final stage of statistical analysis involved selection of a group of patients in which each individual had a blood sample taken before his vasectomy and then at 3, 6, 9 and 12 months after vasectomy. This group came entirely from the HV study since only 2 patients qualified in the MAMC study. Analysis was performed on this group both with and without regard for sperm antibody (responder/nonresponder) status.

RESULTS

No men from either population had agglutinating or immobilizing antibodies at the time of vasectomy. However, 29 men from the HV group and 13 men from the MAMC group developed measurable levels of one or both antibodies within 1 year after vasectomy. Since 13 men from the HV group and 10 men from the MAMC group had insufficient data to determine antibody status the responders constituted 48% and 33% of the measurable population for HV and MAMC respectively. The incidence of sperm antibodies for each time interval are shown in Tables 1 and 2.

Comparison of mean blood chemistry or sex hormone values from HV and the older MAMC men at the time of vasectomy revealed significant differences between the two populations for most of the parameters studied (Table 3).

In order to determine if men who developed sperm antibodies in response to vasectomy were different from those who did not, with respect to blood chemistry or sex hormone levels at any time before or after vasectomy, each study population was divided into men who developed antisperm antibodies (responders) and those who did not (nonresponders). Data for sex hormone parameters analyzed in this way are shown in Tables 4 and 5. No significant differences between responders and nonresponders were found for testosterone or LH values in the HV or MAMC populations. However, the pattern of low probability values associated with FSH in both HV (Table 3) and MAMC (Table 4) study groups and the consistently

lower FSH values for responders compared with nonresponders at all time intervals through 36 months in the MAMC group and 42 months in the HV group strongly suggest that responders and nonresponders are different with respect to circulating FSH levels, even prior to vasectomy and the consequent development of measurable antisperm antibody titers. There were no significant differences in the ages of responders (MAMC, 32.3 ± 8.4; HV, 28.4 ± 5.6) compared with nonresponders (MAMC, 37.8 ± 7.2; HV, 30.4 ± 3.9). These results imply that men with low circulating FSH levels are more likely to develop antisperm antibodies after vasectomy. Since FSH has classically been associated with sperm production in a negative-feedback relationship, prevasectomy total sperm counts (available only for HV group) were analyzed in a similar fashion. Mean total sperm count for responders (235.1 ± 212.5 millions of sperm) was almost identical to that for nonresponders (232.6 ± 179.2 millions of sperm).

Blood chemistry data for the two study groups are shown in Tables 6 and 7. Because of the large number of statistical tests and, in some cases small sample sizes, isolated statistical differences are unlikely to be meaningful physiologically. No consistent pattern of differences between responders and nonresponders, and low probability levels, were evident for any blood chemistry parameter. However, some suggestion of differences in a few parameters is worthy of note. Serum potassium tended to be higher for responders compared with nonresponders from 9-12 months after vasectomy, with a pattern of low probability values particularly in the larger and more balanced HV population.

Another pattern suggesting lower serum sodium concentrations in the responder population both before and after vasectomy was reflected in the data from the HV group (Table 6) but could not be evaluated in the MAMC group because of the lack of responder data for this parameter (Table 7). Apart from a slight suggestion of lowered serum chlorine levels in the responder population in the first 3 months following vasectomy no other blood chemistry parameters showed remarkable differences between responders and nonresponders.

Comparisons of mean pre- and postvasectomy values were carried out using all the data for each parameter within each study group. These data are of limited value since they do not take into account changes occurring in the unvasectomized population throughout the period of study. In addition, transient changes over time may be distorted or obscured by the variable loss to follow-up at each time interval after vasectomy. Consequently, only dramatic changes resulting from vasectomy would be evident from this analysis. As expected, there were no dramatic changes in any of the parameters following vasectomy.

In order to remove distortion resulting from the fluctuating population at different time intervals we selected out of the HV group all of the men for whom data was available at all or most postvasectomy intervals. Means from these 29 men (21 nonresponders and 8 responders) are plotted over time for each parameter (Figure 1). At no time did a mean value for any parameter fall outside of the normal range for adult men. Additionally, analysis of variance revealed no significant differences between any mean within each parameter. The lowest probability value

encountered was 0.292 for serum albumin. There was, however, a tendency for transient changes to occur in a number of parameters (Figure 1) during the first 6 months of the study. Additionally, small net downward trends were evident for total protein, albumin, LH and testosterone while net upward trends were evident for Co_2 and creatinine. In the absence of a control population of unvasectomized men over the same time period we have no way of assessing the impact of aging, seasonal and other environmental factors on these parameters.

DISCUSSION

The data presented in this paper offer a more comprehensive picture of systemic physiological events surrounding vasectomy than has been offered heretofore. They substantiate previous studies (4,5,8,9,11,12, 13,14,15,16,17) suggesting no dramatic changes in the gonad-pituitary axis following vasectomy and further suggest that no substantial changes in blood chemistry result from the operation. The appearance of antisperm antibodies in 30-50% of men following vasectomy has been well documented ( ) and, for the present, remains the only clearly measurable change in blood parameters resulting from vasectomy.

A new perspective is offered in this study by comparison of the blood picture before and after vasectomy in those men that develop antisperm antibodies and those that do not. The most outstanding finding is that men who develop antisperm antibodies after vasectomy tend to have lower FSH levels before and after vasectomy than those who do not develop these antibodies.

This finding is strongly supported by data from each of the two groups of men vasectomized at different centers and otherwise very different with respect to blood chemistry values. The relationship between FSH and postvasectomy antisperm antibody formation is not obvious. It does not appear to involve simple numbers of sperm since the prevasectomy total sperm count did not differ for men who developed postvasectomy antibodies and those who did not. This finding poses some intriguing questions about both the role of FSH in the adult male and the etiology of antisperm antibody formation.

A pattern of lower serum sodium levels seen both before and after vasectomy in men who develop sperm antibodies after vasectomy also presents difficulties in interpretation. Although the evidence is less strong than for FSH primarily because of lack of meaningful numbers of responders measured for this parameter in the MAMC group, the suggestion of a serum sodium differences nevertheless warrants further study.

FSH levels do not appear to have predictive value for antisperm antibody formation since in the HV population studied here, only 54% of men developing antisperm antibodies after vasectomy had prevasectomy FSH levels below the median value. Conversely only 53% of men who never developed antibodies had prevasectomy FSH levels above the median value. However, when sodium was taken into account together with FSH the predictive value for nonresponder increased to 83%.

No strong evidence was found for changes in blood chemistry or sex hormones related to antisperm antibody production. There was some indication

of higher potassium levels 9-12 months after vasectomy and lower chloride levels within the first 3 months after vasectomy in men who developed antisperm antibodies compared with those who did not.

Discussion of this point: Paulson & Alexander

A group of 29 men for whom largely complete sets of data were available throughout the study period provided a basis for examining general trends in all the blood parameters throughout the period of study. Some strong trends were apparent in this data although the means never moved outside of the normal range, nor did the difference between any two sampling intervals ever approach statistical significance. There was, however, some recurring features among the family of trend curves, including perturbations in the first 3 months following vasectomy and net upward or downward trends. Since this present study suffers from the same limitation of many that have come before it, namely, of monitoring no control population of unvasectomized men during the study period, it is entirely possible that these trends reflect environmental factors influencing the population. Presumably, vasectomy itself would represent a mildly traumatic event that would be expected to result in transient nonspecific changes in blood chemistry and endocrinology.

In summary, we can state on the basis of this study that, other than antisperm antibody formation, no other significant changes in the blood picture have been found following vasectomy. However, the population of men who develop antisperm antibodies have a lower FSH level and may have a lower sodium concentration before and after vasectomy compared with those who do not develop antibodies. These findings and other suggestive evidence for antibody related changes and postvasectomy perturbations warrant further investigation including studies with carefully matched populations of vasectomized and unvasectomized men.

FIGURE 1 Blood Chemistry and Reproductive Hormone Status of 29 Men (HV group) at the time of, and up to 3 years after Vasectomy.

Each point is the average of all men from the group of 29 returning for follow-up at that interval. Intervals at which less than 5 men returned for follow-up were rejected in this analysis. The 95% confidence limits for the means are shown as bands either side of the mean.

REFERENCES

1. Chisari FV, Edington TS: Lymphocyte E rosette inhibitory factor: a regulatory serum lipoprotein. J Exp Med 142:1092, 1975.

2. Crafts R, Llerena LA, Guevara A, Lobotsky J, Lloyd CW: Plasma androgens and 17-hydroxycorticosteroids throughout the day in submarine personnel. Steroids 12:151, 1968.

3. Curtiss LK, Edington TS: Regulatory serum lipoproteins: regulation of lymphocyte stimulation by a species of low density lipoprotein. J Immunol 116:1452, 1976.

4. Johnsonbaugh RE, O'Connel K, Engel SB, Edson M, Sode J: Plasma testosterone, leuteinizing hormone, and follicle-stimulating hormone after vasectomy. Fertil Steril 26:329, 1975.

5. Kobrinsky NL, Winter JSD, Reyes FI, Faiman C: Endocrine effects of vasectomy in man. Fertil Steril 27(2):152, 1976.

6. Kubota R: Electron microsciopic studies on the testis after vasectomy in rats and men. Jap J Urol 60:373, 1969.

7. Naftolin F, Yen SS, Tsai CC: Rapid cycling of plasma gonadotrophins in normal men as demonstrated by frequent sampling. Nature 236:92, 1972.

8. Naik VK, Thakur, AN, Sheth AR, Joshi UM, Rao SS, Pardanani DS, Kulsreshtha JK, Handa RK: The effect of vasectomy on pituitary-gonadal function in men. J Repro Fertil 48(2):441, 1976.

9. Purvis K, Saksena SK, Cekan Z, Diczfalusy E, Giner J: Endocrine effects of vasectomy. Clin Endocrinol 5:263, 1976.

10. Rosemberg E, Crigler JF Jr, Jan WF, Butlat G, Nakano R, Lee SG: Biologic effect of human pituitary luteinizing hormone and human chorionic gonadotropin. In The Human Testis, Edited by E Rosemberg, CA Paulsen. New York, Plenum Press, 1970, 1970, p. 281.

11. Rosemberg E, Marks SC, Howard PJ, James LP: Serum levels of follicle stimulating and luteinizing hormones before and after vasectomy in men. J Urol 111(f):626, 1974.

12. Skegg, DC, Mathews JD, Guillbaud J, Vessey MF, Biswas S, Ferguson KM, Kitchin Y, Mansfield MD, Sommerville IF: Hormonal assessment before and after vasectomy. Br Med J 1(6010):621, 1976.

13. Smith KD, Chowdhury M, Tcholakian RK: Endocrinological effects of vasectomy. In Control of Male Fertility, Edited by JJ Sciarra, C Markland, JJ Speidel. New York, Harper and Row, 1975, p. 169.

14. Smith KD, Tcholakian RK, Chowdhury M, Steinberger E: An investigation of plasma hormone levels before and after vasectomy. Fertil Steril 27(2):145, 1976.

15. Varma MM, Varma RR, Johanson AJ, Kowarski A, Migeon CJ: Long-term effects of vasectomy on pituitary-gonadal function in man. J Clin Endocrinol Metab 40:868, 1975.

16. Whitby M, Gordon RD, Seeney N, Thomas MJ: Vasectomy: a long-term study of its effects on testicular endocrine function in man. Andrologia 8(1):55, 1976.

17. Wieland RG, Hallberg MC, Zorn EM, Klein DE, Luria SS: Pituitary-gonadal function before and after vasectomy. Fertil Steril 23: 799, 1972.

TABLE 1. Antisperm Antibodies, HV Group

	Months After Vasectomy					
	0	1.5	3	6	9	12
Number of Responders/ Number of Nonresponders	0/0	25/27	22/23	25/22	22/24	22/30
Percent of men with detectable levels of:						
Sperm agglutinating antibody alone	0	8	11	11	11	8
Sperm immobilizing antibody alone	0	2	7	4	7	10
Sperm agglutinating plus immobilizing	0	4	13	28	28	23
Percent of men responding	0	14	31	43	46	41

TABLE 2. Antisperm Antibodies, MAMC Group

	Months After Vasectomy				
	0	3	6	9	12
Number of Responders/ Number of nonresponders	0/0	8/15	11/22	6/19	8/18
Percent of men with detectable levels of:					
Sperm agglutinating antibody alone	0	0	6	8	0
Sperm immobilizing antibody alone	0	4	3	0	8
Sperm agglutinating plus immobilizing	0	17	12	12	19
Percent of men responding	0	21	21	20	27

TABLE 3. Variable Means Before Vasectomy

Variable		Study HV	Study MAMC	Prob.
Age (years)	N	73	58	
	$\bar{X}$	29.1	36.0	
	S_x	5.3	8.3	<0.001
FSH (mμg LER 907/ ml serum)	N	68	48	
	$\bar{X}$	181.9	210.5	0.052
	S_x	74.4	81.3	
TESTOSTERONE (μg/100 ml)	N	66	46	
	$\bar{X}$	66.5	63.7	0.539
	S_x	24.4	22.2	
LH (mIU 2nd IRP/ ml serum)	N	68	49	
	$\bar{X}$	99.6	69.1	0.001
	S_x	44.5	53.6	
NA (mEq/liter)	N	73	12	
	$\bar{X}$	140.7	133.7	<0.001
	S_x	2.4	12.5	
K (mEq/liter)	N	73	12	
	$\bar{X}$	43.3	41.1	0.070
	S_x	3.8	4.2	
CL (mEq/liter)	N	72	12	
	$\bar{X}$	103.2	98.9	<0.001
	S_x	2.4	6.1	
CO_2 (mEq/liter)	N	73	12	
	$\bar{X}$	25.7	28.7	0.007
	S_x	3.2	5.0	
TOTAL PROTEIN (g/100 ml)	N	73	45	
	$\bar{X}$	74.4	68.6	<0.001
	S_x	4.1	8.5	

Variable		Study HV	Study MAMC	Prob.
ALBUMIN (g/100 ml)	N	72	45	
	$\bar{X}$	46.5	48.9	0.006
	S_x	2.7	6.4	
CA (mg/100 ml)	N	73	45	
	$\bar{X}$	99.8	92.5	<0.001
	S_x	5.0	12.9	
ALKALINE PHOSPHATASE (units)	N	71	45	
	$\bar{X}$	61.3	56.0	0.057
	S_x	14.7	14.1	
BILIRUBIN (mg/100 ml)	N	72	45	
	$\bar{X}$	7.0	4.4	<0.001
	S_x	3.9	1.9	
BUN (mg/100 ml)	N	73	12	
	$\bar{X}$	15.3	13.4	0.123
	S_x	3.8	4.6	
GLUCOSE (mg/100 ml)	N	73	12	
	$\bar{X}$	101.7	84.1	<0.001
	S_x	12.3	28.2	
URIC ACID (mg/100 ml)	N	70	45	
	$\bar{X}$	58.3	56.1	0.308
	S_x	11.3	11.1	
CREATININE (mg/100 ml)	N	72	45	
	$\bar{X}$	10.5	10.0	0.108
	S_x	1.5	1.8	
CHOLESTEROL (mg/100 ml)	N	46	45	
	$\bar{X}$	202.0	218.1	0.094
	S_x	39.2	50.8	

TABLE 4. Twelve-Month Follow-Up of Sex Hormone Levels: HV Group

		Months					
		0	1.5	3	6	9	12
FSH (mμg LER 907/ml serum)							
Nonresponder	N	30	29	25	27	26	31
	$\bar{X}$	202.8	198.5	201.8	193.3	192.5	203.7
	S_x	74.7	77.9	65.3	70.6	86.7	70.6
Responder	N	26	7	15	22	20	21
	$\bar{X}$	163.4	119.0	151.2	182.0	169.3	188.2
	S_x	70.6	61.4	81.5	82.1	67.6	64.3
	Prob.	0.049	0.017	0.037	0.605	0.328	0.425
TESTOSTERONE (μg/100 ml)							
Nonresponder	N	30	23	19	24	23	26
	$\bar{X}$	0.644	0.598	0.669	0.632	0.613	0.638
	S_x	0.282	0.241	0.293	0.247	0.200	0.247
Responder	N	25	7	10	16	17	18
	$\bar{X}$	0.648	0.207	0.725	0.659	0.595	0.629
	S_x	0.168	0.207	0.244	0.231	0.176	0.181
	Prob.	0.951	0.070	0.613	0.731	0.760	0.896
LH (mIU 2nd IRP/ml serum)							
Nonresponder	N	30	29	25	27	26	30
	$\bar{X}$	10.52	9.12	9.60	8.88	8.71	10.04
	S_x	4.73	3.41	3.60	4.52	3.54	4.52
Responder	N	26	7	15	22	20	21
	$\bar{X}$	9.74	11.01	10.63	10.09	10.59	9.99
	S_x	4.38	4.41	4.31	5.49	4.23	3.68
	Prob.	0.528	0.222	0.424	0.401	0.109	0.965

TABLE 5. Twelve-Month Follow-Up of Sex Hormone Levels: MAMC Group

		Months				
		0	3	6	9	12
FSH (mμg LER 907/ml serum)						
Nonresponder	N	26	20	22	20	19
	$\bar{X}$	241.3	242.1	228.9	250.8	238.9
	S_x	82.7	89.6	82.1	103.4	100.7
Responder	N	13	4	8	5	7
	$\bar{X}$	185.9	218.5	197.9	157.2	193.9
	S_x	74.8	118.6	81.7	38.7	71.0
	Prob.	0.049	0.651	0.368	0.062	0.290
TESTOSTERONE (μg/100 ml)						
Nonresponder	N	25	19	22	20	19
	$\bar{X}$	0.630	0.689	0.644	0.668	0.646
	S_x	0.138	0.185	0.201	0.219	0.208
Responder	N	12	5	8	5	7
	$\bar{X}$	0.678	0.684	0.576	0.802	0.717
	S_x	0.368	0.131	0.247	0.384	0.593
	Prob.	0.560	0.956	0.450	0.305	0.312
LH (mIU and IRP/ml serum)						
Nonresponder	N	26	20	22	20	19
	$\bar{X}$	6.39	7.85	7.04	8.19	7.91
	S_x	2.94	5.28	2.64	4.54	4.38
Responder	N	13	5	8	5	7
	$\bar{X}$	6.01	6.34	7.45	6.48	8.17
	S_x	2.69	1.86	3.35	4.21	2.23
	Prob.	0.694	0.540	0.729	0.454	0.883

TABLE 6. Twelve-Month Follow-Up of Blood Chemistry: HV Group

		Months					
		0	1.5	3	6	9	12
NA (mEq/liter)							
Nonresponder	N	31	30	27	26	25	31
	$\bar{X}$	141.3	141.3	140.5	140.8	141.2	141.2
	S_x	2.2	1.8	2.6	1.8	2.4	2.2
Responder	N	29	9	14	22	20	21
	$\bar{X}$	139.8	140.4	140.1	140.0	139.7	140.1
	S_x	2.5	1.4	5.7	2.1	2.8	3.8
	Prob.	0.015	0.226	0.732	0.202	0.065	0.213
K (mEq/liter)							
Nonresponder	N	31	30	27	26	25	31
	$\bar{X}$	4.30	4.33	4.19	4.32	4.19	4.20
	S_x	0.41	0.26	0.33	0.34	0.34	0.34
Responder	N	29	9	14	22	20	21
	$\bar{X}$	4.35	4.29	4.36	4.30	4.37	4.39
	S_x	0.39	0.20	0.48	0.31	0.36	0.33
	Prob.	0.597	0.641	0.166	0.835	0.096	0.054
CL (mEq/liter)							
Nonresponder	N	30	30	27	26	25	31
	$\bar{X}$	103.2	103.2	104.0	103.5	102.8	103.7
	S_x	2.2	2.2	2.4	2.0	2.0	2.5
Responder	N	29	9	14	22	20	21
	$\bar{X}$	102.9	101.9	101.9	103.6	102.8	103.2
	S_x	2.6	1.8	4.6	3.6	2.1	4.0
	Prob.	0.671	0.116	0.057	0.867	0.948	0.624

TABLE 6. Continued.

		Months					
		0	1.5	3	6	9	12
CO_2 (mEq/liter)							
Nonresponder	N	31	30	27	25	25	31
	$\bar{X}$	25.9	26.2	25.3	26.2	26.6	26.8
	S_x	2.6	2.0	2.8	3.8	1.9	2.3
Responder	N	29	9	14	22	20	21
	$\bar{X}$	25.5	27.7	26.3	25.5	26.3	26.7
	S_x	3.7	2.3	1.9	1.8	1.9	2.7
	Prob.	0.586	0.064	0.259	0.492	0.503	0.861
TOTAL PROTEIN (g/100 ml)							
Nonresponder	N	31	30	27	26	23	30
	$\bar{X}$	7.41	7.43	7.36	7.35	7.43	7.39
	S_x	0.47	0.40	0.46	0.30	0.29	0.47
Responder	N	29	7	14	20	19	21
	$\bar{X}$	7.43	7.40	7.47	7.43	7.40	7.30
	S_x	0.34	0.26	0.62	0.40	0.30	0.25
	Prob.	0.867	0.853	0.528	0.498	0.740	0.384
ALBUMIN (g/100 ml)							
Nonresponder	N	31	30	26	26	25	30
	$\bar{X}$	4.61	4.51	4.55	4.62	4.69	4.53
	S_x	0.29	0.32	0.30	0.25	0.26	0.20
Responder	N	28	9	14	22	19	21
	$\bar{X}$	4.67	4.66	4.69	4.60	4.61	4.55
	S_x	0.27	0.18	0.31	0.23	0.31	0.23
	Prob.	0.397	0.198	0.200	0.775	0.353	0.816

TABLE 6. Continued

		Months					
		0	1.5	3	6	9	12
CA (mg/100 ml)							
Nonresponder	N	31	30	26	26	24	31
	$\bar{X}$	9.98	9.78	10.01	9.80	9.89	9.77
	S_x	0.66	0.39	0.73	0.48	0.47	0.42
Responder	N	29	9	14	21	20	21
	$\bar{X}$	9.98	9.94	10.08	10.10	10.05	9.95
	S_x	0.37	0.27	0.70	0.68	0.40	0.71
	Prob.	0.973	0.243	0.780	0.078	0.239	0.262
ALK. P'TASE (U)							
Nonresponder	N	31	30	27	27	23	29
	$\bar{X}$	61.7	59.6	62.3	59.5	59.8	63.0
	S_x	16.1	13.9	17.1	14.8	17.3	16.0
Responder	N	27	9	14	22	20	21
	$\bar{X}$	59.2	62.3	59.7	60.0	61.8	60.0
	S_x	13.3	14.3	12.6	11.5	15.7	13.5
	Prob.	0.527	0.616	0.617	0.926	0.699	0.454
BILIRUBIN (mg/100 ml)							
Nonresponder	N	30	30	27	26	25	31
	$\bar{X}$	0.78	0.63	0.60	0.68	0.75	0.74
	S_x	0.49	0.26	0.26	0.25	0.34	0.46
Responder	N	29	9	14	22	20	21
	$\bar{X}$	0.70	0.70	0.53	0.61	0.70	0.69
	S_x	0.30	0.18	0.13	0.32	0.28	0.28
	Prob.	0.456	0.485	0.333	0.394	0.586	0.652

TABLE 6. Continued

		Months					
		0	1.5	3	6	9	12
BUN (mg/100 ml)							
Nonresponder	N	31	30	27	26	25	31
	$\overline{X}$	15.1	14.8	15.2	15.2	16.3	15.7
	S_x	3.4	3.3	5.0	3.0	4.3	4.6
Responder	N	29	9	14	22	20	21
	$\overline{X}$	15.8	15.1	17.2	16.0	14.8	15.4
	S_x	4.1	3.4	2.8	3.7	3.5	3.8
	Prob.	0.521	0.828	0.170	0.461	0.196	0.798
GLUCOSE (mg/100 ml)							
Nonresponder	N	31	30	27	26	25	31
	$\overline{X}$	102.4	108.5	101.9	106.1	99.4	103.8
	S_x	12.8	24.9	10.9	12.1	14.4	14.6
Responder	N	29	9	14	22	20	21
	$\overline{X}$	101.7	99.2	100.1	100.0	98.3	104.0
	S_x	11.1	8.1	8.1	15.2	14.0	13.3
	Prob.	0.806	0.284	0.593	0.130	0.791	0.955
URIC ACID (mg/100 ml)							
Nonresponder	N	30	29	27	26	25	29
	$\overline{X}$	5.59	5.61	5.72	5.56	5.86	5.68
	S_x	1.03	1.19	1.27	1.04	1.22	1.20
Responder	N	27	9	14	21	20	20
	$\overline{X}$	5.89	5.92	5.51	6.01	6.16	5.85
	S_x	1.01	0.70	0.88	1.05	1.09	0.90
	Prob.	0.274	0.467	0.587	0.148	0.410	0.600

TABLE 6. Continued

		Months					
		0	1.5	3	6	9	12
CREATININE (mg/100 ml)							
Nonresponder	N	30	30	27	26	25	30
	$\bar{X}$	1.01	1.00	1.03	1.02	1.06	1.06
	S_x	0.14	0.12	0.13	0.16	0.18	0.14
Responder	N	29	9	13	22	19	21
	$\bar{X}$	1.06	1.07	1.09	1.06	1.12	1.08
	S_x	0.15	0.14	0.24	0.15	0.14	0.16
	Prob.	0.266	0.139	0.264	0.438	0.273	0.654
CHOLESTEROL (mg/100 ml)							
Nonresponder	N	18	18	18	24	23	28
	$\bar{X}$	196.8	197.4	203.8	192.0	202.3	203.3
	S_x	39.0	40.6	42.3	43.2	44.3	34.7
Responder	N	16	5	11	20	20	20
	$\bar{X}$	187.6	186.6	200.5	196.9	204.1	197.1
	S_x	32.7	24.8	36.0	29.5	34.2	32.2
	Prob.	0.467	0.579	0.830	0.670	0.890	0.533

TABLE 7. Twelve-Month Follow-Up of Blood Chemistry: MAMC Group

		Months				
		0	3	6	9	12
NA (mEq/liter)						
Nonresponder	N	8	15	13	12	19
	$\bar{X}$	133.6	139.9	139.5	142.2	140.6
	S_x	14.9	2.7	9.6	6.0	3.6
Responder	N	1	2	5	4	7
	$\bar{X}$	122.0	143.5	139.0	143.5	141.1
	S_x	--	3.5	12.0	4.8	2.3
	Prob.	--	--	0.922	0.695	0.729
K (mEq/liter)						
Nonresponder	N	8	15	13	12	19
	$\bar{X}$	4.16	4.33	4.33	4.26	4.37
	S_x	0.52	0.29	0.36	0.35	0.31
Responder	N	1	2	5	4	7
	$\bar{X}$	3.90	4.45	4.34	4.68	4.53
	S_x	--	0.35	0.62	0.33	0.46
	Prob.	--	--	0.968	0.056	0.328
CL (mEq/liter)						
Nonresponder	N	8	15	13	12	19
	$\bar{X}$	100.1	101.4	101.1	102.4	103.6
	S_x	6.7	2.7	6.4	3.6	2.1
Responder	N	1	2	5	4	7
	$\bar{X}$	88.0	105.0	99.8	103.8	104.1
	S_x	--	2.8	8.2	2.5	1.1
	Prob.	--	--	0.731	0.508	0.541

TABLE 7. Continued

		Months 0	3	6	9	12
CO_2 (mEq/liter)						
Nonresponder	N	8	15	7	8	17
	$\bar{X}$	26.8	28.2	29.3	28.6	27.2
	S_X	2.5	3.7	6.2	4.5	3.8
Responder	N	1	1	2	2	6
	$\bar{X}$	31.0	29.0	25.0	23.0	23.7
	S_X	--	--	4.2	1.4	4.1
	Prob.	--	--	--	--	0.069
TOTAL PROTEIN (g/100 ml)						
Nonresponder	N	25	19	21	14	19
	$\bar{X}$	6.89	7.10	6.98	7.12	7.05
	S_X	0.87	0.42	0.52	0.42	0.32
Responder	N	11	5	8	3	6
	$\bar{X}$	6.66	7.12	6.96	7.23	6.95
	S_X	1.08	0.88	0.84	0.40	0.50
	Prob.	0.402	0.941	0.958	0.679	0.559
ALBUMIN (g/100 ml)						
Nonresponder	N	25	19	21	14	19
	$\bar{X}$	4.90	4.85	4.71	4.70	4.57
	S_X	0.69	0.50	0.49	0.48	0.28
Responder	N	11	5	8	3	6
	$\bar{X}$	4.86	5.04	4.85	5.07	4.63
	S_X	0.81	0.83	0.94	0.12	0.32
	Prob.	0.891	0.525	0.613	0.219	0.666

TABLE 7. Continued

		Months				
		0	3	6	9	12
CA (mg/100 ml)						
Nonresponder	N	25	19	21	14	19
	$\bar{X}$	9.35	9.59	9.55	9.71	9.64
	S_x	1.33	0.68	0.64	0.39	0.56
Responder	N	11	5	8	3	6
	$\bar{X}$	8.92	9.66	9.38	10.33	9.65
	S_x	1.58	1.01	1.40	0.06	0.69
	Prob.	0.400	0.865	0.649	0.017	0.963
ALK P'TASE (U)						
Nonresponder	N	25	19	21	14	18
	$\bar{X}$	54.4	57.4	57.7	56.3	58.7
	S_x	15.0	19.4	14.7	12.5	14.7
Responder	N	11	5	8	3	6
	$\bar{X}$	56.3	52.4	54.0	53.7	54.7
	S_x	14.2	9.6	10.6	8.4	8.1
	Prob.	0.733	0.589	0.520	0.737	0.536
BILIRUBIN (mg/100 ml)						
Nonresponder	N	25	19	21	14	19
	$\bar{X}$	0.41	0.49	0.41	0.43	0.45
	S_x	0.23	0.20	0.16	0.22	0.21
Responder	N	11	5	8	3	6
	$\bar{X}$	0.39	0.64	0.49	0.53	0.42
	S_x	0.17	0.36	0.25	0 23	0.33
	Prob.	0.529	0.229	0.325	0.462	0.786

TABLE 7. Continued

		Months 0	3	6	9	12
BUN (mg/100 ml)						
Nonresponder	N	8	15	13	12	19
	$\bar{X}$	14.3	14.3	13.5	13.6	14.1
	S_x	5.5	2.3	3.5	2.7	4.4
Responder	N	1	2	5	4	7
	$\bar{X}$	12.0	12.0	13.8	16.0	14.4
	S_x	--	2.8	2.2	4.2	2.6
	Prob.	--	--	0.845	0.196	0.858
GLUCOSE (mg/100 ml)						
Nonresponder	N	8	15	13	12	19
	$\bar{X}$	72.5	89.3	97.1	88.8	91.4
	S_x	27.3	17.2	25.0	16.0	27.8
Responder	N	1	2	5	4	7
	$\bar{X}$	80.0	87.0	76.8	71.5	91.0
	S_x	--	2.8	16.5	9.5	23.2
	Prob.	--	--	0.115	0.062	0.975
URIC ACID (mg/100 ml)						
Nonresponder	N	25	19	21	14	19
	$\bar{X}$	5.42	5.75	5.12	5.02	5.39
	S_x	1.07	0.91	0.86	1.25	1.28
Responder	N	11	5	8	3	6
	$\bar{X}$	5.37	6.08	4.99	5.23	5.36
	S_x	1.06	1.08	1.56	1.44	1.34
	Prob.	0.903	0.497	0.764	0.798	0.985

TABLE 7. Continued

		Months				
		0	3	6	9	12
CREATININE (mg/100 ml)						
Nonresponder	N	25	19	21	13	19
	$\overline{X}$	1.01	0.94	1.00	0.88	1.32
	S_x	0.17	0.15	0.19	0.20	0.89
Responder	N	11	5	8	3	6
	$\overline{X}$	0.95	1.10	0.88	1.13	1.52
	S_x	0.20	0.24	0.40	0.06	1.27
	Prob.	0.386	0.071	0.253	0.055	0.667
CHOLESTEROL (mg/100 ml)						
Nonresponder	N	25	19	21	14	19
	$\overline{X}$	224.1	236.5	233.0	231.6	222.4
	S_x	45.7	32.6	29.4	23.0	33.0
Responder	N	11	5	8	3	6
	$\overline{X}$	196.7	237.6	189.3	236.7	229.5
	S_x	48.7	55.9	47.3	51.4	44.3
	Prob.	0.114	0.956	0.005	0.785	0.676

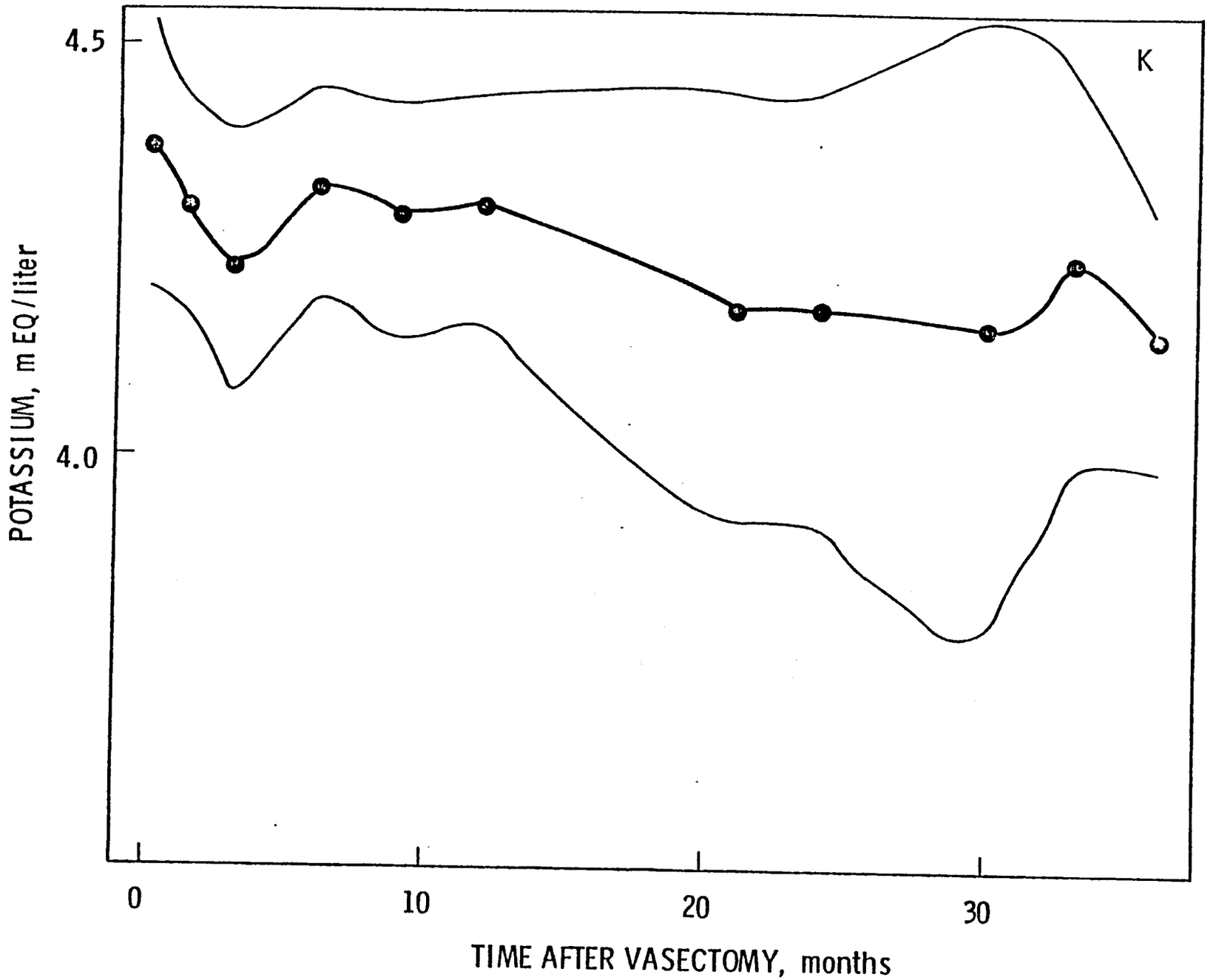
4.5
4.0
POTASSIUM, m EQ/liter
K
0
10
20
30
TIME AFTER VASECTOMY, months

HARBORVIEW

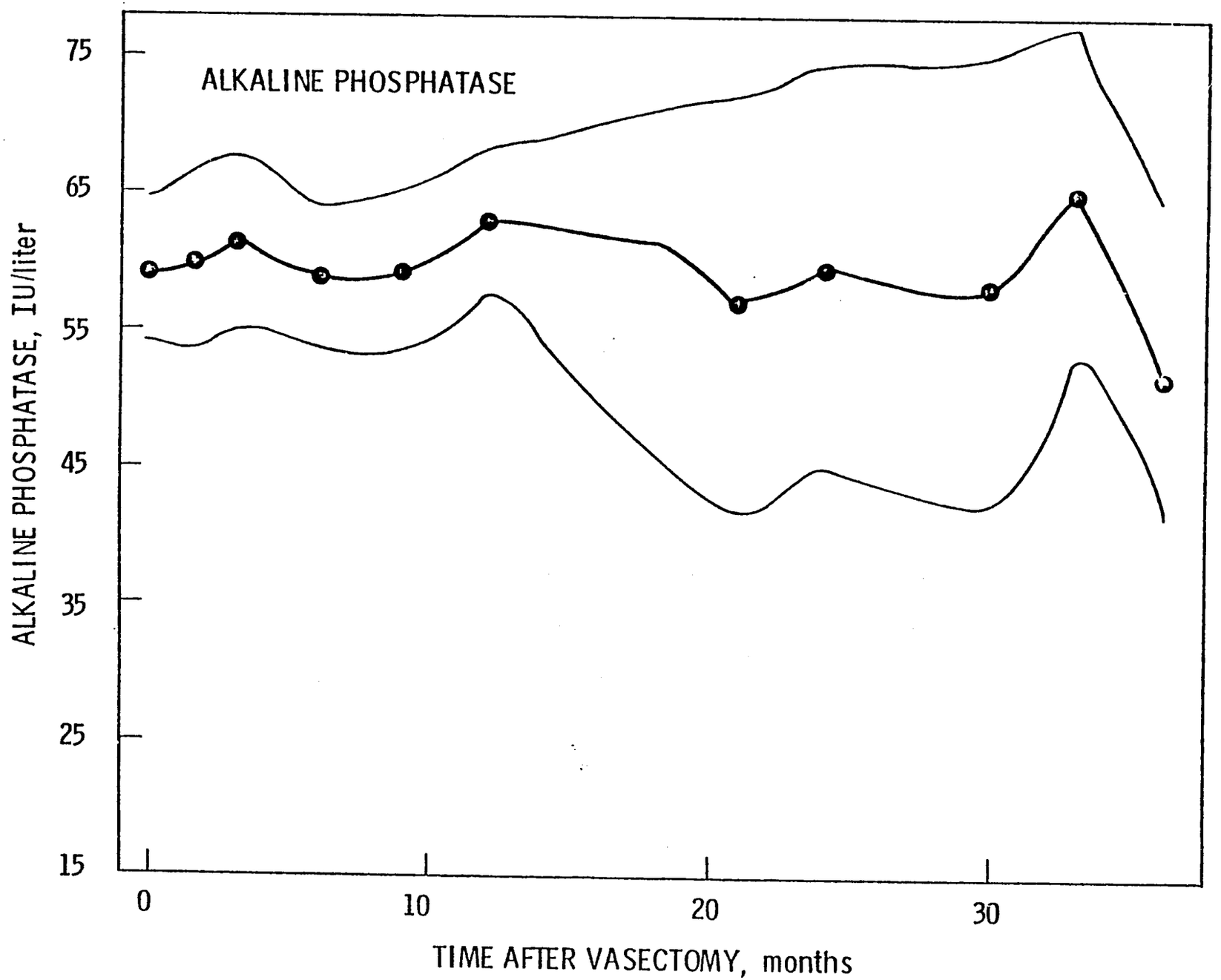
ALKALINE PHOSPHATASE
ALKALINE PHOSPHATASE, IU/liter
75
65
55
45
35
25
15
0
10
20
30
TIME AFTER VASECTOMY, months

HARBORVIEW

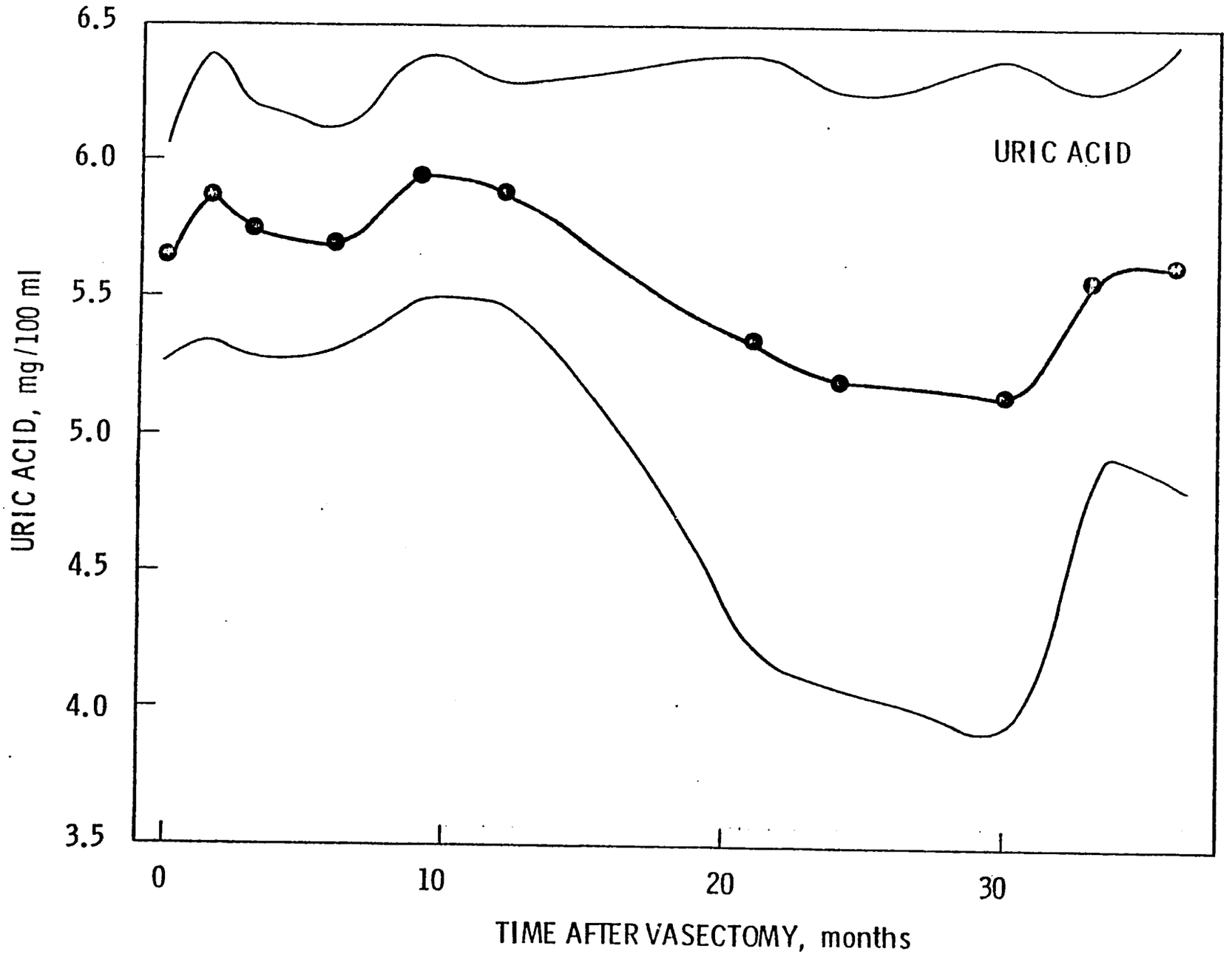

HARBORVIEW

4-21

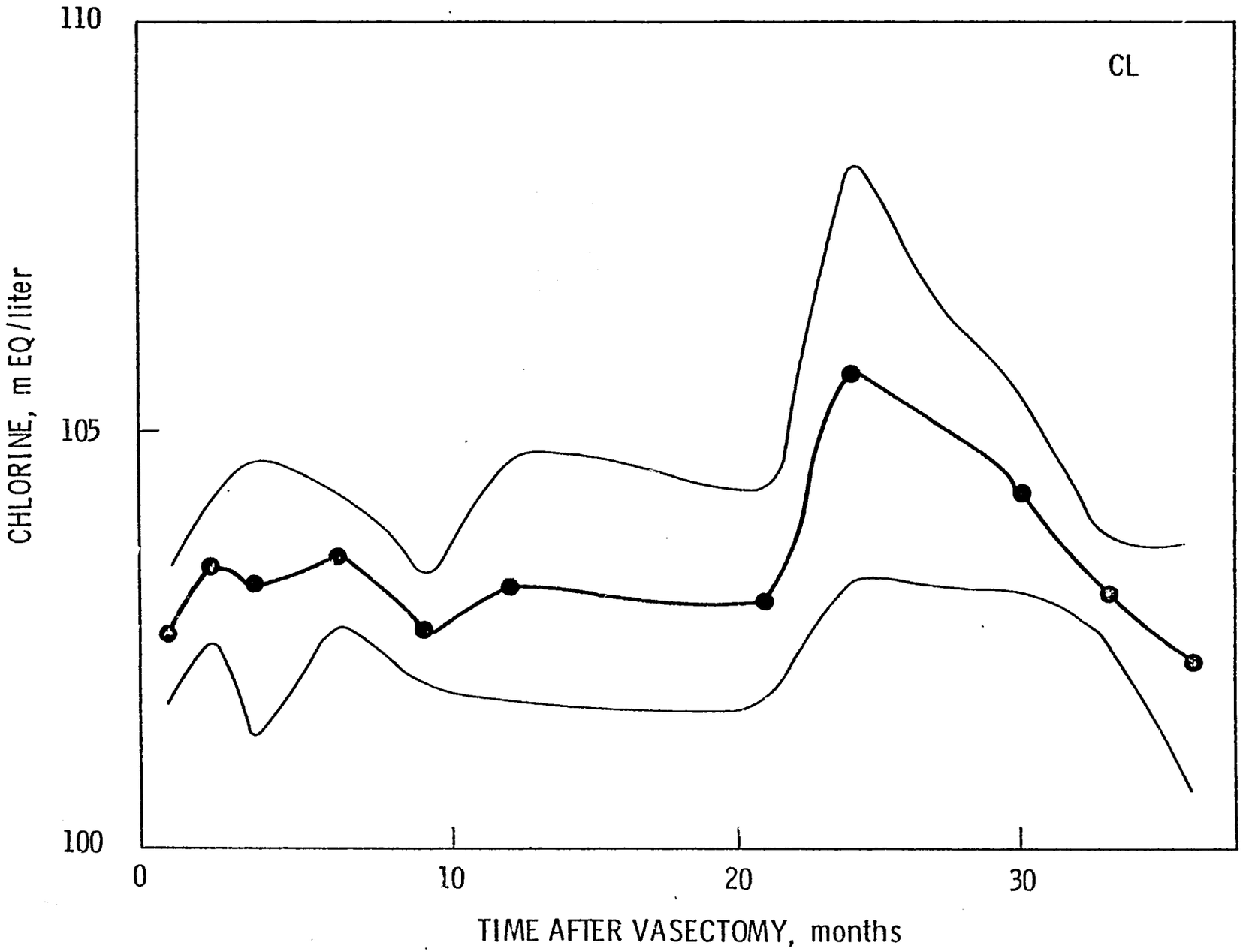
CL
110
105
100
CHLORINE, m EQ/liter
0
10
20
30
TIME AFTER VASECTOMY, months

HARBORVIEW

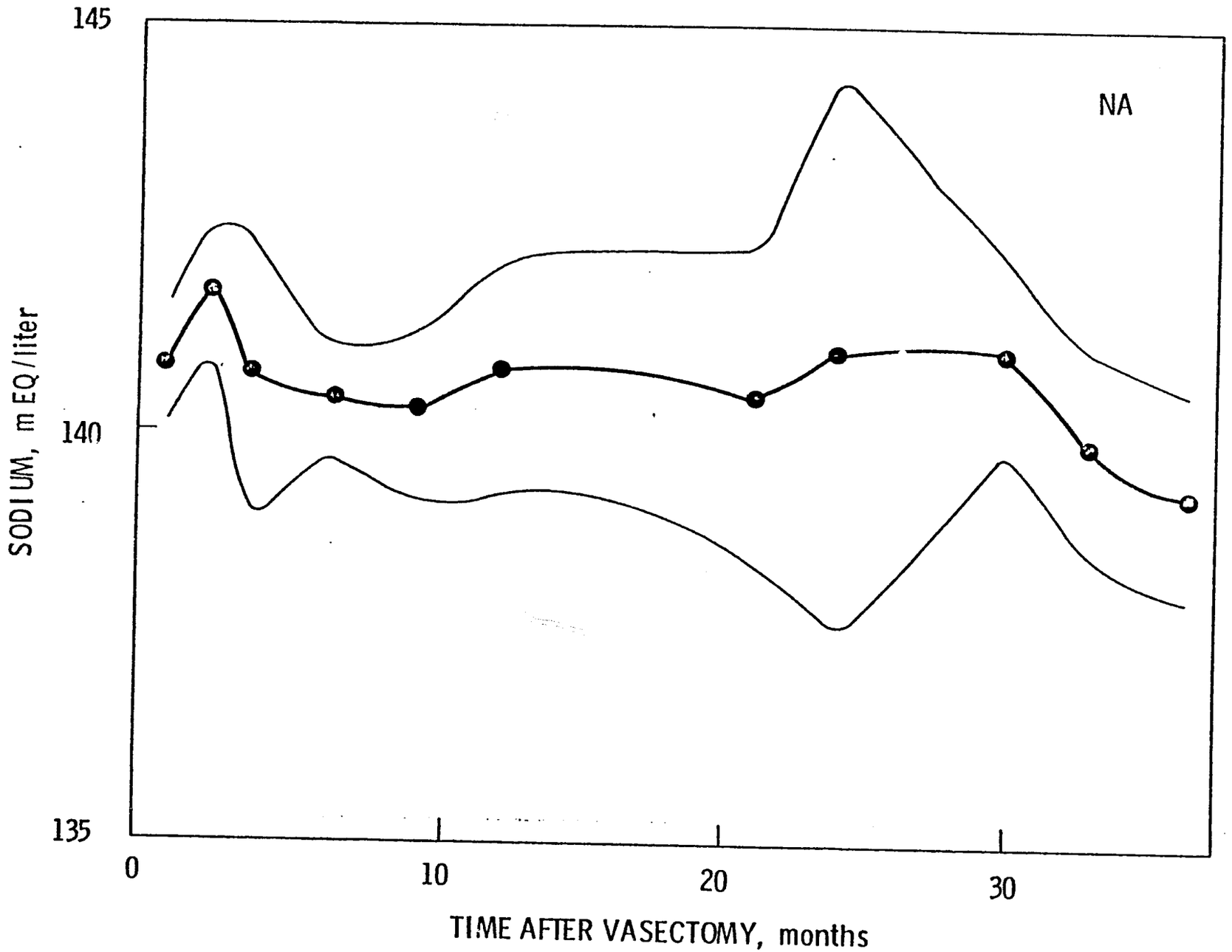

HARBORVIEW

4-33

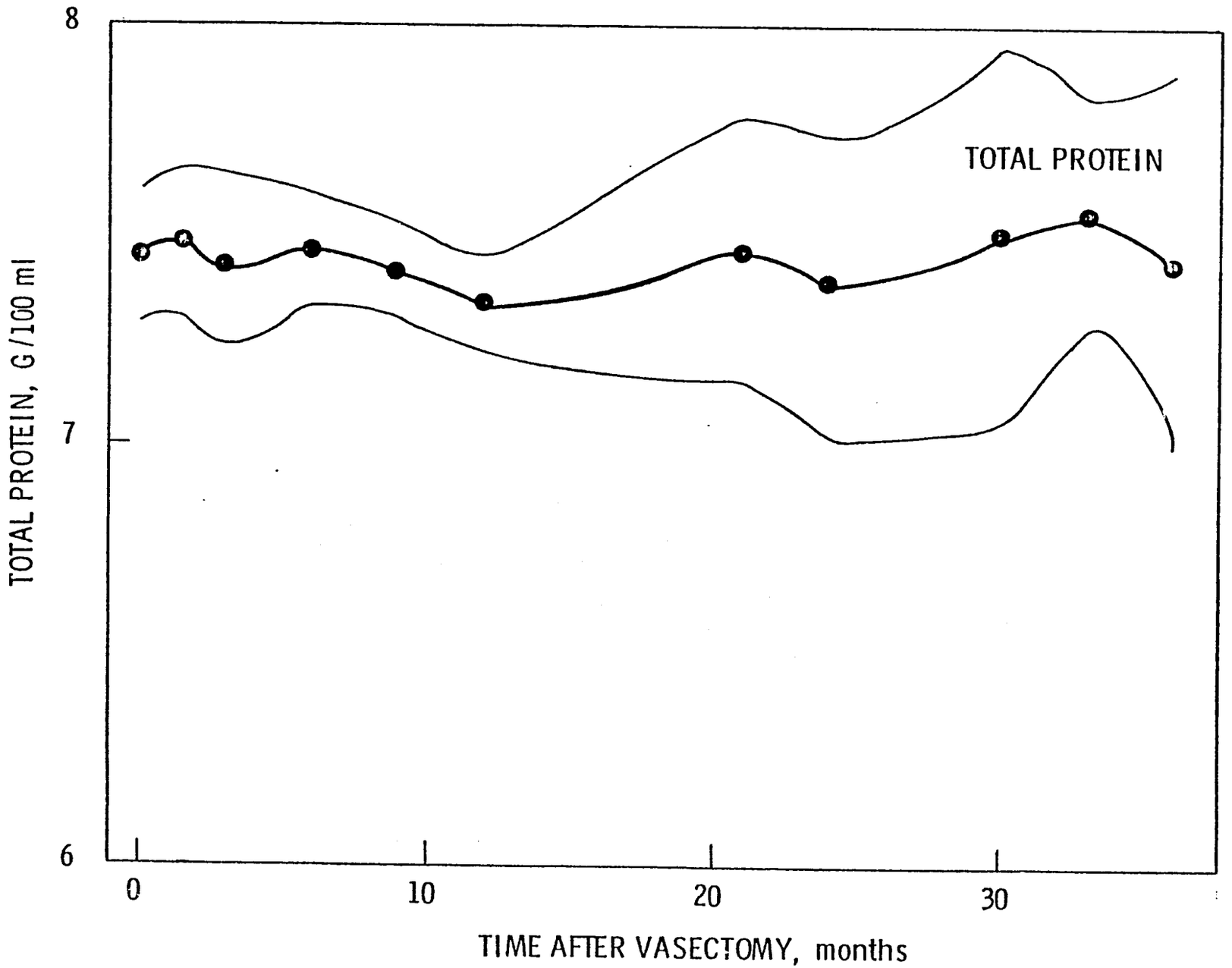
8
7
6
TOTAL PROTEIN, G/100 ml
TOTAL PROTEIN
0
10
20
30
TIME AFTER VASECTOMY, months

HARBORVIEW

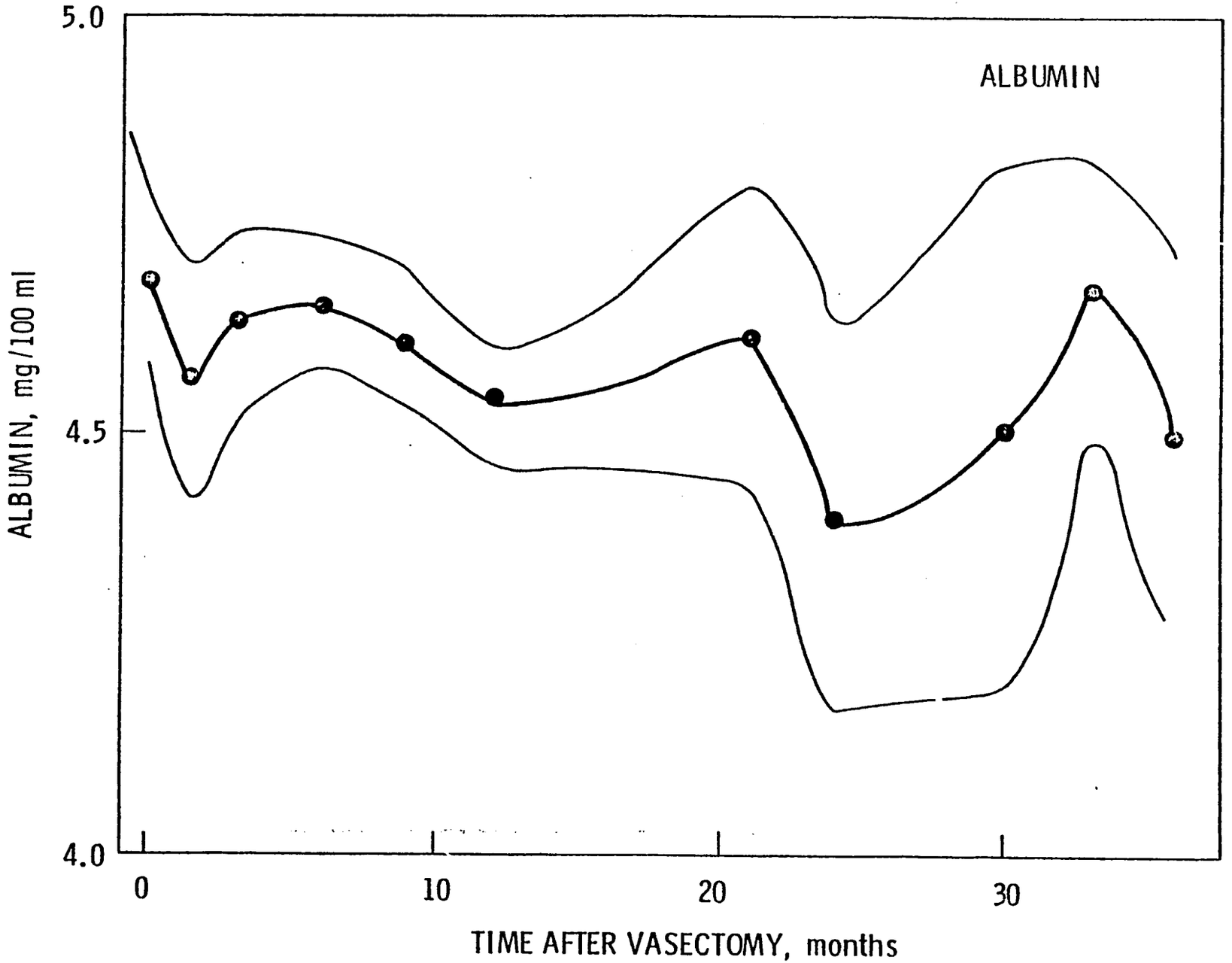

HARBORVIEW

4-35

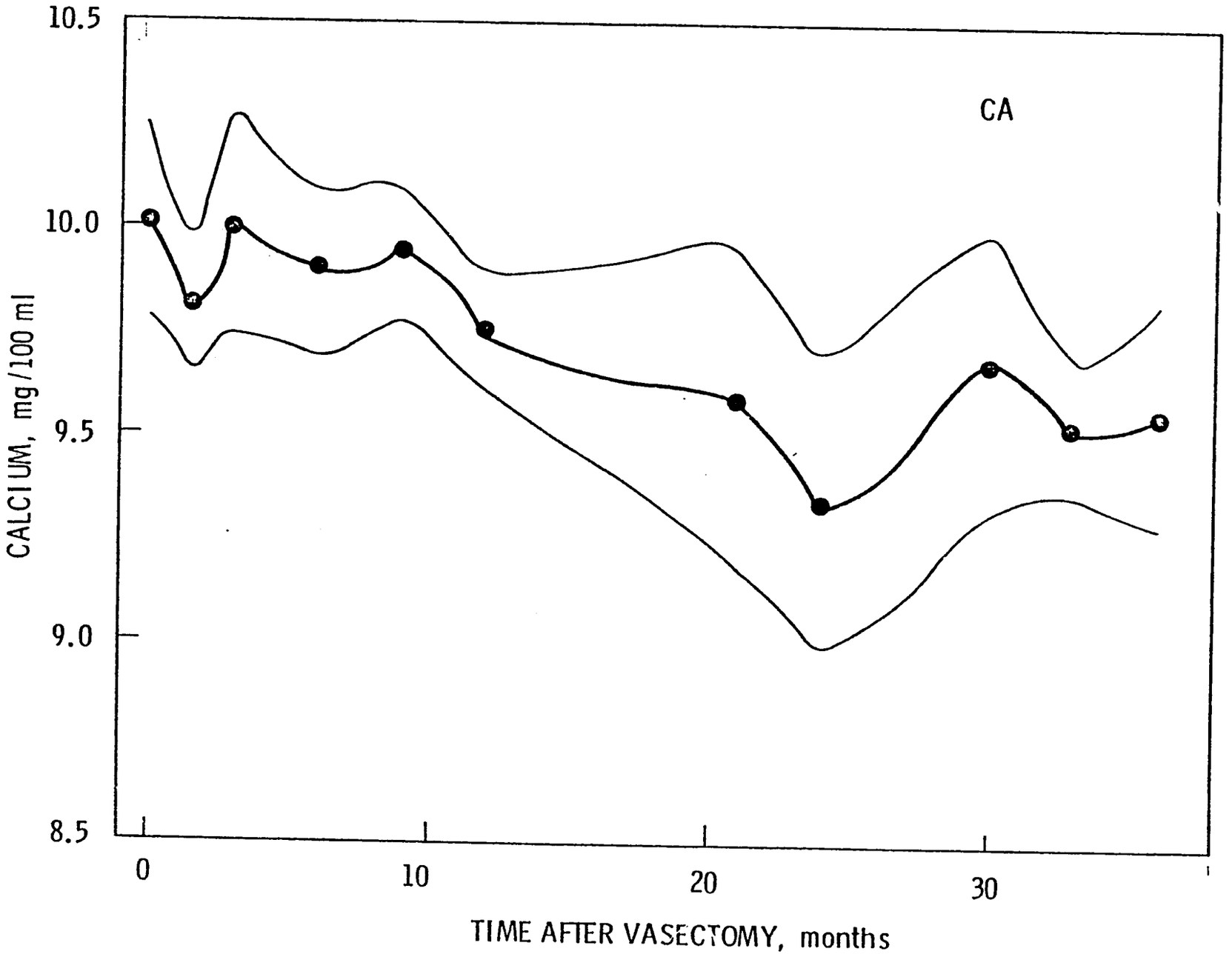

HARBORVIEW

4-36

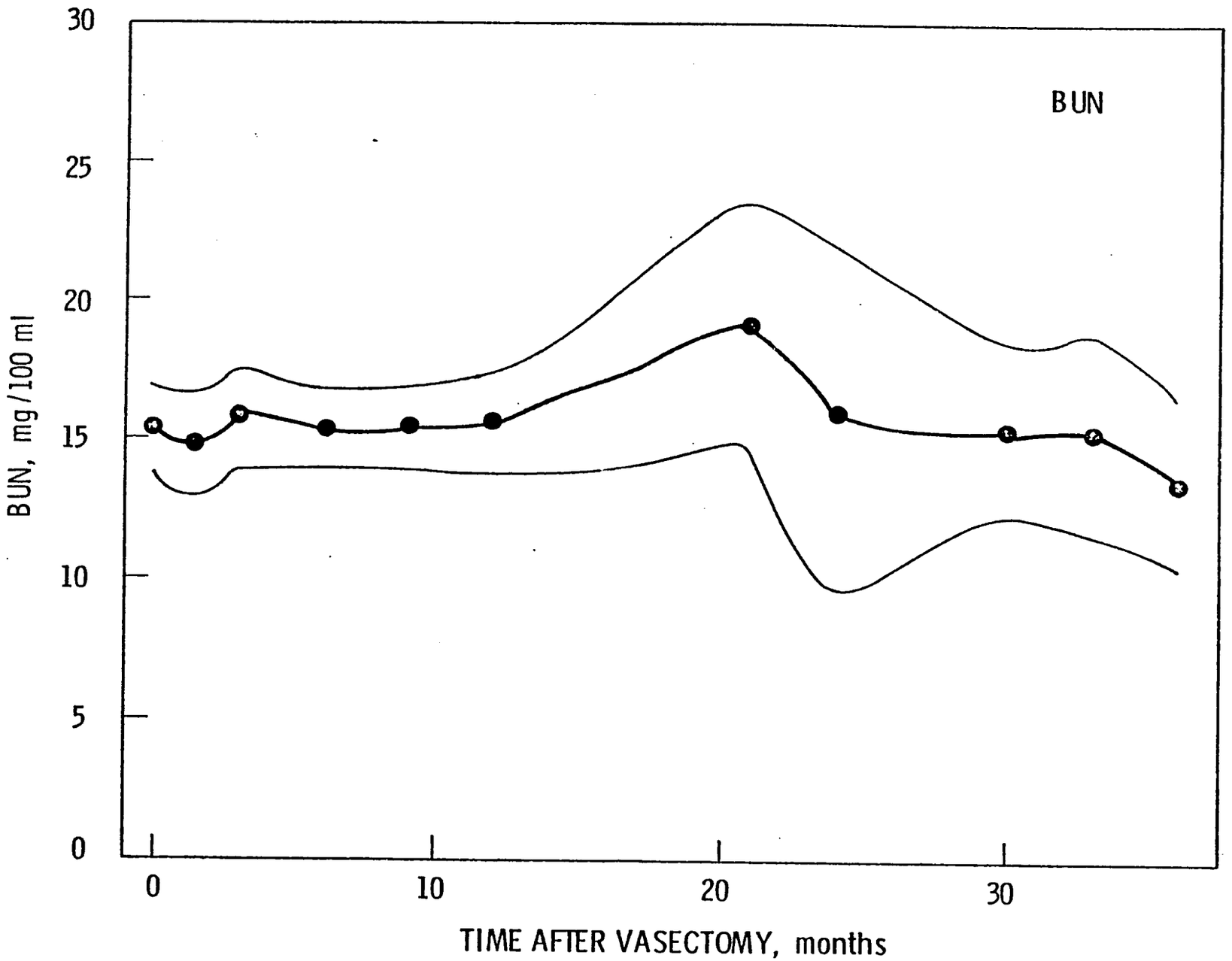
BUN
BUN, mg/100 ml
30
25
20
15
10
5
0
0
10
20
30
TIME AFTER VASECTOMY, months

HARBORVIEW

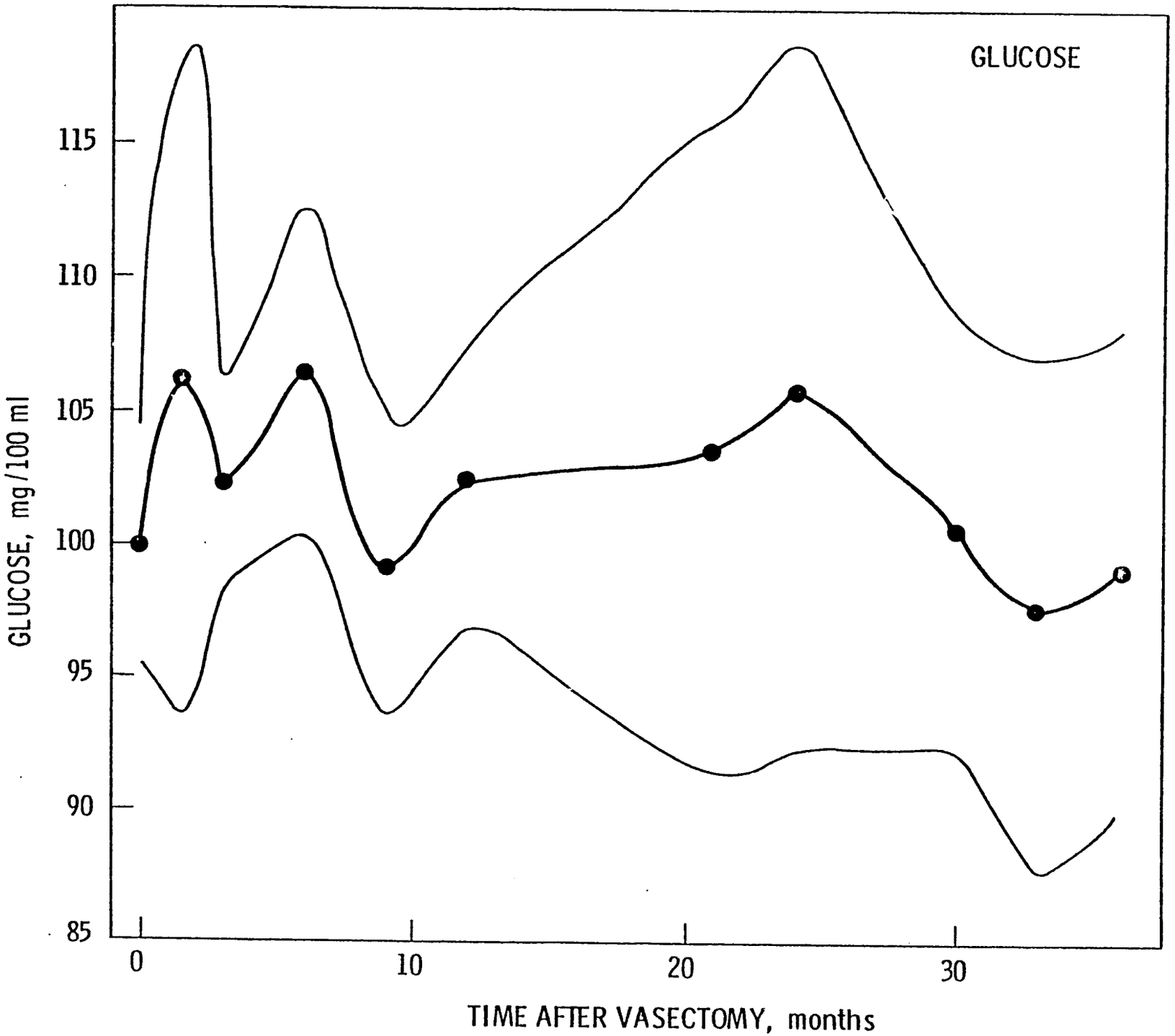

HARBORVIEW

4-38

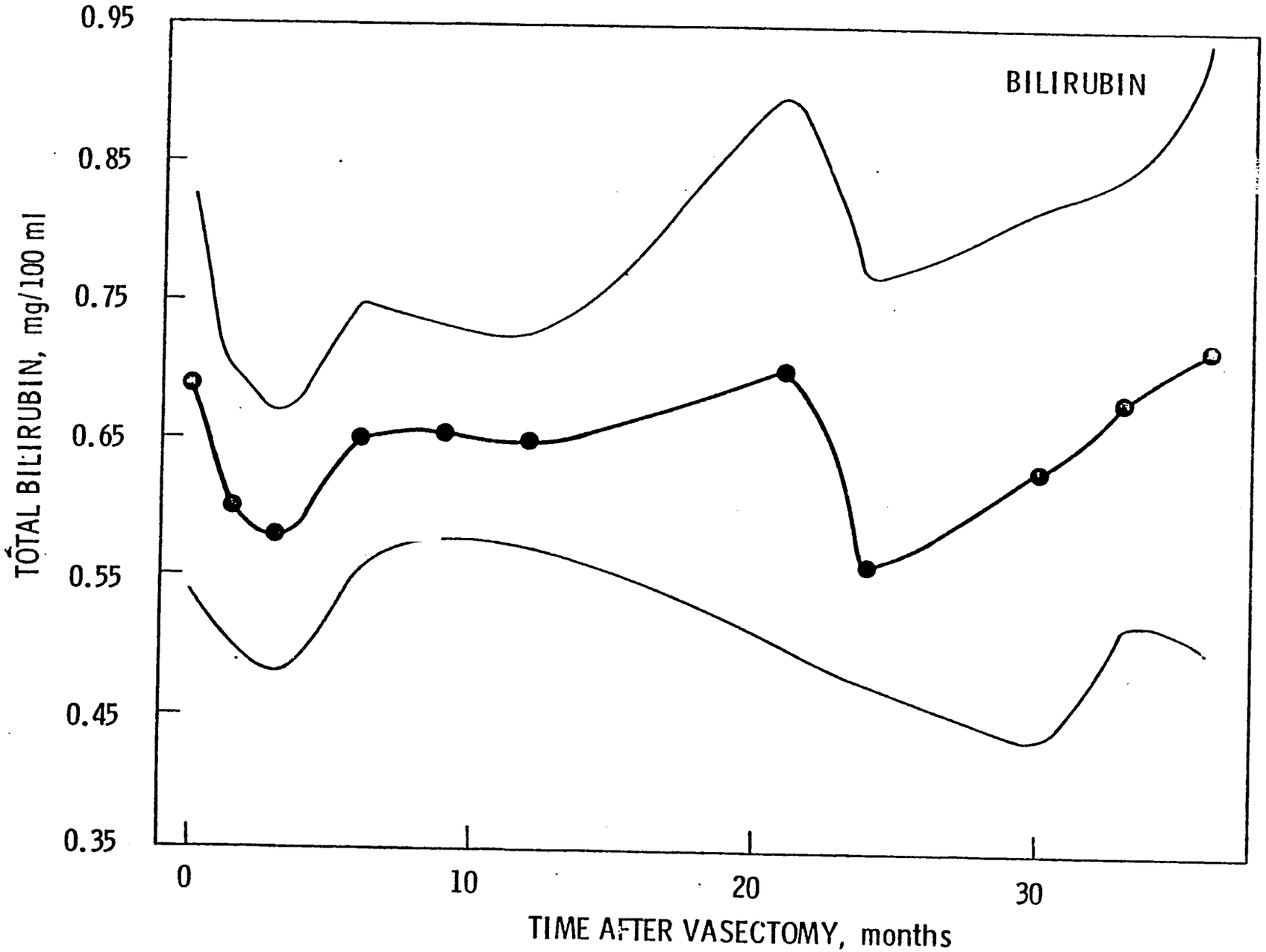

HARBORVIEW

A-39

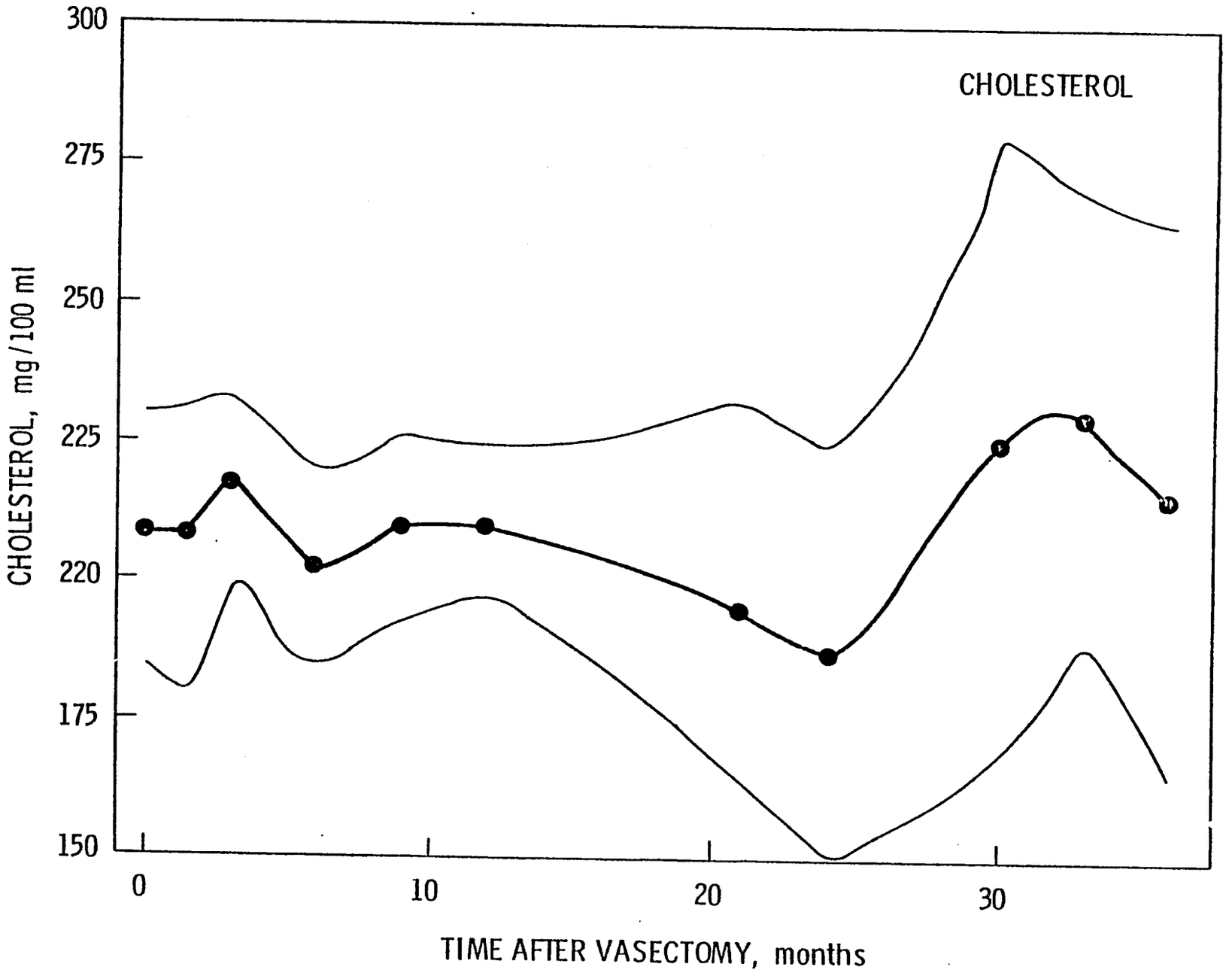
CHOLESTEROL
CHOLESTEROL, mg/100 ml
300
275
250
225
220
175
150
0
10
20
30
TIME AFTER VASECTOMY, months

HARBORVIEW

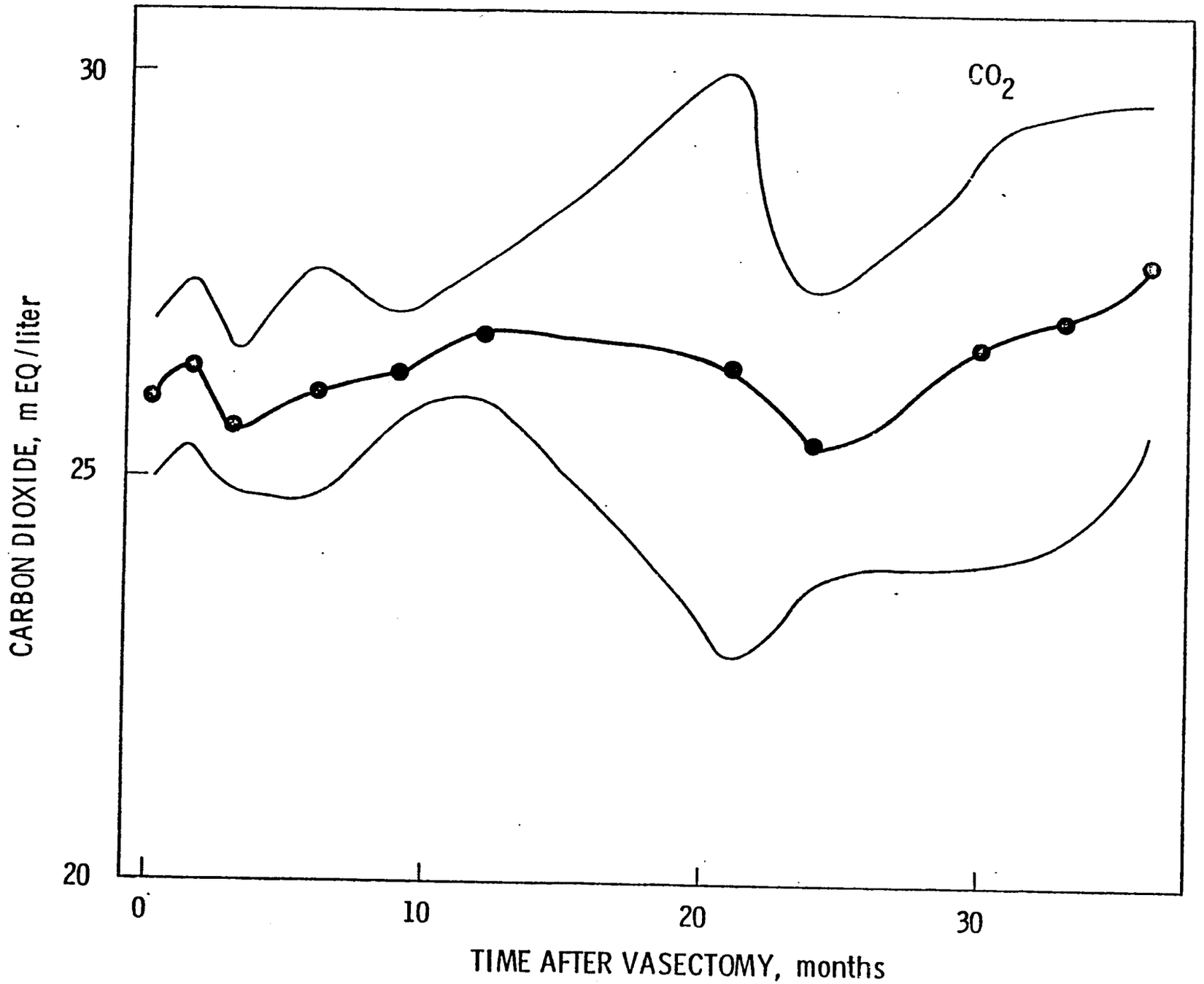

HARBORVIEW

4-41

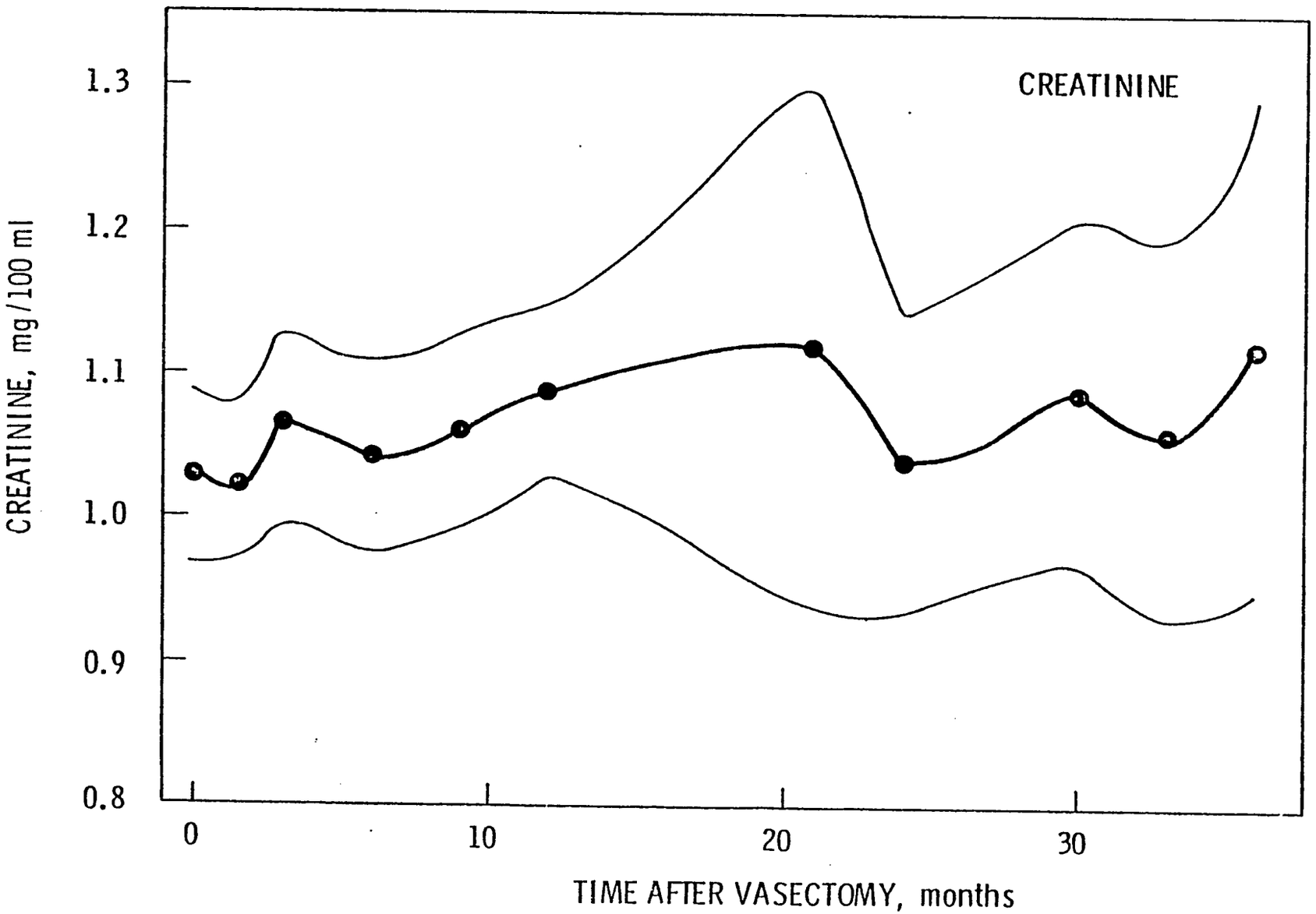
CREATININE
CREATININE, mg/100 ml
1.3
1.2
1.1
1.0
0.9
0.8
0
10
20
30
TIME AFTER VASECTOMY, months

HARBORVIEW