Combination Thin and Thick Blood Films for the Detection of *Babesia* Parasitemia

John P. Bishop, D.V.M., Ph.D., and L. Garry Adams, D.V.M., Ph.D.

SUMMARY

A method for preparing and examining combination thin and thick blood films for the detection of *Babesia* spp. parasitemias was developed. A technique for staining the combination thin and thick films, using a phosphate-buffered Giemsa stain solution containing alkyl phenoxy polyethoxy ethanol (APPE), was also described.

During acute bovine babesiasis, the parasitemia can be detected by examining stained thin blood films. In cattle surviving the acute stage of the disease and becoming carriers, *Babesia* spp. are not readily demonstrable in thin blood films, however, a thick blood film method for detecting *Babesia* parasitemia was described by Mahoney and Saal[2] that facilitated the examination of a greater quantity of blood.

For the diagnosis of malaria in man, a method for the preparation and staining of combination thin and thick blood films was developed.[1] It seemed that a similar method might prove advantageous for the detection of the parasitemia in cattle affected with acute and chronic babesiasis. The method which evolved is described and some results of this application reported.

Received for publication March 7, 1973.

From the Departments of Veterinary Microbiology and Veterinary Pathology, Institute of Tropical Veterinary Medicine, College of Veterinary Medicine, Texas A&M University, College Station, Texas 77843. Dr. Bishop's present address is the National Agricultural Research Institute, Department 24, Quevedo, Ecuador, South America.

Supported by the U.S. Agency for International Development, the Rockefeller Foundation, and the Colombian Agricultural Institute.

The authors thank Miss Nubia Carvajal for technical assistance.

Materials and Methods

Preparation of Combination Thin and Thick Blood Films.—The blood films were made with samples of bovine blood obtained from the jugular vein, using disodium ethylenediaminetetraacetate (1 Gm./L.) as anticoagulant. For the preparation of the thin blood film, a small drop of blood was placed on one end of a microscopic slide and extended over ½ the length of the slide and rapidly air-dried. The method used for the preparation of the thick blood film was based on a technique described by Mahoney and Saal.[2] A loop (2.5 mm., external diameter) was used to deliver a standard drop of blood on the end of the same microscope slide opposite the thin blood film. The loop was made by twisting 30-gauge wire (taken from flyscreen gauze) tightly around a 14-gauge hypodermic needle. After the remaining blood on the loop was blotted on a clean paper towel, the loop was used to spread the drop evenly over an area of 28 sq. mm. which was outlined by a circle 6 mm. in diameter on a paper underneath the microscope slide. Before use on the next blood sample, the loop was rinsed in water and then in absolute methanol which was allowed to evaporate. The thick blood films were then dried in a horizontal position. Initial drying was hastened by placing the slides near a 150-watt incandescent lamp.

The thin blood films were then fixed with absolute methyl alcohol. The slides were held in a slanted position with the thin blood film down and a few drops of absolute methanol were placed on the thin blood film only. To prevent alcohol or alcohol fumes from contacting the thick blood film, the slides were placed in a vertical position with the thick blood film up until the methanol evaporated. The slides were then placed in a staining rack[a] and kept at this state for further processing.

Before staining, the slides were placed in an incubator at 65 C. for 45 minutes for final drying of the thick blood films. Final drying was required to ensure that the thick blood films did not detach during the staining process. To prevent deterioration of the thick blood films, the combination thin and thick blood films were stained soon after final drying.

Staining of the Combination Thin and Thick Blood Films.—The method used for the staining of the combination thin and thick blood films was based on a staining technique described for *Plasmodium* spp. in man. The thin and thick blood films, prepared and placed in staining racks, as described in the preceding topical paragraph, were stained in a 1:50 solution of Giemsa stain[b] for 45 minutes. Phosphate-buffered water (pH 7.0–7.1) containing 0.01% APPE[c] was used to prepare the stain solution. Stock solutions of 0.067 *M* NaH_2PO_4, 0.067 *M* Na_2HPO_4, and 10% APPE were prepared and kept in separate glass-stoppered bottles. Fresh buffered water (pH 7.0 to 7.1) containing 0.01% APPE was prepared each week by using 39 ml. of 0.067 *M* NaH_2PO_4.

[a] Staining Rack Model S7680, Scientific Products, Division of American Hospital Supply Corporation, Evanston, Ill.

[b] Giemsa stain, Gradwohl Laboratories, St. Louis, Mo

[c] Triton X-100, Rohm and Haas, Philadelphia, Pa.

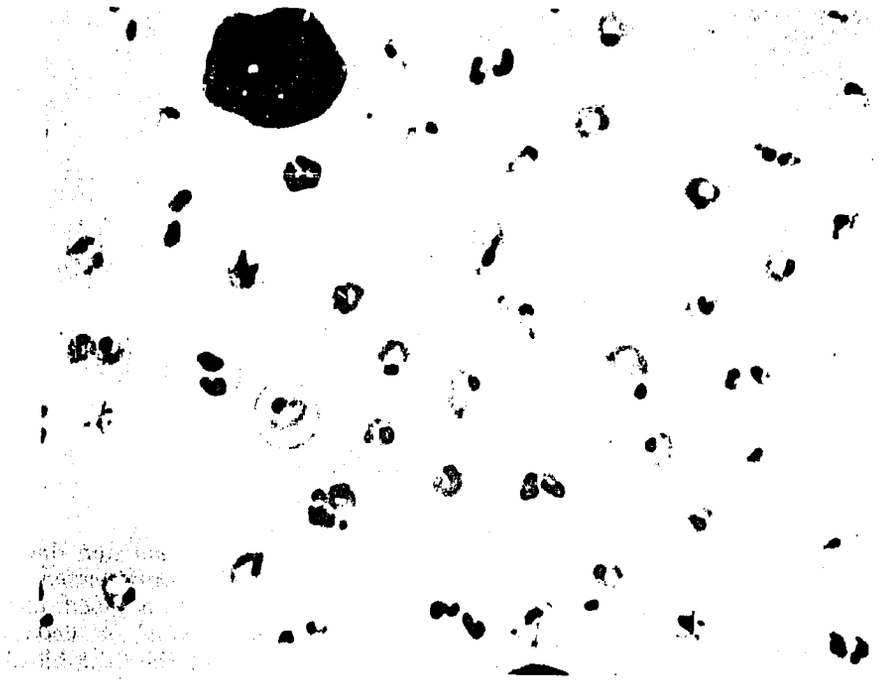

Fig. 1—*Babesia bigemina* parasitized bovine erythrocytes in a thin blood film. Giemsa stain; × 1,330.



Fig. 2—*Babesia bigemina* parasites in a thick bovine blood film. Giemsa stain; × 1,330.

61 ml. of 0.067 *M* Na_2HPO_4, 1 ml. of 10% APPE, and 899 ml. of distilled water. An electric pH meter[d] was used to determine the pH of the freshly prepared buffered water containing APPE.

Immediately following staining, the thin and thick blood films were rinsed briefly by dipping the slides in a staining dish filled with buffered water (pH 7.0 to 7.1) containing 0.01% APPE. A rubber band was placed around the staining rack to hold the slides in place. The staining rack was placed in a vertical position with only the thick blood film immersed in the same buffered water containing APPE for an additional 3 to 5 minutes. The slides were then air dried in the vertical position with the thick film down.

[d] Beckman Expandomatic Model 76, Scientific Instruments Division, Beckman Instruments, Inc., Fullerton, Calif.

Results and Discussion

The use of a 1:50 solution of Giemsa stain provided osmotic pressures that caused lysis of the unfixed erythrocytes in thick blood films during the 45 minutes' staining. Therefore, the usual morphologic criteria for differential identification of parasites based on differences in size and in position in the erythrocyte are not applicable to thick blood films. The use of the surface-active agent APPE in the staining and washing solutions resulted in brighter and cleaner preparations with only parasites, leukocytes, and blood platelets remaining in the thick blood films.

The use of buffered (pH 7.0 to 7.1) Giemsa stain solution provided the most dependable differential staining of the parasite (deep blue cytoplasm and a brilliant red nucleus). For confirmation of *Babesia* parasitemia on thick blood films, it was necessary to resolve the objects under examination into a red nucleus and blue cytoplasm and to find some paired parasites that were typically pyriform. The depth of the thick blood film allowed organisms to lie in any plane which caused some distortion from the typical appearance of the parasites seen in thin films. The typical pairs could, however, be readily recognized, even when some distortion occurred. Photographs of *Babesia bigemina* on thin and thick films are shown (Fig. 1 and 2).

An estimate of the number of parasites per cubic millimeter of blood on thick blood films could be made from the number of parasites and leukocytes seen in 20 microscopic fields (using × 10 ocular and × 100 oil objective) and from the number of leukocytes per cubic millimeter of blood. The number of parasites per cubic millimeter of blood was then converted to the percentage of erythrocytes from the number of erythrocytes per cubic millimeter of blood.

References

1. Anon.: Manual for the Laboratory Diagnosis of Parasitic Diseases. II. Blood Parasites 8010-C. Parasitology Training Unit, National Communicable Disease Center, Atlanta, Ga. (1970): 32–34.
2. Mahoney, D. F., and Saal, J. R.: Bovine Babesiosis: Thick Blood Films for the Detection of Parasitemia. Austral. Vet. J., 37, (Feb., 1961): 44–47.