Advancement of Rwandan Rehabilitation Services Project

in partnership with

A Therapeutic Exercise Approach to Problems of the Extremities Course

Acknowledgements

This training manual is made possible by the generous support of the American people through the United States Agency for International Development (USAID). The contents are the responsibility of Health Volunteers Overseas and do not necessarily reflect the views of USAID or the United States Government.

The pictures included in this manual are for educational use in the ARRSP course sessions and may not be reproduced in any format pending copyright.

Health Volunteers Overseas gratefully acknowledges the work of HVO Volunteer Linn Harding, MA, PT, OCS in developing, teaching, and modifying the course, “A Therapeutic Exercise Approach to Treating Problems of the Extremities.”

Mr. Harding was assisted in the teaching of the course by HVO Volunteer Frances Markovic, PT as well as Rwandan co-teachers Juliette Gasana, PT and Philippe Niyobuhungiro, Msc-PT.

A Therapeutic Exercise Approach to Problems of the Extremities Course

Table of Contents

Session 1..... 1

Shoulder..... 21

Session 2..... 47

Hip..... 50

Knee..... 71

Session 3..... 89

Hand & Wrist..... 91

Session 4..... 146

Foot & Ankle..... 148

Instructor's Manual..... 210

Advancement of Rwandan Rehabilitation Services Project

Therapy Course
Session One

HVO ADVANCEMENT OF RWANDAN REHABILITATION SERVICES PROJECT
CONTINUING PROFESSIONAL DEVELOPMENT COURSES

Therapeutic Exercise and Clinical Decision Making for the Extremities: Content

Introductions
Course Participant Expectations
Pre/Post Course Assessment

- ICF Terms
- Patient Specific Functional Scale
- Group Activity: ICF Terms and Patient Specific Functional Scale
- Group Activity: Types of Muscle Contraction
- Lecture: Shoulder Anatomy and Kinesiology
- Practical: Shoulder Evaluation
- Lecture: Principles of Exercise Selection
- Practical: Patient Cases Using Therapeutic Exercise
- Class Discussion of Patient Cases Using Therapeutic Exercise
- Practical: Progression of Patient Cases Using Therapeutic Exercise
- Class Discussion of Patient Cases Using Therapeutic Exercise
- Practical: Progression of Patient Cases Using Therapeutic Exercise
- Class Discussion of Patient Cases Using Therapeutic Exercise
- Lecture: Manual Therapy Techniques (Optional)
- Practical: Manual Therapy Techniques (Optional)

Homework Assignment
Course Evaluation

HEALTH VOLUNTEERS OVERSEAS

ADVANCEMENT OF RWANDAN REHABILITATION SERVICES PROJECT
CONTINUING PROFESSIONAL DEVELOPMENT COURSES

EXPECTATIONS of COURSE PARTICIPANTS

1. Attend and participate in class sessions one weekend a month (two days) for the duration of the course.
2. Arrive on time to each class session and return from tea break and lunch at the designated time.
3. Do not use cell phones in class.
4. Strive to have appropriate patients scheduled to evaluate and/or treat when the course instructors do clinical visits with you.
5. Turn in homework assignments on time.
6. Participate in class discussions.
7. Use lab time to practice newly taught techniques.
8. Practice new techniques in your clinical setting.
9. Develop a plan to share the material you have learned with other professionals.
10. Use newly learned skills in your practice after the course is over.

You will earn one CPD unit for every hour that you attend the course, and each fully completed homework assignment is worth two CPD units.

HEALTH VOLUNTEERS OVERSEAS
ADVANCEMENT OF RWANDAN REHABILITATION SERVICES PROJECT
CONTINUING PROFESSIONAL DEVELOPMENT COURSES

Pre/Post Course Assessment

Date:_____

Did you attend any of the previous, spinal courses with Dr. Toni? Please circle one:

A. Yes I did attend Dr. Toni's Spinal Course.
B. No, I did not attend any of Dr. Toni's spinal courses.

All questions are multiple choice. Please circle one answer only for each question.

Questions 1 – 5 are based on the following patient-care story:

Your patient tells you it is very difficult to take care of her infant grandchildren because knee pain prevents her from climbing the stairs into their home and she is unable to bend her knee enough to get up and down from the floor. On physical exam you find active knee flexion is 0-65 degrees with 6/10 pain at end of range.

After 4 weeks of therapy, once a week for manual therapy and instruction in a home exercise program, she demonstrates 100 degrees flexion with 3/10 pain at end of range. The family has also built a handrail on the stairs.

Because of her increased knee function and the newly installed handrail your patient is now able to care for her grandchildren. You're still working with your patient to help her get up and down from the floor.

1. Restricted knee flexion (0-65 degrees) is best described as
   A. an impairment
   B. an activity
   C. a participation restriction

2. Manual therapy during your physiotherapy sessions is best described as
   A. a barrier
   B. an intervention
   C. an activity
   D. participation

3. Stair climbing is best described as
   A. an impairment
   B. an activity
   C. participation

4. Building a handrail is an example of
   A. an intervention to decrease an activity limitation
   B. modification of a barrier
   C. an intervention to decrease impairment
   D. both A and B above

5. If, after 12 weeks of physiotherapy emphasizing manual therapy and active exercise, your patient is demonstrating no further gains in knee function and appears to have reached maximum benefit from therapy, which course of action makes the most sense?
   A. Continue with the current plan of care another 4 weeks.
   B. Discharge the patient and let them know you can be of no further help
   C. Consider changing your focus from the impairment to the activity
   D. None of the above

Questions 6 through 9 refer to The Patient Specific Functional Scale (PSFS)

6. Using a written test to measure your patient's level of disability is important because it
   A. measures your patient's progress
   B. identifies goals
   C. helps you decide if your intervention is working
   D. provides valuable data for research
   E. All of the above

7. The PSFS grades the degree of activity limitation on a scale of
   A. Mild, Moderate, or Severe limitation
   B. percent activity limitation from zero percent to 100 percent limitation
   C. zero to five
   D. none of the above

8. The activities to be scored for the PSFS are determined by
   A. the patient
   B. the WHO Functional Disability Index
   C. the Rwandan Ministry of Health
   D. none of the above

9. The PSFS can be used as an initial measure of activity limitation as well as a measurement of functional outcome during the course of treatment.
   A. True
   B. False

Questions 10 through 20 refer to concepts of Therapeutic Exercise

10. Joint instability is best treated with
    A. eccentric contraction at end of range.
    B. isometric contraction in mid-range.
    C. high speed contraction throughout the entire range of motion.
    D. maximum contraction in the unstable position.

11. If rotator cuff tendons are irritated and painful, the best choice for your first session is to
    A. decrease the stress on the tendons and relieve the inflammation.
    B. strengthen the tendons even though it is painful.
    C. identify abnormal biomechanics and begin correcting this.
    D. A and C but not B.

12. Eccentric muscle contraction is defined as a contraction in which the muscle
    A. shortens.
    B. lengthens.
    C. does not change length because there is no joint movement.
    D. All of the above are true

13. Isometric muscle contraction is defined as a contraction in which the muscle
    A. shortens.
    B. lengthens.
    C. does not change length because there is no joint movement.

14. The type of muscle contraction that may rebuild partially torn tendons is
    A. eccentric
    B. concentric
    C. isometric
    D. slow fiber

15. Rotator cuff impingement can result from
    A. a weak rotator cuff.
    B. the scapula failing to upwardly rotate during humeral elevation.
    C. excessive thoracic kyphosis.
    D. All of the above

16. To strengthen knee extension at end-range, exercise must be performed
    A. quickly.
    B. Slowly,
    C. Isometrically
    D. at end range

17. To strengthen fast-twitch muscle fibers, the exercise must be performed
    A. using fast fibers.
    B. throughout the entire range of motion.
    C. isometrically.

18. Rehabilitation of an unstable, chronic ankle sprain must focus on increasing
    A. A. ankle strength.
    B. proprioception of the foot and ankle.
    C. stability of the foot and ankle.
    D. All of the above.

19. If knee extension is full passively but lacks 10 degrees actively, the problem could be
    A. hamstring weakness.
    B. quadriceps weakness.
    C. tibiofemoral hypomobility
    D. All of the above

20. The advantage of closed chain exercises for lower extremity rehab is
    A. it is more functional than open chain.
    B. the lower extremity normally functions in closed chain.
    C. open chain biomechanics increase the risk of injury.
    D. all of the lower extremity joints are more stable in closed chain.
    E. All of the above are true.

Language:

Let's Communicate

What's the Problem?

- Impairment
- Activity Limitation

Impairment

Biology, Anatomy

Measured in Objective Exam

- Muscle strength
- ROM
- Tenderness

Activity Limitation

Performing a Functional Task

"I can't Dance"

Measured during Subjective Exam

PSFS or similar Assessment Tool

Let's Fix It

Intervention

Impairment: Change the Biology

Decrease the Impairment

- Maybe we can fix it
- Maybe we can't

Decrease the Activity Limitation

- Activity Modification
- Assistive Device
- Adaptive Equipment
- Reducing Barriers

What's interfering with Function?

- Impairment ➔ disability
- Activity Limitation➔ disability

Many Thanks

To WHO

and the

ICF Development Team

For creating a common international language

Measuring Function & Progress

The Patient –Specific Functional Scale

Ask the Patient

- Three Activities she/he is having difficulty with

How Much Difficulty?

- Rate the Difficulty Zero to Ten
- Zero = No Difficulty
- Ten = Impossible

Put a Number on it

- Add the Scores for the Three Activities
- Convert to a Percentage
- 5+6+4 = 15
- 15/30 x 100% = 50%
- In this example, the PSFS score is 50%
- For these activities, the patient is 50% disabled

Patient-Specific Functional Scale (PSFS)

Patient Name: _____ Date:_____

Diagnosis: _____

Please list three activities that are difficult for you because of the condition we are treating .

Activity 1: _____

0-------1-------2-------3-------4-------5-------6-------7-------8-------9-------10
No Difficulty — Moderate Difficulty — Impossible

Activity 2: _____

0-------1-------2-------3-------4-------5-------6-------7-------8-------9-------10
No Difficulty — Moderate Difficulty — Impossible

Activity 3: _____

0-------1-------2-------3-------4-------5-------6-------7-------8-------9-------10
No Difficulty — Moderate Difficulty — Impossible

Total Score: Activity 1+ Activity 2 + Activity 3 = _____ x 100 =_____ percent disability
Divided by: 30

Patient-Specific Functional Scale (PSFS]

Patient Name: _____ Date:_____

Diagnosis: _____

Please list three activities that are difficult for you because of the condition we are treating .

Activity 1: _____

0---------1---------2---------3---------4--------5---------6--------7---------8---------9---------10
No DifficultyDifficulty Moderate Impossible

Activity 2: _____

0---------1---------2---------3---------4--------5---------6--------7---------8---------9---------10
No Difficulty Moderate Difficulty Impossible

Activity 3: _____

0---------1---------2---------3---------4--------5---------6--------7---------8---------9---------10
No Difficulty Moderate Difficulty Impossible

Total Score: Activity 1+ Activity 2 + Activity 3 = _____ x 100 =_____ percent disability
Divided by: 30

Use of ICF Terms and the Patient Specific Functional Scale

Group Activity: Your group will be assigned one of the following cases. For that case:

- Complete the Patient Specific Functional Scale (PSFS).
- List all relevant Impairments.
- List all relevant Activity Restrictions.
- Write one impairment-related goal.
- Write one functional, activity-related goal.

Case Number One: Rotator Cuff Tendonitis.
Patient: 37 y/o laborer. Left Shoulder Impingement Syndrome with RC Tendinitis. Shoulder pain prevents sleeping through the night, driving, and from performing his usual job. On exam, AROM is full in all planes with a painful arc from 80 to120 degrees elevation. Resisted ER and ABD are painful.

Case Number Two: Complete Tear of Tendon.
Patient: 75 y/o Right-handed Female, Full Thickness right RC Tear. Elevation of R UE is limited to 50 degrees due to weakness. She is unable to reach her hair or dress herself using the right arm. Shoulder pain interferes with sleep.

Case Number Three:
Patient: 20 y/o right-handed basketball player with chronic anterior dislocation of right shoulder. Shoulder pain interferes with sleep, reaching for objects behind himself, and prevents him from throwing a ball. AROM is full in all planes with pain at end range ER, flexion and ABD. Shoulder pain is reproduced with isometric contraction of Biceps Long Head.

Case Four:
Patient: 39 y/o female with adhesive capsulitis of right shoulder. Shoulder pain and stiffness interferes with sleep, hair care, and dressing. Active elevation is 120 degrees, abduction is 90 degrees, ER 20 degrees. All movements are painful at end range.

Use of ICF Terms and the Patient Specific Functional Scale Practical Activity

Case Number:_____

1. **Please complete the Patient-Specific Functional Scale for your patient.** The numbers for degree of difficulty are not given in the case descriptions, so please choose an appropriate number to complete the PSFS.

2. **Please list all known Impairments in the space below:**

3. **Please list all known Activity Limitations in the space below:**

4. **Please write one Impairment-related goal in the space below:**

5. **Please write one Functional activity-related goal in the space below:**

Clinical Use of Therapeutic Exercise

Some Principles of Exercise Selection

What are we trying to do?

- Anatomically: what is the Impairment?

  Examination tells us this.

Decreasing the Impairment

- Weakness
- Stiffness/ Hypomobiity
- Instability
- Dyskinesia
- Combination

Impairment: Weakness

- Identify Weak Muscles
- Where in the ROM?
- Concentric, Eccentric, Isometric?
- Open or Closed chain?
- Fast Fibers Needed?

Impairment: Weakness

How Much Resistance?

To Fatigue.

Impairment: Stiffness

- Passive or Active ?
- Where in the ROM?

Impairment: Instability

- Which Muscles?
- Slow Fibers or Fast?
- Where in the ROM?
- Concentric, Eccentric, Isometric?
- Open Chain or Closed Chain?

Impairment: Dyskinesia

- Weakness?
- Tightness/stiffness?
- Instability?
- Neurological?

Exercise Progression

- Start Safe
- Slow
- In a Protected Range
- Light Resistance

Practical Activity: Therapeutic Exercise Skills

Pair up and perform each of the following types of muscular contraction. Change roles so both of you perform all contraction types. These are the building blocks of an effective exercise program.

I. Types of Resistance Training/Strengthening Exercise

A. Active Resisted ROM, full range
Definition: Movement against Resistance
Clinical Indications: Weakness

Using manual resistance demonstrate:
1. Humeral ER/IR.
2. PNF diagonal Pattern of flexion, ABD, ER/extension, ADD, IR.

B. Active Resisted, mid-range Exercise
Definition: Movement against Resistance
Clinical Indications: Weakness, Instability

Using manual resistance demonstrate:
1. Humeral ER/IR.
2. PNF diagonal Pattern of flexion, ABD, ER/extension, ADD, IR.

C. ActiveResisted, end-range Exercise
Definition: Movement against Resistance
Clinical Indications: Weakness, Stiffness

Using manual resistance demonstrate:
1. Humeral ER/IR.
2. PNF diagonal Pattern of flexion, ABD, ER/extension, ADD, IR.

D. Isometric Exercise
Definition: Muscular contraction, no movement
Clinical Indications: Weakness, Instability, pain with movement

Using manual resistance demonstrate:
1. Isometric contraction midrange Humeral ER/IR
2. Isometric midrange contraction of biceps long head

E. Eccentric Exercise

Definition: Muscle lengthening against resistance
Clinical Indications: Weakness, Tendon Tears

Using manual resistance demonstrate:

1. Eccentric exercise of Biceps Long Head
2. Eccentric exercise of humeral external rotation

F. Fast fiber (high speed) Exercise

Definition: High speed muscular contraction
Clinical Indications: Need for rapid, powerful movement

Using manual resistance demonstrate:

1. Fast fiber PNF diagonal Pattern of flexion, ABD, ER/extension, ADD, IR.

G. Closed chain Exercise

Definition: Distal extremity fixed
Clinical Indications: weakness, instability, altered mechanics

1. Demonstrate closed chain scapular protraction/retraction

H. Neuromuscular Re-education for Dyskinesia

Definition: Well-controlled movements emphasizing accuracy and precision
Clinical Indications: Scapular Dyskinesia

The Shoulder Girdle

Review of Anatomy and Kinesiology

VIDEOS:

3D Anatomy Tutorial – Glenohumeral Joint

Anatomy and Kinesiology Review

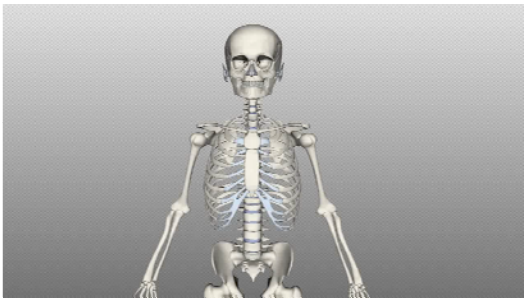

3D Anatomy Tutorial - Rotator Cuff

Scapulohumeral Rhythm

www.cpdo.com.au - Scapulohumeral Rhythm

Accessory Motions

- Accessory Motions Occurring Along with Physiological Motions.
- Accessory Motions are Necessary in order for Physiological Motions to Occur
- Manual Therapy to Restore Accessory Motion is often Necessary to regain Physiological Motion

Pairing of Physiological and Accessory Motions at the GH Joint

Physiological Motion of Humerus	Accessory Motion
External Rotation	Posterior Glide of Humeral Head
Internal Rotation	Anterior Glide of Humeral Head
Elevation	Inferior Glide of Humeral Head

Other Accessory Motions Needed for GH Mobility

- Long Axis Distraction
- Lateral Distraction

Shoulder Girdle

Evaluation and Intervention

Is it Really the Shoulder?

- Viscera?
- Cervical Spine?

Maybe it's not the Shoulder's Fault

If not, look closely and identify the cause

- Is the Thoracic Spine Moving well?
- Is the Scapula Moving well?

Evaluation: Let's Figure it Out!

1. Subjective Examination, including PSFS
2. Glenohumeral Exam
3. Thoracic Spine and Scapular Exam

Subjective Exam

Determines What Tests You Will Do

- Obtain complete Hx
- Complete PSFS

Glenohumeral Exam: Practical

Observation Only in Standing

- **Standing Posture**
  - Head Position
  - Scapular Position
  - Thoracic Kyphosis
  - Sulcus Sign?

AROM All Planes

- Flexion
  - Total Range of Motion
  - Thoracic Contribution
  - Scapular Motion. Repeat with 2Kg weight
  - Pain?
    - End Range?
    - Painful Arc?

Abduction

- Total ROM

Scapular Motion. Repeat with 2 Kg weight

- Pain?
  - End range
  - Painful Arc

Does Humerus ER?

IR & ER

- IR reaching up Spinous Processes
- ER with hands behind head, elbows out

Acromioclavicular Shear Test

Tall Patients may need to sit

Palpation in Standing

- Acromioclavicular Joint
- Greater Tuberosity
  - Supraspinatus Tendon
  - Infraspinatus Tendon
- Lesser Tuberosity
  - Subscapularis
- Biceps Long Head Tendon

Contractile Tests: Pain or Weakness

- ER
- IR
- Biceps Long Head
- Supraspinatus (Empty Can Test)

Scapular Assistance Test

- Perform the Scapular Assistance Test

Observation Only in Supine

- Supine Posture
  - Head Position
  - Shoulder Position
- Breathing Pattern: Diaphragm or Chest?
- AROM in elevation

Palpation and Testing in Supine

- PROM All Planes, Note End-feel

The Shoulder Girdle

Manual Therapy Techniques

Accessory Motions

- Accessory Motions Occurring Along with Physiological Motions.
- Accessory Motions are Necessary in order for Physiological Motions to Occur
- Manual Therapy to Restore Accessory Motion is often Necessary to regain Physiological Motion

Pairing of Physiological and Accessory Motions at the GH Joint

Physiological Motion of Humerus	Accessory Motion
External Rotation	Posterior Glide of Humeral Head
Internal Rotation	Anterior Glide of Humeral Head
Elevation	Inferior Glide of Humeral Head

Other Accessory Motions Needed for GH Mobility

- Long Axis Distraction
- Lateral Distraction

Grades of Movements

I..... I

Grade I: Small movement in early range

I I

Grade II: Large Movement in midrange

I I

Grade III: Large movement to end range

I I

Grade IV: Small Movement at endrange

Which Grade to Use?

- Grade I and II for decreasing pain, gaining Patient Trust.
- Grades III and IV for increasing mobility.

Using Joint Mobilization

- Must define which surface is moving and which surface it is moving on.
- Must define the direction of movement
- Must Define the Grade of Movement

Practical: Perform the Following

Lateral Distraction of the humerus from the Glenoid. Performed in anatomical position

- Grade I Lateral Distraction
- Grade II Lateral DIstraction

Practical

Grade I Posterior Glide of Humeral Head on Glenoid, combined with LAD.

Grade II Posterior Glide of Humeral Head on Glenoid, combined with LAD.

Grade IV Posterior Glide of Humeral Head on Glenoid, combined with LAD.

Deep Friction Massage (DFM):
Increases mobility of adhered tissues

- Must be anatomically accurate
- Direction is perpendicular to fibers
- Tendon must be on slight stretch
- Perform for 30 seconds

Supraspinatus Tendon

Patient sitting, hand In back pocket

Infraspinatus Tendon

Patient prone on elbows, humerus adducted, and externally rotated

Physiotherapy Diagnosis

- Based on Subjective Exam
- And Objective Exam

Impingement with RC Tendonitis, Scapular Dyskinesis, Thoracic Hypomobility

Exam Finding	Diagnosis
Painful Arc	Impingement
Contractile Test	Tendonitis
Scapular Assistance	Scapular Dyskinesis
Observation	Thoracic Hypomobility

Adhesive Capsulitis

Exam Finding	Diagnosis
↓ AROM ABD, ER, Flexion, IR	
↓ PROM ABD, ER, Flexion, IR	
Capsular End-feel	
	Adhesive Capsulitis

Acromioclavicular Sprain

Exam Finding	Diagnosis
Pain in elevation 90 – 180	
Pain with AC Palpation	
Positive AC Shear Test	
	AC Sprain

Patient Cases for Therapeutic Exercise Practical

Case Number One: Rotator Cuff Tendonitis
Patient: 37 y/o laborer. Left Shoulder Impingement Syndrome with RC Tendinitis.

S: Shoulder pain prevents Pt. from sleeping through the night and from performing his usual job. Pain intensity is 8/10.Symptoms have been present for 8 weeks and increasing in intensity the past 2 weeks.

O: On exam there is bilateral scapular protraction at rest. AROM is full in all planes with a painful arc from 80 to120 degrees elevation, poor scapular rotation and thoracic hypomobility noted during UE elevation. Pain reduced with scapular assistance test. Resisted ER and ABD are painful. Tenderness to palpation of supraspinatus and infraspinatus tendons. Pain intensity 8/10 during exam.

A: Acute impingement of supra and infraspinatus tendons, scapular protraction, scapular dyskinesis, thoracic hypomobility are contributing factors.

P:

Case Number Two: Anterior Instability, Recurrent Dislocation
Patient: 20 y/o right-handed basketball player with chronic anterior dislocation of right shoulder.

S: Shoulder pain interferes with sleep and prevents the patient from throwing a ball. Hx of multiple dislocations since age 17. Symptoms and activity restrictions have been increasing. Currently afraid to play ball.

O: Biceps Long Head and ABD contractile tests are positive for pain reproduction. Pain is also reproduced at end-range elevation and end-range ER. AROM is full in all planes but patient is cautious in ER. Posture and thoracic mobility are WNL. There is no evidence of generalized ligamentous laxity.

A: Chronic anterior glenohumeralinstability with recurrent dislocation.

P:

Case Number Three: Adhesive Capsulitis (Frozen Shoulder)
Patient: 39 y/o female grocery clerk with adhesive capsulitis of right shoulder.

S: Right shoulder pain and stiffness first noticed about 6 months ago and getting worse. Shoulder pain now interferes with sleep. Unable to reach her hair or fasten clothing in back. Symptoms are aggravated by working cash register from a seated position at work, reaching overhead or reaching into cabinets.

O: Active elevation is 120 degrees; abduction is 90 degrees, ER 20 degrees with end-range pain in all planes. Resisted Contractile tests are all negative. PROM same as AROM. Postural exam demonstrated mild forward head and shoulders.

A: Adhesive capsulitis with postural component.

P:

Patient Cases for Therapeutic Exercise Practical

These are the same patients after 2 weeks of physiotherapy. The therapeutic exercise program has been working and we need to progress our exercises accordingly. Indicate in the space provided what you will do for exercise during the session. Also write in the plan what you will do for the next few sessions.

Case Number One: Rotator Cuff Tendonitis
Patient: 37 y/o laborer. Left Shoulder Impingement Syndrome with RC Tendinitis.

S: Improving. Sleeping through most nights. Still not able to perform his usual job. Pain intensity is 4/10 at worst. Doing home exercise program and icing the shoulder daily.

O: Demonstrates HEP properly. Painful arc from 80 to100 degrees elevation, scapular rotationand thoracic mobility improved. Pain eliminated with scapular assistance test. Resisted ER and ABD are mildly painful. Pain intensity 2/10 during exam.

Ther ex:

A: Improving. Decreased irritability, Pt is following home program.

P:

Case Number Two: Anterior Instability, Recurrent Dislocation
Patient: 20 y/o right-handed basketball player with chronic anterior dislocation of right shoulder.

S: Doing HEP and icing daily. Ice decreases pain. Still having trouble sleeping.Since you told him not to try playing ball, he hasn't.

O: Demonstrates HEP.

Ther ex:

A: Demonstrates HEP properly. Progressing

P:

Case Number Three: Adhesive Capsulitis (Frozen Shoulder)
Patient: 39 y/o female grocery clerk with adhesive capsulitis of right shoulder.

S: Doing home exercise program and putting ice on the shoulder. Shoulder still hurts but it is moving a little better. Previous treatment with you helped. Still not able to sleep on shoulder or use it for reaching.

O: Demonstrates HEP. Active elevation is 135 degrees; abduction is 100 degrees, ER 40 degrees with end-range pain in all planes. No pain with resisted ER or ABD. Resisted IR still mildly painful.

Ther Ex:

A: Improving

P:

Patient Cases for Therapeutic Exercise Practical

These are the same patients after 4 weeks of physiotherapy. The therapeutic exercise program has been working and we need to progress our exercises accordingly. Indicate in the space provided what you will do for exercise during the session. Please include the home exercise program in your plan.

Case Number One: Rotator Cuff Tendonitis
Patient: 37 y/o laborer. Left Shoulder Impingement Syndrome with RC Tendinitis.

S: Improving. Sleeping well. Doing most of his job but avoiding difficult, overhead positions. Pain intensity is 2/10 at worst. Doing home exercise program and icing the shoulder daily.

O: Demonstrates HEP properly. Full elevation with slight pain (1/10) at 90 degrees. Scapular rotation and thoracic mobility are improved. No pain with 2.5 kilograms resistance to ER and ABD. Mild pain with maximum strength resistance ABD and ER.

Ther ex:

A: Continues to improve, ready for RC strengthening. Pt is doing home program.

P:

Case Number Two: Anterior Instability, Recurrent Dislocation
Patient: 20 y/o right-handed basketball player with chronic anterior dislocation of right shoulder.

S: Doing HEP and icing daily. Ice decreases pain. Sleeping without pain.Still hasn't tried playing ball.

O: Demonstrates HEP.

Ther ex:

A: Demonstrates HEP properly. Progressing. Able to tolerate more vigorous stabilization exercises.

P:

Case Number Three: Adhesive Capsulitis (Frozen Shoulder)
Patient: 39 y/o female grocery clerk with adhesive capsulitis of right shoulder.

S: Doing home exercise program and putting ice on the shoulder. Shoulder still hurts but it is moving a little better. Previous treatment with you helped. Still not able to sleep on shoulder or use it for reaching.

O: Demonstrates HEP. Active elevation is 145 degrees; abduction is 110 degrees, ER 50 degrees with end-range pain in all planes. No pain with resisted ER or ABD. Resisted IR still mildly painful.

Ther Ex:

A: Primary adhesive capsulitis. Improving

P:

Worksheet for Therapeutic Exercise Practical

Clinical decision making for Impairment-based Exercise Interventions:
You are to design a therapeutic exercise program for your patient. Please answer the following questions in the space provided:

Patient Number:_____

1. Identify which tissues you are treating with your exercise interventions.

2. State the physiological effect the exercise will have on these tissues.

3. State the muscle or muscle groups you will include in your intervention and the type of contractions you will use. Explain your reasoning.

4. In what part of the range will you be exercising this patient? Explain your reasoning.

5. Describe and be prepared to demonstrate at least one of your therapeutic exercises.

6. Write short-term and long-term goals for this patient.

Worksheet for Manual Therapy Practical

Clinical decision making for Impairment-based Manual Therapy Interventions:
You are to design a manual therapy program for your patient. Please answer the following questions in the space provided.

Case Number:_____

1. Identify which tissues you are treating with your interventions.

2. State the physiological effect the manual techniques will have on these tissues.

3. State the grade of mobilization will you employ with this patient. Explain your reasoning.

4. State the direction of mobilization will you employ with this patient? Explain your reasoning.

5. Describe and be prepared to demonstrate at least one of your manual techniques.

Patient Cases for Manual Therapy Practical

Patients One and Three are good candidates for Manual Therapy Interventions

Case Number One: Rotator Cuff Tendonitis
Patient: 37 y/o laborer. Left Shoulder Impingement Syndrome with RC Tendinitis.

S: Improving. Sleeping well. Doing most of his job but avoiding difficult, overhead positions. Pain intensity is 2/10 at worst. Doing home exercise program and icing the shoulder daily.

O: Demonstrates HEP properly. Full elevation with moderate pain (3/10) at 90 degrees. Scapular rotation and thoracic mobility are improved. Mild pain with resisted ABD and ER.

A: Patient has progressed well. It appears the involved tendons may be adhered to the synovium. These techniques are to release adhered tendons.

Manual therapy Technique:

- Deep Friction Massage (DFM) to Supraspinatus Tendon (Patient sitting with Hand in back pocket)

- Deep Friction Massage (DFM) to Infraspinatus Tendon (Patient Prone on Elbows with Adduction, ER)

Case Number Three: Adhesive Capsulitis (Frozen Shoulder)
Patient: 39 y/o female grocery clerk with adhesive capsulitis of right shoulder.

S: Doing home exercise program and putting ice on the shoulder. Shoulder hurts less andstiffness is the primary concern. Previous treatment with you helped.

O: Demonstrates HEP. Active elevation is 145 degrees; abduction is 110 degrees, ER 50 degrees with end-range pain in all planes. No pain with resisted tests.

A: Irritability is low now and stiffness is the primary concern so grade 3 and 4 techniques are indicated.

Manual therapy Technique:

- Posterior Glide of Humeral Head on Glenoid, Grade IV with LAD.

- Posterior Glide of Humeral Head on Glenoid, Grade III with LAD.

Homework Assignment:

Please choose one patient and use this form to gather information on that patient. Please do not include the patient's name. Please bring this form back with you next month and be prepared to discuss the case. You receive 2.0 CPD units for completion of this homework assignment. Thank you.

Your Name:_____

Date assignment is completed:_____

Patient Diagnosis:_____

Briefly describe the subjective and objective exam:

S:

O:

1. Please bring a completed Patient Specific Functional Scale for this patient. Do not include the patient's name.

2. Identify the major Impairments and Activity Limitations for this patient.

3. Identify which tissues you are treating with your exercise interventions.

4. State the physiological effect the exercise have on these tissues.

5. Please describe the exercise program you used with this patient. Include a detailed description including:
    - Which muscles or other tissues are involved.
    - Where in the range of motion the exercises were performed. Please explain why you chose this part of the range.
    - What type of contractions you used. Please explain why you chose this type of contraction.

6. Please describe the outcome with this patient. Use the PSFS to demonstrate the outcome. Include whether or not the exercise program was useful to you and your patient.

7. Please indicate if the material from this course was helpful to you in working with this patient. Please say why or why not.

Thank You!

Course Evaluation
EXTREMITIES COURSE

Overall, I would rate the material presented this weekend as:

excellent	good	fair	poor

Comments:

I would rate the instructors as:

excellent	good	fair	poor

Comments:

The facilities were:

excellent	good	fair	poor

Comments:

The written material was:

excellent	good	fair	poor

Comments:

The ***majority*** of the material was:

New to me	Concepts I had been introduced to in school but had not applied to the clinical setting before	A more in-depth discussion of materials already familiar with	A review

Comments:

Time given to practice new material was:

Too Much	Sufficient	Not Enough

Comments:

Did the course meet its objectives of helping you to better evaluate and treat patients?

List some things that you learned this weekend that you will use with patients next week.

How could the course be improved?

Advancement of Rwandan Rehabilitation Services Project

Therapy Course
Session Two

HEALTH VOLUNTEERS OVERSEAS

ADVANCEMENT OF RWANDAN REHABILITATION SERVICES PROJECT
CONTINUING PROFESSIONAL DEVELOPMENT COURSES

EXPECTATIONS of COURSE PARTICIPANTS

1. Attend and participate in class sessions one weekend a month (two days) for the duration of the course.
2. Arrive on time to each class session and return from tea break and lunch at the designated time.
3. Do not use cell phones in class.
4. Strive to have appropriate patients scheduled to evaluate and/or treat when the course instructors do clinical visits with you.
5. Turn in homework assignments on time.
6. Participate in class discussions.
7. Use lab time to practice newly taught techniques.
8. Practice new techniques in your clinical setting.
9. Develop a plan to share the material you have learned with other professionals.
10. Use newly learned skills in your practice after the course is over.

You will earn one CPD unit for every hour that you attend the course, and each fully completed homework assignment is worth two CPD units.

HVO ADVANCEMENT OF RWANDAN REHABILITATION SERVICES PROJECT
CONTINUING PROFESSIONAL DEVELOPMENT COURSES

Therapeutic Exercise and Clinical Decision Making for the Extremities: Content

Day One:

Lecture: Hip Anatomy and Kinesiology

Practical: Evaluation of the Hip

Practical: Patient Cases Using Therapeutic Exercise

Class Discussion of Patient Cases Using Therapeutic Exercise

Lecture: Manual Therapy Techniques for the Hip

Practical: Manual Therapy Techniques for the Hip

Day Two:

Lecture: knee Anatomy and Kinesiology

Practical: Evaluation of the Knee

Practical: Patient Cases Using Therapeutic Exercise

Class Discussion of Patient Cases Using Therapeutic Exercise

Lecture: Manual Therapy Techniques for the Knee

Practical: Manual Therapy Techniques for the Knee

Homework Assignment
Course Evaluation

Important Anatomical Structures

The Hip Joint (First Video)

Synovial Capsule

Articular surface

Acetabular Labrum

Ligaments reinforcing the joint capsule

Blood Supply to Femoral Head

Muscles of the Hip (Second Video)

Muscle Action Attachments

Gluteus Maximus

Gluteus Medius

Tensor Fascia Lata

Piriformis

ObturatorInternus

ObturatorExternus

Gemellus Superior

Gemellus Inferior

QuadratusFemoris

Iliopsoas

Rectus Femoris

Sartorius

Nerves: Sciatic Nerve and Femoral Nerve

The Hip

What Makes the Hip Difficult?

Hip Interacts With Other Regions

Lumbar Spine

Sacroiliac Joint

Pubes

Pelvic Floor, Genitourinary

Reproductive

Lower Abdominal Structures

Biomechanical Interactions

- The Knee
- Tibiofemoral Joint
- Patellofemoral Joint
- The Foot and Ankle

What Else Makes it Difficult?

Many Structures are very Deep

Palpation is Difficult or Impossible

Visual Exam is Often Unreliable

Contractile Tests Less reliable

May Refer Pain to the Knee

Joint Structures

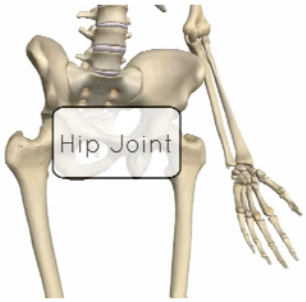

VIDEOS:

3D Anatomy Tutorial – Hip Joint

Muscles of the hip

Muscles of the Thigh & Gluteal Region – Anatomy Tutorial Pt 1

Practical: Examination of the Hip

AROM all Planes: Patient Supine

PROM all Planes Note End Feel

Active Extension in Prone
Test Extension strength in this position

Anteversion, Retroversion

- Craig's Test
- Patient is Prone
- 90 degrees knee flexion
- Position Greater Trochanter Laterally
- Measure Hip Rotation

Muscle Tightness

- Thomas Test
- for Tight Rectus Femoris
- for Tight Iliopsoas

Patient is supine, hip over edge of table
Contralateral hip flexed to end range
Observe resting position of tested hip

Ober's Test: Iliotibial Band Tightness

- Sidelying, Tested side up
- Flex, Abduct the hip
- Bring hip into End Range Extension
- Stabilize the pelvis
- Release the hip and Observe resting position
- This is a good time to manual muscle test Gluteus Medius

Testing Articular Structures

- Quadrant, scour test
- Patient is supine
- Hip is passively flexed to 90 degrees
- Long Axis Compression
- Moved through flexion, IR, ADD
- Crepitus and pain are positive signs

Palpation

- Greater Trochanter
- ASIS (anterior superior iliac spine)
- AIIS (anterior inferior iliac spine)

- Ischial Tuberosity
- Sacrotuberous Ligament
- Piriformis
- Sciatic Nerve

Common Impairments and Diagnoses of the Hip

Weakness of Gluteus Medius

Tightness of ITB / TFL
(iliotibial band/tensor fascia lata)

Trochanteric Bursitis

Weakness of Gluteus Maximus

Tightness of Iliopsoas and Rectus Femoris

Iliopectineal bursitis

Anterolateral Contusion

- Meralgia Paraesthetica

(Entrapment or Irritation of the Lateral Femoral Cutaneous Nerve)

Myositis Ossificans

Hamstring Tightness

- Hamstring Syndrome
  Entrapment of Sciatic Nerve
- Ischial Bursitis

Piriformis Syndrome

- (entrapment of Sciatic Nerve)
- Sacroiliac Joint Dysfunction
- Pubic Symphysis Dysfunction

Slipped Capital Femoral Epiphysis

9 to 15 year old
Hx of Trauma or Femoral Compression

Sudden onset Hip or Knee Pain

Positive Drehmann's Sign
(obligatory ER with passive hip flexion)

Degenerative Joint Disease

Capsulitis

Capsular Pattern is variable
but will include limited IR
ER may be normal

Femoral Fracture

- Highly Variable

Avascular Necrosis of Femoral Head (AVN)

Total Joint Replacement

- Precautions and Progression is Per Protocol

MANUAL THERAPY FOR THE HIP to Increase Extension

. LONG AXIS DISTRACTION (LAD)

. PA Glides

PT IS PRONE

- POSITION HIP AT END RANGE EXTENSION
- Neutral Rotation

- PERFORM GRADED LAD
- PA Glide

Lateral and Caudal Glide to Increase Flexion

- Patient is supine

- Position hip at end range flexion
  45 degrees lateral
  Repeat 45 degrees caudal

Piriformis Lengthening

- Patient is Supine
- Maximum passive elongation of Piriformis
- (Flexion, Adduction, IR)
- Perform Contract/Relax at end-range

ITB Lengthening

- ITB Test Position
- Myofascial Release of ITB

Examination of the Hip
Patient Cases

Case One: Dx is Gluteus Medius Weakness, ITB Tightness, Trochanteric Bursitis. 48 year-old male with Right lateral hip pain that interferes with sleep, running, and stair climbing.

Perform the following procedures and tests with your lab partner:

O: 1. Observe Trendelenburg Gait due to gluteus medius weakness

2. Positive Ober's Test due to tight ITB

3. Palpation tenderness of trochanteric bursa

A: Impairments: Gluteus Medius Weakness, ITB Tightness, Trochanteric Bursitis

P: **Develop and Demonstrate a therapeutic exercise program for this patient.**

1. Three exercises for strengthening gluteus medius

2. Two exercises for increasing the mobility of the TFL/ITB

3. Perform at least one manual therapy technique for this patient.

Case Two: Dx is Gluteus Maximus Weakness, Iliopsoasand Rectus FemorisTightness, Iliopectineal Bursitis. 48 Year old female with left hip and groin pain that interferes with sitting, running, and driving.

Perform the following procedures and tests with your lab partner:

O: 1. Observe supine bridge or other test to detect gluteus maximus strength

2. Thomas Test to detect tight iliopsoas and rectus femoris

3. Resisted hip flexion to detect iliopectineal bursitis

A: Impairments: Gluteus Maximus Weakness, Iliopsoas Tightness, Iliopectineal Bursitis

P: Develop and Demonstrate a therapeutic exercise program for this patient.

1. Three exercises for strengthening gluteus maximus

2. Two exercises for elongating Iliopsoas and Rectus Femoris

3. Perform at least one manual therapy technique for this patient.

Case Three: Dx is Hamstring Syndrome, Hamstring Tightness, Ischial Bursitis. 32 Year old male with Right buttock and posterior thigh pain that interferes with sitting, running, and sleep.

Perform the following procedures and tests with your lab partner:

O: 1. Positive contractile test of hamstring in straight leg raise (SLR) position

2. Limited SLR due to tight hamstrings

3. Palpation tenderness of ischialbursa

A: Impairments: Sciatic nerve entrapment, Hamstring tightness, IschialBursitis

P: **Develop and Demonstrate a therapeutic exercise program for this patient.**

1. Two exercises for lengthening hamstrings

2. One technique for increasing the mobility of the Sciatic Nerve

3. Perform at least one manual therapy technique for this patient.

4. Demonstrate one self-care technique for relieving the Ischial Bursitis.

Case Four: Dx is Piriformis Syndrome, Sacroiliac Joint Dysfunction. 42 Year old female with Low back, right buttock, posterior thigh, and groin pain that interferes with sleep, walking, running, and sitting.

Perform the following procedures and tests with your lab partner:

O: 1. Reproduction of buttock pain with piriformis contraction at end range.

2. Reproduction of sacroiliac pain with PA mobilization of the SI joint

A: Impairments: Piriformis syndrome, SI joint dysfunction.

P: Develop and Demonstrate a therapeutic exercise program for this patient.

1. One exercise for lengthening Piriformis

2. One home exercise for the SI joint

3. Perform at least one manual therapy technique for this patient.

Case Five: Dx is one week post Anterior Thigh Contusion with Meralgia Paraesthetica, Myositis Ossificans. 27 Year old male with Right Anterolateral hip pain and numbness that interferes with sleeping and walking.

Perform the following procedures and tests with your lab partner.

O: 1. Reproduction of anterolateral thigh pain with test of Lateral Femoral Cutaneous nerve

A: Impairments: Contusion, Meralgia Paraesthetica, Myositis Ossificans

P: Develop and demonstrate a therapeutic exercise program for this patient.

1. One manual technique to mobilize the lateral Femoral Cutaneous nerve

2. One home exercise to mobilize the lateral Femoral Cutaneous nerve

3. State two precautions when dealing with Myositis Ossificans.

4. Perform at least one manual therapy technique for this patient.

Case Six: Dx is 16 weeks post ORIF for Right Femoral Neck Fracture with persistent hip and groin pain aggravated by weight bearing. Possible AVN.

Perform the following procedures and tests with your lab partner.

O: 1. Joint Scouring test for articular surface dysfunction

2. Assess Active and Passive ROM for capsular limitation

A: Impairments: 16 weeks Post ORIF, possible Avascular Necrosis of Femoral Head

P: What is the appropriate action to be taken with this patient?

1. Perform at least one manual therapy technique for this patient.

Worksheet for Therapeutic Exercise Practical

Clinical decision making for Impairment-based Exercise Interventions:
You are to design a therapeutic exercise program for your patient.
Please answer the following questions in the space provided.

Patient Number:_____

1. Identify which tissues you are treating with your exercise interventions.

2. State the physiological effect the exercise will have on these tissues.

3. State the muscle or muscle groups you will include in your intervention and the type of contractions you will use. Explain your reasoning.

4. In what part of the range will you be exercising this patient? Explain your reasoning.

5. Describe and be prepared to demonstrate at least one of your therapeutic exercises.

6. Write short-term and long-term goals for this patient.

Worksheet for Manual Therapy Practical

Clinical decision making for Impairment-based Manual Therapy Interventions:
You are to design a manual therapy program for your patient.
Please answer the following questions in the space provided.

Case Number:_____

1. Identify which tissues you are treating with your interventions.

2. State the physiological effect the manual techniques will have on these tissues.

3. State the grade of mobilization will you employ with this patient. Explain your reasoning.

4. State the direction of mobilization will you employ with this patient? Explain your reasoning.

5. Describe and be prepared to demonstrate at least one of your manual techniques.

Homework Assignment:

Please choose one patient and use this form to gather information on that patient. Please do not include the patient's name. Please bring this form back with you next month and be prepared to discuss the case. You receive 2.0 CPD units for completion of this homework assignment. Thank you.

Your Name:_____

Date assignment is completed:_____

Patient Diagnosis:_____

Briefly describe the subjective and objective exam:

S:

O:

1. Please bring a completed Patient Specific Functional Scale for this patient. Do not include the patient's name.

2. Identify the major Impairments and Activity Limitations for this patient.

3. Identify which tissues you are treating with your exercise interventions.

4. State the physiological effect the exercise have on these tissues.

5. Please describe the exercise program you used with this patient. Include a detailed description including:
    - Which muscles or other tissues are involved.
    - Where in the range of motion the exercises were performed. Please explain why you chose this part of the range.
    - What type of contractions you used. Please explain why you chose this type of contraction.

6. Please describe the outcome with this patient. Use the PSFS to demonstrate the outcome. Include whether or not the exercise program was useful to you and your patient.

7. Please indicate if the material from this course was helpful to you in working with this patient. Please say why or why not.

Thank You!

Patient-Specific Functional Scale (PSFS]

Patient Name: _____ Date:_____

Diagnosis: _____

Please list three activities that are difficult for you because of the condition we are treating .

Activity 1: _____

0---------1---------2---------3---------4--------5---------6--------7---------8---------9---------10
No DifficultyDifficulty Moderate Impossible

Activity 2: _____

0---------1---------2---------3---------4--------5---------6--------7---------8---------9---------10
No Difficulty Moderate Difficulty Impossible

Activity 3: _____

0---------1---------2---------3---------4--------5---------6--------7---------8---------9---------10
No Difficulty Moderate Difficulty Impossible

Total Score: Activity 1+ Activity 2 + Activity 3 = _____ x 100 =_____ percent disability
Divided by: 30

Anatomy Videos

Knee Anatomy Videos are played at this point in the classroom. Videos are publicly available online; the ones used have been identified.

The videos are:

- Basic Anatomy of the Knee & Associated Injuries – Dr. Nabil Ebraheim
- Knee Anatomy & Patellofemoral Pain Qlok www.bioskin.com
- Knee Joint – 3D Anatomy Tutorials Pts 1 & 2

Basic Palpation of the Knee

Identify and palpate the following structures:

Medial Femoral Epicondyle

Lateral Femoral epicondyle

Medial and Lateral Joint Line

Medial (Tibial) Collateral Ligament

Lateral (Fibular) Collateral Ligament

Patellar Ligament

Tibial Tuberosity

Infrapatellar Fat Pad

Superior Border of Patella, Quadriceps Tendon

Medial Patellar Retinaculum

Lateral Patellar Retinaculum

Fibular Head

Rectus Femoris

VastusLateralis

VastusMedialis and VMO

Insertion of Semimembranosis

Insertion of Biceps

PesAnserinus (Insertion of Gracilis, Sartoruius, Semi Tendinosis)

Common Diagnoses and Exam Procedures for the Knee

First: Is it really the Knee??

Hip refers pain to the knee.

Lumbar spine refers pain to the Knee (L3, 4)

If it really is the Knee, Differential Dx is essential.

AROM: Look very closely for extensor lag

PROM: Note the End-feel

Patellar Mobility

Superior Glide

Inferior Glide

Medial Glide

Lateral Glide

Joint Effusion: Hughston's Slap Test.
This is an essential test to differentiate intra-articular vs. extra-articular tissue damage. Effusion is graded 1+, 2+, 3+. See handout for definition of grades.

Ligament Tests (Joint Stability)

MCL Ligament: Palpation and Valgus Stress Test.
(performed at 10 degrees flexion)

LCL Ligament: Palpation and Varus Stress Test.
(performed at 10 degrees flexion)

Lachman's: For Anterior Instability, ACL Insufficiency
(performed in 30 degrees flexion)

Anterior Drawer: For Anterior Instability, ACL Insufficiency
(performed in 90 degrees flexion, supine or sitting)

Posterior Sag Sign: For Posterior Instability, PCL Insufficiency (Patient supine, knees flexed 90 degrees)

Posterior Drawer: For Posterior Instability, PCL Insufficiency (performed in 90 degrees flexion, supine or sitting)

Tests for Muscle Tightness:

Thomas Test: For tight Iliopsoas and or Rectus Femoris

Ober's Test: For tight ITB

SLR, Proximal Initiation for tight Hamstrings

Prone Knee Flexion for tight Quadriceps

Observation for Patellar Tracking: Maltracking Patella

McConnell's Test for Patello femoral pain Relief:

Manual Therapy Interventions:

Manual Mobilization of the Patella

Superior Glide to increase Extension

Inferior glide to increase Flexion

Manual Mobilization of the Tibia

Posterior Glide of Tibia on Femur to increase Flexion

Anterior Glide of Tibia on Femur to increase Extension

Patellar Taping

Medial Patellar Taping

Lateral Patellar Taping

Clinical Decision-Making in Physiotherapy of the Knee

The Knee is Simple
It only does Three Things
It Extends
And it Flexes
Must be stable in single leg stance

Let's Look at Extension

- If active extension is not full
- It's either stiffness or quadriceps weakness.

Stiffness

- Tibiofemoral
- Or patella can't glide superiorly

If it Can't Flex

- Tibiofemoral.
- Or the Patella isn't Gliding Inferiorly

Get it to Extend and Flex

- Then Make it stable in Single Leg Stance
- You have Succeeded.

Where is the Problem Tissue?

- It's either intra-articular
- Or it's extra-articular
- The test for effusion will tell you which
- If there is a joint effusion, the problem is intra-articular
- If there is no effusion, It's extra-articular

Patellofemoral Dysfunction

- Four Possibilities
- Tightness of lateral structures
- Quadriceps Weakness
- Hip Dyskinesia
- Excessive foot pronation

Patient Cases for the Knee

1. **Perform all tests indicated in Objective exam and be prepared to explain the rationale for doing them.**
2. **Develop therapeutic exercise and manual therapy interventions as instructed.**
3. **Please complete the Therapeutic Exercise and Manual Therapy Worksheets for your case.**

Case Number One: DX isPatellofemoral dysfunction, ITB tightness, unstable single leg stance.

S: 32 y/o female with left lateral knee pain going up and down stairs, with prolonged sitting, and walking uphill and downhill. No pain at rest.

O: 1. Ober's Test is positive for tight ITB

2. Lateral Tracking patella

3. Positive McConnel Test for pain with isometric quad contraction at 30 degrees flexion.

4. Marked instability with single leg hop.

5. Palpation tenderness of lateral patellar facet

6. No joint effusion noted

A: Patellofemoral dysfunction, ITB tightness, unstable single leg stance. Weakness of hip and knee.

P: For each impairment listed above, demonstrate an appropriate therapeutic exercise and one manual technique.

Case Number Two: Dx is 12 weeks post Proximal Tibial FX treated with POP for 8 weeks. No weight-bearing for weeks 0 to 6, partial weight bearing for weeks 6 -8.

S: 42 y/o male with right knee pain and stiffness. Pain interferes with walking, sit to stand transfers, and climbing stairs. Traumatic tibial fracture 12 weeks ago. Cast removed 4 weeks ago.

O: 1. AROM is 20 to 110 degrees flexion

2. PROM 5 to 115 degrees flexion
3. Patella is hypomobile, especially in superior glide.
4. Poor Quadriceps Contraction
5. Unable to perform right single leg stance.
6. No joint effusion noted

A: General Right lower extremity atrophy, especially quadriceps. Poor quadriceps contraction. Patellar hypomobility, tibiofemoral hypomobility, post immobilization fibrosis and atrophy.

P: For each impairment listed above, demonstrate two appropriate therapeutic exercises.

Demonstrate an appropriate manual therapy intervention for this patient.

Case Number Three: Dx is16 weeks post Patellar FX treated with POP in full extension for 12 weeks due to early malunion. Non-weight-bearing for weeks 0 to 8, partial weight-bearing for weeks 8-12.

S: 40 y/o male moto rider with left knee stiffness and pain. Stiffness interferes with walking, sitting, and climbing stairs. Traumatic patellar fracture 16 weeks ago. Cast removed 4 weeks ago.

O:

1. AROM is 5 to 35 degrees flexion
2. PROM 0 to 40degrees flexion.
3. Patella is hypomobile , especially in inferior glide
4. Unstable single leg stance on left
5. No joint effusion noted

A: General left lower extremity atrophy. Patellar fibrosis and hypomobility, tibiofemoral hypomobility, post immobilization fibrosis and atrophy.

P: **For each impairment listed above, demonstrate two appropriate therapeutic exercises.**

Demonstrate an appropriate manual therapy intervention for this patient.

Case Number Four: Dx is left MCL sprain, probable medial meniscal tear

S: 24 y/o male with left knee pain stiffnessafter injury in football game 3 weeks ago. Pain with walking on uneven surfaces, and with certain knee movement. Unable to run or play football.

O: 1. Antalgic gait protecting left lower extremity

2. 2+ effusion left knee

3. Valgus Stress test positive for pain reproduction and moderate MCL laxity

4. Varus Stress test negative

5. Lachman's and Anterior Drawer negative

6. Posterior Drawer negative

7. AROM 10 to 115 with pain at end range extension

8. PROM 0 to 120 with pain at end range extension

9. Unable to perform left single leg stance due to pain

A: MCL strain, probable meniscal tear, 2+ joint effusion

P: <u>For each impairment listed above, demonstrate two appropriate therapeutic exercises.</u>

<u>Demonstrate an appropriate self care intervention for this patient.</u>

Case Number Five: Dx is Degenerative Joint Disease (DJD), left knee.

S: 62 y/o female with left knee pain stiffness . Symptoms have been present for about 2 years but have been increasing in recent months. Uses a walking stick when symptoms increase. Pain is worse with walking, especially on uneven surfaces or on stairs. Difficult to get shoe on left foot due to pain and stiffness of knee. Does not interfere with sleep.

O: 1. Antalgic gait protecting left lower extremity

2. 2+ effusion left knee

3. AROM 10 to 110 degrees flexion

4. PROM 0 to 115 degrees flexion

5. Patellar mobility is normal.

6. All ligamentous tests of the knee WNL

A: DJD with 10 extensor lag. Quadriceps weakness.

P: <u>For each impairment listed above, demonstrate two appropriate therapeutic exercises</u>.

<u>Demonstrate an appropriate self care intervention for this patient.</u>

Worksheet for Therapeutic Exercise Practical

Clinical decision making for Impairment-based Exercise Interventions:
You are to design a therapeutic exercise program for your patient.
Please answer the following questions in the space provided.

Patient Number:_____

1. Identify which tissues you are treating with your exercise interventions.

2. State the physiological effect the exercise will have on these tissues.

3. State the muscle or muscle groups you will include in your intervention and the type of contractions you will use. Explain your reasoning.

4. In what part of the range will you be exercising this patient? Explain your reasoning.

5. Describe and be prepared to demonstrate at least one of your therapeutic exercises.

6. Write short-term and long-term goals for this patient.

Worksheet for Manual Therapy Practical

Clinical decision making for Impairment-based Manual Therapy Interventions:
You are to design a manual therapy program for your patient.
Please answer the following questions in the space provided.

Case Number:_____

1. Identify which tissues you are treating with your interventions.

2. State the physiological effect the manual techniques will have on these tissues.

3. State the grade of mobilization will you employ with this patient. Explain your reasoning.

4. State the direction of mobilization will you employ with this patient? Explain your reasoning.

5. Describe and be prepared to demonstrate at least one of your manual techniques.

Patient-Specific Functional Scale (PSFS]

Patient Name: _____ Date:_____

Diagnosis: _____

Please list three activities that are difficult for you because of the condition we are treating .

Activity 1: _____

0---------1---------2---------3---------4--------5---------6--------7---------8---------9---------10
No DifficultyDifficulty Moderate Impossible

Activity 2: _____

0---------1---------2---------3---------4--------5---------6--------7---------8---------9---------10
No Difficulty Moderate Difficulty Impossible

Activity 3: _____

0---------1---------2---------3---------4--------5---------6--------7---------8---------9---------10
No Difficulty Moderate Difficulty Impossible

Total Score: Activity 1+ Activity 2 + Activity 3 = _____ x 100 =_____ percent disability
Divided by: 30

Homework Assignment:

Please choose one patient and use this form to gather information on that patient. Please do not include the patient's name. Please bring this form back with you next month and be prepared to discuss the case. You receive 2.0 CPD units for completion of this homework assignment. Thank you.

Your Name:_____

Date assignment is completed:_____

Patient Diagnosis:_____

Briefly describe the subjective and objective exam:

S:

O:

1. Please bring a completed Patient Specific Functional Scale for this patient. Do not include the patient's name.

2. Identify the major Impairments and Activity Limitations for this patient.

3. Identify which tissues you are treating with your exercise interventions.

4. State the physiological effect the exercise have on these tissues.

5. Please describe the exercise program you used with this patient. Include a detailed description including:
    - Which muscles or other tissues are involved.
    - Where in the range of motion the exercises were performed. Please explain why you chose this part of the range.
    - What type of contractions you used. Please explain why you chose this type of contraction.

6. Please describe the outcome with this patient. Use the PSFS to demonstrate the outcome. Include whether or not the exercise program was useful to you and your patient.

7. Please indicate if the material from this course was helpful to you in working with this patient. Please say why or why not.

Thank You!

Course Evaluation
EXTREMITIES COURSE

Overall, I would rate the material presented this weekend as:

excellent	good	fair	poor

Comments:

I would rate the instructors as:

excellent	good	fair	poor

Comments:

The facilities were:

excellent	good	fair	poor

Comments:

The written material was:

excellent	good	fair	poor

Comments:

The ***majority*** of the material was:

New to me	Concepts I had been introduced to in school but had not applied to the clinical setting before	A more in-depth discussion of materials already familiar with	A review

Comments:

Time given to practice new material was:

Too Much	Sufficient	Not Enough

Comments:

Did the course meet its objectives of helping you to better evaluate and treat patients?

List some things that you learned this weekend that you will use with patients next week.

How could the course be improved?

Advancement of Rwandan Rehabilitation Services Project

Therapy Course
Session Three

HEALTH VOLUNTEERS OVERSEAS

ADVANCEMENT OF RWANDAN REHABILITATION SERVICES PROJECT
CONTINUING PROFESSIONAL DEVELOPMENT COURSES

EXPECTATIONS of COURSE PARTICIPANTS

1. Attend and participate in class sessions one weekend a month (two days) for the duration of the course.
2. Arrive on time to each class session and return from tea break and lunch at the designated time.
3. Do not use cell phones in class.
4. Strive to have appropriate patients scheduled to evaluate and/or treat when the course instructors do clinical visits with you.
5. Turn in homework assignments on time.
6. Participate in class discussions.
7. Use lab time to practice newly taught techniques.
8. Practice new techniques in your clinical setting.
9. Develop a plan to share the material you have learned with other professionals.
10. Use newly learned skills in your practice after the course is over.

You will earn one CPD unit for every hour that you attend the course, and each fully completed homework assignment is worth two CPD units.

Anatomy Videos

Tutorial videos of the elbow, wrist and hand are played at this point in class. Videos are publicly available online and the ones used have been identified.

The videos are:

- eOrthopod.com – Anatomy of the Elbow – Animation – Everything You Need to Know
- eOrthopod.com - Anatomy of the Elbow Joint
- eOrthopod.com - Anatomy of the Hand

Intrinsic Hand Anatomy and Common Diagnoses

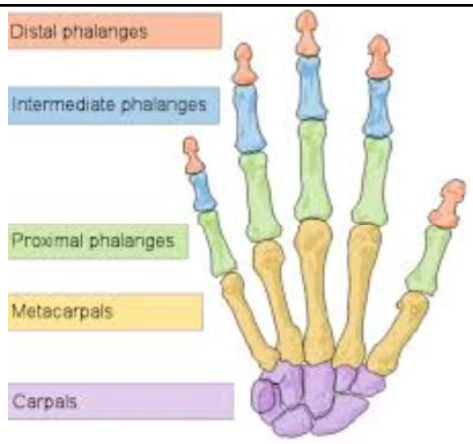

Terms

- Metacarpophalangeal Joint =MP joint
- Proximal Interphalangeal Joint = PIP Joint
- Distal Interphalangeal Joint = DIP Joint
- Interphalangeal Joint = IP Joint

Intrinsic Muscles and Extensor Mechanism

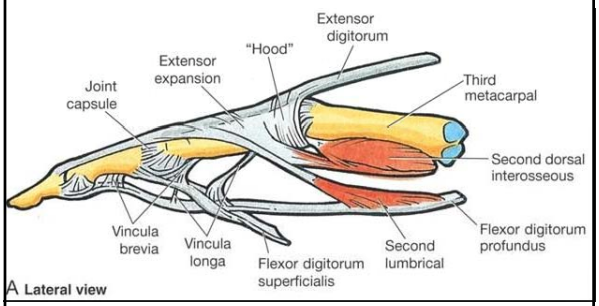

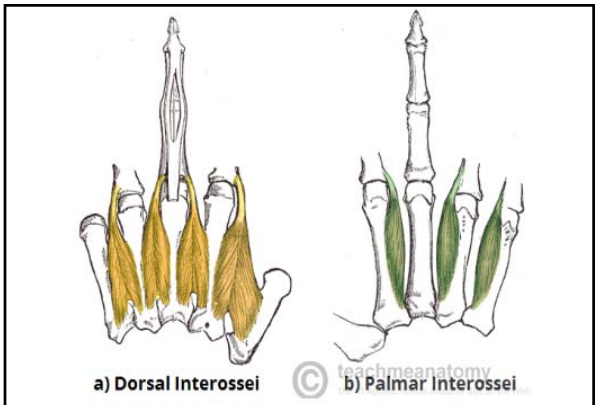

Fig 1.3 – The dorsal and palmar interossei of the hand.

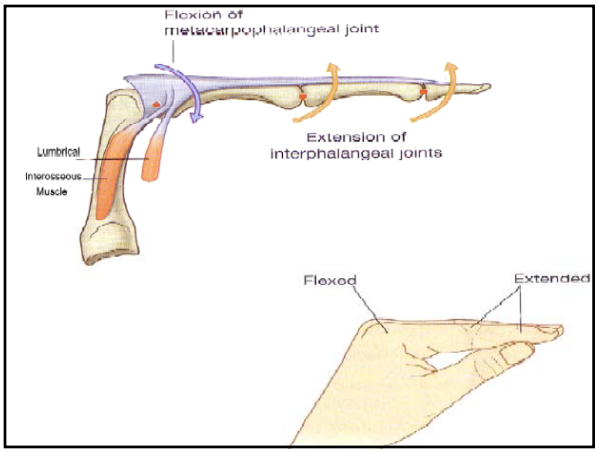

Mallet finger injury

Intervention

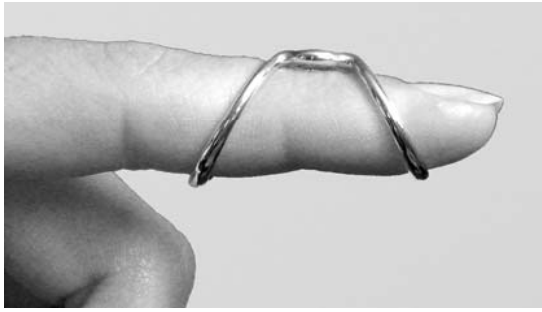

Can Progress to Swan Neck Deformity

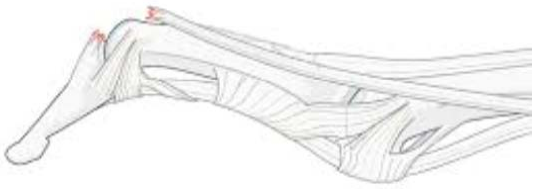

Simple Splint

Boutonniere's Deformity

- Note Flexion at the Proximal Interphalangeal Joint (PIP)

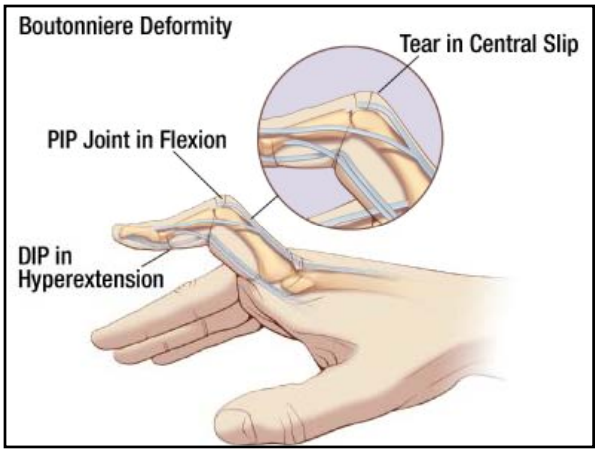

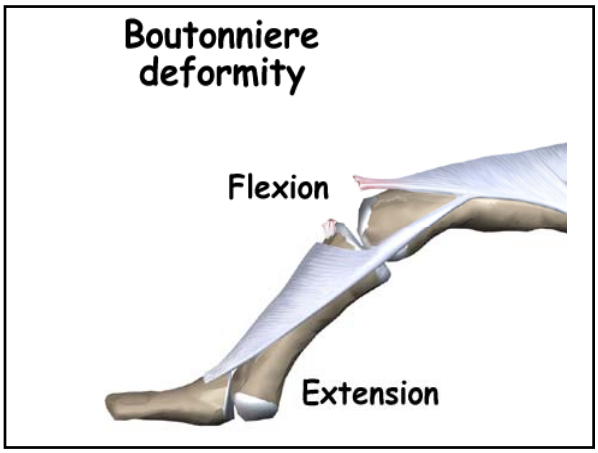
Boutonniere deformity
Flexion
Extension

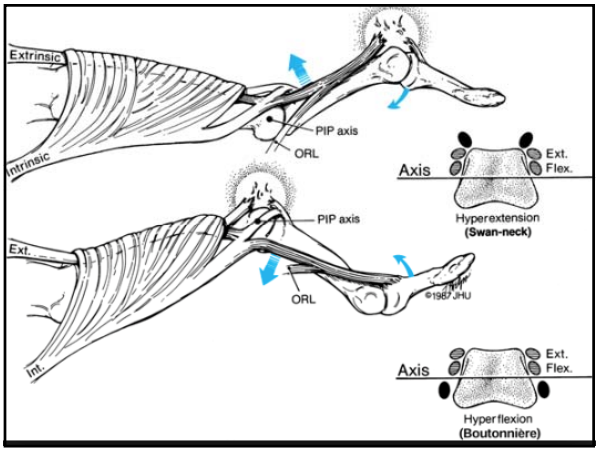
Extrinsic
Intrinsic
PIP axis
ORL
Axis
Ext.
Flex.
Hyperextension
(Swan-neck)
Ext.
Int.
PIP axis
ORL
©1987 JHU
Axis
Ext.
Flex.
Hyperflexion
(Boutonnière)

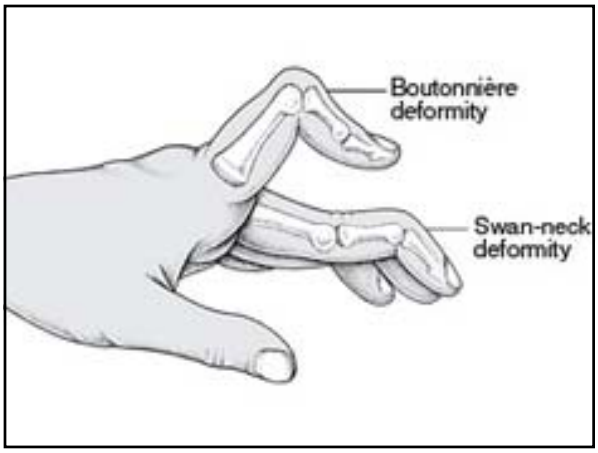
Boutonnière deformity
Swan-neck deformity

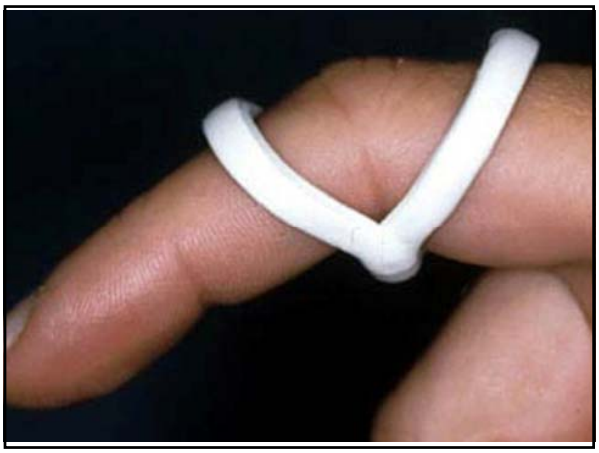

Simple Splint

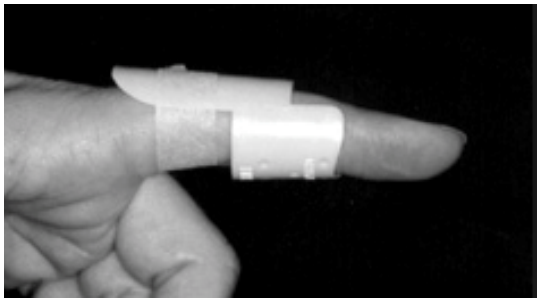

Surface Anatomy of Wrist and Hand

Palpation Guide for the Wrist

- Median Nerve located between palmaris Longus and Flexor Carpi Radialis.
- Radial Artery lateral to Flexor Carpi Radialis
- Radial Nerve Lateral to Radial Artery

Palpation at Wrist

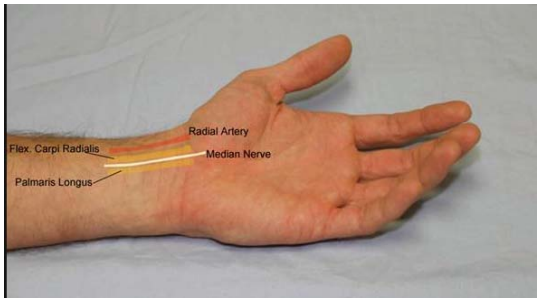

Landmarks at wrist

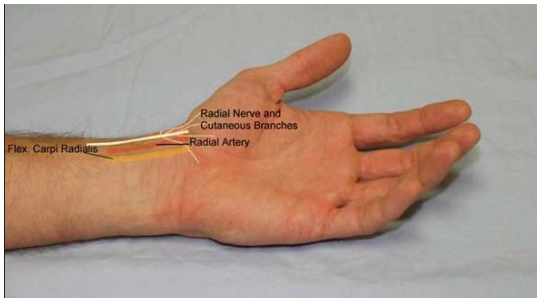

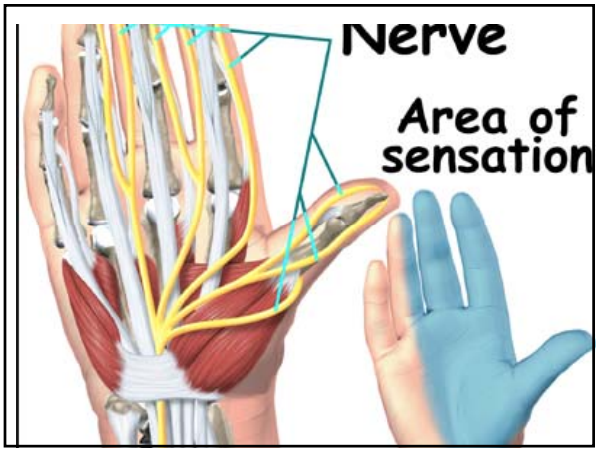

Nerves at the Wrist

Radial Nerve at Wrist

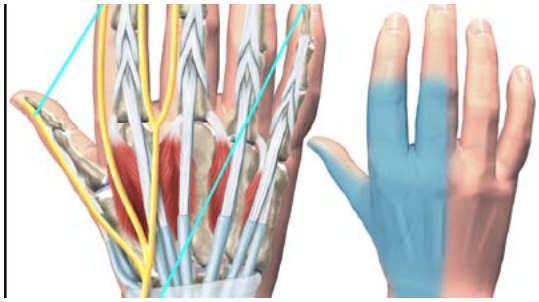

Sensory Innervation

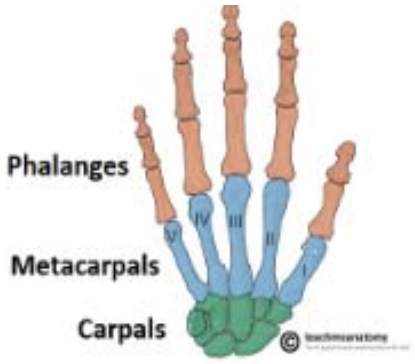

Fig 1.0 – Overview of the bones of

Radiocarpal Joint

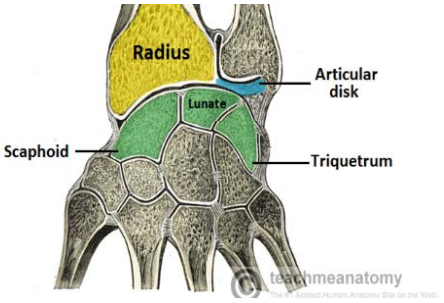

Carpal Bones

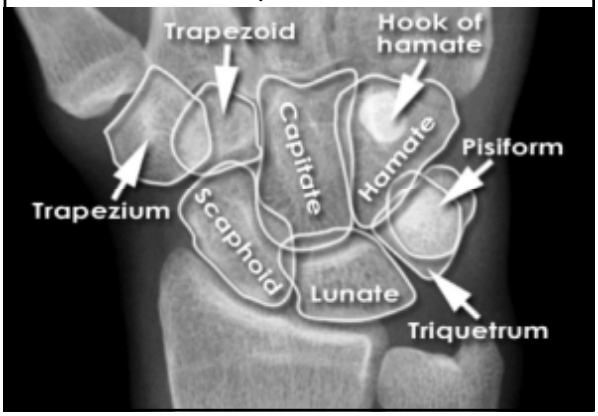

Arteries at Wrist

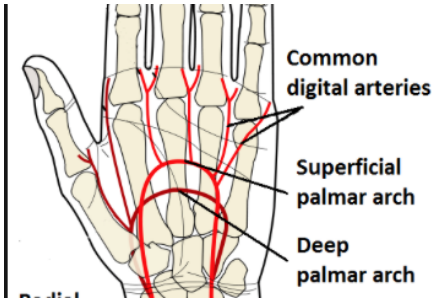

Palpation of the Elbow and Forearm

- Many structures are easily palpable
- Can be a Big Help in Differential Diagnosis

Bony Structures

Medial Epicondyle
Lateral Epicondyle
Olecranon
Note relationship of these three:
Form a straight line in extension
equilateral triangle at 90 flexion
Triangle overlies the capsule

Bony Structures, Cont'd

- Lateral supracondylar ridge
- Radial Head
- Proximal Radioulnar Joint
- Distal Radioulnar Joint

Ligaments

- Radial Collateral (Lateral Collateral)
- Ulnar Collateral (Medial Collateral)

Contractile Tissues

- Common Extensor Tendon
(From supracondylar ridge and lateral epicondyle)
- Extensor Carpi Radialis Longus origin
(From supracondylar ridge)
- Common Flexor Tendon
(from medial epicondyle)
- Biceps Tendon
- Triceps Common Tendon
(Olecranon)

Neurovascular Structures

- Brachial Artery
- (medial and deep to Biceps tendon)
- Ulnar Nerve
(between medial epicondyle and olecranon)

Palpation of the Forearm and Wrist

- Radial Styloid Process
- Ulnar Styloid Process
- Palmaris Longus
- Flexor Carpi Radialis
- Median Nerve
- Radial Artery
- Ulnar Artery

Dorsal Wrist

- Scaphoid
- Extensor Pollicis Longus
- Extensor Pollicis Brevis
- Abductor Pollicis Longus

- Radiocarpal Joint
- Capitate
- Carpometacarpal Joints
- Metacarpophalangeal joints
- Interphalangeal joints

Make Sure it's the Arm.
Arm and Hand Pain may be of Proximal origin

- Cervical
- Thoracic Outlet Syndrome
- Shoulder Pathology

Common Diagnoses at the Elbow and Wrist

Overuse Tendinopathy
Ligamentous Sprains
Neural Entrapments
Bursitis
Trauma/Fracture

Tennis Elbow

- **Lateral Elbow Pain/Tendinopathy**
- Diagnostic Tests
- Contractile Tests
- Wrist extension
- Finger Extension
- Supination
- Palpation
- Extensor Carpi Radialis Longus and Brevis
- Pain with stretch into Wrist Flexion

Golfer's Elbow

- **Medial Elbow Pain/Tendinopathy**
- Diagnostic Tests

  Contractile Tests

  Wrist Flexion

  Finger Flexion/ Grip

  Pronation

  Palpation

  Origin of Common Flexor Tendon

Medial and Lateral Elbow Pain Intervention

- This is not an inflammatory Condition
- Activity Modification
- Stretch Involved Tissues
- Eccentric Strengthening of Involved Muscles
- Bracing or Taping
- Scapular Position, posture

Biceps Tendinitis at the Elbow

- Tests:
- Palpation
- Resisted, contractile test
- **Intervention**
- Rest, Ice,
- Eccentric strengthening when resisted tests are negative
- Avoid Heavy resistance or aggressive stretch

DeQuervain's Tendinopathy

- Abductor Pollicis Longus
- Extensor Pollicis Brevis

- Tests:
- Finklestein's Test

- Intervention
  Rest, Activity Modification, Brace, Tape

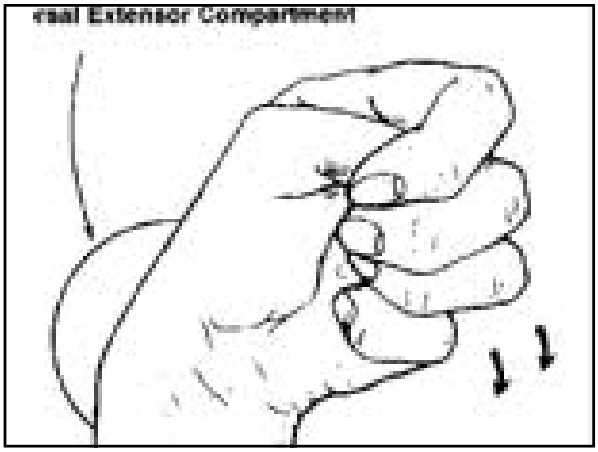

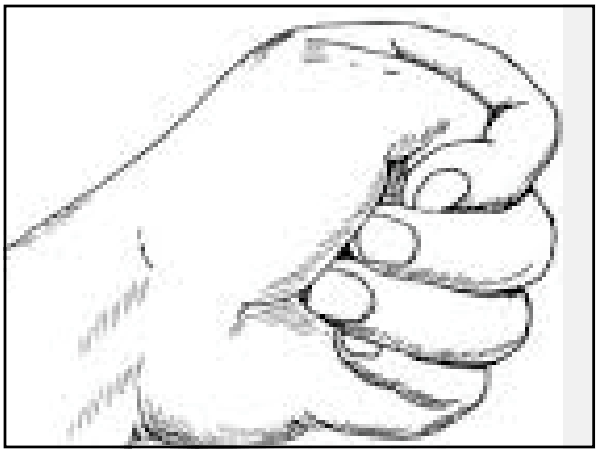

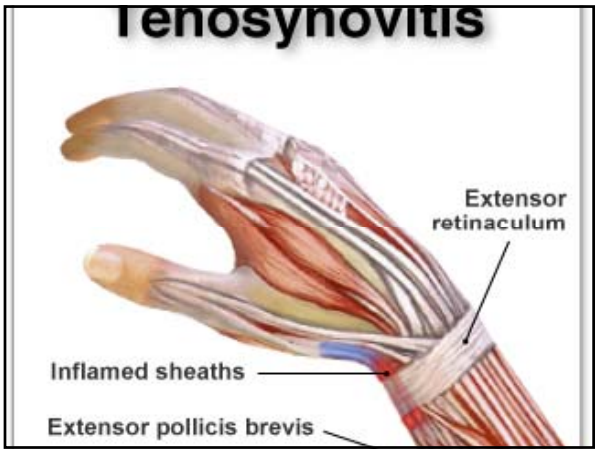

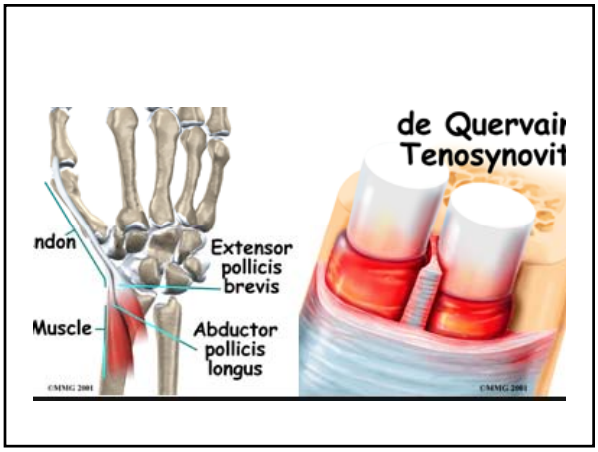

Ulnar and Radial Collateral Ligament Sprain

- Tests: Varus and Valgus Stress Tests at 20 degrees flexion.
- Palpation
- Intervention: Ice, Light Compression, Possible Splint or Brace.
- Avoid High Stress Activities
- Gradual Return to Activity

Cubital Tunnel Syndrome

- Entrapment /Irritation of Ulnar Nerve at the Elbow
- Cause: Excessive flexion and/or pressure on Nerve
- Test: Tinel's Sign

- **Intervention**
- Activity Modification
- Splint 30 degrees flexion, Full Supination
- Mobilize Ulnar Nerve (when irritability decreased)
- Elongate Flexor Carpi Ulnaris

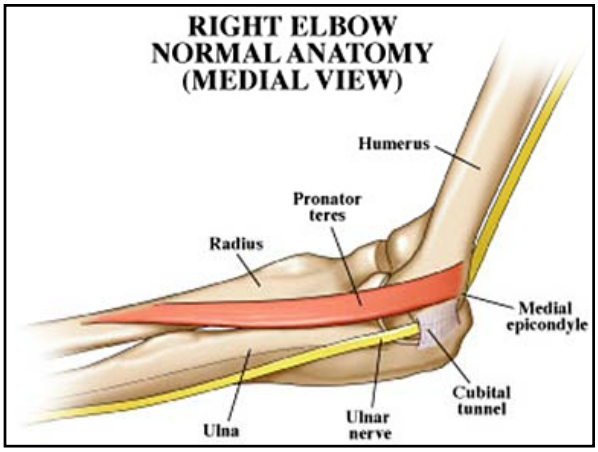

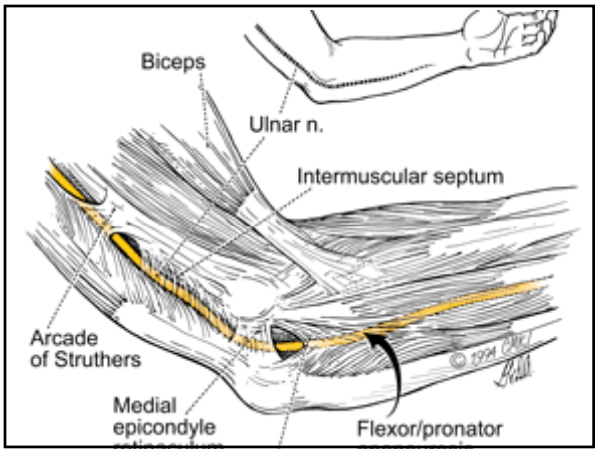

Carpal Tunnel Syndrome

- Entrapment of Median Nerve at the Wrist
- Tests
  . Tinel's Sign
  .Phalen's Sign

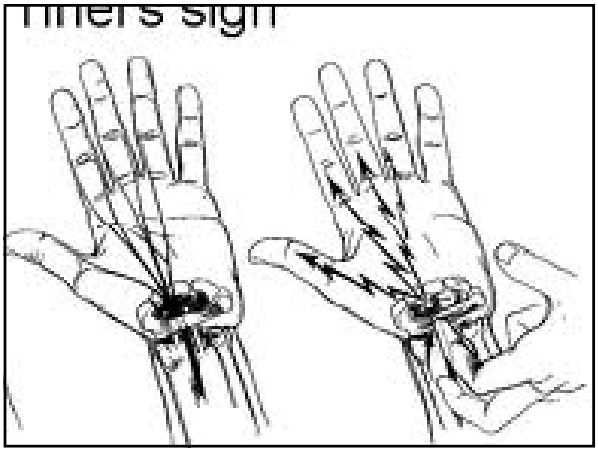

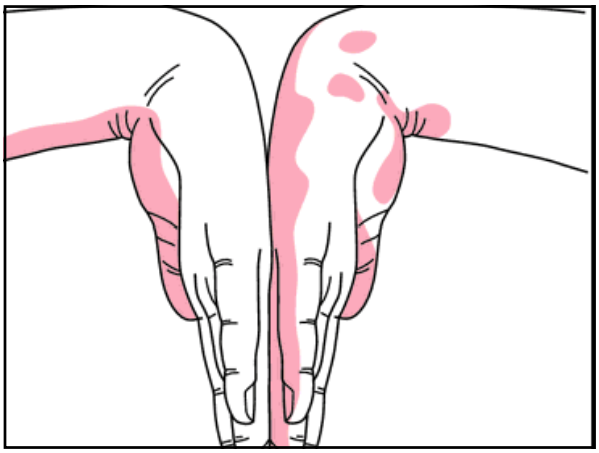

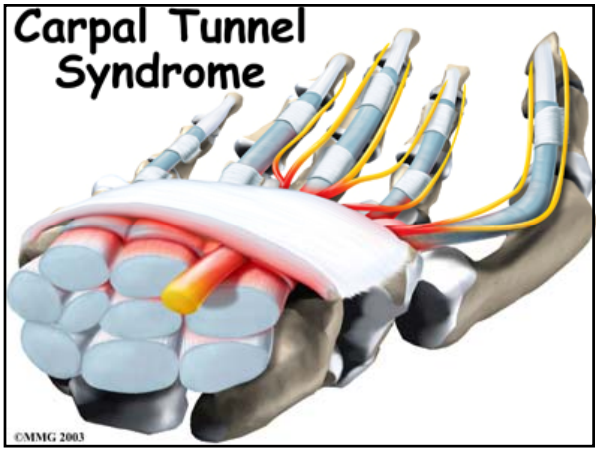

Carpal Tunnel Intervention

- Rest, Activity Modification
- Brace. Especially night time
- Treat cervical spine as needed (Evaluate C5, 6)

Ulnar Entrapment at Guyon's Canal

- Ulnar Tension Test
- Tinel's over Ulnar Nerve

- **Intervention:** Activity Modification, Rest, Mobilize Hamate

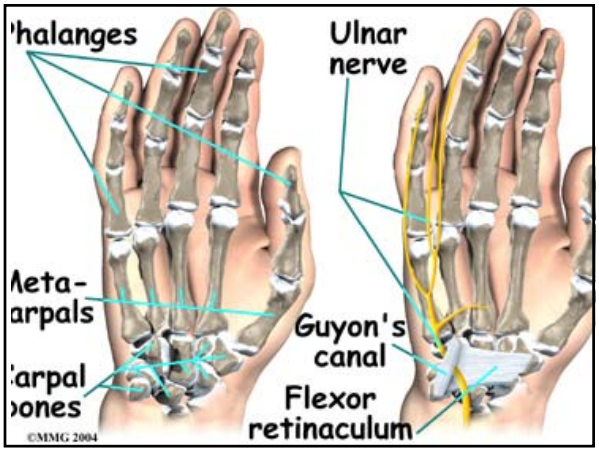

Vascular Compromise

Tests: Vascular Patency.

Block blood flow, then open one artery at a time to observe capillary refill.

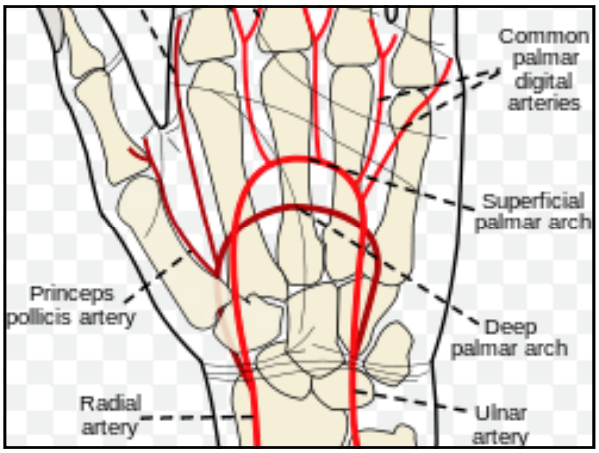

Radial Palsy

Bracing as Intervention

Bursitis

- Olecranon Bursitis
- Tests: Palpation, observe for swelling
- **Intervention:**
- Ice
- Avoid Pressure on Bursa

Trauma/Fracture

- Prolonged Immobilization
- Prolonged swelling of the Hand
- Can result in permanent loss of motion and disability

Distal Radial Fracture

- Elbow and wrist immobilized due to high risk of deformity

Intervention

- Edema Control
- elevation
- light compression
- Early Active and Passive Mobilization of Shoulder, Hand and Fingers as allowed by POP
- Active and Passive Mobilization of all Joints when fracture is stable

Tennis Elbow

- **Lateral Elbow Pain/Tendinopathy**
- Diagnostic Tests
- Contractile Tests
- Wrist extension
- Finger Extension
- Supination
- Palpation
- Extensor Carpi Radialis Longus and Brevis
- Pain with stretch into Wrist Flexion

Golfer's Elbow

- **Medial Elbow Pain/Tendinopathy**
- Diagnostic Tests

Contractile Tests

Wrist Flexion

Finger Flexion/ Grip

Pronation

Palpation

Origin of Common Flexor Tendon

Biceps Tendinitis at the Elbow

- Tests:
- Palpation
- Resisted, contractile test
- **Intervention**
- Rest, Ice,
- Eccentric strengthening when resisted tests are negative
- Avoid Heavy resistance or aggressive stretch

DeQuervain's Tendinopathy

- Abductor Pollicis Longus
- Extensor Pollicis Brevis

- Tests:
- Finklestein's Test

- Intervention
  Rest, Activity Modification, Brace, Tape

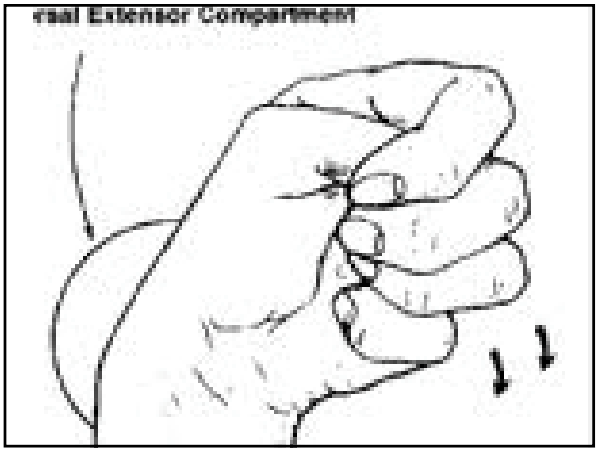

Ulnar and Radial Collateral Ligament Sprain

- Tests: Varus and Valgus Stress Tests at 20 degrees flexion.

- Palpation

- Intervention: Ice, Light Compression, Possible Splint or Brace.
- Avoid High Stress Activities
- Gradual Return to Activity

Cubital Tunnel Syndrome

- Entrapment /Irritation of Ulnar Nerve at the Elbow
- Cause: Excessive flexion and/or pressure on Nerve
- Test: Tinel's Sign

- **Intervention**
- Activity Modification
- Splint 30 degrees flexion, Full Supination
- Mobilize Ulnar Nerve (when irritability decreased)
- Elongate Flexor Carpi Ulnaris

Carpal Tunnel Syndrome

- Entrapment of Median Nerve at the Wrist

- Tests
  . Tinel's Sign
  .Phalen's Sign

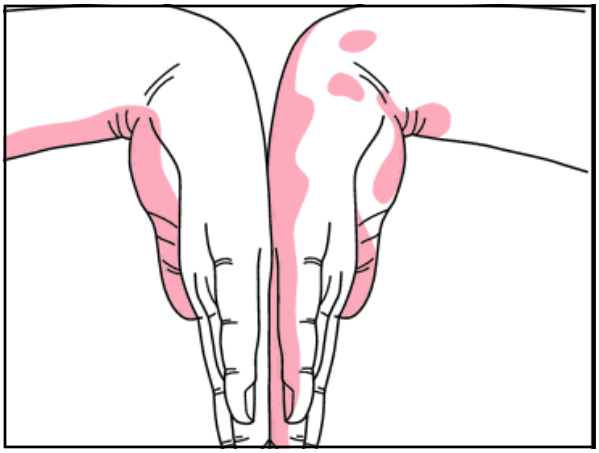

Ulnar Entrapment at Guyon's Canal

- Ulnar Tension Test
- Tinel's over Ulnar Nerve

- **Intervention:** Activity Modification, Rest, Mobilize Hamate

Vascular Compromise

Tests: Vascular Patency.

Block blood flow, then open one artery at a time to observe capillary refill.

Manual Therapy to the Elbow, Wrist , and Hand

Taping, Bracing for Medial and Lateral Elbow Pain

Joint Mobilization

Pronation, Supination

- Proximal and Distal Radioulnar Joints
- Both Follow the Convex/Concave Rule
- Distal Radioulnar Joint
- Posterior Glide of Radius for Supination

- Proximal Radioulnar Joint
- Anterior Radial Glide for Supination

Elbow Flexion

- Joint Distraction at End of Range

Elbow Extension

- Joint Distraction at end of range
- Same motion as in Flexion

Wrist Extension

- Palmar Glide of Proximal Carpals on Distal Radius

Wrist Flexion

These techniques must all be performed at end-range flexion

- Dorsal Glide of Proximal Carpals on Radius
- Intercarpal Mobility:

Palmar Glide of all Carpals Around a Fixed Capitate

MP and IP Flexion/Extension

- All follow the Concave/Convex Rule
- Palmar Glide of Distal Segment for Flexion
- Dorsal glide of Distal Segment for extension

Nerve Glides

- Ulnar Nerve: Elbow flexion, pronation, Internal Rotation, Shoulder elevation. Scapular depression.
- (See Drawing)

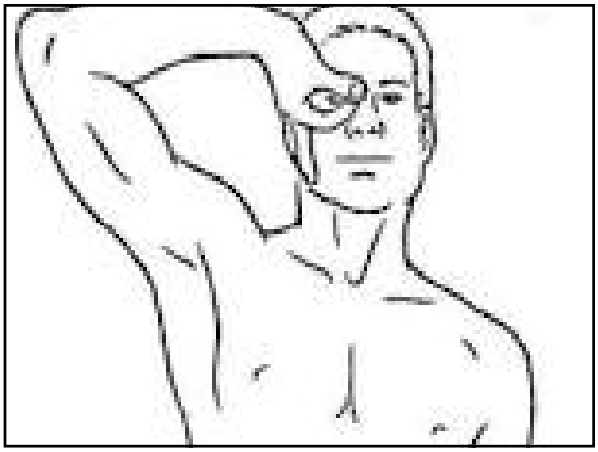

Median Nerve Glide

- Elbow Extension, Supination, wrist and finger extension, shoulder Elevation and external Rotation. Scapular Depression, Cervical sidebending away

Median Nerve Glide

Radial Nerve Glide

- cervical side bending away
- scapular depression
- Internal Rotation
- Pronation
- wrist and finger flexion

Tendon Gliding Exercises

A series of hand positions or exercises that assure all tendons and joints of the hand are fully mobilized. These exercises may done actively, passively or active assist.

Post trauma wrist cases should be instructed in performing these to prevent loss of function at the hand.

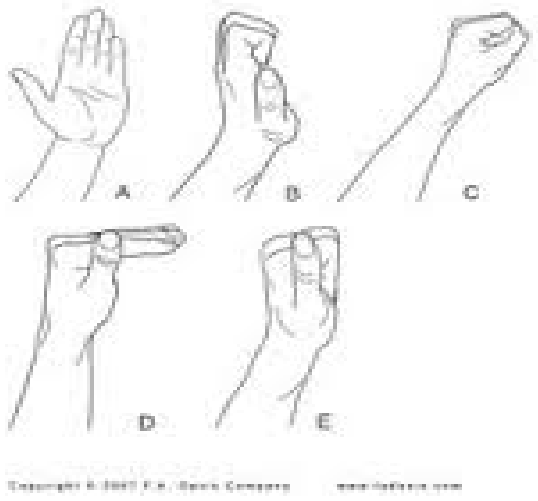

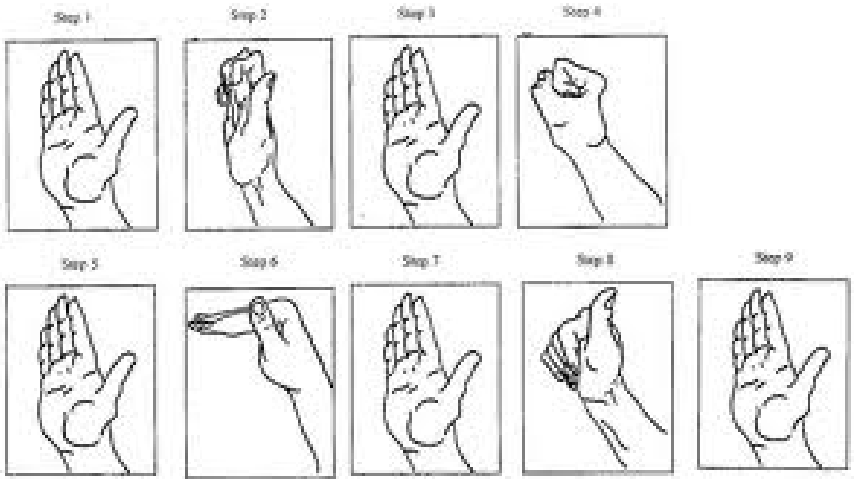
Step 1
Step 2
Step 3
Step 4
Step 5
Step 6
Step 7
Step 8
Step 9

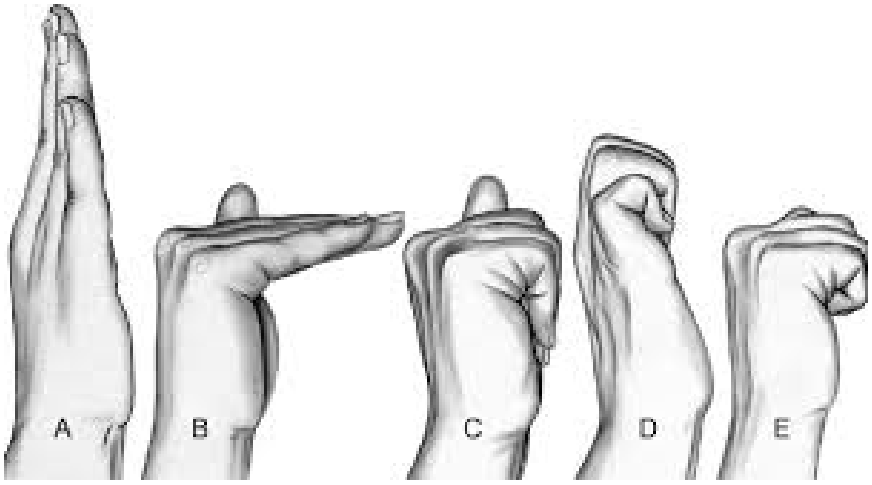
A
B
C
D
E

Hand and Wrist
Patient Cases

Case Number One: 22 year old male football player fell and fractured right lunate. He is 10 days post op for excision of lunate fragment. Incision site is covered with dressing since there was some slight bleeding during suture removal yesterday.

O: All digits are swollen and finger tips are 2.5 cm from touching his palm during active hook fist and full fist. Passively, pads can reach palm with persistent overpressure. IP and MP extension are full. Active supination is full, pronation is 40 degrees . Active elbow flexion, extension and all shoulder motions are full. Testing of wrist motion was deferred until his next visit which is scheduled for tomorrow.

A: Elbow, Wrist and Hand Stiffness status post lunate fracture and excision.

P: Mobilize Proximal and Distal Radioulnar Joints to increase Pronation

Home Exercise Plan: Tendon Gliding Exercises (See Handout).

Opposition all digits to Thumb

Wrist AROM all planes

Elevate to control Swelling

1. Please list and demonstrate the manual mobilization techniques you will use with this patient.

2. Please list and demonstrate this patient's home exercise program

Case Number Two: 38 year old Nurse 12 weeks post left distal radial fracture. Immobilized for 8 weeks with POP. Has not been using the left UE due to pain and stiffness. Pain has been steadily decreasing but stiffness remains a major problem.

O: Left hand is moderately swollen. Patient is unable to make a full fist or to completely extend digits 2 through 5. During attempted hook fist, fingertips are 3 Cm from touching the palm. Actively, PIP and DIP joints lack 20 degrees of extension. Passively, all joints can be pushed about 5 degrees further than active. Active wrist supination and pronation are 45 degrees. Active wrist extension is 25 degrees, flexion is 30 degrees. Passive motion is about 5 degrees further than active. All motions are limited by stiffness.

A: Wrist and hand stiffness post immobilization.

P: Manual mobilization and home exercise to increase ROM of wrist flexion, extension, supination, pronation; finger flexion and extension at all joints.

1. Please list and demonstrate the manual mobilization techniques you will use with this patient.

2. Please list and demonstrate this patient's home exercise program

Case Number Three: 38 year old accountant complains of right lateral elbow pain interfering with sleep and aggravated by his work operating the keyboard. Symptoms have been present about 6 months and are getting worse.

O: AROM of all upper extremity joints is full without pain. Resisted right wrist and finger extension reproduce lateral elbow pain. Right lateral epicondyle and supracondylar ridge are painful to palpation. Posture is remarkable for forward head and shoulders.

A: Lateral epicondylosis, elbow pain.

P: Postural correction, home exercise plan, ergonomic evaluation at work.

1. Please list and demonstrate the diagnostic tests you will perform with this patient

2. Please list and demonstrate this patient's home exercise program

3. Please list and demonstrate any manual techniques you will use with this patient.

Upper Extremity Exercise Lab

- Pair up with a partner and practice each of the following exercises.
- For each exercise state the muscle or muscles you are working.
- State the kinesiological reason for performing this exercise.
- Decide what type of contraction you will use for this exercise.
- Decide what part of the ROM you will perform the exercise in and why.

Scapular Retraction, Stabilization

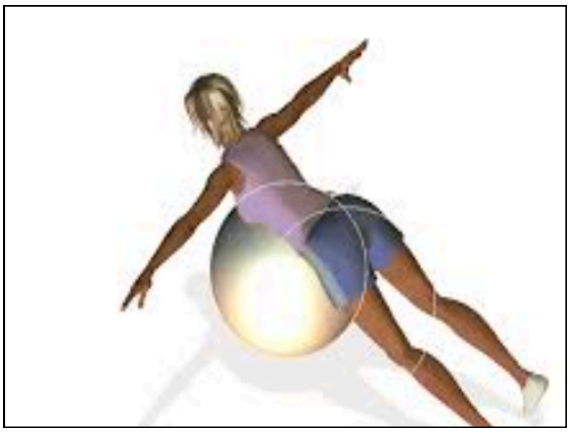

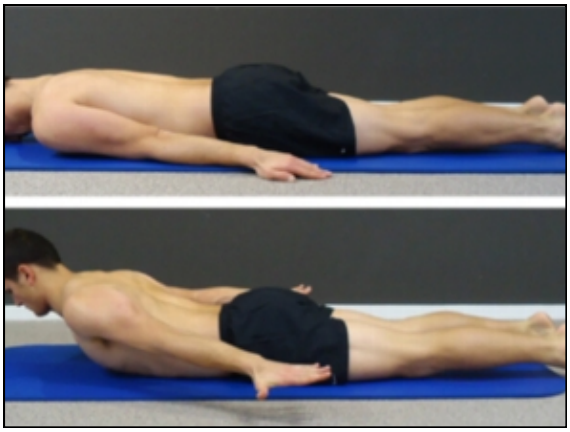

Rotator Cuff Strengthening

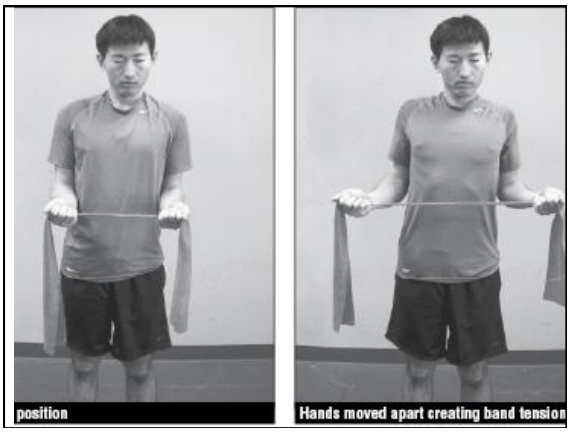

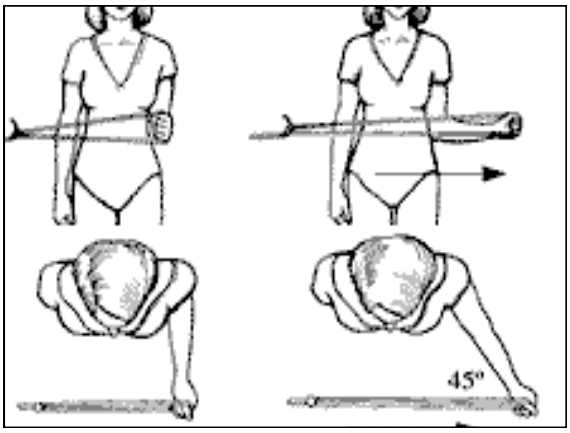
45°



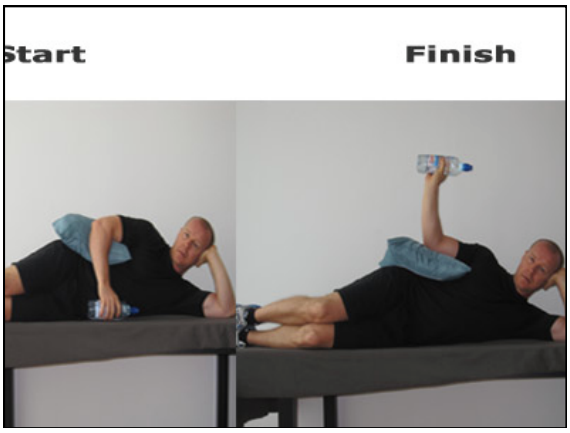
Start
Finish

- Glenohumeral Stabilization in Neutral

Passive Elevation for Home

Home Exercises for Elbow



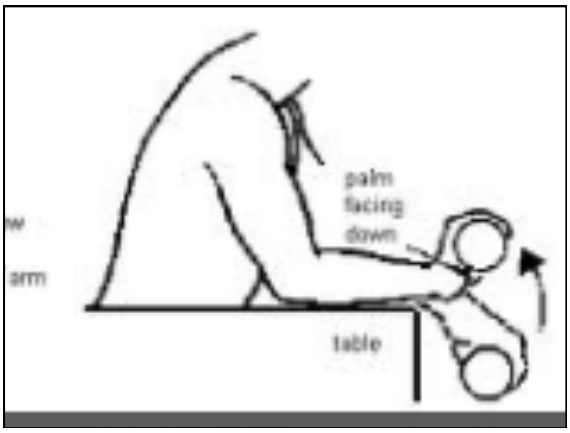
palm
facing
down
table

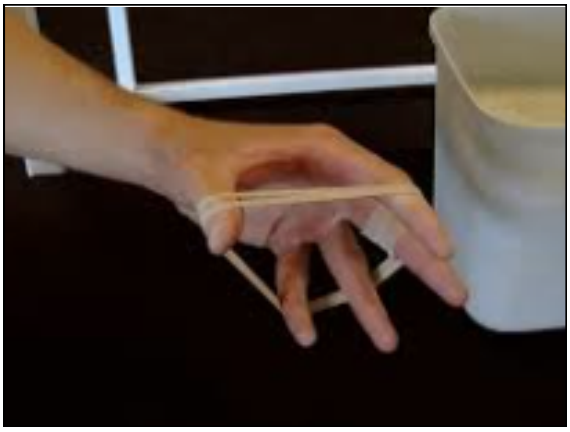

Advancement of Rwandan Rehabilitation Services Project

Therapy Course
Session Four

HEALTH VOLUNTEERS OVERSEAS

ADVANCEMENT OF RWANDAN REHABILITATION SERVICES PROJECT
CONTINUING PROFESSIONAL DEVELOPMENT COURSES

EXPECTATIONS of COURSE PARTICIPANTS

1. Attend and participate in class sessions one weekend a month (two days) for the duration of the course.
2. Arrive on time to each class session and return from tea break and lunch at the designated time.
3. Do not use cell phones in class.
4. Strive to have appropriate patients scheduled to evaluate and/or treat when the course instructors do clinical visits with you.
5. Turn in homework assignments on time.
6. Participate in class discussions.
7. Use lab time to practice newly taught techniques.
8. Practice new techniques in your clinical setting.
9. Develop a plan to share the material you have learned with other professionals.
10. Use newly learned skills in your practice after the course is over.

You will earn one CPD unit for every hour that you attend the course, and each fully completed homework assignment is worth two CPD units.

The Foot

What Does it Do?

Shock Absorption in early to mid stance.
Must be Flexible and change shape to absorb shock.

Propulsion during push off
Must be a Rigid Lever to transmit push off force

How can the Foot do Both Jobs?

- Arches of the Foot change height during different phases of the Gait Cycle

- When the foot is in the arched form (supinated) it is rigid.
- When it is in the flattened form (pronated), it is soft and floppy.

The foot arches and flattens during the gait cycle.

- Tarsal Bones are shaped like the stones in an archway
- They are pulled into an arch and held there by muscles.
- When the muscles lengthen the foot becomes a loose bag of bones.
- When the muscles shorten, the bones are pulled into a rigid arch.
- The foot is rigid for push off
- And loose for shock absorption at early and midstance

Arches of the Foot

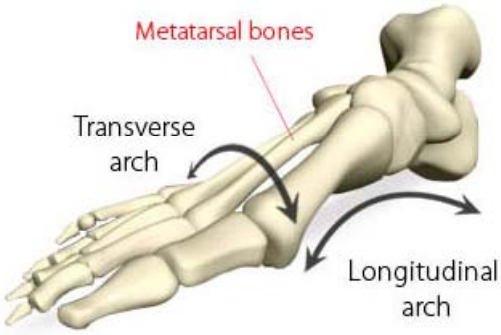

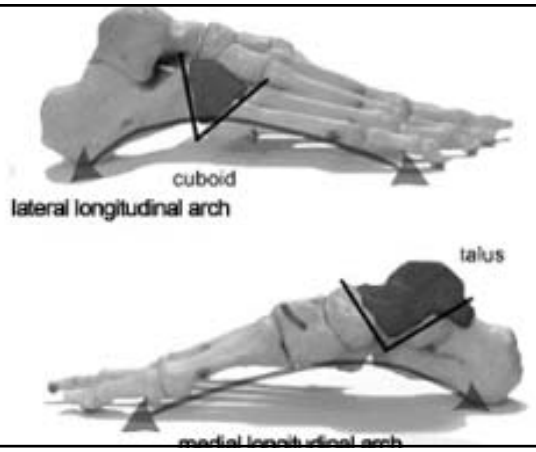

Transverse Arch

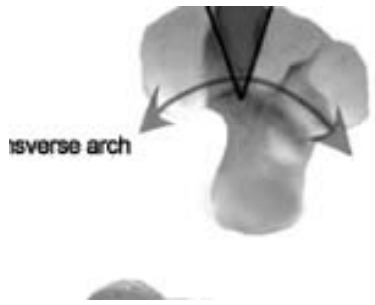

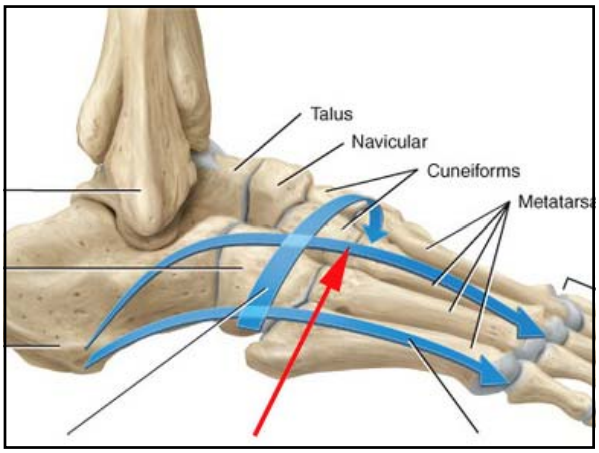

Potential Problems

- Too much Arch

Pes Cavus

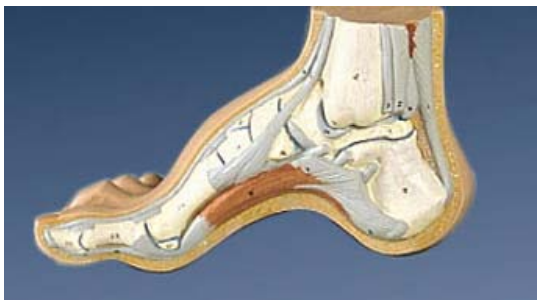

Pes Cavus

- High Arched foot fails to absorb Shock
- Foot is too Rigid. Cannot flatten and absorb shock
- Transmits Ground Forces up to Proximal structures
- Ankle
- Knee Hip
- Sacroiliac Joint
- Lumbar Spine
- Restricted Ankle Dorsiflexion causes Plantar fasciitis

Pes Cavus Biomechanics

- **Supinated Foot Type**
- Plantar Flexion at Ankle
- Inversion at subtalar joint, midfoot and forefoot
- Internal (Adduction) Rotation of Foot

- **Proximal Kinetic Chain**
- Subjected to Increased Shock from Ground Force

The Opposite Foot Type is also a Problem

Pes Planus

Pes Planus (Pronated Foot Type)

- Cannot become a Rigid Lever for Push Off
- Results in Posterior muscles overworking
- Posterior Tibialis Tendinitis
- Achilles Tendinitis
- Over stretches Plantar Fascia
- Plantar Fasciitis
- Alters Biomechanics of Kinetic Chain

Pes Planus Biomechanics

- **Foot and Ankle**
- Dorsiflexion
- Eversion
- External Rotation
- **Tibia**
- Internal Rotation
- **Knee**
- Genu Valgus
- Hyperextension

Pes Planus Biomechanics Continued

- **Hip**
- Internal Rotation
- **Lumbar Spine**
- Increased Lordosis

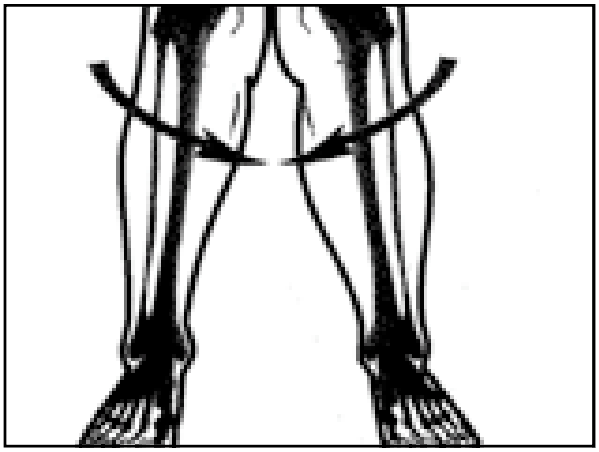

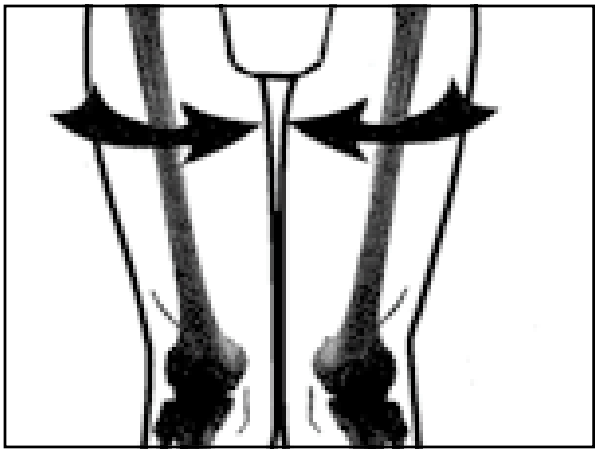

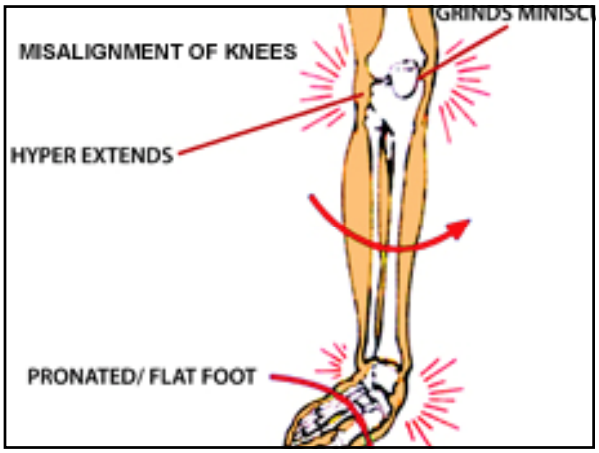

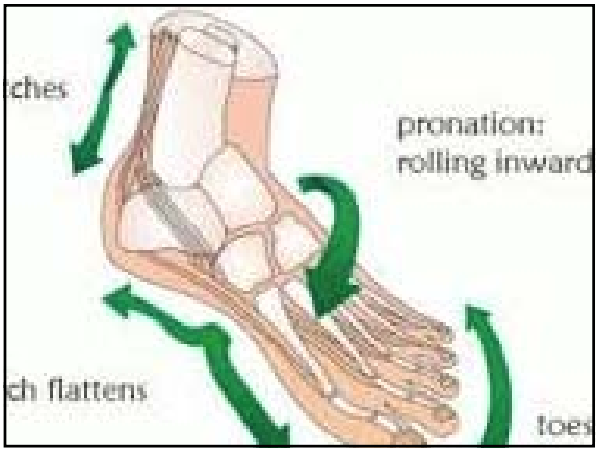

- **Pes Planus Foot Type**
- is an excessively Pronated foot

- **Pes Cavus Foot Type**
- Is an excessively Supinated foot

Terms: Pronation

- **Triplanar Movement**
- **Pronation**
- Dorsiflexion
- Eversion
- External Rotation of Foot

Supination

- **Triplanar Movement**
- Plantar flexion
- Inversion
- Internal rotation of the foot

- Both Extremes Cause Problems.
- We will have a closer look at the diagnoses associated with each of these foot types as we study common diagnoses.
- Much of the Anatomy in this Region Functions to control the Arches of the Foot

Anatomy Videos

Tutorial videos of the foot and ankle are played in the classroom at this time. Videos are publicly available online; the ones used have been identified.

The videos are:

- eOrthopod.com - Foot Anatomy Animated Tutorial
- eOrthopod.com - Anatomy of the Ankle Joint

Functional Anatomy of the Foot

Those structures responsible for the Supination/Pronation Cycle

Bones
Ligaments
Muscles
Fascia

Bones

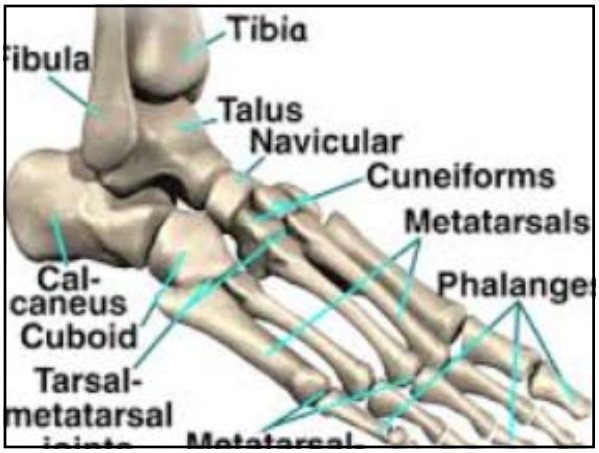

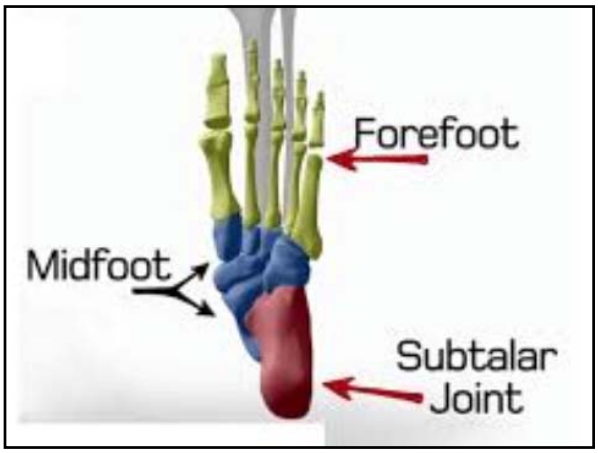

- Subtalar Joint or Hind Foot:
- Talus on Calcaneus
- Midfoot: navicular, cuboid, cuneiforms
- Forefoot: Metatarsals and Phalanges

Subtalar Joint

- Allows Inversion/Eversion
- Subtalar Eversion Initiates Pronation
- Controlling the Rearfoot is Important in Controlling Pronation

Midfoot: **Navicular, Cuboid, Cuneiforms are Free to become loose- packed and assume a Decreased Arch Height:**

- When Intrinsic and Extrinsic muscles lengthen
- When the Subtalar Joint Everts

- Arch Support can be used to prevent excessive Collapse of Tarsals

ForeFoot

- First and Fifth Metatarsal Heads are the Primary Contact surfaces with the Ground.
- First metatarsal Head, Fifth metatarsal Head and Calcaneus form a weight bearing tripod.
- First Metatarsal phalangeal (MTP) Joint must Dorsiflex During Late Stance
- First MTP can only Dorsiflex when the First Metatarsal is plantar flexed by Peroneus Longus (Fibularis Longus)

Ligaments

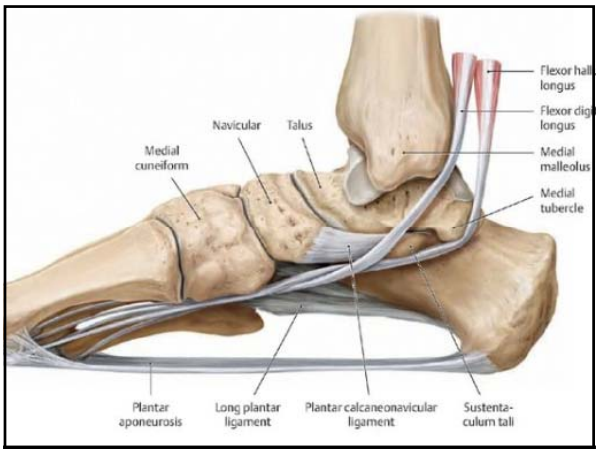

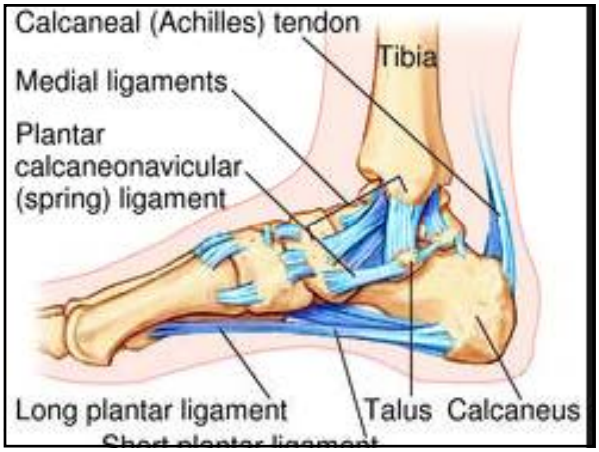

Muscles

- Intrinsic
- Extrinsic

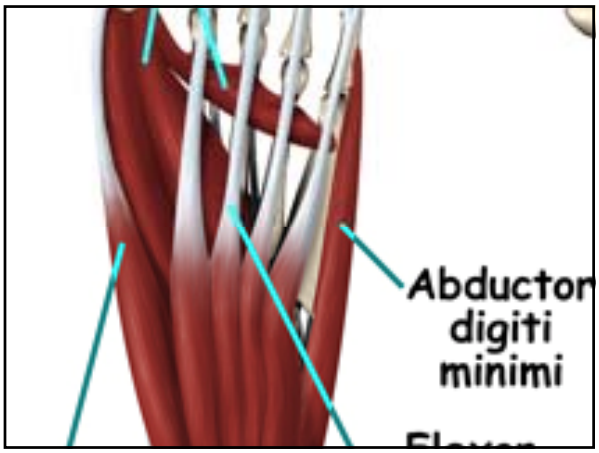
Abductor
digiti
minimi

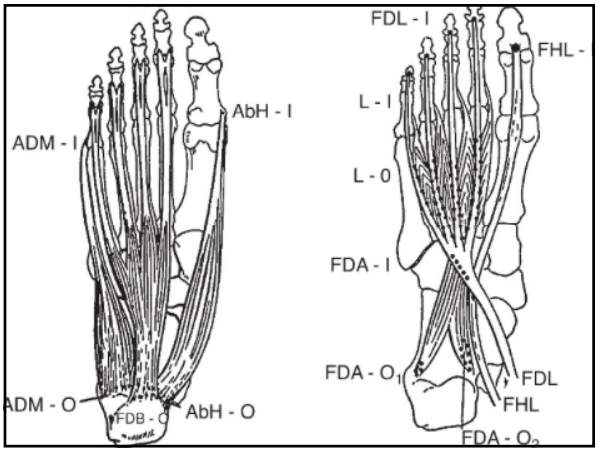
ADM - I
AbH - I
ADM - O
FDB - O
AbH - O
FDL - I
FHL -
L - I
L - 0
FDA - I
FDA - O1
FDL
FHL
FDA - O2

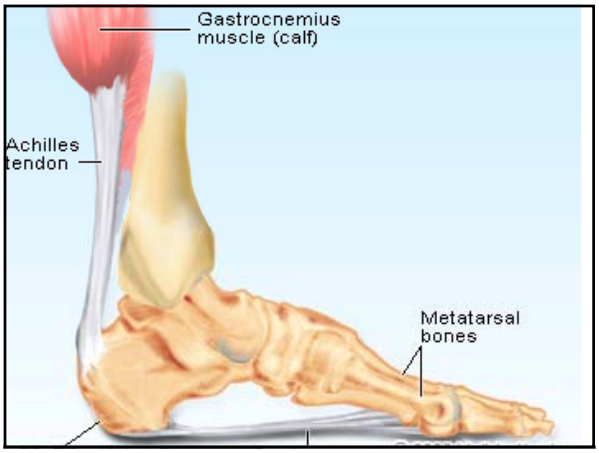
Gastrocnemius
muscle (calf)
Achilles
tendon
Metatarsal
bones

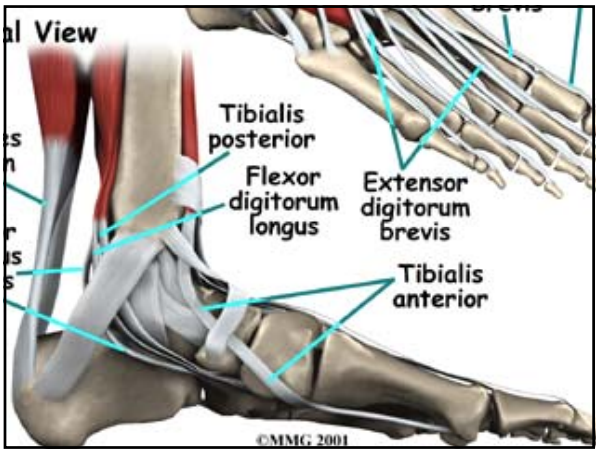
al View
Tibialis posterior
Flexor digitorum longus
Extensor digitorum brevis
Tibialis anterior
©MMG 2001

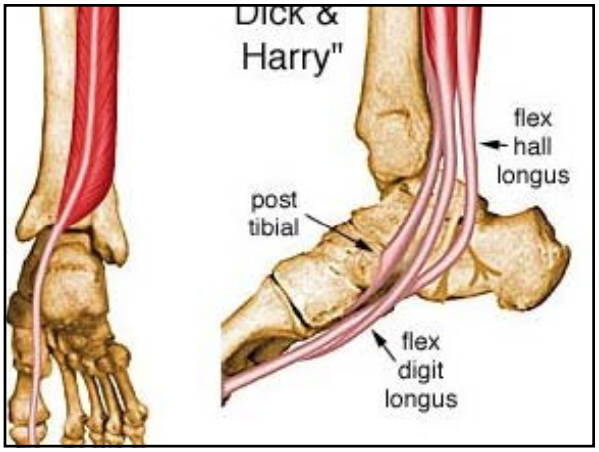
Dick &
Harry"
flex hall longus
post tibial
flex digit longus

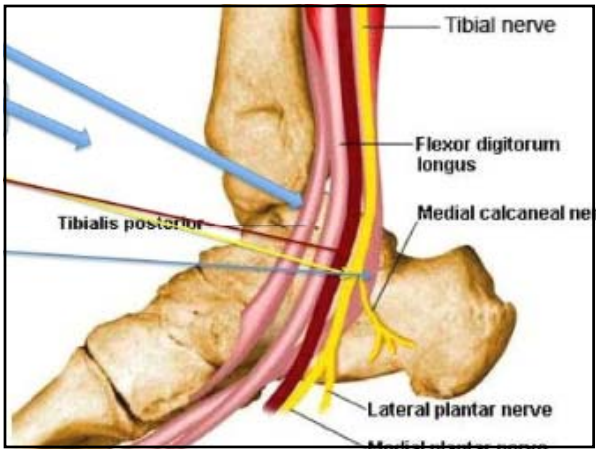
Tibial nerve
Flexor digitorum longus
Medial calcaneal ne
Tibialis posterior
Lateral plantar nerve

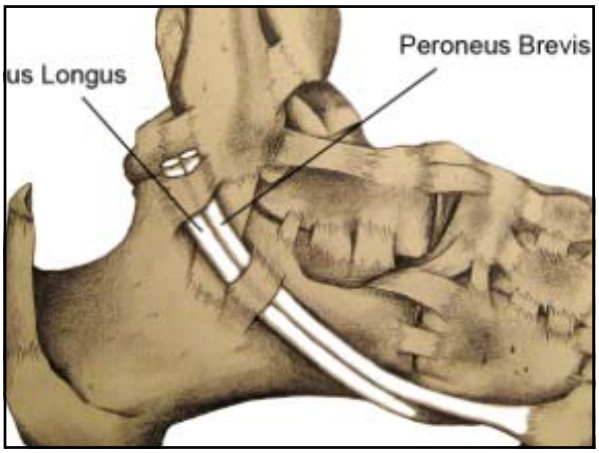
us Longus
Peroneus Brevis

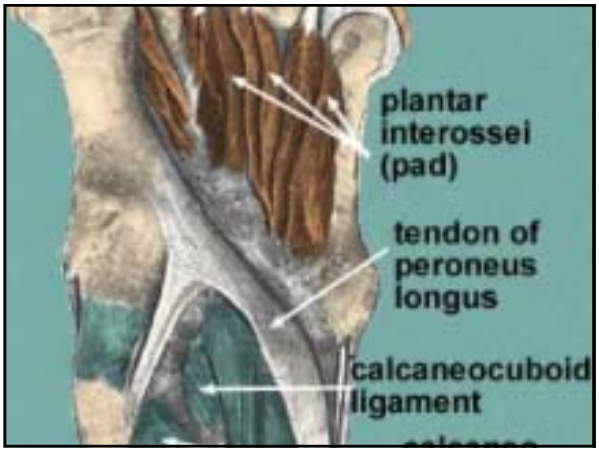
plantar
interossei
(pad)
tendon of
peroneus
longus
calcaneocuboid
ligament

Fascia

Plantar Fascia

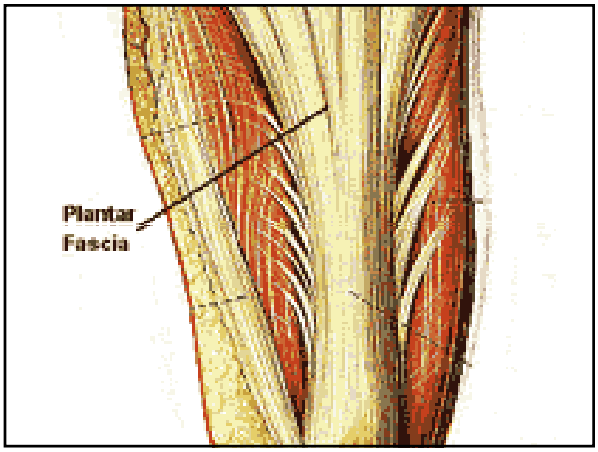

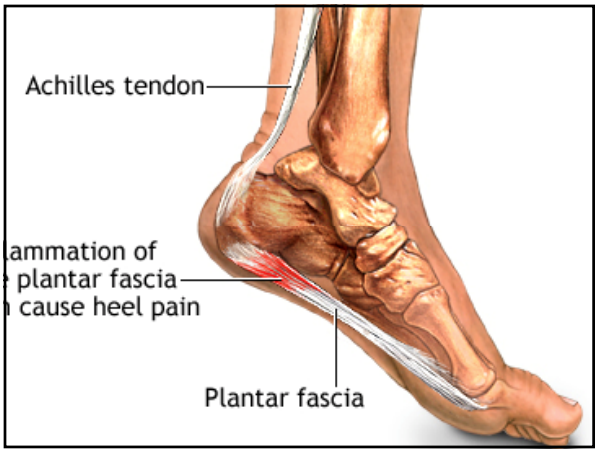

Anatomy of the Ankle
(Talocrural Joint)

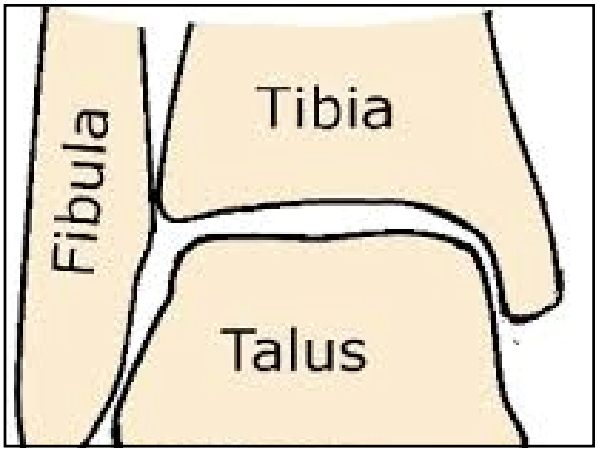

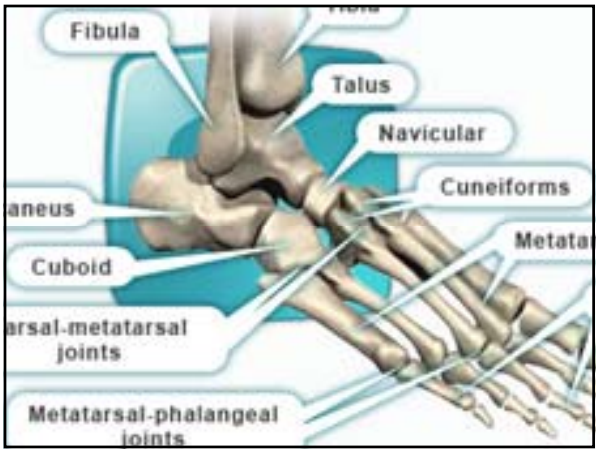

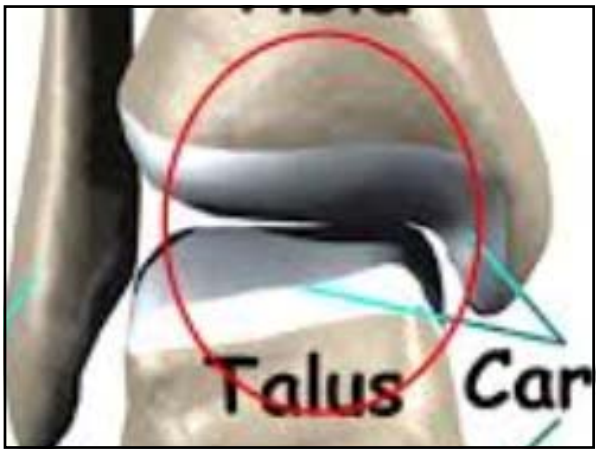
Talus
Car

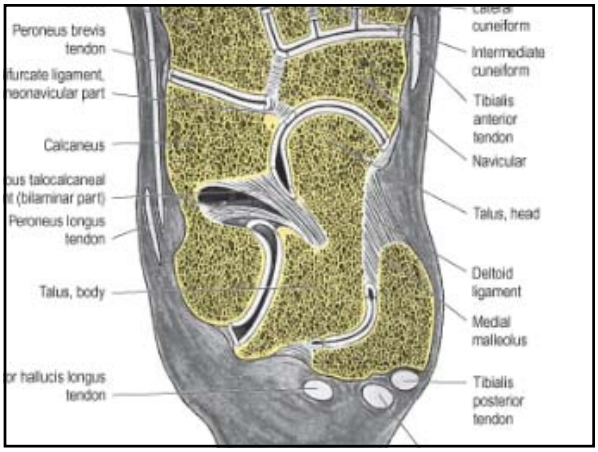
Peroneus brevis tendon
furcate ligament, eonavicular part
Calcaneus
bus talocalcaneal t (bilaminar part)
Peroneus longus tendon
Talus, body
r hallucis longus tendon
cuneiform
Intermediate cuneiform
Tibialis anterior tendon
Navicular
Talus, head
Deltoid ligament
Medial malleolus
Tibialis posterior tendon

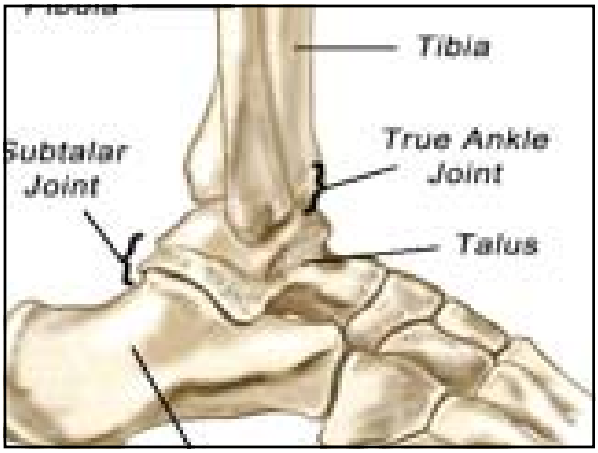
Tibia
Subtalar Joint
True Ankle Joint
Talus

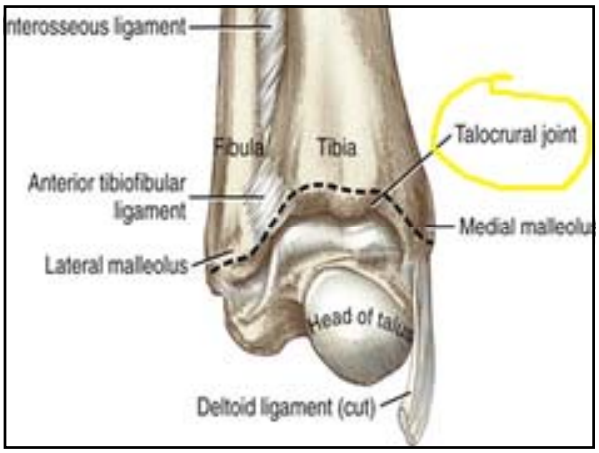

Talar Shape

- The Talus is Wide Anteriorly so the Talocrural Joint is Stable in Dorsiflexion.
- Much Less stable in Plantarflexion

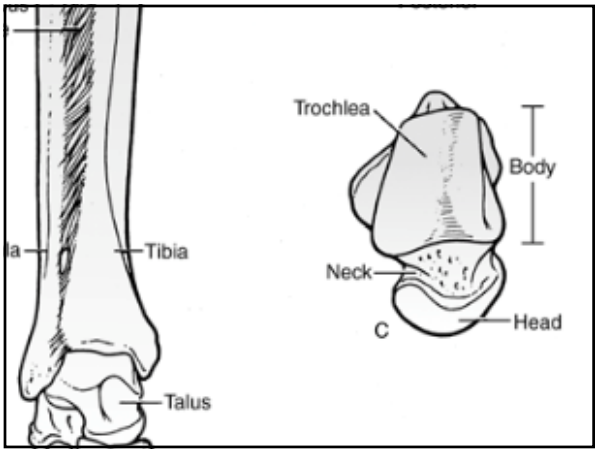

Lateral Ligaments

- Anterior Talofibular Ligament (ATF)
- Most Frequently Sprained

- Calcaneofibular Ligament
- In more severe cases, this ligament tears after the ATF has torn

- Posterior Talofibular Ligament
- Is the third to Tear

- Isolated Calcaneal Fibular or Posterior Talofibular Ligament tears are not common

- The ATF ligament tears first, if force and excursion is great enough, Calcaneoffibular Ligament tears, then the Posterior Talofibular Ligament

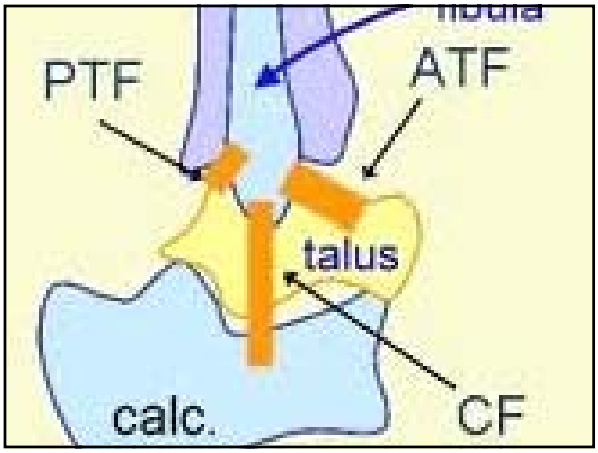

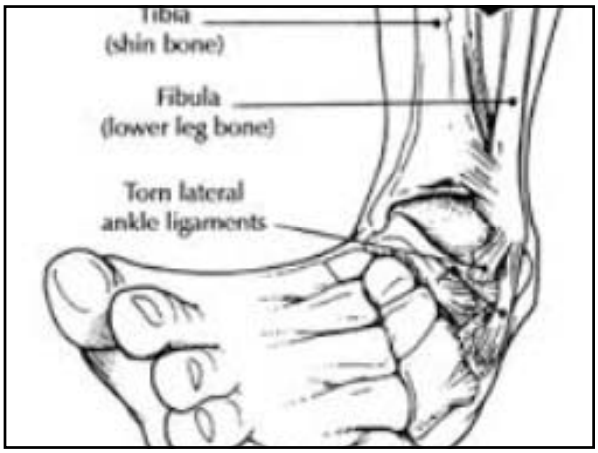

Stress X-Ray

Medial Ligaments

Deltoid Ligament

- Quite Strong
- Much Less frequently injured than lateral Ligaments
- Mechanism of Injury is Eversion

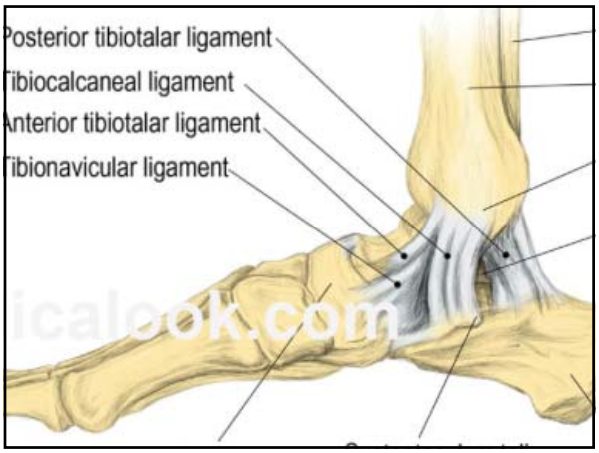
Posterior tibiotalar ligament
Tibiocalcaneal ligament
Anterior tibiotalar ligament
Tibionavicular ligament

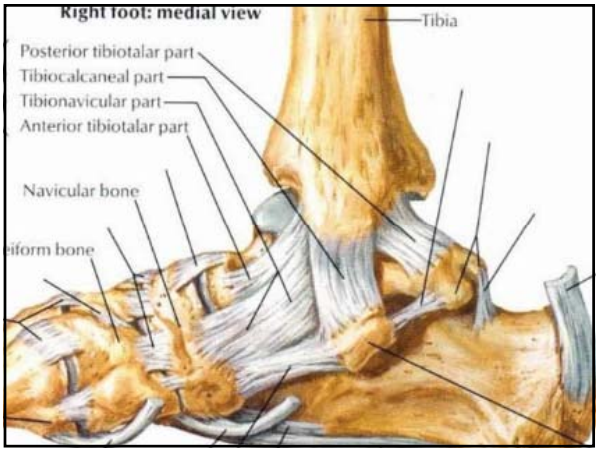
Right foot: medial view
Tibia
Posterior tibiotalar part
Tibiocalcaneal part
Tibionavicular part
Anterior tibiotalar part
Navicular bone

Palpation of Foot and Ankle: Patient Supine on Examination table

Lateral Foot and Ankle

.Peroneus (Fibularis) Longus Superior and Posterior to lateral Malleolus

. Cuboid (peroneus longus passing lateral and plantar to cuboid)

.Peroneus (Fibularis) Brevis tendon to 5th metatarsal base

.Peroneal (Fibular) Retinaculum

.Anterior Talofibular Ligament

. Calcaneofibular ligament

. Posterior Talofibular ligament

Medial Foot and Ankle

- Medial Malleolus
- Deltoid ligament
- Posterior Tibialis, Flexor Digitorum, Flexor Hallucis Longus Tendons
- Posterior Tibialis Retinaculum
- Navicular

Forefoot

- Assess Mobility of First Metatarsal Head in Plantar Flexion/ Dorsiflexion

. Assess Dorsiflexion of Hallux (70 degrees)
. Assess this with First Metatarsal Dorsiflexed and Plantarflexed

Examination of Rearfoot: Patient Prone on Table

- Assess Rearfoot Eversion and Inversion
- Determine Total Rearfoot Mobility
  Look for Hyper or Hypomobility.

. Normal mobility values are highly variable:
Approximately 15 degrees each direction; inversion slightly greater than eversion

Plantar Structures Palpated in Prone

.Palpate Plantar Fascia from metatarsal heads to Calcaneus
.Palpate Insertion of Plantar Fascia on Calcaneus

.Palpate Flexor Hallucis Longus Tendon Plantar to the First Metatarsal Shaft

.Palpate between the 3rd and 4th metatarsal heads for tenderness (Morton's Neuroma)

Common Diagnoses of the Foot and Ankle

Acute Ankle Sprain

- Most commonly Inversion/plantar flexion Injury leading to Anterior Talofibular Ligament Sprain
- Calcaneofibular and Posterior Talofibular ligaments may be involved in more severe cases
- In even more severe cases, the interosseus membrane may be torn (High Ankle Sprain)

Intervention

- Elevate, Ice, Rest from strenous activity.
- Gait training with crutches if needed, weight bearing to tolerance. Normalize gait.
- Ankle stabilization , proprioception training when tolerated.
- Evaluate for abnormal biomechanics, Pes Planus and Pes Cavus are both at increased risk for ankle sprain.
- Evaluate for High Ankle Sprain. This requires surgical intervention.

Distal Tibial Fracture

- May include fibula as well.
- Often the same mechanism as the inversion sprain.
- **Intervention:**
- Early gait training, Weight bearing as allowed per surgeon. (Typically Nonweight bearing for 6 weeks). Normalize gait to the extent possible.
- AROM, strengthening of hip and knee

Tendinitis

- Usually results from impaired biomechanics.
- **Posterior Tibialis Tendinitis**
- Common with Pes Planus
- **Intervention**
- Ice, rest
- Friction Massage
- Correct Biomechanics
- Eccentric Strengthening when Tolerated

- **Peroneus (Fibularis) Longus Tendinitis**
- Common with Pes Planus
- **Intervention**
- Ice, rest
- Friction Massage
- Correct Biomechanics
- Eccentric Strengthening when Tolerated

Achilles Tendinitis

- Commonly seen with Gastrocnemius Tightness
- Common with Pes Planus
- **Intervention**
- Ice, rest
- Friction Massage
- Assure at least 10 degrees dorsiflexion
- Correct Biomechanics
- Eccentric Strengthening when Tolerated
- Consider a Temporary Heel Lift.

Achilles Tendon Tear

- May be a Sudden, Acute Event or may Follow Chronic Tendinitis.
- **Intervention**:
- Complete tear will require Surgical Intervention.
- Partial Tear: Immobilization in Boot Six to Eight weeks. Ambulation with Crutches, protected weight bearing.

Post Immobilization Rehab of Achilles Tear

- Continue Crutch use another 2 to 4 weeks partial weight bearing, increasing time out of boot.
- Begin Active AROM Emphasizing Ankle Dorsiflexion.
- Gradually Discontinue Boot and Crutches. Consider a Temporary Heel Lift.
- When Ambulation, full weight bearing is pain free, start weight bearing Stretch into Dorsi Flexion and Eccentric Strengthening.
- Progress to Ankle Stabilization, Proprioception and Fast Fiber Rehab.

Retrocalcaneal Bursitis

- Same mechanism as Achilles Tendinitis
- Same intervention except No Friction Massage

Plantar Fasciitis

- May be from Pes Planus or Pes Cavus
- Excessive Body Weight may be a factor
- Poor Footwear may be a factor
- Standing on a rigid surface may also be a factor
- Usually painful during first step in the morning
- **Intervention**
- Assure At least 10 degrees of dorsiflexion
- Night Splint
- Correct Biomechanics

Hallux Limitus / Rigidus

- Failure of Great Toe to Dorsiflex (<45 degrees)
- Cause is usually failure of First Metatarsal to Plantar flex during push off
- Over time, First MTP will become stiff, Arthritic.
- **Intervention**
- Mobilization of First Metatarsal into Plantar Flexion
- Mobilization of MTP joint

Hallux Valgus

- Valgus deformity of great toe due to lack of MTP Dorsiflexion (Hallux Rigidus)
- **Intervention**
- Same as Hallux Rigidus
- Surgical Correction

Morton's Neuroma

- Medial and Lateral Plantar Nerves anastomose between the 3rd and 4th Metatarsal Heads so neural Mobility here is limited. Repeated stress at this point can result in formation of a Neuroma.
- Often associated with Supinated Foot Type and /or Poor Footwear.
- Diagnosis: Palpation and Squeezing Metatarsal Heads Together Reproduces Pain.

Morton's Neuroma Intervention

- Increase Forefoot Mobility: Manual Mobilization of Metatarsal Heads.
- Increase Pronation if Supinated Foot Type is Present.
- Assess for tightness of all plantar Flexors.
- Assess Footwear. Minimize stress on Forefoot.

Pes Planus

- This is a problem of instability.
- Identify muscles capable of stabilizing the foot and train them in isometric or very short arc, midrange contraction, in weight bearing.
- Typically all intrinsics, Peroneus Longus, Posterior Tibialis, Flexor Hallucis Longus, Flexor Digitorum, Gastroc/soleus complex, and Anterior Tibialis.
- Include Proprioception training
- Start very slow or isometric and increase speed as tolerated. Must include fast fiber rehab for the foot.

Pes Planus Continued

- Footwear with arch support
- Low Dye Taping (Arch Support)
- Orthotic

  To Stabilize the rearfoot

  To Provide Arch Support

Pes Cavus

- More Difficult to change than Pes Planus.
- This is a rigid foot with shortened posterior muscles.
- **Intervention**
- Stretching of Gastroc/soleus complex and posterior Tibialis
- Footwear with cushion
- Consider a temporary Heel lift.

Diagnostic Evaluation of the Foot and Ankle

Palpation is very useful and reliable

Contractile tests are reliable

Ligamentous Stress tests are reliable

Acute Inversion Ankle Sprain

- Observe for Swelling and Discoloration.
- Palpation of Anterior Talofibular Ligament.
- Inversion Stress Test: Passive Inversion of the Foot with overpressure.
- Anterior Drawer test: Stabilize Distal Tibia and Fibula, Glide Rearfoot Anteriorly.
- Talar Tilt Test for Calcaneofibular Ligament. Stabilize distal Tibia and fibula, Invert Calcaneus.
- Test for tibiofibular ligaments and Interosseus Membrane Tear: Squeeze Tibia and Fibula together, above the malleoli.

Tendinitis

- Palpate the Tendon and Perform the Resisted, Contractile Test.
- Achilles Tendinitis: Standing on Toes
- Posterior Tibialis Tendinitis: Standing on Toes
- Peroneus Longus Tendinitis: Resisted Eversion or Standing on Toes
- Flexor Hallucis Longus: Great Toe Flexion

Achilles Tendon Tear

- Partial Tear may be Difficult to Differentiate from Tendinitis
- May be a Sudden, Isolated event or can result from Chronic Tendinitis.
- Partial Tear may be Palpated within the Muscle Body or at the Musculotendinous Junction

Retrocalcaneal Bursitis

- Contractile test will be positive.
  (standing on toes)
- Palpation will differentiate this from the Achilles Tendinitis.
  Tenderness is deep to the Tendon

Plantar Fasciitis

- Question: Is the first step in the morning painful?
- Palpation – especially at Calcaneal Attachment.

Hallux Limitus / Rigidus

- First Metatarsopahalangeal (MTP) dorsiflexion < 30 degrees
- Asses mobility of First Metatarsal into Plantar flexion

- **Hallux Valgus** long term consequence of decreased dorsiflexion at the first MTP, usually due to poor Fibularis Longus function.

Pes Planus

- Feiss Line to grade Pes Planus, Grade one through three.

Manual Therapy of the Foot and Ankle

Very short Lever Arms, Highly Stable Joints Designed to Withstand Forces Far in Excess of Body Weight Limit effectiveness of Joint Mobilization in the Foot and Ankle.

Forefoot

- Metatarsal Mobility: Plantar Glide of First, 4th, and 5th Metatarsal Heads.
- Dorsal Glide of First Proximal Phalanx on Metatarsal for Great Toe Extension

Rearfoot

- Lateral Glide of Calcaneus for Inversion (subtalar Joint)
- Medial Glide of Calcaneus for Eversion (subtlalar Joint)

Talocrural Joint

- Posterior Glide of Talus for Ankle Dorsiflexion

Soft Tissue Mobilization

- Achilles / Gastrocnemius Longitudinal Myofascial Release
- Flexor Hallucis Longus Longitudinal Myofascial Release
- Transverse Friction Massage to Fibularis Longus

Low Dye Arch Taping

- First apply three strips of tape on the plantar surface of the foot. Following the plantar fascia.
- Apply an anchor from the base of the 5th metatarsal, around the calcaneus to the first metatarsal head
- Apply three or four stirrups under the arch starting laterally and pulling the medial longitudinal arch up.

Clinical Evaluation of the Foot

- The Foot must be evaluated in nonweight bearing exam on the examination table
- and along with the entire kinetic chain during standing and ambulation.

Nonweight Bearing Exam: Patient on examination table, palpate the lateral foot for tenderness of the following:

- Anterior Talofibular ligament
- Peroneal (fibular) tendons
- Assess peroneal retinaculum for tenderness or tears

Medial Foot: Palpate the following for Tenderness

- Deltoid ligament
- Posterior Tibialis, Flexor Hallucis Longus tendons

Plantar Structures

- Palpate Plantar Fascia for Tenderness – especially at calcaneus
- Flexor Hallucis Longus Tendon
- Plantar surface of Cuboid
- Metatarsal Heads
- Between third and fourth metatarsal heads (Site of Morton's Neuroma)

Ligament Testing

- Passively move the foot into inversion with overpressure to assess for tenderness of lateral ligaments
- Passively move the foot into eversion to assess for tenderness of the medial ligaments
- Perform Anterior Drawer test of the Talus to test Talofibular Ligaments.

Differentiating Structures Limiting Ankle Dorsiflexion

- Measure Ankle dorsiflexion **with knee in full extension** (10 degrees needed for normal gait)
- Measure Ankle dorsiflexion again **with knee flexed to remove Gastrocnemius tension**
- **If gastrocnemius is the limiting factor, dorsiflexion will be greater with knee flexed**

Assessing Great Toe Extension

- Test Active Great Toe Extension (60-70 degrees needed).
- If limited, assess first metatarsal mobility in Plantarflexion . First MTP dorsiflexion cannot occur without metatarsal plantar flexion.
- Observe for Hallux Valgus

Feiss Line Test for Grading Pes Planus: Start with the patient in sitting. No Weight bearing

- Draw a dot at the inferior aspect of the medial malleolus
- Draw another Dot at the middle of the Metatarsal head
- Note the position of the Navicular Tuberosity with respect to this line
- These three dots should be in a line

Patient Standing, Full weight bearing of both feet

- Draw the line from the Malleolar dot to the First metatarsal dot with the patient in full weight bearing. Now mark the Navicular position with a dot.
- Observe the position of the navicular tuberosity with the patient in full weight bearing.

Pes Planus grading In full weight bearing:

- Navicular Tuberosity lies on the line: Normal
- Navicular is below the line but in the top third of the distance between the line and the ground: First Degree Pes Planus.
- Navicular is in the middle third of the distance between the line and the ground: Second Degree Pes Planus
- Navicular is in the bottom third of the distance between the line and the ground: Third Degree Pes Planus

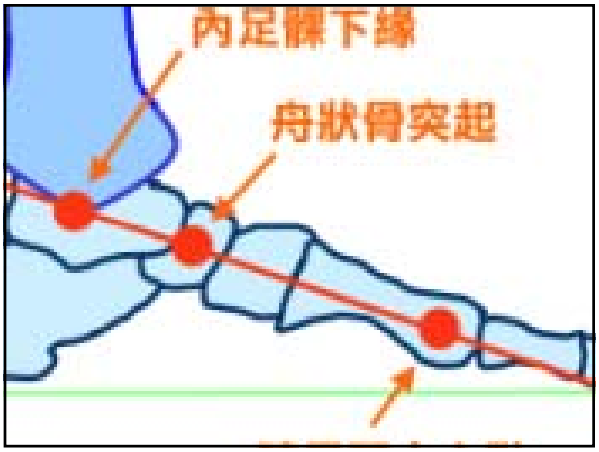

Evaluation of the Kinetic Chain During Gait

The Trunk:

Frontal Plane: Excessive Lateral Sway
Antalgic or Instability?

The Pelvis:

Horizontal Plane: Excessive Rotation
Too Little Rotation
Frontal Plane: Instability
Sagittal Plane: Anterior Tilt at Late Stance

- **Hip (Femoral Motion):**
- Horizontal Plane: Internal or External Rotation
- Frontal Plane: Adduction
- Sagittal Plane: Decreased Extension at push off

- **Knee:**
- Frontal Plane: Genuvalgus (or Varus)
- Sagittal Plane: Hyperextension

- **Ankle (Talocrural)**
- Horizontal Plane: Tibial Internal or External Rotation
- Frontal plane: Valgum or Varum of Tibia
- Sagittal Plane: Inadequate Dorsiflexion

- **Foot:**
- Arch Height in Early and Midstance
- Horizontal Plane: External or Internal Rotation of the Midfoot (Forefoot Abduction or Adduction).
- Frontal Plane: Eversion or Inversion at the subtalar joint (calcaneal Eversion or Inversion)
- Decreased Dorsiflexion of the Great Toe
- Failure to weight shift on to First Metatarsal for push off

Evaluation of Gait

Trunk: (Frontal Plane)

Pelvis: (Frontal and Sagittal Planes)

Hip: (Frontal, Sagittal, Transverse Planes)

Knee: Frontal, Sagittal, Transverse Planes)

Tibia: (Frontal, Transverse Planes)

Ankle: (Sagittal Plane)

Foot: (Transverse Plane, Arch height, Great Toe Extension, First Metatarsal Push off, Rear foot Valgus)

Patient Cases for the Foot

Case One: PesPlanus with Achilles Tendinitis.
42 year old male carpenter reports left posterior ankle pain with stair climbing and walking up hills. Symptoms have been present about three months and are getting worse.

O: Standing on toes reproduces Achilles pain, Achilles tendon is tender to palpation and there is palpable thickening of the tendon. There is a Third Degree PesPlanus in weight bearing. Active ankle dorsiflexion is 7 degrees with the knee in full extension, 12 degrees with knee flexion.

A: Achilles Tendinitis with PesPlanus. Moderate limitation of ankle dorsiflexion.

P: Ice, Achilles stretch and soft tissue release. Intrinsic and extrinsic muscle strengthening / re-education for arch enhancement.

1. Please list and demonstrate the manual techniques you will use with this patient.

2. Please describe and demonstrate the exercise program you will develop for this patient, including the home exercise program.

Case Two: Hallux Limitus
42 year old female office worker reports pain at the right first metatarsophalangeal (MTP) joint aggravated by walking. Symptoms have been present about 6 months and are getting worse.

O: There is an antalgic gait protecting the right lower extremity. Right great toe extension is limited to 20 degrees actively and 25 passively. Left great toe demonstrates 50 degrees dorsiflexion.Depression of the first metatarsal is markedly limited. Right first MPT joint is tender to palpation. Ankle dorsiflexion measured in full knee extension is 6 degrees bilaterally with knee in full extension, 10 with knee flexion.

A: Hallux limitus with painful first MTP joint. Moderate limitation of ankle dorsiflexion.

P: Ice, manual mobilization of first metatarsal and first MTP joint to increase great toe extension. Fibularis Longus retraining and strengthening.

1. Please list and demonstrate the manual techniques you will use with this patient.

2. Please describe and demonstrate the exercise program you will develop for this patient, including the home exercise program.

Case Three: Plantar Fasciitis with PesPlanus
32 year old male police officer reports right plantar foot pain aggravated by prolonged standing or walking. Also very painful when first standing in the morning.

O: There is a bilateral third degree PesPlanus in standing, right plantar fascia is tender to palpation at the calcaneal insertion. Right ankle dorsiflexion measured in full knee extension is 4 degrees, left is8 degrees. Ankle Dorsiflexion is full bilaterally when measured in knee flexion.

A: Right plantar fasciitis, pesplanus, tight gastrocnemius.

P: Stretching and manual soft tissue mobilization to Achilles tendon / gastrocnemius; arch building exercises, taping, arch support. Consider night splint.

1. Please list and demonstrate the manual techniques you will use with this patient.

2. Please describe and demonstrate the exercise program you will develop for this patient, including the home exercise program.

Case Four: PesCavus, Sacroiliac Pain
24 year old female teacher reports low back and sacroiliac pain aggravated by walking, prolonged standing and sit–to-stand. Symptoms have been present for about 5 months and are not getting better.

O: Sacroiliac pain is reproduced by direct PA pressure on the sacrum and with standing extension of the lumbar spine. Gait is remarkable for anterior pelvic tilt at end of stance phase bilaterally. Pescavus is present bilaterally, and active ankle dorsiflexion with full knee extension is limited to neutral bilaterally and WNL when measured in knee flexion. Active hip extension is zero bilaterally.

A: Sacroiliac dysfunction secondary to decreased ankle dorsiflexion and hip extension. Supinated foot type contributing to proximal dysfunction.

P: Stretching and manual soft tissue mobilization to Achilles tendon / gastrocnemius; active exercise to increase hip extension. Manual mobilization and active exercise to increase mobility of longitudinal and transverse arches of the foot.

1. Please list and demonstrate the manual techniques you will use with this patient.

2. Please describe and demonstrate the exercise program you will develop for this patient, including the home exercise program.

Case Five: Acute Inversion Ankle Sprain
18 year old female student reports left lateral ankle pain and difficulty walking after sustaining inversion ankle sprain one week ago.

O: Marked edema and echymosis of left lateral ankle. Very tender to palpation of anterior talofibular ligament. Anterior drawer of left ankle is mildly positive. Ambulation is without assistive device and is remarkable for antalgic gait protecting left ankle from weight bearing.

A: Acute Inversion Ankle Sprain, Grade II.

P: Rest, ice, compression, elevation. Normalize gait with single point cane or crutch, weight-bearing as tolerated. Progress to closed chain proprioception, stabilization training as tolerated.

1. Please list and demonstrate the manual techniques you will use with this patient.

2. Please describe and demonstrate the exercise program you will develop for this patient, including the home exercise program.

Lower Extremity Exercise Lab

- ROM: Hip Extension, Ankle Dorsiflexion, Knee
- Lower Extremity Stabilization, Proprioception
- Elimination of Extensor Lag
- Arch Building
- Fast Fiber, Return to Sport (or Challenging ADL'S)

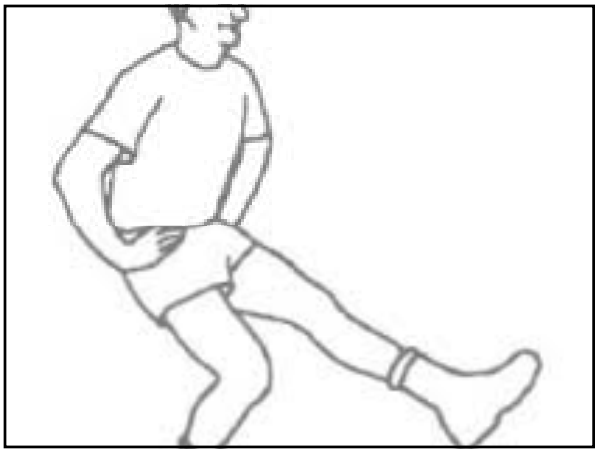

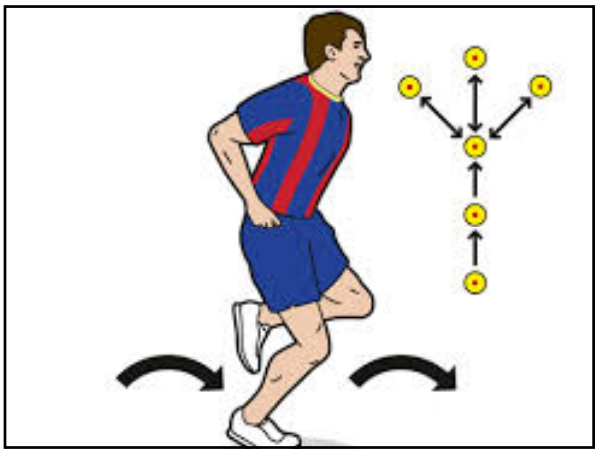



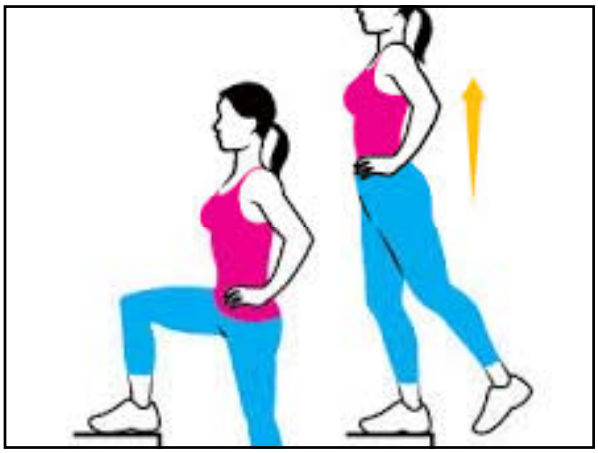

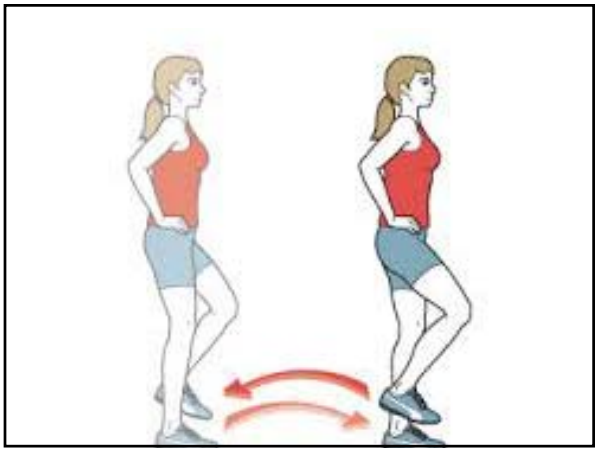

Arch Building Exercises

C

Course Evaluation
EXTREMITIES COURSE

Overall, I would rate the material presented this weekend as:

excellent	good	fair	poor

Comments:

I would rate the instructors as:

excellent	good	fair	poor

Comments:

The facilities were:

excellent	good	fair	poor

Comments:

The written material was:

excellent	good	fair	poor

Comments:

The ***majority*** of the material was:

New to me	Concepts I had been introduced to in school but had not applied to the clinical setting before	A more in-depth discussion of materials already familiar with	A review

Comments:

Time given to practice new material was:

Too Much	Sufficient	Not Enough

Comments:

Did the course meet its objectives of helping you to better evaluate and treat patients?

List some things that you learned this weekend that you will use with patients next week.

How could the course be improved?

HEALTH VOLUNTEERS OVERSEAS
ADVANCEMENT OF RWANDAN REHABILITATION SERVICES PROJECT
CONTINUING PROFESSIONAL DEVELOPMENT COURSES

Pre/Post Course Assessment

Date:_____

Did you attend any of the previous, spinal courses with Dr. Toni? Please circle one:

A. Yes I did attend Dr. Toni's Spinal Course.
B. No, I did not attend any of Dr. Toni's spinal courses.

All questions are multiple choice. Please circle one answer only for each question.

Questions 1 – 5 are based on the following patient-care story:

Your patient tells you it is very difficult to take care of her infant grandchildren because knee pain prevents her from climbing the stairs into their home and she is unable to bend her knee enough to get up and down from the floor. On physical exam you find active knee flexion is 0-65 degrees with 6/10 pain at end of range.

After 4 weeks of therapy, once a week for manual therapy and instruction in a home exercise program, she demonstrates 100 degrees flexion with 3/10 pain at end of range. The family has also built a handrail on the stairs.

Because of her increased knee function and the newly installed handrail your patient is now able to care for her grandchildren. You're still working with your patient to help her get up and down from the floor.

1. Restricted knee flexion (0-65 degrees) is best described as
   A. an impairment
   B. an activity
   C. a participation restriction

2. Manual therapy during your physiotherapy sessions is best described as
   A. a barrier
   B. an intervention
   C. an activity
   D. participation

3. Stair climbing is best described as
   A. an impairment
   B. an activity
   C. participation

4. Building a handrail is an example of
   A. an intervention to decrease an activity limitation
   B. modification of a barrier
   C. an intervention to decrease impairment
   D. both A and B above

5. If, after 12 weeks of physiotherapy emphasizing manual therapy and active exercise, your patient is demonstrating no further gains in knee function and appears to have reached maximum benefit from therapy, which course of action makes the most sense?
   A. Continue with the current plan of care another 4 weeks.
   B. Discharge the patient and let them know you can be of no further help
   C. Consider changing your focus from the impairment to the activity
   D. None of the above

Questions 6 through 9 refer to The Patient Specific Functional Scale (PSFS)

6. Using a written test to measure your patient's level of disability is important because it
   A. measures your patient's progress
   B. identifies goals
   C. helps you decide if your intervention is working
   D. provides valuable data for research
   E. All of the above

7. The PSFS grades the degree of activity limitation on a scale of
   A. Mild, Moderate, or Severe limitation
   B. percent activity limitation from zero percent to 100 percent limitation
   C. zero to five
   D. none of the above

8. The activities to be scored for the PSFS are determined by
   A. the patient
   B. the WHO Functional Disability Index
   C. the Rwandan Ministry of Health
   D. none of the above

9. The PSFS can be used as an initial measure of activity limitation as well as a measurement of functional outcome during the course of treatment.
   A. True
   B. False

Questions 10 through 20 refer to concepts of Therapeutic Exercise

10. Joint instability is best treated with
    A. eccentric contraction at end of range.
    B. isometric contraction in mid-range.
    C. high speed contraction throughout the entire range of motion.
    D. maximum contraction in the unstable position.

11. If rotator cuff tendons are irritated and painful, the best choice for your first session is to
    A. decrease the stress on the tendons and relieve the inflammation.
    B. strengthen the tendons even though it is painful.
    C. identify abnormal biomechanics and begin correcting this.
    D. A and C but not B.

12. Eccentric muscle contraction is defined as a contraction in which the muscle
    A. shortens.
    B. lengthens.
    C. does not change length because there is no joint movement.
    D. All of the above are true

13. Isometric muscle contraction is defined as a contraction in which the muscle
    A. shortens.
    B. lengthens.
    C. does not change length because there is no joint movement.

14. The type of muscle contraction that may rebuild partially torn tendons is
    A. eccentric
    B. concentric
    C. isometric
    D. slow fiber

15. Rotator cuff impingement can result from
    A. a weak rotator cuff.
    B. the scapula failing to upwardly rotate during humeral elevation.
    C. excessive thoracic kyphosis.
    D. All of the above

16. To strengthen knee extension at end-range, exercise must be performed
    A. quickly.
    B. Slowly,
    C. Isometrically
    D. at end range

17. To strengthen fast-twitch muscle fibers, the exercise must be performed
    A. using fast fibers.
    B. throughout the entire range of motion.
    C. isometrically.

18. Rehabilitation of an unstable, chronic ankle sprain must focus on increasing
    A. A. ankle strength.
    B. proprioception of the foot and ankle.
    C. stability of the foot and ankle.
    D. All of the above.

19. If knee extension is full passively but lacks 10 degrees actively, the problem could be
    A. hamstring weakness.
    B. quadriceps weakness.
    C. tibiofemoral hypomobility
    D. All of the above

20. The advantage of closed chain exercises for lower extremity rehab is
    A. it is more functional than open chain.
    B. the lower extremity normally functions in closed chain.
    C. open chain biomechanics increase the risk of injury.
    D. all of the lower extremity joints are more stable in closed chain.
    E. All of the above are true.

Instructor's Manual

This manual accompanies course material developed and presented in Rwanda as professional continuing education for practicing Rwandan physiotherapists from April through August, 2014.

The courses were developed and offered as part of the Health Volunteers Overseas (HVO) Advancement of Rwandan Rehabilitation Services (ARRS) Project, funded by USAID. The ARRS Project includes course content specific to orthopedic diagnoses of the spine and extremities, neurological conditions and pediatrics.

The content covered by this Instructor's Manual and its companion compilation of course materials is limited to orthopedic diagnoses of the extremities. This series of courses is entitled A Therapeutic Exercise Approach to Orthopedic Problems of the Extremities and consists of four Sessions. All course materials can be found onsite in digital form at the Physiotherapy Department of the University of Rwanda, Kigali. Digital files include the PDF files as well as the original Power Point and Word documents. All three dimensional anatomy videos used in this course are also available onsite. Videos are also publicly available online.

Please note that this course material is not intended for independent study but rather requires the presence of a skilled and knowledgeable instructor to maximize learning. Course notes are presented in outline form and participants are encouraged to take notes and write in details as they are presented and discussed in class. It is well documented that this maximizes learning because participants see the material, hear the material and write the material.

All courses were delivered with four instructors present in the classroom, two HVO volunteers and two local Rwandan physiotherapist co-teachers. This allowed for one instructor to provide the lecture/discussion while other instructors demonstrated all special tests, techniques, or procedures being discussed.

The Appendix concluding this Instructor's Manual provides the forms and documents that were used repeatedly in multiple sessions. The body of this manual is intended to guide the potential instructor in use of the power point and word files that comprise the region-specific content of the course.

Please note that when a the lecture topic changes and a new Power Point or Word document is being discussed, the title of the new document will appear in bold, underlined text.

Session I:

ICF Terminology
Patient Specific Functional Scale
Principles of Therapeutic Exercise
The Shoulder: Evaluation and Intervention

Session I begins with participants completing a **pre-post assessment tool** comprised of 20 questions. This tool is completed again upon the completion of the final course, Session IV. Completion of this pre-post assessment tool required about 20 minutes and was followed by presentation of **ICF concepts and terminology**. This material is based on the published work of the World Health Organization (WHO) Committee and Task Force for development of a common language for health care providers. In this course we present and discuss the basic terms related to impairment, activity, function, disability, participation and intervention. Although this presentation of ICF terminology is only presented in Session I, the terms and concepts are repeated in all sessions to encourage inclusion of this terminology in Rwandan rehabilitation culture.

It is emphasized that physiotherapy intervention must not be limited to domain of impairment but must also address functional activity limitations and must include activity modification as one of the primary tools of intervention.

Immediately following the ICF presentation/discussion the **Patient Specific Functional Scale** (PSFS) is presented and discussed. This discussion focuses broadly on the need to use a valid and reliable disability assessment tool and outcome measure in the practice of physiotherapy and then focuses more narrowly on the PSFS itself as an appropriate and useful assessment tool for Rwandan physiotherapists.

The PSFS is chosen for the following reasons:

1. Validity and reliability have been demonstrated for all major anatomical regions, both axial and appendicular.(Patient Specific Functional Scale References):
    A. Heford C, et al. JOSPT 2012. Vol 42, issue 2 pgs 56-65 . PSFS for use in UE dysfunction.
    B. Chatman, A, et al 1997 PhysTher 77. (8) 820-829 Lower Extremity
    C. Cleland, J and WHiman J 2012 Spine 2012. 12 (10) 921-931.Lumbar Spine.
    D. Westaway, Md, et al 1998, JOSPT 27 (5) 331-338. Cervical Spine.

2. Availability. In order to integrate a disability assessment tool into clinical practice, the tool must be readily available to the clinician. Although there are many reliable and valid tools in widespread use, nearly all of them require the clinic to invest resources to make the tools available to the clinician. The PSFS offers a huge advantage in this respect since it simply requires the patient to report three activity restrictions. These three items can easily be included in the initial or daily progress note. There is no need to purchase additional forms or resources to integrate the PSFS into practice.

3. Minimal time burden to patient and clinician. The information needed to complete the PSFS is information already included in a thorough subjective interview and adds far less time than other assessment tools. In a busy clinical setting, this is essential.

4. Elimination of culturally biased questions. The questions employed for the PSFS are generated by the patient.

Following the presentation/discussion of the PSFS, class participants are organized into small groups (three or four participants per group) to complete a case-based activity in which participants read the case and answer questions designed to foster integration and mastery of ICF terminology and use of the PSFS.

It is recommended that each case be assigned to at least two groups of participants. This allows the instructor to alternate between groups when asking questions and discussing the case. This format encourages interaction and discussion between the different groups working on the same case. This same format of case-based analysis and discussion within and between groups is employed throughout this series of courses.

Clinical Use of Therapeutic Exercise: Principles of Exercise Selection starts by making the distinction between an impairment-based exercise program, which addresses physiological factors such as strength, mobility, and stability of specific anatomical structures and an activity-based exercise program – which is likely to consist of a series of successive approximations of a desired functional activity. While the two approaches overlap considerably, the impairment-based approach is more likely to involve strengthening or stretching of specific anatomical structures. The exercises involve movements in a plane or planes specific to a given anatomical structure whereas an exercise program based on a functional activity, will involve multiple structures working in multiple planes to perform or approximate a functional activity.

Types of muscle contraction and the clinical indications for each contraction type are discussed and the need to consider fast versus slow fiber training is also introduced. The clinical indications for exercising through full range, just mid-range, or end range are discussed.

This lecture/discussion of exercise principles is followed by a lab experience in which participants perform specific types of contractions in a specific range of motion with a partner.

The Shoulder Girdle begins with a pair of three dimensional anatomy videos. The first reviews the glenohumeral joint and associated rotator cuff. The second reviews scapulothoracic and scapulohumeral function. These two videos are embedded in the power point presentation and can also be found in the file labeled "Anatomy Videos".

The shoulder is chosen as the first region for orthopedic evaluation and intervention because it is ideal for demonstrating the principles of musculoskeletal differential diagnosis. Isometric contractile testing, palpation of relevant structures and carefully chosen special tests allow the clinician to confidently state which tissues are generating pain. Observation of humeral, scapular and thoracic motion further allow the clinician to understand the biomechanical mechanism underlying the irritation of painful tissues. It is emphasized that musculoskeletal evaluation does not end with identification of irritated tissues. It is necessary to understand

the pathomechanics causing impingement, entrapment, or over-working of the painful tissues. This fundamental principle is repeated in all sessions.

Physiotherapy Diagnoses is a summary discussion of the findings necessary to make an accurate differential diagnosis of the shoulder girdle and serves as a guide to clinical reasoning.

The final classroom activity in Session I is the small groups working on **Patient Cases.** Each case requires the group to decide which evaluation procedures will be used to make the appropriate diagnosis, which manual therapy techniques will be useful and to develop an appropriate therapeutic exercise program for their patient. The PSFS is completed for each case. The groups then present, discuss, and demonstrate their findings to the class. It is recommended that group size of three to four individuals is ideal and that two groups are assigned the same patient case. This allows for intergroup interaction during the presentations.

Unlike sessions II through IV, Session I cases are divided into manual therapy cases and therapeutic exercise cases. Session I cases are also reproduced on separate handouts for follow up visits at week two and week four. In session II, III and IV materials, this progression of intervention remains an important part of the process but it was found that additional handout sheets were not necessary for this purpose and the program progression could effectively be developed without separate handouts for weeks two and four. Also, the practice of dividing the cases into manual therapy cases and therapeutic exercise cases was discontinued in subsequent sessions. It was found that both therapeutic exercise and manual therapy could be effectively employed in all cases and that separation of cases was best discontinued.

Participants are reminded that, as in all sessions, there is a **Homework Assignment** which is to be completed and turned in when they return for the following session.

Session II

The Hip and Knee: Evaluation and Intervention

The Hip

Prior to presenting the anatomy videos of the hip, a list of **important anatomical structures** is presented. This enables participants to attend to those structures which are of clinical relevance to the physiotherapist and will be discussed in class. The videos are excellent but osteology of the hip is covered in more detail than is necessary and it was felt that participants would benefit from having a list of important structures in front of them as the videos were being viewed so it would be clear they not expected to learn details not included on the list.

The fourth and fifth slides of the Power Point presentation contain the three dimensional anatomy videos and they can also be found in the file labeled "Anatomy Videos". Slides one through three discuss those factors complicating examination of the hip.

Examination of the Hip is a lab experience in which pairs of participants perform palpation of major structures of the hip and selected special tests of the hip.

Common Impairments and Diagnosis of the Hip is a lecture/discussion presentation and is followed by **Manual Therapy of the Hip** which is a lab experience in which pairs of participants perform selected manual therapy techniques.

The small group format is employed for **Patient Cases** in which relevant testing and evaluation procedures are performed for each case, an appropriate exercise program is developed and appropriate manual therapy procedure performed. Each group presents their case to the class and it is suggested that for each case, two groups present simultaneously. This allows the instructor to alternate questions between the two groups and to develop inter-group discussion and interactions.

Completion of the PSFS is also a part of this exercise.

The Knee

Study of the knee begins with a series of four anatomy videos. One of these videos, unfortunately, is a promotional video for a commercial product – a patellofemoral knee brace. It is emphasized to the participants that we are not advocating use of this brace but simply using the video as it provides an excellent description and visual representation of patellar maltracking. It is emphasized that we will perform patellar taping, other manual techniques and therapeutic exercise as interventions for patellofemoral dysfunction. These videos can be found in the file labeled "Anatomy Videos".

Palpation of the Knee follows the videos. This is a lab experience in which pairs of participants palpate relevant structures of the knee.

Common Diagnoses and Exam Procedures is a lecture and demonstration in which common knee diagnoses are presented along with relevant diagnostic testing procedures for each diagnosis. Following this lecture/demonstration, participants use this same document as a guide for performing the testing procedures themselves. A group size of two participants is recommended.

Clinical Decision-Making in Physiotherapy of the Knee is a lecture/discussion presentation in which it is emphasized that because the knee offers only one plane of motion, rehabilitation is less complex than in the hip or shoulder, where we must contend with three axes of movement.

Relevant special tests and exam findings that lead to an accurate diagnosis are reviewed and summarized. It is then emphasized that regardless of the specific anatomical structure causing dysfunction of the knee, rehabilitation consists of controlling inflammation and swelling, obtaining full extension, functional flexion, good single leg stability, and proper patellar tracking.

As in all sessions, this session is concluded with a small group format studying **Patient Cases.** Special tests and examination procedures are selected and performed, appropriate self-care is outlined, an appropriate therapeutic exercise program is developed, and appropriate manual therapy techniques are chosen and performed. Each group then comes in front of the class to explain their clinical reasoning and demonstrate all techniques and exercises. It is recommended that two groups be in front of the class presenting on the same case simultaneously. This allows the instructor to guide and moderate the interaction between the two groups and maximize the information conveyed by the case presentations.

Course Evaluations are completed and participants are reminded of the **Homework Assignment** to be handed in during the following session.

Session III

Elbow, Wrist and Hand: Evaluation and Intervention

Session III begins with a series of three dimensional anatomy videos. Three of these pertain to the elbow and one to the hand. These videos can be found in the folder labeled "Anatomy Videos".

Intrinsic Hand Anatomy and Common Diagnosis is a six page power point handout (three slides per page) which covers the extensor mechanism and intrinsic muscles of the hand since these topics are not well-represented in the videos. After reviewing the relevant anatomy, common diagnoses of the hand are presented, starting with the mallet finger deformity. Emphasis is placed on splinting of the mallet deformity as intervention to allow the tendon to reattach and to prevent progression to a swan-neck deformity. Boutonniere's deformity is also presented and the mechanism of injury is discussed. For all deformities, splinting is recommended to limit the progression of deformity. Simple splints are demonstrated and it is recommended that plaster of Paris could be used to fabricate an effective splint as well.

Surface Anatomy of the Hand is demonstrated to the class as the slides are presented and two instructors demonstrate palpation. Students are encouraged to leave their seats and come up to the front where the demonstration is taking place if they are unable to see adequately from their seat. This is followed by **Palpation of the Elbow and Forearm** which follows the same format and after these two lecture/demonstrations, participants pair up and follow the same two handouts as a guide to a lab exercise in palpation of the hand, elbow and wrist.

Common Diagnoses of the Wrist and Elbow are presented next and as one instructor presents the lecture/discussion, two other instructors demonstrate the special tests used to diagnose these conditions.

The participants then proceed to a laboratory exercise in which pairs of participants perform these same tests using the 4-page power point handout (three slides to a page) starting with **Tennis Elbow** as a guide.

Participants return to their seats as **Manual Therapy to the Elbow, Wrist, and Hand** is discussed and presented. The format used in all such demonstrations is one instructor delivering and guiding the lecture/discussion while two other instructors demonstrate the techniques being discussed. After observing this demonstration, participants practice these techniques in pairs. Note that the single page **Tendon Gliding Exercises** is included in this exercise.

The small group activity of studying and presenting the Patient Cases takes place next. This is the same format used in all courses of all four sessions and involves a group of three participants studying the case they are assigned and then presenting the case to the class. Specific questions to be answered by the group members are provided by the **Worksheet for Manual Therapy Practical** and **Worksheet for Therapeutic Exercise Practical.**

Session III is concluded by an **Upper Extremity Exercise Lab** in which a number of stations are created and small groups of participants perform the exercises indicated at each station. There are three or four exercises at each station and the stations are organized into functional groups as follows: Scapular Stabilization, Rotator Cuff strengthening, Glenohumeral Stabilization in Neutral, Passive Glenohumeral Elevation, Stretching of Wrist Extensors and Flexors, Eccentric strengthening of Wrist Extensors and Flexors, Tendon Gliding Exercises for the Hand.

Following participation in the exercise lab, each group of participants is asked to demonstrate one exercise of their own creation, based on the principles discussed in principles of therapeutic exercise discussion.

The upper extremity exercise lab was not originally designed into the course but was introduced into Session III. It was originally thought that patient cases would provide sufficient opportunity for participants to demonstrate skill in developing therapeutic exercise programs for specific diagnoses but it was observed that this was not the case. Clinical decision making and manual therapy skills were evident in the case presentations but development of the therapeutic exercise component appeared to be lacking.

Please note that, other than the very brief pre-post assessment tool, there are no testing procedures built into this course. This makes the patient case presentations particularly valuable as a means of assessing participant understanding and integration of course content. It is recommended that the patient case presentations be maximized both as an assessment tool and as an opportunity to summarize and consolidate participant learning.

Participants are reminded that, as in all sessions, there is a **Homework Assignment** which is to be completed and turned in when they return for the following session.

Session IV

The Foot and Ankle: Evaluation and Intervention

Before presenting the three dimensional anatomy videos for the foot and ankle, a discussion of **Biomechanics of the Foot** is presented. The purpose of this lecture/discussion is to place the many anatomical structures of the foot into the functional context of controlling the arches of the foot. It is emphasized that both the intrinsic and extrinsic muscles, the ligaments and even the bone structure all serve to control the rigidity/ flexibility cycles of the foot. The pathomechanics of both pes cavus and pes planus are discussed. Following this discussion, three dimensional videos of foot and ankle anatomy are presented.

Following the videos, **Functional Anatomy of the Foot** is presented. This is a lecture/discussion in which extrinsic muscles are discussed in some detail with respect to their role in controlling the transverse and longitudinal arches and the pathomechanics present if they fail to perform this function. The ligaments and plantar fascia are similarly discussed. Intrinsic muscles of the foot are not studied individually but simply as a group with the function of maintaining the transverse and longitudinal arches.

Common diagnoses of the foot are covered in this discussion as well.

Functional Anatomy of the Ankle follows and this is a lecture/discussion format discussing functional anatomy and common diagnoses of the talocrural joint.

Palpation of the Foot and Ankle is a lab experience performed in pairs after being demonstrated by the instructors in class.

Common Diagnoses of the Foot and Ankle is a lecture/discussion in which common pathologies are discussed. The pathomechanics and/or mechanism of injury leading to these diagnoses are emphasized and appropriate intervention is presented and discussed.

Diagnostic Evaluation of the Foot is a laboratory experience which is demonstrated in front of the class prior to participants paring up and performing the evaluation procedures on each other. This lab presents the same diagnoses that were presented in Common Diagnoses of the Foot and Ankle. During that presentation the evaluation procedures and special test were not presented and that is the purpose of this lab activity. All relevant special test and evaluation procedures are performed by the participants. As with all lab experiences, the instructors move from group to group answering questions and assisting with proper performance of the procedure.

Manual Therapy of the Foot and Ankle is a laboratory experience and this follows the same format as all lab experiences in these courses: two of the instructors demonstrate manual therapy techniques in front of the class while one instructor presents and discusses the Power Point slides and points out the details of the techniques being demonstrated by the instructors. Following this demonstration, participants perform these techniques on each other in groups of two and are assisted as needed by course instructors.

Clinical Evaluation of the Foot introduces more detailed biomechanical analysis and further special tests and then proceeds to present a systematic approach to gait analysis. This is first demonstrated by two instructors in front of the class while one instructor presents the slides and discusses the details of what is being performed.

Participants are then put into small groups of approximately four individuals to perform these techniques and to perform gait analysis. A gait analysis data sheet is provided for recording observations regarding gait analysis. The class reconvenes and their findings are discussed.

Foot and Ankle Cases are presented next and this is the same small group format employed in all previous session, in which each group determines the appropriate special test and examination procedure to perform, which manual techniques to perform, and develops and appropriate therapeutic exercise program for their patient. The group then presents their findings in front of the class along with another group who has been given the same case. Intergroup interaction is facilitated by the instructor in order to maximize the learning opportunity afforded by this case-based format.

The final activity of Session IV is the **Lower Extremity Exercise Lab**. This is analogous to the upper extremity exercise lab of Session III. Stations are established using the printed photos in the handouts and small groups are assigned to each station. The stations are created to emphasize specific intervention goals. Stations include stability and proprioception; increasing ankle dorsiflexion and hip extension; arch building exercises; and fast fiber, multiaxial rehab for return to sports or activities of daily living.

Session IV is concluded with completion of the **course evaluation** and the **pre-post assessment tool** which was previously completed at the beginning of Session I.

Appendix

This appendix consists of forms and documents that are common to Sessions I- IV

Appendix Contents:

1. ARRSP Educational Program Objectives
2. Emphasis of Continuing Education Courses Offered Through ARRS Project
3. Expectations of Course Participants
4. Pre-Post Course Assessment Tool (Sessions I and IV only)
5. Patient Specific Functional Scale
6. Worksheet for Therapeutic Exercise Practical
7. Worksheet for manual Therapy Practical
8. Homework Assignment (not employed in Session IV)
9. Course Evaluation

ARRSP and Educational Program Objectives

These objectives are intended to guide patient interactions across all of the teaching units presented in Rwanda.

Given a patient with any diagnosis or functional limitation, the therapist will be able to:

1. Perform a patient interview that identifies functional problems
2. Determine if the patient needs to be referred to another health care professional
3. Interpret information from observation of the patient moving
4. Identify impairments to examine specific to the patient's problem
5. Safely, effectively and efficiently perform examination procedures specific to the patient's problem(s)
    a. Determine a 'comparable sign' to assess progress
6. Combine information from the interview, observation and examination to determine a reason why the patient has functional problems
7. Select treatments that address the cause of the functional problems
8. Safely, effectively and efficiently perform treatment procedures
9. Document examination, treatment, progress and functional goals
10. Use functional outcome measures to document progress and to communicate with other healthcare professionals
11. Assess outcomes, modify treatment, and determine when discharge is appropriate
12. Develop a discharge plan including home programs and referral to community resources
13. Adjust and reflect on practice outcomes using knowledge and skills gained during the courses
14. Analyze outcomes and present results to Physiotherapists, Medical and other Healthcare Providers to promote the Physiotherapy profession
15. Identify community resources who will refer patients for Physiotherapy and develop a plan to increase communication with these individuals

EMPHASIS OF CONTINUING EDUCATION COURSES OFFERED THROUGH THE ADVANCEMENT OF RWANDAN REHABILITATION SERVICES (ARRS) PROJECT

During the month of April 2013 HVO conducted a Needs Assessment in Rwanda interviewing clinicians in rural and urban areas as well as the physiotherapy faculty at the University of Rwanda. Our goals were not only to determine which topics would be taught in the ARRS Project but also to assess strengths and weaknesses in the current professional education and practice of physiotherapy in Rwanda. In this way we have been able to identify four areas that will be emphasized in each course.

I. Clinical Decision-Making

a. Special emphasis will be placed on:
   i. the design of individual treatment programs based on the findings in the initial evaluation.
   ii. Regular re-assessment of progress and progression of treatment programs.

b. By strengthening clinical decision-making skills, the profession of physiotherapy will move more strongly from the role of technician to the role of professional, thereby helping to increase the respect for the profession and increase appropriate referrals.

II. Active Treatment Techniques

a. Courses will focus on patient-centered treatments including therapeutic exercise, therapeutic activity, and skilled manual therapy.

III. Clinical Skill Building

Lab time to practice newly taught skills must be emphasized and adequate time for structured practice needs to be built into the curriculum.

Physiotherapy knowledge base must be correlated with *skill mastery* in order to most effectively treat patients. Both University of Rwanda physiotherapy faculty and practicing clinicians have identified the need to build on the clinical skills that they already possess, and incorporate new, evidence-based skills into their practices.

IV. Return to Function

Courses will emphasize the physiotherapy goal of return to optimal function, with patients being active participants in determining their individualized functional rehabilitation goals. Courses will utilize WHO's International Classification of Function (ICF) as a means to determine disabilities and functional treatment goals.

HEALTH VOLUNTEERS OVERSEAS
ADVANCEMENT OF RWANDAN REHABILITATION SERVICES PROJECT
CONTINUING PROFESSIONAL DEVELOPMENT COURSES

EXPECTATIONS of COURSE PARTICIPANTS

1) Attend and participate in class sessions one weekend a month (two days) for the duration of the course.
2) Arrive on time to each class session and return from tea break and lunch at the designated time.
3) Do not use cell phones in class.
4) Strive to have appropriate patients scheduled to evaluate and/or treat when the course instructors do clinical visits with you.
5) Turn in homework assignments on time.
6) Participate in class discussions.
7) Use lab time to practice newly taught techniques.
8) Practice new techniques in your clinical setting.
9) Develop a plan to share the material you have learned with other professionals.
10) Use newly learned skills in your practice after the course is over.

You will earn one CPD unit for every hour that you attend the course, and each fully completed homework assignment is worth two CPD units.

HEALTH VOLUNTEERS OVERSEAS
ADVANCEMENT OF RWANDAN REHABILITATION SERVICES PROJECT
CONTINUING PROFESSIONAL DEVELOPMENT COURSES

Pre/Post Course Assessment

Date: _____

Did you attend any of the previous, spinal courses with Dr. Toni? Please circle one:

A. Yes I did attend Dr. Toni's Spinal Course.
B. No, I did not attend any of Dr. Toni's spinal courses.

All questions are multiple choice. Please circle one answer only for each question.

Questions 1 – 5 are based on the following patient-care story:

Your patient tells you it is very difficult to take care of her infant grandchildren because knee pain prevents her from climbing the stairs into their home and she is unable to bend her knee enough to get up and down from the floor. On physical exam you find active knee flexion is 0-65 degrees with 6/10 pain at end of range.

After 4 weeks of therapy, once a week for manual therapy and instruction in a home exercise program, she demonstrates 100 degrees flexion with 3/10 pain at end of range. The family has also built a handrail on the stairs.

Because of her increased knee function and the newly installed handrail your patient is now able to care for her grandchildren. You're still working with your patient to help her get up and down from the floor.

1. Restricted knee flexion (0-65 degrees) is best described as
   A. an impairment
   B. an activity
   C. a participation restriction

2. Manual therapy during your physiotherapy sessions is best described as
   A. a barrier
   B. an intervention
   C. an activity
   D. participation

3. Stair climbing is best described as
   A. an impairment
   B. an activity
   C. participation

4. Building a handrail is an example of
    A. an intervention to decrease an activity limitation
    B. modification of a barrier
    C. an intervention to decrease impairment
    D. both A and B above

5. If, after 12 weeks of physiotherapy emphasizing manual therapy and active exercise, your patient is demonstrating no further gains in knee function and appears to have reached maximum benefit from therapy, which course of action makes the most sense?
    A. Continue with the current plan of care another 4 weeks.
    B. Discharge the patient and let them know you can be of no further help
    C. Consider changing your focus from the impairment to the activity
    D. None of the above

Questions 6 through 9 refer to The Patient Specific Functional Scale (PSFS)

6. Using a written test to measure your patient's level of disability is important because it
    A. measures your patient's progress
    B. identifies goals
    C. helps you decide if your intervention is working
    D. provides valuable data for research
    E. All of the above

7. The PSFS grades the degree of activity limitation on a scale of
    A. Mild, Moderate, or Severe limitation
    B. percent activity limitation from zero percent to 100 percent limitation
    C. zero to five
    D. none of the above

8. The activities to be scored for the PSFS are determined by
    A. the patient
    B. the WHO Functional Disability Index
    C. the Rwandan Ministry of Health
    D. none of the above

9. The PSFS can be used as an initial measure of activity limitation as well as a measurement of functional outcome during the course of treatment.
    A. True
    B. False

Questions 10 through 20 refer to concepts of Therapeutic Exercise

10. Joint instability is best treated with
    A. eccentric contraction at end of range.
    B. isometric contraction in mid-range.
    C. high speed contraction throughout the entire range of motion.
    D. maximum contraction in the unstable position.

11. If rotator cuff tendons are irritated and painful, the best choice for your first session is to
    A. decrease the stress on the tendons and relieve the inflammation.
    B. strengthen the tendons even though it is painful.
    C. identify abnormal biomechanics and begin correcting this.
    D. A and C but not B.

12. Eccentric muscle contraction is defined as a contraction in which the muscle
    A. shortens.
    B. lengthens.
    C. does not change length because there is no joint movement.
    D. All of the above are true

13. Isometric muscle contraction is defined as a contraction in which the muscle
    A. shortens.
    B. lengthens.
    C. does not change length because there is no joint movement.

14. The type of muscle contraction that may rebuild partially torn tendons is
    A. eccentric
    B. concentric
    C. isometric
    D. slow fiber

15. Rotator cuff impingement can result from
    A. a weak rotator cuff.
    B. the scapula failing to upwardly rotate during humeral elevation.
    C. excessive thoracic kyphosis.
    D. All of the above

16. To strengthen knee extension at end-range, exercise must be performed
    A. quickly.
    B. slowly.
    C. isometrically.
    D. at end range.

17. To strengthen fast-twitch muscle fibers, the exercise must be performed
    A. using fast fibers.
    B. throughout the entire range of motion.
    C. isometrically.

18. Rehabilitation of an unstable, chronic ankle sprain must focus on increasing
    A. ankle strength.
    B. proprioception of the foot and ankle.
    C. stability of the foot and ankle.
    D. All of the above.

19. If knee extension is full passively but lacks 10 degrees actively, the problem could be
    A. hamstring weakness.
    B. quadriceps weakness.
    C. tibiofemoral hypomobility.
    D. All of the above

20. The advantage of closed chain exercises for lower extremity rehab is
    A. it is more functional than open chain.
    B. the lower extremity normally functions in closed chain.
    C. open chain biomechanics increase the risk of injury.
    D. all of the lower extremity joints are more stable in closed chain.
    E. All of the above are true.

Patient-Specific Functional Scale (PSFS]

Patient Name: _____ Date: _____

Diagnosis: _____

Please list three activities that are difficult for you because of the condition we are treating.

Activity 1: _____

0---------1---------2---------3---------4--------5---------6--------7---------8---------9---------10
No Difficulty — Moderate Difficulty — Impossible

Activity 2: _____

0---------1---------2---------3---------4--------5---------6--------7---------8---------9---------10
No Difficulty — Moderate Difficulty — Impossible

Activity 3: _____

0---------1---------2---------3---------4--------5---------6--------7---------8---------9---------10
No Difficulty — Moderate Difficulty — Impossible

Total Score: Activity 1+ Activity 2 + Activity 3 = _____ x 100 =_____ percent disability
Divided by: 30

Worksheet for Therapeutic Exercise Practical

Clinical decision making for Impairment-based Exercise Interventions:
You are to design a therapeutic exercise program for your patient.
Please answer the following questions in the space provided.

Patient Number: _____

1. Identify which tissues you are treating with your exercise interventions.

2. State the physiological effect the exercise will have on these tissues.

3. State the muscle or muscle groups you will include in your intervention and the type of contractions you will use. Explain your reasoning.

4. In what part of the range will you be exercising this patient? Explain your reasoning.

5. Describe and be prepared to demonstrate at least one of your therapeutic exercises.

6. 6. Write short-term and long-term goals for this patient.

Worksheet for Manual Therapy Practical

Clinical decision making for Impairment-based Manual Therapy Interventions:
You are to design a manual therapy program for your patient.
Please answer the following questions in the space provided.

Case Number: _____

1. Identify which tissues you are treating with your interventions.

2. State the physiological effect the manual techniques will have on these tissues.

3. State the grade of mobilization will you employ with this patient. Explain your reasoning.

4. State the direction of mobilization will you employ with this patient? Explain your reasoning.

5. Describe and be prepared to demonstrate at least one of your manual techniques.

Homework Assignment:

Please choose one patient and use this form to gather information on that patient. Please do not include the patient's name. Please bring this form back with you next month and be prepared to discuss the case. You receive 2.0 CPD units for completion of this homework assignment. Thank you.

Your Name: _____

Date assignment is completed: _____

Patient Diagnosis: _____

Briefly describe the subjective and objective exam:

S:

O:

1. Please bring a completed Patient Specific Functional Scale for this patient. Do not include the patient's name.

2. Identify the major Impairments and Activity Limitations for this patient.

3. Identify which tissues you are treating with your exercise interventions.

4. State the physiological effect the exercise has on these tissues.

5. Please describe the exercise program you used with this patient. Include a detailed description including:
    - Which muscles or other tissues are involved.
    - Where in the range of motion the exercises were performed. Please explain why you chose this part of the range.
    - What type of contractions you used. Please explain why you chose this type of contraction.

6. Please describe the outcome with this patient. Use the PSFS to demonstrate the outcome. Include whether or not the exercise program was useful to you and your patient.

7. Please indicate if the material from this course was helpful to you in working with this patient. Please say why or why not.

Thank You!

Course Evaluation
EXTREMITIES COURSE

Overall, I would rate the material presented this weekend as:

excellent	good	fair	poor

Comments:

I would rate the instructors as:

excellent	good	fair	poor

Comments:

The facilities were:

excellent	good	fair	poor

Comments:

The written material was:

excellent	good	fair	poor

Comments:

The ***majority*** of the material was:

New to me	Concepts I had been introduced to in school but had not applied to the clinical setting before	A more in-depth discussion of materials already familiar with	A review

Comments:

Time given to practice new material was:

Too Much	Sufficient	Not Enough

Comments:

Did the course meet its objectives of helping you to better evaluate and treat patients?

List some things that you learned this weekend that you will use with patients next week.

How could the course be improved?